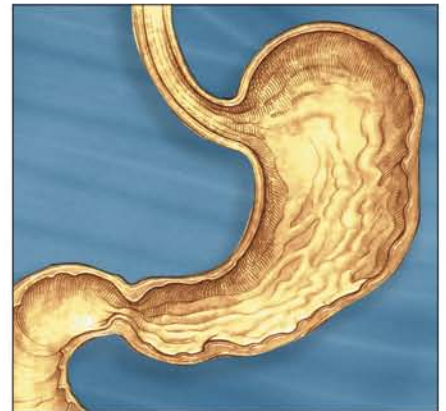
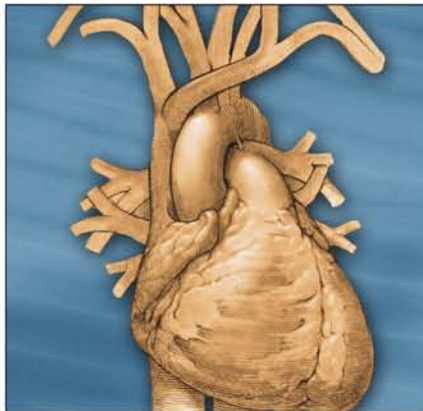
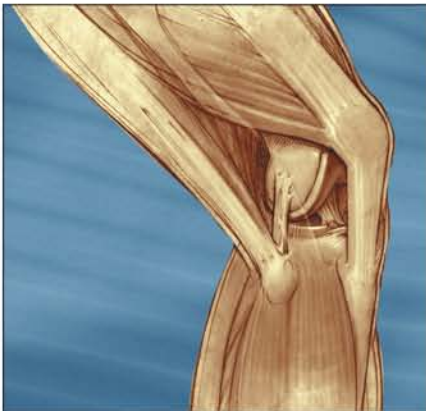
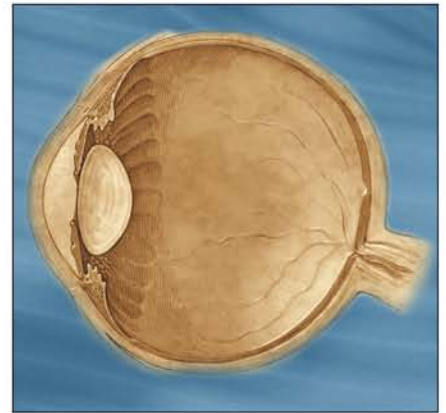
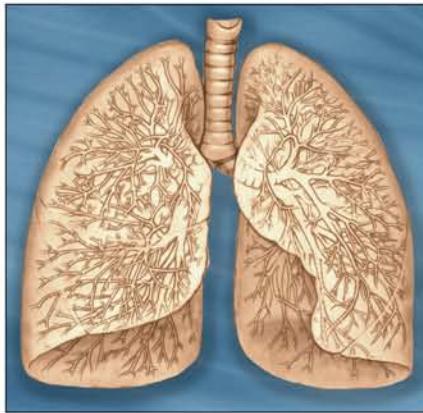
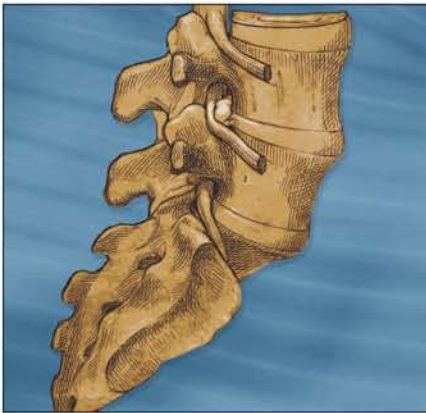


The Facts On File
Illustrated Guide
to the
Human Body



THE DIAGRAM GROUP

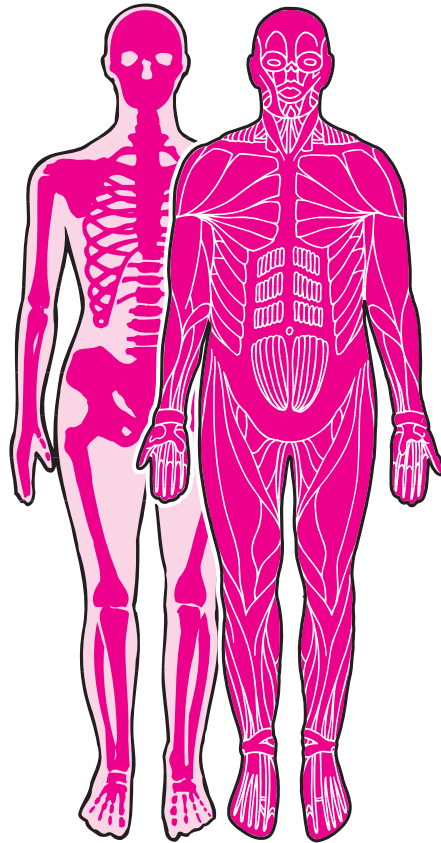
How to go to your page

This eBook contains two volumes. Each volume has its own page numbering scheme, consisting of a volume number and a page number, separated by a hyphen.

For example, to go to page 5 of Volume 1, type v1-5 in the "page #" box at the top of the screen and click "Go." To go to page 5 of Volume 2, type v2-5 in the "page #" box... and so forth.

THE FACTS ON FILE
ILLUSTRATED GUIDE TO
THE HUMAN BODY

SKELETAL AND MUSCULAR SYSTEMS



THE DIAGRAM GROUP

The Facts On File Illustrated Guide to the Human Body: Skeletal and Muscular Systems

Copyright © 2005 The Diagram Group

Editorial: Lionel Bender, David Harding, Denis Kennedy,
Gordon Lee, Steve Parker, Jamie Stokes

Scientific consultant: Stephen Rudd

Design: Anthony Atherton, Richard Hummerstone,
Lee Lawrence, Kim Richardson, Ben White

Illustration: Pavel Kostal, Kathleen McDougall

Picture research: Neil McKenna

Indexer: Jane Parker

All rights reserved. No part of this book may be reproduced or utilized in any form or by any means, electronic or mechanical, including photocopying, recording, or by any information storage or retrieval systems, without permission in writing from the publisher. For information contact:

Facts On File, Inc.
132 West 31st Street
New York NY 10001

eISBN 978-1-4381-2546-6

Library of Congress Cataloging-in-Publication Data

The Facts on File illustrated guide to the human body. Skeletal and muscular systems / The Diagram Group.
p. cm.

Includes index.

1. Musculoskeletal system—Juvenile literature. I. Title: Skeletal and muscular systems. II. Diagram Group.

QM100.F33 2005

611'.7—dc22

2004022096

Facts On File books are available at special discounts when purchased in bulk quantities for businesses, associations, institutions, or sales promotions. Please call our Special Sales Department in New York at 212/967-8800 or 800/322-8755.

You can find Facts On File on the World Wide Web at
<http://www.factsonfile.com>

Printed in the United States of America

EB Diagram 10 9 8 7 6 5 4 3 2 1

This book is printed on acid-free paper.

Note to the reader

This book is not intended to serve as a medical textbook for either physicians or patients. The information and advice it contains should not be used or relied upon without consulting the advice of a qualified physician. The publishers disclaim any responsibility for the accuracy of the information or advice that this book contains and any responsibility for any consequences that may result from any use or reliance thereon by the reader.

Contents

Introduction: About this book	4		
SECTION 1		SECTION 4	
BODY SYSTEMS		ARMS & SHOULDERS	
Introduction	6	Introduction	64
Parts of the skeletal system	8	Shoulder muscles	66
Skeletal key words and diagrams	10	Arm muscles	68
Bone types and development	12	Wrist and hand muscles	70
Bone and cartilage structure	14	Exercises and disorders	72
Muscle system	16		
Muscle features and key words	18	SECTION 5	
Muscle layers—superficial	20	LEGS & FEET	
Deep muscles and motor units	22	Introduction	74
Muscle contractions and names	24	Leg muscles	76
Muscle attachments and fibers	26	Foot bones and muscles	78
Skeleton and muscle care	28	Leg and feet exercises	80
Fitness and exercise	30	Leg disorders	82
Skeletal disorders	32	Foot disorders	84
Muscular disorders	34		
SECTION 2		SECTION 6	
HEAD & SPINE		JOINTS	
Introduction	36	Introduction	86
Vertebrae	38	Joint types	88
Pelvic girdle	40	Joint movements 1	90
Mouth, jaws, and teeth	42	Joint movements 2	92
Head muscles	44	Joint mobility exercises	94
Spinal muscles	46	Posture problems and exercises	96
Pelvic and lower back muscles	48	Joint disorders 1	98
Relaxing the neck and back	50	Joint disorders 2	100
Strengthening the neck and back	52		
SECTION 3		Glossary of the human body	
CHEST & ABDOMEN		Web sites to visit	
Introduction	54	Index	
Chest muscles	56		
Abdominal muscles	58		
Isometric exercises	60		
Strengthening exercises	62		

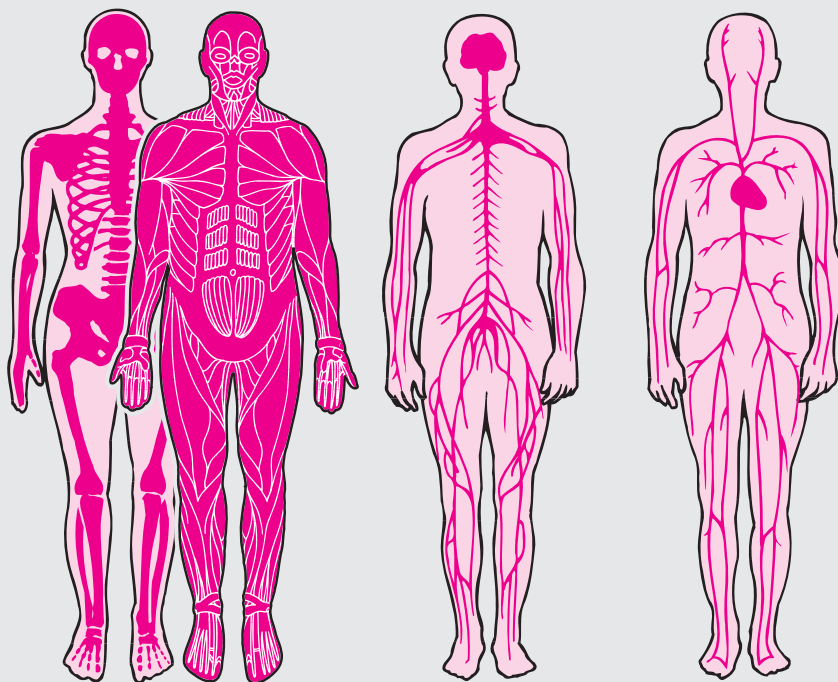
This book is a concise, illustrated guide to the anatomy, physiology, well-being, and disorders of the human skeletal and muscular systems. It has been written and illustrated specially for students and laypeople interested in medicine, health, fitness, and first aid. The subject is dealt with in clear steps, so that the reader can steadily acquire a good overall understanding. Explanatory texts, diagrams, illustrations, captions, and fact boxes are combined to help readers grasp important information at a glance. A glossary of scientific and jargon words defines medical terms in everyday language. A list of Web sites provides links to other relevant sources of information, and the index enables quick access to articles.

There are six sections in the book. The first section looks in detail at the components of the skeletal and muscular systems. The other sections survey each major region of the body, from the head to the toes and joints. Within each section, discussion and illustration of the structure and function of anatomical parts are followed by the general principles of healthcare, fitness, and exercise, and a survey of the main disorders and diseases affecting the region. Information is presented as double-page topics arranged in subsections.

Section 1: BODY SYSTEMS deals with the individual bones and muscles that make up the skeleton and musculature. It looks at the microscopic structures of bone, muscle cells,

Human body systems

This book is one of eight titles in THE FACTS ON FILE ILLUSTRATED GUIDE TO THE HUMAN BODY series, which looks at each of the major body systems in turn. Some of the titles in the series include more than one system. The skeletal and muscular systems, and the blood and lymphatic systems, for example, work in conjunction and so are treated together. There is a separate title for human cells and genetics, which are the building blocks and underlying chemistry of all body systems.



**Skeletal and
Muscular Systems**

**Brain and
Nervous System** **Heart and
Circulatory System**

and tissues, and how these relate to the functioning of systems.

Section 2: HEAD & SPINE surveys the skeleton and musculature of the upper part of the body. This includes discussion of the teeth.

Section 3: CHEST & ABDOMEN looks at the bones and muscles associated with the rib cage and how exercise of this region can help with general fitness.

Section 4: ARMS & SHOULDERS features the upper limbs and limb girdles.

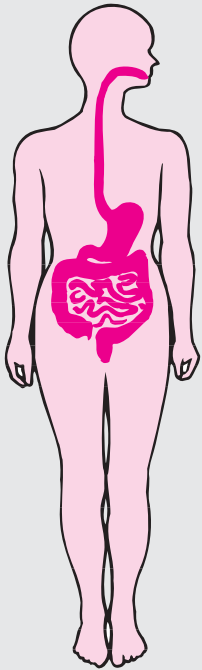
Section 5: LEGS & FEET looks at the bones and muscles of the lower limbs and limb girdle. The exercises and disorders dealt with here are particularly relevant to athletes.

Section 6: JOINTS examines the workings of


skeletal joints, where muscles and bones work together to provide body movement.

This book has been written by anatomy, physiology, and health experts for non-specialists. It can be used:


- as a general guide to the way the human body functions
- as a reference resource of images and text for use in schools, libraries, or in the home
- as a basis for examination preparation for students of human biology, medicine, nursing, physiotherapy, and general healthcare.



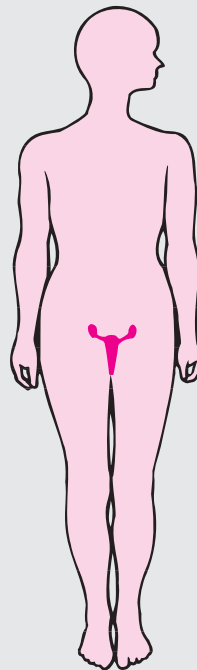
Digestive System



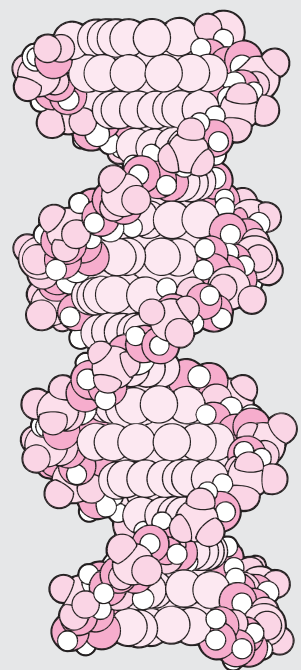
The Senses



Respiratory System



Reproductive System



Cells and Genetics

The skeletal system consists of all the bones in the body, and provides an internal protective and supportive framework. Most bones are linked at moveable joints to make the system flexible. Bones act as anchor points for muscles and are pulled by them to produce body movements. However, not all of the muscular system is associated with the skeleton. Muscle tissue is also found in the intestines, heart, and other internal organs.

Skeleton and muscle facts

- The bones of the skeleton make up about 12–14 percent of the body's overall weight.
- Muscles make up about 45 percent of body weight in a typical male, and 40 percent in a typical female.

Muscular system functions

To produce movement

Movements and actions of the body are caused by contraction (shortening) of skeletal muscles.

To maintain posture

Certain muscles work constantly to maintain stationary body positions and balance, as when sitting or standing. They tense against the force of gravity and the pull of other muscles.

To stabilize joints

Skeletal muscles tense to strengthen and stabilize very flexible joints, such as the shoulder, when these joints come under strain due to body actions.

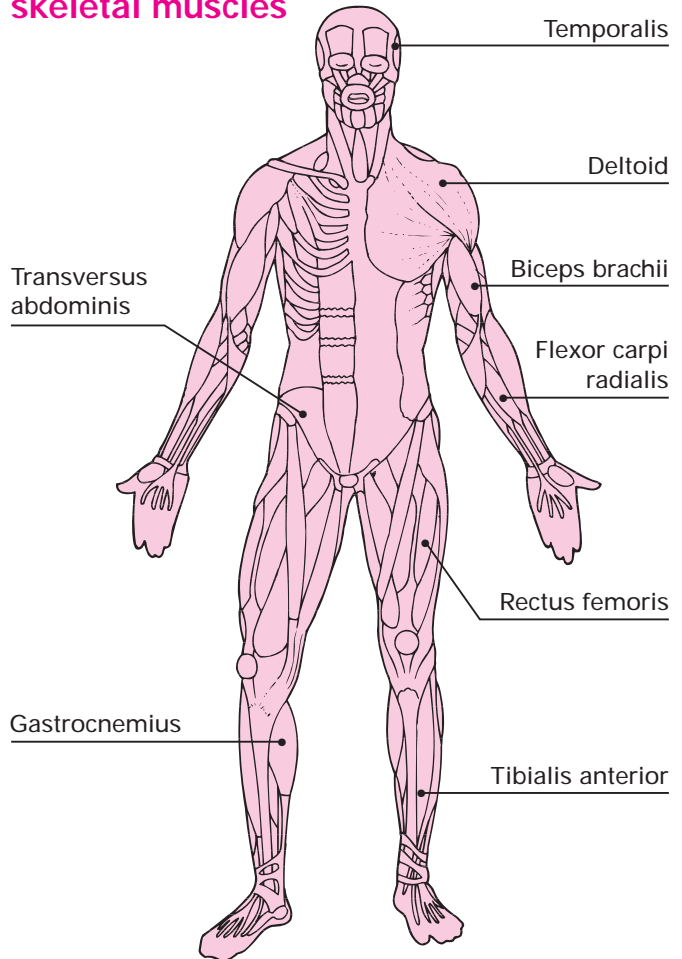
To help internal processes

Several inner organs contain muscle tissue which contracts to squash, squeeze, or move the substances they contain. These substances include food in the digestive tract, urine in the urinary tract, blood in the heart, and eggs or sperm in the reproductive system.

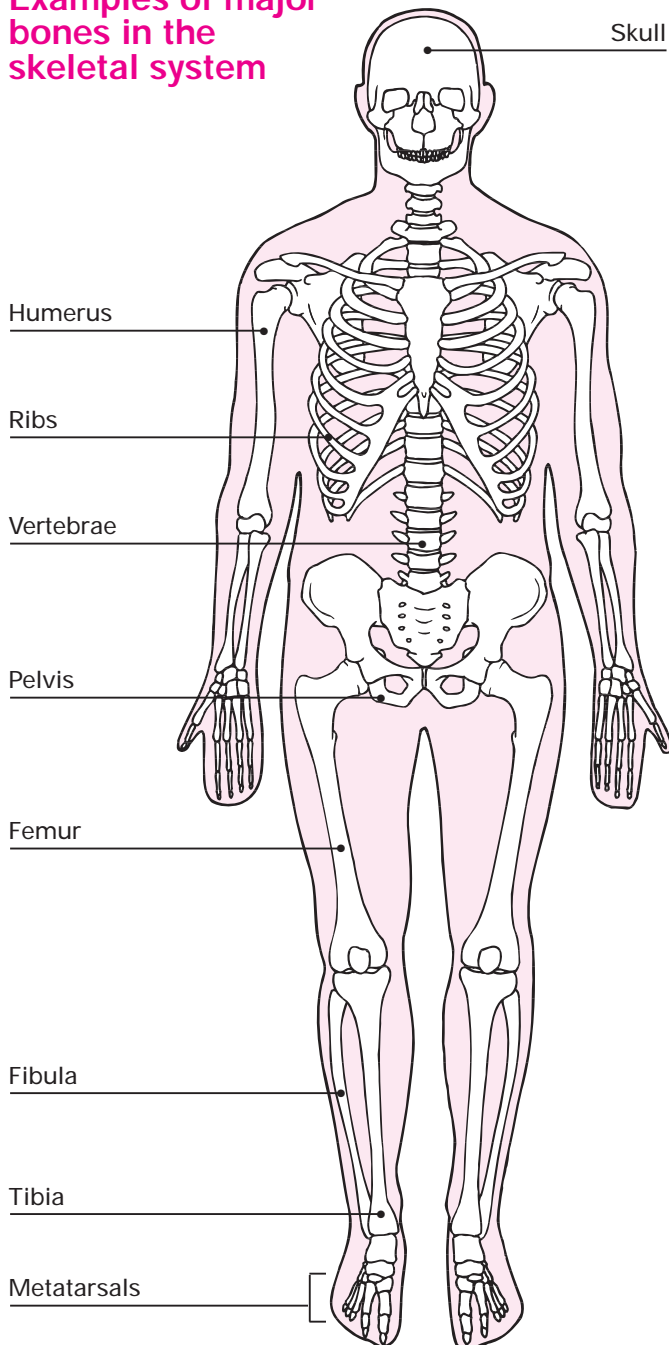
To generate heat

Nearly 85 percent of heat produced in the body is the result of muscle contraction.

Examples of major skeletal muscles



Examples of major bones in the skeletal system



Skeletal system functions

To support soft parts

Bones provide support for the soft organs of the body against gravity. Large bones of the lower limbs hold up the body when standing.

To take part in movement

Bones provide points of attachment for muscles that move the body. Bones and muscles work together as different types of mechanical levers to produce motion. Different types of joints determine the type and range of movement.

To protect delicate organs

The skeleton protects some internal organs. For example, the skull protects the brain; ribs shield the heart and lungs; the spine (vertebral column) protects the spinal cord.

To store minerals

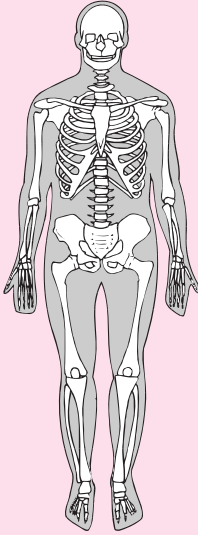
Bones serve as storage reservoirs for certain minerals. Among the most important are calcium and phosphate. In times of dietary shortage, as an emergency measure, these stored minerals are released from bones into the bloodstream, to be distributed to where they are needed. Other minerals contained in bones include magnesium and potassium. Deposit and withdrawal of minerals to, and from, bones is mainly under the control of hormones.

To make new blood cells

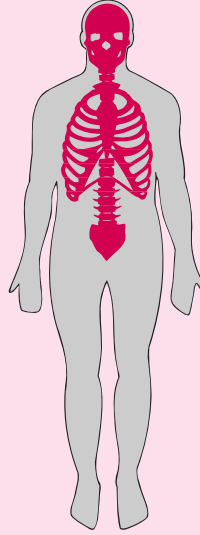
Most blood cell formation (hematopoiesis) takes place in the red marrow of bones, in the skull, ribs, sternum, clavicles, vertebrae, and pelvis. Fat is stored in the yellow bone marrow.

Structure

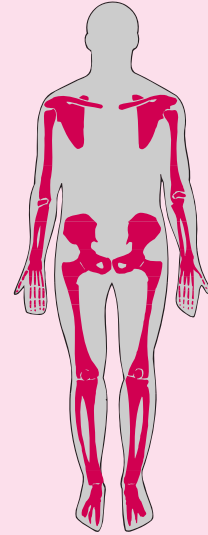
There are 206 bones in the skeleton. These are grouped as the axial and appendicular skeletons.



The axial skeleton has 80 bones and consists of the skull, vertebrae (including sacrum), ribs, and sternum.



The appendicular skeleton has 126 bones and consists of the limbs and their attachments.



Skull

The 22 bones of the skull comprise eight in the cranium (a rigid shell guarding the brain), and 14 facial bones, including the mandible (the single lower jaw bone).

Vertebrae

The backbone's 33 vertebrae form a weight-bearing column that has a slight S-curve viewed from the side. There are seven cervical (neck) vertebrae, 12 thoracic (chest), and five lumbar (lower back) vertebrae. Below these lie the sacrum (five fused load-bearing vertebrae) and coccyx (four fused "tail" vertebrae).

Rib cage

The rib cage or chest has 12 pairs of flat bones, the ribs, curving forward from the thoracic vertebrae. True ribs (upper seven pairs) join the sternum at the front of the chest. False

ribs (pairs 8–10) join the seventh pair. Floating ribs (pairs 11–12) end short.

Limb girdles

These anchor the limbs to the axial skeleton. In each shoulder girdle there is a scapula hung at the back of the chest, and a clavicle bracing it to the sternum. The hip girdles consist of two hip bones (each made up of three fused bones) flanking the sacrum and with it forming the pelvis.

Limbs

Each arm has a humerus (upper arm), radius and ulna (forearm), and 27 bones of the hand: carpals (wrist), metacarpals (hand), and phalanges (fingers). In the leg is a femur (thigh), tibia (shin) and fibula, and 26 foot bones: tarsals (ankle), metatarsals (sole), and phalanges (toes).

Feature	Description	Examples
Condyle	A concave or convex prominence forming part of a joint.	Medial and lateral condyles of the humerus at the elbow.
Diaphysis (or shaft)	The part of a long bone between the epiphyses.	Shaft of the femur in the thigh.
Epiphysis	Near the end of a long bone; the last part to become true bone.	Epiphyses of the humerus near the shoulder and elbow.
Facet	A smooth, flat surface forming part of a joint.	Articular facet of a vertebra in the backbone.
Fissure	A slit or furrow.	Superior orbital fissure of the sphenoid bone.
Foramen	A hole for the passage of blood vessels, nerves, or ligaments.	Foramen magnum at the base of the skull, for the spinal cord.
Fossa	A depression, hollow, or cavity.	Canine fossa in the jaw bone.
Head	Rounded projection at the end of a bone nearest the main body.	Head of the femur; head of the humerus.
Meatus	A canal or passageway running through a bone.	External auditory meatus (outer ear canal) in temporal bone.
Neck	Constricted part of a bone, supporting the head.	Neck of the humerus; neck of the femur.
Process	A prominent projection.	Mastoid process of temporal bone of skull, behind the ear.
Spinous process	A pointed, slim projection to which connective tissues attach.	Spinous process of a vertebra.
Trochanter	A large, blunt projection to which connective tissues attach.	Greater and lesser trochanters of the femur, at hip joint.
Trochlea	Joint surface grooved like a pulley.	Trochlea of the humerus.

Skeletal system: key words

Acetabulum A socket in the hip bone for the femur's round head.

Backbone See **Vertebral column**.

Bone marrow Soft red or yellow substance inside a bone.

Calcaneus The tarsal (ankle) bone that forms the heel.

Carpus The wrist's framework of eight small carpal bones.

Cartilage "Gristle," dense, white connective tissue.

Cranium The part of the skull that contains the brain.

Frontal bone The forehead bone.

Haversian canals (or Osteonic canals) Tiny canals in bone, containing nerves and blood vessels.

Hip bones (or Innominate bones) Flared bones forming the pelvis, each with three fused bones: ilium, ischium, pubis.

Intervertebral disk The fibrocartilaginous disk between two vertebrae.

Ligament Fibrous tissue that connects bones.

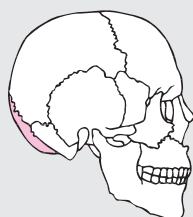
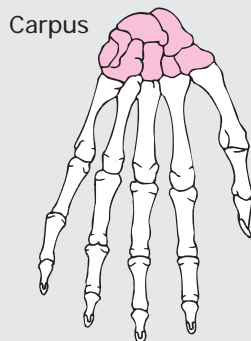
Maxilla One of the two bones of the upper jaw (plural: maxillae).

Metacarpus The five metacarpal bones in the palm, between the wrist and the fingers.


Metatarsus The five metatarsal bones in the foot, between the ankle and the toes.

Occipital bone A bone at the lower rear of the skull, with a hole in it for the spinal cord.

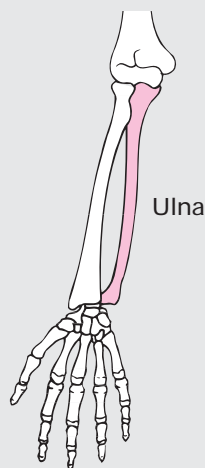
Ossicles Tiny bones, especially



Occipital bone



Pelvis (male, inferior view)



the auditory ossicles (malleus, incus, stapes) in the middle ear.

Osteocytes Mature bone cells.

Parietal bones Two fused bones forming the top of the skull.

Patella The kneecap.

Pelvis A bony basin formed by the two hip bones, the sacrum, and the coccyx.

Phalanges Finger and toe bones.

Sacrum Five fused vertebrae joined to the two hip bones.

Spine See **Vertebral column**.

Suture An immovable fibrous joint between the skull bones.

Symphysis A cartilaginous joint.

Synovial joint A movable joint encased by synovial membrane and lubricated by synovial fluid.

Tarsus The seven small tarsal bones which form the ankle.

Temporal bone One of a pair of bones forming the skull's lower side walls.

Tendons Bands of fibrous connective tissue joining muscles to bones.

Ulna The innermost and longer of the two forearm bones.

Vertebra A bone of the vertebral column (plural: vertebrae).

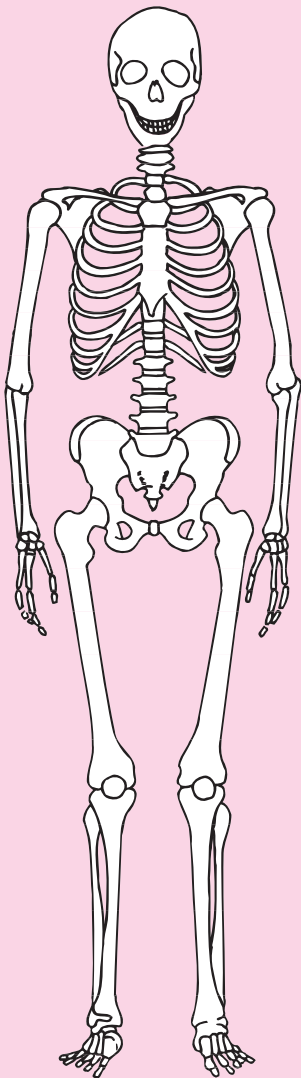
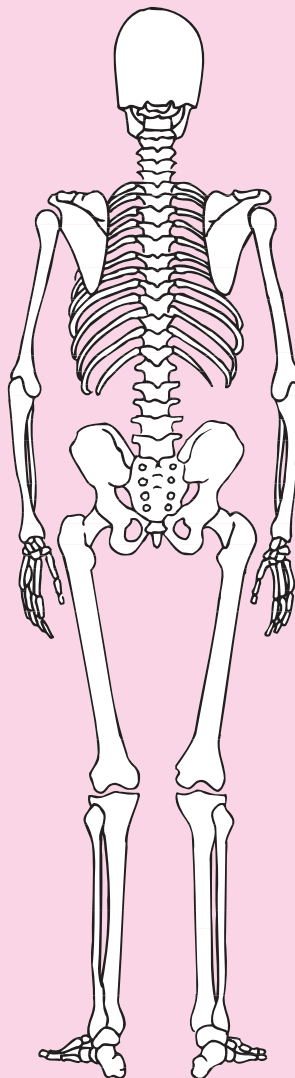
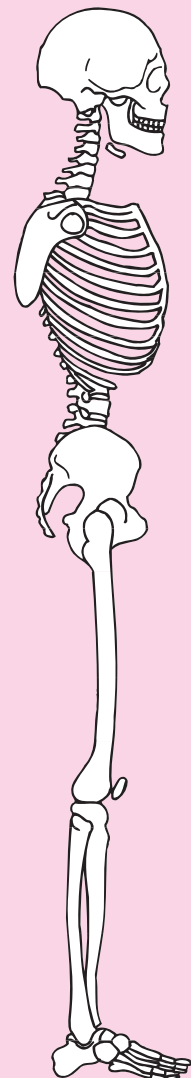
Vertebral column (or **Backbone** or **Spine**) The column of vertebrae between the skull and the hip bones, supporting the body and shielding the spinal cord. It has five sections: cervical, thoracic, lumbar, sacral, and coccygeal.

Zygomatic bone The cheekbone.

Whole-skeleton diagrams

The skeleton as a whole is bilaterally symmetrical, that is, left and right are mirror-images. Apart from a few midline bones such as the mandible (lower jaw), sternum (breastbone), and vertebrae, all

other bones are “paired,” having opposing partners. Lateral stability is enabled by the pelvis which acts as a “bridge” over the legs. Skull, chest, and abdomen are on top of one another and balance over the feet.

Anterior (front) view**Posterior (rear) view****Lateral (side) view**

Types of bone

Type

Long bones

These bones are longer than they are wide.



Humerus

Structure

- A diaphysis (shaft).
- Two epiphyses (extremities).
- Mostly compact bone with spongy bone at the ends.

Function

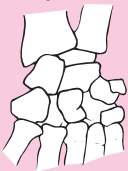- Act as levers and shock absorbers.

Examples

- The bones of the thighs, legs, toes, upper arms, forearms, and fingers.

Short bones

Generally boxy or cube-shaped.



Wrist

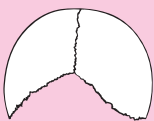
- Spongy bone covered by a thin all-over layer of compact bone, which is thicker in some parts to resist greater stresses.

- Form bone groups or close units like the wrist; some sesamoids (a special type of bone found within tendon) change the direction of pull of a tendon.

- Bones in the wrists and ankles; the patella (kneecap) is an example of a sesamoid bone.

Flat bones

Flat or curved sheets of bone.



Skull

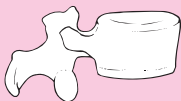- A middle layer of spongy bone.
- A layer of compact bone on each side of the spongy bone layer.

- Provide large anchorage areas for muscles.
- Protect organs such as the brain (skull) and lower abdominal parts (pelvis).

- Skull, ribs, sternum, hips, and scapula (shoulder blade).

Irregular bones

Do not fit into the above categories.



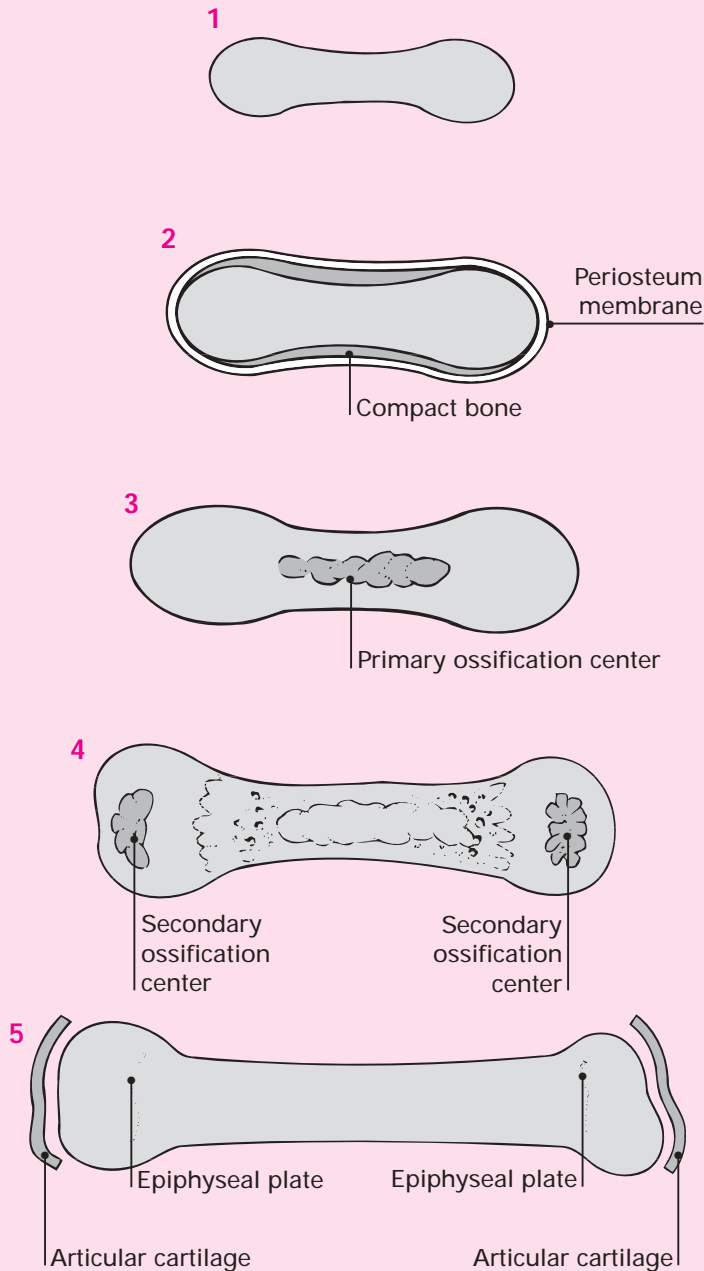
Vertebra

- Mainly spongy.
- Thin layers of compact bone.
- Proportion of spongy to compact bone varies.

- Function varies, generally complex shapes.
- Often several faces or facets for joints and also flanges or ridges for muscle attachment.

- The vertebrae of the spine, the facial bones, and some ankle and wrist bones.

Development of bones



1 Before birth, the embryonic skeleton consists not of bones, but of cartilage structures called “models,” in similar shapes to those of the eventual mature bones.

2 The outer bone membrane or periosteum forms around the model. Hard or compact bone begins to solidify as an outer layer around the cartilaginous central region.

3 In the center of the bone, at a region called the primary ossification center, the cartilage begins to change into spongy bone. All the time the “model” structure enlarges within the growing body.

4 As the cartilage changes from the center outward into spongy bone, the middle itself starts to break down to form what will become the marrow cavity. Secondary ossification centers form at the ends.

5 After birth, the bone continues to lengthen at growth areas between the shaft and each end, called epiphyseal plates. A layer of articular cartilage forms over each end to cover the bone inside the joint.

General bone structure

A long bone consists of both compact and spongy bone tissue.

Diaphysis (shaft) A mainly tubular shape made of compact bone. This is hard, with a rigid structure (for weight bearing), yet lightweight (to permit movement).

Medullary cavity A cavity inside the diaphysis, filled with yellow bone marrow. Sometimes called the marrow cavity. This is where the bone stores fat.

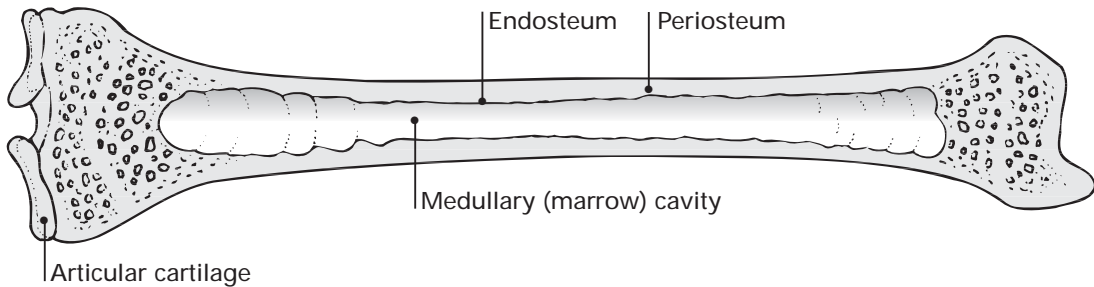
Epiphyses The ends (head/foot) of the bone, made of spongy bone tissue.

Articular cartilage Each epiphysis is covered with a layer of smooth, shiny cartilage that acts like a cushion to protect the joint from wear and tear.

Periosteum This is a strong fibrous membrane that covers the entire bone with the exception of the joint surfaces. The periosteum provides an anchoring point for tendons and ligaments.

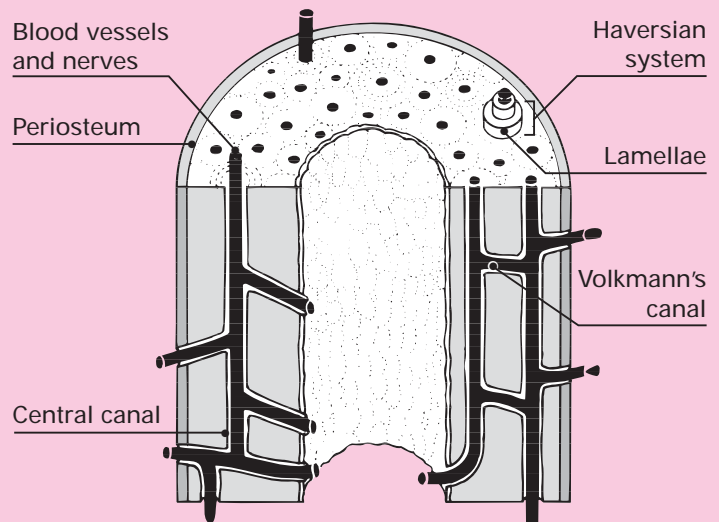
Endosteum A fibrous membrane that lines the medullary cavity.

Bone cells Bone contains bone-forming cells called osteoblasts and bone-destroying cells called osteoclasts.



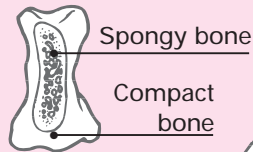
Bone microstructure

Compact bone is made up of cylindrical units called Haversian systems (osteons). These run lengthways along the bone and comprise a central canal (the Haversian canal) housing blood vessels and nerves, surrounded by lamellae (concentric tubular plates). Lamellae can withstand stress and act like tiny weight-bearing pillars. They are joined to each other by similar canals called Volkmann's canals.

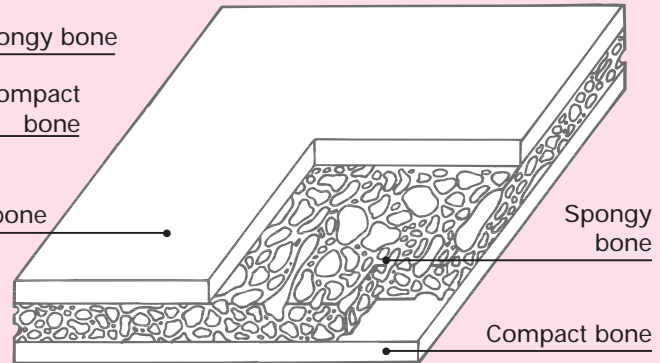


Bone and cartilage

Compact (hard) bone is dense and strong. Spongy (cancellous) bone has honeycomb-like spaces. Hyaline cartilage includes articular (joint) cartilage. Elastic cartilage is springy and found in locations such as the ear flap. Fibrocartilage is denser and stronger, and reinforces some joints.

Section through a short bone

Compact bone

Section through a flat bone


Spongy bone

Compact bone

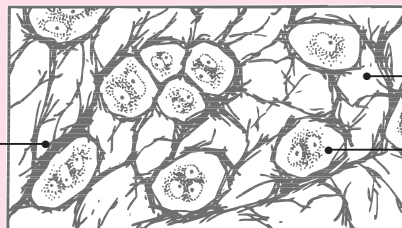
Microscopic section through hyaline cartilage

Chondrones

Chondrocytes

Intercellular matrix
(ground substance)**Microscopic section through elastic cartilage**

Elastic fibers

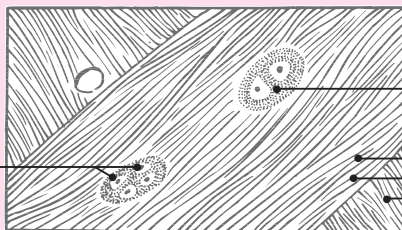


Intercellular matrix

Chondrones

Microscopic section through fibro-cartilage

Chondrones



Cell halo

Collagen fibers

Muscles comprise bundles of elastic fibers that contract to produce movement when stimulated by nerve impulses. There are three main types of muscle tissue, differentiated in both structure and functions: skeletal, smooth, and cardiac.

Skeletal muscle Also known as striated (striped) or voluntary muscle, skeletal muscle operates the bony skeleton. Skeletal muscles are mostly under conscious or voluntary control (they can be contracted at will). Skeletal muscle cells are long, slim, and cylindrical with multiple nuclei situated near cell membranes. The cells are collected into bundles and covered by fasciae of connective tissue to form individual muscles. Skeletal muscles are attached to bones, cartilages, ligaments, skin, or other muscles.

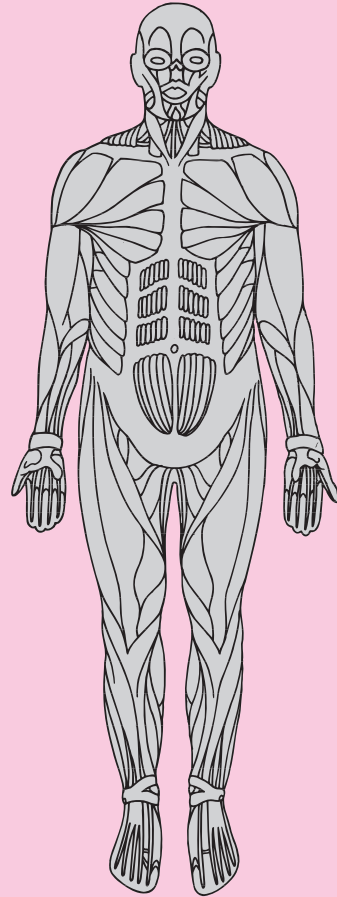
Connections are direct, or via cordlike tendons (sinews), or aponeuroses (fibrous sheets). Skeletal muscles function either as prime movers, as antagonists opposing prime movers, as fixation muscles (steading one part as a base for others), or as synergists working with prime movers to prevent unwanted movements.

Smooth muscle Other names for this type of muscle are unstriated (unstriped), involuntary, or visceral muscle. Smooth muscle cells are spindle-shaped (long with tapering ends; thicker in the middle than at the ends) and under the microscope have no cross-stripes. The cells are arranged close together into sheets. This type of muscle tissue is found in the walls of blood vessels and internal organs such as the stomach and intestines. It works automatically, without the need for conscious control.

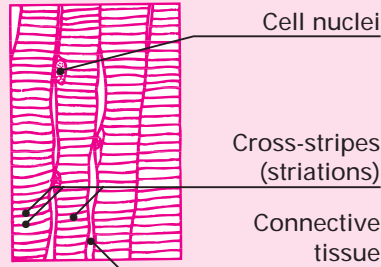
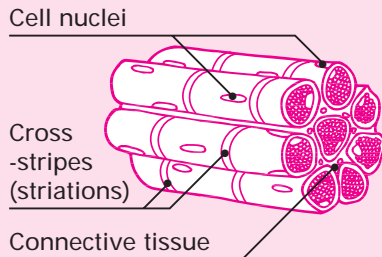
Cardiac muscle This type of muscle is found only in the heart, forming the myocardium, the heart wall's muscular middle layer. Its cells, which are part-striated, are cylindrical

Superficial muscles

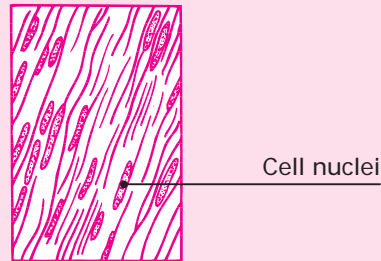
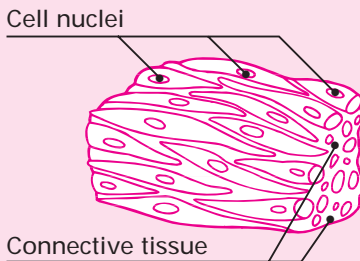
These are muscles just under the skin. Beneath are intermediate and deep muscle layers.



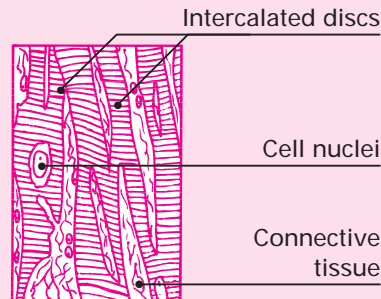
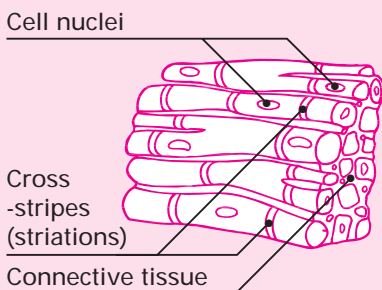
with branches, often Y-shaped, and containing a central nucleus. Cardiac muscle cells are separated by junctions called intercalated disks, and form a dense network encased in connective tissue. Cardiac muscle works without conscious control to produce contractions (heartbeats) that propel blood around the body.

Skeletal (striated) muscle**Longitudinal section****Typical location**

limbs, head,
neck, trunk

Smooth (visceral) muscle**Longitudinal section****Typical location**

Intestinal tract,
other viscera

Cardiac muscle**Longitudinal section****Typical location**

Myocardium in
walls of heart

Muscle groups Skeletal muscles are grouped by location into: head muscles (operating the scalp, eyelids, nose, mouth, and jaws); anterolateral neck muscles (including cervical, hyoid, and anterior and lateral vertebral muscles); trunk muscles (including the thorax, abdomen, back, pelvis, and perineum); and upper and lower limb muscles.

Muscle actions Many different terms describe the actions of muscles. These are often incorporated into the name of the muscle. For example, the pronator teres in the forearm pronates the hand, turning the palm downward or backward. The adductor magnus adducts the thigh, pulling it toward the midline of the body.

Skeletal muscle tissue features

Excitability

The ability to receive and respond to a stimulus. Muscles receive stimuli in the form of nerve signals from the nervous system. They respond by contraction.

Contractility

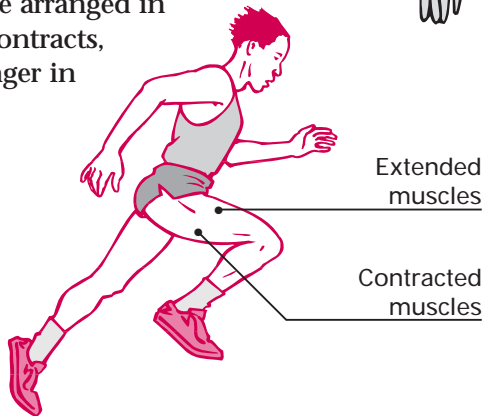
The ability to shorten. When stimulated, muscles shorten to produce movement. A whole muscle may contract by 15–20 percent of its normal or resting length.

Elasticity

The ability of a muscle to return to its normal or resting size after contraction or extension.

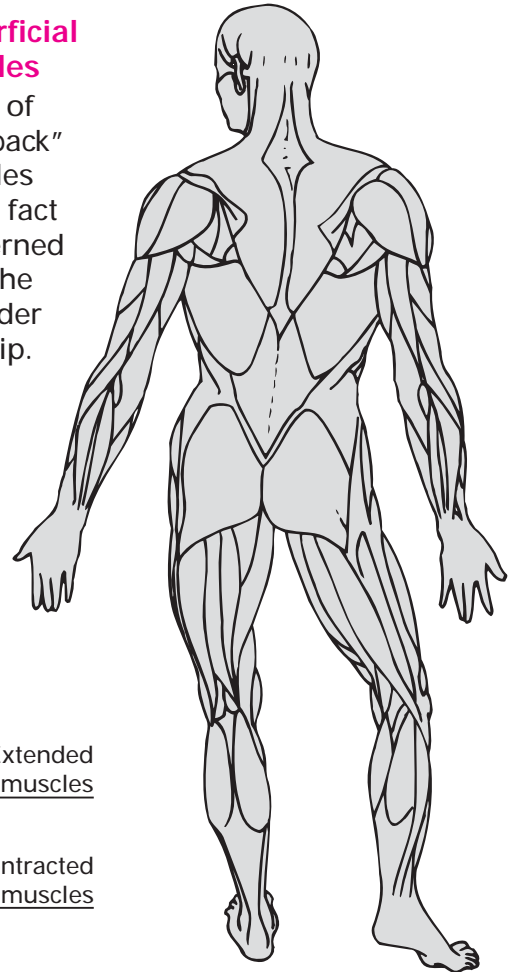
Extensibility

The capacity to be stretched or extended. Many skeletal muscles are arranged in pairs so that when one contracts, the other is stretched longer in relation to its relaxed or resting state. Some muscles can be extended to more than twice their normal resting length.



Superficial muscles

Many of the “back” muscles are in fact concerned with the shoulder and hip.



Smooth muscle tissue features

Shape

Most smooth (visceral) muscle is arranged in layers, sheets, tubes, or bags, which are not connected to the skeletal system.

Contractility

Some smooth muscle tends to shorten with a rhythmic traveling pattern, sending a wave of contraction along or through its structure. Other smooth

muscle retains its contracted state (tonus) for longer periods, from minutes to hours, without the fatigue associated with skeletal muscle tissue.

Examples

Changing blood vessel widths; changes of eye pupil diameter and lens shape; erection of tiny hairs in the skin; propulsion of urine from kidneys to bladder; uterine contractions at birth.

Muscle system: key words

Abductor A muscle that moves a bone (or limb) away from the body's midline.

Adductor A muscle that moves a bone (or limb) toward the body's midline.

Biceps A muscle with two heads: biceps brachii in the upper arm and biceps femoris in the thigh.

Brevis The shortest of similarly named muscles, such as peroneus brevis.

Cardiac muscle Involuntary striated muscle, found only in the heart.

Depressor A muscle that results in downward movement.

Diaphragm The muscular sheet that separates the thorax (chest) and abdomen. It contracts and flattens during inspiration (breathing in), and then relaxes and becomes dome-shaped during expiration (breathing out).

Extensor A muscle that increases (makes less sharp) the angle of a joint, as when extending (straightening) the elbow.

Fascia Connective tissue formed into layers. One type, deep fascia, forms sheaths around individual muscles.

Fascicle (or Fasciculus) A bundle of muscle or nerve fibers.

Flexor A muscle that decreases (makes sharper) the angle of a joint, as when flexing (bending) the elbow.

Gluteus One of the three paired muscles in the buttocks. Gluteus maximus is the body's largest muscle.

Insertion The point of attachment of a muscle that is relatively movable when the muscle contracts.

Levator A muscle that lifts or results in upward movement.

Maximus The largest among similar muscles, such as gluteus maximus.

Minimus The smallest of similar muscles.

Myocardium Cardiac muscle forming the middle layer of the heart wall.

Orbicularis A muscle with fibers that run in a circular direction, for example orbicularis oculi (around the eye) or orbicularis oris (around the mouth).

Origin The point of attachment of a muscle that remains relatively fixed when the muscle contracts.

Peristalsis Waves of muscular contraction that propel substances through passageways, such as the alimentary canal.

Rectus A muscle with straight fibers, such as rectus femoris in the thigh.

Rhomboideus A rhomboid-shaped muscle, such as rhomboideus major and rhomboideus minor in the upper back.

Rotator A muscle that moves a bone around its longitudinal axis.

Sphincter A ring-shaped muscle that contracts to close an orifice.

Tendons Bands of fibrous connective tissue joining muscles to bones.

Tensor A muscle that increases tension or rigidity (stiffness).

Teres A round muscle, such as teres major and teres minor in the shoulder.

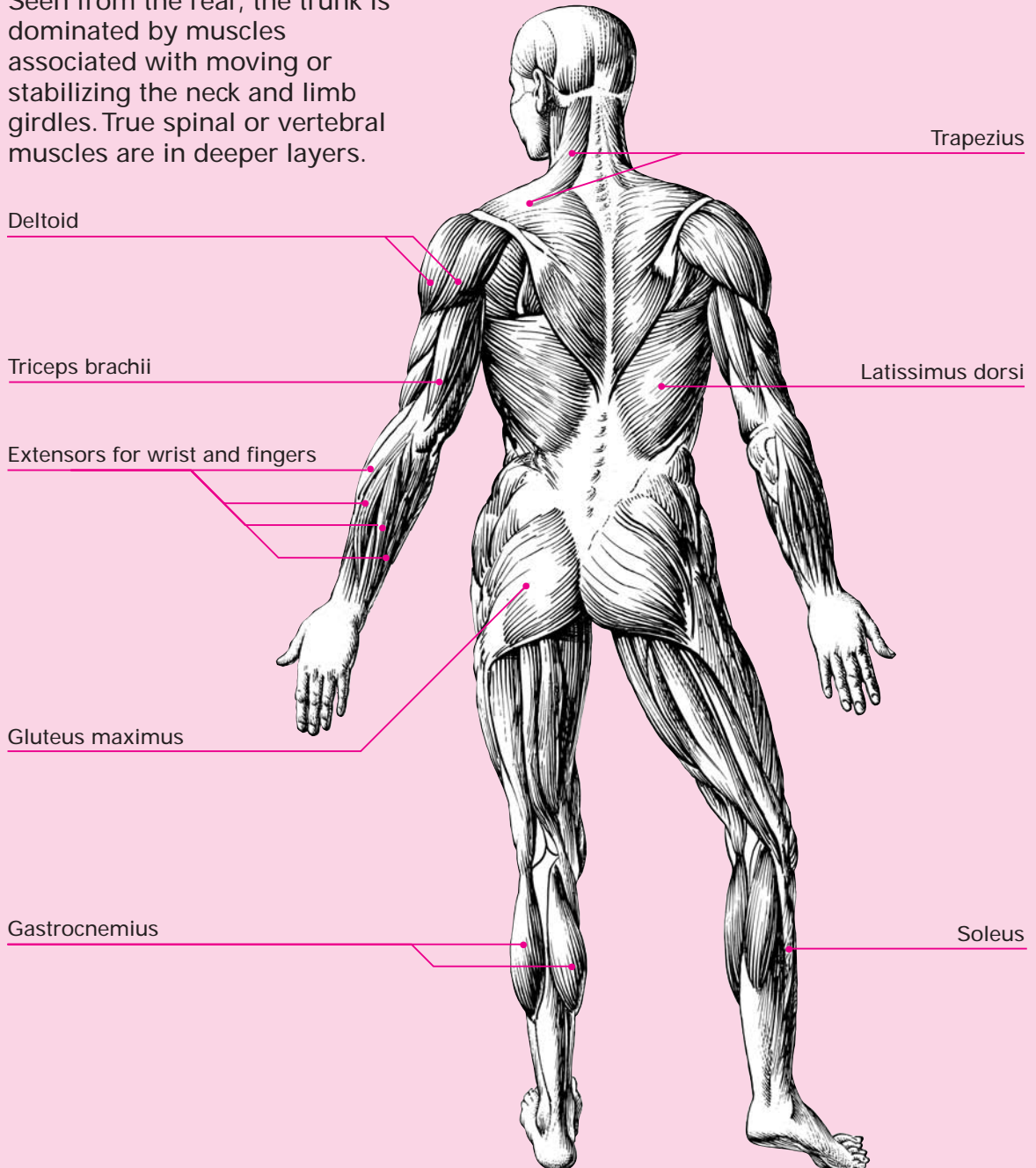
Transversus A muscle with fibers at right angles to the midline, for example transversus abdominis.

Triceps A muscle with three heads, especially triceps brachii in the upper arm.

Vastus A term denoting a relatively large or huge muscle compared to those around it, such as vastus lateralis in the thigh.

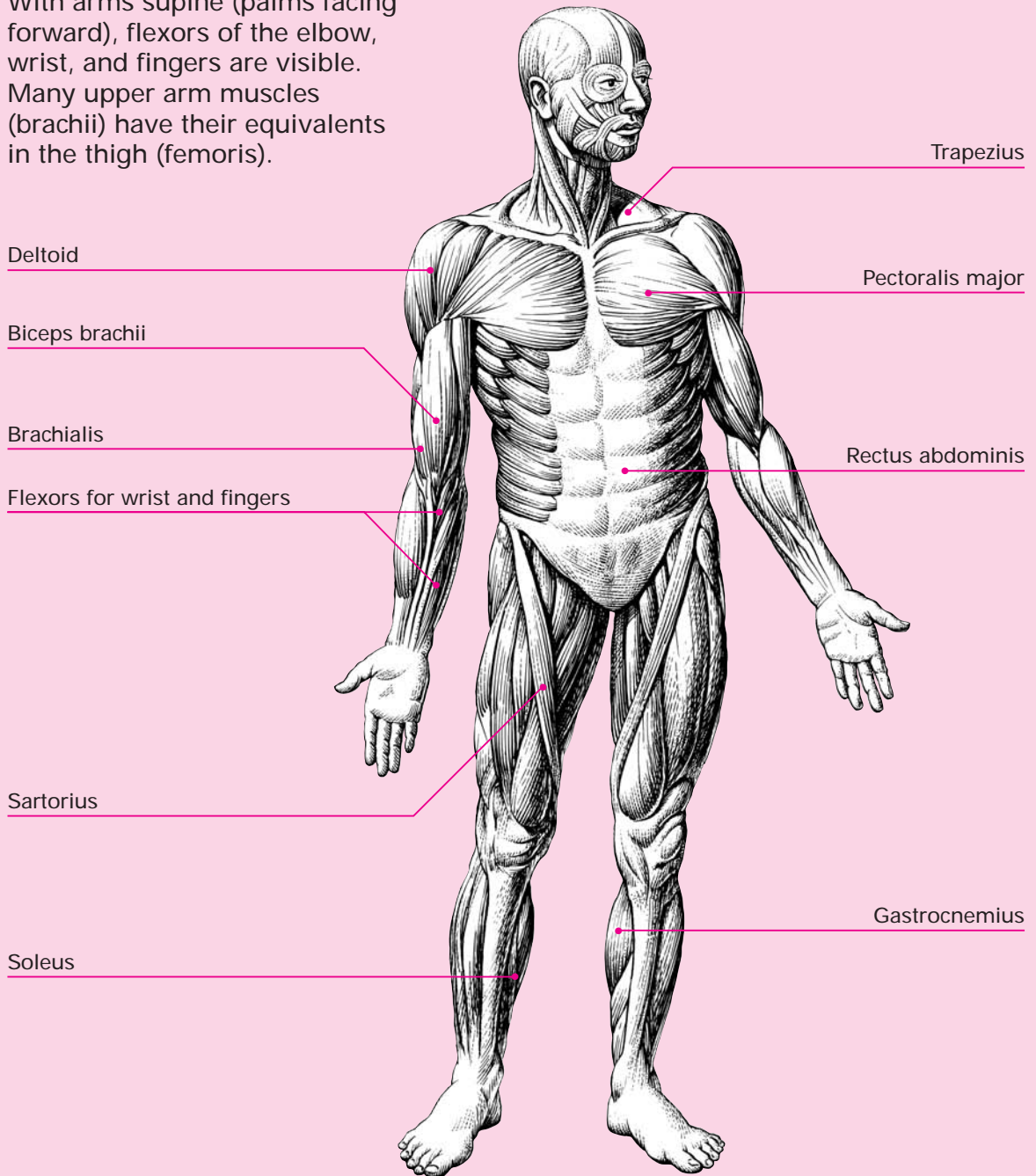
Posterior view of the superficial muscles

Seen from the rear, the trunk is dominated by muscles associated with moving or stabilizing the neck and limb girdles. True spinal or vertebral muscles are in deeper layers.



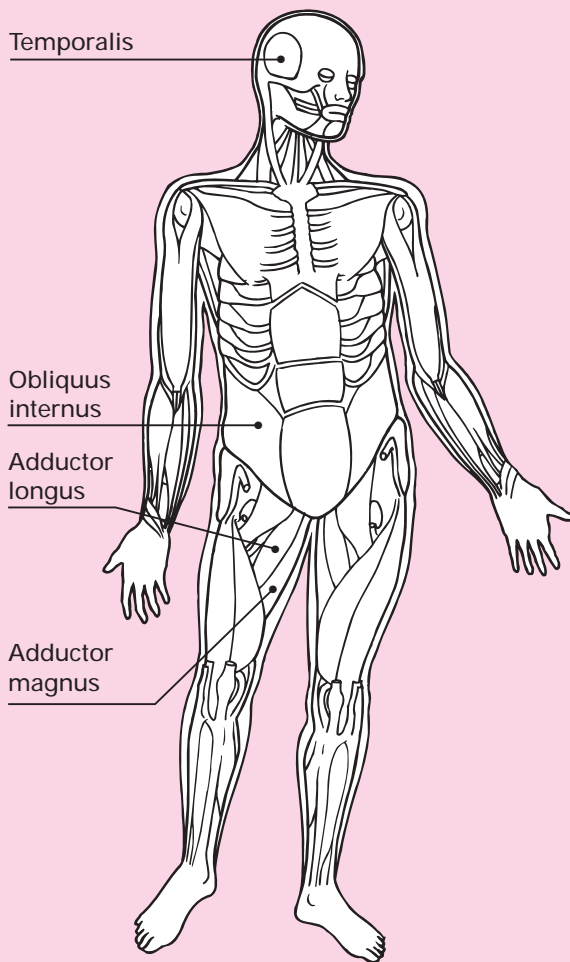
Anterior view of the superficial muscles

With arms supine (palms facing forward), flexors of the elbow, wrist, and fingers are visible. Many upper arm muscles (brachii) have their equivalents in the thigh (femoris).



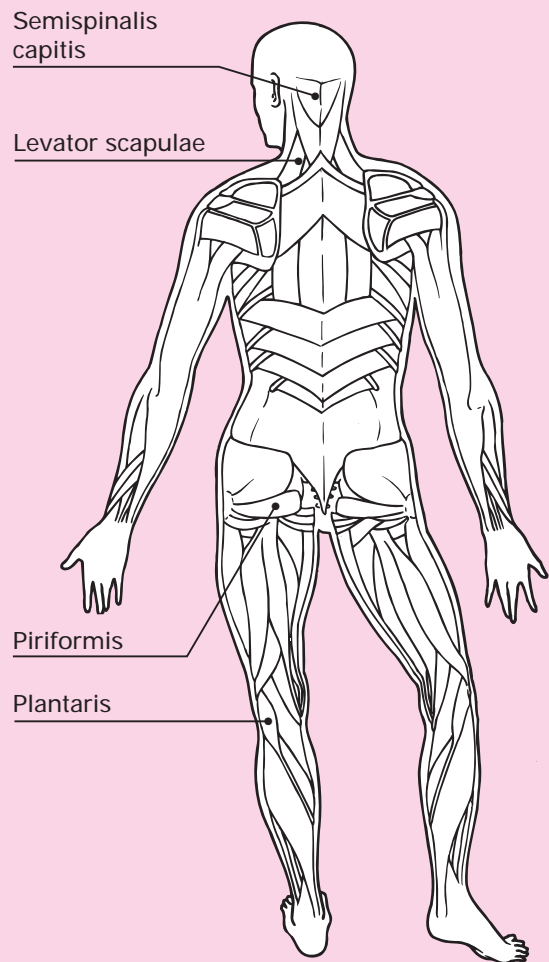
Anterior view of deep muscles

Most deep muscles lie directly against bones. The adjacent surfaces are protected against rubbing by various structures such as bursae (fluid-filled sacs) or fibrous tendons.



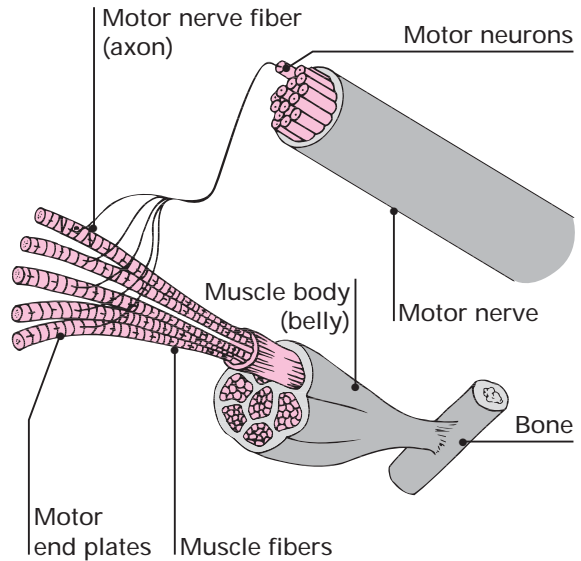
Posterior view of deep muscles

Deep muscles tense to prevent them being squashed as superficial muscles overlying them contract and bulge, which could cause pressure disruption to their blood or nerve supplies.



Motor units

Muscle fibers have to contract quickly when stimulated in order to bring about a given action. To do this they are fed by nerves from the central nervous system—the brain and spinal cord. A single neuron (nerve cell with its fiber) and all the muscle fibers that it stimulates are known as the motor unit. Different muscles have different numbers of motor units. Muscles that require very precise action, like those moving the eyeball, have small motor units with as few as four muscle fibers each. Muscles with less precise movements, such as the big muscles of the hip and thigh, have large motor units, each with many hundreds of muscle fibers.



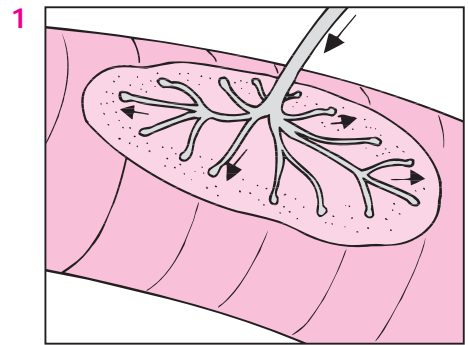
Structure

Each motor unit is served by one motor nerve fiber or axon from a motor nerve. The axon terminals of the motor neuron attach to the muscle fibers at points called motor end plates or neuromuscular junctions (see below).

How a motor unit works

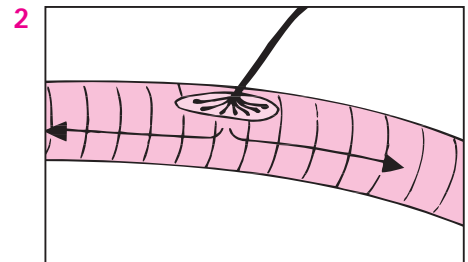
1 A nerve impulse is sent along the motor neuron's fiber or axon. When the impulse arrives at the motor end plate, a chemical called acetylcholine is released from the axon terminals.

2 The chemical crosses the micro-gaps between the axon terminals and their muscle fibers and stimulates the fibers in the form of an electric charge. The charge passes along the muscle fibers, which contract. The muscle fibers of the motor unit then relax unless there is another nerve impulse.



The all-or-none principle

A single muscle fiber does not act with graded responses as the strength or frequency of the incoming nerve signals increases. It either responds maximally or not at all. This means that the force of contraction of the whole muscle depends on the number of fibers excited. In turn this depends partly on the number of fibers per motor unit.



Tetanic and twitch contractions

Tetanic contractions

For muscles to work efficiently they need to produce coordinated, fluid movements. A tetanic contraction is produced when several stimuli bombard a muscle in rapid succession. Repeated contractions of sets of muscle fibers

are coordinated into a sustained overall contraction or tetanus. This is the way muscles normally contract.

Twitch contractions

A twitch is a quick, uncoordinated response to a stimulus. Twitch contractions in muscle can be produced under laboratory conditions.

Isotonic contractions

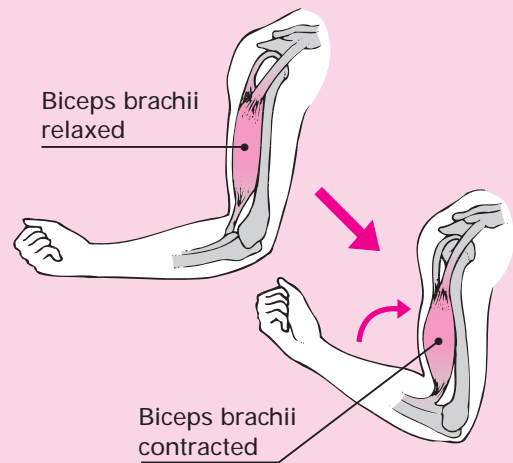
Tension in the muscle remains constant while the muscle is contracting. For example, picking up a heavy book results in an isotonic contraction of the biceps in the arm. Isotonic contractions can be concentric or eccentric.

Concentric contractions

The muscle shortens while contracting. For example, the biceps in the arm shortens as the arm is raised and the tension in the muscle remains constant.

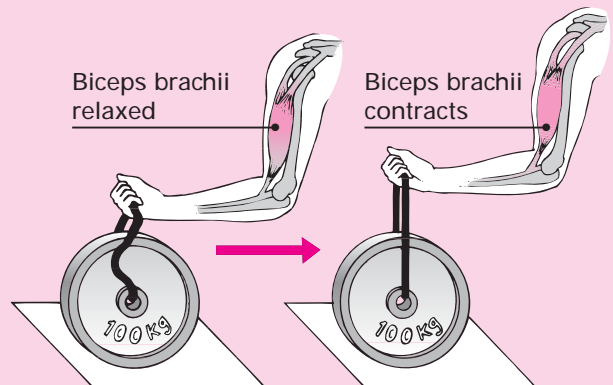
Eccentric contractions

The muscle lengthens even though exerting tension, being pulled by an opposing muscle or a weight such as a lifted load.



Isometric contractions

Tension increases but the muscle remains the same length—it neither lengthens nor shortens. For example, an isometric contraction occurs when a weight is too heavy to be lifted: tension in the biceps increases as the muscle tries to raise the weight, but the length of the biceps remains constant. Isometric contractions occur almost constantly in many body parts to maintain posture and balance.



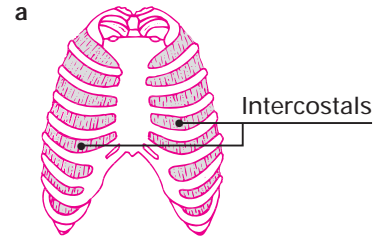
Isometric contraction as muscle pull (tension) increases but length remains constant

Naming skeletal muscles

Muscles can be named according to their location, shape, size, origins, insertions, action, and according to the direction in which their muscle fibers run.

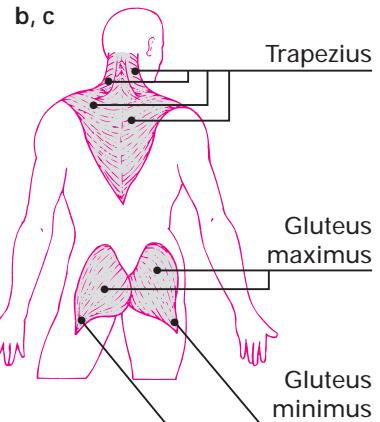
a Location

Some muscles have been named according to their position on the body. For example, the intercostals are muscles that run between the ribs (costals); the tibialis anterior is located on the front (anterior) of the tibia bone.



b Shape

Some muscles are named with reference to their shape: deltoid (triangular), latissimus (wide), teres (round), rhomboid (diamond shaped). For example, the trapezius in the back is trapezoid in shape.



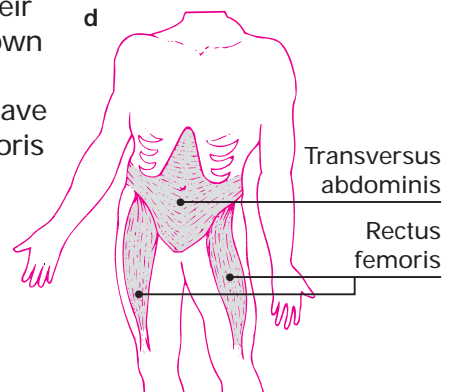
c Size

The terms maximus (largest) and minimus (smallest) are used to differentiate between similarly named muscles. For example, the gluteus maximus is a similarly shaped muscle to the gluteus minimus, which is located in the same area of the body. The terms longus (long), brevis (short), and vastus (huge) are similarly used.

d Direction of muscle fibers

Muscles are sometimes named for the way in which their fibers run compared with an imaginary line running down the midline of the body.

- Muscles with the word rectus (straight) in the name have fibers running parallel to the midline—the rectus femoris in the front of the thigh, for example.
- Those with the word transversus have muscles with fibers running at right angles to the midline—the transversus abdominis, for example.
- The term oblique indicates that the muscle fibers run obliquely (diagonally) to the midline.
- Orbicularis muscles have fibers that run in a circular direction, such as the eyelid muscles, orbicularis oculi.

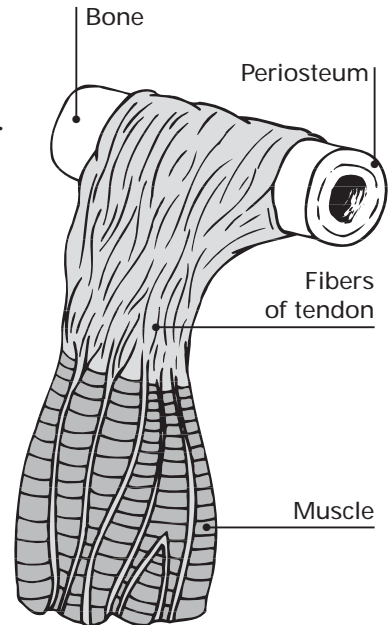
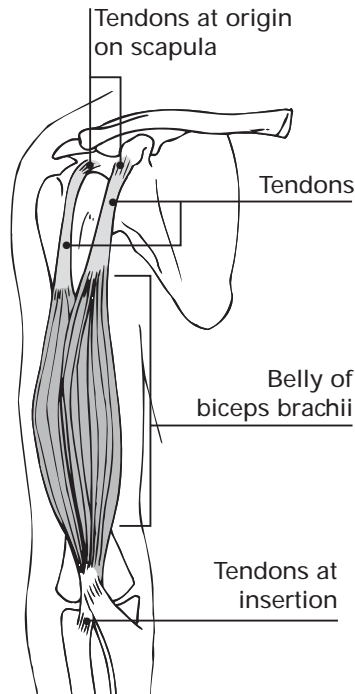


Attachment of muscle

Most muscles span one or more joints and are attached to the bones that form the joints. When they contract they pull the bones of a joint toward each other. Usually, one bone remains stationary relative to the rest of the body, while the other moves.

Tendons

The belly is the widest, bulging central part of a typical long muscle. A tendon is a fibrous cord situated at the tapering end of a muscle. It attaches the muscle to the bone and is anchored into the bone's periosteum (outer covering). Some muscles have several tapering ends, each with a tendon. The largest single tendon links the gastrocnemius muscle in the calf to the heel. It is known as the Achilles tendon or "Achilles heel."



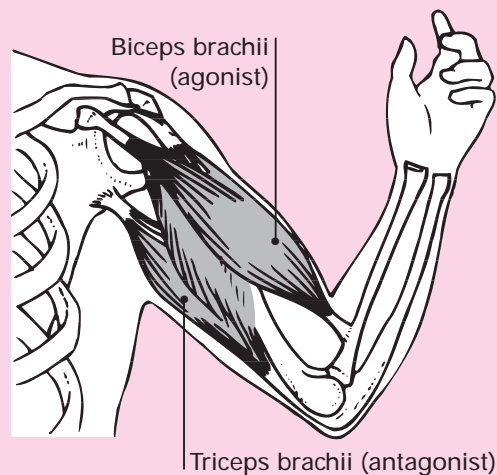
Tendon structure

Tendons consist of collagen fibers and have a minimal blood supply. So they take a long time to heal when strained or torn.

Group actions

Movement usually involves the coordination of several muscles.

- Agonists or prime movers are muscles that initiate movement.
- Antagonists are opposing muscles. They relax when the agonists contract, and contract to reverse the agonist's action.
- Synergists are muscles that help or assist movement.
- Fixators are stabilizing muscles that prevent unwanted movement.

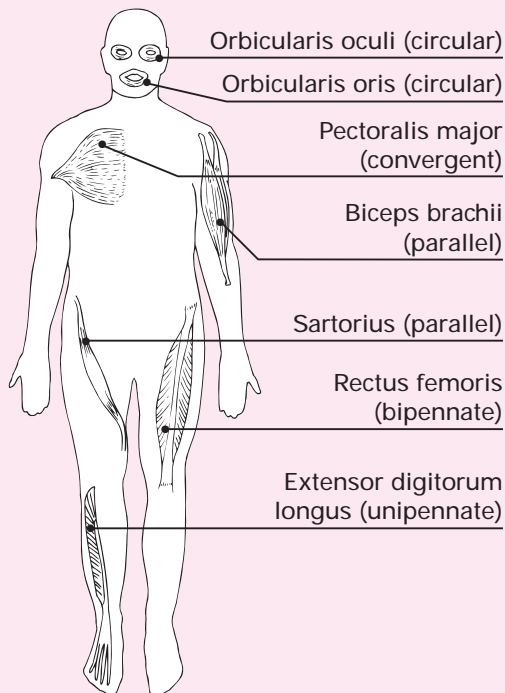


Arrangement of fibers

Muscles are made up of groups of fibers called fascicles arranged in a variety of different patterns. This results in muscles with different shapes and functional abilities. The most common arrangements of fascicles are parallel, pennate, convergent, and circular.

Parallel

- Fascicles run parallel to the muscle's main length or axis.
- They are straplike or fusiform (spindle shaped), have an expanded belly, and end in flat tendons.
- They have a large range of movement but are weaker than pennate muscles.
- The biceps and sartorius have parallel arrangements.



Pennate

- Fascicles are short in relation to the muscle length and attach obliquely to a central tendon that runs the length of the muscle, rather like a feather.
- Pennate muscles have a large number of fascicles giving them power but a limited range of movement.
- Unipennate muscles such as the extensor digitorum longus insert into only one side of the tendon.
- Bipennate muscles such as the rectus femoris join both sides of the tendon.

Convergent

- Convergent muscles tend to be triangular in shape, such as the pectoralis major.
- They contain a large number of fascicles with a narrow insertion.

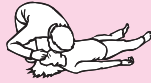Circular

- Fascicles are arranged in a circular pattern to form an orifice, such as the orbicularis oculi in the eyelids and orbicularis oris around the mouth.

Actions of fibers

- When a muscle fiber contracts, it shortens.
- The strength of a muscle is determined by the number of fibers.
- The range of movement is determined by the length of muscle fibers.
- The longer the fibers, the greater the range of movement.
- Muscles can contain a large number of short fibers or a small number of long fibers.

Muscles are one of the major body systems that gain obvious benefit from exercise and other aspects of health care. Not only skeletal muscles, but the cardiac muscle of the heart, and the breathing muscles of the chest and diaphragm, benefit from regular activity several times weekly. Perhaps less obvious is the effect of a healthy lifestyle on the skeleton—until something snaps. Regular exercise helps to keep bones strong and responsive to the stresses placed on them. A balanced diet is also vital to maintain muscle and bone condition.



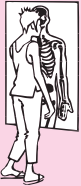Accidents: 1

Accidental injuries to muscles and bones range from a slight muscle tear to a bone shattered by multiple fractures. Most accidents could have been prevented with a little care, forethought, or organization. Some of the major safety hazards affecting the muscle and skeletal systems are falls, misused or dangerous tools, and impacts at speed, in sports, or on the road.



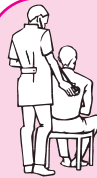Accidents: 2

Around the home, muscles and bones are at risk from various everyday activities. Slipping in the shower or bathtub can result in wrenched joints, torn muscles, or even bone fractures. Lifting heavy or awkward loads is particularly hazardous to the multiple joints between the vertebrae in the spinal column, resulting in back injuries that may need many weeks of recuperation.



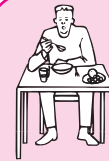Body and environment

Knowledge of your body and its functions, its likes and dislikes, its habits and characteristics, can be a great ally in health matters. If you are familiar with the normal functioning of your muscles, you will be quickly aware of anything that is changed or disturbed. Changes may include muscle tremors, twinges, or tender spots, and aches or stiffness in joints.



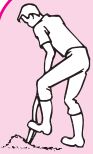Sources of help

Numerous varied organizations can be incorporated into your personal health plan. Do not be ashamed to take full advantage of the services available from outside resources. These include expert advice on activities which may put muscles and bones at risk, such as lifting, stretching, and general exercise programs, including correct techniques and precautions in sports and games.



Nutrition

Eating a well-balanced diet benefits your whole body in many ways, including muscles and bones. For example the calcium that is so important in the diets of babies and young children enables their bones and teeth to form properly. Continuing intake of calcium helps to maintain a healthy skeleton, while several other minerals are needed for muscle function.



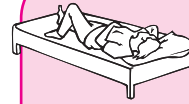Energy and calories

Energy is supplied to the body by the calories in the food we eat. Most of these calories are used by muscles, in a wide range of activities including all bodily movements, also the beating heart and the muscle-powered actions of breathing. Increased muscle activity “burns” calories and so helps to avoid unwanted accumulation of body fat and weight problems.



Obesity

Reducing, or dieting, is the removal of excess body weight in the form of fat. Excess stores of fat, in an overweight or obese body, provide no benefit. In fact they increase its risk of developing numerous diseases and medical conditions, including muscle strains and tears, joint aches and sprains, and excessive load on bones leading to cracks or breaks.



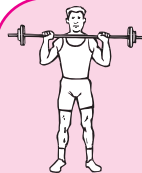Sleep

Satisfactory sleep is necessary for many reasons, including repair of minor wear and tear. During sleep, restoration of trivial injuries occurs in muscles, tendons, cartilages, ligaments, and other musculo-skeletal structures. Over-use or excessive strain of these parts can lead to increasing levels of wear which are more difficult for the body to mend.



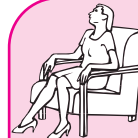Body image

Some people become obsessed with a particular body image. Examples include extreme thinness so that the bones and joints are visible just below the skin, and extreme muscular development with bulging muscles in every part. The healthy body usually lies somewhere between these extremes. Additional problems include substance abuse to build unnatural muscle bulk.



Exercise

Exercise is a fundamental bodily need. It should bring into action many muscle groups, for example, pumping the blood faster around the body, and increasing the depth and rate of breathing. It helps to keep the skeletal muscles toned so that the body feels and also looks in good shape. There are many ways of organizing your own exercise program to suit your needs.



Relaxation

Relaxation can be physical or mental, and the best kind of relaxing activity joins the two elements. Relaxation provides a peaceful oasis in a busy and hectic life, and provides a time when body and mind can renew themselves. It allows muscles to recover from fatigue and it rests joints against overuse and injury. Body and mind function more efficiently after mental and physical refreshment.

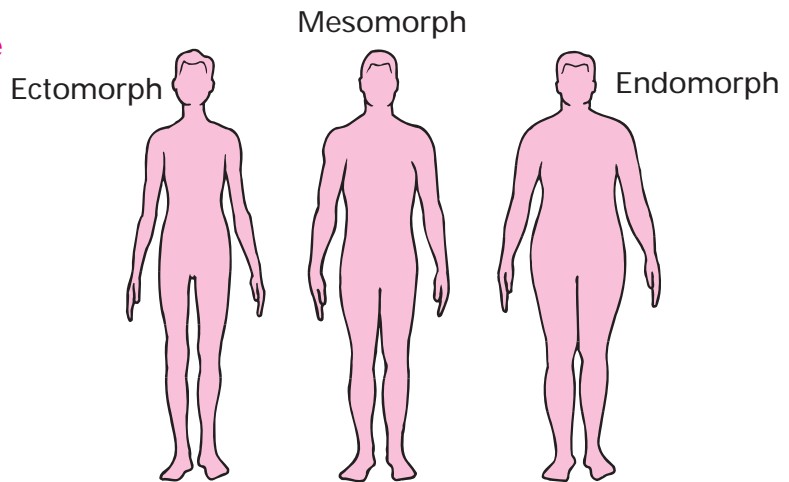
Exercise is a vital ingredient for keeping the human body in good health. The skeletal muscles, lungs, and heart are built to work. An inactive lifestyle makes them ineffective and out of condition, but exercise can help to remedy these ill effects and promote a sense of well-being. As physical fitness increases you will find that your work and leisure activities become less tiring, and also your capacity for activity of all kinds increases. Exercise improves muscle tone, skin tone, and general appearance, and helps to delay the physical effects of aging. It also helps to make internal organs work more efficiently, reducing the risks of poor health and disease.

Exercise and age

Exercise of some sort is possible whatever your age, and in fact suitable exercises are desirable at every age. Babies should receive exercise through play and movements that increase their range of activities and physical skills. Older children and young adults usually get plenty of exercise through play and sport. In middle and old age, a conscious effort may be needed to ensure that exercise is a regular part of life. Always check with your doctor or a qualified health professional before you embark on any exercise program or take up a new sport, especially if you are over 35 years of age.

Body type and exercise

Body physiques are determined mainly by skeletal proportions, muscle development, and amounts of body fat. They can be classified into three main types. Ectomorphs are lean and rangy, with no excess body fat or weight. Mesomorphs have a good balance of muscle and weight. Endomorphs tend to be bulky and rounded in shape. The type of exercise that may suit you best depends to some extent on your body type. Ectomorphs with very little excess weight or bulk to carry often do very well at exercises and sports that



require endurance and stamina; they also find that they can sprint and cycle rapidly. Endomorphs tend to find that their natural range of activities is more limited. Copious muscle bulk may equip a person for weightlifting and power sports such as football.

Mesomorphs are generally suited to most kinds of exercise and sport. Whatever your physique, try to include several types of exercise—mobility, strength, endurance, suppleness, etc.—in your health program.

Physical benefits of exercise

The illustration shows some of the parts of the body benefited by regular exercise.

1 The contours of the body alter as the muscles and ligaments strengthen. Body tissue is prevented from sagging when the muscles are in good condition.

2 Weight may be lost as body fat is burned up in strenuous exercise.

3 Muscles themselves develop improved tone, greater stamina, and an increased blood supply to combat weakness and fatigue.

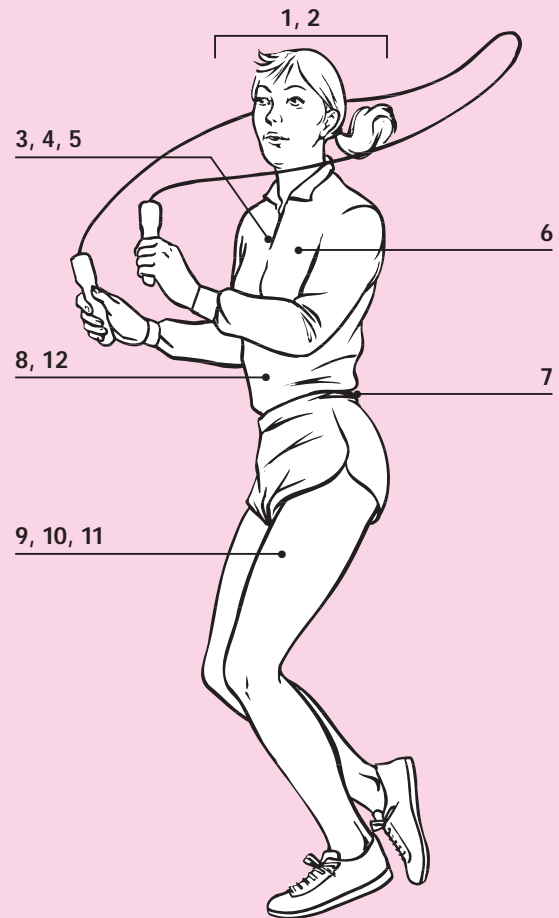
4 The efficiency of the heart muscle increases a great deal. The volume of blood pumped per beat rises, so that the heart does not have to work so hard to pump the blood around the body and supply muscle demand. The heart rate decreases as a result, both at rest and during strenuous activity.

5 The new efficient circulation causes more capillaries to form in the body tissue and therefore improves the blood supply to internal organs.

6 The efficiency of the lungs and breathing muscles also increases. The improved blood supply enables them to exchange carbon dioxide for oxygen at a faster rate, and their capacity is enlarged.

7 The bones and joints of the body strengthen so that they are less liable to injury and debilitation.

8 The posture improves as the overall condition of the muscles and joints is improved; as a result, problems such as back trouble and muscle aches may be avoided.



9 As muscles become stronger and movements more skilled and accurate, the dangers of injuries, such as falls and joint dislocations, recede.

10 The coordination and responses of the nervous system improve as the body becomes more accustomed to obeying mental signals promptly.

11 The skin tone improves as its increased circulation disperses waste products and impurities more quickly.

12 The metabolism alters, and fats and sugars in the blood are reduced.

Fractures and their repair

1 Hematoma formation

- Blood vessels in the bone and surrounding tissues are torn.
- A hematoma (blood clot) forms at the fracture site and plugs the gap between the broken ends of bone, usually within a few hours of injury.
- Blood circulation to the area stops and bone cells adjacent to the fracture begin to die from lack of nutrition.
- Tissues at the site become swollen.

2 Fibrocartilaginous callus formation

- Over the next three to four weeks capillaries grow into the hematoma.
- Bacteria-destroying cells invade the area and begin their cleaning job.
- Fibroblasts (cells that produce special fibers) cover the break, connecting the broken bone ends.

- Osteoblasts (bone-forming cells) begin to form spongy bone tissue. Together the fibroblasts and osteoblasts splint the broken bone. The external callus (repair tissue) is formed by new tissue protruding from the outer bone surface; the internal callus is the repair tissue connecting the bone ends.

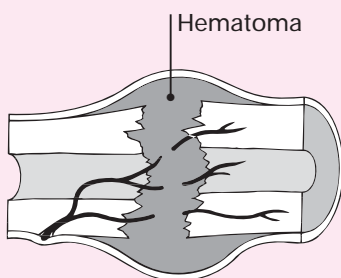
3 Bony callus formation

- More bone-forming cells enter the site, and three to four weeks after injury the formation of a bony callus (woven bone) begins.

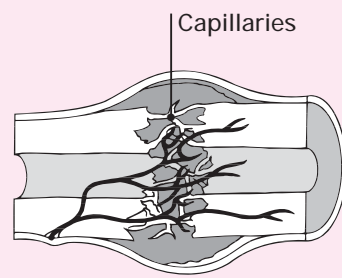
4 Remodeling

- Excess material outside the bone shaft and in the marrow cavity is removed.
- Compact bone is laid down to reconstruct and reshape the shaft.

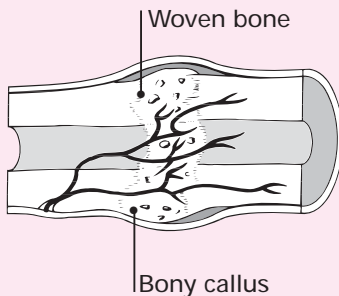
1



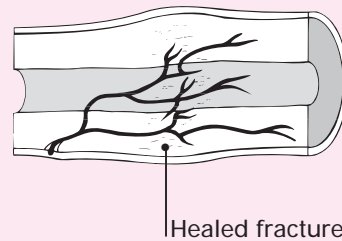
2



3



4



Some disorders of the skeletal system

Ankylosing spondylitis When joints become inflamed and later fuse.

Arthritis The term used for a variety of inflammatory or degenerative diseases that damage joints. Examples include osteoarthritis, rheumatoid arthritis, and gouty arthritis. Acute forms are commonly caused by bacterial invasion.

Dislocation When bones are forced out of their normal positions at a joint.

Gouty arthritis Caused by urate crystals (formed from uric acid) deposited in the soft tissues of joints.

Osteoarthritis (Degenerative joint disease) Cartilage repair is an ongoing process, but in osteoarthritis, more cartilage is broken down than is repaired.

Osteomalacia A group of disorders caused by lack of vitamin D, when bones soften and weaken.

Osteomyelitis Infection of bone marrow, usually caused by bacteria.

Osteoporosis When the resorption of bone outpaces its formation, leading to lighter, more porous and brittle bones, making them more susceptible to fracture.

Rheumatism Any painful state in bones, ligaments, joints, tendons, or muscles.

Rheumatoid arthritis See below.

Rickets Osteomalacia in children, when growing bones cannot calcify due to lack of nutrients, so their ends become enlarged.

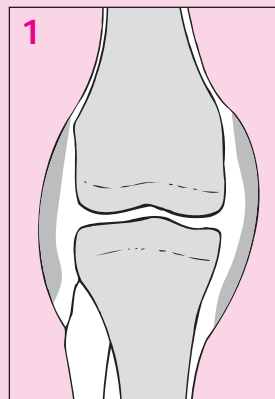
Scoliosis Abnormal curvature of the spine to the side.

Slipped disk (Disk prolapse) When the pulpy center of an intervertebral disk bulges or oozes out and may press on an adjacent nerve, causing pain.

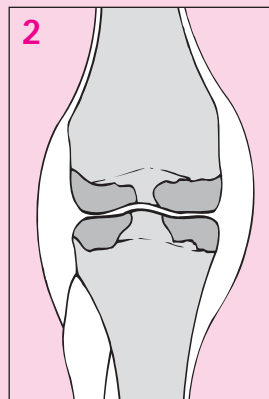
Tendonitis The inflammation of tendons, often due to overuse of muscles.

Stages of rheumatoid arthritis

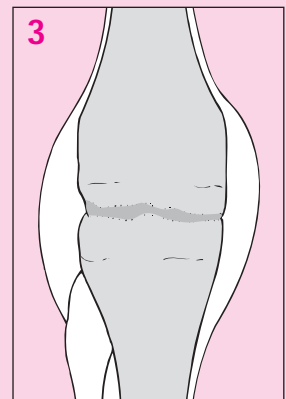
This chronic inflammatory disorder causes severely swollen and painful joints. It tends to flare up, then fade for a time. It is an autoimmune disease (the body's immune system attacks its own tissues).



Inflammation



Erosion of cartilage



Fused joint

In general, muscle tissue is less prone than many other tissues of the body to serious disease processes such as infections, malignancies, and degenerations. However, more than most other tissues, muscle is prone to injury—as a result of its primary role in carrying out physical movements of the body. Many muscle problems stem from underused, fatigued, torn, or strained muscle fibers and tendons. When muscles are fatigued and

weak, the body is at greater risk of losing balance, grip or stability, and so accidental injuries such as twisted joints, ripped ligaments, or sprained tendons are more likely. Torn muscle fibers are a common minor problem but a major tear through an entire muscle or its tendon is rare. The more muscles are exercised, and the greater their blood supply, then the more rapid will be their healing processes.

Sites of problems

The following troubles show up in muscles or tendons but some are rooted in disorders of the nerves that operate them.

a Tics: blinking, nose-wrinkling, and head-shaking are typical habit spasms (see opposite).

b Bell's palsy is a problem with the facial nerve affecting one eyelid and one side of the forehead and mouth (see opposite). It is usually only temporary.

c In crossed eyes (strabismus), the muscles that control eyeball motions are imbalanced.

d Stiff neck is often a mild disorder caused by muscle cramp due to sudden twisting or sleeping uncomfortably.

e Spasm of involuntary muscle in the bronchial tubes narrows them and

produces wheezing, breathlessness, and similar asthma symptoms.

f Torn tendons often occur at joints where strong forces act, for instance the knee and ankle.

g Ruptured biceps (at upper end) may occur in middle-aged people who lift or pull heavy weights.

h Wrist ganglion is a painless lump in the wrist produced by a tendon cyst.

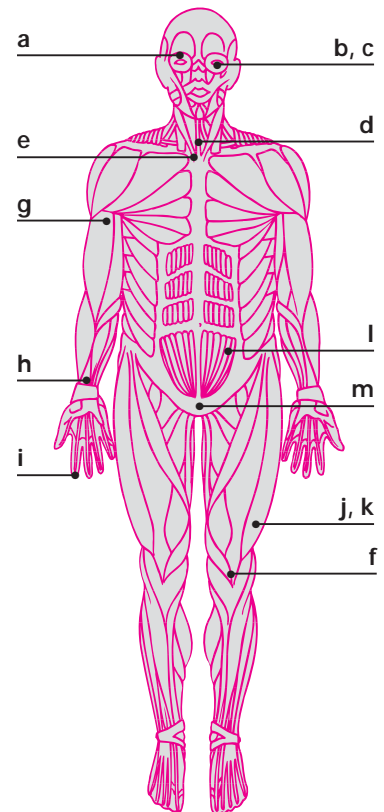
i Raynaud's disease involves spasm affecting blood vessels in the fingers.

j Cerebral palsy can produce twitching limbs and partial facial paralysis.

k Poliomyelitis is a viral disease that may paralyze limbs.

l Lumbago is a vague term for low back pain (see Fibrositis opposite).

m Spasms or loss of muscle control sometimes affect the



sphincter muscles which make up the pylorus (stomach outlet), gallbladder, bladder outlet, or anus.

Some disorders of the muscular system

Bell's palsy (See opposite) Also known as facial palsy. Temporary paralysis of the facial muscles on one side. The paralysis can be caused by injury to, or infection of, the controlling nerve.

Bursitis Inflammation of the sac (bursa) lubricating a joint. It can be caused by calcium deposits on a tendon, but is generally a result of continuous friction, pressure, or other injury.

Cardiomyopathy Disease of the heart muscle (myocardium).

Convulsions Involuntary contractions of a group of muscles caused by an imbalance in the nervous system.

Cramp A painful involuntary muscle spasm, which may result from loss of salt owing to excessive sweating or from deficient blood supply to the affected area.

Fibrositis Pain in muscles around joints. When this occurs in the lower back it is sometimes called lumbago. The cause is not known, but tension and bad posture may be to blame.

Gangrene (gas) A type of gangrene involving bacterial infection, usually of a wound, leading to muscle death.

Leiomyoma A noncancerous tumor of smooth muscle. Fibroids are common leiomyomas that occur in the uterus.

Muscular dystrophy A group of inherited disorders in which there is a progressive wasting of muscle.

Myasthenia gravis Weakness in skeletal muscles caused by an abnormality that prevents muscles from contracting.

Myoclonus Rapid, involuntary spasm or jerks of a muscle or muscles during

movement or rest. It can occur as a result of a brain disorder or epileptic fit, and may be linked with diseases of the nerves and muscles.

Myoma A benign muscle tumor.

Myopathy A muscle disease—usually degenerative, but sometimes caused by drug side-effects, chemical poisoning, or by chronic disorder of the immune system. The muscles generally fail to function fully.

Myositis Inflammation of muscle tissue, causing weakness, tenderness, and pain.

Myotonia The inability of a muscle to relax after the need for contraction has passed.

Rhabdomyolysis Destruction of muscle tissue, accompanied by the release into the blood of myoglobin (oxygen-carrying red muscle pigment). A common cause is a crushing muscle injury.

Spasm A sudden, involuntary contraction of the muscle lasting a short time.

Stitch A sharp pain in the side that can occur during strenuous exercise. Its exact cause is disputed.

Tenosynovitis Inflammation of the sheath around a tendon caused by rheumatism or bacterial infection.

Tetanus Disease caused by bacterial infection in which muscles are severely affected. Causes stiffness, contractions, and spasms. Also known as lockjaw.

Tic The involuntary twitching of a muscle normally under voluntary control. Generally a sign of anxiety or insecurity, a tic begins as a deliberate movement that becomes unconscious.

Wrist ganglion A lump in the wrist produced by a cyst affecting a tendon.

The axial skeleton is the central column or axis that supports the torso, neck, and head in an upright position, and to which the limb girdles attach. The total of 80 bones in the axial skeleton includes six ear ossicles—the three tiny bones in each middle ear concerned with sound vibrations and hearing rather than support. The total also includes the slim, curved hyoid bone, at the root of the tongue and just above the larynx. It provides support, protection, and attachment for muscles.

Skull structure and functions

Skull bones: cranium

The skull has two main components: the cranium and face. The cranium consists of eight large, curved plates of bone. Two of these are paired, being the temporals (in the temple region just above the ear) and parietals (above the temporalis). The unpaired bones are the frontal of the forehead, the ethmoid and sphenoid below and behind the eyes, and the occipital forming the lower rear bulge of the head.

Skull bones: face

The largest of the facial bones is the mandible (lower jaw), sometimes considered as a separate element from the skull itself. Above this are the paired maxillae (forming the upper jaw). Most prominent to the sides are the zygomatics (cheek bones). The two small nasal bones form the bridge of the nose.

The prominence of the nose consists of cartilage rather than bone.

Cavities and chambers

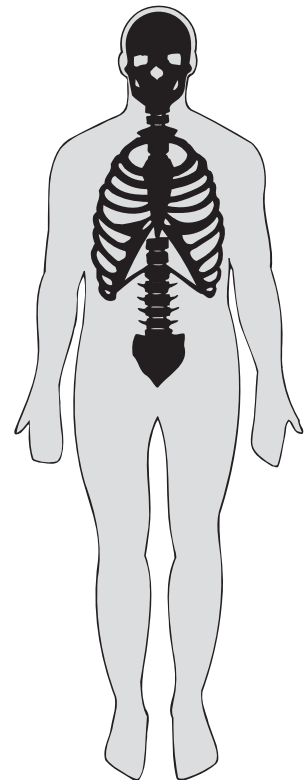
The facial bones enclose and define the main chambers of the nasal and oral cavities (the interiors of the nose and mouth). The major cerebral cavity of the cranium houses the brain. A hole below the brain, in the base of the occipital bone, permits the spinal cord to extend downward from the brain. Cavities within each temporal bone form the outer ear canal, middle ear space, and fluid-filled inner ear chambers. There are also four pairs of paranasal sinuses—air-filled regions of spongy or honeycomb bone that communicate via openings with the main nasal airway. These are set within the ethmoid, maxillary, sphenoid, and frontal bones.

The young skull

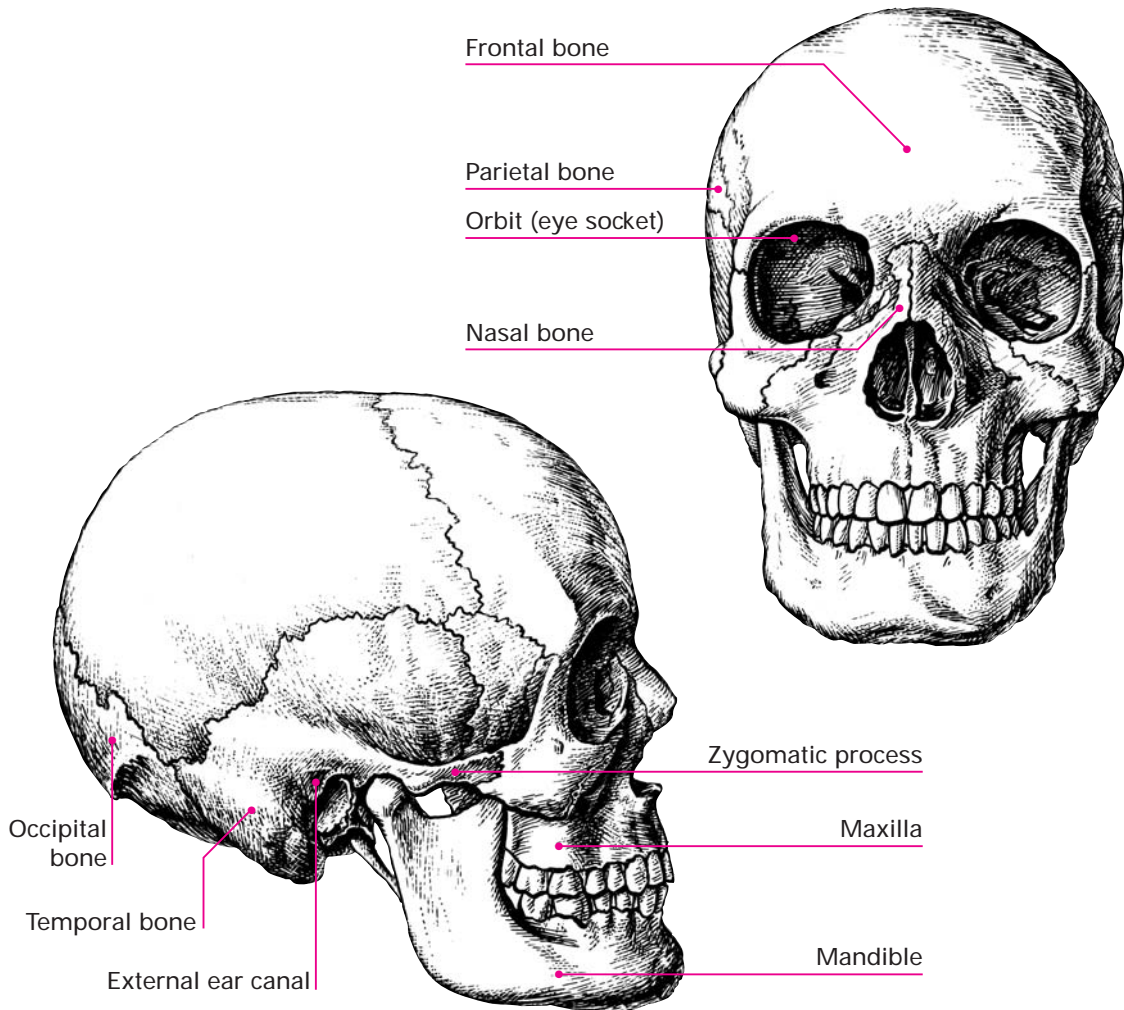
- In a newborn baby, some of the skull bones are not yet fused together.
- Gaps between the bones are called fontanelles.
- They allow the baby's head to "mold" during birth.

Axial skeleton

The axial skeleton has 80 bones and consists of the skull, vertebrae, ribs, and sternum.



The main components of the skull



Skull bone functions

The cranium forms a protective “braincase” which is extremely strong due to its domed shape. Each side of the cranium, in the temporal region, provides a large area to anchor the powerful jaw-closing chewing muscle, the temporalis, which links to the

mandible below. More than 50 facial muscles attach to the facial bones and permit innumerable facial movements and expressions. The sides and base of the skull anchor neck muscles which link to the shoulder bones of the scapula and clavicle, and the upper ribs.

The vertebral column, also called the spine, spinal column, or colloquially, the backbone, consists of 26 bone elements—vertebrae. These are located one on top of another and are linked by intervertebral joints. In each of these joints is a washer-like pad or cartilage—

the intervertebral disk—which gives the whole column flexibility and shock-absorbing qualities. Cavities within the main parts, or bodies, of the vertebrae align to form a long tunnel within the column, which houses and protects the spinal cord.

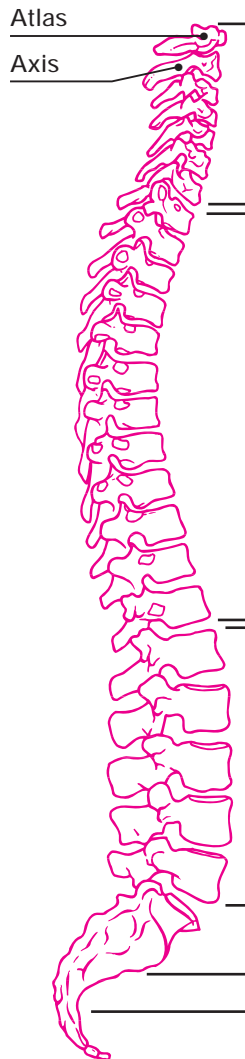
Regions and curvatures

The uppermost region of the vertebral column is the topmost seven cervical (neck) vertebrae. Below this is the thoracic (chest) region of 12 thoracic vertebrae, each supporting a pair of ribs. The lumbar (lower back) region contains the five largest individual bones, the lumbar vertebrae. The sacrum at the base consists of five fused sacral vertebrae. In lateral view each region shows a curvature, with the cervical and lumbar arching forward, and the thoracic and sacral rearward.

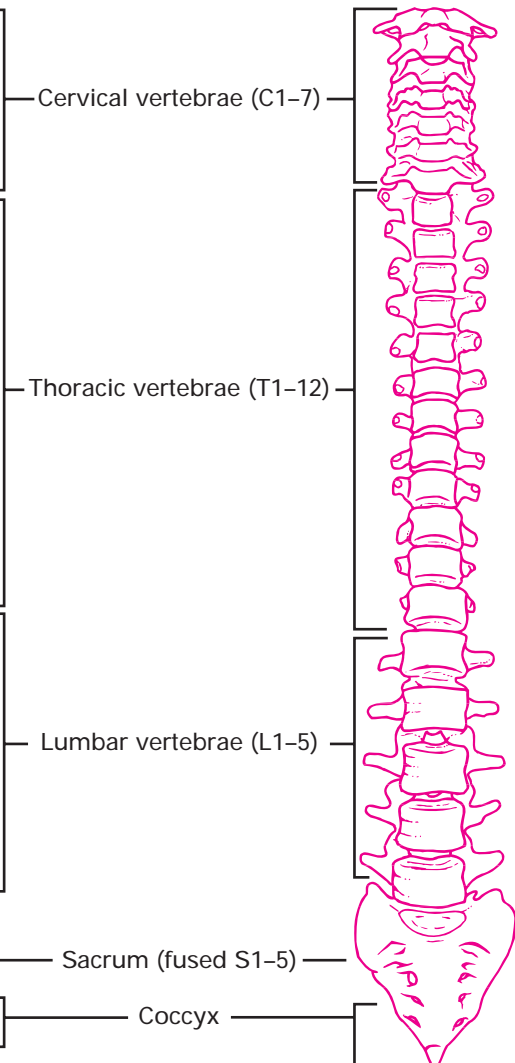
Nodding yes, shaking no

- The uppermost vertebra, atlas, contributes to nodding head motions.
- The second vertebra, axis, contributes to head-shaking movements.

Lateral (side) view



Posterior (rear) view

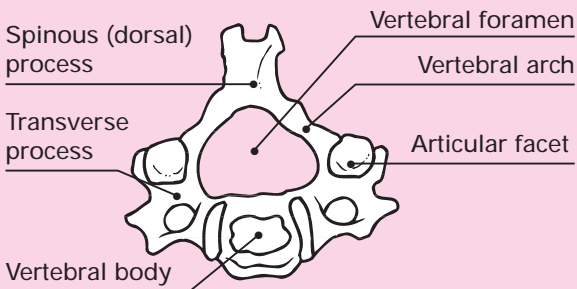


Structure of the vertebrae

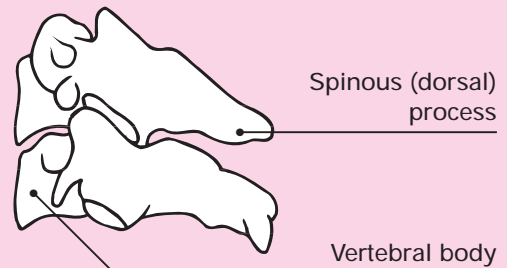
Each vertebra has an approximately cylindrical main body or centrum. The body is to the front, and rearward is the vertebral or neural arch. This encloses the vertebral foramen, the hole for the spinal cord. Projecting to each side from

the arch are transverse processes, and to the rear, the spinous or dorsal process. These are anchor sites for back muscles. The smaller articular processes have facets that join with those of neighboring vertebrae.

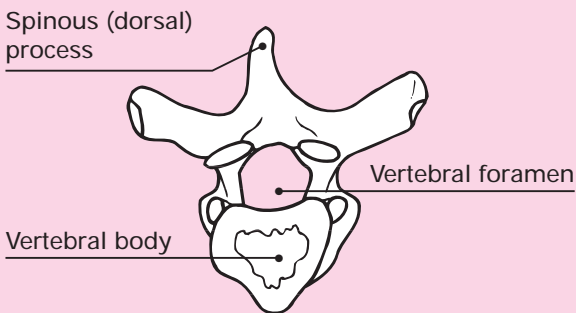
Cervical vertebrae: superior (top) view



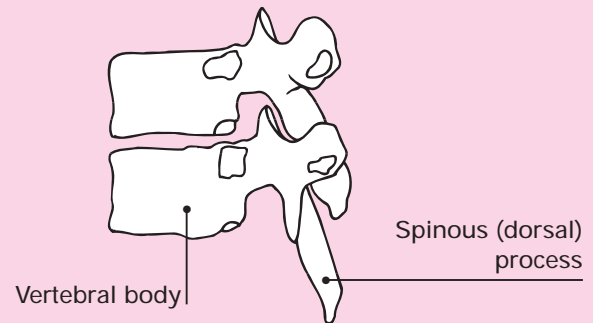
Cervical vertebrae: lateral view



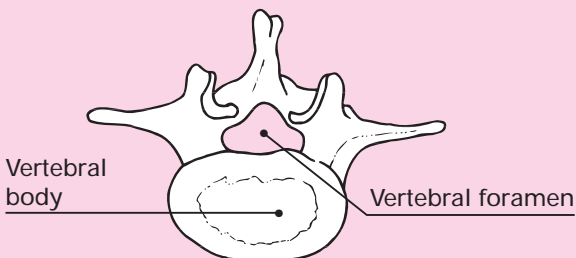
Thoracic vertebrae: superior view



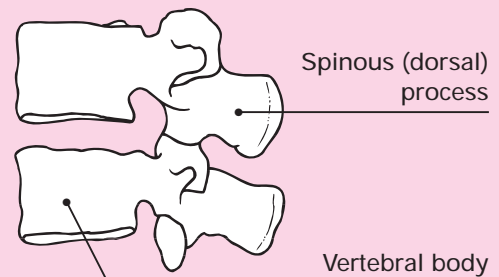
Thoracic vertebrae: lateral view



Lumbar vertebrae: superior view



Lumbar vertebrae: lateral view



The pelvis or hip bone is a composite structure with seven main elements. In the center at the rear is the wedge-shaped sacrum, which with the coccyx below it, forms the base of the spinal column. To either side, arching around to the front, is the bowl-shaped pelvic bone, made of six elements.

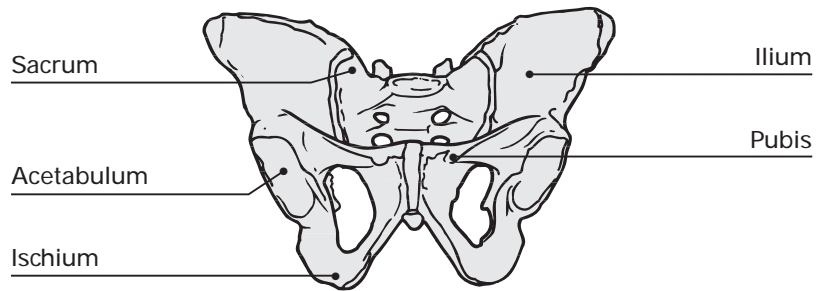
Pelvic bones

On either side, the pelvic bone consists of three bony elements. These are the ilium adjacent to the sacrum, the ischium below and arching to the front, and the pubis above and also arching forward. These three bones are known as the os coxa.

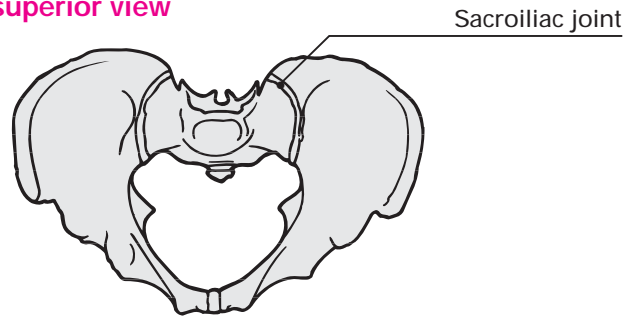
Joints

The seven pelvic elements are linked firmly by cartilaginous joints. At the front the two pubic bones are joined by the less firm pubic symphysis. A socket-shaped acetabulum at the junction of all three bones—ilium, ischium, and pubis—forms the hip joint with the head of the femur.

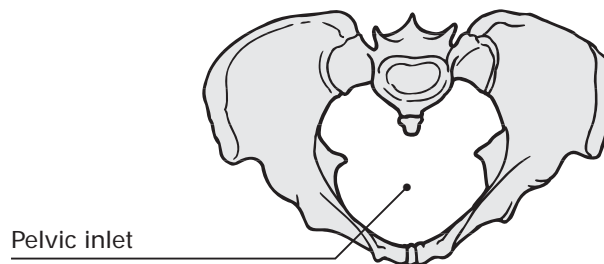
Male pelvis: anterior view



Male pelvis: superior view



Female pelvis: superior view



Male and female pelvis

There are significant differences between a male and female pelvis related to child-bearing. The female pelvis is wider than the male's and is set at a more shallow angle, allowing a baby to pass through at childbirth.

General structure

- Male pelvis is heavier and thicker.
- Joint surfaces are larger in the male.
- Female pubis is more rounded.
- Acetabulum is smaller in the female.
- Pelvic inlet is larger in the female.

Sacrum

The sacrum begins in embryonic development as five vertebrae, part of the entire vertebral column, with typical intervertebral disks and joints between. During development these joints ossify and fuse to make the sacrum a single solid structure. Transverse lines indicate the sites of the former joints (opposite). The upper center of the sacrum articulates with the lowest and largest of the individual vertebrae, L5, at the lumbosacral joint. Nerves from the spinal cord exit through gaps in the sacrum.

Coccyx

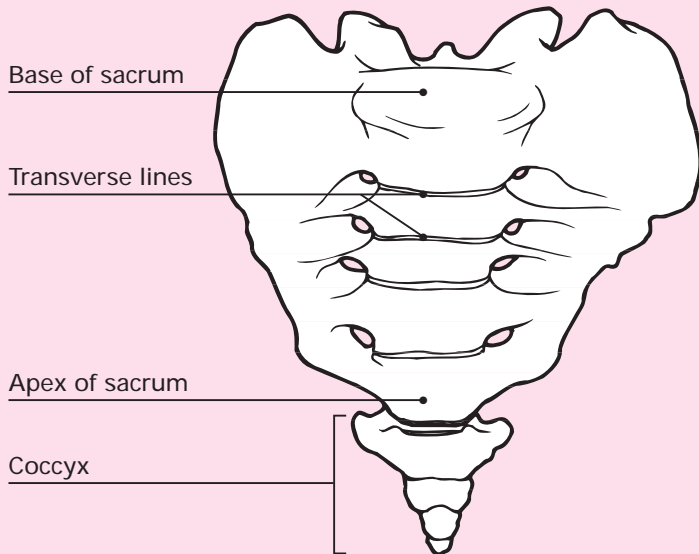
The coccyx or vestigial “tail” (see below) articulates with the sacrum above it. This is a modified intervertebral joint with a fibrous intervertebral disk. The coccyx tapers to a stump or apex below. It has a variable number of fused vertebrae in different individuals, usually four but occasionally three or five.

The human “tail”

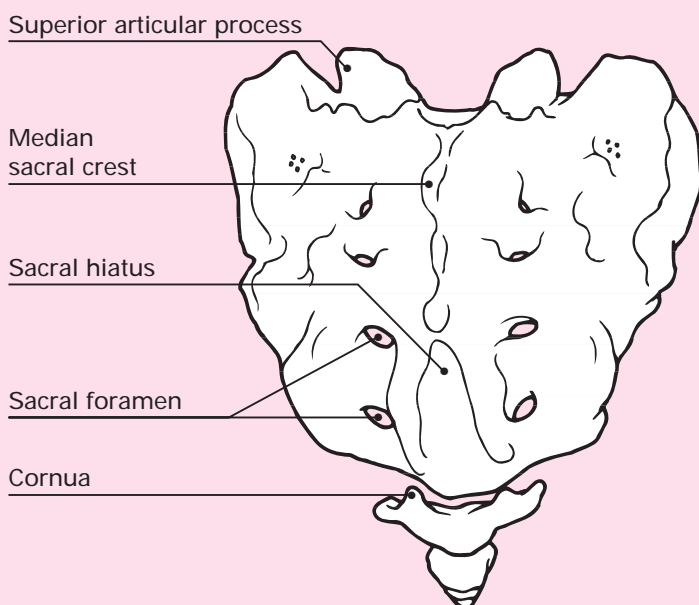
- The “tailbone” or coccyx consists of three to five fused coccygeal vertebrae.
- The coccyx is relatively long in the embryo but shrinks by the eighth week.

Sacrum and coccyx

Anterior view



Posterior view



The mouth, or oral cavity, is a mucosa-lined chamber housing the teeth and tongue (accessory digestive organs). It is made up of the lips, cheeks, and palate. It is bounded by the maxillae (upper jaws), mandible (lower jawbone), and the palate or roof, which is formed from horizontal plate-like extensions of the facial maxillae and palatine bones.

Lips

Structure The lips, or labia, are folds of skeletal muscle with a thin covering of epithelium (layer of cellular lining tissue).

Functions

- Hold food and drink in the mouth and keep them in place for chewing and swallowing.
- Protect the anterior (front) opening of the mouth.
- Act as sensory receptors to judge the temperature and texture of foods.
- Alter shape to change the quality of sounds including speech and vocalizations.

Palate

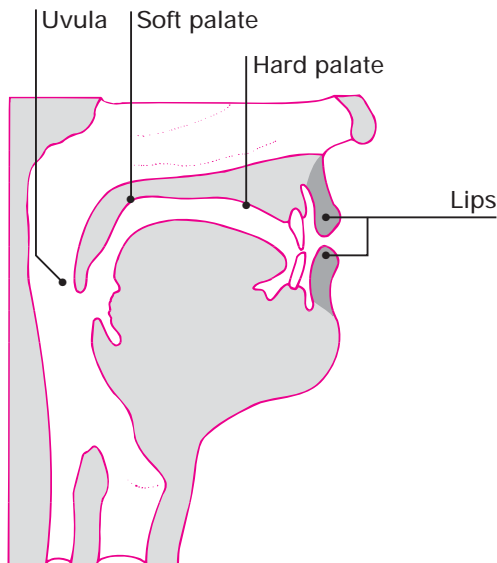
Structure This is the roof of the oral cavity.

- The front part, the hard palate, comprises on each side the palatine processes of both the maxilla and palatine bone.
- The rear part, the soft palate, is made up of skeletal muscle, cartilage, and connective tissue.
- The soft palate ends in a projection called the uvula, visible when looking into the open mouth.
- The palatine tonsils (paired masses of lymphoid tissue) are at the rear of the oral cavity.

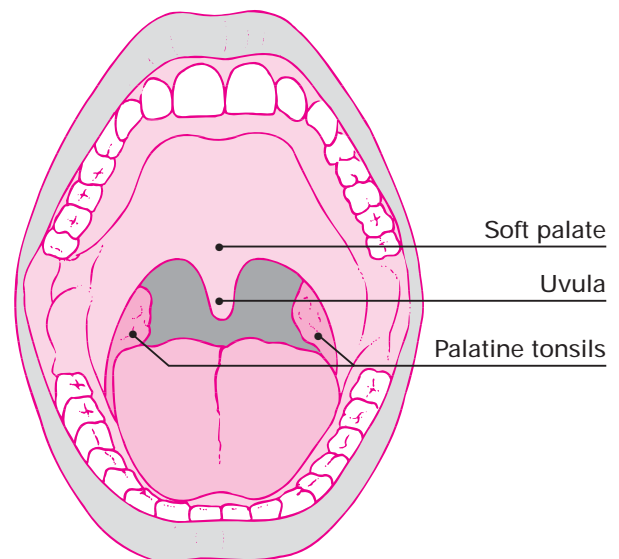
Functions

- Constrains food when chewing.
- Prevents food from entering the nasal cavity during swallowing. This is achieved by the soft palate and uvula rising to cover the nasopharynx (entrance to nasal cavity) so that food must pass downward into the pharynx or throat).

Side view of mouth and nose



Anterior view of mouth

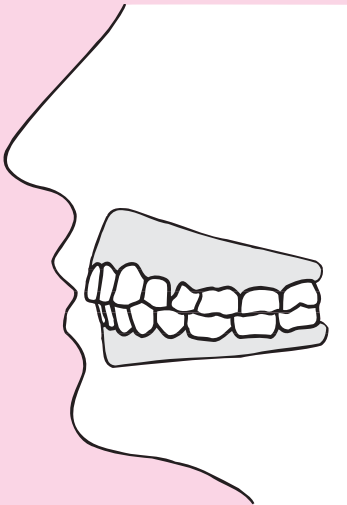


Teeth

Teeth are anchored into the jawbone in deep sockets, by strong periodontal fibers and a natural “glue,” cementum. The part of a tooth fixed into the bone is the root; the part projecting above is the

crown. A typical adult has 32 teeth in total. On each side of the mouth, in each jaw (upper and lower), there are: two incisors, one canine, two premolars, and three molars.

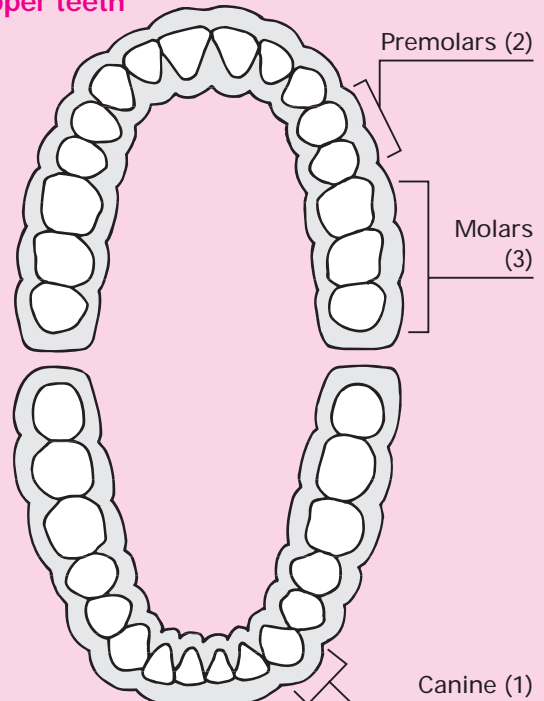
Side view



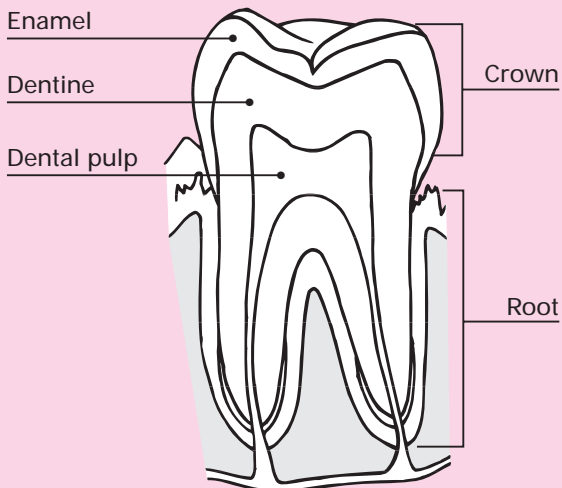
Individual teeth of upper jaw



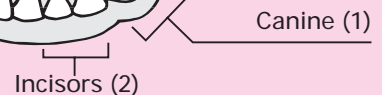Upper teeth



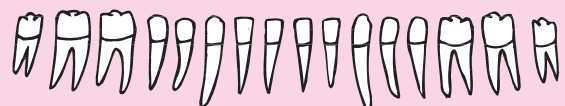Structure of a permanent molar tooth



Lower teeth



Individual teeth of lower jaw

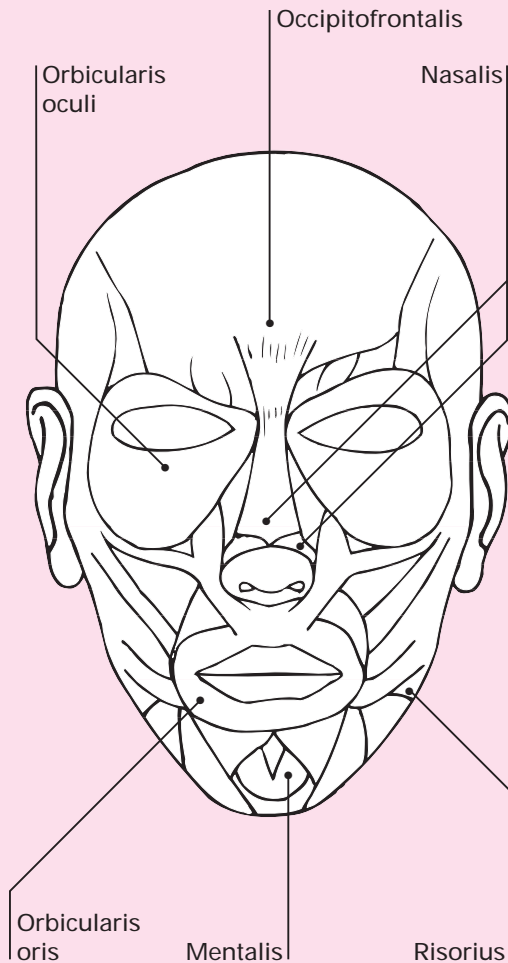

More than 60 muscles provide the face with its vast range of movements for feeding and to convey information, feelings, and emotions, both by vocalized sounds and unspoken expressions. These muscles are in the face and also the scalp and neck.

Smile or frown?

- The old adage is true: it takes more effort to frown than to smile.
- A typical smile employs 18–20 muscles.
- A typical frown uses twice as many.

Muscles of the face: anterior view

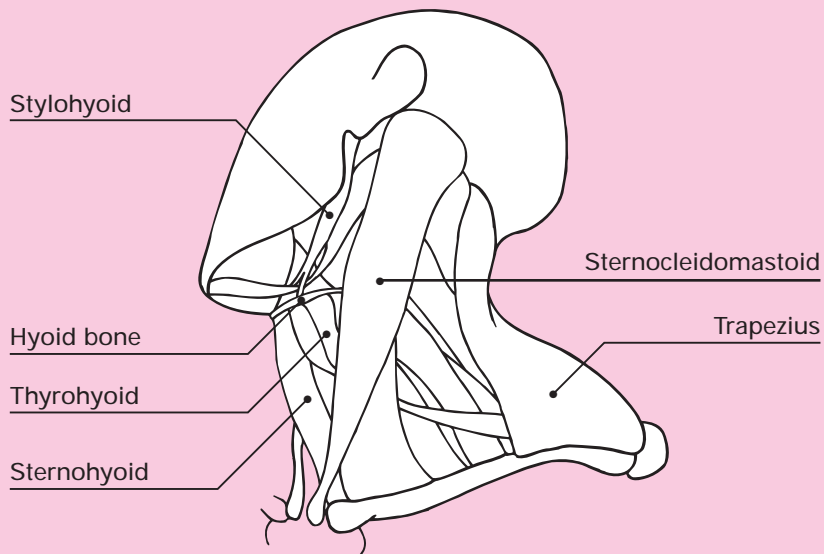


Muscles of the face: lateral view



Muscles of the neck

Neck muscles balance the head and twist the face to look around. Most run from the rear skull and facial area down to the hyoid, clavicle (collar bone), scapula (shoulder blade), sternum (breastbone), and the cervical and thoracic vertebrae.

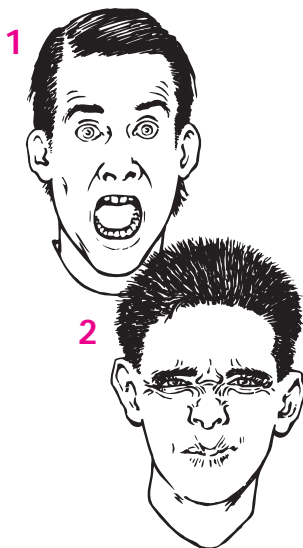


Exercises for the face

Isometric exercises help to keep the muscles of the face supple and in good condition. They are quite strenuous for the muscles concerned, so only do each exercise once a day and maintain the position for a maximum of only six seconds.

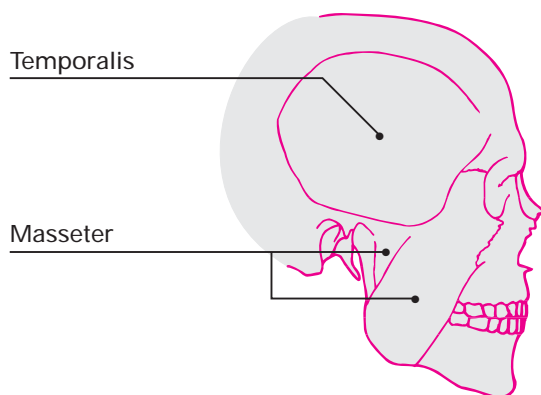
1 Open your mouth and eyes wide so that your facial muscles are as fully stretched as possible; hold this position.

2 Screw up your eyes and mouth and wrinkle your nose so that your facial muscles are contracted; hold this position.



Muscles used in eating The main power for biting and chewing comes from the temporalis and masseter muscles on the side of the face, running from the temple region and cheekbone down to the mandible.

The muscles of mastication

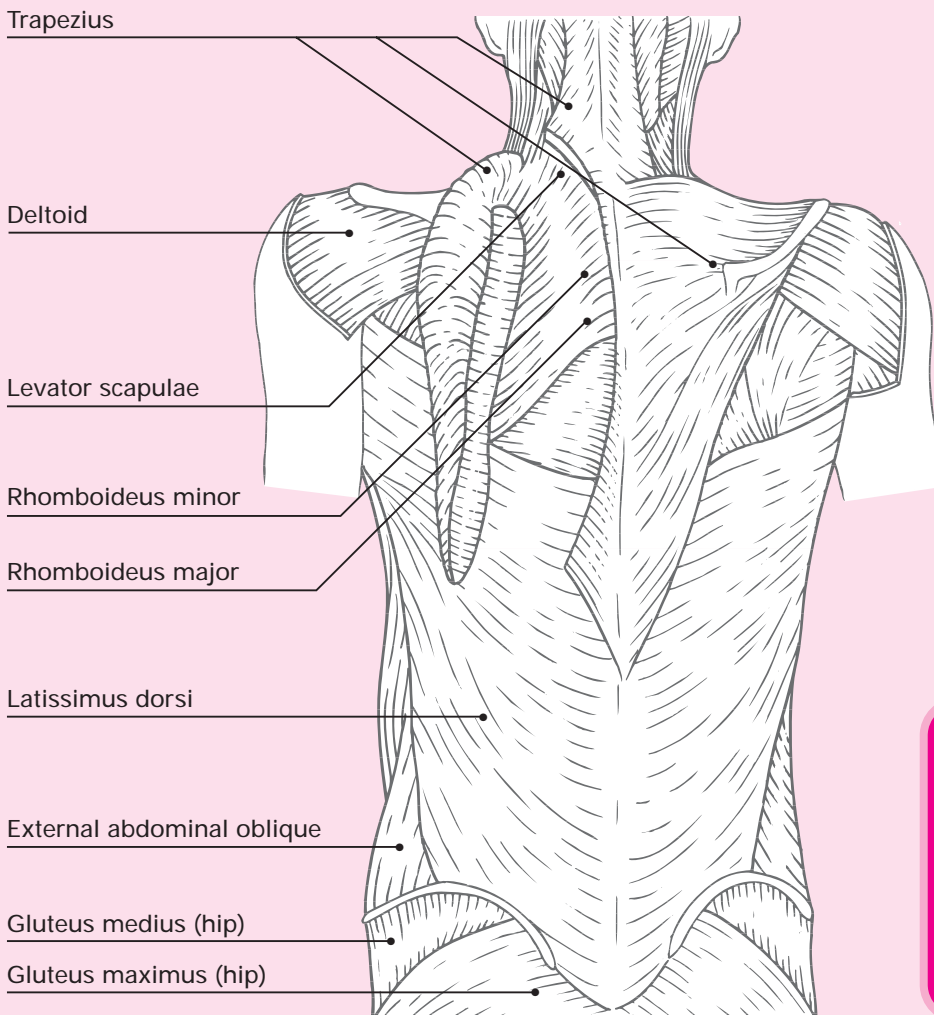


Groups of back muscles

Muscles that move the back or vertebral column may be regarded as two main groups. The superficial or extrinsic group are also associated with the limb girdles (shoulders and hips) and may bend or twist the back as a secondary

effect to positioning the limbs (see below). The middle and deep, or intrinsic, spinal muscles are mostly concerned with moving and stabilizing the vertebral column itself (see opposite and also page 48).

Posterior view showing superficial (extrinsic) muscles



Bearing the load

- When standing upright at rest, many back muscles relax since ligaments take the strain (see next page).

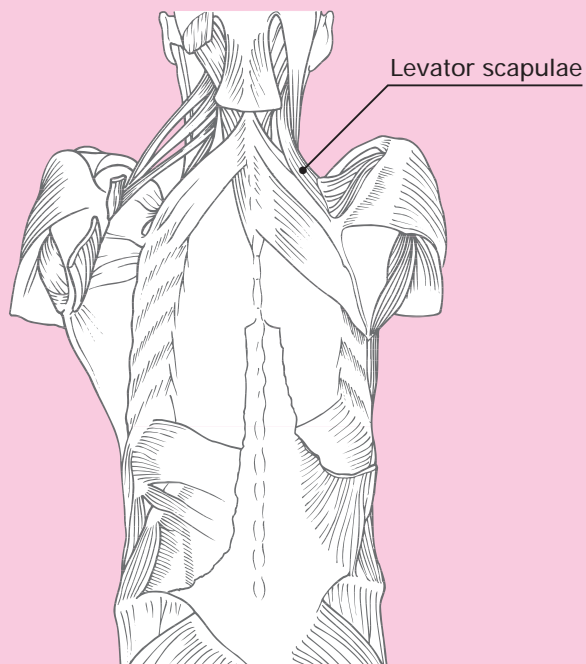
Intermediate spinal muscles

The intermediate or middle layer of spinal muscles is involved in limb and back movements, and also in the movements of respiration (breathing). For example, the levator scapulae lifts or “shrugs” the shoulder and also extends the chest to increase its volume for deep breathing.

Longest muscles

- Some fibers of the longissimus thoracis muscle run almost half the length of the back.

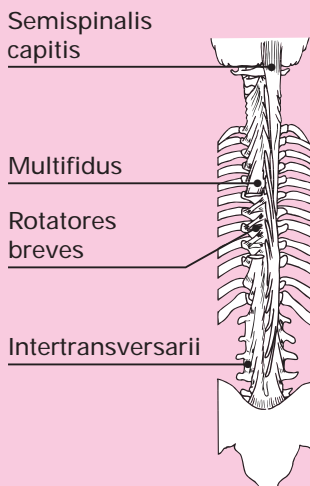
Posterior view showing middle layer muscles



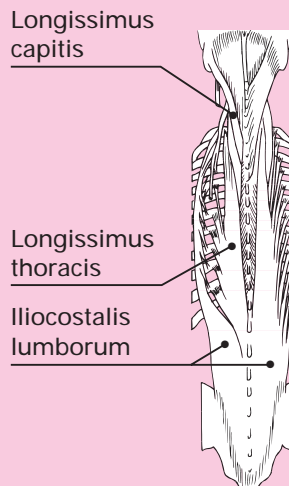
Erector tracts

The erector spinae or sacrospinalis tracts of muscles lie on either side of the vertebral column. The medial tracts are adjacent to the column with the medial tracts to the side. They are formed over overlapping sets of muscles which “leapfrog” each other, spanning from five to 15 or more vertebrae. They bend and twist the spinal column.

Erector spinae: medial tract



Erector spinae: lateral tract

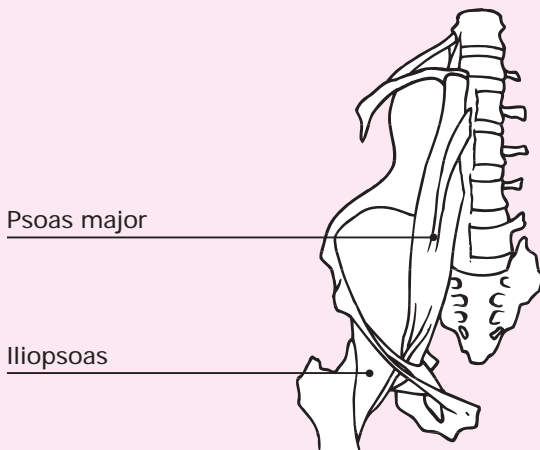


Pelvic muscles

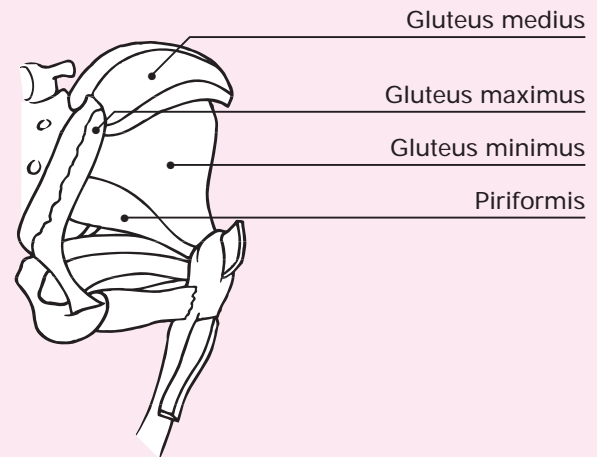
The wide, flaring surfaces of the pelvic (hip) bone provide anchorage for three main groups of muscles. These are the spinal muscles of the vertebral column and the abdominal wall muscles, both from above, and the hip and leg muscles

below. Deeper pelvic muscles support the pelvic floor or diaphragm (base of the abdomen) against the weight of the viscera above, and are also involved in urination, defecation, and childbirth.

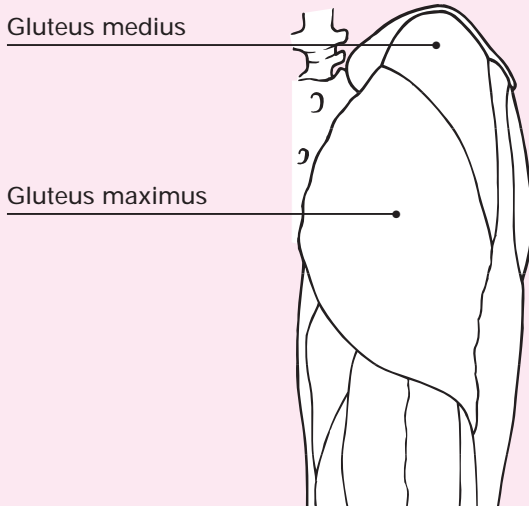
Anterior view: deep muscles



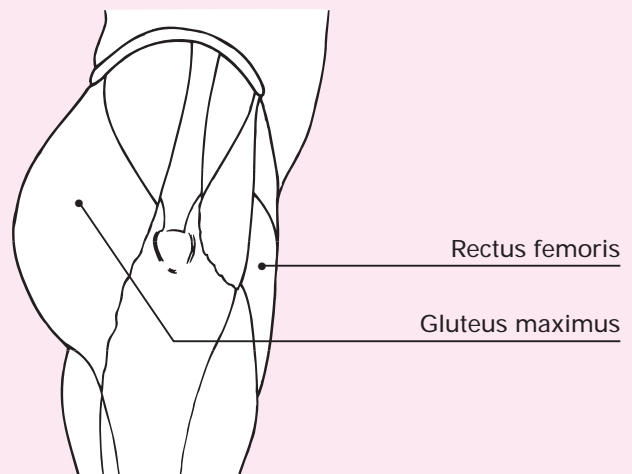
Posterior view: deep muscles



Posterior view: superficial muscles



Lateral view: superficial muscles



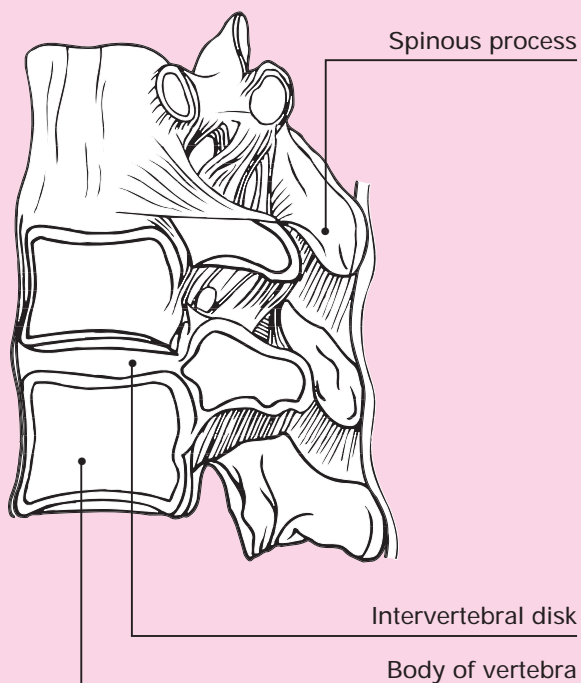
Lower spinal muscles

Intrinsic vertebral or spinal muscles (see previous pages) attached to the transverse and spinous processes act to bend and twist the back, and also to stabilize it, for example, when lifting heavy loads. Elastic ligaments span and encase each intervertebral joint.

More spinal muscles

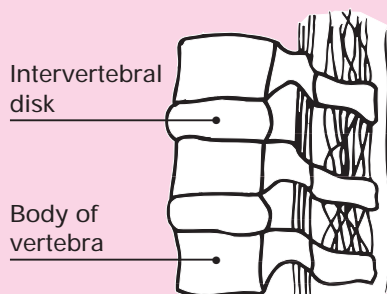
- Intrinsic spinal muscles are named from the number of vertebrae they span or "leapfrog."
- Rotatores bundles span one or two vertebrae.
- Multifidus bundles span two or three vertebrae.
- Semispinalis bundles span four or five.

Lateral view and section



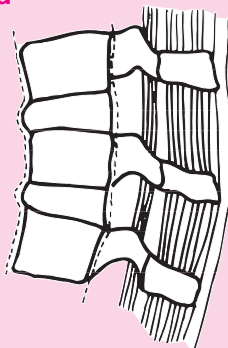
Movements of spinal column

Straight



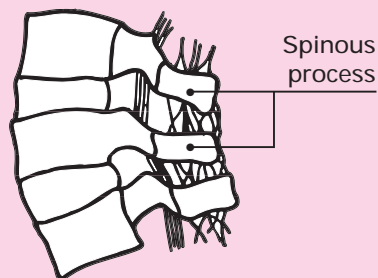
The spinal column's load is balanced front and rear, side to side.

Fixed



Muscles tense against an unequal load to stiffen and hold the back rigid.

Extended

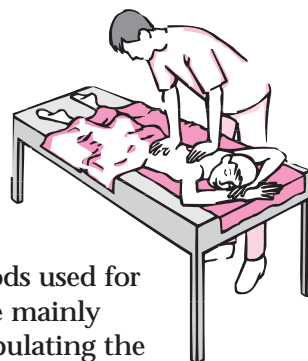


Dorsal (posterior) muscles contract to arch the back to the rear.

Relaxation should concern everyone who wants to maintain a healthy body. Relaxation enables the body to rest from the stresses and pressures of everyday life; the muscles are given an opportunity to relax, and you can use your period of relaxation as a time to remove worrying thoughts from your mind, since physical relaxation cannot be effectively achieved in the absence of mental relaxation. These pages cover some of the problems caused by lack of relaxation, and also look at ways in which you can help your body and your mind to relax. Try to spend at least 30 minutes relaxing every day.

Massage

Massage is one of the most effective ways of relieving tension in tired, knotted muscles. Techniques vary greatly but straightforward methods used for physical relaxation are mainly concerned with manipulating the muscle tissues with slow, even pressure. This increases the blood supply, removes impurities, and restores suppleness.

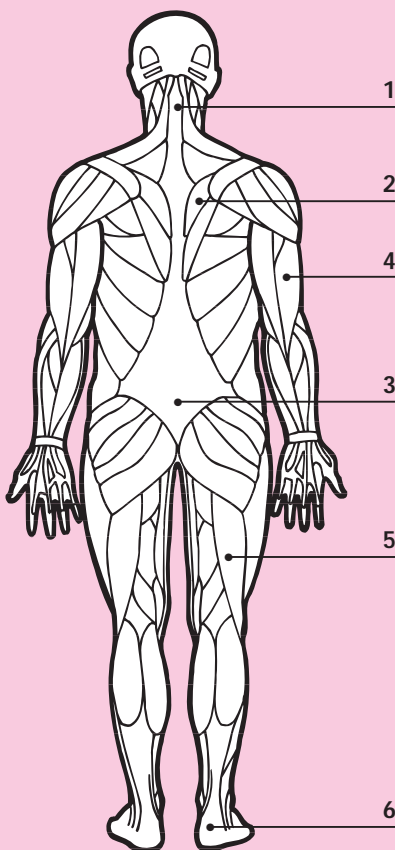


Areas of tension

1 Tension in the back of the neck may be due to anxiety or stress, or long hours in certain postures, such as computer work. Massaging the back of the neck with your fingertips may relieve the tension.

2 Tension in the shoulders may occur if your desk or workbench is at the wrong height. Stretching and easing the muscles often proves effective.

3 Pain and muscle tension in the small of the back may be a result of poor posture, wearing high-heeled shoes too frequently, or sagging muscles in the back and abdomen that fail to give proper support.



4 Muscle tension and aches in the arms are usually caused by overworking the muscles concerned.

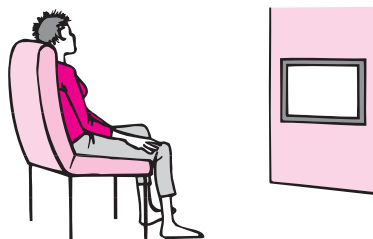
Massage and rest should ease the problem.

5 Tension and stiffness of the thigh and calf muscles is usually caused by enthusiastic exercise, such as running or cycling, especially the following day. This can be eased by using the muscles gently, for instance, walking or gentle jogging.

6 Aching and/or tender muscles in the feet result from overwork, walking, running, or standing for long periods. Warm footbaths are often soothing.

Sitting positions

Relaxation is possible in many positions. Learn by discovering some of the positions that enable your body to rest itself without strain. If you are sitting in a chair, make sure that it gives adequate support all the way down the spine. Sit well back on the seat with your back and neck straight, and your head and especially lower back well supported.



Sitting correctly



Lying correctly

Lying positions

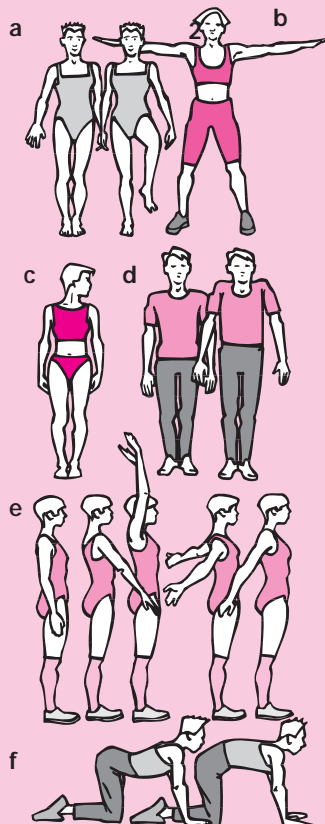
Lying down is one of the most effective ways to relax the entire body, and need not be reserved only for sleep. Lying on your right side ensures that your heart is not constricted and enables you to relax better than lying on your left. Bend your left knee up so that you do not have to tense muscles to prevent rolling over, and cushion your head on a pillow.

Relaxation exercises

a Stand upright, as relaxed as possible, and shake each arm in turn. Shake first from your wrist, then from your elbow, then from your shoulder. Then repeat with each leg in turn, shaking from the ankle, the knee, and then the hip.

b Stand with your feet apart and your arms by your sides. Take a deep breath as you slowly raise your arms out to shoulder level, then hold your breath as you maintain this position for a few seconds. Breathe out steadily as you lower your arms slowly.

c Loosen your neck muscles by tilting your head down, to the right, to the back, to the left, then



down again.

d Loosen your shoulder muscles by standing with your arms by your sides and then shrugging your shoulders as high as you can. Hold this position briefly, then relax; repeat several times.

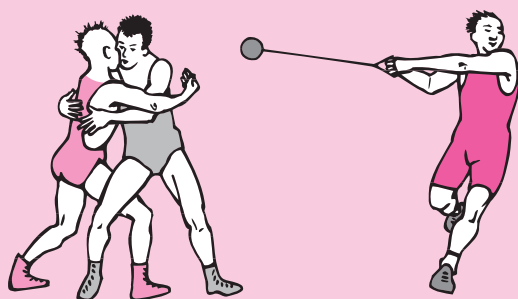
e Stand with your arms at your sides. With the backs of the hands leading, move your arms forward, up, back, then down again to trace large circles; this will help to relieve tension in the shoulder muscles.

f To relieve stiff back muscles, kneel on all fours, then alternately hollow and hump your back. (Beware of this exercise if you suffer from backache.)

Strength exercises are not just for “power” activities such as weightlifting and bodybuilding. They are beneficial exercises that will improve the health of most people’s bodies. They impart shape and tone to the body muscles, and enable the body to cope with situations that call for more than usual physical effort, such as carrying or pushing heavy objects and taking part in certain strenuous sports. Strengthening exercises also make the muscles more capable of protecting the joints and the internal organs; as a result these parts of the body are less liable to injury. Strengthening exercises usually build up the weight and power of the muscles by repeating various strenuous actions. Using weights or other aids while exercising is one way to increase the effects of strengthening exercises. Before starting any of these programs, consult a qualified adviser.

Sports and activities

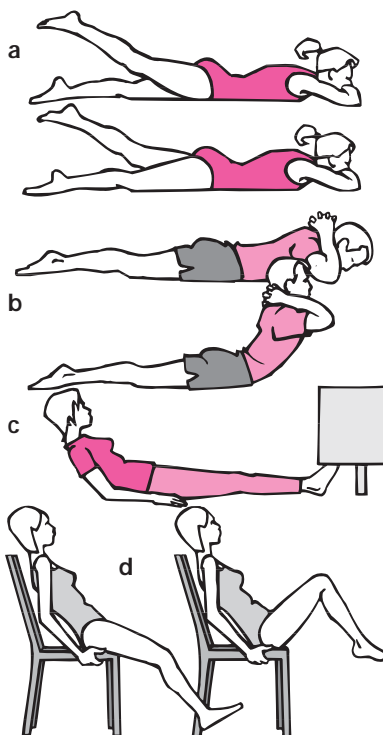
Various sports increase strength by repeatedly exercising one or more sets of muscles. Competitive swimming and rowing have great all-around effects on the body’s strength, because most of the body’s muscles are exercised.



Strengthening routines

a Lie face down with your hands under your chin. Lift first one leg and then the other, each time as high as possible. Repeat a few times at first. Increase the number of lifts each day by one or two. Discontinue if there are spasms in the small of the back.

b Lie face down with your hands clasped behind your head. Raise your head and chest as high as possible. As above, repeat a limited number of times at first, and increase the number gradually day by day. Discontinue if there is discomfort or spasm in the neck or back.



c Lie on your back with your feet hooked under a piece of furniture or held down by a partner. Lift your head and shoulders off the ground, keeping your elbows in contact with the ground, using your shoulders, arms, and the front of your lower abdomen to provide the lifting power.

d Sit at the front of a chair, gripping the sides with your hands, legs out straight in front with heels resting on the floor. Lift your feet and bend your knees up to touch your chest, then lower them back again slowly.

Exercises for backache sufferers

General advice

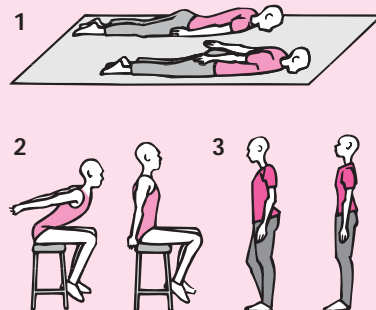
Unless advised otherwise by a doctor, sit on hard, straightbacked chairs; sleep on a firm mattress; and organize work surfaces so that you do not have to lean forward. To get into bed, face the bed, placing both hands on it for support. Raise one knee at a time onto the bed. Crawl into position and roll onto your side, using a pillow to support your head.

Back exercises

Unless doctors advise otherwise, these exercises may benefit bad backs. Do each exercise twice daily.

1 Lie face down with your arms at your sides; contract your abdomen and buttocks to bring your shoulder blades together.

2 Sit upright. With your hands clasped behind you, bend forward as you lift your head and bring your shoulder blades together. Pull both hands down and



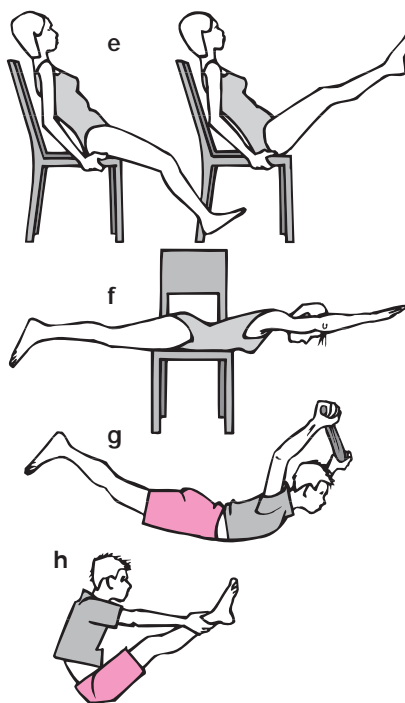
back, and sit upright again.

3 Stand erect, and hold your head up as you contract your abdomen and buttocks.

Strengthening routines (continued)

e Begin as for routine d, sitting at the front of a chair and gripping the sides with your hands (see opposite). Then lift your legs while keeping them straight. Hold them in this position as long as you can, then lower them steadily. Rest for a few seconds and repeat, but avoid too much strain or fatigue.

f Lie with your lower abdomen and hips over a chair as shown. Raise your head, arms, and legs as far as you can so that your whole body comes into a straight line. As above, hold yourself in this position for as long as



you can, then lower your arms and legs steadily and rest for a few seconds.

g Lie face down with your arms stretched to the sides, holding a towel on the ground in front of your head. Raise your legs and arms simultaneously so that the towel lifts above your head, then lower them again, taking about three seconds for the whole movement.

h Sit on the floor with your weight balanced over your buttocks. Raise your legs and try to hold your ankles as shown. Eventually you should be able to hold this position for several seconds.

The chest (thorax) and abdomen form the main part of the body, the torso. The division between chest and abdomen is usually identified as the diaphragm, the dome-shaped muscle below the lungs, whose movements provide the main power for respiration (breathing). The vertebral column in the back provides the major support structure for both divisions. However, the chest has numerous bones, while the abdomen has very few.

Above the diaphragm, the chest is bounded by the clavicles (collar bones) at its highest point, the thoracic vertebrae at the back, the ribs around the sides or laterally, and the sternum (breastbone) at the front. The abdomen has relatively fewer skeletal elements—only the lumbar vertebrae at the back, and the bony bowl of the pelvis (hip bone) below, to support and cradle its contents. Most of the support for the abdominal contents comes from large sheets of muscle and connective tissue (fasciae) that wrap around its sides and front, and maintain tone.

Contents and functions

The chest and abdomen have distinctly different contents and functions. The chest contains the major parts of the respiratory and circulatory systems, being the bronchi (main airways) and lungs, and the heart and great blood vessels. In addition, the muscular tube of the esophagus (gullet) passes through the chest, carrying swallowed food from the mouth down to the stomach. The abdomen contains the major organs of digestion (stomach, intestines, liver, pancreas), excretion (kidneys, ureters, urinary bladder), and reproduction (chiefly in the female, being the ovaries, uterine tubes, and uterus). Together these abdominal organs are referred to as the viscera.

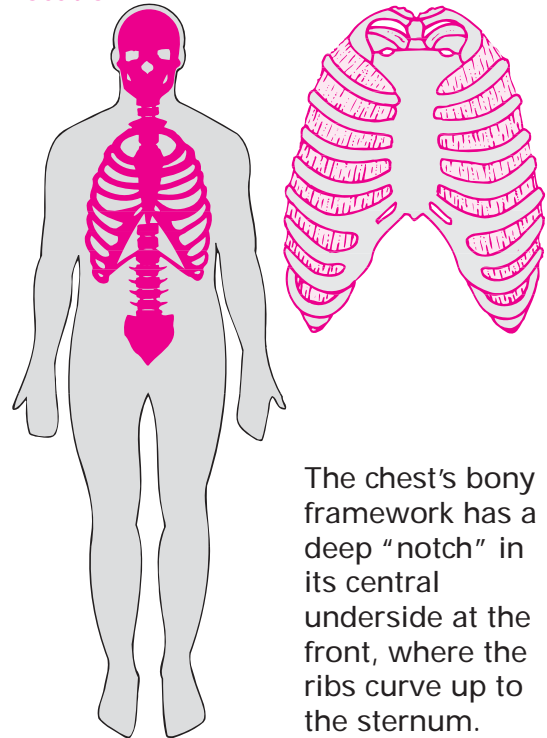
Variable ribs

- There is no truth in the old tale that men have a different number of ribs than women.
- Both sexes have 24 ribs.
- However, about one person in 20 naturally has one pair of ribs extra or missing.

Chest and axial skeleton

The chest forms the central section of the axial skeleton, between the cervical (neck) region of the vertebral column above, and the lumbar (lower back) region below.

Location



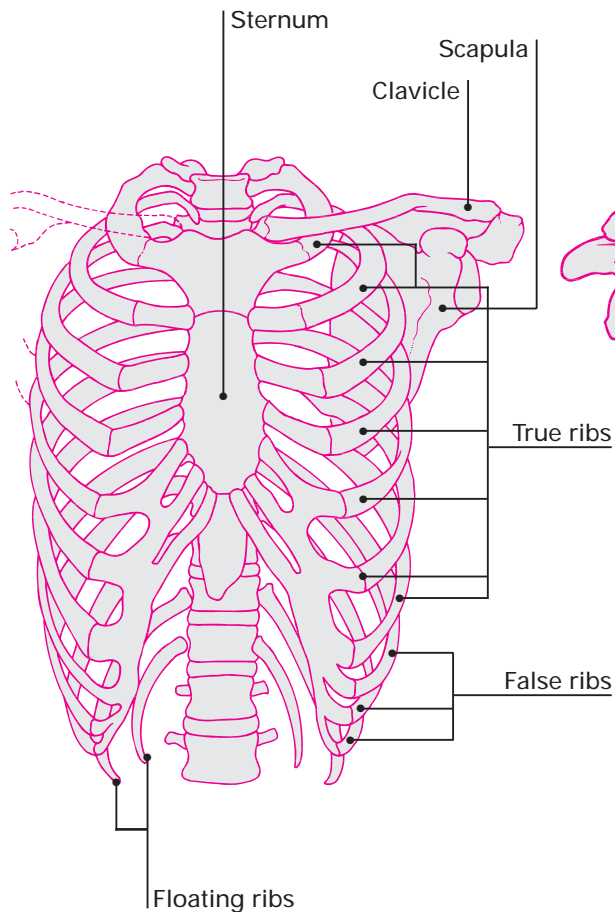
The chest's bony framework has a deep "notch" in its central underside at the front, where the ribs curve up to the sternum.

Bones of the chest

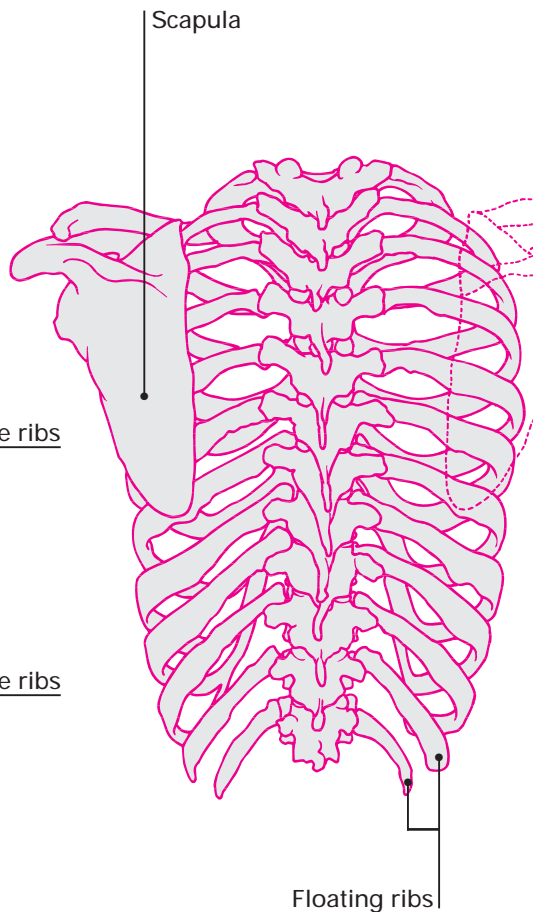
The chest has 41 bony elements. There are 12 thoracic vertebrae, with one pair of ribs joined to each, the sternum, and a clavicle and scapula (shoulder blade) on each upper side. The first seven pairs of ribs are true ribs, linking to the

sternum by costal cartilages. Rib pairs eight to 10 are false ribs, linking by extended costal cartilages to the true ribs above. Pairs 11 and 12 are floating, with no anterior fixing; their forward ends are within the chest musculature.

Anterior view



Posterior view



The chest has a complex musculature fulfilling several functions. A vital function is to drive the movements of respiration (breathing), whereby the rib cage expands in volume to stretch the lungs and draw in air. Also the chest muscles support the torso, and include muscles linking to the neck and head above, and the abdomen below, in order to maintain body posture and balance. In addition, the

chest region provides anchorage for the upper limb girdle or shoulder muscles that operate the upper arm. Most of these muscles are flattened and shaped like straps or elongated triangles. The scapula and clavicle act as fixing points for numerous superficial muscles that join to the neck, ribs, vertebrae, and humerus (upper arm bone). Respiratory muscles tend to be deeper.

Anterior chest wall

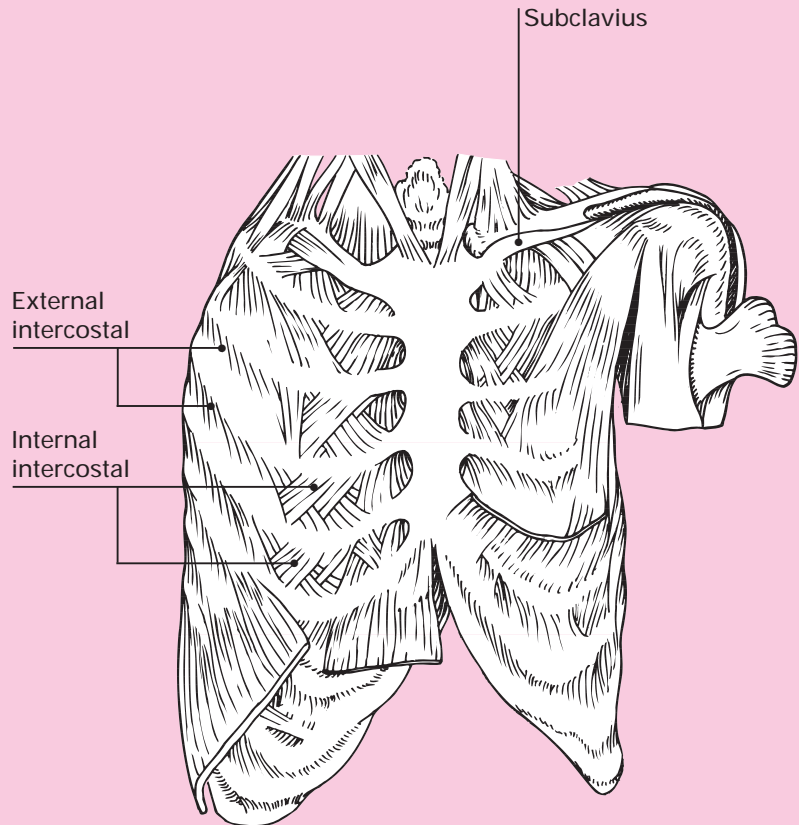
Larger shoulder muscles overlie the intercostals, which are long, narrow muscles running between each pair of ribs. The intercostals are important in respiration (see opposite).

Naming chest muscles

- Many chest muscles are named from the bones they link.
- For example, the subclavius runs along under the clavicle (collar bone).
- The intercostals run between the ribs, which are also known as the costae.

Breathing out: no muscles

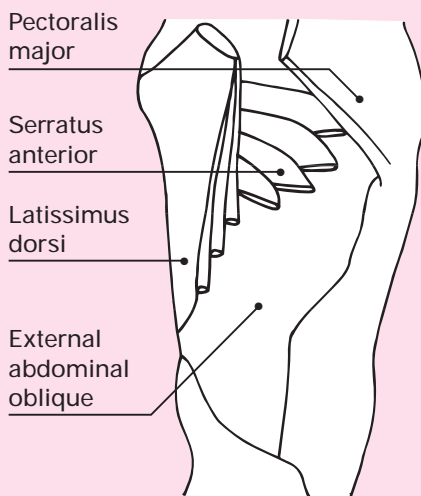
- Expiration occurs mainly by the natural elastic recoil of the lungs, which returns them to their pre-inhalation size.



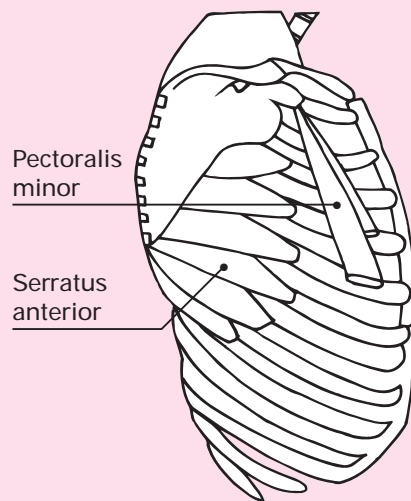
Chest muscles

The external intercostal muscles contract to make the ribs swing outward and upward in a tilting or “bucket-handle” motion. Coupled with diaphragm contraction (see below), this forcefully enlarges the volume of the thoracic cavity and causes air to flow into the lungs, during inspiration.

Lateral view: superficial muscles



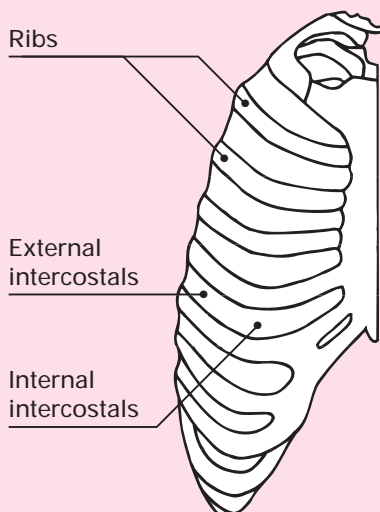
Lateral view: deep muscles



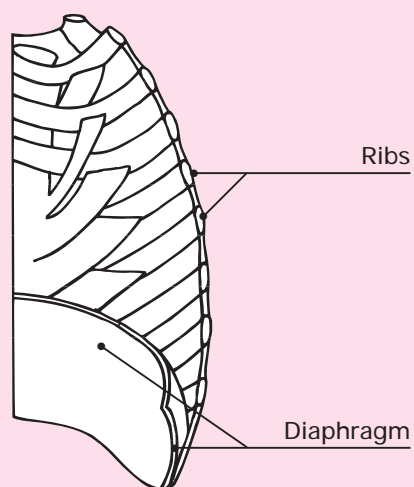
Chest interior

The dome-shaped diaphragm sheet of muscle at the base of the chest contracts and becomes flatter, pulling down the lung bases and increasing their size for inspiration. The internal intercostals contract to pull the ribs down and inward during forced expiration as when inflating a balloon.

Anterior view: intercostal muscles



Posterior view: anterior chest wall



The abdominal muscles consist chiefly of large sheets of muscle tissue wrapping around the sides and front of the viscera. They are attached to the vertebral muscle column at the rear, the lower ribs above, and the flanges of the pelvis below. Most of these muscles are named from their fiber direction: transversus (horizontal), rectus (vertical), or oblique (diagonal).

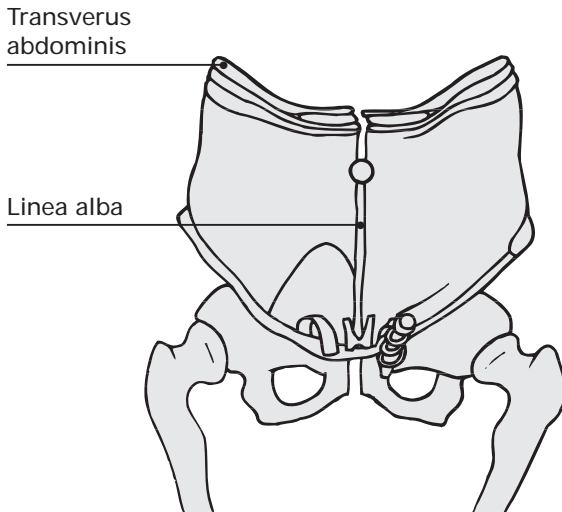
White line

- The linea alba or “white line” is a cordlike tendon running from the base of the sternum, down the front center of the abdomen, to the upper middle joint (pubic symphysis) of the pelvis or hip bone.

Deeper abdominal muscles

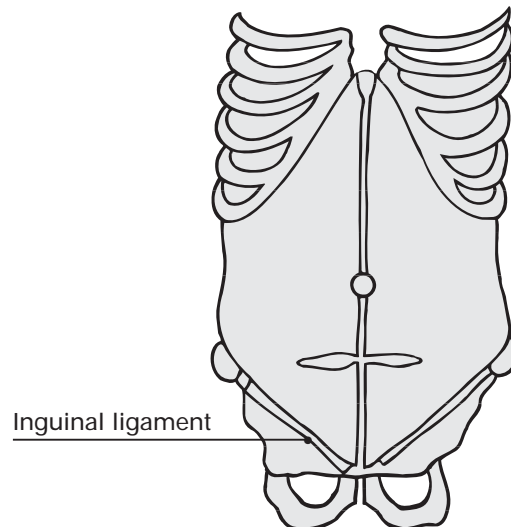
The transversus abdominis is the major muscle sheet running horizontally around the abdomen. Its paired sections join centrally at the linea alba.

Anterior view: transversus abdominis



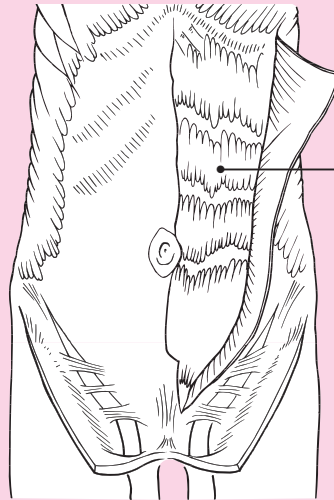
The inguinal or groin region contains a number of muscle borders and edges, with fibrous connections to each other and to ligaments.

Anterior view: inguinal region



Outer abdominal wall

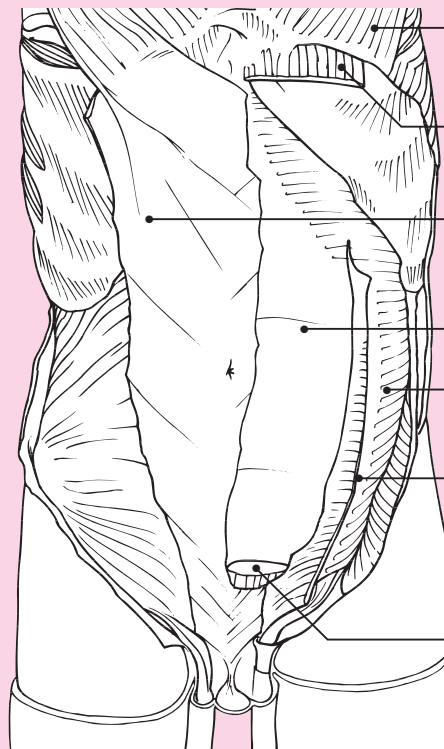
In the process of dissection, this view precedes that shown below. Here the rectus abdominis is still in place. All these sheets of abdominal muscles not only retain the viscera; they can also be tensed to form a boardlike barrier that protects the soft inner organs, in case of a knock or blow.



Rectus abdominis

Inner abdominal wall

In this view the large vertical muscle straps on either side of the midline, called the rectus abdominis, have been removed to reveal the inner musculature. The external rectal sheath, or covering, of the left rectus abdominis has been folded over to the right to aid the exposure.



Pectoralis major

Rectus abdominis
(upper cut end)Anterior layer of
rectus sheathPosterior layer
of rectus sheath

Transversus abdominis

Internal abdominal oblique

Rectus abdominis
(lower cut end)

Isometric exercises are aimed at building muscle strength and tone. They take up little time—just six seconds exerting maximum muscle force for one exercise or routine, and 90 seconds for 15 exercises covering the whole body. Moreover they require no special

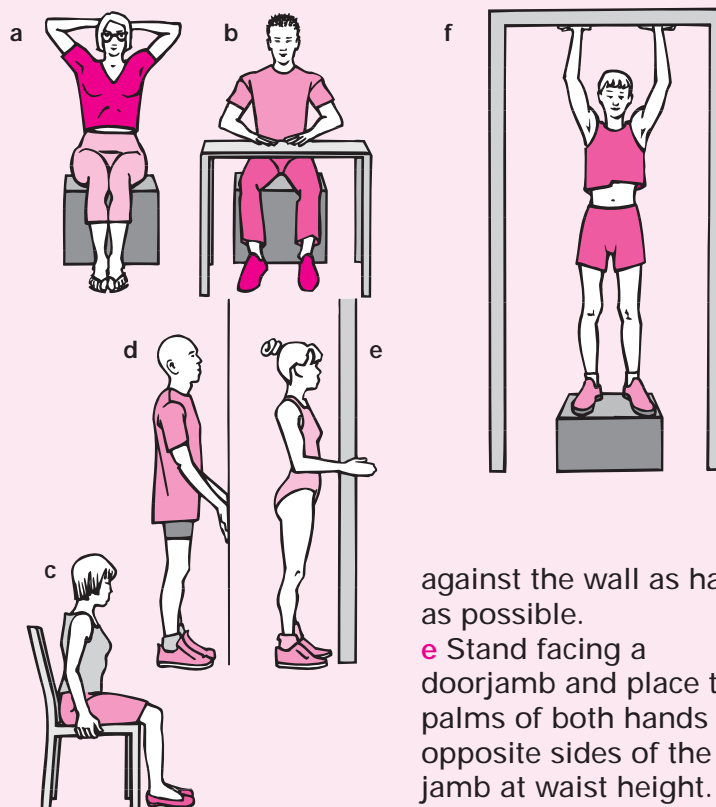equipment. They can be useful for adding tone to sagging chest and abdominal muscles, and improving back posture and upper-body strength. But they leave the heart-lung system unexercised and so should be carried out alongside strenuous mobility routines.

Chest and upper-body exercises

Here are some exercises for the upper body, including the chest and shoulders. Since these are isometric exercises and use all potential muscle strength, instead of the 20–30 percent customarily exerted, they have significant effects on muscles. To avoid strains or other trouble, limit each exercise to six seconds and perform it only once a day.

a Interlock the fingers of both hands behind your head. Push your hands forward and head back. Repeat with interlocked fingers pressed back against your forehead as you try to force your head forward.

b Sit at a table or flat-topped desk and press your hands down upon its surface, with your fingers spread wide apart. You can repeat this while standing.



c Sitting on a chair without arms, grip the sides of the seat and try to pull it upward.

d Stand near a wall, facing it with your arms straight down and the palms of your hands toward the wall. Press your hands

against the wall as hard as possible.

e Stand facing a doorjamb and place the palms of both hands on opposite sides of the jamb at waist height. Press your hands hard toward each other. Relax and repeat at chest level, then at eye level.

f Stand in a doorway and raise your arms to press the palms of your hands hard against the top of the door frame. You may need to stand on a box.

Shoulder and trunk routines

Like the exercises shown opposite, these routines are isometric. This means the muscles do not change in length, even though they exert considerable force. In general isometrics, one group of muscles exerts pressure against an immovable object or an opposing group of muscles. Due to the forces exerted, the positions should be held for a maximum of only six seconds, once each day.

a Sit with your legs apart and your hands on your knees. With your hands, try to push your knees together; resist the pressure with your legs.

b Sit with your legs apart and your hands crossed as shown. Try to push your knees apart by hand as you resist the pressure with your legs.

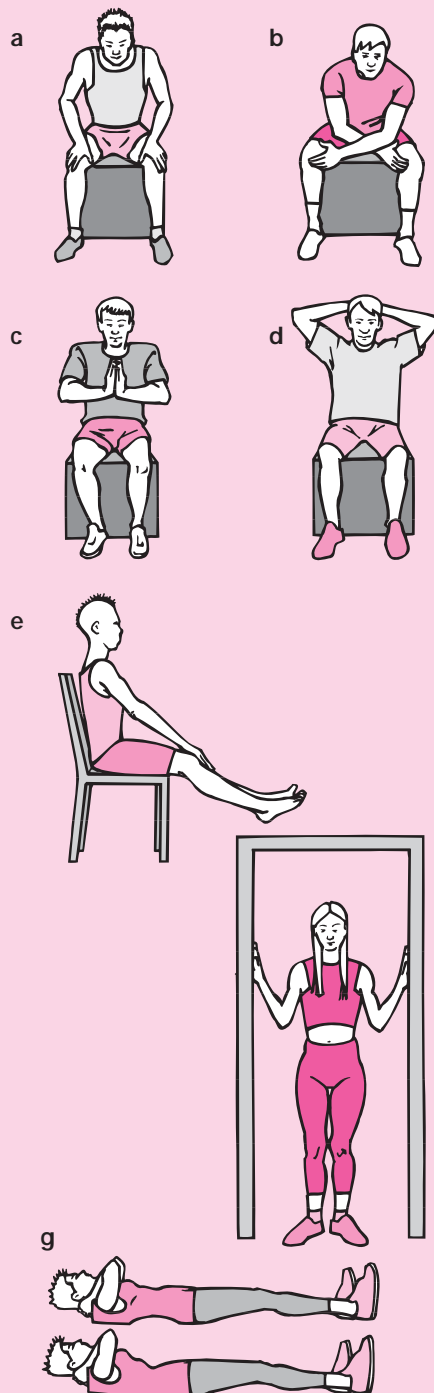
c Place the palms of your hands together and push them against each other with shoulder and arm muscles; also feel your chest muscles tense.

d Clasp your hands behind your head. Keep your fingers gripping, but try to pull apart your hands using your upper body muscles.

e Sit well back in a chair with your legs raised and your hands on your shins. Press downward with your hands and upward with your legs, feeling your abdominal muscles contract.

f Stand in a doorway with your hands resting on the inside of the door frame. Push against the frame.

g Lie on your back with your hands under your head, and press your abdomen downward as hard as possible.



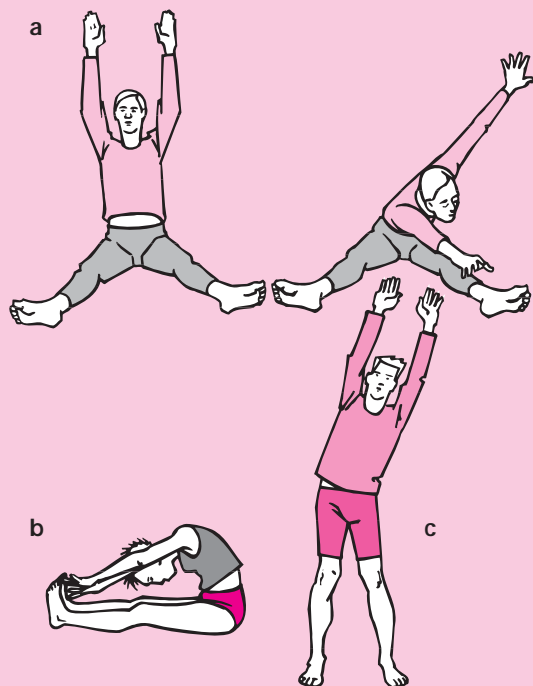
Waist and trunk flexibility

Movements of the torso and waist depend largely on the action of lower vertebral and abdominal muscles. These exercises should improve the mobility of your waist and trunk.

a Sit on the ground with your legs apart. Put your hands over your head as shown, and then lean your trunk forward to try and touch each foot in turn with the opposite hand.

b Sit with your legs stretched out in front of you, then lean forward and try to put your head on your knees. This will be impossible at first, but you will gradually improve suppleness over the weeks.

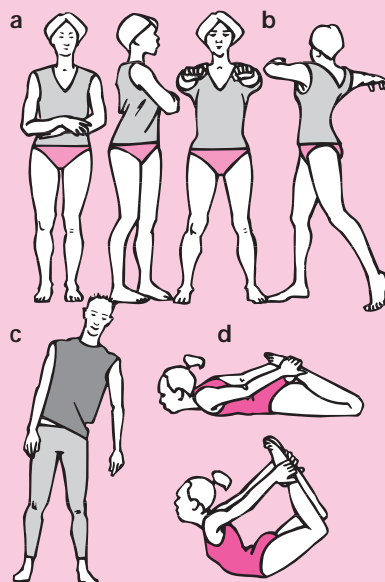
c Stand with your legs apart and your arms over your head. Bend as far as possible to one side, then the other.



Strengthening waist and trunk

a Stand facing forward with your arms loosely crossed. Twist your trunk to one side then the other, as far as possible each time. Keep your feet flat on the floor. Over several days you should be able to twist farther each time.

b Stand with your arms stretched out to the front and feet apart. Swing your arms around as far as possible, to the left and then the right.



c Stand upright with your legs slightly apart and your arms hanging loosely by your side. Bend as far as possible to each side, using mainly your waist and lower back area, keeping your head as level as possible.

d Lie on your front with knees bent and feet in the air. Try to clasp your ankles and raise your thighs. This may be awkward at first, but as with the other exercises, your suppleness and strength should improve.

Isotonic exercises for the upper body, chest, and abdomen

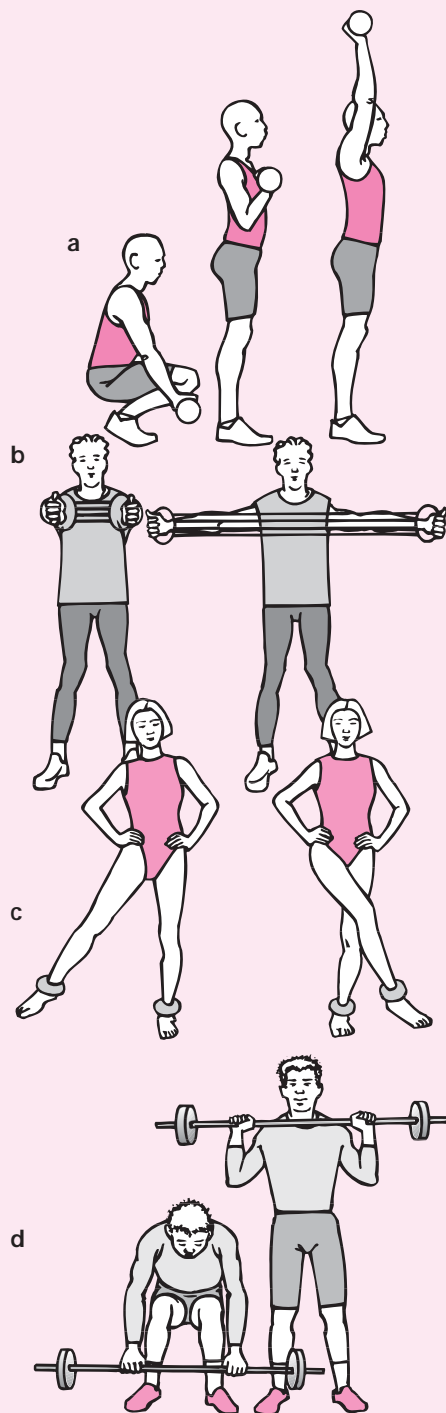
In contrast to isometric exercises, isotonic exercises produce movement at the joints, and contracting muscles shorten in length.

a Crouch with a dumbbell in each hand, knuckles uppermost, keeping your back straight. Then stand up, bending your arms and lifting the dumbbells to shoulder height. Next, thrust the dumbbells to arm's length above the head. Such exercises help strengthen chest, arm, and shoulder muscles.

b With both hands grip an expander in front of you at arm's length and shoulder level. Keeping both arms straight, pull them out and back until the expander touches your chest. This helps to strengthen chest and upper abdominal muscles.

c Using weighted boots or ankle weights, stand on your left foot with your hands on your hips and stretch your right leg to the side as far as you can. Then bring the right leg across the body as far as you can. Repeat with the other leg.

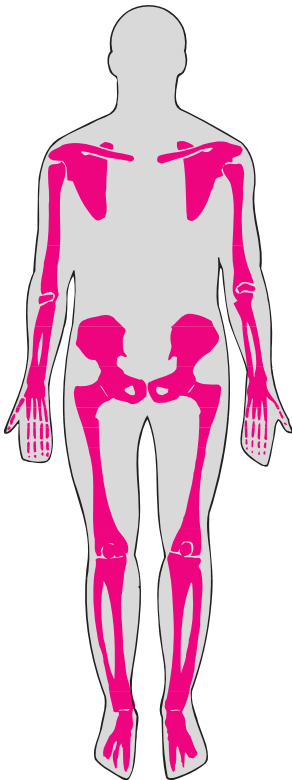
d Stand with your feet slightly apart under a barbell. Bend your knees and grasp the bar with both hands, knuckles uppermost; your hands should be just farther apart than your shoulders. Keeping your chest and head up and your back flat, breathe in and rise to a standing position, using mainly your knees, and pulling the bar up to touch your upper chest under your chin. Turn your hands to bring the palms up, and breathe out. This lifting exercise strengthens the trunk and whole body.



Each upper limb consists of 32 bones, including the scapula and clavicle adjacent to each side of the upper rib cage, and more than 100 muscles. These muscles include those at the shoulder, which generally move the upper arm bone or humerus; those in the upper arm, which operate the elbow joint; and those in the forearm, which move the wrist and also the fingers.

The appendicular skeleton

The appendicular skeleton has 126 bones and consists of the limbs and their attachments.



Limb muscle names

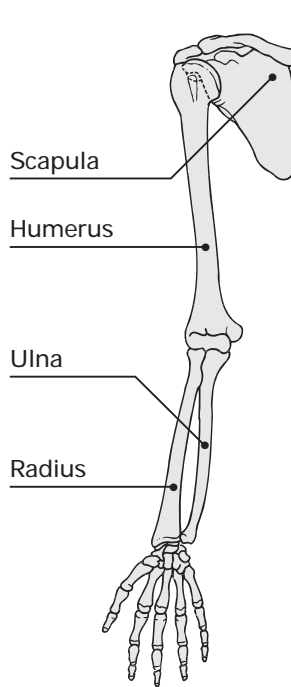
Terms used to describe the action of muscles may often become incorporated into the names of arm and leg muscles.

Dorsiflexor	Points the toes upward, flexing the foot at the ankle.
Evertor	Turns the sole of the foot outward.
Extensor	Increases the angle of a joint, as when straightening.
Flexor	Decreases the angle of a joint, as when bending.
Invertor	Turns the sole of the foot inward.
Plantar flexor	Points the toes downward, extending the foot at the ankle.
Pronator	Turns the palm downward.
Rotator	Moves or twists a bone around its longitudinal axis, as when twisting the leg to point the foot sideways.
Supinator	Turns the palm upward.
Tensor	Generally makes a body part stiffer or more rigid.

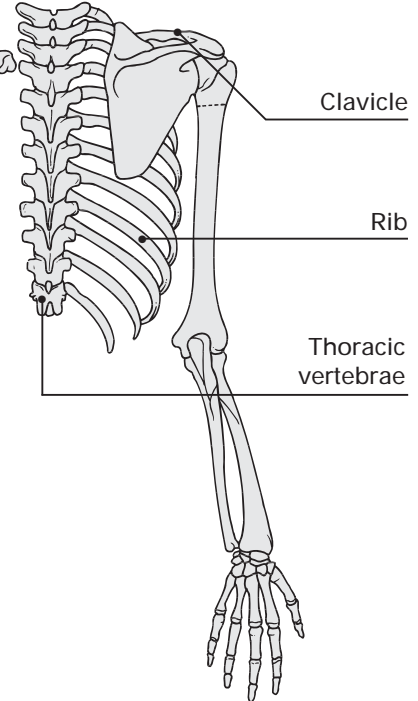
Upper limb bones

The skeleton of the upper limb is analogous to that of the lower limb. There is one major long bone next to the torso (upper arm/thigh); two long bones in the second limb section (forearm/calf); a group of small bones within a complex joint (wrist/ankle); and the same pattern of three sets of extremity bones (hand/foot). The arm is designed for mobility and manipulation, and can twist along its length and turn virtually a full circle.

Anterior view



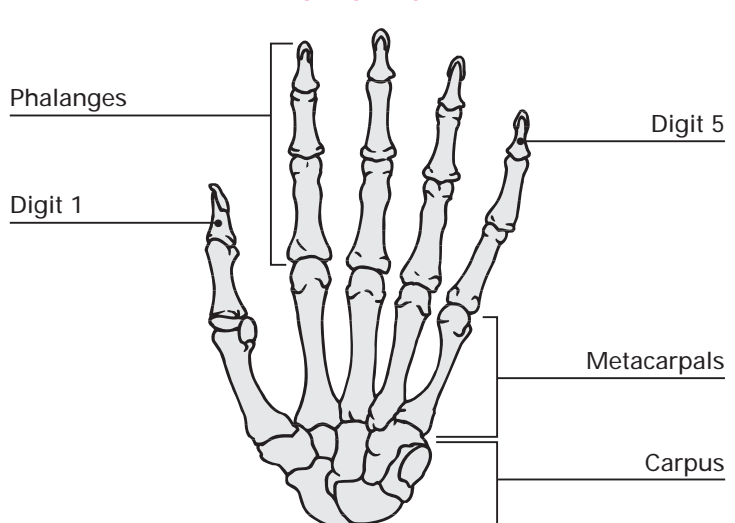
Posterior view



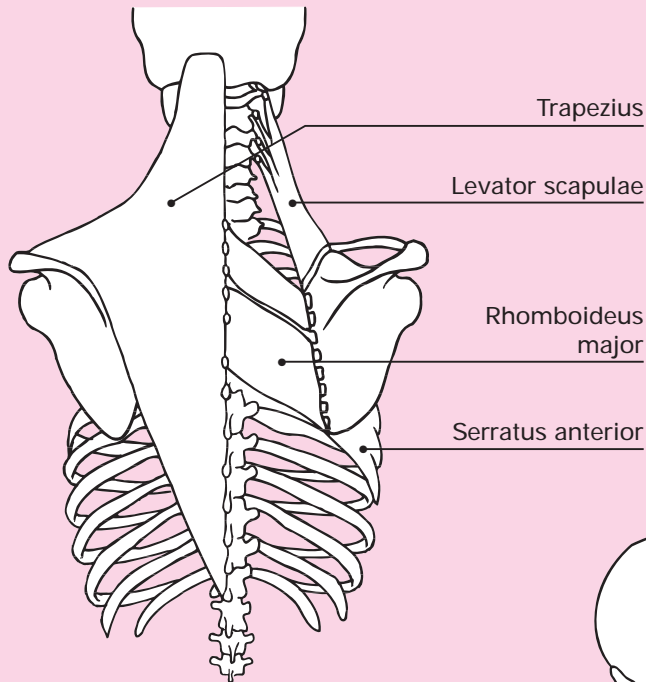
Skeleton of the hand

The carpus or wrist consists of eight small, mainly box-shaped, bones. Their joints are chiefly of the gliding type and have limited movements. The metacarpal bones are encased in muscle and flesh and form the palm of the hand. The finger bones are termed phalanges and numbered 1 to 5, from the innermost or thumb, to the little finger (pinky).

Palmar view



Posterior view: superficial and deep muscles

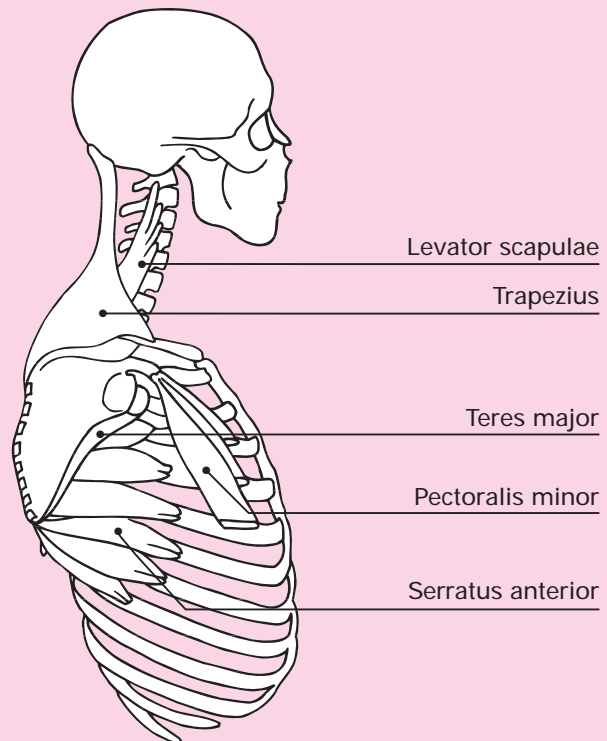


Very mobile

- The shoulder is the most flexible of all body joints.
- It has a wide range of abduction/adduction, when the arms are lifted out sideways.
- It also has a wide range of flexion/extension, forward and backward.
- It permits rotation, to twist the elbow and hand.

The shoulder joint

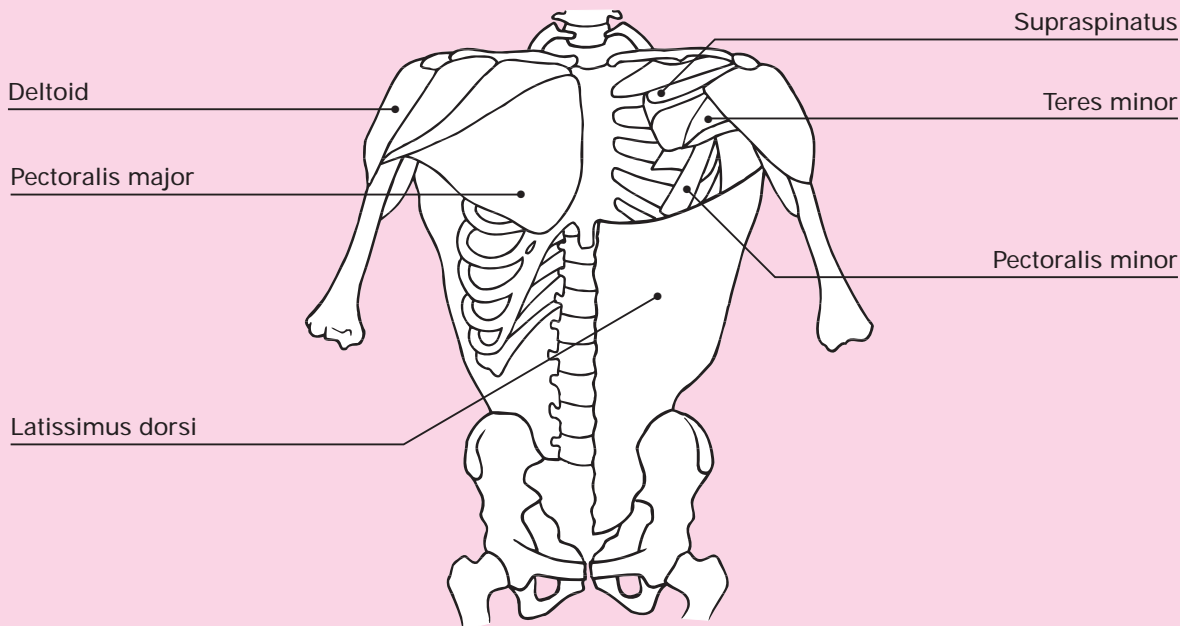
The shoulder is very supple or mobile. But this comes at the expense of stability. In mechanical design the shoulder is regarded as inherently unstable. It is maintained in position by its joint ligaments, and by the tendons of the muscles which wrap around it, especially those of the "SITS": supraspinatus, infraspinatus, teres minor, and subscapularis. These form its "rotator cuff."



Anterior view: dorsal muscles

Anterior view: superficial muscles

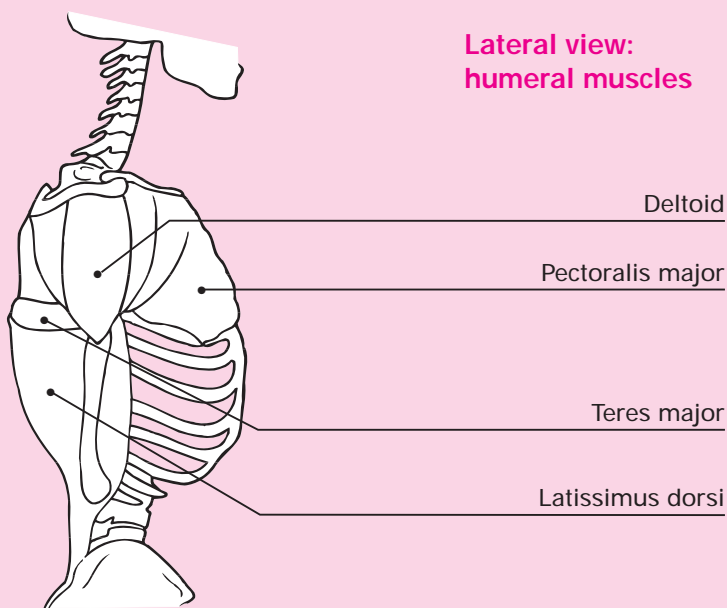
Anterior view: deep muscles



Upper arm muscles

Each of these muscles has several actions, depending on which part of it contracts most. For example, the deltoid can pull the arm into the body, or forward, or backward, or rotate the upper arm inward or outward. If most of the shoulder muscles are tensed to hold the arm steady, the latissimus dorsi acts to twist and pull the shoulder blade down and back.

Lateral view: humeral muscles



Upper arm muscles

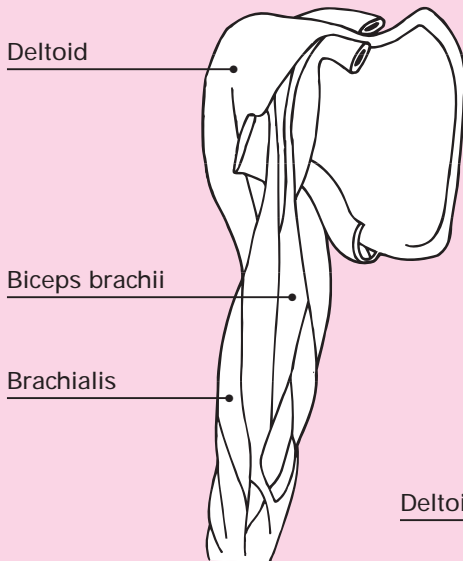
The upper arm muscles aid the shoulder muscles in movements there, but primarily they are responsible for motion at the elbow joint. This includes bending and straightening, and also twisting of the forearm bones.

Bend and twist

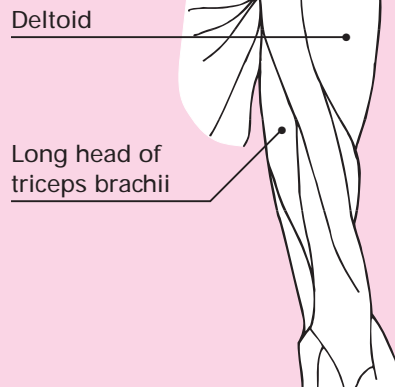
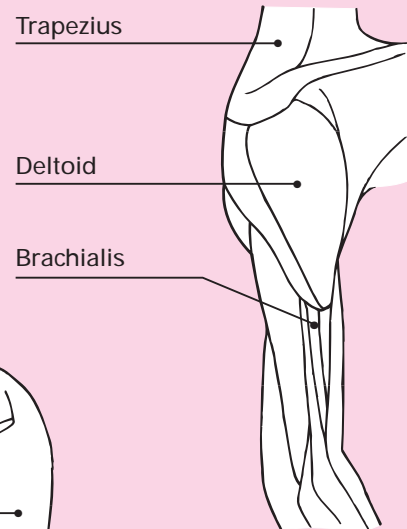
- One of the body's best-known muscles is the biceps brachii in the upper arm.
- In addition to flexing (bending) the elbow, the biceps brachii also supinates the forearm, causing the palm to rotate and face upward.

Upper arm muscles

Anterior view: upper arm muscles

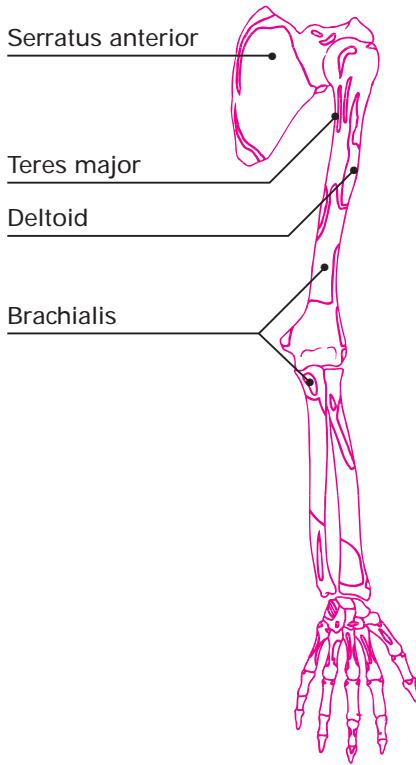


Lateral view: upper arm muscles



Posterior view: upper arm muscles

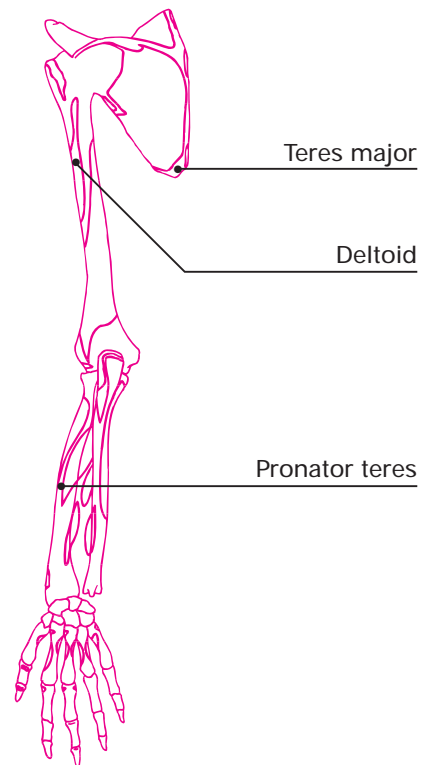
Anterior view



Muscle attachments

Where muscles attach to bones via their tendons, the bone surface is rough and pitted. Only selected arm muscle attachments are labelled here.

Posterior view

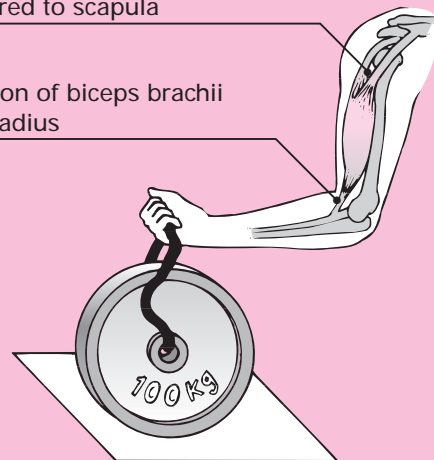


Mechanical advantage

Many muscles, especially in the limbs, show mechanical advantage. This is a property of levers. The insertion of the muscle is near the pivot or fulcrum—the joint which the muscle operates. When the muscle contracts only a small amount, the end of the bone near the joint moves a correspondingly small amount. But the other end of the bone, which is acting as a lever, is moved much farther. In this way the biceps brachii can contract by the length of a thumb, yet move the hand through an arc as long as the arm itself.

Two heads of biceps brachii anchored to scapula

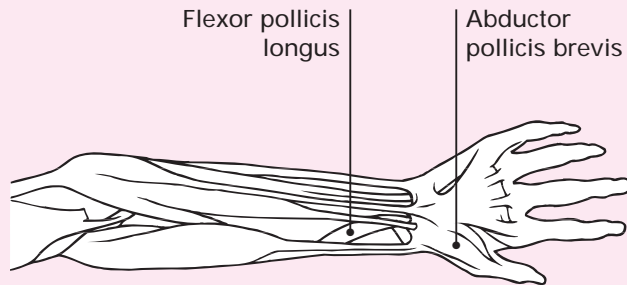
Insertion of biceps brachii onto radius



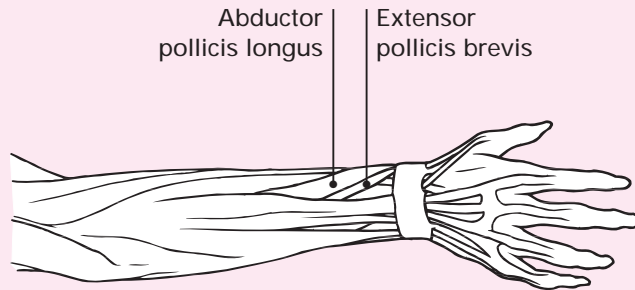
Forearm muscles

Most forearm muscles have long tendons through the wrist to the fingers. "Pollicis" refers to the thumb.

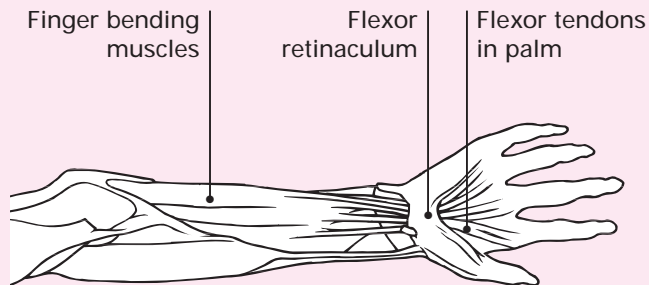
Right forearm: superficial flexors



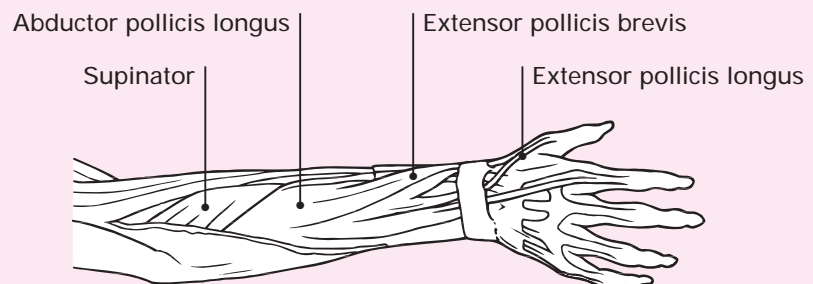
Right forearm: superficial extensors

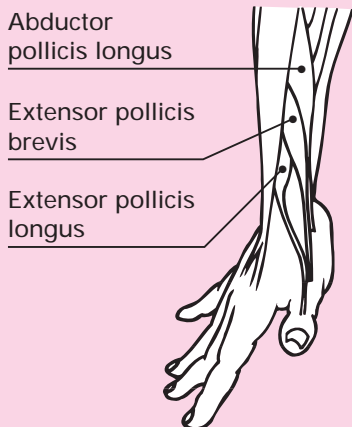


Right forearm: deep flexors

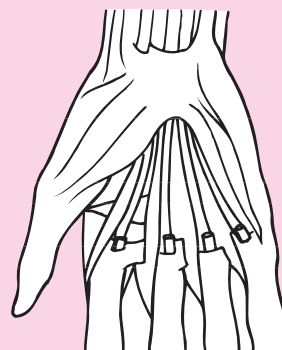


Right forearm: deep extensors



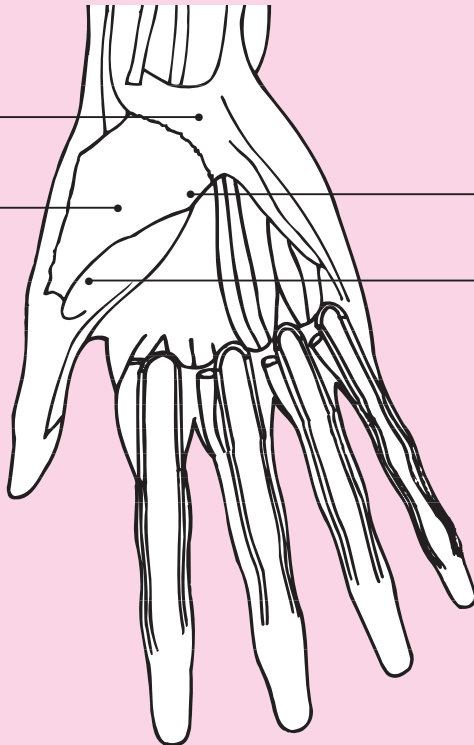
Lateral view: muscles acting on the thumb**Hand muscles**

The thumb (pollex) alone is moved by more than a dozen muscles, short (brevis) and long (longus). Many hand muscles come together to form broad, flat, fibrous sheets known as aponeuroses, which transmit the pulls of these various muscles into other directions.

Superficial flexors of the palm**First digit (thumb) muscles**

Flexor retinaculum

Opponens pollicis



Flexor pollicis brevis

Superficial head

Deep head

The complex interplay of joints, muscles, and tendons in the arm and hand make them capable of a wide variety of movement. The shoulder swivels and moves in almost all directions; the upper arm and forearm act as long levers; the wrist has about 20 joints between its eight small carpal bones; and the many joints in the hand allow the brain to control very complicated maneuvers. The arm is also strong—the biceps brachii and triceps

muscles in the upper arm are large and powerful, and additional strength for lifting comes from the shoulder muscles. Since the arms and hands are used constantly, from pushing back the bedding in the morning to switching off the light at night, problems such as injury or illness can cause great inconvenience as well as discomfort. Here we look at ways of preventing or minimizing some common arm and hand problems.

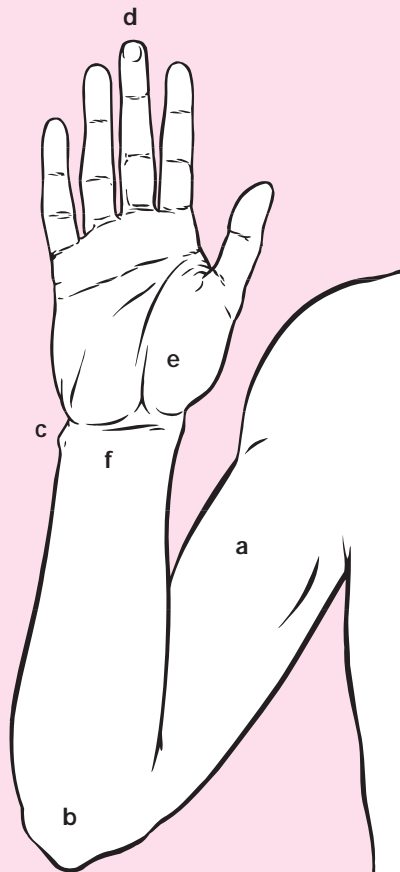
Common arm and hand problems

a Rupture of the biceps.

This problem can occur at any age, but may be seen particularly in middle-aged men who tend to strain flabby muscles by lifting or pulling heavy objects.

b Tennis elbow. Any repeated twisting or rotary forearm action combined with a strong handgrip may lead to this pain on the outer side of the elbow. It occurs not only in tennis but when holding an item tightly in the hand. Despite its name, it is not a problem of the elbow joint itself. Rest, massage, and immobilization of the forearm may ease the condition.

c Ganglion of the wrist. This saclike swelling encloses fluid around a tendon. A doctor may try to burst the ganglion by



pressing hard on it but, if left alone, the swelling often disappears spontaneously.

d Mallet finger is an injury often caused by a hard blow to the fingertip. It is due to hard scar and fibrous tissue building up in the end of the finger. It may reduce the fingertip skin's delicate sense of touch and so lead to more accidental blows.

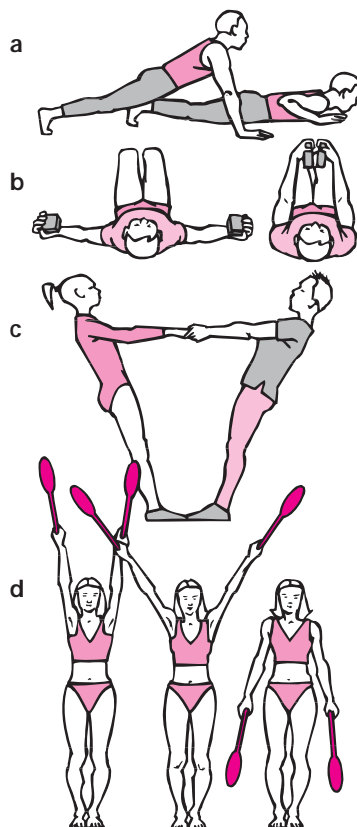
e Repeated stress injuries (RSIs) can occur in almost any part of the arm, wrist, hand, or fingers, due to repetitive work such as computer keyboarding or screwdriver use. They may affect the muscles, joints, or tendon sheaths. Preventative measures include regular breaks and shifts in position and posture.

f Carpal tunnel syndrome (see opposite).

Arm and hand exercises

a Balance your body weight on your hands and toes in the push-up position. Keeping your back straight, lower your body by bending your elbows. Try to allow your chin to touch the floor. Straighten your arms to return to the original position, pushing up with your fingers as you do so. This is a strenuous routine, but regular sessions soon show improvement.

b Lie on your back with your knees bent up, clasp a heavy object such as a book in each hand. Keeping your arms straight, slowly raise the objects to bring them together, then steadily lower them again.



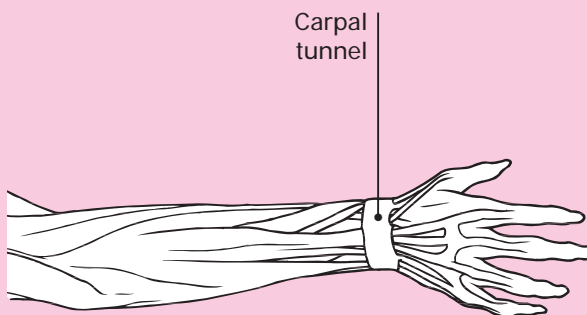
Ensure you keep a firm grip on the objects throughout.

c Stand facing a partner with your feet touching each other's. Hold hands, then both lean back, keeping your backs straight and your fingers firmly clasped. Try to extend your arms fully, then bend them again to become upright once more.

d Hold long heavy objects such as clubs, books, or rolled magazines. Stand with your arms raised, lower them out to the sides while keeping them straight, until your arms are by your sides. Then reverse the movement to raise the objects again, all the while keeping a firm grip on the objects.

The "carpal tunnel"

The long tendons from the forearm muscles gather together with blood vessels and nerves, to pass through the "carpal tunnel" in the wrist. This is a sheath of connective tissue that wraps around the wrist like a watchstrap. Repeated stress in this area may cause the sliding tendon coverings to swell and press on the nerves, causing irritation, aches, shooting pains, and loss of feeling or movement due to the nerve inflammation.



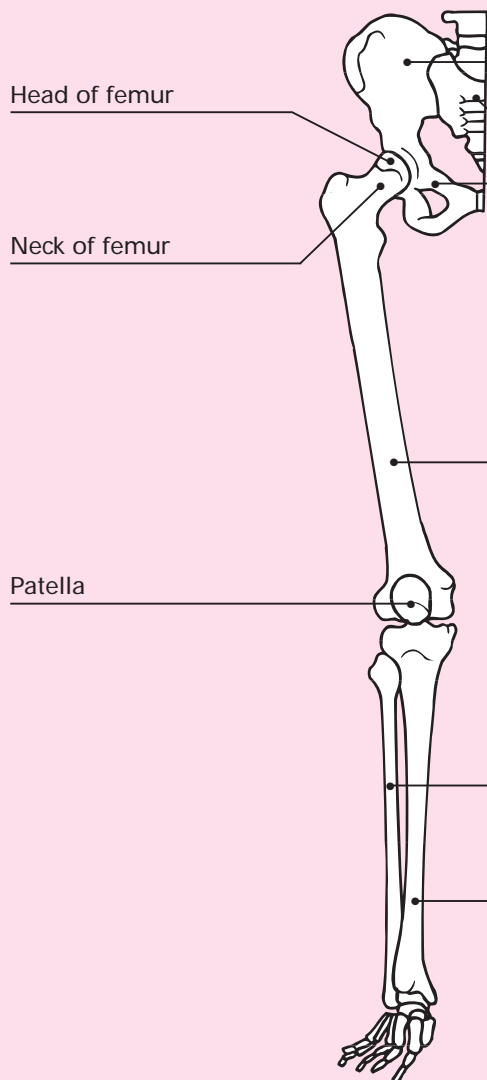
The lower limbs extend from the hip bone or pelvis, which flanks the sacrum. Fitted into a socket in the pelvis, the acetabulum, is each femur (thigh bone), below which is the tibia (shin bone) and fibula. This leads to the seven bones of the tarsus or ankle and 19 foot bones: tarsals, metatarsals, and phalanges.

Bones of the lower limbs

Calcaneus The largest bone in the foot, forming the heel. The Achilles tendon is attached to it. It helps support the talus.

Cuneiform bones Three tarsal bones that form the cross-arch of each foot (see page 78).

Anterior view of hip and leg bones



Head of femur

Neck of femur

Patella

Ilium

Sacrum

Pubic bone

Neck of femur

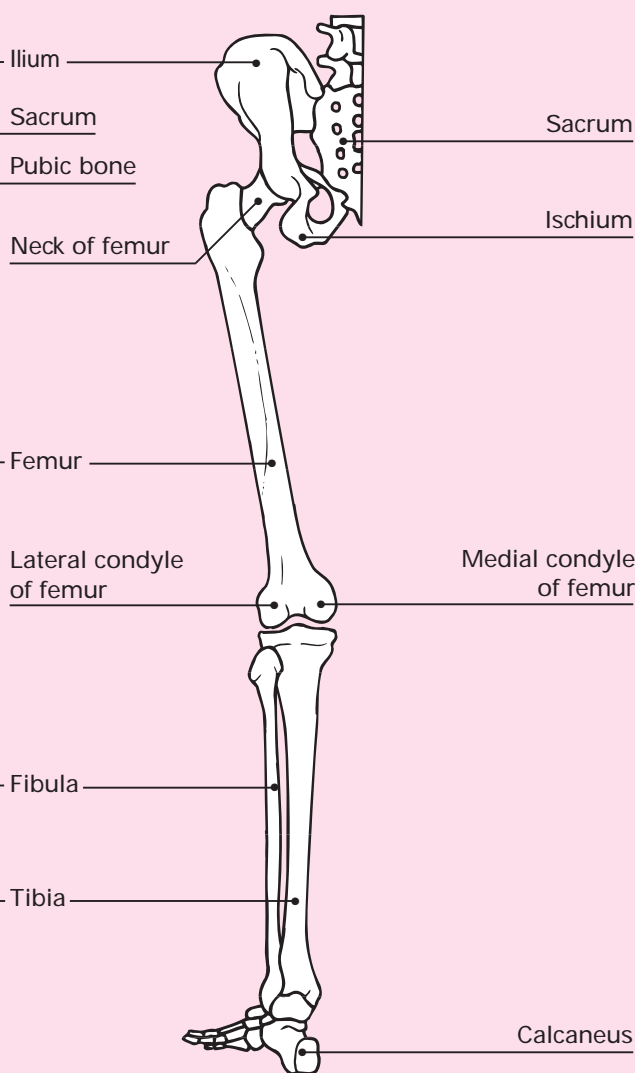
Femur

Lateral condyle of femur

Fibula

Tibia

Posterior view of hip and leg bones



Sacrum

Ischium

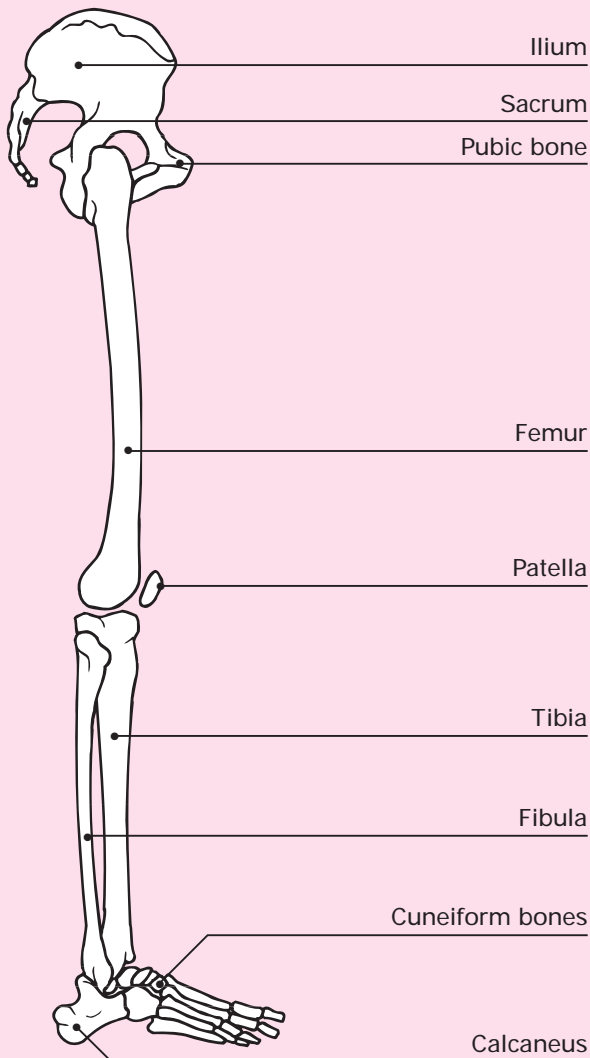
Medial condyle of femur

Calcaneus

Femur The thigh bone, the longest bone in the body, is situated between the hip and knee. It articulates with the tibia and in a typical adult forms one-quarter of the body's height. Its lower end bears two knuckle-like condyles that articulate with shallow hollows in the tibia's upper surface, to form the knee joint.

Fibula The lateral (little toe side) bone of the lower leg, sometimes referred to as the calf

Lateral view of hip and leg bones



bone. It has projections on the lateral (outer) side of the ankle to which muscles of the foot are attached, and which forms the lateral prominence of the ankle itself. At its upper end it does not take part in the knee joint.

Metatarsal bones Five bones in the foot, forming the main part of the foot inside the sole area (see page 78).

Patella The kneecap bone, on the front of the knee joint.

Phalanges The toe bones. There are 14 in each foot—two in each big toe, and three in each of the other toes (see page 78).

Talus One of the ankle or tarsal bones, forming the link between the tibia above and the other tarsal bones below (see page 78).

Tarsus The seven tarsal bones of the ankle joint (see page 78).

Tibia The medial (big toe side) bone of the lower leg, sometimes referred to as the shin bone. It is the main weight-bearing bone of the lower limb. Its projection on the medial (inner) side of the ankle forms the prominence of the ankle itself on that side.

The patella

The kneecap bone, or patella, is unusual in that it is not joined or linked to any other bone of the skeleton. It is the largest of the body's sesamoid bones. It is set within the main tendon of the front thigh muscles, the quadriceps femoris, which extends down to the tibia and acts to straighten the knee. The patella has grooves on its inner (rear-facing surface) that slide around the epicondyles or "knuckles" at the base of the tibia, as the knee joint moves.

The muscles of the leg are in most respects analogous to those of the upper limb, as shown previously. The main bulk of the muscles that move the hip joint are located in the buttock area. The main bulk of the knee-bending muscles are in the thigh. The muscles

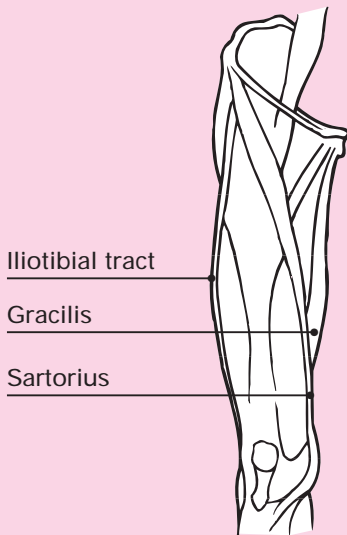
that operate the ankle, foot, and toes have their main bulk in the lower leg, the shin and calf. However, each of these sets of muscles can operate the joint above, rather than below it, if other muscles of the leg act to stabilize and steady the other joints.

Muscles of the leg

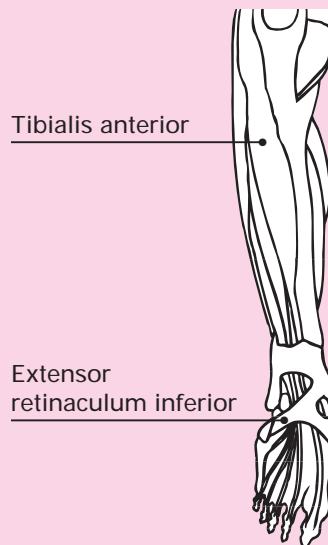
The major movements at the hip and knee are flexion and extension, straightening and bending as when running. The knee is primarily a hinge joint and is capable of little twisting or lateral motion. The hip is more mobile, allowing adduction and abduction (movements toward and away from the body's midline) as well as the leg's main rotation.

As in the wrist, the ankle has a straplike sheath of connective tissue, called the extensor retinaculum. It is Z-shaped, comprising superior, intermediate, and inferior sections. It holds the long tendons of the extensor muscles, at the front of the lower leg, against the ankle region (see also page 78).

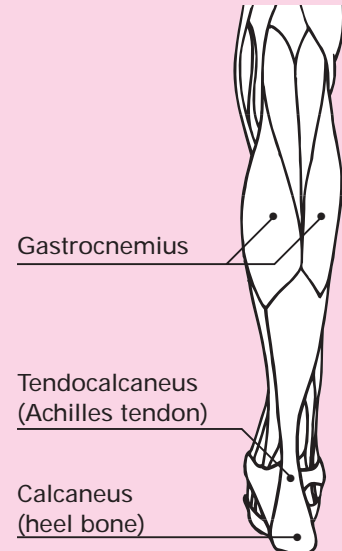
Anterior muscles: flexors of thigh



Anterior muscles: extensors of shin



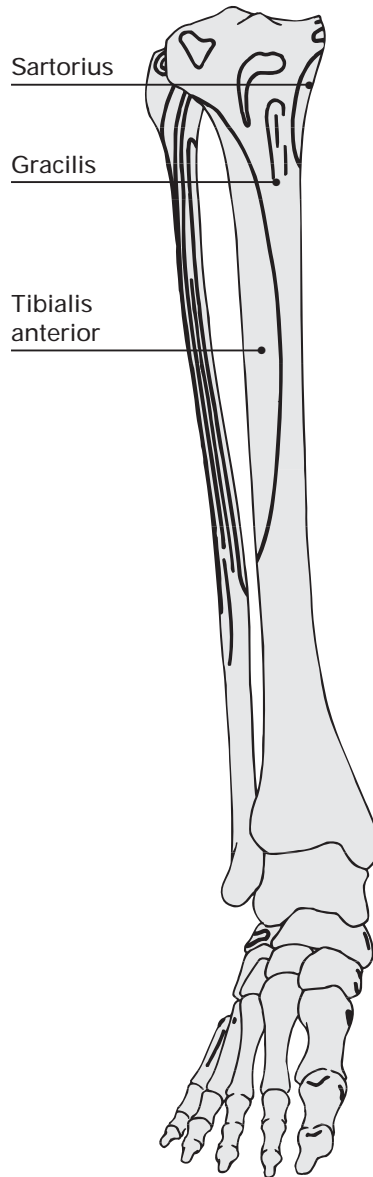
Posterior muscles: superficial layer of calf



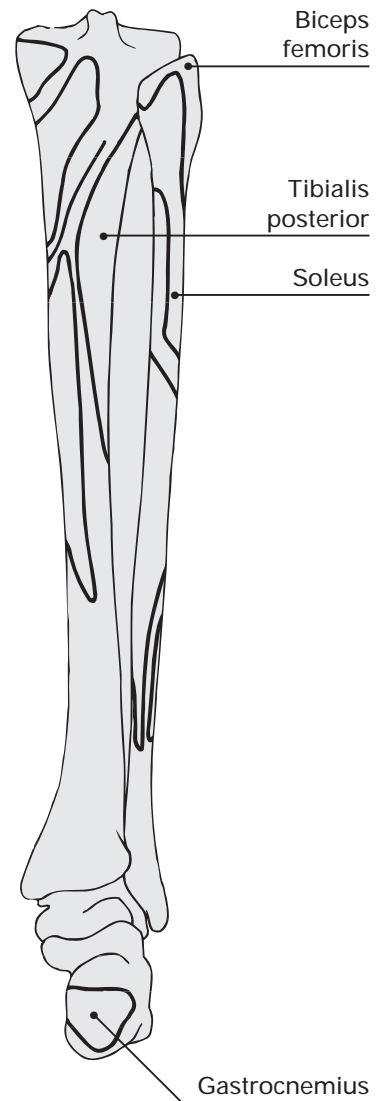Muscle attachments of the lower leg

The upper attachments include the insertions of muscles extending down from the thigh. Below these are the origins of muscles extending down through the ankle to the foot.

Anterior view: muscle attachments



Posterior view: muscle attachments



Strings and heels

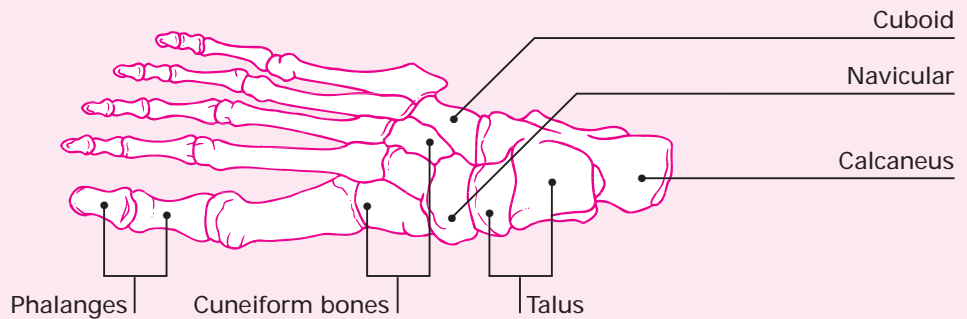
- The hamstring muscles at the rear of the thigh are the “BSS” flexor group: biceps femoris, semimembranosus, and semitendinosus.
- Their thick tendons are seen under the skin just above the knee, as the knee is flexed.
- The achilles tendon above the heel is the largest single tendon.

Bones of the foot

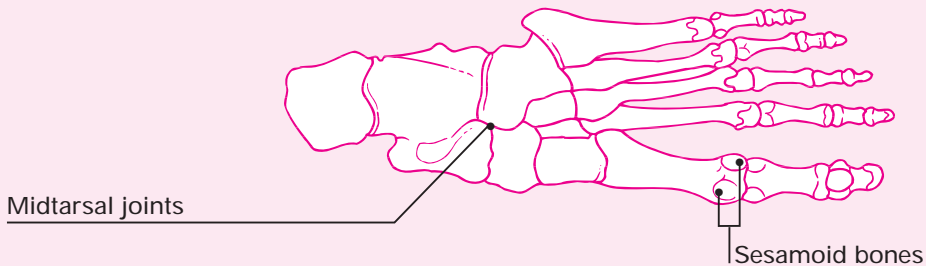
The ankle or tarsal bones are the talus (uppermost), calcaneus (lower at rear, forming the heel), cuboid, navicular, medial cuneiform, intermediate cuneiform, and lateral cuneiform. The

main sole or arch of the foot contains the five metatarsal bones. Each of the toes contains three phalanges, except for digit 1, the big toe, with two phalanges (as in the thumb).

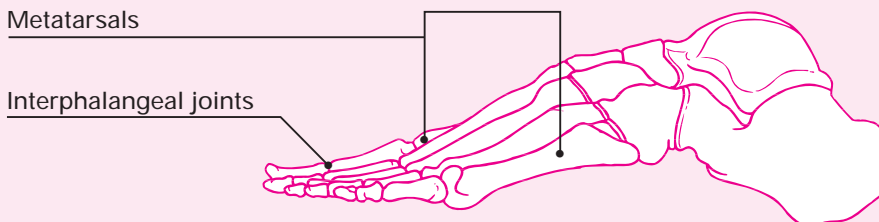
Right foot: dorsal view



Right foot: plantar view



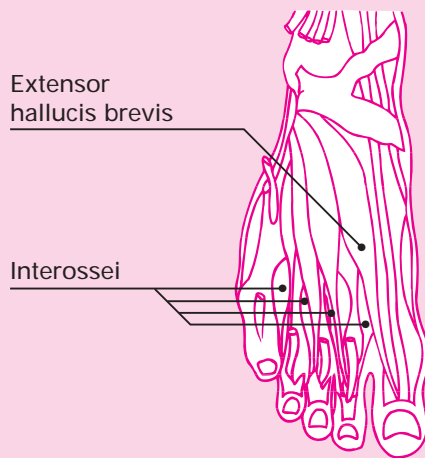
Left foot: lateral view



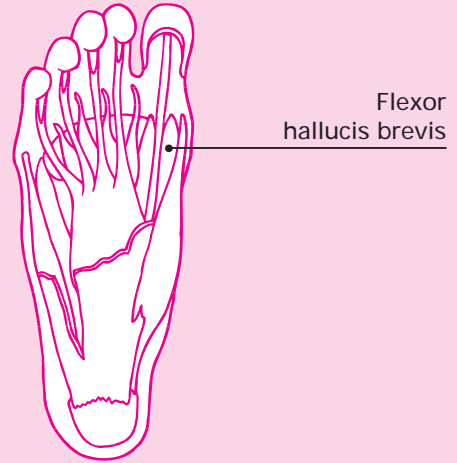
Muscles of the foot

The sole of the foot is known as the plantar surface, and the upper side as the dorsal surface. Strong ligaments, tendons, and further bands of connective tissue in the foot give it its naturally arched shape. This provides a degree of cushioning and springiness when walking and running.

Dorsal surface



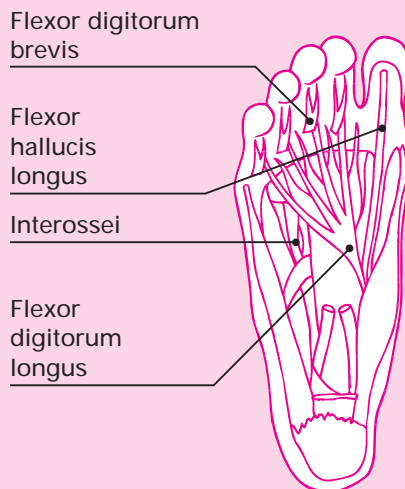
Plantar surface: superficial layer



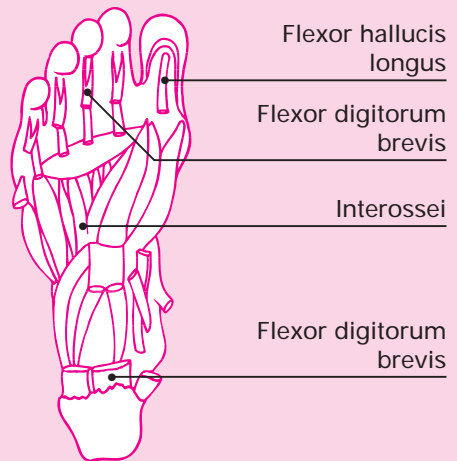
Foot muscle names

- As in the hand, *brevis* are shorter muscles, *longus* are longer ones.
- “Hallucis” refers to the big toe, which is known as the hallux.
- *Interossei* are small muscles spanning the phalanges in the interphalangeal (toe) joints.

Plantar surface: middle layer



Plantar surface: deep layer



Leg exercises

a Stand facing a firm step or low chair with your hands on your hips, then swiftly step up onto it; step down with the other leg.

b Run up and down a staircase quickly, until you feel out of breath.

c With a partner, sit on the floor and raise your legs so that your feet meet as shown. Push your legs away from you as your partner resists the pressure, then repeat with the roles reversed.

d Start from the same position as for c but this time move your right and left leg alternately.

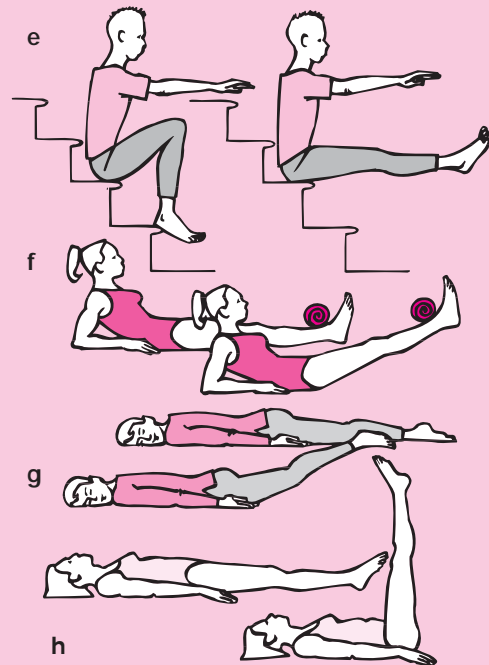
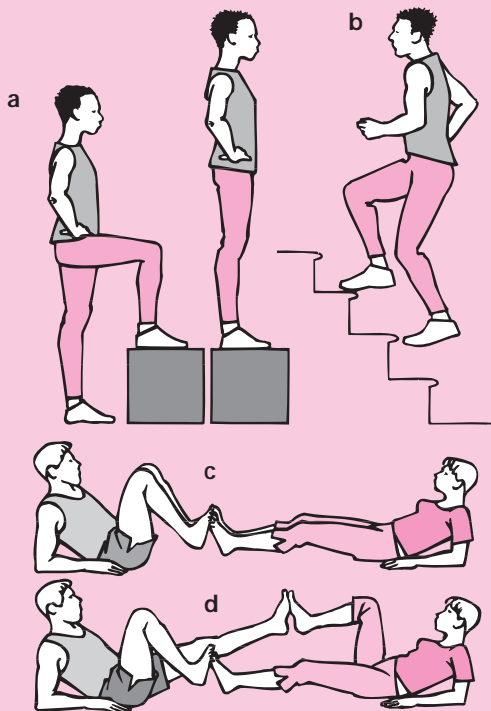
e Sit on one step of a staircase with your feet on the step below and your arms outstretched. Raise your legs until they are horizontal, and balance in this position.

f Attach light ankle weights to your feet (or use a heavy book or rolled magazines) and lie back on your elbows as shown. Lift your feet and legs and

hold them in the raised position.

g Lie face down with your arms at your sides. Lift both legs together as high as possible, and hold in this position for as long as you can.

h Lie on your back with your hands at your sides. Keeping your legs straight and your toes slightly pointed, raise your legs slowly until they are vertical. Hold in that position, then lower them slowly.



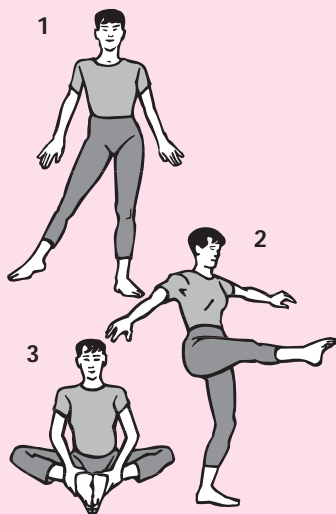
Leg and hip flexibility (below)

Use these flexibility routines in the same way as the others, to improve your body's mobility.

1 Stand upright, back against a wall. Raise one leg out to the side and then across your body as far as it will go, keeping it straight at the knee.

2 With your arms out to the sides for balance, take a small step forward and then kick the other leg into the air as high as you comfortably can, keeping it straight.

3 Sit with your knees apart and your feet together. Hold your ankles and see how near you can press your knees to the floor.



Leg and hip exercises (above)

a Stand on one leg, supported by your hand on a wall or table, then lift your free leg as high as possible to the side. Repeat for other leg.

b Stand as in 1, and swing your free leg forward and back as far as possible.

c Lie on your back with your buttocks touching a wall and your legs raised, then open your legs as wide as you can.

d Stand with your arms behind your head as shown, then lunge forward onto each leg in turn, with knee bent.

e Stand with your feet together. Keeping your feet flat on the ground, bend your knees while at the same time twisting them to the left. Straighten up, then repeat twisting them to the right.

f Stand with your feet together, then jump as high as you can to one side as though jumping a fence, keeping your feet together. Repeat to the other side.

g Lie on one side with your arms positioned as shown. Lift your upper leg as far as possible in the air, then lower it.

h Lie face down with your arms at your sides, then lift each leg in turn as high as possible off the floor.

Legs are generally strong and robust parts of the human body, but are nevertheless prone to many problems because of the various strains imposed by their functions. The knee is the largest joint in the body, and takes the strain of almost all of our body weight. Consequently its well-being can be affected by bad posture, by poor walking habits, and also by the state of the thigh and calf muscles.

Whenever one part of the leg is injured or troublesome, it tends to affect the rest of the leg adversely as muscle movements and patterns shift to “protect” the injury, and so the problem can be multiplied. It may even cause trouble in the torso too. On these pages we look at some of the common leg problems and show you how to avoid them, and their effects, as much as possible.

Common leg problems

The illustration plots the sites of some of the problems that commonly affect the legs.

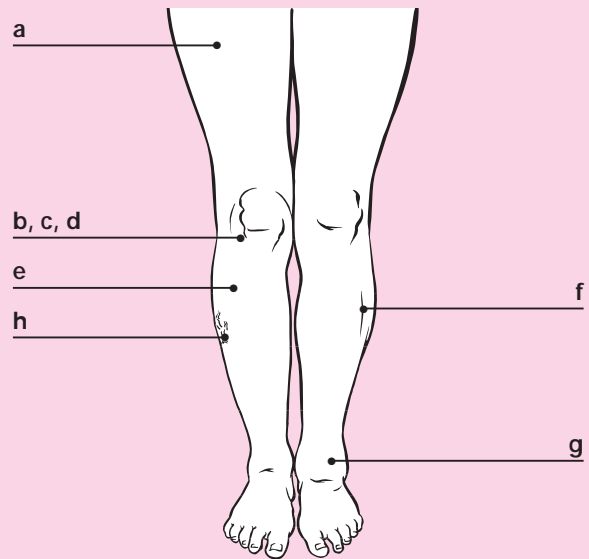
a Sciatica. This severe pain down the leg is caused by pressure on the sciatic nerve (see opposite).

b Housemaid's knee, an inflammation of the knee joint which may be caused by frequent kneeling.

c Runner's knee. This condition often affects joggers and long-distance runners, and consists of pain and strain caused by insufficient foot support during running. Soft supports placed inside the running shoes usually ease the problem.

d Degenerative arthritis. This tends to occur more often in the knee than in other joints, because of the extra wear caused by the knee's weight-bearing function. Obesity often precipitates the problem, especially in women.

e Shin splints. This condition may be suffered by runners, and takes the form of pain over the shin area. It is often caused by running on hard surfaces, such as sidewalks. A different condition is caused by inadequate support from running shoes.



f Cramp. The intense pain of cramp is often experienced in the calves, and is caused by the muscle contracting hard or going into spasm. This may be because of an insufficiency of salt, or unaccustomed exercise without warm-up activity.

g Swollen ankles. Accumulation of fluid in the ankles causes them to swell and feel tender and heavy. Excessive water retention, obesity, pregnancy, lack of exercise, and heart failure are all possible contributing factors.

h Varicose veins—see opposite.

Aggravating situations

Certain occupations or habits tend to increase the likelihood or the severity of leg problems. Overweight people increase the strain on their knee joints, and this is also true of women carrying extra weight because of pregnancy. Poor posture also strains the knees, and high-heeled shoes place an unnatural strain on the legs and should not be worn for long periods. Standing occupations, such as serving at a counter or cooking, increase circulatory problems as the calf muscles may not work hard enough to pump the blood back up to the heart.



Varicose veins

These develop when valves in the lower leg veins become faulty and allow the blood to pool, causing the veins to swell and become engorged. The blood flow around the legs is disturbed and the problem is increased unless the faulty valves are removed or normal flow can be established by exercise. Standing occupations, although they do not cause varicose veins, do increase any inherent tendency to them. The actions of the leg muscles are important in squeezing the blood in the calves and maintaining circulation. Any measures that improve blood flow from the legs will help, such as brisk walking and leg exercises.

Circulatory problems

Many circulatory problems in the legs are associated with, or are complications of, varicose veins (see left). Varicose eczema is caused by scratching the inflamed skin over the veins. Varicose ulcers appear when the tissue degenerates as the circulation deteriorates. The ulcers are wounds and need dressings until they are healed. Phlebitis, or clotting of the surface vessels, can be eased by extensive bandaging of the leg until the condition subsides and the underlying causes can be treated. Greater use and fitness of leg muscles helps their squeezing action to force blood upward toward the heart.

Sciatica

Sciatica is the term used to describe pain that is usually spinal in origin, but that is felt along the sciatic nerve in the leg. The diagram (opposite) shows the usual place in the leg where the pain is generally felt. In fact this part of the leg is not the source of the pain. It results from pressure exerted on the sciatic nerve when it is squeezed or pressed by one of the vertebrae or by an intervertebral disk, higher up in the vertebra column (backbone). The condition is usually cured by rest, followed by physical therapy. Surgery may be needed in severe cases. Avoiding back strain through good posture and exercise may help to prevent sciatica.

The feet are very complex structures, as their tasks require coordinated combinations of balance, movement, rigidity, maneuverability, strength, and flexibility. Each foot contains 26 bones, 19 muscles, and more than 100 ligaments to help it carry out these diverse functions. There are also numerous foot- and ankle-moving muscles in the lower leg. Problems with the feet can affect a great deal of the rest of the body, causing leg pain, back pain, poor posture, and fatigue. Some foot problems may affect the muscles or bones, or may be viral, fungal, or bacterial infections; others may simply be caused by poor foot hygiene or a lack of general care and exercise. Here we show you ways in which you can help to prevent many of these problems by giving your feet a little extra attention.

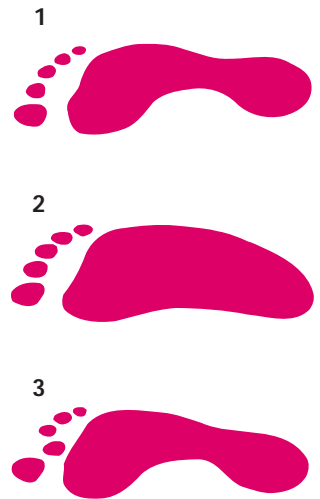
Footprints

The foot's state of health is often reflected in the shape of its print.

1 A foot that is structurally sound; the print is well-formed and lacks unnatural bumps or hollows.

2 A fallen arch; the sole is flattened out.

3 A foot with a hammer toe, where one of the toes is drawn up out of the natural line.



Common foot problems

The illustrations show the sites of some of the most common foot problems.

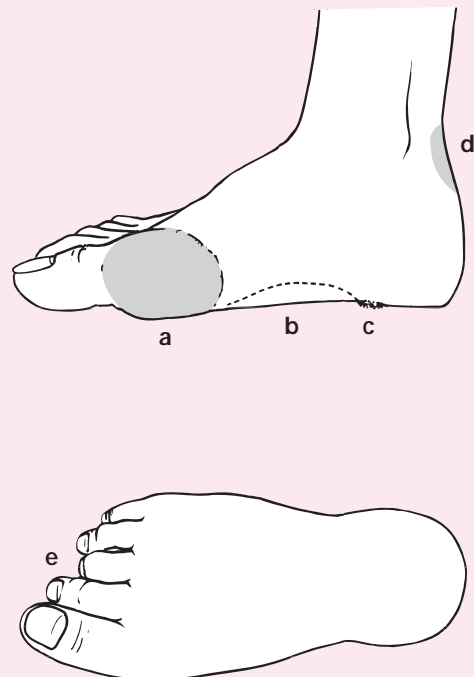
a Bunion. This may develop as the underlying joint becomes swollen and deformed, often due to poor footwear.

b Fallen arch or flat foot. This condition is not always problematic, although arches that are in the process of falling may cause pain and a chiropodist should be consulted.

c Verruca. This is a wart that usually appears on a weight-bearing area of the foot, including the toe (see opposite).

d Achilles tendinitis. Inflammation in this area is usually caused by poor footwear that places strain on the heel.

e Hammer toe. This may be the result of pinching the toes into tight or pointed shoes. The toe finally becomes permanently bent up at the joint.



Verrucae

Verrucae, warts on the feet, are unsightly and can cause considerable pain. They are transmitted rapidly in damp conditions, so anyone who develops a verruca should refrain from using swimming pools and communal shower rooms until it has gone. Like ordinary warts, a verruca may disappear spontaneously. But if it is large or painful, it may have to be removed. Treatment includes antiviral cream, or surgery to cut out the wart or destroy it by intense heat or cold.

Corns

Corns are impacted and thickened dead cells that have not been shed from the skin normally, but have been hardened by friction from ill-fitting shoes. Corns have nuclei, often mistakenly called “roots,” and any cure must remove the nucleus as well as the dead skin. Correctly fitting footwear is an important corrective measure. Professional treatment from a chiropodist will remove the corn. Do not try to remove it yourself, as you may damage your foot.

Shoes and socks

The fit of shoes and socks is important throughout life, since the feet can be pushed out of shape by constant mistreatment at any time. Socks should always be long enough to cover the foot when unstretched, and not too tight or they may restrict muscles and blood flow. Shoes should be comfortable and fit well in both length and width. Fashion shoes are best as occasional wear. Everyday shoes have relatively low heels that are broad enough to spread the body's weight.

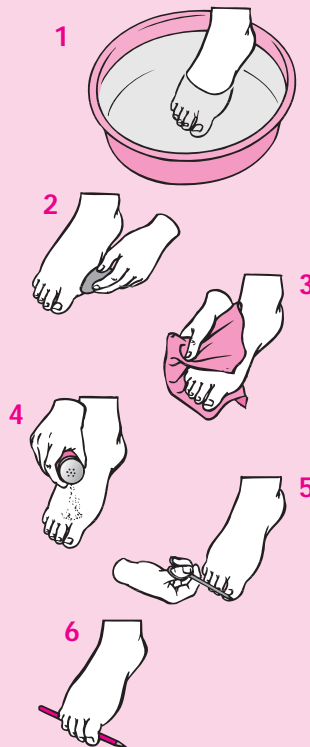
Home pedicure

It is worth spending the time every few weeks to give your feet a complete home pedicure. This will help to prevent common foot problems.

1 Bathe your feet in alternate baths of hot and cold water—this stimulates the circulation, and also helps to relieve tired feet.

2 Rub down any calluses or hard skin patches with a wet pumice stone smeared with soap.

3 Dry your feet thoroughly with a towel, particularly between the toes. This discourages



fungus infections such as athlete's foot.

4 Dust your feet very lightly with talcum powder; a little powder will help prevent sweaty feet, but too much will aggravate the problem.

5 Cut your toenails straight across; do not be tempted to shape them or cut them down at the sides, as this will encourage ingrowing.

6 Exercise your feet by trying to pick up a pencil with your toes. This will keep the muscles well toned and help the circulation.

Joints or articulations are classified structurally as fibrous, cartilaginous (see page 98), and synovial, depending on the material binding the bones together. They can also be classified functionally, based on the bone shapes and direction of movement (see opposite), or the

amount of movement allowed, as follows:

- **Synarthrotic joints (immovable).**
- **Amphiarthrotic joints (slightly movable).**
- **Diarthrotic joints (freely movable).**

Fibrous joints

There is no joint cavity. Bones are held together by fibrous tissue.

Type

Suture

Syndesmosis

Gomphosis

Description

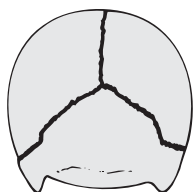
- Bones are separated by a thin layer of fibrous tissue.
- Bones are united by dense fibrous tissue.
- Bone is a cone-shaped peg in a socket.

Movement

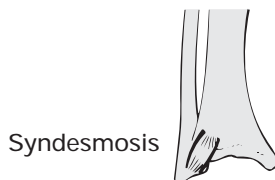- None (synarthrotic).
- Slight (amphiarthrotic).
- None (synarthrotic).

Examples

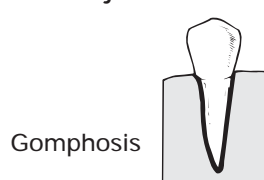
- Between skull bones, forming the wiggly suture lines across its surface.
- Ends of tibia and fibula, lower leg.
- Roots of teeth in alveolar bone of jaw.



Sutures



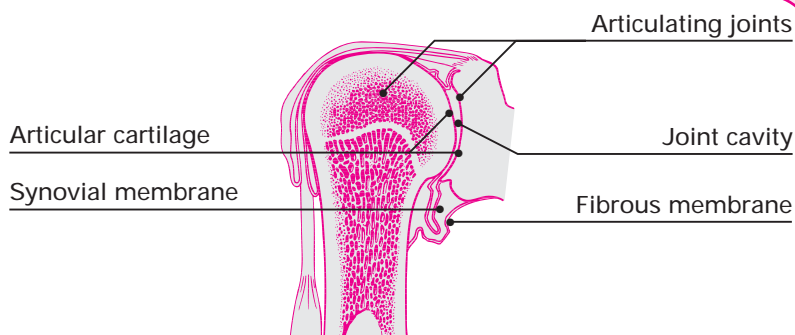
Syndesmosis

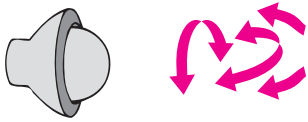


Gomphosis

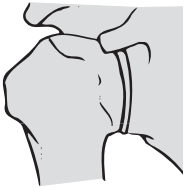Synovial joints

The ends of the bones are covered by articular cartilage. A baglike synovial capsule encases the joint. Its inner lining, the synovial membrane, makes oily synovial fluid to lubricate the joint.

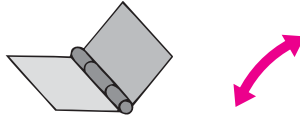


Ball and socket

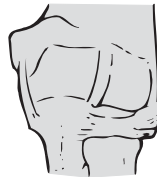Allows movements in three planes, including twisting (rotation)



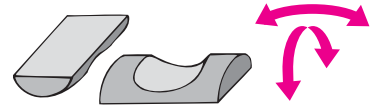
Shoulder joint

Hinge joint

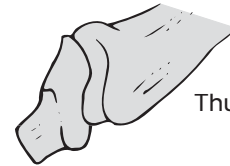
Allows movements in only one plane, like a door hinge



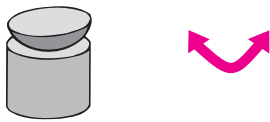Elbow joint

Saddle joint

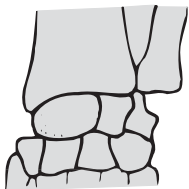
Permits movements in two planes by saddle-shaped surfaces



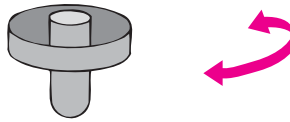
Thumb joint

Ellipsoid joint

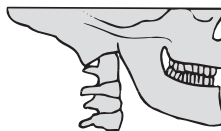
Allows movements in two planes (lacks rotation)



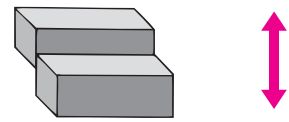
Basal wrist joint

Pivot joint

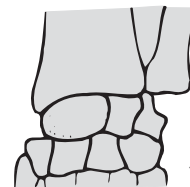
Permits rotational motion in one plane, like a wheel on an axle



Second neck joint (atlas-axis)

Plane joint

Sliding movement of flat surface, usually limited in extent



Distal wrist joint

HEAD AND NECK

Joint	Joint type	Description
Atlanto-axial joint	Synovial	Pivot joint between atlas and axis, pivoting on odontoid process of axis
Atlanto-occipital joint	Synovial	Ellipsoid (or condyloid) joint between occipital bone of skull and atlas
Coronal suture	Suture	Immovable joint between frontal and parietal bones
Intermaxillary suture	Suture	Immovable joint between maxillae
Lambdoidal suture	Suture	Immovable joint between occipital and parietal bones
Metopic suture	Suture	Immovable joint between two halves of frontal bone
Sagittal suture	Suture	Immovable joint between parietal bones
Temporomandibular joint	Synovial	Modified hinge joint between temporal bone and mandible (jaw joint)

CHEST

Joint	Joint type	Description
Costochondral joints	Synchondrosis	Immovable joints between ribs and their costal cartilages
Manubriosternal joints	Symphysis	Slightly movable joint between manubrium and body of sternum
Sternocostal joints	Synchondrosis; synovial	Immovable joint between sternum and first rib; slightly movable joints between second to seventh ribs
Vertebrocostal joints	Synovial	Plane joints between vertebrae and ribs
Xiphisternal joint	Symphysis	Slightly movable joint between xiphoid process and body of sternum

BACK

Joint	Joint type	Description
Intervertebral joints	Symphysis	Slightly movable joints between adjacent vertebrae
Zygapophyseal joints	Synovial	Plane joints between articular processes of adjacent vertebra

PELVIS

Joint	Joint type	Description
Sacroiliac joint	Synovial	Plane joint between sacrum and ilium
Symphysis pubis	Symphysis	Slightly movable joint between pubic bones

ARM

Joint	Joint type	Description
Acromioclavicular joint	Synovial	Plane (gliding) joint between acromion process of scapula and lateral end of clavicle
Carpometacarpal joints	Synovial	Plane or modified saddle joint connecting carpals with metacarpals
Distal radioulnar joint	Synovial	Pivot joint between head of ulna and ulnar notch of radius
Elbow joint	Synovial	Hinge joint between humerus and radius/ulna
Interphalangeal joints	Synovial	Hinge joints between phalanges
Metacarpophalangeals	Synovial	Ellipsoid (condyloid) joints at base of fingers
Midcarpal joints	Synovial	Plane joints between adjacent carpal bones
Proximal radioulnar joint	Synovial	Pivot joint between head of radius and ulna
Shoulder joint	Synovial	Ball and socket joint between head of humerus and glenoid cavity of scapula
Sternoclavicular joint	Synovial	Saddle joint between clavicle and sternum
Wrist joint	Synovial	Ellipsoid joint between lower end of radius and carpals

LEG

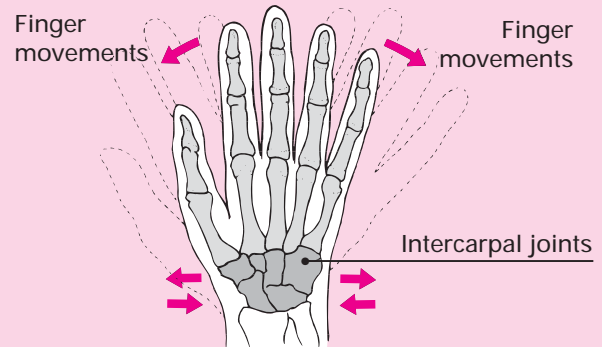
Joint	Joint type	Description
Ankle joint	Synovial	Hinge joint between talus and tibia/fibula
Calcaneocuboid joint	Synovial	Plane joint between calcaneus and cuboid
Cuneonavicular joint	Synovial	Plane joint between cuneiform bones and navicular bone
Hip joint	Synovial	Ball and socket joint between head of femur and acetabulum of hip bone
Inferior tibiofibular joint	Fibrous	Slightly movable joint between lower ends of tibia and fibula
Interphalangeal joints	Synovial	Hinge joints between phalanges
Knee joint	Synovial	Modified hinge joint between condyles of femur and condyles of tibia
Metatarsophalangeal joints	Synovial	Ellipsoid joints between metatarsals and phalanges
Subtalar joint	Synovial	Plane joint between talus and calcaneus
Superior tibiofibular joint	Synovial	Plane joint between lateral condyle of tibia and head of fibula
Talocalcaneonavicular joint	Synovial	Modified plane joint between talus, calcaneus, and navicular in ankle
Tarsometatarsal joints	Synovial	Plane joints between tarsals and metatarsals

Gliding

One surface moves over another surface, back and forth and side to side.

Examples

- Intercarpal joints (in the wrist).
- Intertarsal joints (in the ankle).
- Certain parts of ribs that glide on parts of adjacent vertebrae.



Flexion

Flexion (bending) usually brings two bones closer together, decreasing the angle between them. (See also descriptions on page 19.)

Examples

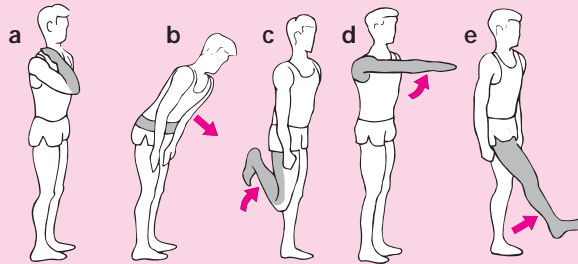
a Bringing the forearm to the shoulder flexes the arm.

b Bending the trunk flexes the spine.

c Lifting the heel to the bottom flexes the leg.

d Lifting the arm forward flexes the shoulder.

e Swinging the leg forward flexes the hip.



Extension

Extension (straightening) is the opposite of flexion. It usually increases the angle between bones.

Examples

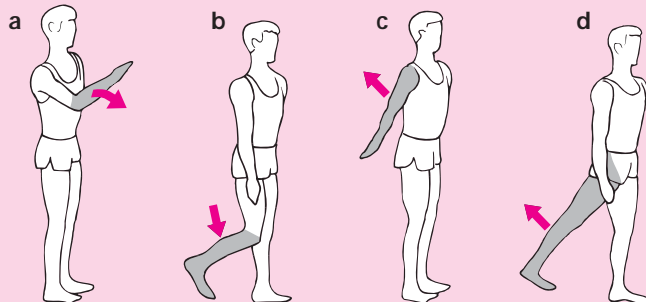
a Straightening the arm extends the arm.

b Straightening the leg extends the leg.

c Moving the arm

backward (rearward) extends the shoulder.

d Swinging the leg back extends the hip.

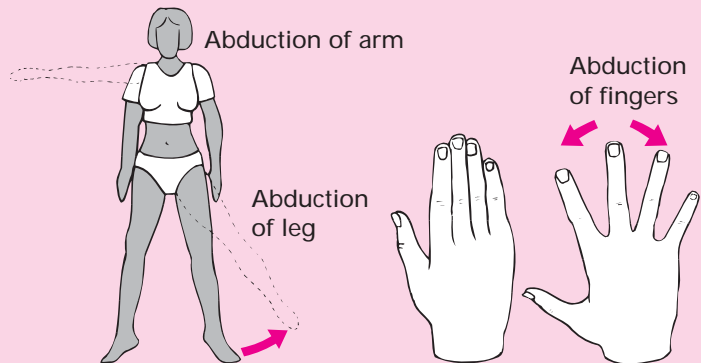


Abduction

Abduction (moving away) is the movement of a limb away from the midline of the body.

Examples

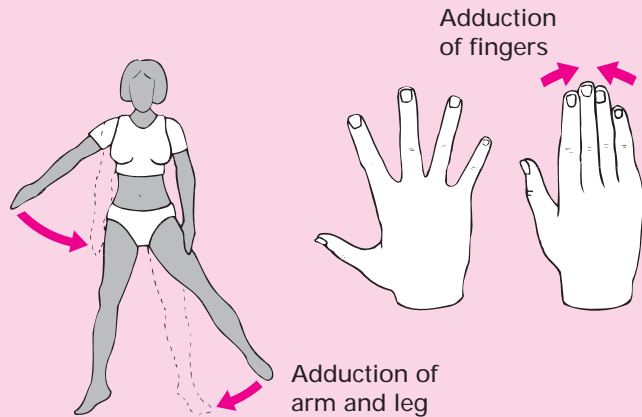
- Taking the arm out to the side.
- Taking the leg out to the side.
- Spreading the fingers and toes apart.

**Adduction**

Adduction (bringing together) is the opposite of abduction: it is the movement of a limb toward the midline of the body.

Examples

- Bringing the arm down to the side of the body.
- Bringing the leg to a standing position.
- Closing the fingers or toes.

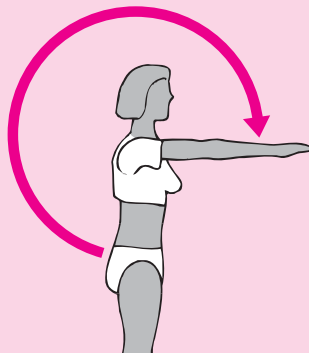
**Circumduction**

This is a 360° rotation that outlines a circle or cone in space. It is limited to the most mobile joints.

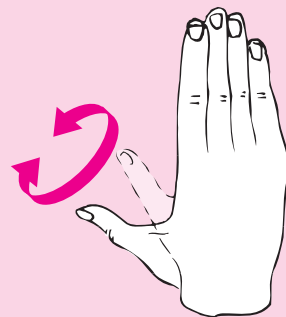Examples

- The shoulder.
- The saddle joint of the thumb.

Circumduction of shoulder

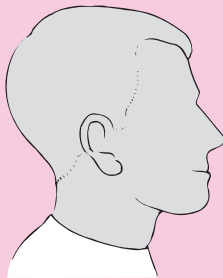


Circumduction of thumb

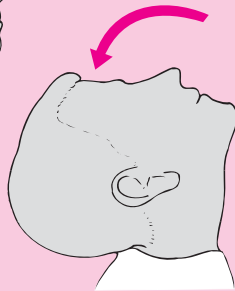


Hyperextension

This is when the body is extended beyond the anatomical position. This means that the joint angle becomes greater than 180° .



Example
• Tilting the head back to look up.



Hyperextension of neck

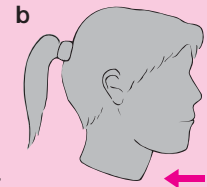
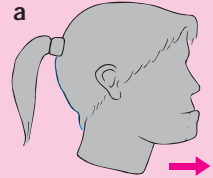
Protraction and retraction

These only refer to the mandible (jaw) or scapula (shoulder blade).

Protraction and retraction involve anterior (front) and posterior (back) movements in the same plane.

Examples include

- Sticking out the jaw (protraction, **a**).
- Moving the jaw back to the original position (retraction, **b**).
- Pulling back or squaring the shoulders (retraction).

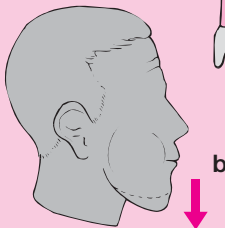
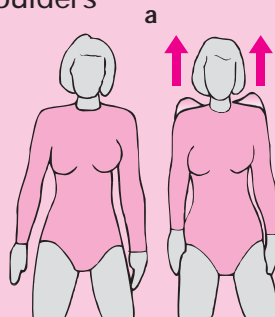


Elevation and depression

In elevation, part of the body moves upward; in depression, it moves downward.

Examples

- Hunching the shoulders (elevation, **a**).
- The jaw moving downward when eating (depression, **b**).

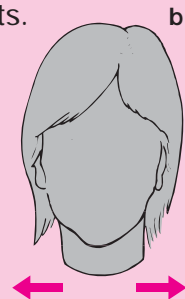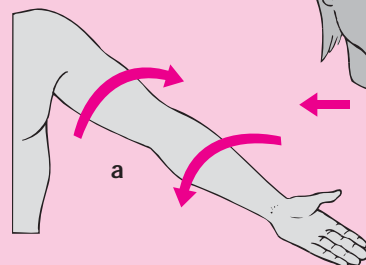


Rotation

This is the turning of a bone around its own long axis, like the rotating axle of a wheel.

Examples

- Hip and shoulder joints.
- Twisting arm (**a**).
- Shaking head from side to side (**b**).

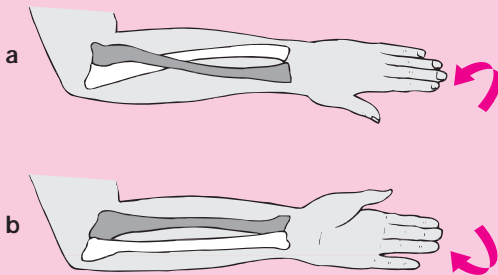


Supination and pronation

These refer to movements of the radius around the ulna.

Examples

- Rotating the arm so that the palm faces down (pronation, **a**).
- Rotating the arm so that the palm faces up (supination, **b**).

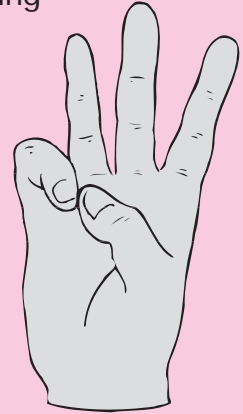


Opposition

This refers to a specific movement of the fingers and thumb. The thumb, fingers, and palm can be moved to touch or oppose each finger in turn, as when picking up a tiny item such as a pin.

Example

- Touching the tip of the little finger on one hand with the thumb of the same hand.

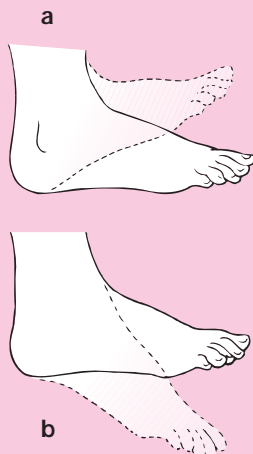


Dorsiflexion and plantarflexion

These refer to movements of the ankle and foot only.

Examples

- Lifting the top of the foot upward, decreasing the angle between the foot and leg (dorsiflexion, **a**).
- Pointing the toes and arching the foot, increasing the angle between the foot and leg (plantarflexion, **b**).

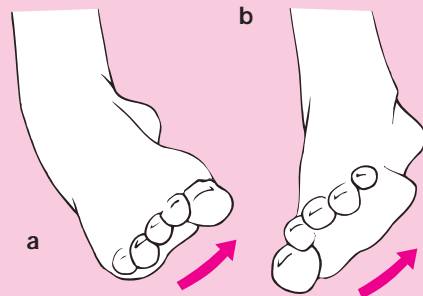


Inversion and eversion

These refer to special movements of the foot and toes only.

Examples

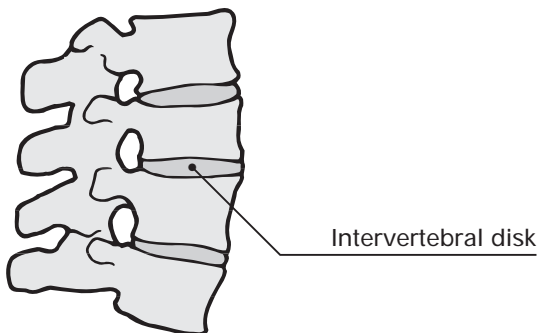
- Turning the foot inward toward the midline of the body (inversion, **a**).
- Turning the foot out away from the body (eversion, **b**).



Mobility exercises help to improve the flexibility and range of movements of the joints, and the muscles attached to them. They also tone ligaments and tendons with regular use. People who lead sedentary lives often have limited mobility in their joints. As a result their bodies are limited in efficiency and movement, and prone to various joint and muscle problems. General “aches and pains” can often be removed by a course of mobility exercises, and this kind of exercise is used in physiotherapy for rehabilitating stiff joints and weakened muscles. Always be careful when beginning mobility exercises. Joints that have become unused to their full range of natural movements can become sprained or dislocated. Begin any course of exercises gently to avoid aches and stiffness the following day. Never stretch your joints to the point of discomfort.

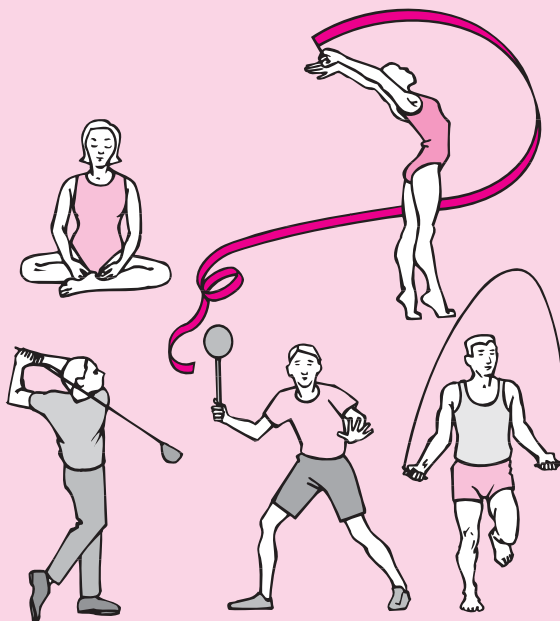
Back joints

The joints between the vertebrae are complex and cope with great stresses. Activities that strengthen back and abdominal muscles are important to support the vertebral column and ward off back disorders.



Mobility activities

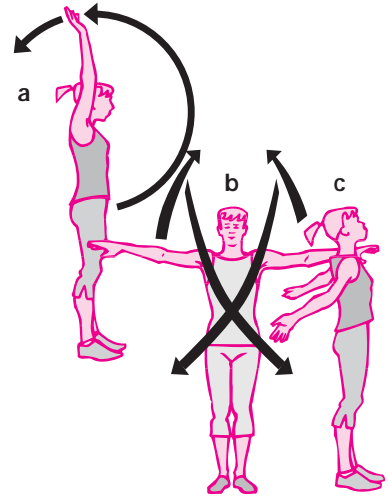
Yoga is very good for improving mobility and flexibility, as it stretches and loosens joints and muscles. T'ai Chi and Kai Men sequences of exercises are also beneficial for making joints more supple, as they involve a series of stretching poses that exercise the whole body. Jumping rope improves the flexibility of the arms and shoulders, and also helps the hips, knees, and ankles. Sports such as swimming, golf, gymnastics, racket sports, and track and field events all promote mobility as they tend to require the use of many joints and muscles for coordinated movements. Exercising with Indian clubs or ribbons, and gymnastic floor exercises and movement sequences, also improve flexibility and suppleness.



Arm and shoulder flexibility

These tests will enable you to see how well you are progressing as you use the mobility exercises to increase your flexibility. Try the tests before you begin your exercise program, and then do them at weekly or two-weekly intervals and note your improvement.

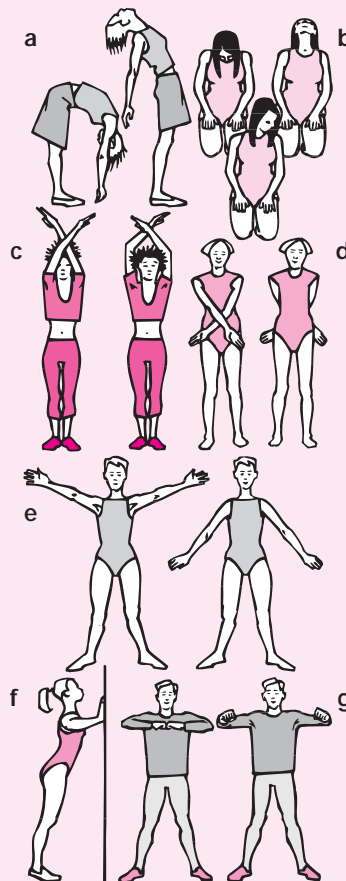
- a** Stand with your arms at your sides. Keeping them straight from the shoulders, move them forward and up, then down and back as far as possible, moving your hands in an arc.
- b** Stand with your arms straight out to the sides. Move them first up, and then down and across your body, as far as they will go without discomfort.
- c** Start as for b, and reach behind you as far as you can.



Mobility exercises

For these exercises, begin with one or two repetitions each day and work up slowly to a maximum of 30 repetitions each.

- a** Stand upright, with your arms loosely at your sides. Bend your trunk first forward and then backward.
- b** Move your head first forward and back, and then from side to side, to loosen your neck and shoulder joints.
- c** Stand upright with your arms stretched above your head. Cross your arms in front of your face, and then behind your head.
- d** Stand with your arms at your sides. Cross your arms first in front of your



body then behind your back.

- e** Stand with your arms at your sides and make giant circles first forward and then backward.

f Stand with your feet together and your arms against a wall. Bend your arms so that your chest moves toward the wall, and then straighten your arms again. This is a modified pushup; when you are more flexible you may be able to do full pushups.

g Stand with your feet apart and your elbows raised to shoulder level. Clench your fists in front of your chest. Push your elbows back as far as possible, keeping your back straight.

Keeping the various parts of the musculoskeletal system and the joints in balanced relationship with one another—in other words, cultivating good posture—can play a vital role in preventing or treating backache and certain other ailments.

Correct posture

Maintaining correct posture reduces the risk of accidents in everyday living and working, as well as in play and sport. It also delays or prevents onset of osteoarthritis due to joint overuse or injury.

Poor posture

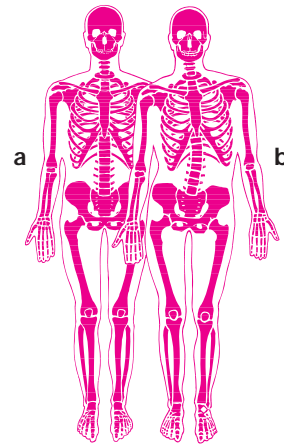
On the other hand, bad posture produces poor muscle coordination and hampers blood circulation to the muscles. This can handicap would-be sports and games players. It also leaves anyone with less energy at the day's end for active recreation.

Contributing factors

Back strain risks increase if you have poor posture, if you bend or lift incorrectly, if you wear wedge or high-heeled shoes, or if you are pregnant or obese.

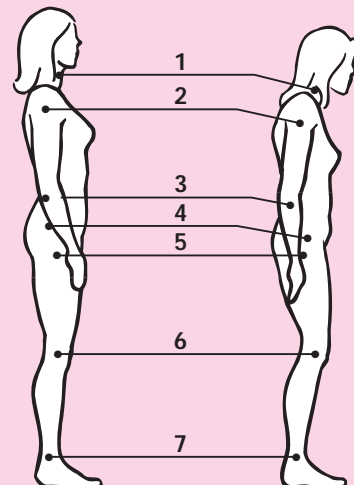
Postural problems

The diagrams below show how posture affects skeletal alignments. Person **a** stands correctly balanced, spine vertical. The bones of both shoulders, both hips, and both hands are horizontally aligned. In person **b** the spine curves to one side and shoulders, hips, and hands are tilted.



Key posture points

People with good posture stand so you could draw a vertical line through certain key points of the body. Check your posture against the key points listed here, especially the joints, as you stand sideways to a full-length mirror. Pull your head up, shoulders back, chest out. Keep your back straight, arms loosely at the sides, buttocks relaxed, knees slightly bent, weight evenly distributed. Check the key points one by one: **1** neck, **2** shoulders, **3** lower back, **4** pelvis, **5** hip joints, **6** knee joints, **7** ankle joints.

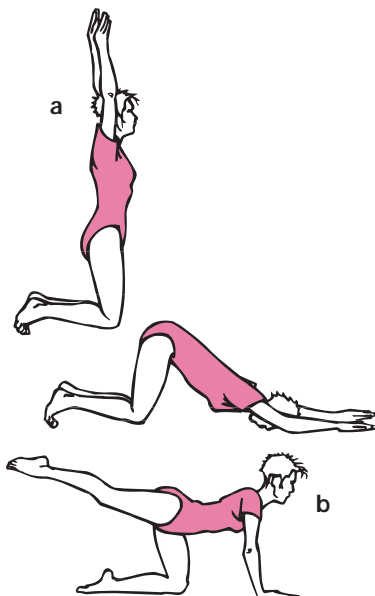


Spinal disorders

These include scoliosis (see page 33), where the spine curves to one side, and lordosis, where the lumbar vertebrae curve inward. Some such spinal conditions are progressive; others are less serious and respond better to exercises. If doctors approve, scoliosis sufferers can try these exercises.

a Kneel with arms above your head, then bend forward from the hips and touch the floor. Walking on your knees, pivot right then left around your hands.

b Kneeling on one knee, propped by the opposite arm, lift and extend the other arm and leg in line with the body. Repeat with opposite limbs.



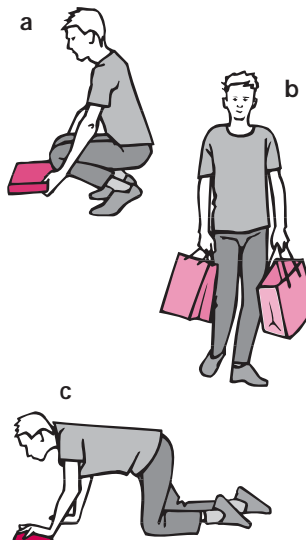Posture and daily activity

Using the body correctly to perform daily chores can help to prevent straining or injuring the back.

a Keep your back as straight as you can to lift a load from the floor. Kneel or squat; do not bend. Open a drawer or put items on low shelves in the same way.

b When carrying a load in one hand, balance it with a load in the other, or half support it on a hip.

c If kneeling, raise your buttocks so that the hips and shoulders support the spine. Also, sit with the pelvis touching the back of the chair and keep the spine slightly curved.



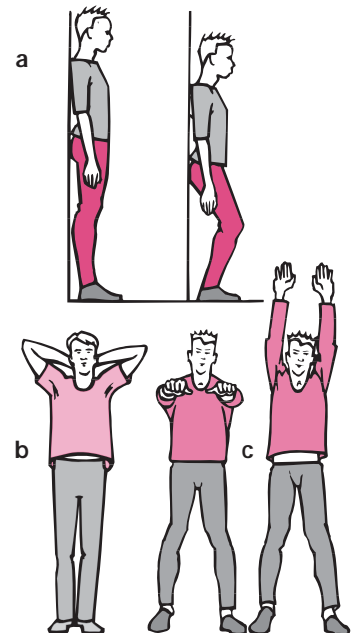
Posture exercises

These exercises will help to achieve and maintain a correct, healthy posture.

a Stand with your back against a wall. Slightly bend the knees, tilt the hips upward, lower the head, and broaden the shoulders.

b Stand and clasp your hands behind your neck. Pull the elbows back and up and hold the position for five seconds.

c Stand with your feet well apart. Holding your arms straight, raise them forward from your sides to the front, then up so that your shoulders brush your ears. Continue moving your arms backward to complete a circle.



Disorders and diseases of the joints and skeleton

(Note: See also descriptions of some major disorders of the skeletal system on page 33.)

Arthritis A general term for inflammation, swelling, redness, and tenderness or pain in a joint. This term is usually further defined for the names of specific medical conditions, such as osteoarthritis, gouty arthritis, and rheumatoid arthritis.

Dislocation An injury in which bones are forced out of their normal positions—see opposite.

Gouty arthritis A form of arthritis caused by urate crystals (formed from uric acid) deposited in the soft tissues of joints. Uric acid is a waste product, normally eliminated without any problems. However if the crystals form in a joint, often in the big toe (metacarpophalangeal and interphalangeal joints), this causes intense pain.

Kyphosis Abnormal outward curvature of

the upper spine, which can affect the intervertebral joints of the vertebral column, with stiffening and pain.

Lordosis Abnormal inward curvature of the lumbar vertebrae in the lower spine. As in kyphosis, it can affect the intervertebral joints and cause pain and loss of mobility.

Lyme disease Caused by bacteria transmitted by bites from ticks. It can result in forms of arthritis, affecting especially the knee joint.

Osteoarthritis Often referred to as degenerative joint disease. The specific cause is unknown. One theory is that enzymes are released that break down the articular cartilage covering the ends of the bones in synovial joints. It is linked to overuse and excessive stress placed on the joints, for example, after many years of intensive activity in certain sports.

Types of cartilaginous joints

There is no joint cavity. Articulating bones are held together by cartilage. These joints are very rarely prone to disease or injury, compared to synovial joints (see page 86).

Type	Description	Movement	Examples
Symphysis	<ul style="list-style-type: none"> The connecting material is a broad, flat disk of fibrocartilage 	<ul style="list-style-type: none"> Slight (amphiarthrotic) 	<ul style="list-style-type: none"> Intervertebral joints between the backbones
Synchondrosis	<ul style="list-style-type: none"> The connecting material is hyaline cartilage 	<ul style="list-style-type: none"> None (synarthrotic) 	<ul style="list-style-type: none"> The epiphyseal plate in a growing long bone

Paget's disease Involves the abnormal formation and resorption of bone. Bones become soft, weak, thickened, and deformed, and this affects their joints and may lead to increased risk of fractures and dislocations.

Rheumatism A general name for any painful state in bones, ligaments, joints, tendons, or muscles.

Rheumatoid arthritis A chronic inflammatory disorder affecting joints,

especially those of the fingers and toes, and causing severe swelling. (See page 33 for diagrams of this disorder.)

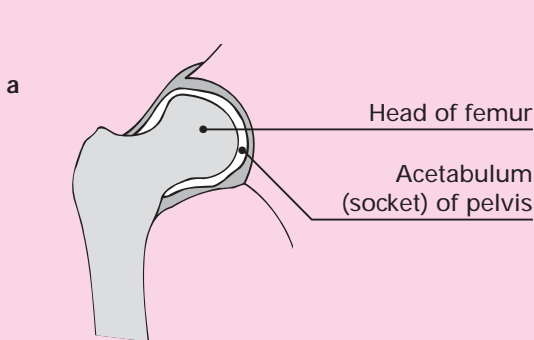
Sprain An injury in which the ligaments reinforcing a joint are stretched or torn (see next page for treatment).

Whiplash injury Joints, muscles, and ligaments around the cervical (neck) vertebrae are torn by sudden head movement, often resulting from an automobile accident (see page 101).

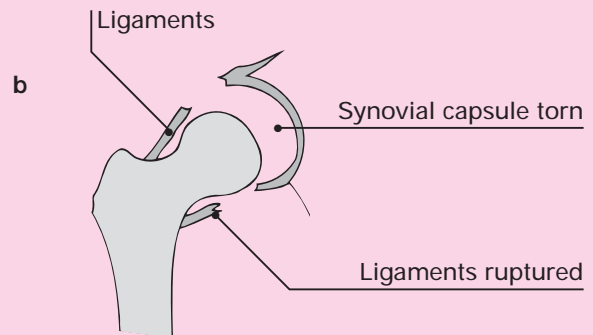
Dislocated joints

Many joints in the body can be dislocated or “come out” when the bone ends are allowed to move apart. The cause is usually excessive stress such as twisting or impact at speed. Signs are great pain and perhaps an obviously misshapen joint. Particularly at risk is the shoulder, since its ball-and-socket design has a very shallow socket in the

scapula to allow for great mobility. Treatment usually involves reduction, or replacing the bones into their correct positions and alignments, followed by possible surgery to repair ruptured ligaments and tendons. Repeated dislocations can cause ligaments and tendons to become slack and weak, requiring corrective surgery.



a Normal synovial joint (the example here is the hip). The cartilage-covered bone surfaces are kept in close proximity by ligaments, and separated only by a thin film of synovial fluid.

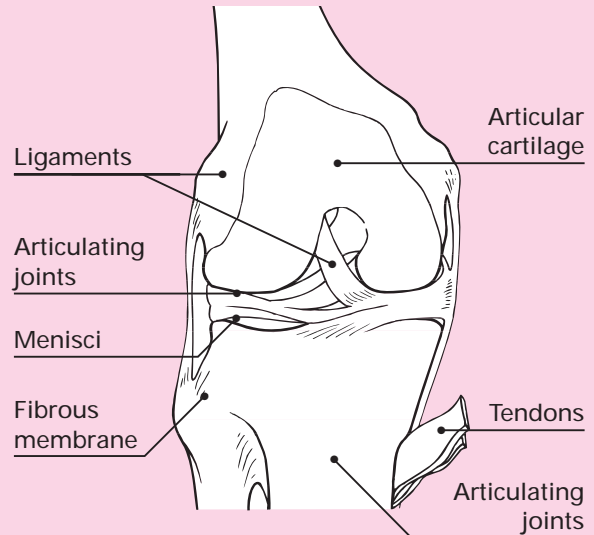


b Dislocated joint. The ligaments that keep the two bone surfaces in place are ruptured or torn. The ends of the bones have become displaced and separated from each other.

The troublesome knee joint

The knee is the body's largest single joint, and also has an unusual structure. On each side are strong ligaments, the medial (inner side) and lateral (outer side). There are also ligaments within the joint, known as cruciate ligaments since they form a cross (X) shape. In addition to the usual articular cartilage covering the bone ends, there are also two moon-shaped pieces of "floating" cartilage, menisci, between the bones. Knees must cope with unusual stresses in many modern sports, where players run fast, then suddenly stop or jerk or swerve to the side. Sometimes the menisci begin to fragment and must be surgically removed from the joint.

Knee joint: anterior view

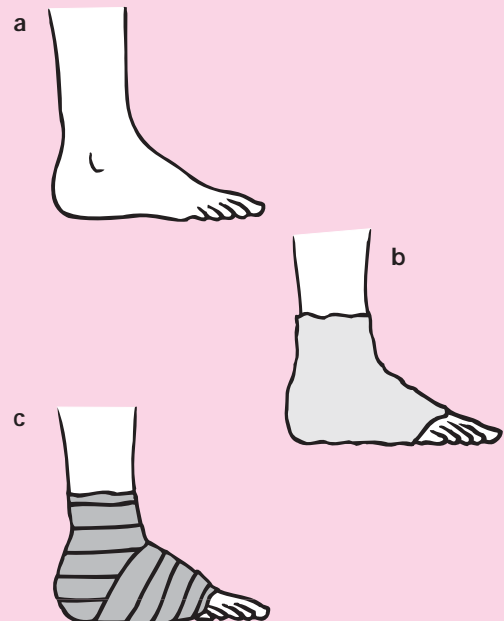


Treating joint sprains

Treat torn or bruised ligaments (for instance in a knee or an ankle) by resting the injured part. With firm support and gentle use, a sprained ankle may recover in only a few days.

A cold compress is useful for first aid. Treatment includes deep massage to disperse blood and fluid that has collected around the injury.

In the event of a sprained ankle (a), follow this procedure: lay a thick layer of cotton over the ankle, then firmly fix in place by elastic bandaging (b). You may need to add a second layer of cotton covered with a second bandage (c). If the sprain is still painful and you suspect fracture, seek prompt medical advice.



Effects of joint problems

Poor posture and lack of general activity and exercise, with inflexible joints and lack of tone, mean that key sections of the body are ineffectively supported by unbalanced sets of muscles and ligaments. The joint problems that follow can also cause other

disorders in the body; not all of these directly related to the musculoskeletal system. The sites and ensuing disorders include:

- a** Head-neck junction: headaches, muscle pain in the neck and upper back, disk degeneration in the cervical (neck) vertebrae.
- b** In whiplash injury (see

page 99), ligaments and muscles around the fifth cervical vertebra are torn by sudden head movement. Treatment involves wearing a soft cervical collar for some weeks. Serious side-effects include numbness and paralysis in parts of the body below the neck, due to inflamed or possibly ruptured nerves. These consequences may take some time—many months—to resolve.

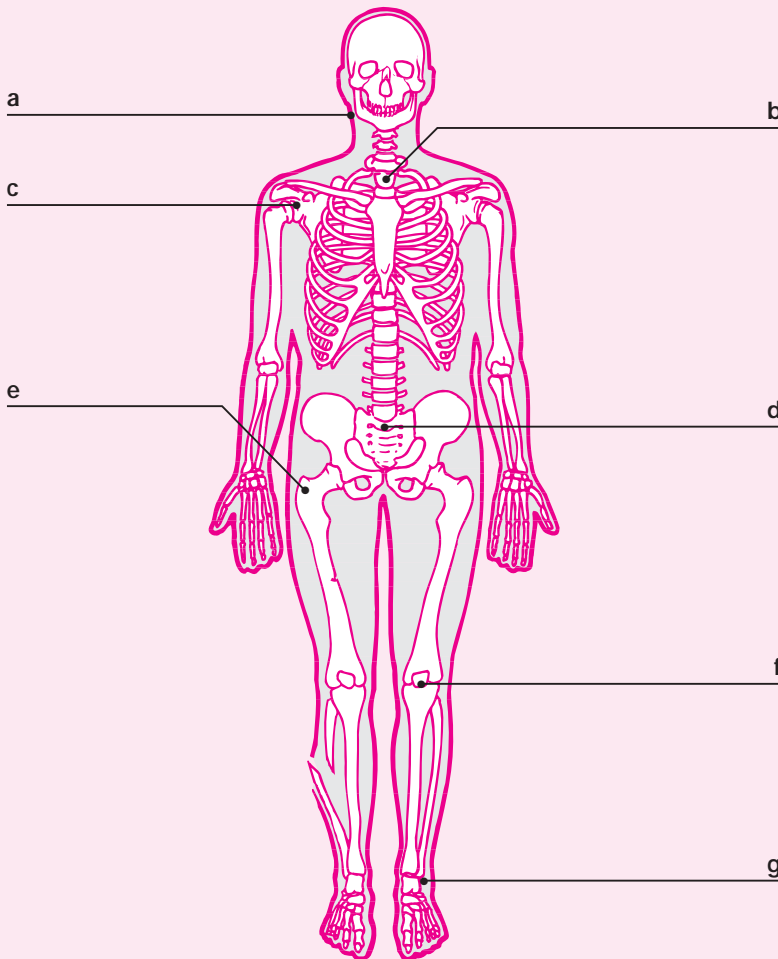
c Shoulder girdles: painful shoulder muscles, capsulitis, pinched nerve.

d Lumbo-sacral articulations: low-back pain, disk degeneration in the lower intervertebral joints, sciatica.

e Hip joints: muscle strain affecting the buttocks and hamstrings.

f Knee joints: strained ligaments, strained tendons, osteoarthritis.

g Feet and ankles: strained and painful muscles in the foot and leg, painful knee, hip and ankle joints, greater risk of stress fractures and varicose veins.



Adipose tissue Connective tissue containing numerous fat cells.

Adrenal glands (*or* Suprarenal glands) Endocrine glands located on each kidney. The cortex and medulla produce a range of hormones.

Afferent Directed toward a central organ or part of the body.

Alimentary canal (*or* Gastrointestinal tract *or* Gut) The digestive tract: a tube starting at the mouth and ending at the anus.

Anus The lower end of the rectum, forming the outlet of the alimentary canal.

Aorta The largest artery, arising from the left ventricle of the heart.

Appendix (*or* Vermiform appendix) A short, wormlike tube opening into the cecum but closed at the other end. It contains lymphoid tissue, which is involved in immunity.

Arteriole A small artery supplying blood from a main artery to a capillary.

Artery A blood vessel transporting blood from the heart to elsewhere in the body.

Atrioventricular valve (*or* AV valve) A valve between a ventricle and an atrium. The right atrioventricular valve (*or* tricuspid valve) has three cusps. The left atrioventricular

valve (mitral valve or bicuspid valve) has two cusps.

Auditory Relating to hearing.

Axillary Relating to the armpit.

Backbone See **Vertebral column**.

Basal ganglia Paired structures deep in the forebrain: they help coordinate and control willed muscle movements.

Basophil A type of white blood cell that is readily stained by basic dyes.

Biceps A muscle with two heads: biceps brachii in the upper arm and biceps femoris in the thigh.

Bile ducts Tiny tubes that carry bile (a liver secretion) from the liver to the duodenum.

Bladder A sac, especially the muscular bag inside the pelvis where urine collects before being expelled from the body.

Blood A sticky red fluid consisting of colorless plasma, red blood cells (Erythrocytes), white blood cells (Leukocytes), and platelets (thrombocytes).

Blood pressure The pressure of blood against blood-vessel walls, especially artery walls.

Bone The hard, dense connective tissue that forms the skeleton's components.

Bone marrow Soft red and yellow substances that fill cavities in bone.

Bowel See **Large intestine**.

Brain The body's chief control center, consisting of billions of interconnected nerve cells.

Brainstem A stalklike part of the brain, between the cerebrum and spinal cord. It contains the midbrain, pons, and medulla oblongata.

Breast A female breast consists mainly of a mammary (milk-secreting) gland embedded in fatty tissue.

Breastbone See **Sternum**.

Bronchiole A small subdivision of a bronchus, ending in tiny air sacs called alveoli.

Bronchus The main tubes branching from the lower end of the trachea and forming the main airways to and from the lungs (plural: bronchi).

Capillary The tiniest type of blood vessel, connecting an arteriole and a venule.

Cardiac Relating to the heart.

Cardiovascular Relating to the heart and blood circulatory system.

Cartilage Gristle: dense, white connective tissue cushioning bones.

Cecum The first part of the large intestine, forming a blind pouch.

Cell The basic unit of the body, usually comprising an outer membrane, cytoplasm, a nucleus, and organelles.

Central nervous system

(CNS) The brain and spinal cord.

Cerebellum The largest part of the hindbrain. It helps coordinate muscular movements.

Cerebral cortex The cerebrum's thin outer layer of gray matter.

Cerebral hemisphere Either of the two halves of the cerebrum.

Cerebrospinal fluid A clear fluid filling the brain's ventricles and surrounding the brain and spinal cord to protect them from injury.

Cerebrum The upper, major part of the brain, comprising cerebral hemispheres and diencephalon.

Cervix A neck, especially the neck of the uterus (womb) where it opens into the vagina.

Clavicle Either of the two collarbones.

Clitoris An erectile, pea-sized organ above the opening of the vagina; it is highly sensitive and is involved in female sexual response.

CNS See **Central nervous system**.

Coccyx Four fused vertebrae forming the "tail" of the backbone.

Collagen A fibrous protein that is a major constituent of connective tissue.

Colon The part of the large intestine between the cecum and rectum.

Connective tissue Tissue that supports, binds, or separates more specialized body tissues or acts as packing.

Corium See **Dermis**.

Cornea The transparent circular area at the front of the eye, which acts as a lens.

Coronary arteries Supply the heart muscle.

Corpuscles A term often used for red and white blood cells.

Cortex The outer layer of the brain.

Cranial nerves Twelve pairs of nerves linking the underside of the brain with parts of the head, neck, and thorax.

Cranium The part of the skull that contains the brain.

Cutaneous Relating to the skin.

Cuticle See **Epidermis**.

Deoxyribonucleic acid (DNA) A nucleic acid in the cell's chromosomes containing the cell's coded genetic instructions.

Dermis (or **Corium**) The layer of skin below the epidermis, containing nerves, blood vessels, glands, and hair follicles.

Diaphragm A muscular sheet used in breathing. It separates the thorax (chest) and abdomen (belly).

Digestion The chemical and mechanical breakdown of foods into substances that can be absorbed by the body.

DNA See **Deoxyribonucleic acid**.

Duodenum The upper part of the small intestine, where most chemical digestion takes place.

Ejaculation The discharging of semen from the penis.

Endocardium The membrane that lines the heart and the heart valves.

Endothelium The cell layer that lines the inside of the heart, blood vessels, and lymph vessels.

Enzymes Biological catalysts: proteins that speed up chemical reactions without undergoing change themselves.

Epidermis (or **Cuticle**) The skin's outer layer.

Epiglottis A cartilage flap behind the tongue that is closed during swallowing to stop food from entering the larynx.

Epiphysis See **Pineal gland**.

Epithelium The cell layer covering the body, and lining the alimentary canal and respiratory and urinary tracts.

Erythrocytes Red blood cells.

Esophagus (or **Gullet**) The muscular tube through which food travels between the pharynx and the stomach.

Fallopian tubes (or Uterine tubes or Oviducts) The tubes through which ova (eggs) travel from the ovaries to the uterus.

Femur The thigh bone: the long bone between the hip and the knee.

Follicle A small secreting cavity or sac. Ova (egg cells) develop in follicles in the female ovaries.

Forebrain The front part of the brain comprising diencephalon and telencephalon.

Gallbladder A pear-shaped bag where bile is stored, below the liver.

Gametes Sex cells: sperm in males; ova in females.

Gastric Of the stomach.

Gastrointestinal tract See **Alimentary canal**.

Genes Basic biological hereditary units, consisting of DNA, located on chromosomes.

Genitalia Sex organs.

Gland A structure that synthesizes and secretes a fluid.

Gonads Primary reproductive organs: the ovaries and testes.

Granulocytes White blood cells with cytoplasm that contains granules: basophils, eosinophils, and monocytes.

Gray matter The darker tissue of the brain and spinal cord mainly consisting of neurons' cell bodies and dendrites.

Gullet See **Esophagus**.

Gut See **Alimentary canal**.

Heart The hollow, muscular, fist-sized organ that pumps blood around the body.

Hemoglobin The iron-rich, oxygen-transporting pigment in red blood cells that gives them their color.

Hepatic Relating to the liver.

Hepatic portal vein See **Portal vein**.

Hindbrain Brain structures below the midbrain, comprising the pons, medulla oblongata, and cerebellum.

Hormones Chemical substances released into the blood by endocrine glands to influence organs or tissues in other parts of the body.

Hypophysis See **Pituitary gland**.

Hypothalamus A part of the brain with endocrine functions.

Ileum The last part of the small intestine.

Immune system The body's defense system against infective organisms or other foreign bodies. It includes the lymphatic system.

Involuntary muscle Muscle that is not under conscious control. See also **Smooth muscle**.

Jejunum The middle part of the small intestine.

Joint The junction between bones.

Karyotype The chromosome complement of a person or species: the genome.

Kidney A bean-shaped organ that filters wastes from blood to form urine.

Lactation Milk production by the mammary glands.

Large intestine (or Bowel) The lower part of the alimentary canal, comprising the cecum, colon, and rectum.

Larynx The cartilaginous voice box.

Leukocytes White blood cells. They attack invading microorganisms and help to combat injuries.

Ligament Fibrous tissue that connects bones.

Liver The largest organ in the body, it is involved in various metabolic processes.

Lungs The two organs of respiration, filling most of the chest cavity inside the rib cage and above the diaphragm.

Lymph A transparent fluid that leaks from blood vessels into tissue spaces.

Lymph gland See **Lymph node**.

Lymph node (or Lymph gland) One of the "knots" in the lymphatic system, which contain lymphocytes and macrophages that filter the lymph passing through the nodes.

Lymphatic system A network of lymph vessels and lymph nodes. Vessels collect lymph from body tissues and return it to the blood after harmful substances have been filtered out in the lymph nodes.

Mammary glands The milk-producing structures in the breast.

Medulla oblongata The lowest part of the brain stem, containing the vital centers that control heartbeat and respiration.

Meiosis A type of cell division that produces daughter cells (sperm and ova) each with half as many chromosomes as the parent cell.

Meninges Three protective membranes surrounding the brain and spinal cord.

Menopause When a woman ceases to have menstrual periods.

Menstruation Menstrual periods: the monthly flow of blood and uterine lining from the vagina of nonpregnant females of childbearing age.

Metabolism The array of continuous chemical changes that maintain life in the body.

Mitosis Ordinary cell division in which both daughter cells have as many chromosomes as the parent cell.

Mucous membranes The mucus-secreting linings of the

digestive, respiratory, reproductive, and urinary tracts.

Nasal Relating to the nose.

Nasal cavity The space inside the nose between the base of the skull and the roof of the mouth.

Nerve A bundle of nerve fibers (axons) that transmit impulses to (in the case of sensory nerves) or from (in the case of motor nerves) the central nervous system.

Nervous system The coordinated networks of neurons that control the body. It is divided into the central nervous system (brain and spinal cord), and the peripheral nervous system (the somatic and autonomic nervous systems).

Neuron (*or* Neurone) A nerve cell: the basic unit of the nervous system.

Neurone *See* **Neuron**.

Neurotransmitter A chemical released at nerve endings to transmit nerve impulses across synapses.

Nucleic acids Molecules that store genetic information.

Nucleus The control center of a cell, which contains coded genetic instructions.

Olfactory Relating to smell.

Optic Relating to the eye.

Organ A body part with different types of tissue that performs a particular task.

Organelles Tiny structures (miniorgans) in a cell's cytoplasm with particular tasks.

Ovaries Female sex organs that produce ova (eggs) and sex hormones.

Oviducts *See* **Fallopian tubes**.

Ovulation The release of a ripe egg from a female's ovary.

Ovum An egg; a female sex cell (plural: ova).

Palate The roof of the mouth.

Pancreas An abdominal organ that produces pancreatic juice and the hormones glucagon and insulin.

Parasympathetic nervous system The part of the autonomic nervous system that predominates when the body is at rest.

Parathyroid glands Four pea-sized endocrine glands on the thyroid gland. They produce parathyroid hormone, which controls blood calcium level.

Pelvis A bony basin formed by the two hip bones, the sacrum, and the coccyx.

Pericardium The double-layered membrane that encloses the heart and attaches it to the diaphragm and sternum.

Peristalsis Waves of muscular contraction that propel substances through passageways, such as the alimentary canal.

Phagocytes Types of leukocytes that engulf and destroy microorganisms and foreign bodies.

Pharynx The throat.

Pineal gland (or Epiphysis) An endocrine gland in the brain that secretes melatonin.

Pituitary gland (or Hypophysis) A three-lobed, pea-sized gland below the hypothalamus. It produces growth hormone, hormones that act on other endocrine glands, oxytocin, and ADH. It is often called the body's "master gland."

Plasma The fluid part of blood.

Pleura The membrane that covers the lungs (visceral pleura) and lines the chest wall (parietal pleura).

Plexus A network of nerves (or blood or lymph vessels).

Portal vein (or Hepatic portal vein) Drains blood from digestive organs to the liver.

Prostate gland A gland situated below the bladder in males. It produces a sperm-activating fluid that forms nearly a third of the semen's volume.

Pudendum See **Vulva**.

Pulmonary Relating to the lungs.

Receptor A structure, such as a sensory nerve ending, specialized to detect environmental stimuli.

Rectum The last part of the colon, where feces collects before leaving the body.

Reflex action The body's automatic response to a stimulus, such as blinking.

Renal Relating to the kidney.

Respiration 1) Breathing; 2) Taking in oxygen and giving out carbon dioxide; 3) Deriving energy from food with or without using oxygen.

Respiratory system In humans, the mouth, nose, pharynx, larynx, trachea, bronchi, bronchioles, alveoli, and lungs.

Ribonucleic acid (RNA) A nucleic acid concerned with protein synthesis.

Ribs Twelve pairs of bones that protect the chest cavity and assist breathing by moving up and out during inspiration and down and in during expiration.

Salivary glands The lingual, parotid, sublingual, and submandibular glands that produce saliva.

Serum Blood plasma that does not contain clotting factors but does contain antibodies.

Sinus A cavity, such as the channels draining venous blood from the brain.

Skeleton The bony framework that protects and supports the body's soft tissues.

Skin The body's waterproof covering; its largest organ, comprising two main layers: the epidermis and dermis.

Small intestine The alimentary canal between the stomach and large intestine, comprising the duodenum, jejunum, and ileum. Most digestion occurs here.

Smooth muscle (or Unstriated muscle or Involuntary muscle) Muscle without striped fibers that automatically operates internal organs such as the stomach, bladder, and blood vessels.

Sphincter A ring-shaped muscle that contracts to close an orifice.

Spinal cord The cable of nerve tissue running down inside the vertebral column (spine) and linking the brain with nerves supplying most of the body.

Spine See **Vertebral column**.

Sternum The breastbone.

Subcutaneous tissue The sheet of connective tissue below the dermis.

Suprarenal glands See **Adrenal glands**.

Suture An immovable fibrous joint between the skull bones.

Taste buds Tiny sensory organs of the tongue and palate, distinguishing salty, sweet, sour, and bitter tastes.

Teeth Bonelike structures in the jaws. Different types (incisors, canines, premolars, molars) are specialized to tear, crush, and/or grind food.

Tendons Bands of fibrous connective tissue joining muscles to bones.

Testis (*or* Testicle) One of a pair of primary male sex organs that manufacture sperm (plural: testes).

Thalamus A brain structure above the hypothalamus. It sends sensory impulses to the cerebral cortex, links sensations with emotions, and affects consciousness.

Thymus An endocrine gland located behind the sternum. It produces thymosin.

Thyroid An endocrine gland at the front of the neck, producing thyroid hormone.

Tissue A collection of similar cells that perform a particular task.

Trachea (*or* Windpipe) The tube between the larynx and the bronchi.

Tubule A tiny tube.

Tunica A tissue layer forming a coating. Blood vessels have three such layers (intima, media, adventitia).

Unstriated muscle *See* Smooth muscle.

Ureter The tube conveying urine from a kidney to the bladder.

Urethra The passage taking urine from the bladder to the body's exterior.

Urinary system The kidneys, ureters, bladder, and urethra.

Urine Liquid waste excreted by the kidneys.

Uterine tubes *See* Fallopian tubes.

Uterus (*or* Womb) A hollow muscular organ located above the bladder. Inside it, a fertilized ovum develops into a fetus.

Uvula A conical tag hanging from the back of the palate. It helps to keep food out of the nasal cavities.

Vagina The muscular passage between the vulva and cervix (neck of the uterus).

Vascular Relating to or richly supplied with vessels, especially blood vessels.

Vein A blood vessel that transports blood from capillaries back to the heart. Veins contain valves to prevent the backflow of blood.

Venous Relating to veins.

Ventricle A cavity: one of the two lower chambers of the heart.

Venule A small vein.

Vermiform appendix *See* Appendix.

Vertebra A bone of the vertebral column (plural: vertebrae).

Vertebral column (*or* Backbone *or* Spine) The column of vertebrae between the skull and the hip bones, supporting the body and shielding the spinal cord. It has five sections: cervical, thoracic, lumbar, sacral, and coccygeal.

Vestibule A space before a passage begins, as in the inner ear beyond the oval window, between the semicircular ducts and cochlea.

Vocal cords Two belts of tissue stretched across the larynx which produce sounds when air rushes past them.

Vulva (*or* Pudendum) The external female genitals.

White matter The paler tissue of the brain and spinal cord comprised mainly of myelin-sheathed nerve fibers.

Windpipe *See* Trachea.

Womb *See* Uterus.

There is a lot of useful information on the internet. There are also many sites that are fun to use. Remember that you may be able to get information on a particular topic by using a search engine such as Google (<http://www.google.com>). Some of the sites that are found in this way may be very useful, others not. Below is a selection of Web sites related to the material covered by this book. Most are illustrated, and they are mainly of the type that provides useful facts.

Facts On File, Inc. *takes no responsibility for the information contained within these Web sites. All the sites were accessible in January 2005.*

Anatomy of the Human Body: Gray's Anatomy

Online version of the classic *Gray's Anatomy of the Human Body*, containing over 13,000 entries and 1,200 images.
<http://www.bartleby.com/107/>

Biology Online

A source for biological information, suitable for homework, research projects, and general interest, with hundreds of biology Web site links.
<http://www.biology-online.org>

BIOME

A guide to selected, quality-checked internet resources in the health and life sciences.
<http://biome.ac.uk>

Health Sciences & Human Services Library

Provides links to selected Web sites that may be useful to both students and researchers.
<http://www.hshsl.umaryland.edu/resources/lifesciences.html>

Human Anatomy Online

Interactive resource, with visual keys to text on the human body.
<http://www.innerbody.com>

North Harris College Biology Department

Tutorials and graphics on biology, human anatomy, human physiology, microbiology, and nutrition.
<http://science.nhmccd.edu/biol/>

Open Directory Project: Anatomy

Comprehensive list of internet resources.
http://dmoz.org/Health/Medicine/Basic_Sciences/Anatomy/

Open Directory Project: Physiology

Comprehensive list of internet resources.
<http://dmoz.org/Science/Biology/Physiology/>

The Biology Project

Structured tutorials on life sciences. Particularly strong on cell biology, human biology, and molecular biology.
<http://www.biology.arizona.edu>

University of Texas: BioTech Life Sciences Resources and Reference Tools

Enriching knowledge of biology and chemistry, for everyone from high school students to professional researchers. The Dictionary and Science Resources are particularly useful.
<http://biotech.icmb.utexas.edu>

A

abdomen 54–63
abductor muscles 19
acetabulum 10, 40, 89
acetylcholine 23
Achilles tendon 26, 74, 76, 77, 84
adductor muscles 17, 19, 22
agonistic and antagonistic muscles 26
appendicular skeleton 8, 64
arms 64
 bones 8, 12
 disorders 72–73
 exercises 72–73, 95
 joints 88, 90, 91, 92, 93
 muscles 67, 68, 69, 70
arthritis 33, 82, 98, 99
atlas bone 38, 87, 88
axial skeleton 8, 36–53
axis bone 38, 87, 88

B

biceps brachii muscle 6, 19, 21, 27, 68
 contraction 24
 exercise 72
 tendons 26
birth 18, 40
bone marrow 7, 10
bones 6, 7, 9
 development 13
 exercise benefits 28
 fractures 32
 muscle attachments 26
 structure 14
 types 12
brain 7, 36, 37
breathing 19, 47
bursae 22, 35

C

calcaneus (heel) bone 10, 74, 75, 76, 78, 89
cardiac (heart) muscle 16, 19
carpal (wrist) bones 8, 10, 12, 72–73, 89
carpus (wrist) 10, 64, 65, 87, 90
cartilage 10, 13, 14, 15
 disorders 33
 intervertebral disk 38
 knee joint 100
 nose 36
 ribs 55
cells 32
 bone 10, 14, 32
 muscle 16
cervical vertebrae 8, 38, 39, 54
chest (thorax) 54–63
 joints 88
 muscles 55, 56, 57
chewing (mastication) 42, 45
clavicles (collar bones) 7, 8, 54, 55, 56
 joints 89
 limb skeleton 64, 65
coccyx 8, 10, 38, 40, 41
collagen fibers 15, 26
compact (hard) bone 12, 13, 14, 15
 fracture repair 32
condyles 9, 75
connective tissue 10, 16, 17, 19
cranium 8, 10, 36, 37

D

deep muscles 22, 48, 57, 58

deltoid muscle 6, 20, 21, 25, 46, 67, 68, 69
dentine 43
diaphragm 19, 54, 57
digestive tract 6, 54
dislocation 33, 98, 99
disorders
 arm 72–73
 feet 84–85
 hand 72–73
 joints 98–101
 legs 82–83
 skeleton 98–99

E

ear bones (ossicles) 10, 36
elbow joint 64, 68, 87, 89
embryo skeleton 13
enamel 43
endosteum 14
epiphysis 9, 12, 14
ethmoid bone 36
exercises 28, 29, 30, 31, 34
 arm and hand 72–73
 chest and abdominal muscles 60–63
 face muscles 45
 joints 94–95
 leg and foot 80–81, 85
 posture 96–97
 relaxation 51
 strengthening 52–53
extensor muscles 19, 20
 fingers 70, 71
 foot 79
 limbs 64, 76
eye muscles 18

F

facial bones 8, 36, 37
facial muscles 37, 44

- false ribs 8, 55
 - femur (thigh bone) 7, 8, 9, 74, 75, 89
 - fibroblasts 32
 - fibula 7, 8, 74, 75, 89
 - finger bones (phalanges) 8, 10, 12, 64
 - joints 89, 90, 91, 93
 - muscles 70, 71
 - flat bone 12, 15
 - flexor carpi radialis muscle 6
 - flexor muscles 19, 21
 - fingers 70, 71
 - foot 79
 - limbs 64, 76
 - floating ribs 8, 55
 - foot (metatarsal) bones 8, 10, 78
 - disorders 84–85
 - exercises 80–81
 - joints 93, 101
 - muscles 79
 - frontal bone 10, 36, 37, 88
- G**
- ganglion 34, 35, 72
 - gastrocnemius muscle 6, 20, 21, 26, 76
 - gluteus maximus muscle 19, 20, 25, 46, 48
- H**
- hamstring muscles 77
 - hand bones (metacarpals) 8, 10, 65, 89
 - disorders and exercises 72–73
 - muscles 71
 - Haversian systems 10, 14
 - head and neck joints 88, 92, 101
 - heart 6, 7, 54
 - cardiac muscle 16, 19
 - disease 35
 - exercise 28, 30, 31
 - hip girdle 8
 - hip joint 10, 76, 89, 90, 92
 - problems 101
 - hormones 7
 - humerus 7, 8, 9, 64, 65, 89
 - hyaline cartilage 15, 98
 - hyoid bone 36, 45
- I**
- ilium 10, 40, 74, 88
 - incus 10
 - injuries 28, 29
 - bone fracture 32
 - legs 82–83
 - muscles 34
 - insertion 19, 26
 - intercostal muscles 56, 57
 - intervertebral disk 10, 33, 38, 49
 - intestines 6, 16, 54
 - irregular bones 12
 - ischium 10, 40, 74
- J**
- joints 7, 9, 86–101
 - disorders 33, 98–101
 - elbow 64, 68
 - exercise 31, 94
 - head and neck 88
 - hip 76
 - jaw 88, 92
 - knee 75, 76
 - muscles 6, 26
 - shoulder 66–67
 - types 10, 87, 88–89
 - vertebral column 38
- K**
- knee joint 74, 76, 89
 - disorders 82, 83, 100, 101
- L**
- legs 74–85
 - bones 8, 12
 - disorders 82–83
 - exercises 80–81
 - joints 88, 90, 91
 - muscles 76–77
 - levers 69
 - ligaments 10, 79, 99, 100
 - lips 42
 - long bones 12, 65
 - lumbago 34, 35
 - lumbar vertebrae 8, 38, 39, 54
 - lungs 7, 54, 56, 57
- M**
- magnesium 7
 - malleus 10
 - mandible (lower jaw bone) 8, 36, 37, 42
 - joint 88, 92
 - marrow 7, 13
 - massage 50
 - masseter muscles 45
 - maxillae (upper jaw bones) 10, 36, 37, 42, 88
 - meatus 9
 - medullary cavity 14
 - mesomorphs 30
 - metabolism 31
 - metacarpal (hand) bones 8, 10, 65, 89
 - metatarsal (foot) bones 7, 8, 10, 74, 75, 78, 89
 - minerals 7
 - motor units 23

mouth (oral cavity) 42
 movement
 bones 7
 joints 90–93
 muscles 6, 16
 muscle fibers 23, 25, 27
 muscles 6, 17, 18
 abdomen 54, 58–59
 arm 67, 68, 69, 70
 attachments 26
 back 46–47, 49
 chest 55, 56, 57
 contractions 18, 23, 24
 deep 22
 disorders 34, 35
 exercise 28
 face 37, 44
 hand 71
 leg 76–77
 massage 50
 mouth 42
 neck 45
 pelvis 48
 shoulder 66–67
 superficial 20, 21
 muscular dystrophy 35
 muscular system 6, 16–35
 injuries and disorders 34–35
 myocardium 19
 myopathy 35

N
 nasal bones 36, 37
 neck 45, 92
 neck and head joints 88, 92, 101
 nerve cell (neuron) 23
 nerve disorders 34, 35
 nerve impulse 16, 18, 23

O
 occipital bones 10, 36, 37, 88
 orbit (eye socket) 37
 origin of a muscle 19, 26
 ossification 13
 osteoarthritis 33, 98
 osteoblasts 14, 32
 osteocytes 10
 osteoporosis 33

P
 Paget's disease 99
 palate 42
 parietal bones 10, 36, 37
 patella (kneecap) 10, 12, 74, 75
 pectoralis major muscles 21, 27
 pelvic muscles 48
 pelvis (hip) bones 7, 8, 10, 40, 54
 blood cell production 7
 flat bones 12
 joints 88
 leg bones 74
 periosteum 13, 14, 26
 peristalsis 19
 phalanges (finger and toe bones) 8, 10, 65, 74, 75, 78, 89
 phosphate 7
 posture
 exercises 31, 96–97
 joint problems 101
 muscles 6, 24
 potassium 7
 pubic bone 74, 88
 pubis 10, 40

R
 radius 8, 89

rectus femoris muscle 6, 19, 25, 27
 red bone marrow 7
 relaxation 29, 50–51
 reproductive system 6, 54
 respiration (breathing) 54, 56, 57
 rheumatism 33, 99
 rheumatoid arthritis 33, 98, 99
 ribs 7, 8, 54, 55, 57
 intercostal muscles 25
 joints 88, 90

S
 sacrum 8, 10, 38, 40, 41, 74
 joints 88
 scapula (shoulder blade) 8, 55, 64, 65
 joints 89, 92
 sciatica 82, 83, 101
 scoliosis 33, 97
 sesamoid bones 12, 75
 short bones 12, 15
 shoulder girdle 8, 56
 shoulder joint 87, 89, 91
 dislocation 99
 exercises 95
 muscles 66–67
 problems 101
 sinuses 36
 skeletal (striped, voluntary) muscle 16, 17, 18
 skeletal system 6–7
 bones 8–15
 disorders 33, 98–101
 skeleton 11
 embryonic 13
 skull 7, 8, 9, 10, 12, 36–37
 sleep 29
 slipped disk 33

smooth (involuntary, visceral) muscle 16, 17, 18
 spasm 34, 35
 speech 42
 sphenoid bone 9, 36
 sphincter muscle 19
 spinal cord 7, 38, 39
 spinal disorders 97
 spinal muscles 46–47, 49
 spongy (cancellous) bone 12, 13, 14, 15, 32
 sprained ligaments 99, 100
 sternum (breastbone) 7, 8, 54, 55, 88, 89
 stitch 35
 stomach 16, 54
 superficial muscles 16, 20–21
 back 46
 chest 57
 pelvis 48
 suture joints 10, 86, 88
 swollen ankles 82
 symphysis 10, 40, 88, 98
 synovial joints 10, 86, 88, 89, 99

T

tarsal (ankle) bones 8, 10, 12, 74, 75, 78
 joint 89, 90, 101

teeth 42, 43, 86
 temporal bone 9, 10, 36, 37, 88
 temporalis muscle 6, 22, 45
 tendons 10, 16, 19, 26
 arm 69, 70
 disorders 33, 34
 foot 79
 knee joint 100
 leg 75
 tension, muscular 50
 tensor muscle 19
 thoracic vertebrae 8, 38, 39, 54, 55
 tibia (shin bone) 7, 8, 74, 75, 89
 toe bones (phalanges) 8, 10, 12, 75, 91, 93
 tongue 42
 torso, chest 56
 transversus abdominis muscle 6, 19, 25, 58
 trapezius muscle 20, 21, 45, 46, 66
 triceps brachii muscle 19, 20, 72

U

ulna 8, 10, 65, 89
 urinary system 6, 18, 54
 uterus 18, 54
 uvula 42

V

varicose veins 82–83, 101
 vertebrae 7, 8, 10, 38, 39
 features 9
 irregular bones 12
 joints 88, 90
 vertebral column
 (backbone, spine) 7, 10, 38, 90
 disorders 98
 joint exercises 94
 muscles 46–47, 49
 vitamin D 33

W

whiplash injury 99, 101

Y

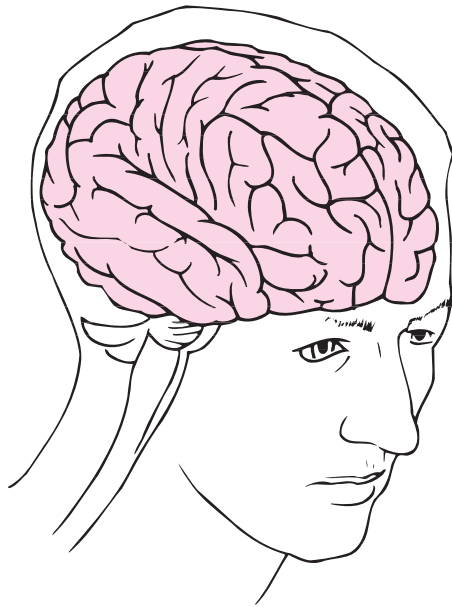
yellow bone marrow 7, 14

Z

zygomatic bone
 (cheekbone) 10, 36, 37

THE FACTS ON FILE
ILLUSTRATED GUIDE TO
THE HUMAN BODY

BRAIN AND NERVOUS SYSTEM



THE DIAGRAM GROUP

The Facts On File Illustrated Guide to the Human Body: Brain and Nervous System

Copyright © 2005 The Diagram Group

Editorial: Lionel Bender, David Harding, Tom Jackson
Denis Kennedy, Gordon Lee, Jamie Stokes

Scientific consultant: Stephen Rudd

Design: Anthony Atherton, Richard Hummerstone,
Lee Lawrence, Kim Richardson, Ben White

Illustration: Pavel Kostal, Kathleen McDougall

Picture research: Neil McKenna

Indexer: Jane Parker

All rights reserved. No part of this book may be reproduced or utilized in any form or by any means, electronic or mechanical, including photocopying, recording, or by any information storage or retrieval systems, without permission in writing from the publisher. For information contact:

Facts On File, Inc.
132 West 31st Street
New York NY 10001

Library of Congress Cataloging-in-Publication Data

The Facts On File illustrated guide to the human body. Brain and nervous system / the Diagram Group.

p. cm.

Includes index.

ISBN 0-8160-5986-1 (hc : alk. paper)

1. Nervous system—Juvenile literature. 2. Brain—Juvenile literature. I. Title: Illustrated guide to the human body. Brain and nervous system. II. Title: Brain and nervous system. III. Diagram Group.

QP361.5.F33 2005

612.8—dc22

2004022925

Set ISBN: 0-8160-5979-9

Facts On File books are available at special discounts when purchased in bulk quantities for businesses, associations, institutions, or sales promotions. Please call our Special Sales Department in New York at 212/967-8800 or 800/322-8755.

You can find Facts On File on the World Wide Web at
<http://www.factsonfile.com>

Printed in the United States of America

EB Diagram 10 9 8 7 6 5 4 3 2 1

This book is printed on acid-free paper.

Note to the reader

This book is not intended to serve as a medical textbook for either physicians or patients. The information and advice it contains should not be used or relied upon without consulting the advice of a qualified physician. The publishers disclaim any responsibility for the accuracy of the information or advice that this book contains and any responsibility for any consequences that may result from any use or reliance thereon by the reader.

Contents

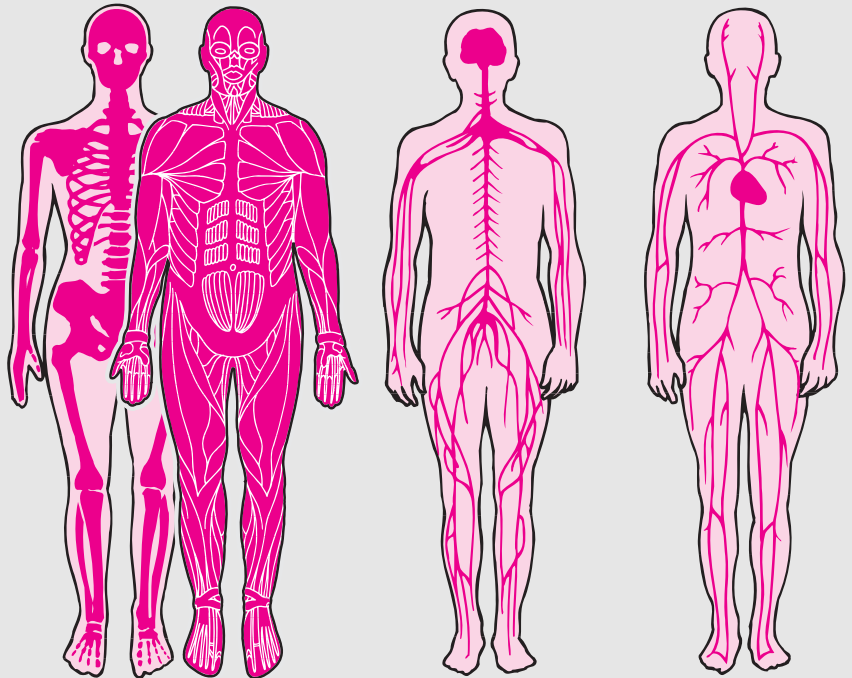
Introduction: About this book	4	Cranial nerves	62
SECTION 1		Shoulder, chest, and arm nerves	64
NERVOUS SYSTEM		Hip and leg nerves	66
Introduction	6	Skin nerves	68
Nervous system organization	8	Nerve plexi	70
Nerves and brain key words	10	Protecting the nervous system	72
Nerve cells—neurons	12	Nerve damage and disorders	74
Types of nerve cell	14	SECTION 4	
Nerve impulses	16	AUTONOMIC NERVOUS SYSTEM	
Nerve synapses	18	Introduction	76
Sensory nerves and sense perception	20	Sympathetic control	78
Motor nerves and muscle control	22	Parasympathetic control	80
Reflexes	24	SECTION 5	
Endocrine system	26	HORMONAL SYSTEM	
Pituitary gland and hypothalamus	28	Introduction	82
Major nervous system disorders	30	Endocrine glands and hormones	84
SECTION 2		How hormones work	86
BRAIN		Thyroid and parathyroid glands	88
Introduction	32	Thymus and pineal glands	90
Brain development	34	Adrenal glands	92
Brain: external features	36	Pancreas as a hormonal gland	94
Brain: internal structures	38	Negative feedback and hormones	96
Brainstem and midbrain	40	Sex glands and hormones	98
Brain functions	42	Endocrine disorders and stress	100
Memory	44	Glossary of the human body	102
Sleep	46	Web sites to visit	108
Stress and mental illness	48	Index	109
Exercises to relieve stress	50		
Drugs and the brain	52		
Brain disorders	54		
SECTION 3			
SPINAL CORD			
Introduction	56		
Spinal cord	58		
Spinal nerves	60		

This book is a concise, illustrated guide to the anatomy, physiology, well-being, and disorders of the human brain and nervous system. It has been written and illustrated specially for students and laypeople interested in medicine, health, fitness, and first aid. The subject is dealt with in clear steps, so that the reader can steadily acquire a good overall understanding. Explanatory texts, diagrams, illustrations, captions, and fact boxes are combined to help readers grasp important information at a glance. A glossary of scientific and jargon words defines medical terms in everyday language. A list of Web sites provides links to other relevant sources of information, and the index enables quick access to articles.

There are five sections within the book. The first section looks in detail at the organization and components of the nervous system. The following three sections survey each major region of the system. The last section looks at the hormonal system, which works in conjunction with the nervous system to control all the body's actions and reactions. Within each section, discussion and illustration of the structure and function of anatomical parts are followed by the general principles of healthcare, fitness, and exercise, and a survey of the main disorders and diseases affecting the region. Information is presented as double-page topics arranged in subsections.

Human body systems

This book is one of eight titles in THE FACTS ON FILE ILLUSTRATED GUIDE TO THE HUMAN BODY series, which looks at each of the major body systems in turn. Some of the titles in the series include more than one system. The skeletal and muscular systems, and the blood and lymphatic systems, for example, work in conjunction and so are treated together. There is a separate title for human cells and genetics, which are the building blocks and underlying chemistry of all body systems.



**Skeletal and
Muscular Systems**

**Brain and
Nervous System** **Heart and
Circulatory System**

Section 1: NERVOUS SYSTEM deals with individual nerve cells and how they create and send nerve impulses, or messages, round the body. It also looks at the organization of the hormonal system.

Section 2: BRAIN surveys the external and internal features and components of the brain. This includes discussion of mental activity, stress, and the effects of drugs and alcohol on the brain.

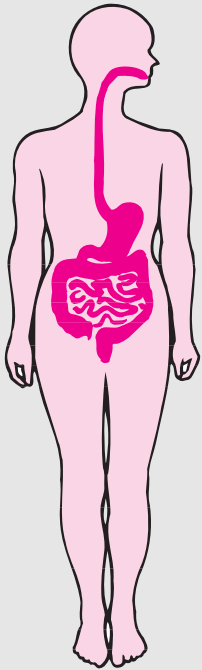
Section 3: SPINAL CORD describes how nerve impulses travel back and forth between the brain, muscles, and the rest of the body.

Section 4: AUTONOMIC NERVOUS SYSTEM features that part of the nervous system that controls all actions and reactions outside conscious control.


Section 5: HORMONAL SYSTEM looks at the endocrine glands and the effects of the hormones they produce.

This book has been written by anatomy, physiology, and health experts for non-specialists. It can be used:


- as a general guide to the way the human body functions
- as a reference resource of images and text for use in schools, libraries, or in the home
- as a basis for examination preparation for students of human biology, medicine, nursing, physiotherapy, and general healthcare.



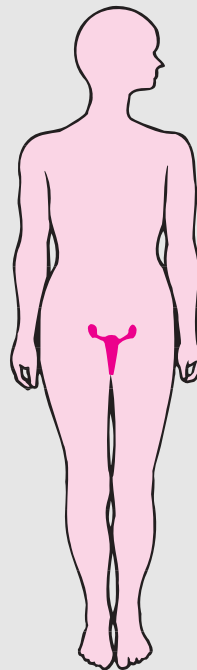
Digestive System



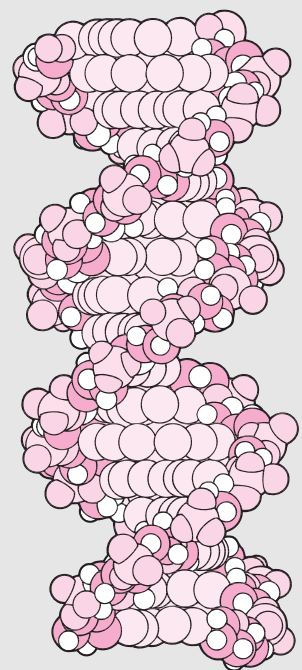
The Senses



Respiratory System

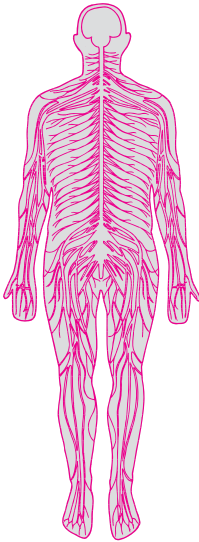


Reproductive System



Cells and Genetics

The nervous system controls and correlates basic bodily functions and behavior. There are two main parts: the central nervous system, which consists of the brain and spinal cord, and the peripheral nervous system, which is made up of cranial nerves, spinal nerves, and the nerves of the autonomic (involuntary) nervous system. The body monitors itself and its surroundings through receptors. These are nerve endings specialized in registering specific stimuli. Changes inside the body are detected by internal proprioceptors and interoceptors. Stimuli from outside the body are detected by receptors called exteroceptors, which are concentrated in the skin, eyes, nose, tongue, and ears. They detect changes in contact (touch), pressure, pain, heat, cold, light, scent, taste, and sound. Together these receptors perform functions known as the senses.



Nervous system

The brain and spinal cord are connected to the rest of the body by a network of nerves.

Neurons Neurons are nerve cells. They are made up of a central cell body, an axon, and branched dendrites. The nervous system is a network of neurons that carries signals in the form of electric pulses. The pulses are generated electrochemically by the movement of ions (charged particles) across membranes. Pulses begin at the synapses (junctions) between the axon of one cell and the dendrites of another. The configuration of dendrites divides neurons into three types: unipolar, bipolar, and multipolar. Bundles, or fibers, of sensory (also called afferent) neurons carry signals from unipolar or bipolar receptor neurons to the central nervous system. From there, motor (also

known as efferent) neurons conduct impulses to muscles.

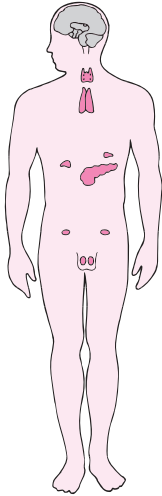
Brain An outgrowth of the spinal cord, the brain is protected by the cranium, or skull. It has three main regions: the hindbrain, midbrain, and forebrain. The hindbrain features the medulla oblongata, pons, and cerebellum. The hindbrain controls breathing and muscle coordination, and regulates other vital life processes. The midbrain acts largely as a relay station. The forebrain, comprising the diencephalon (between brain) and telencephalon (endbrain), is the part of the brain that handles higher mental functions, such as thinking, language, and consciousness.

Spinal cord From the brain, the spinal cord extends down inside the spine, bulging at intervals where pairs of spinal nerves branch out to other parts of the body. Its main role is to provide a highway for nerve impulses passing to and from the brain, but it also processes basic sensory information and initiates appropriate motor responses without recourse to the brain. These movements are known as reflexes.

Cranial nerves These 12 pairs of peripheral nerves emerge directly from the brain. (All other nerves connect to the

Endocrine system

Glands produce chemical messengers called hormones that regulate some bodily functions and development.



brain via the spinal cord.) Some cranial nerves serve facial, throat, and chest muscles; others control the sense organs, such as the eyes, ears, and tongue. The vagus nerve is a direct link to the heart.

Spinal nerves These 61 nerves sprout from the spinal cord. In descending order they are grouped as: cervical, thoracic, lumbar, sacral, and coccygeal nerves.

Autonomic nervous system This is a system of neurons that controls involuntary processes in the body such as digestion and locomotion. The sympathetic subsystem enhances muscle activity, while the parasympathetic system serves to calm the body down again.

THE SENSES

Skin The body covering has a thin outer layer (epidermis) and a thicker, deeper layer (dermis or corium) overlying subcutaneous fat. As well as forming a protective barrier to infection, skin also contains mechanoreceptors sensitive to touch and pressure, and thermoreceptors sensitive to temperature. Nails, hairs, sweat glands, and sebaceous glands are appendages of the skin.

Eyes Each eyeball is positioned in an orbit (eye socket) at the front of the skull. Light rays enter the eye through the cornea (a transparent area at the front of the sclera), which acts as the eye's main "lens." The rays then pass through the anterior chamber and the pupil (central opening in the iris) before being further focused by the lens (sometimes called the crystalline lens). Focused rays produce an inverted image on the retina at the back of the eye, where they are converted into electrical impulses by photoreceptor cells (known as rod and cone cells for their shape). The impulses are then transmitted via the optic nerve to the optical cortex at the rear of the brain's cerebral hemispheres to be processed into a mental image.

Nose Chemoreceptors in two olfactory membranes—one in each nasal cavity—register airborne scent molecules, triggering nerve signals to olfactory bulbs that are linked with the brain's limbic system.

Tongue Taste chemoreceptors on papillae (protruding taste buds) on the tongue and also lining the mouth, throat, and nostrils register combinations of tastes. Nerves transmit signals to the brain.

Ears Sound waves reaching an ear pass from its fleshy auricle through the external auditory canal to the middle ear, vibrating in sequence the tympanic membrane (eardrum) and ossicles (tiny bones called the malleus, incus, and stapes). These bones agitate fluid in the inner ear which in turn vibrates a lining of hairlike cells. From there, nerve impulses go to the brain's temporal lobes. The inner ear's vestibular system registers the head's position and so helps to control body balance and give a perception of orientation and direction of movement.

System subdivisions

The nervous system is organized into subdivisions. The brain and spinal cord make up the central nervous system (CNS). This is the control center where all information from the external senses and internal organs is processed and interpreted. The response to every stimulus also comes from the CNS. The CNS is connected to the rest of the body by the peripheral nervous system. This is a network of nerves spreading out from points on the spinal cord and the brain. The peripheral nervous system is itself divided into two subdivisions: the

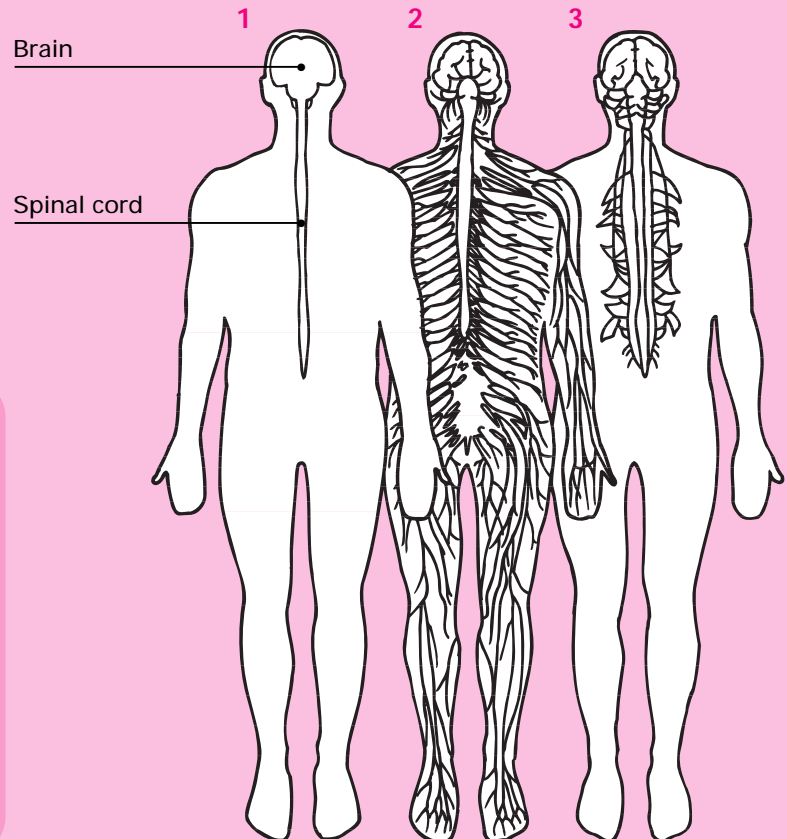
somatic and autonomic nervous systems. The somatic nervous system carries signals to skeletal muscles. These muscles control voluntary movements.

The autonomic nervous system carries signals to glands, organs, and the muscles in the heart and digestive system that are not under voluntary control.

1 Central nervous system

2 Somatic nervous system

3 Autonomic nervous system



Functions

The functions of the nervous system are:

- to sense changes (called stimuli) both outside and within the body (sensory input);
- to transmit information to the brain (integration);
- to make changes to the functioning of muscles and glands (motor output).

The nervous system

The nervous system has two main parts that act as a single unit: the central nervous system (CNS) and the peripheral nervous system (PNS).

Central nervous system (CNS)

The CNS comprises the brain and spinal cord. It is the body's control center, receiving and transmitting information via the peripheral nervous system.

Peripheral nervous system (PNS)

The PNS comprises all of the nerves and nerve processes that connect the CNS with receptor cells, muscles, and glands.

Afferent system

This comprises nerve cells (called sensory neurons) that convey information from receptors in the body to the CNS.

Efferent system

This comprises nerve cells (called efferent or motor neurons) that convey information from the CNS to muscles and glands.

Somatic nervous system (SNS)

Efferent neurons conduct impulses from the CNS to skeletal muscles. This system is under voluntary (conscious) control.

Autonomic nervous system (ANS)

Efferent neurons convey impulses away from the CNS to smooth muscle tissue, the heart, and glands. It is under involuntary (unconscious) control.

Sympathetic nervous system

This comprises the nerves that adjust bodily activity involuntarily, opposing the parasympathetic system. The sympathetic system is dominant during times of stress.

Parasympathetic nervous system

This comprises the nerves that adjust bodily activity involuntarily, opposing the sympathetic system. Broadly, the parasympathetic system takes over during periods of relaxation.

NERVES AND BRAIN: KEY WORDS

Afferent Nerves that are directed toward a central organ or obvious region of the body. The afferent (or sensory) nerves of the peripheral nervous system send impulses to the central nervous system.

Arachnoid The middle of the three meninges, with a weblike appearance.

Autonomic nervous system Part of the peripheral nervous system that is not under conscious control. It operates smooth muscle (in the gut), cardiac muscle, and glands. It is divided into the sympathetic and parasympathetic nervous systems, which normally balance each other.

Brachial plexus A network of spinal nerves, arising in the neck and upper back, occupying the axilla (armpit), and supplying many arm muscles.

Brain The body's chief control center, containing billions of interconnected nerve cells. It receives, collects, processes, and stores information, and controls the body's responses.

Brainstem A stalklike part of the brain, between the cerebrum and spinal cord. It contains the midbrain, pons, and medulla oblongata.

Cauda equina A bundle of nerve roots from the lumbar, sacral, and coccygeal spinal nerves that hangs below the end of the spinal cord.

Central nervous system (CNS) The brain and spinal cord.

Cerebellum The largest part of the hindbrain. Literally "the little brain," the cerebellum helps produce smoothly controlled and coordinated muscular movements.

Cerebrum The upper, major part of the brain, comprising cerebral hemispheres and diencephalon. It handles consciousness and the mind, learning, memory, emotions, sensations, and voluntary movements.

Cortex The outer layer of the brain.

Cranial nerves Twelve pairs of nerves linking the underside of the brain with parts of the head, neck, and thorax. Some feed sensations from the eyes, nose, and ears to the brain.

Dermatome The area of skin supplied by an individual spinal nerve.

Diencephalon The "between brain" area of the forebrain between the midbrain and cerebral hemispheres. It includes the thalamus and the hypothalamus.

Efferent Directed away from a central organ or part of the body. Efferent nerve fibers are those that carry signals away from the central nervous system.

Gray matter The darker tissue of the brain and spinal cord, mainly consisting of neurons' cell bodies and dendrites.

Hindbrain Structures below the midbrain, comprising the brainstem and cerebellum.

Hypothalamus A structure in the diencephalon, above the midbrain. Its centers control emotion, hunger, and thirst, and it releases hormones that trigger the production of other hormones by the pituitary gland.

Lumbar plexus A network of spinal nerves arising in the lower back that connects to parts of the abdomen, genital area, and legs.

Medulla oblongata The lowest part of the brainstem, containing the vital centers that control heartbeat and respiration.

NERVE AND BRAIN: KEY WORDS (CONTINUED)

Meninges Three protective membranes surrounding the brain and spinal cord: the pia mater, arachnoid, and dura mater.

Midbrain The top of the brainstem, between the diencephalon and pons. It is a relay station for sensory impulses.

Mind The mental entity that encompasses a person's identity. The mind is distinct from the brain.

Motor neurons (or efferent neurons)

Nerve cells that transmit information from the central nervous system to an effector organ such as a muscle.

Nerve A bundle of nerve fibers (axons) that transmit impulses to (in the case of sensory nerves) or from (in the case of motor nerves) the central nervous system. Mixed nerves contain both sensory and motor fibers.

Nervous system The coordinated networks of neurons that control the body. It is divided into the central nervous system (brain and spinal cord), and the peripheral nervous system (the somatic and autonomic nervous systems).

Neuron A nerve cell: the basic unit of the nervous system responsible for conveying electrochemical nerve impulses around the body.

Parasympathetic nervous system The part of the autonomic nervous system that predominates when the body is at rest.

Peripheral nervous system A network of nerves linking the brain and spinal cord to other parts of the body. It is divided into the autonomic nervous system, which is not under conscious control, and the somatic nervous system, which is.

Plexus A network of nerves (or blood or lymph vessels).

Ramus A branch, especially of a nerve or blood vessel.

Reflex action The body's automatic involuntary response to a stimulus.

Sacral plexus A network of spinal nerves arising in the sacral and lumbar region, supplying parts of the leg, buttocks, and genital area.

Sensory neurons (or afferent neurons)

Nerve cells that send signals to the central nervous system.

Somatic nervous system The part of the peripheral nervous system that sends motor impulses to skeletal muscles.

Spinal cord The cable of nerve tissue running down inside the vertebral column and linking the brain with nerves supplying most of the body.

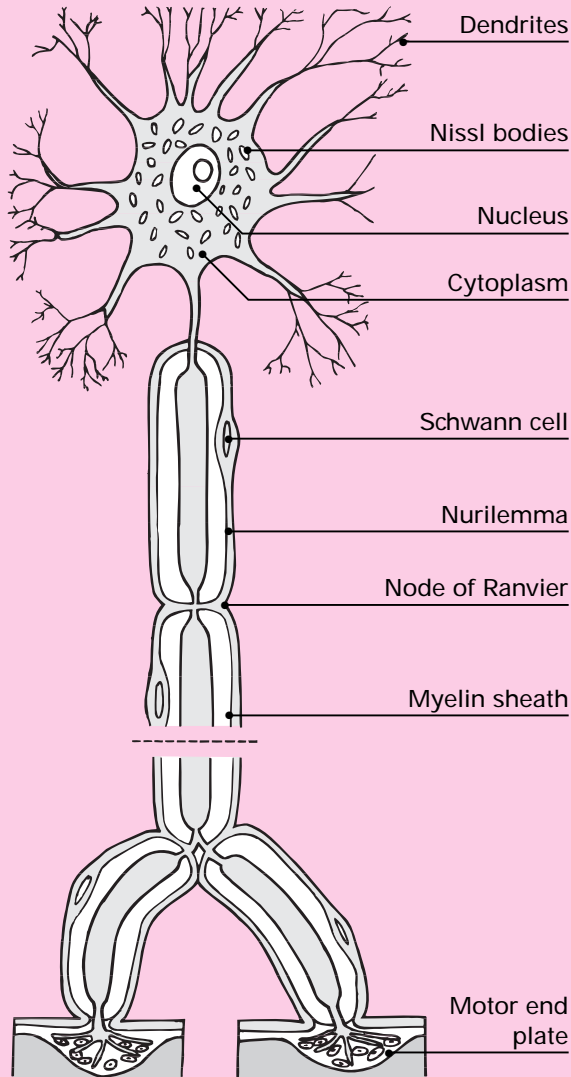
Spinal nerves Thirty pairs of nerves and one single nerve (which soon divides) that branch directly from the spinal cord.

Sympathetic nervous system The part of the autonomic nervous system that prepares the body to cope with impending threats by fighting or fleeing. For example, blood is directed to the muscles and away from the skin and digestive system and heart rate is increased. This response is linked to the hormone epinephrine.

Thalamus A brain structure above the hypothalamus. It sends sensory impulses to the cerebral cortex, links sensations with emotions, and affects consciousness.

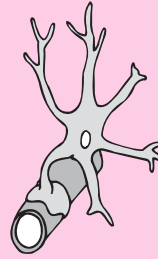White matter The paler tissue of the brain and spinal cord, mainly comprising nerve fibers sheathed with myelin fat.

Multipolar neuron

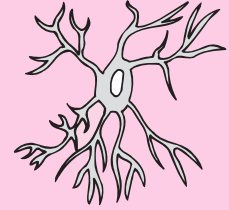


Schwann cells


Schwann cells and satellite cells—found in the peripheral nervous system—are sometimes considered to be neuroglia.



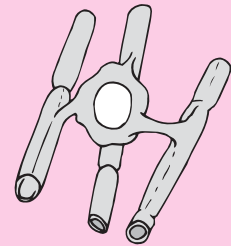
a Astrocytes



b Microglia



c Ependymal cells



d Oligodendrocytes

Neuroglia

The nervous system also contains neuroglia cells. These do not conduct nerve impulses. Instead, they support and protect neurons. They are capable of mitosis (so if damaged can be replaced). There are four types of neuroglia within the central nervous system.

a Star-shaped astrocytes cling to neurons and help protect them.

b Smaller microglia are spiky and help get rid of dead brain cells and bacteria.

c Ependymal cells line the ventricles of the spinal cord and brain, and their cilia (hairlike fronds) help circulate cerebrospinal fluid.

d Long-extended oligodendrocytes wrap around and protect nerve fibers.

NEURONS: KEY WORDS

Axodendritic synapse The synaptic junction between the axon of one neuron and the dendrites of another.

Axon A single process extending from the cell body of a neuron, taking impulses away from the cell body.

Axosomatic synapse The junction between the axon of one neuron and the body of another.

Bipolar neuron A nerve cell with two processes: a dendrite leading into the cell body, and an axon leaving it.

Cell body The main part of a neuron containing the nucleus.

Dendrites Short fibers branching out from the cell body of a neuron that receive impulses from other neurons.

Interoceptor A sensory nerve ending found in internal organs that responds to changes inside the body.

Motor end plate The terminal formed at the end of a motor neuron axon that connects the nerve to a muscle fiber.

Multipolar neuron A nerve cell with more than two processes (usually one axon and multiple dendrites, but sometimes only dendrites) extending from its cell body.

Myelin The fatty white substance forming an insulating sheath around some axons. White matter in the brain and spinal cord contains myelinated nerve fibers, while gray matter contains unmyelinated fibers.

Nerve fiber The axon of a neuron.

Neurilemma The thin membrane covering the myelin sheath of long nerve fibers or the axons of other unmyelinated nerve fibers.

Neuroglia Cells in nerve tissue that support the cells that convey nerve impulses.

Neurotransmitter A chemical released at nerve endings to carry nerve impulses across synapses. Examples include acetylcholine, noradrenaline, and dopamine.

Nissl bodies Collections of granular material in the cytoplasm of neurons.

Nodes of Ranvier Narrow gaps in the myelin sheath, between adjacent Schwann cells, through which axon branches leave.

Perikaryon The part of a neuron containing the nucleus.

Postsynaptic Situated distally to a synapse (further away from the central nervous system; CNS), or after a synapse is crossed.

Presynaptic Situated proximally to a synapse (nearer to the CNS), or before a synapse is crossed.

Receptor A structure, such as a sensory nerve ending, specialized to detect environmental stimuli.

Schwann cell A separate cell completely enclosed by the neurilemma that produces a nerve fiber's myelin sheath.

Synapse The junction between two neurons (or between a neuron and an effector organ), consisting of a tiny gap known as the synaptic cleft, across which nerve impulses are transmitted by a chemical neurotransmitter.

Synaptic Relating to a synapse.

Synaptic knob The thickened area at the end of a presynaptic axon. (Also known as Boutons terminal; plural: Boutons terminaux).

Unipolar neuron A neuron that has just a single process (axon) extending from its cell body. Unipolar neurons are generally associated with receptors.

Neurons by structure

a Bipolar neurons

These have one process (dendrite) leading into the cell body and another process (axon) leaving it. This type of neuron is mostly found in the retina of the eye.

b Unipolar neurons

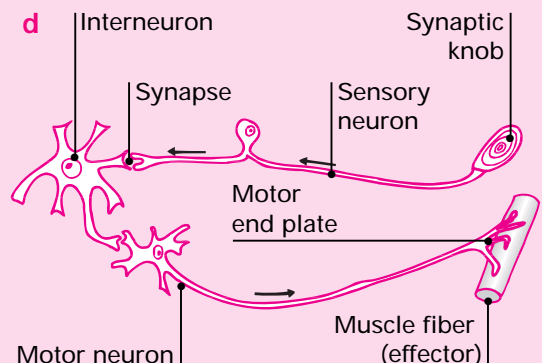
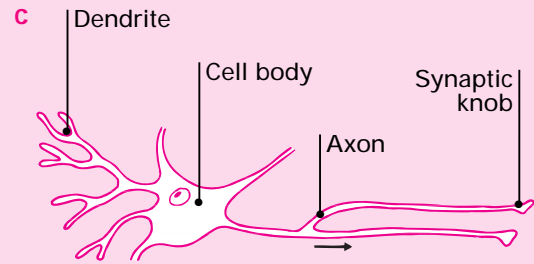
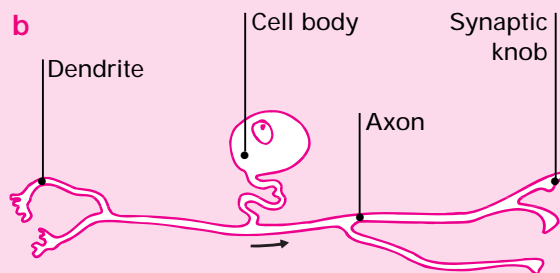
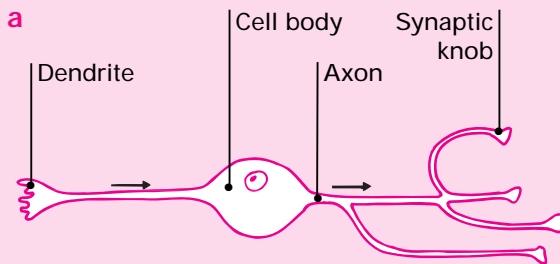
Unipolar neurons (sometimes called pseudounipolar) originate as bipolar neurons, but during development their two processes fuse to form a single process. They are found in a chain of ganglia (clusters of nerve cells, largely in the peripheral nervous system) that runs parallel to the spinal cord.

c Multipolar neurons

These are the most common type of neuron. They have multiple (three or more) processes (axons and dendrites) projecting from the cell body and are found everywhere in the central nervous system. Although most have one axon and many dendrites, there are some that have only dendrites.

d Interneurons

Interneuron, or association neurons, are the link between sensory neurons and motor neurons. Interneurons are found in the central nervous system. They are multipolar and tend to have short processes.



Neuron	Structure	Function
Afferent (sensory neuron)	<ul style="list-style-type: none"> • Cell body located in PNS • Short axon ("trunk") extending into CNS • Long dendrites (branched projections) located in the PNS 	<ul style="list-style-type: none"> • Brings signals to the CNS from elsewhere in the body
Efferent (motor neuron)	<ul style="list-style-type: none"> • Cell body located in CNS • Long axon extending into PNS • Short dendrites located in CNS 	<ul style="list-style-type: none"> • Sends out signals from the CNS to the body
Interneuron	<ul style="list-style-type: none"> • Short or long axon located in the CNS • Short dendrites in the CNS 	<ul style="list-style-type: none"> • Transmits impulses between afferent and efferent neurons

Neurons by function

Neurons (nerve cells) are linked together to form a network. The simplest of these networks control reflex actions (see pages 24–25), which are totally automatic and involuntary. More complex networks are used to control voluntary movements.

Neural circuits

The pathways are often called neural circuits, since they carry an electrical impulse. The impulse generally begins in a unipolar afferent neuron that is connected to a receptor of some sort in the peripheral nervous system.

The impulse travels along the cell's axon and passes into the central nervous system (CNS). The impulse may make the journey to the CNS along a single axon, or it will more probably be passed between several afferent neurons en route. Afferent impulses generally enter the CNS at the spinal cord via one of the spinal nerves.

Connections

Once it arrives in the CNS, the impulse passes to another neuron. Instead of an electrical pulse passing between cells, signals are transferred by chemical means across a tiny gap called a synapse (see pages 18–19). In the simplest reflex pathways, the afferent neuron passes to an interneuron. Then the impulse is passed on to an efferent neuron, which carries the signal out of the CNS to an effector, such as a muscle.

More complex pathways involve impulses being passed on to several parts of the CNS. In these cases, the impulse is first passed to a multipolar neuron. (Most of the neurons in the CNS are multipolar.) From there the signal may be passed on to several more multipolar neurons as it is redirected around the brain. One of these multipolar neurons will be connected to one or several efferent neurons, which carry a response signal across the peripheral system to the relevant effector.

Neurons

In complex animals, nerve cells form the organs of the central nervous system (CNS)—the brain and spinal cord—and peripheral nervous system (PNS), which comprises nerves and nerve processes (extensions) that connect the CNS to muscles, glands, and receptors.

Structure

Nerve cells do not reproduce themselves by mitosis (cell division). Neurons are said to be amitotic: if destroyed, they cannot be replaced. Ganglia are dense clusters of nerve-cell bodies outside of the CNS.

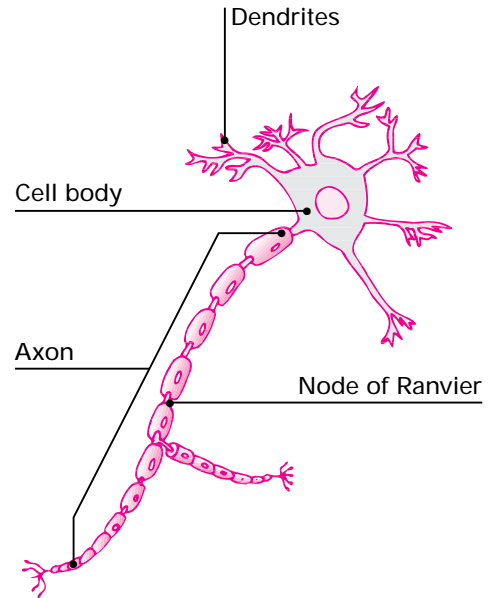
All neurons contain the same elements, listed below.

Cell body This includes a nucleus and cytoplasm.

Axon This is a long, slim “trunk” that transmits information from the cell body to other cells via junctions known as synapses. Some axons are only a fraction of an inch long; others are over a yard (90 cm) long. Most axons are sheathed in a fatty substance called myelin, which helps speed up the conduction of electrical impulses. Constrictions at regular intervals along the axon are called the nodes of Ranvier.

Dendrites These are networks of short fibers that branch out from the axon or cell body and link the ends of axons from other neurons. Dendrites are the cell’s receivers of information, bringing signals to their neuron’s own cell body. Each neuron might have hundreds of dendrites.

Structure of a neuron

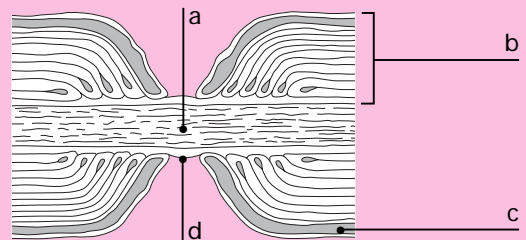


Function

Neurons communicate electrochemically with each other to transmit impulses throughout the body.

Myelin sheath

- Schwann cells spiral around one or more axons (a) forming a myelin sheath.
- This consists of multiple layers (perhaps 50 to 100) of plasma membranes (b), between which liquid cytosol is excluded from all except the outermost layer (c).
- The myelin sheath around a long axon is divided into segments, each



produced by a single Schwann cell.

- Consecutive segments are separated by gaps, called the nodes of Ranvier (d), where the axon is unsheathed.

Nerve impulses

In complex animals, messages are sent around the body and to and from the brain by electrical impulses transmitted via nerves. Nerves emit impulses when stimulated by a physical, chemical, or electrical event that alters the cell membrane.

1 Resting neuron

A resting neuron is negatively charged inside the cell membrane (a) and positively charged outside the cell membrane (b). This is called the resting membrane potential.

It is maintained by two factors:

- The differential permeability of the cell membrane to sodium and potassium ions, both of which have an equal positive charge. Sodium diffuses into the cell more slowly than potassium diffuses out of the cell.
- The sodium-potassium pump, which drives more positive ions out of the cell than it drives in. As a result, more positive ions collect on the outside of the cell membrane than on the inside.

2 Stimulated neuron

When a neuron is stimulated, the permeability of a patch (c) on the cell

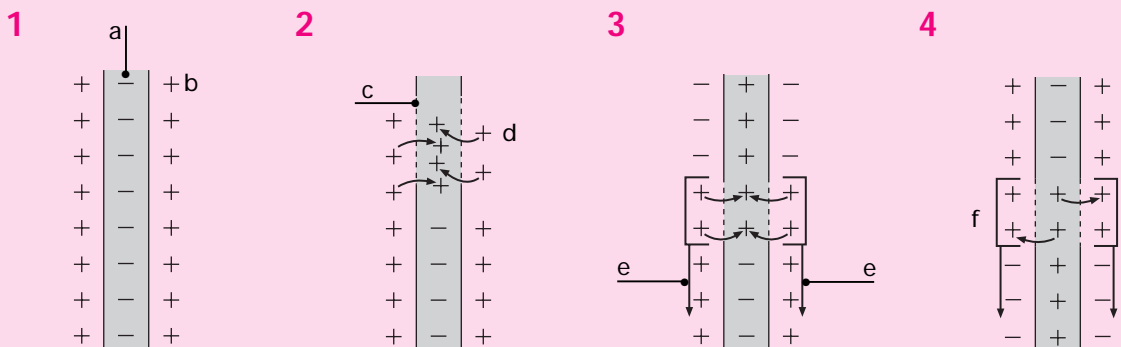
membrane alters. Positively charged sodium ions (d) begin to enter the cell more quickly than during the resting state, making the local area inside positive. This is called depolarization.

3 The nerve impulse

Depolarization spreads along the cell membrane (e). Eventually, the charge on either side of the cell membrane is temporarily reversed. This is called reverse polarization. It is, in fact, the nerve impulse traveling along the nerve cell's membrane.

4 Repolarization

The cell membrane alters its permeability again. Positively charged sodium ions (Na^+) begin to pass out of the cell (f). Finally, the outside of the cell is again positively charged, and the inside negatively charged. This process is called repolarization.

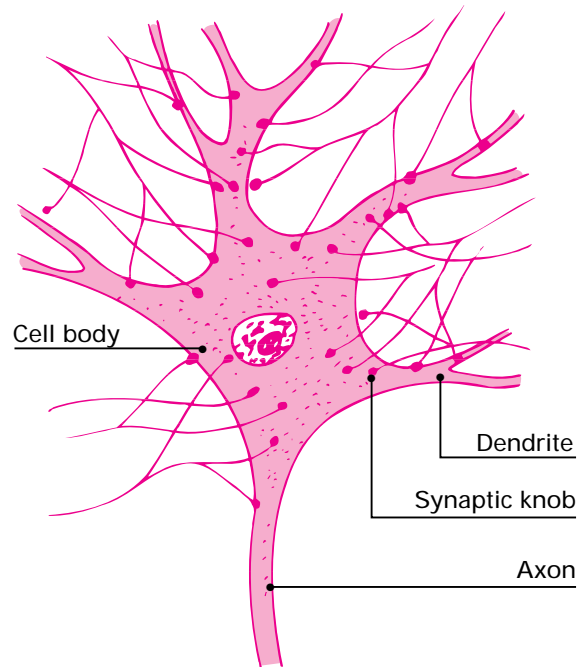


The junction between two neighboring neurons (nerve cells) is called a synapse. Synapses are features that connect one neuron (the presynaptic neuron) to another (the postsynaptic neuron). Synapses are actually tiny gaps. There is no physical connection between cells. Tiny bulges called synaptic knobs at the end of each presynaptic axon approach the dendrites, axons, or cell body of the postsynaptic cell. It is through the synaptic knobs that neurotransmitters are emitted.

Neurotransmitters

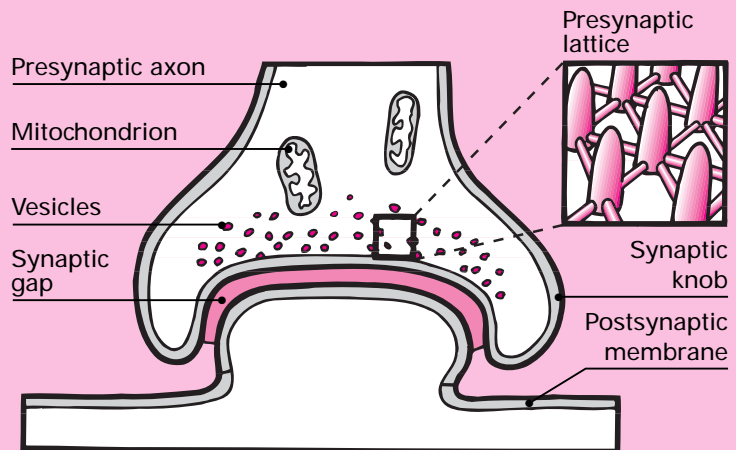
Neurotransmitters are molecules that act as chemical messengers, transferring an electrical impulse from one cell to the next. They cross the synapses between the synaptic buttons of one neuron and the dendrite of another. Chemicals that allow an impulse to continue flowing through a neuron are called excitatory neurotransmitters. Inhibitory neurotransmitters block electrical impulses.

Junction between two neurons



Anatomy of a synapse

An axon terminates in a synaptic knob. This does not touch the neighboring neuron, but leaves a tiny gap, or synapse, between the pre- and postsynaptic membranes. Mitochondria in the axon produce the energy needed for neurotransmitters to be released. These are contained in vesicles before being released through the presynaptic lattice to cross the gap and pass through the postsynaptic membrane.



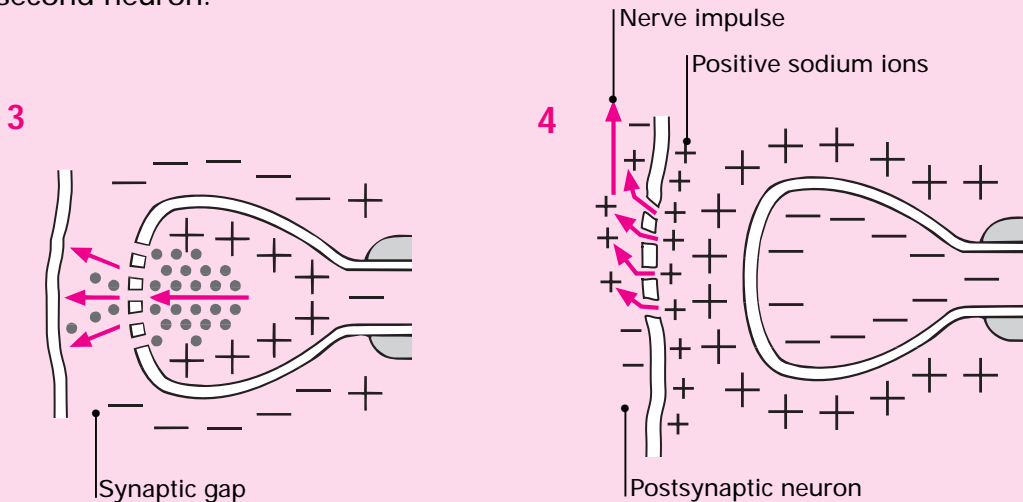
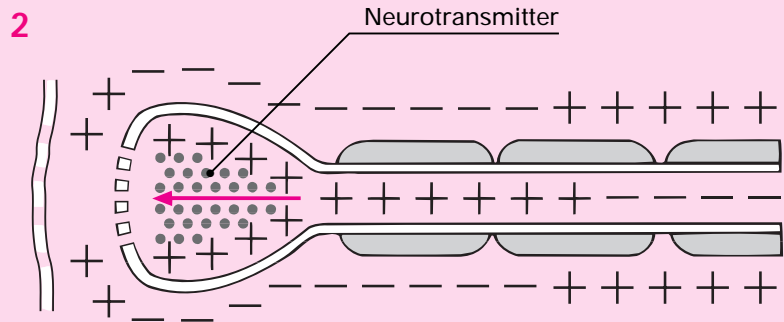
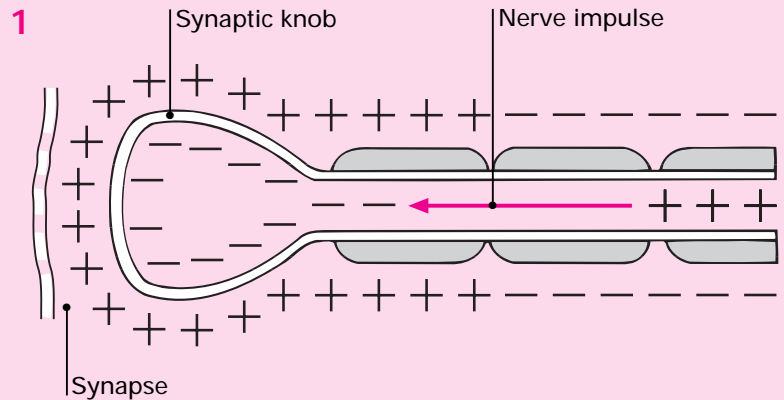
How synapses work

1 A nerve impulse arrives at the synaptic knob of a synapse.

2 Neurotransmitters are released into the synapse.

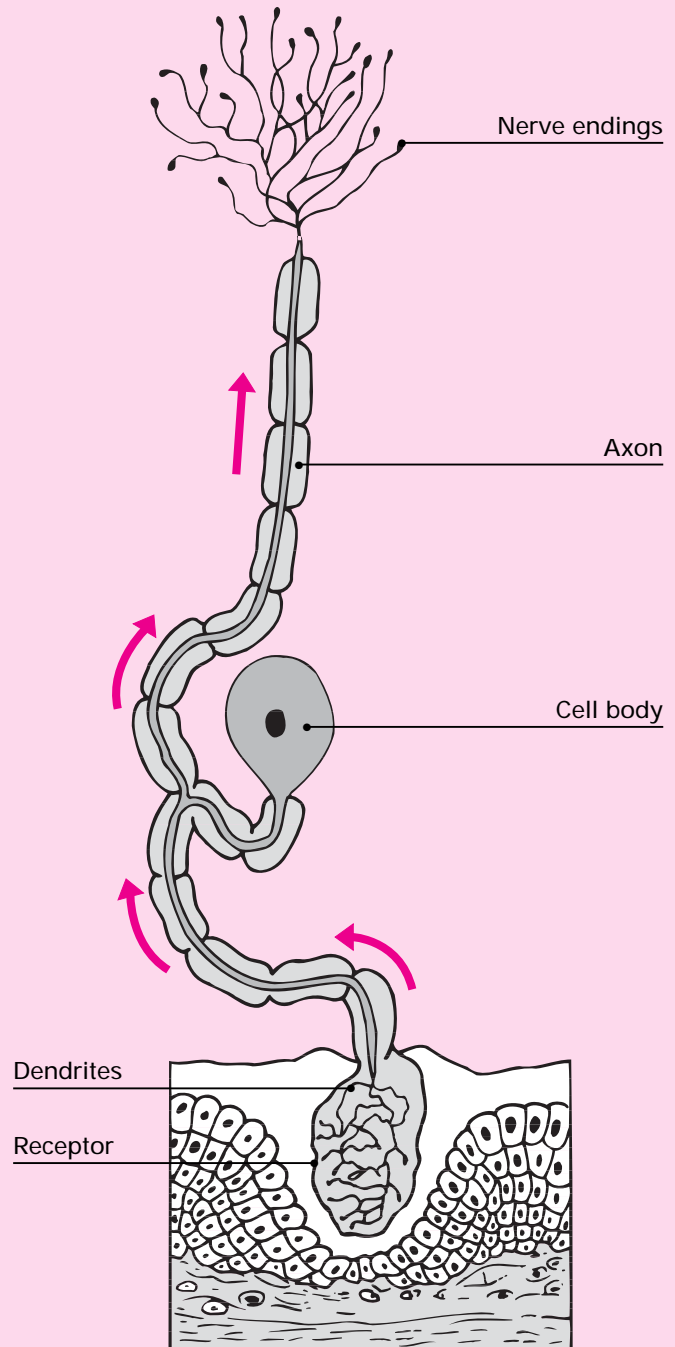
3 The neurotransmitters quickly diffuse across the gap and the molecules fit into receptors on the membrane of the postsynaptic neuron.

4 This changes the local permeability of the postsynaptic membrane to sodium ions, and these positive ions pass into the postsynaptic neuron causing the area close to the synapse to undergo depolarization. As a result, a nerve impulse is triggered in this second neuron.



Sensory neurons

Sensory neurons (or receptor cells) are unipolar nerve cells that convey information from receptors in the body to the central nervous system. Dendrites (short, branched projections) in the receptor in the skin, eye, nose, and other sensory organs, pick up signals caused by certain stimuli. These are then transmitted as nerve impulses to the cell body. The axon, or cell "trunk," conveys the impulses through synapses to other neurons in the brain or spinal cord. The solid arrows show the direction of the impulses.



Nerve pathways

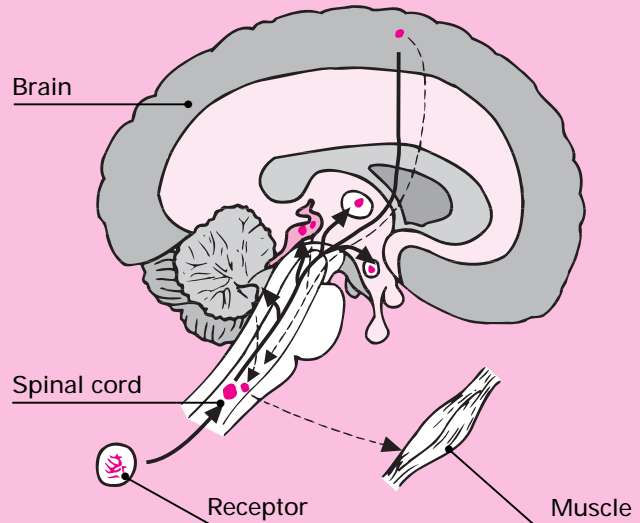
Different nerves transmit information via specific routes (nerve pathways). The pathways taken by nerves relaying information about pain and temperature, for example, are different from each other and from those taken by nerves relaying information received from the senses. The speed at which the impulse travels depends on the width of the axon. Large axons carry signals more quickly than smaller ones. This explains why some sensations, such as heat, are felt before others, such as pain. The heat receptors have a faster pathway than the pain sensors.

Pathway of a sensory receptor

1 A sensory receptor (nerve ending sensitive to stimuli) in the skin carries messages to the spinal cord.

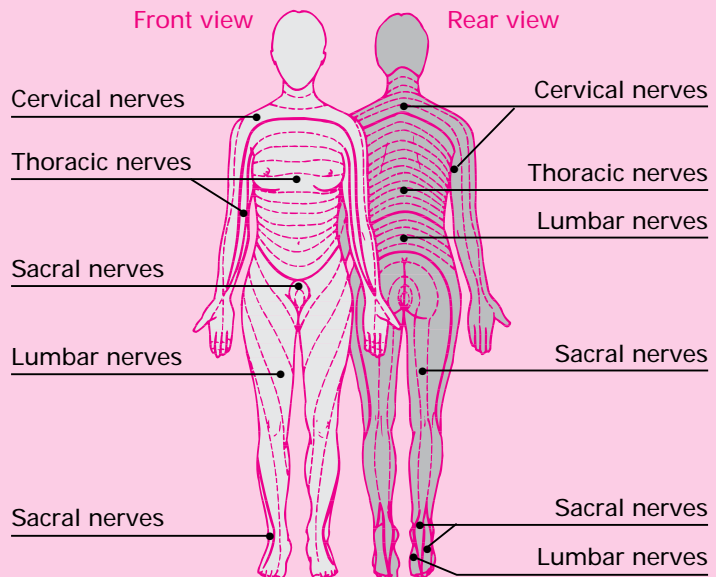
2 Information is sent from the spinal cord to the brain, and the touch sensation is interpreted using the different processing centers.

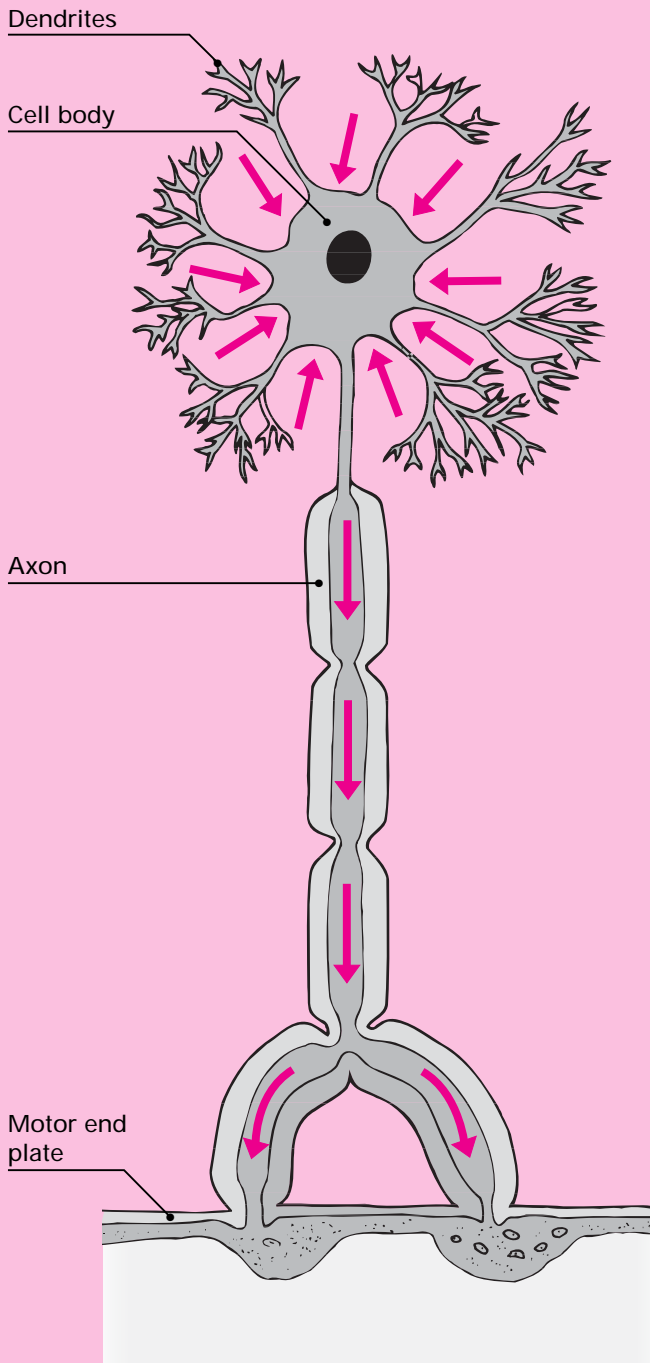
3 In order to move a muscle (or innervate another effector), a command is sent from the brain back through the spinal cord. The final motor signal is a mix of several coming from different parts of the brain.



Dermatomes

Dermatomes (represented by dotted lines) are areas of the skin identified by the nerves that supply them. Pain in a dermatome may result from a problem with an internal organ that is supplied by the same nerve. The pain caused by a heart attack, for example, can often be felt in the left arm—since both the heart and left arm are served by thoracic nerves. Solid lines represent the boundaries between groups of dermatomes supplied by different nerves. The diagram shows the front and rear dermatomes of an adult.





Motor neurons

Motor neurons are nerve cells that convey information from the central nervous system to muscles and glands. Electrical impulses in a motor neuron travel in the opposite direction from those in a sensory neuron. The arrows show the direction of the impulses. Dendrites collect signals from nerve fibers in the central nervous system. These are transmitted to the cell body and via an axon to motor end plates, which innervate an effector organ. For example, they may stimulate a gland to secrete a hormone, or the signals may cause a muscle to contract or relax.

All or nothing

The electrical impulse of a nerve fiber is converted into a muscle contraction by the neurotransmitter acetylcholine, which passes from the nerve fiber to the muscle fiber. Muscles contain many muscle fibers. Each fiber has an all-or-nothing response. Either it contracts fully or it does not. The power of a muscle depends on the number of fibers in it that have been stimulated by nerves.

Motor units

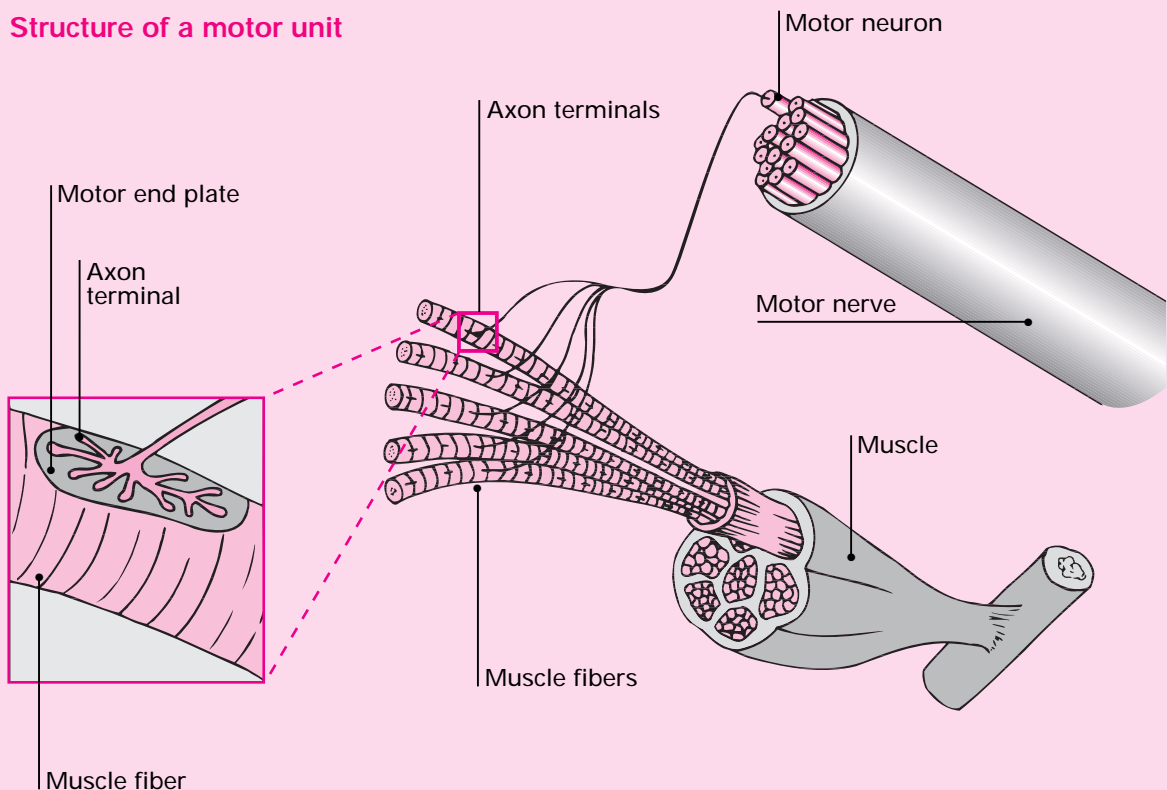
Muscle fibers have to contract quickly when stimulated in order to bring about a given action. To do this they are fed by nerves from the central nervous system—the brain and spinal cord. A single neuron (nerve cell) and all the muscle fibers that it stimulates are known as the motor unit. Different muscles have a

different number of motor units. The number of muscle fibers within a motor unit varies from as few as four to many hundreds. Muscles that require very precise action have small motor units. Muscles that are required to be powerful but need less precise movements have many large motor units.

Structure

Each motor unit is served by one motor nerve housing many motor neurons. The axon terminals of motor neurons attach to muscle fibers in the muscle at points called motor end plates.

Structure of a motor unit



Reflex arcs are nerve pathways that allow the one-way flow of messages. They are preprogrammed involuntary responses to specific stimuli. They can, however, be overridden by the brain.

Structure

Reflex arcs have five main parts: receptor, sensory neuron, integration center, motor neuron, and effector.

Receptors These are located at the site of the stimulus. They respond to a change in the environment.

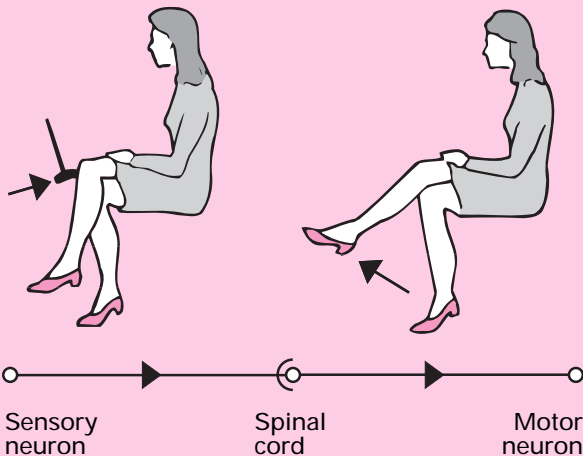
Sensory neurons These transmit nerve impulses from the receptor to the central nervous system (CNS).

Integration centers These convert incoming signals into outgoing ones.

Motor neurons These transmit impulses from the integration center in the CNS to the effector organ (for example, a muscle or gland) which is outside the CNS.

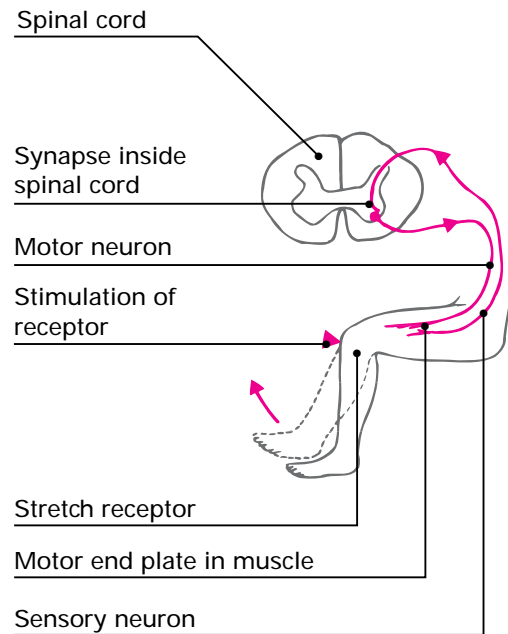
Effectors These respond to impulses from the motor neurons and produce the appropriate action—such as contraction of a muscle or secretion from a gland.

Types of reflex arc

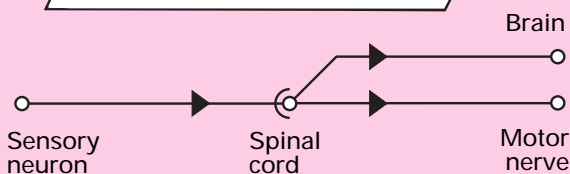
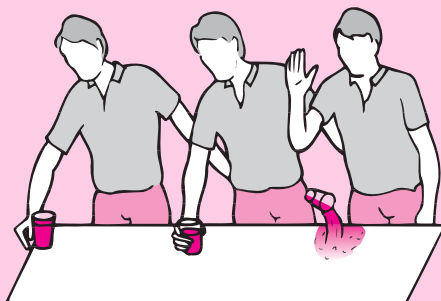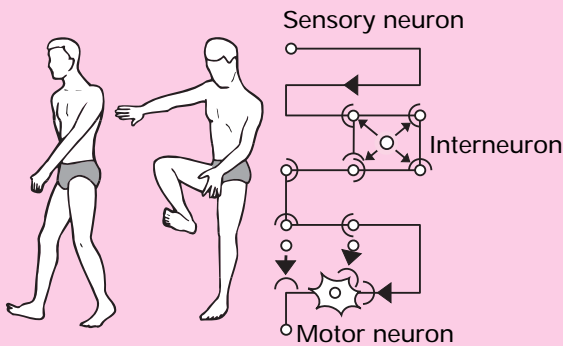


a A simple reflex arc occurs when the knee is tapped with a knee hammer. The tendon beneath the knee is stretched and a sensory neuron relays this information to the spinal cord. This is relayed to a motor neuron, which contracts the leg muscle, and the leg swings upward.

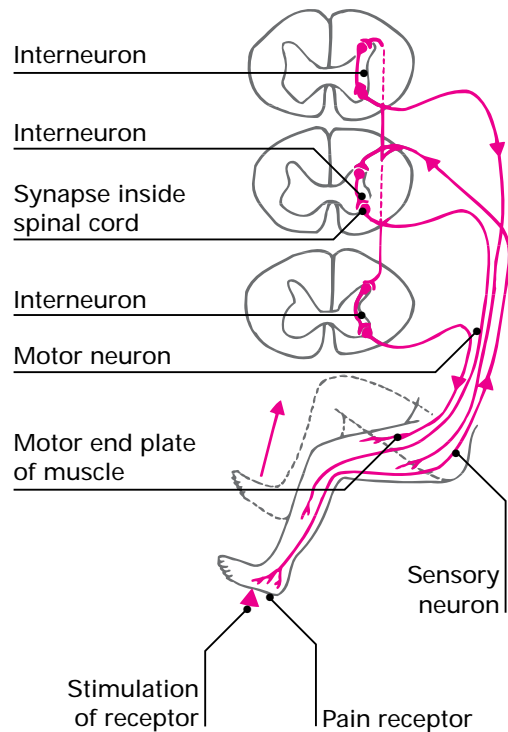
Mechanism of a simple stretch reflex



b If you step on a tack with bare feet, a sensory neuron in your foot registers pain and links to the spinal cord via a collection of interneurons. These interneurons send messages to motor neurons that cause muscles to contract and relax, enabling you to withdraw your foot and keep your balance. Messages sent to the spinal cord also produce movements in the head and arms, and the involuntary “ouch!”



Mechanism of a polysynaptic avoidance reflex



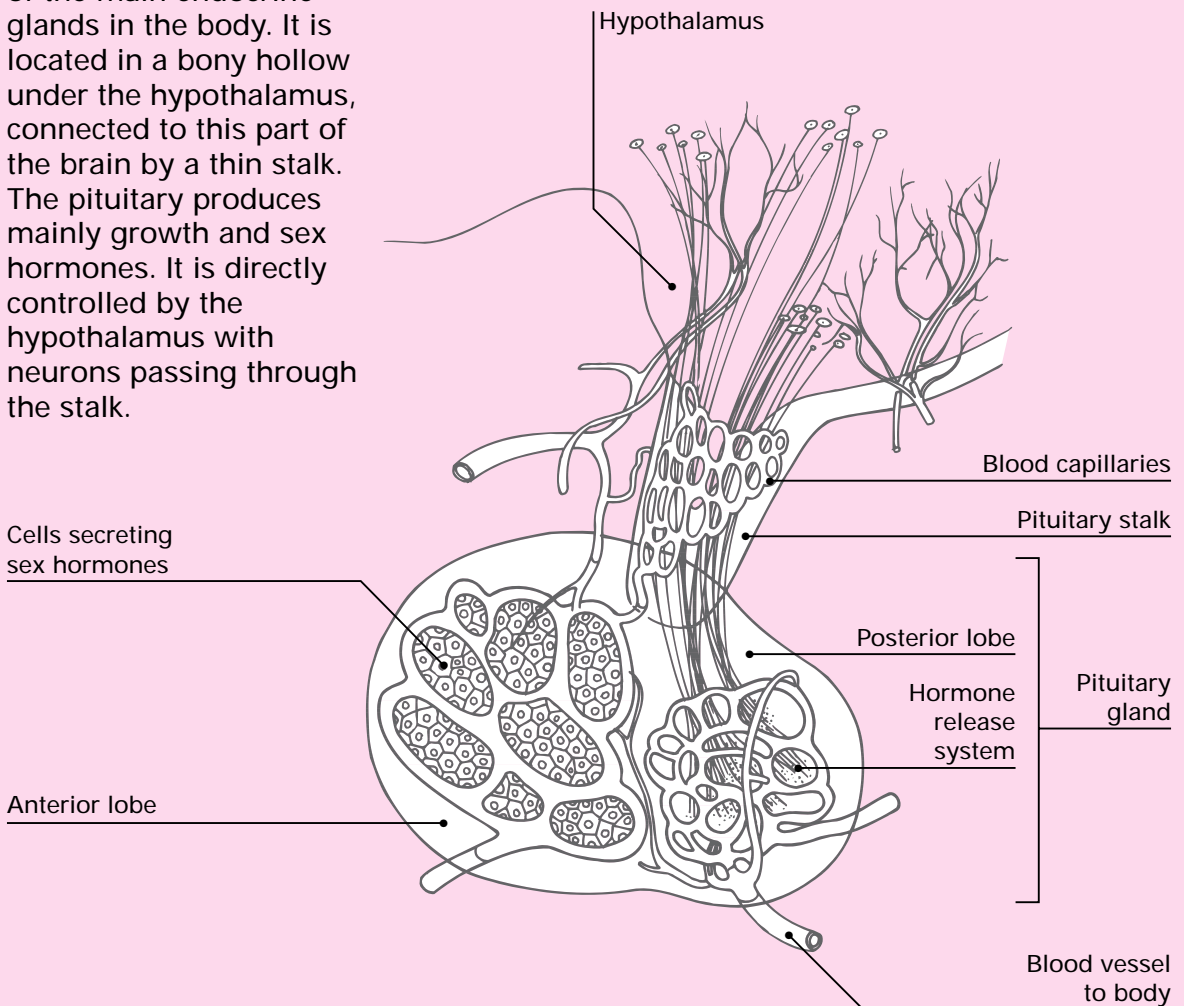
c A slightly more complex reflex arc occurs when a hot cup is picked up. Heat is registered by a sensory nerve in the skin and this information is relayed to a motor nerve in the arm via interneurons in the spinal cord. The motor nerve causes muscles to contract, which draws the hand away. Pain messages are sent to the brain, but the reflex occurs before the brain has registered the sensation of pain.

The endocrine system employs a series of glands throughout the body. The glands produce chemical messengers called hormones that control body functions. These substances are released into the blood supply and may have an effect on several different parts of the

body. Familiar glands include the thyroid gland in the neck, the pituitary gland in the brain, and the pancreas—really a collection of glands—located behind the stomach and liver. Common hormones include insulin, testosterone, and estrogen.

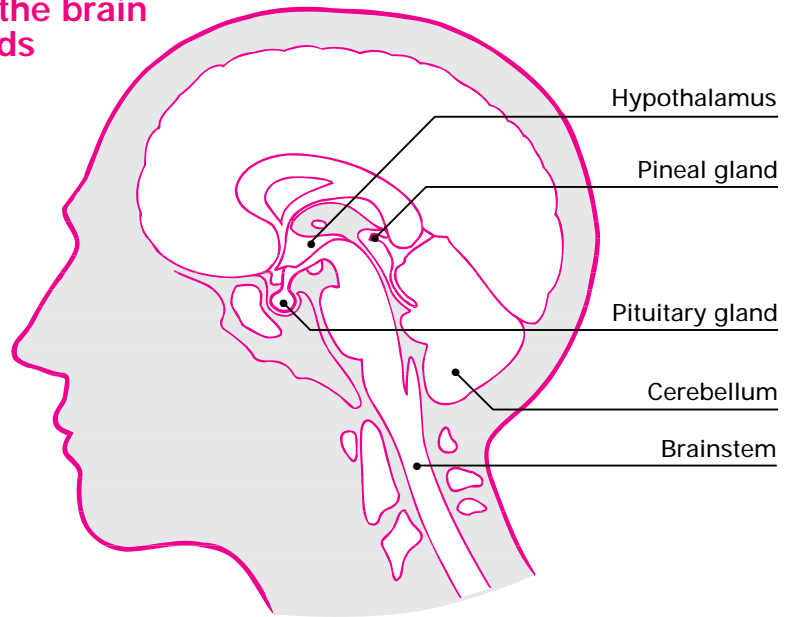
Nerve connections and blood supply of the pituitary gland

The pituitary gland is one of the main endocrine glands in the body. It is located in a bony hollow under the hypothalamus, connected to this part of the brain by a thin stalk. The pituitary produces mainly growth and sex hormones. It is directly controlled by the hypothalamus with neurons passing through the stalk.



Median section through the brain to show position of glands

Two endocrine glands—the pituitary and pineal—are closely associated with the brain. Both produce hormones associated with growth and development. The hypothalamus, above the midbrain, also produces hormones. These largely control other glands. The pituitary is often compared to the conductor in an orchestra—it oversees and directs the actions of other players in the endocrine system (see page 28).



Hypothalamus

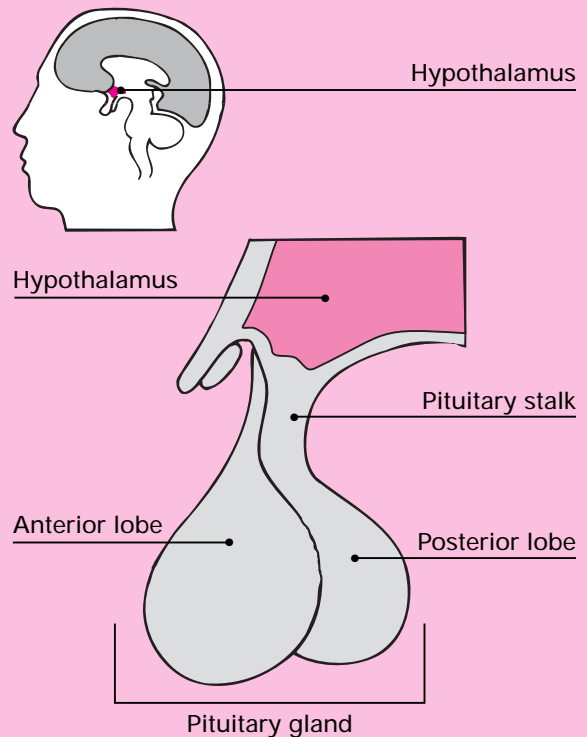
Location and structure

The hypothalamus is a small region of the brain above the pituitary gland. It is connected to the nervous system.

Functions

The hypothalamus is important in the nervous system as well as in the endocrine system, and it links the two by converting nervous signals into hormonal signals. It is directly tied to the function of the pituitary by:

- secreting, releasing, and inhibiting hormones that flow to the anterior lobe of the pituitary, stimulating it to release its hormones;
- producing hormones (oxytocin and antidiuretic hormone) that are sent to, and stored in, the posterior lobe of the pituitary.



The pituitary gland location and structure

The pituitary gland (**a**) is a small, round gland attached to the hypothalamus (**b**) in the brain. It is stimulated by the hypothalamus. The pituitary has two main lobes, called the posterior (**c**) and

the anterior (**d**). These are connected by a narrow intermediate lobe (**e**), which produces melanocyte-stimulating hormone (MSH). This stimulates the skin to darken during tanning.

Functions

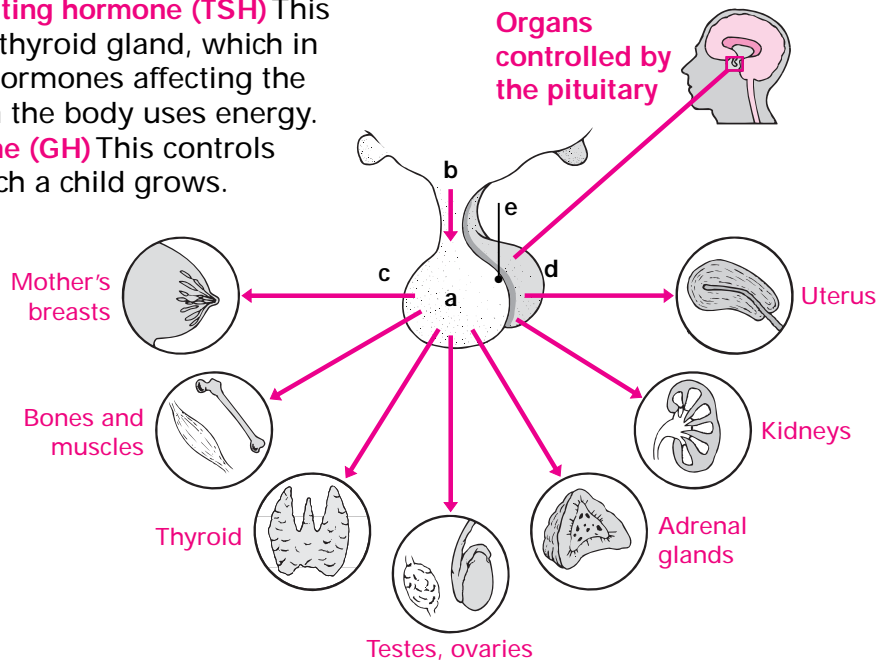
The anterior lobe This secretes several hormones that are vital to development.

- **Adrenocorticotrophic hormone (ACTH)** This acts on the adrenal glands, which are above the kidneys, to produce hormones that prepare the body to cope with physical threats.
- **Follicle-stimulating hormone (FSH) and luteinizing hormone (LH)** These act on male and female sex glands (testes and ovaries), which themselves then produce sex hormones vital for sexual development and menstruation.
- **Thyroid-stimulating hormone (TSH)** This stimulates the thyroid gland, which in turn secretes hormones affecting the speed at which the body uses energy.
- **Growth hormone (GH)** This controls the rate at which a child grows.

- **Prolactin (PRL)** This stimulates a new mother's breasts to produce milk.

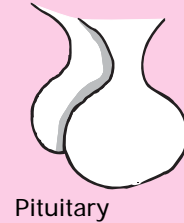The posterior lobe This releases two hormones that are produced by the hypothalamus:

- **Oxytocin** This causes the uterus to contract during childbirth.
- **Antidiuretic hormone (ADH) or vasopressin** This is produced when the body's water level is low. ADH acts on the kidneys, making them reabsorb water that would otherwise be flushed out in urine.

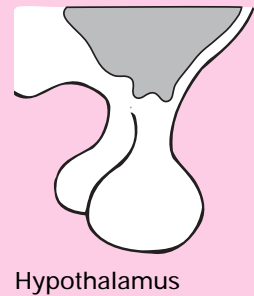

Glands and their hormones

Gland	Target tissue	Effects
Pituitary (intermediary lobe) Melanocyte-stimulating hormone (MSH)	Skin	<ul style="list-style-type: none"> Stimulates the synthesis of melanin pigments in the skin

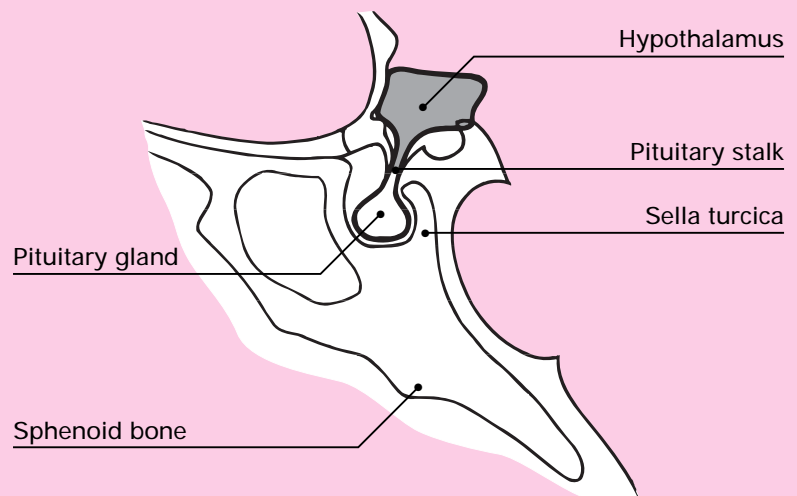


Hypothalamus Releasing and inhibiting hormone	Anterior lobe of pituitary gland	<ul style="list-style-type: none"> Inhibits or stimulates the secretion of pituitary gland hormones
---	----------------------------------	--



Median section through sella turcica

The pituitary gland is protected inside a hollow in the sphenoid bone, a part of the skull. The hollow is called the sella turcica. A thin stalk connects the pituitary gland to the region of the brain known as the hypothalamus.



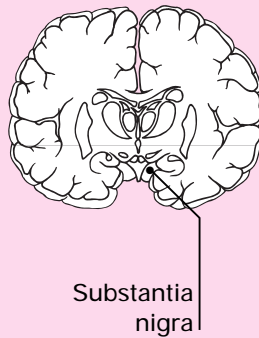
Disorders of the brain and nerves

Alzheimer's disease The progressive degeneration of the brain resulting in dementia (mental deterioration). Very few people begin to suffer from Alzheimer's before they reach the age of 60. One in five people over 85, however, show symptoms. Symptoms include loss of memory and comprehension. Sufferers become weakened by the disease and generally die from infections within ten years.

Encephalitis An inflammation of the brain caused by an infection by bacteria, a virus, or prion (pathogenic protein), or polluting chemicals. The inflammation may cause a headache for a few days, but convulsions, coma, or even death may result. Encephalitis is linked to meningitis. This is an inflammation of the meninges, the membranes around the brain and spinal cord. When both the brain and its membranes are inflamed, the condition is called meningoencephalitis.

Headache Any pain in the head. Many factors that affect the nervous system can produce a headache, including damage to the brain and its blood vessels; infection of the ears, eyes, and nose; and tension in muscles that results in a painful constriction of nerves. But, in fact, it can often be non-specific.

The substantia nigra is affected by Parkinson's disease



Insomnia Difficulty in falling or staying asleep. It can be caused by stress, drinking too much coffee, or taking too little exercise, or it may be a symptom of a physical or mental disorder.

Migraine A severe headache often accompanied by blurred vision and nausea. It can be caused by stress or certain foods, or the tendency may have been inherited.

Motor neuron disease The nerves in the brain and spinal cord that control muscular activity degenerate. Muscles become weak and may waste away. Also known as Lou Gehrig's disease.

Parkinson's disease The progressive degeneration of part of the brain that results in muscle rigidity and tremors. The disease is associated with neurons dying in the substantia nigra, part of the midbrain, resulting in a lack of the neurotransmitter dopamine.

Spina bifida An incomplete formation of the spine, sometimes resulting in damage to nerves and loss of lower limb function.

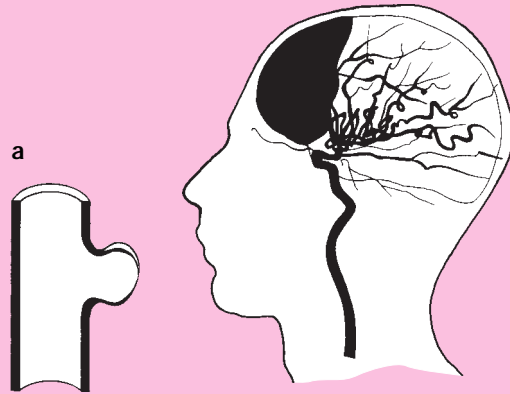
Spinal shock The temporary loss of ability that results from injury to the spinal cord.

Stroke A condition in which brain tissue dies, usually as a result of a disruption to the blood supply. Also referred to as a cerebrovascular accident.

Stroke: three main causes

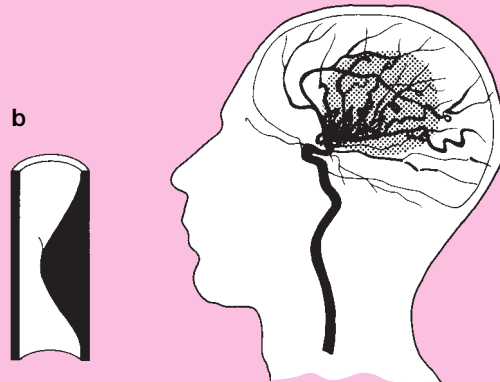1 Cerebral hemorrhage

A weakened spot in a blood vessel wall ruptures (**a**), letting blood flood into the brain tissue. The blood clots, causing pressure on the brain.



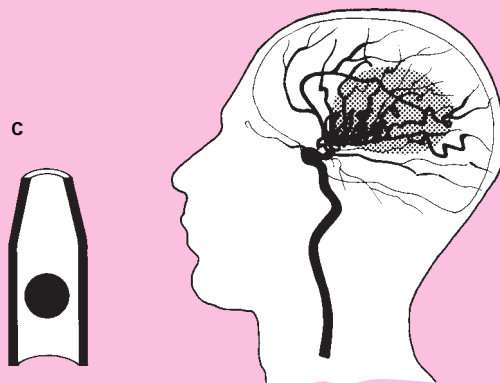2 Cerebral thrombosis

A blood clot (thrombus) forms in a cerebral blood vessel (**b**) and blocks the supply of blood to part of the brain. The resulting shortage of blood, and thus of oxygen and glucose, kills some brain tissue.



3 Cerebral embolism

Abnormal material (an embolus, such as a clot from elsewhere in the body) blocks an artery leading to the brain (**c**), depriving nerve cells of nutrients and killing them.



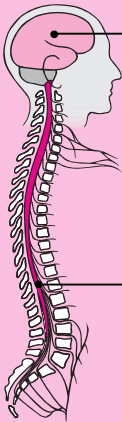
The brain is a walnut-shaped organ, housed within the skull, made up of many nerve cells. The bodies of nerve cells are often referred to as gray matter, and their fibers are referred to as white matter. Deep wrinkles in the brain give it a surface area of 324 square inches (2,090 cm²). Men's brains are usually heavier than women's: an adult male brain weighs about 3 pounds (1.4 kg); an adult female brain weighs about 2.8 pounds (1.3 kg). However, there is no evidence that brain size and intelligence are related directly.

Brain facts

- The brain alone uses a fifth of the oxygen required by the body.
- A human brain grows to full size in six years.
- The brain is the source of moods and emotions, and is the seat of the mind.

The brain

The brain is the main part of the central nervous system, which also includes the spinal cord. It controls all of the body's processes. Most of the signals from the brain reach the body via the spinal cord.



Side view

The brain is positioned above the spinal cord.

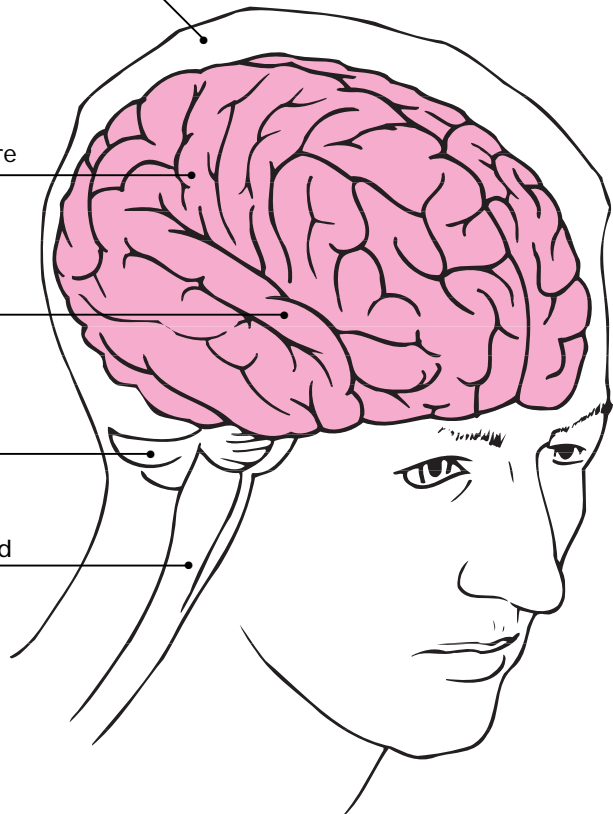
Skull or braincase

Cerebral hemisphere

Brain

Hindbrain

Spinal cord



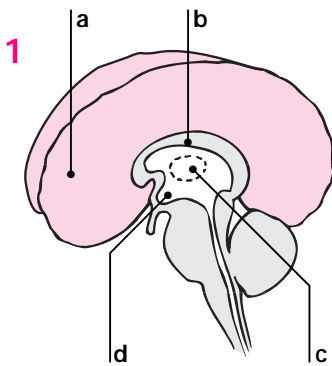
Brain structure

The brain is divided into three main regions:

1 The forebrain, where memory, the mind, and intelligence are based. This is also involved in body-part movements, receiving sensations, speech, hearing, and sight.

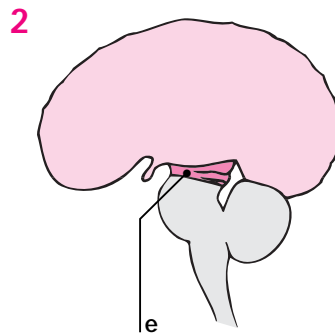
2 The midbrain, which works mainly as a relay station for messages to and from the brain. Eye movements are controlled here.

3 The hindbrain, which coordinates complex body movements, especially of the arms and legs.



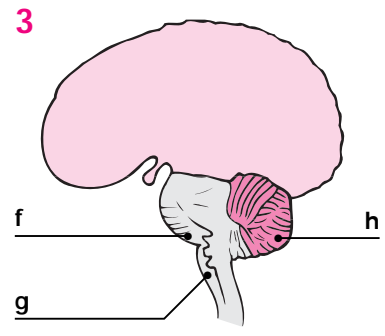
1 Forebrain

Arising from the brainstem (a slim stalk at the top of the spinal cord), the brain spreads out to fill the space inside the skull. The forebrain, or cerebrum, consists of two cerebral hemispheres (a). Within the cerebrum lie the corpus callosum (b) (linking the two brain hemispheres), the thalamus (c), and the hypothalamus (d). The thalamus and hypothalamus are also part of the region within the cerebrum called the diencephalon.



2 Midbrain

The midbrain (e) is the shortest and highest section of the brainstem (which otherwise consists of parts of the hindbrain). The midbrain is a relay station between the reticular system lower down the brainstem and the forebrain above. The midbrain is also involved in controlling the movement of the eyes and the size of their pupils.



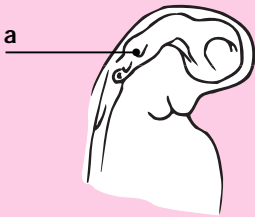3 Hindbrain

This involves all the main structures beneath the midbrain and includes the pons (f), medulla oblongata (g), and cerebellum (h). Pons and medulla oblongata form most of the brainstem, which is fused with the spinal cord. The medulla oblongata is involved in controlling breathing, heartbeat, and other vital processes. The pons is the connection between the cerebellum and the rest of the brain. The cerebellum coordinates body movements.

Brain development

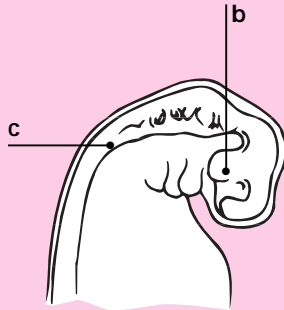
Embryo: 3 weeks

The central nervous system begins to form from a neural tube (**a**). In the third week of development, the tube closes, and the brain begins to form from three sacs.



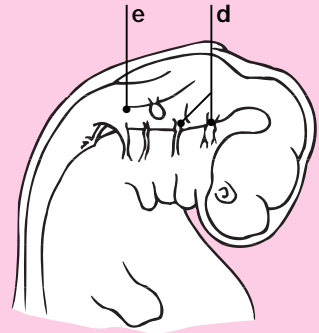
Embryo: 4 weeks

By this time the forebrain or cerebrum (**b**) has become differentiated from the rest of the central nervous system. The spinal cord (**c**) grows along the neural tube.



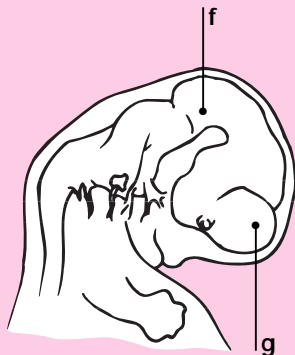
Embryo: 5 weeks

After five weeks, the paired cranial nerves (**d**) are growing from what will be the hindbrain (**e**). Spinal nerves are also developing lower down the body.



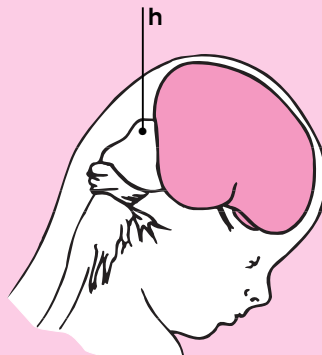
Embryo: 7 weeks

By this point, the forebrain is divided into the diencephalon (**f**), which contains the thalamus, and the telencephalon (**g**).



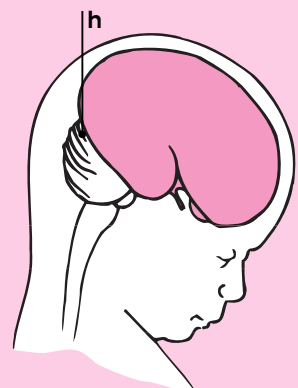Embryo: 11 weeks

The cerebellum (**h**) becomes apparent by this time as it grows from a swollen area on the hindbrain.



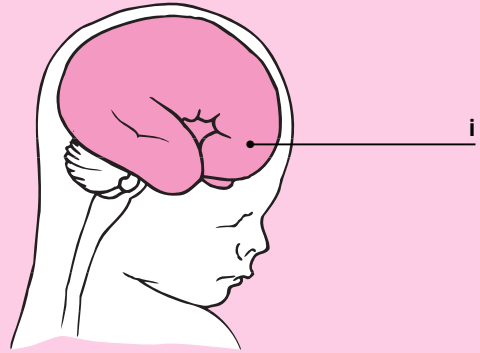Fetus: 4 months

As the cerebellum (**h**) develops, the movements of the fetus increase and it begins to respond to sound.

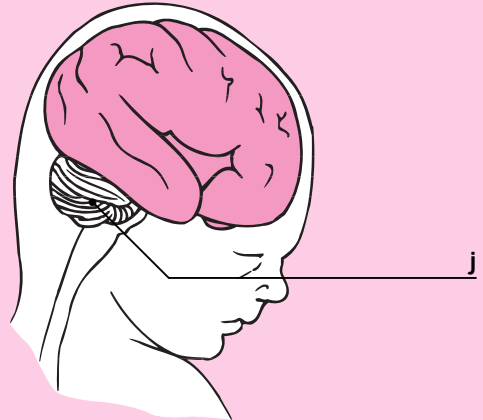

Fetus: 6 months

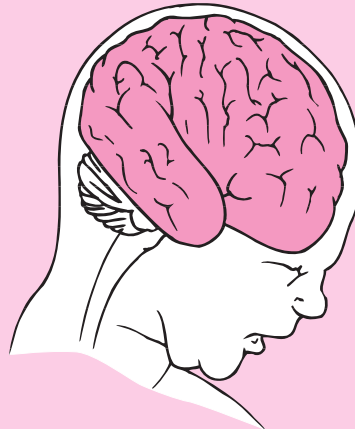The cerebrum (i) begins to fold in on itself. This makes the brain's surface area larger, making more room for neurons. Responses controlled by the autonomic nervous system, such as hiccuping and coughing, are now possible.

**Fetus: 8 months**

The cerebrum is becoming increasingly folded as the number of neurons increases. Soon the fetus will be able to open its eyes when awake, and also detect light. The movements that are coordinated by the cerebellum (j) are now much stronger.

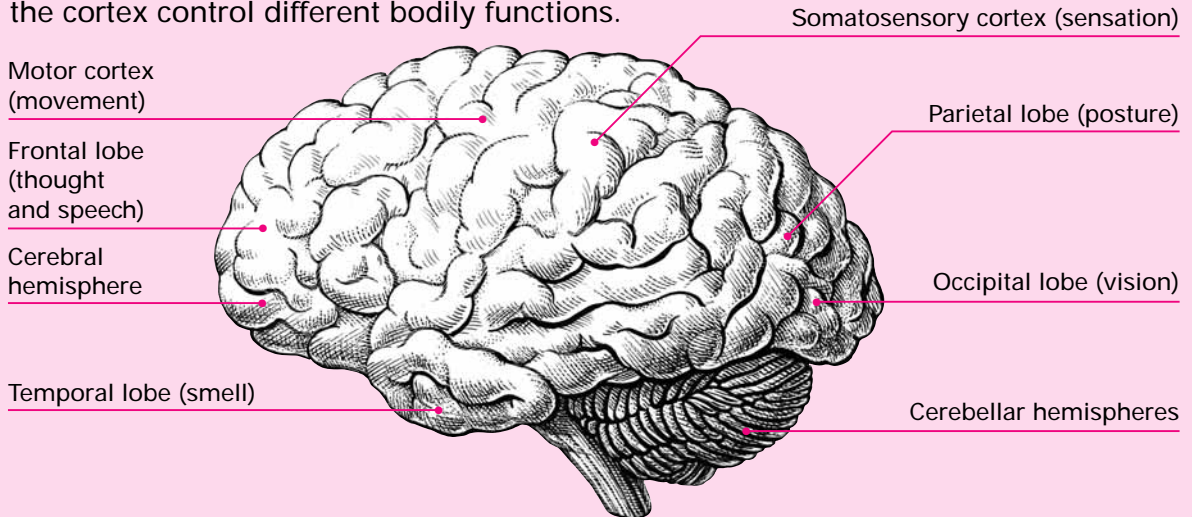
**Newborn baby**

At birth, a human baby has more or less all the brain cells it will need for the rest of its life. However, the brain weighs less than 1 pound (0.5 kg). The brain reaches full size in six years. The increase in weight is caused by nerve cells growing and the development of neuroglia. As the child grows and learns, neurons in the brain begin to connect into circuits.



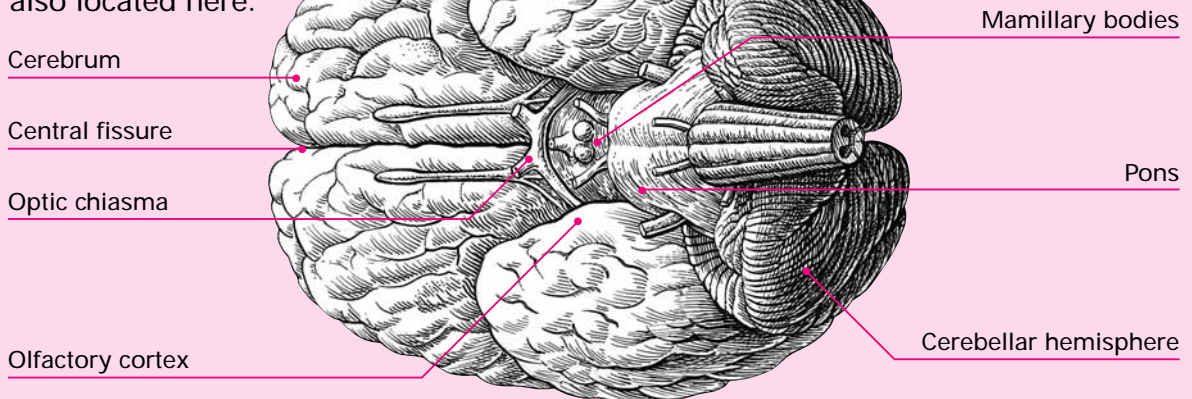
Lateral surface of left hemisphere of brain

The surface of the cerebrum is covered by a folded layer of neurons called the cortex. Different areas of the cortex control different bodily functions.



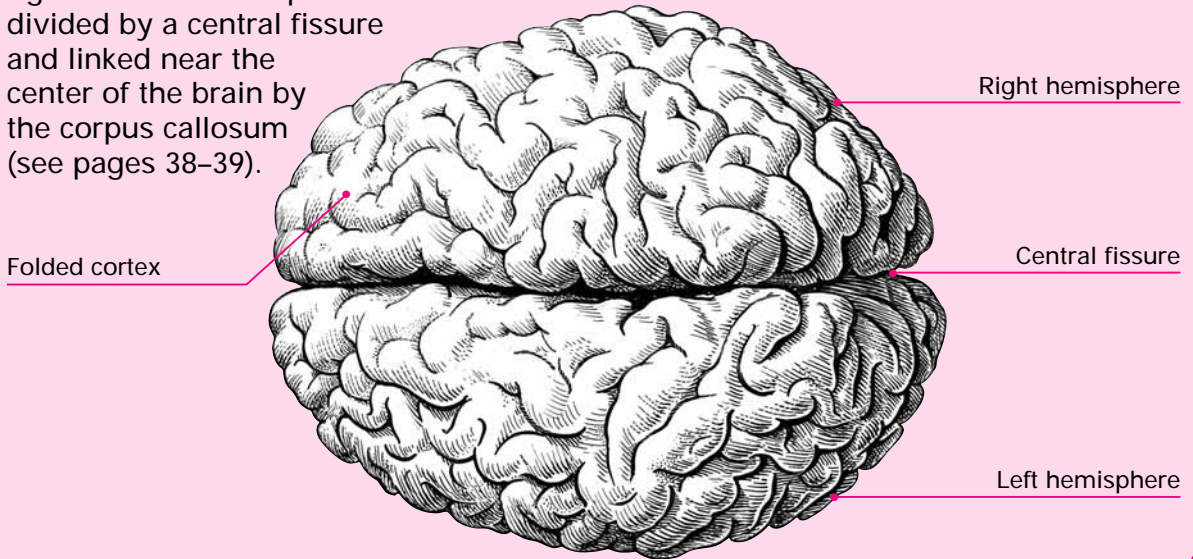
Base of brain

Like the cerebrum, the cerebellum is divided into two hemispheres. These are connected to the rest of the brain by the pons. At the base of the cerebrum, the two optic nerves cross at the optic chiasma. The olfactory cortex is also located here.



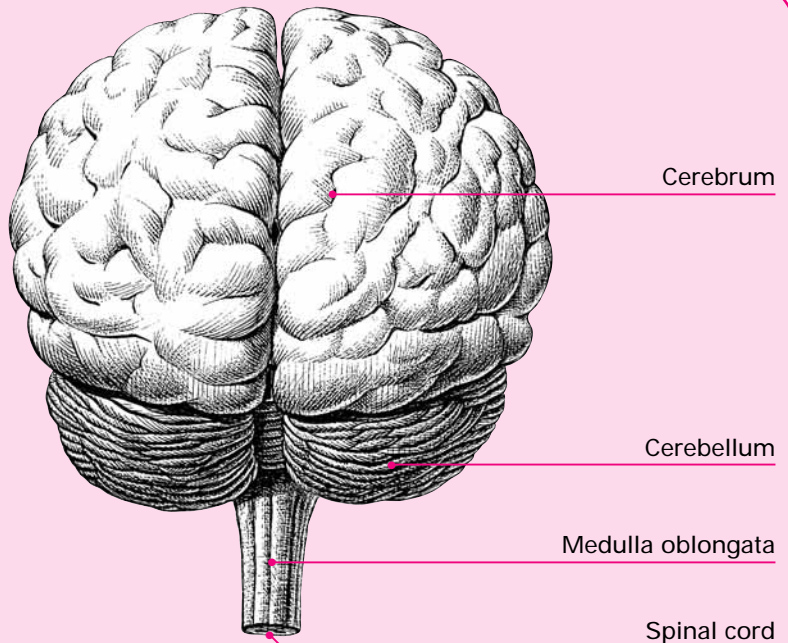
Cerebral hemispheres from above

The cerebrum is divided into a left and right cerebral hemisphere. These are divided by a central fissure and linked near the center of the brain by the corpus callosum (see pages 38–39).



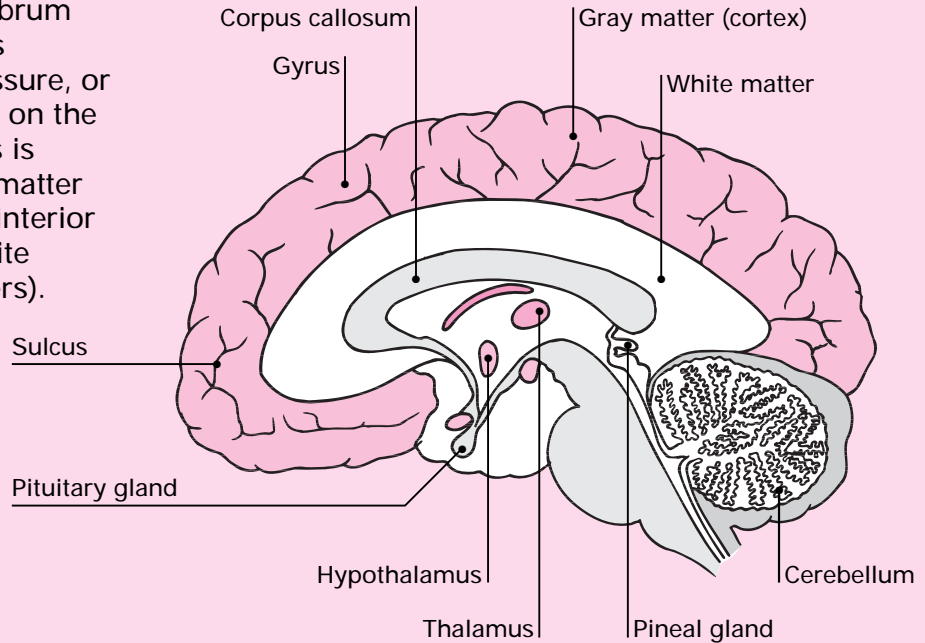
Posterior view of brain

The spinal cord connects to the medulla oblongata beneath the posterior half of the cerebrum. The medulla and the rest of the brainstem connects to the cerebrum at a more central point. In front of this position are the mamillary bodies, so-called because they resemble nipples. They form part of the limbic system, which controls emotions.



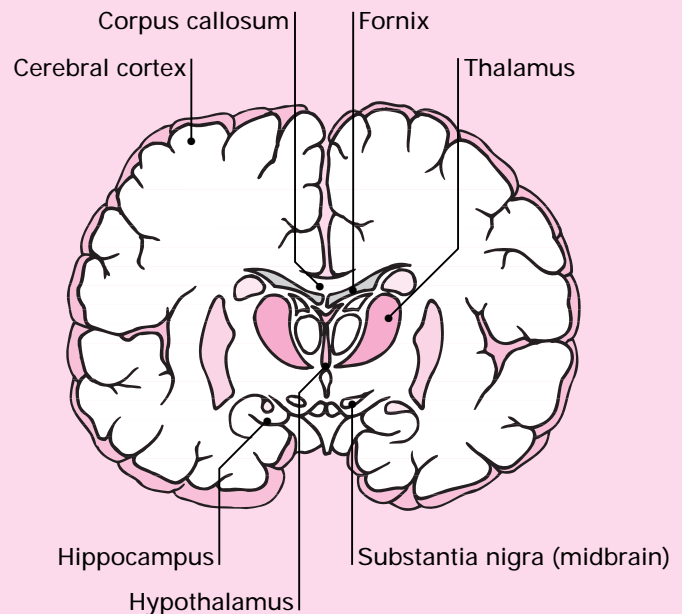
Cross section through brain

Each folded section, or gyrus, of the cerebrum is divided from its neighbors by a fissure, or sulcus. The cortex on the surface of a gyrus is made up of gray matter (cell bodies). The interior is made up of white matter (nerve fibers).



Frontal section through brain

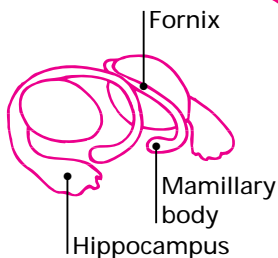
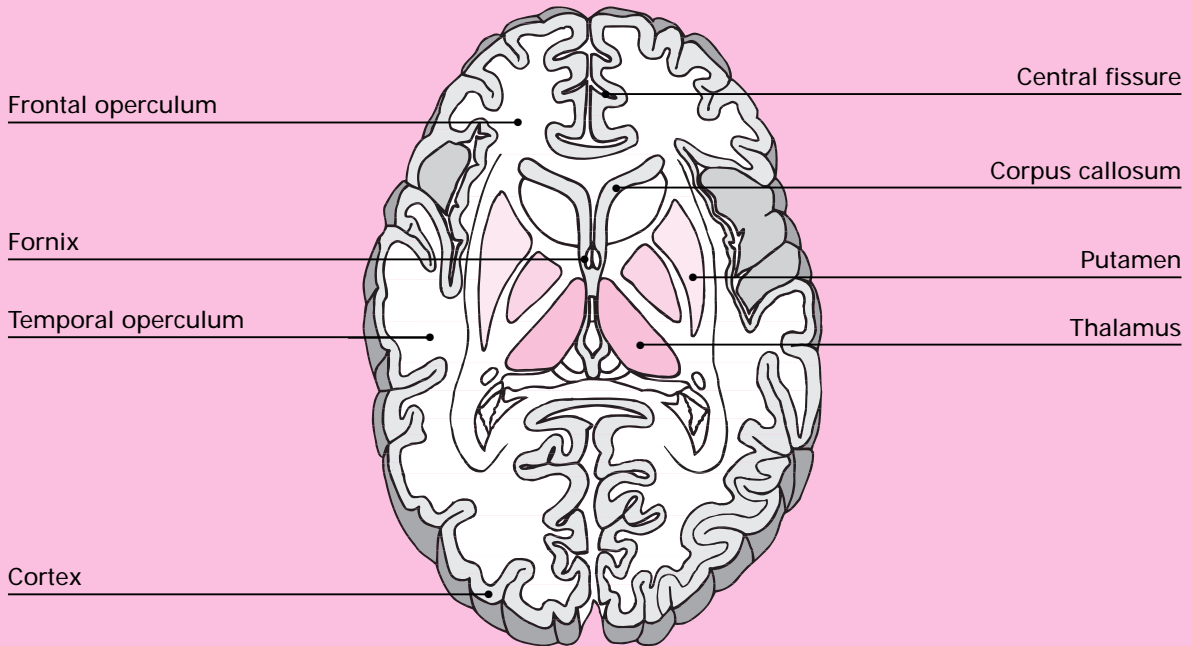The cerebral hemispheres are connected by the corpus callosum. This region is part of the diencephalon which also includes the hypothalamus and thalamus, which control vital body processes, and the fornix and hippocampus which are linked to emotions.



Horizontal section of brain

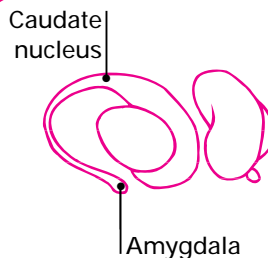
While the surface of a cerebral lobe is made up of the cortex, the interior area of white matter is called the operculum. The central fissure that divides the

cerebral hemispheres extends both forward and back from the central region. Around the center, the putamen is involved in planning movements.



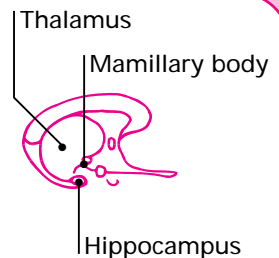
Thalami

The two thalami are relay stations between the cerebral cortex and the cerebellum.



Basal ganglia

These bodies link the midbrain to the cerebral hemispheres, controlling voluntary movements.



Limbic system

This is involved in controlling moods and emotions and also has a memory function.

Spaces inside the brain

The brain and spinal cord are bathed in cerebrospinal fluid (CSF). This is contained between membranes called meninges (see page 55). However, at the center of the brain, the CSF fills spaces, or ventricles. There are two large lateral ventricles in the cerebral hemispheres. These are linked to other ventricles and

ducts. The CSF is produced by a lining in the ventricles called the choroid plexus and is reabsorbed by the meninges. (Fluid also drains out of the brain through the olfactory tract linked to the nose.) The CSF's function is to cushion the brain. It flows to the hindbrain through the cerebral aqueduct.

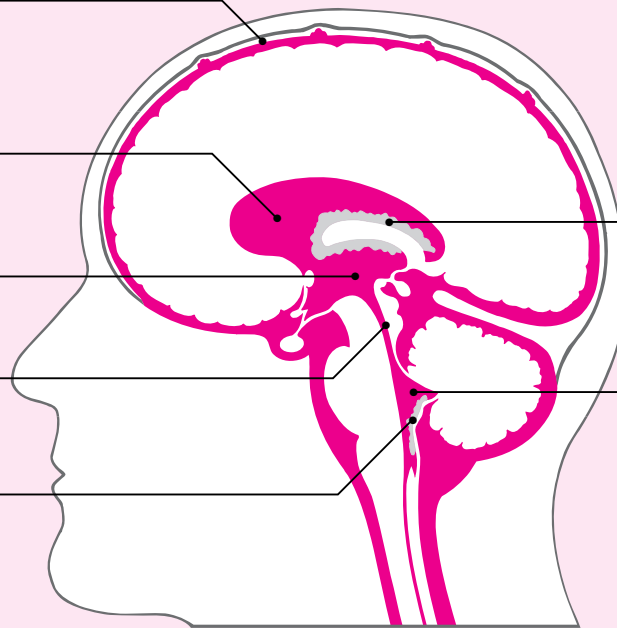
Meninges

Lateral ventricles

Third ventricle

Cerebral aqueduct

Choroid plexus



Choroid plexus

Fourth ventricle

Cerebrospinal fluid

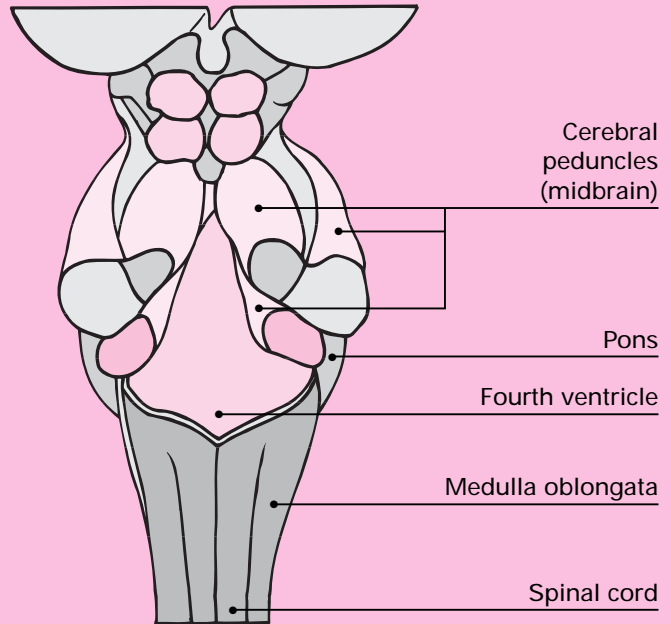
- An infection of the cerebrospinal fluid (CSF) by a virus or by bacteria causes meningitis.
- CSF is largely water.
- The CSF in the spinal cord occupies the central canal.

Blood-brain barrier

- The brain needs to be protected from chemicals in the blood.
- Capillaries in the brain do not "leak" molecules in the same way as they do elsewhere.
- Enzymes control what passes between the brain and the blood.

Posterior view of brainstem

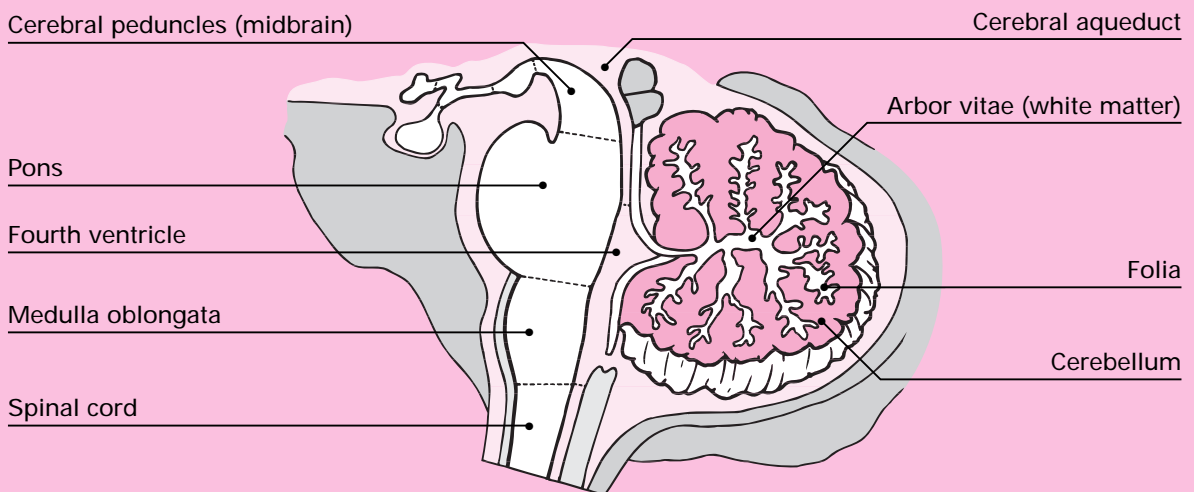
From the top down, the brainstem is made up of the midbrain, pons, and medulla oblongata. These last two make up the hindbrain along with the cerebellum. Deep inside the brainstem is the reticular system. This formation regulates the brain's level of awareness and alertness.



Side view of hindbrain

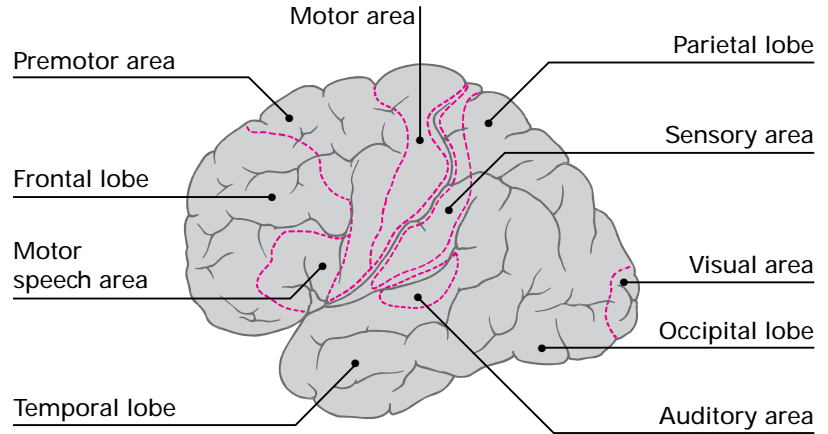
The brainstem forms the link between the cerebrum and the cerebellum. The cerebellum has two hemispheres

connected to the pons. The cerebellar hemispheres contain folia, which are leaflike bundles of neurons.



Surface of left hemisphere

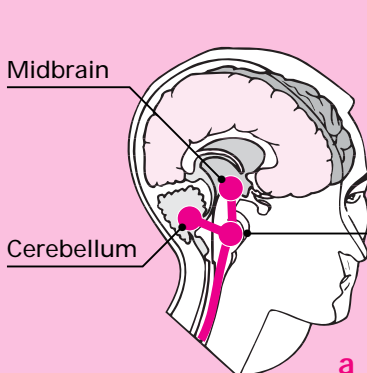
The left hemisphere of the cerebral cortex is divided into several areas and lobes. These are: the motor area, premotor area, frontal lobe, motor speech area, auditory area, temporal lobe, parietal lobe, sensory area, visual area, and occipital lobe.



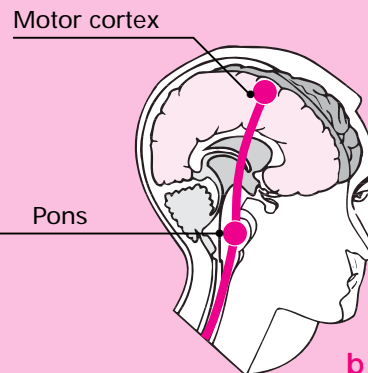
Movement

Controlling movement requires a number of different parts of the brain to work together. There are various subsystems within the central nervous system that control particular movements.

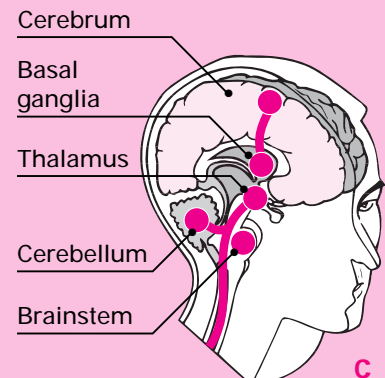
a The pons (in the brainstem) and the cerebellum help to maintain balance. This is aided by the midbrain, which relays signals from the eyes and ears.



b The motor cortex relays commands via the brainstem to the muscles that control posture.



c Other pathways link the cerebrum, basal ganglia, brainstem, cerebellum, and thalamus. These enable smooth limb movements and can also halt movements.



Brain function and personality

Structure

Function

Brainstem

Medulla oblongata

- Acts as a two-way path conducting information between the spinal cord and higher brain centers.
- The cardiac center regulates the heartbeat and the force of the heart's contractions.
- The medullary rhythmicity area adjusts the rate of breathing.
- The vasomotor center regulates the diameter of blood vessels.

Pons

- Acts as a two-way path conducting information between the body and certain areas of the brain.
- The pons also affects respiration (breathing).

Midbrain

- Works as a relay station for messages to and from the brain.

Reticular formation

- Responsible for maintaining consciousness.

Diencephalon

Thalamus

- Relays information from the senses to the cerebrum.
- Sends instructions from the cerebrum to the body's muscles.

Hypothalamus

- Acts as a coordinator of the central nervous system.
- Controls basic life processes such as body temperature, sleep, and appetite.

Cerebrum

Cerebral hemispheres

- Controls intelligence, memory, perception, thinking, decision-making, and the movement of body parts. Receives sensations and is involved in speech, hearing, and sight. Different lobes have different functions.
- Contains an area called the limbic system which plays an important part in emotions.

Basal ganglia

- Involved in planning and programming voluntary (under conscious control) muscle movement.

Cerebellum

- Coordinates complex body movements, especially of the arms and legs.
- Helps to maintain posture.

How memory works

It is not fully understood exactly how we remember things. Most information does, however, have to go through elaborate processes that categorize and intensify it by linking it to already-known material. The diagram shows how some scientists think memory works.

Registration

1 Our senses perceive outside stimuli.

2 These are converted into electrical nerve impulses that are registered by the brain.

Storage

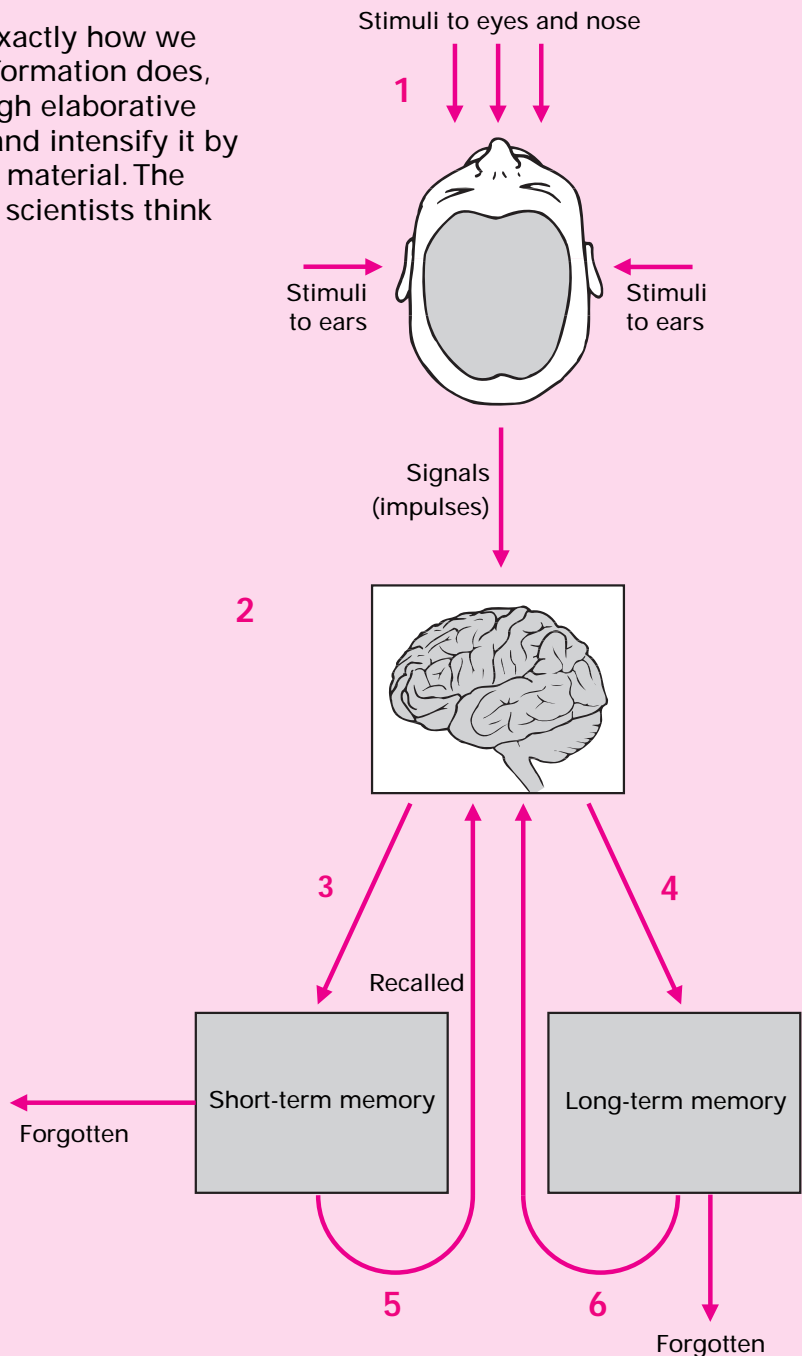
3 The brain stores the signals in its short-term memory. Unless these memories are frequently recalled, they are soon forgotten.

4 Memories that are more important are sent to the long-term memory.

Recall

5 Information is recalled to the conscious mind. The ease with which this is done depends on the strength of the elaborate processes initially used to memorize.

6 Memories infrequently recalled or very old become harder to recall. Eventually, they may be permanently forgotten.



Synapses—the basis of learning and memory

Synapses are the junctions between neurons. Most transmit the nerve's electric impulses to the next cell by chemical means. Much less common are electrical synapses, in which impulses are transmitted directly by the flow of ions (charged particles) from one cell to another.

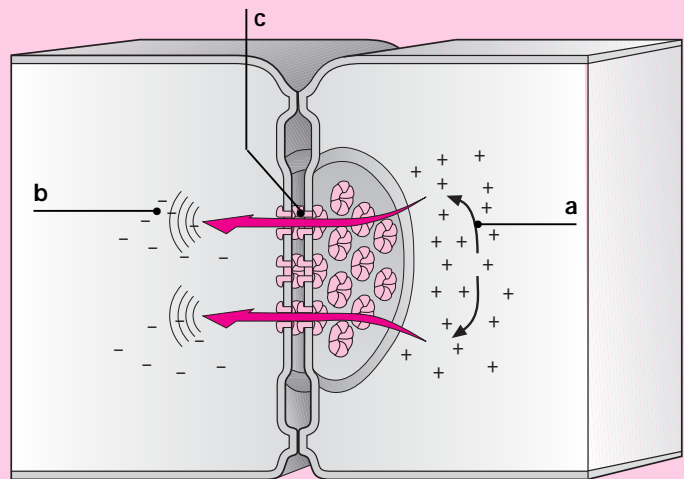
- These synapses create continuity

between cells, which become a single electrical circuit.

- This means virtually instantaneous transmission of impulses, without the slight delay of chemical synapses.
- Electrical synapses occur between the cells of cardiac muscle and between certain neurons of the central nervous system of vertebrates.

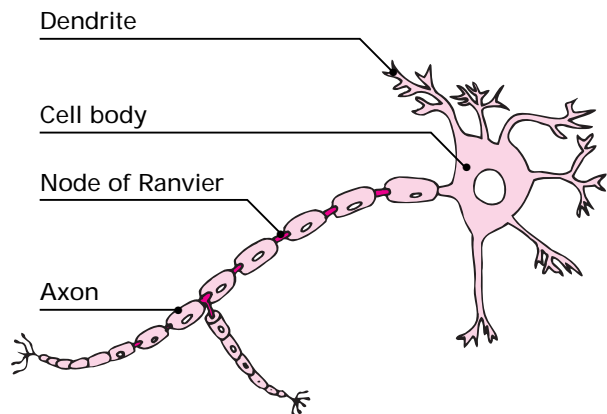
Structure and function

- The terminal region of the presynaptic cell (**a**) is connected to the postsynaptic cell (**b**) via numerous gap junctions (**c**).
- When an action potential arrives at the presynaptic cell terminus, ions flow through the channels formed by the gap junctions.
- This triggers an action potential in the postsynaptic cell virtually instantaneously.



Neurons

Nerve cells are called neurons. All neurons contain the same elements. The cell body includes a nucleus and several extensions. The axon is the largest extension. It transmits information from the cell body to other cells via synapses. Dendrites are short fibers that receive signals from neighboring cells.



To be asleep is to be in a state of lowered consciousness combined with reduced metabolism. What causes people to sleep is not fully understood. It may be linked to the levels of certain chemicals secreted by brain cells. There are two types of sleep: nonrapid-eye-movement (NREM) and rapid-eye-movement (REM) sleep.

Nonrapid eye movement (NREM)

During NREM sleep, brain electrical activity and vital signs decline.

Rapid eye movement (REM)

REM sleep is also called paradoxical sleep because the brain becomes more electrically

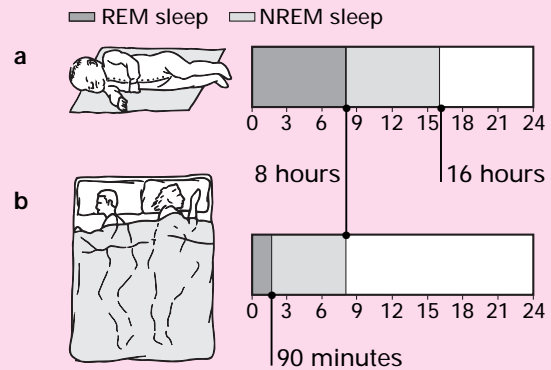
active, almost as if the person were awake. During REM sleep, the body temperature, heart rate, breathing rate, and blood pressure all rise. There is a decrease in digestive activity, and the eyes move rapidly under their lids. Dreams occur during REM sleep.

Functions

Sleep is vital. It is not understood, however, exactly why this is so. It may be necessary for the brain to rest in order to continue functioning efficiently. Activity during REM sleep (dreaming, for example) may be the brain sorting information that it has collected during the day.

Sleep requirements

The need for sleep depends on many factors, including age. Newborn babies (a) will sleep for as much as 16 hours a day. Half of this will be REM sleep. One-year-olds sleep for around 14 hours a day; by the age of five this has dropped to 12 hours. On average, adults (b) need to sleep for 7–8 hours per day. Of this, only about one-fifth will be REM sleep.



Sleep chart

An average night's sleep is shown on the series of charts below. There are two type of sleep: orthodox, or NREM, sleep and paradoxical, or REM, sleep. About three-quarters of sleep is orthodox, but

brain activity regularly increases to produce paradoxical sleep, which may include dreaming. Despite high brain activity during paradoxical sleep, it is essential for a good night's rest.

Brain patterns



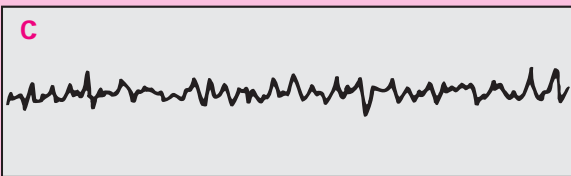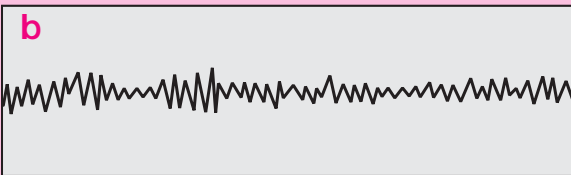
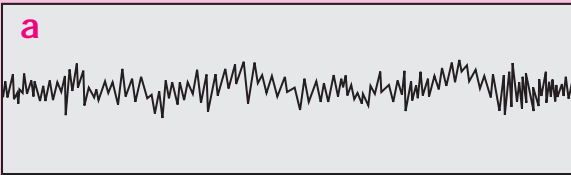
The sleep cycle

The two types of sleep (NREM and REM) alternate in cycles of roughly 90 minutes throughout the sleep period. The length of REM sleep periods increases as the cycle progresses. Most people experience four or five cycles per night.

EEGs Electroencephalograms (EEGs) are recordings of the brain's electrical activity—"brain waves." EEGs are used to monitor the brain's activity during sleep. Different brain waves are associated with the stages of sleep.

a Awake When a person is awake, EEGs typically record beta waves, which are associated with arousal, alertness, and mental activity.

b NREM sleep: stage 1 The eyes are closed and relaxation begins; body temperature, respiration, pulse, and blood pressure are normal. The EEG shows alpha waves.

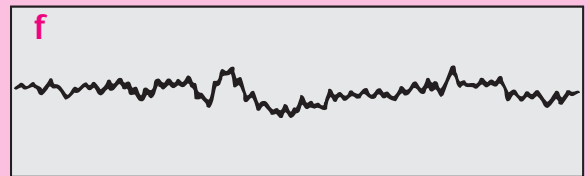
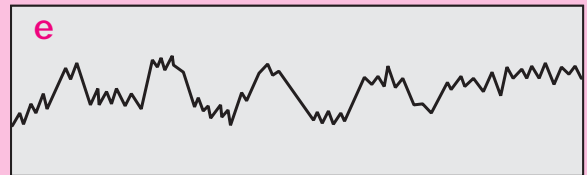
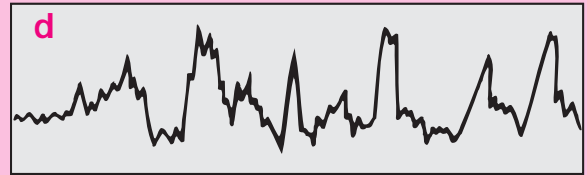


c NREM sleep: stage 2 The eyes roll from side to side; the EEG pattern becomes irregular.

d NREM sleep: stage 3 Sleep deepens, and the EEG shows theta and delta waves. Body temperature, respiration, pulse, and blood pressure decline; skeletal muscles become very relaxed.

e NREM sleep: stage 4 The EEG shows delta waves. Body temperature, respiration, pulse, and blood pressure are at their lowest levels; skeletal muscles are very relaxed. Bedwetting or sleepwalking may occur in stage 4.

f REM sleep The cycle then reverses through stages 4, 3, and 2, but instead of waking into stage 1, the sleeper enters REM sleep. The EEG shows similar patterns as for the awake state. It is in REM sleep that most dreams occur.



The origin of stress lies in survival. All animals are at risk of attack by a predator or being confronted with sudden danger. They need to be able to defend themselves either by fighting the threat or fleeing from it. The body prepares itself for these responses by releasing hormones into the blood. The modern era has produced its own stresses attacking mainly the mind, the senses, and the emotions, and the body undergoes similar physiological processes even though the source of the stress

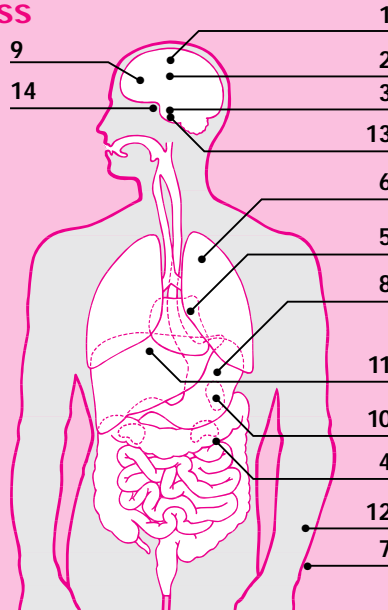
is psychological. An individual's ability to cope with stress will play a large part in determining his or her state of mental health. We look below at some of the causes and effects of stress.

The need for stress The human body and mind are built to thrive on a certain amount of stress. Many people find high levels of stress pleasurable when they provide challenges that have to be overcome. Such people include those taking part in highly

Physical effects of stress

The diagram shows the parts of the body affected when under stress. The body's instinctive reaction is either to fight or take flight.

- 1** The cerebral cortex receives and analyzes the incoming source of stress via the senses.
- 2** The brain then instructs the alarm center in the lower brain to prepare the parts of the body that need to take action.
- 3** The pituitary gland releases a hormone (ACTH) which will be carried in the blood.
- 4** The hormone is carried to the adrenal glands, which sit just above the kidneys. The glands release two hormones, epinephrine and norepinephrine, and cortisones. These



- substances adjust body functions to prepare for sudden activity.
- 5** The heart speeds up and pumps blood more quickly.
- 6** Breathing rate increases and air passages in the lungs dilate to collect more oxygen for delivery to the muscles.

- 7** Blood vessels constrict making the skin pale.
- 8** Blood vessels constrict in the stomach area.
- 9** More blood is diverted to muscles and brain as a result of actions 7 and 8.
- 10** The spleen contracts, releasing more red cells into the blood to carry more oxygen.
- 11** The liver releases supplies of sugar while cholesterol is released into the blood from deposits in the body. Both these substances provide energy.
- 12** The skin begins sweating, ready to shed excess heat.
- 13** The blood-clotting system is enhanced. White blood cells count goes up.
- 14** Stress hormones reduce sex drive.

competitive or dangerous sports, and those who thrive on careers that put them under constant pressure.

Mental problems About 15 percent of the U.S. population suffers a psychiatric or psychological disorder at some time in their lives. More people are being treated both in and out of hospitals than in the past, although the stays in hospitals tend to be shorter. We outline some of the types of treatment available (see pages 50–51). Rather

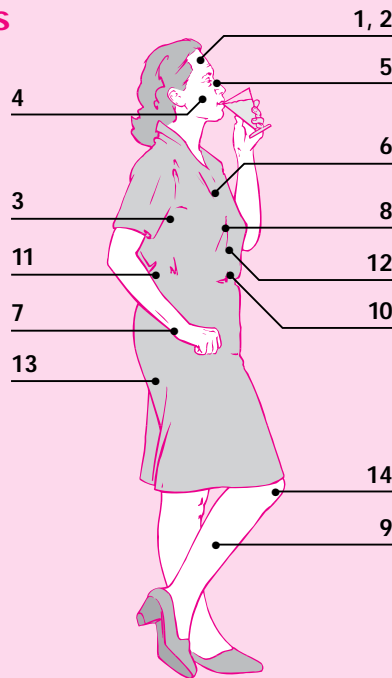
than pointing to an increase in mental illness, however, the pattern may suggest that more people are willing to seek treatment, and to admit to themselves that they might have a problem. The stigma once attached to mental illness is gradually diminishing. But the onset of mental disturbance can be so gradual that sufferers may be unaware that anything is wrong; here we describe what can go wrong, what to look for, and how to help before professional treatment is required.

Complications of stress

Stress contributes to the following physical disorders:

- 1 Headaches
- 2 Exhaustion
- 3 Excessive sweating
- 4 Facial flushing
- 5 Nasal catarrh
- 6 Asthma attacks
- 7 High blood pressure
- 8 Heart disease
- 9 Skin diseases
- 10 Indigestion and stomach ulcers
- 11 Back pain
- 12 Diabetes
- 13 Diarrhea
- 14 Rheumatism and arthritis

Excessive stress may also result in psychological disorders: **Depression.** A minority of people may suffer from manic depression, which is cycles of euphoria



alternating with severe depression.

Postpartum depression is caused by hormone changes, childcare problems, separation from the baby, or lack of self-confidence.

Schizophrenia is often brought on by stress within the family. Symptoms may include deterioration of personality, illogical thought, seeing visions, hearing imaginary voices, and delusions of persecution (paranoia).

Anorexia nervosa is self-starvation usually affecting insecure or over-pressurized adolescents.

Aggressive behavior may be caused by stress. **Overdependence on drugs** frequently results from stress.

Neuroses such as panic attacks and palpitations, phobias, hypochondria, hysteria, amnesia, and obsessions may develop in a person anxious to escape from stress.

Relaxation techniques aim to combat stress by bringing the “fight or flight” response of the body under control. Eastern methods, although they are not widely recognized by the Western medical profession, are often beneficial as they are not merely physical exercises but aim to integrate the mind and body. Hatha yoga, the physical side of yoga, is a series of postures or poses; some are

illustrated here. Correct breathing and slow, graceful progress toward the more advanced poses are essential. The Chinese exercises, originally based upon the movements of animals, put the emphasis on continuous movement sequences designed to allow the body’s physiology to work freely, instead of being hindered by holding the breath or maintaining a set position.

Standing poses

1 This position is called the triangle. Start with your arms stretched out to the sides, then bend from the hips with one hand moving down your leg as shown. The other arm can be moved as far as possible over your head until it is parallel to the ground.

2 The reverse triangle involves bringing the lower arm over to the opposite leg so that your trunk is twisted as shown.

3 The side bend is performed with the legs together and your arms above your head; keep your arms parallel and stretch them as far over as you can.

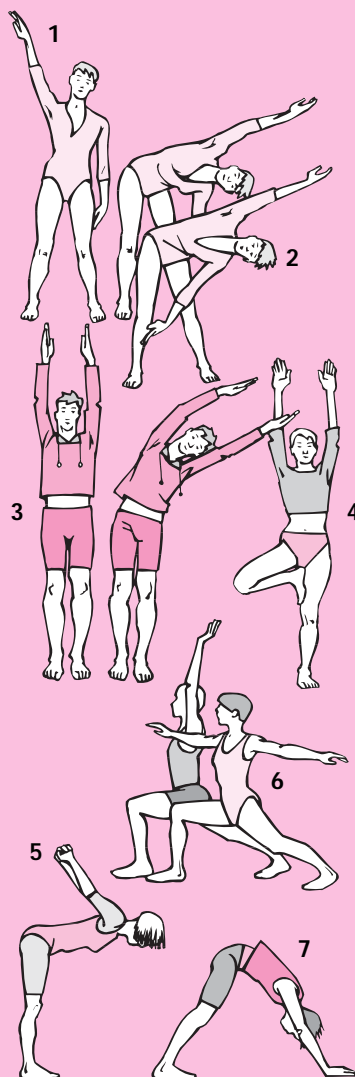
4 To do the tree pose, stand on one leg with the foot of the other resting as high as possible on the thigh. Stretch your

arms as high as possible above your head.

5 Starting with the basic standing pose, clasp your arms behind you, then bend forward so that the trunk is perpendicular to your legs.

6 Lunge forward on one leg so that your front leg is bent and your back leg straight. Two alternate positions for the arms are shown.

7 Form an equilateral triangle by stretching your arms forward and your legs back as shown.



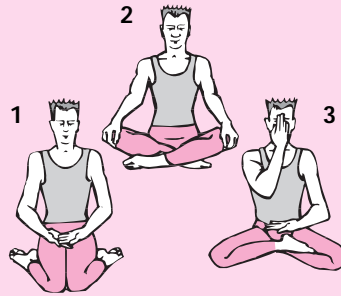
Yoga safety

- Yoga involves many standing, sitting, and lying poses, and several inverted handstands.
- When practiced with proper supervision, yoga can be both physically and mentally rewarding.

Breathing exercises

The type of breathing that is most helpful in yoga involves exhaling deeply to empty the lungs and then expanding the chest as you inhale deeply. Your stomach muscles should be pulled in and your nostrils should be relaxed; you should be aware of your chest and stomach movements.

1 To practice deep breathing, kneel with your knees together and



your feet apart; keep your back straight and hold your hands palms upward.

2 To practice full-lung breathing sit cross-legged. Breathe in slowly to fill the lungs from the bottom up. Swallow, press the tongue

against the roof of your mouth, and hold your breath. Exhale steadily.

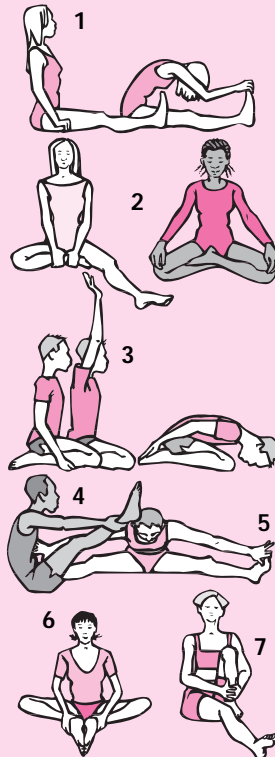
3 For alternate nostril breathing, place the first and second fingers of your right hand on your forehead with the thumb beside your right nostril and your third fingers beside the left. Using your fingers to close each nostril in turn, breathe in slowly through one nostril and blow out through the other. Repeat using the other hand.

Sitting poses

1 Sit with your legs stretched out to the front, and lean forward to grasp your toes. With practice you will be able to pull your head down onto your knees.

2 This is the classic lotus position. Place your right foot on your left thigh and then your left foot on your right thigh.

3 Sit between or on your feet, then raise your arms above your head. Breathing out, lower your arms, place your hands on the soles of your feet, and bend your trunk forward. Sit up, breathing in.



4 Balancing on your bottom, raise your legs and hold them up with your hands as shown.

5 This position requires a good deal of suppleness; sit with your legs wide apart and stretch your arms to grasp your feet, hooking your fingers around the big toes.

6 Sit with your knees flat and the soles of your feet touching; clasp your feet with your hands.

7 Sit with one leg straight across your body while the other leg is brought up to the body and held by the hands.

Effects of smoking

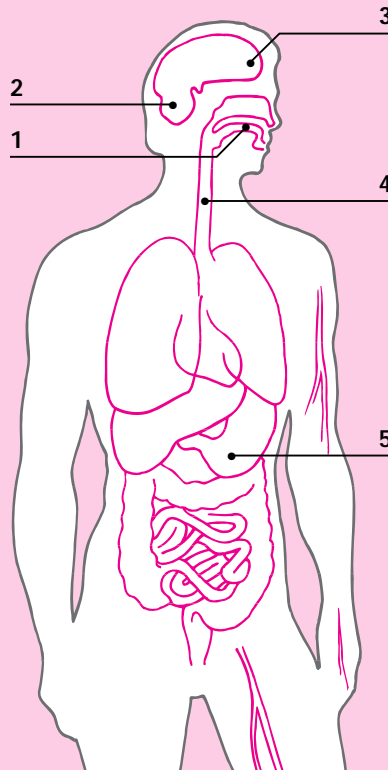
This diagram illustrates some of the parts of the body affected when a cigarette, cigar, or pipe is smoked. These effects wear off gradually when the smoking stops, but if smoking is frequent or continuous the affected parts of the body have no time to revert to their normal states.

1 Nicotine is absorbed through the lining of the mouth (as well as through the lungs) and enters the bloodstream.

2 The nicotine releases a small quantity of catecholamines, which subdue the transmission of nerve signals and so reduce feelings of fatigue and hunger.

3 The toxins carbon monoxide and cyanide in the smoke may cause a headache. Carbon monoxide is only absorbed through the lungs, and its presence in the bloodstream indicates that the smoker is inhaling the smoke into the lungs.

4 Nicotine acts on the nerves, and paralyzes the cilia of the airways. Cilia are the tiny hairlike



projections responsible for removing the mucus that traps harmful particles. When they are put out of action, the mucus and the particles remain in the airways. Nicotine also inhibits the alveolar phagocytes, which are normally responsible for engulfing and destroying the bacteria and viruses in inhaled air; one cigarette puts them out of action for 15 minutes.

Everyday drugs

Drugs are contained in many preparations that are not always associated with drug-taking. Alcohol and nicotine are drugs, and so is the caffeine in coffee, tea, and cola. People also use painkillers, laxatives, diarrhea medications, antacids, cough medicines, and cold remedies, all of which are drugs. Even homeopathic medications are drugs; the difference is that they are used in infinitesimally small amounts.

5 Hunger is abated because of the action of the nicotine on the autonomic nervous system. This is the part of the nervous system that governs the actions of the involuntary smooth muscles, including those that work in the esophagus, stomach, and intestines. Slight nausea may be experienced if the stomach is empty, but this soon passes.

Alcohol is an intoxicating drug known since ancient times. It has anesthetic properties and acts as a tranquilizer and a depressant. It induces mood changes not by acting as a stimulant, as many people think, but by depressing the part of the brain that controls impulsive behavior, judgment, and memory. Alcohol in small quantities can be used

effectively to ease tensions and overcome shyness, but heavy drinking can lead to alcoholism, fatal diseases, and serious social problems such as traffic offenses, marital strain, and violence. Here we look at the nature and effects of alcohol use and suggest ways of preventing abuse and its serious consequences.

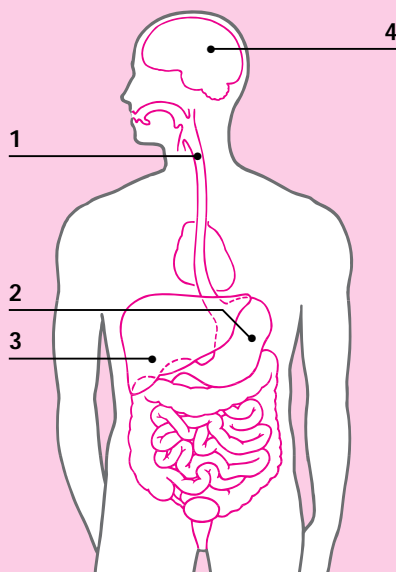
Effects of alcohol

The diagram illustrates some of the parts of the body affected when a person drinks alcohol. These effects wear off gradually, but there could be lasting complications with continuous, heavy use of alcohol.

1 As alcohol passes through the mouth, throat, and gullet, it irritates the membranes lining these passages and increases the secretion of saliva. Alcohol can be smelled on the breath.

2 Alcohol also irritates the lining of the stomach. Heavy drinking causes the stomach lining to become thickened and overactive. This often leads to gastritis, with its symptoms of indigestion, retching, and loss of appetite.

3 Alcohol is absorbed from the stomach and intestines into the



bloodstream, which carries it to the brain and other organs. In the liver, alcohol is broken down by the enzyme alcohol dehydrogenase (ADH).

4 Alcohol has its greatest effect on the brain. Perception, reaction time, agility, memory, and problem-solving are all impeded. Drinkers may also become emotional.

Nonprescription drugs

Nonprescription drugs are generally taken for the conditions listed below. Dependency on these drugs begins when the user takes drug as a “preventive” against illness or takes the drug for its side-effects rather than its intended use.

Headache The most common use of painkillers, such as aspirin or acetaminophen.

Fatigue Overtiredness may be combated with stimulants, usually in the form of caffeine, or large doses of vitamins.

Insomnia Over-the-counter remedies usually contain antihistamines or analgesics.

Disorders of the brain and nerves

Amnesia The inability to memorize and/or to recall previously memorized information. This can be caused by damage to the brain resulting from physical injury or disease.

Anencephaly A condition in which a child is born with an incomplete brain. The child has no mental life as we understand it. Usually, death occurs soon after birth.

Cerebral edema Swelling of the brain often resulting from head injury.

Cerebral hemorrhage Bleeding inside the brain caused by a ruptured blood vessel. The escaped blood damages the surrounding nerve cells. When the blood clots, it applies pressure to the brain tissue. High blood pressure is one major cause of cerebral hemorrhages.

Cerebral palsy The poor control over, or paralysis of, voluntary muscles resulting from damage to the developing brain. Categories of disability caused by cerebral palsy include: diplegia, in which all four limbs are affected but the legs more severely than the arms (see below); hemiplegia in which the limbs on only one side of the body are affected; and quadriplegia, in which both arms and both legs are severely affected.

Concussion A slight injury to the brain that inevitably causes a temporary loss of consciousness.

Dyslexia A disorder in which the brain has difficulty with reading, writing, and counting. Intelligence is not affected, but letters in words may appear transposed or reversed, for example.

Epilepsy Recurrent and abnormal seizures caused by abnormal and irregular discharges of electricity from the millions of neurons (nerve cells) in the brain.

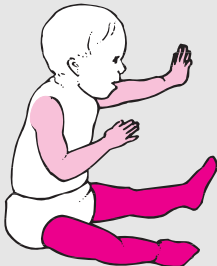
Meningitis Inflammation of the linings of the brain (meninges) usually caused by an infection.

Paraplegia The paralysis of the lower limbs resulting from damage to the spinal cord between the first thoracic vertebra and the first lumbar vertebra.

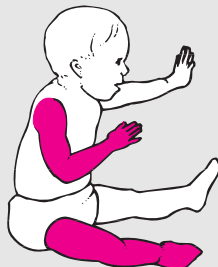
Reye's syndrome A brain dysfunction sometimes following chickenpox or influenza (flu).

Tay-Sachs disease Degeneration of the central nervous system caused by excessive amounts of a chemical called ganglioside in the brain.

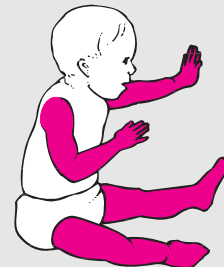
Forms of cerebral palsy



Diplegia



Hemiplegia

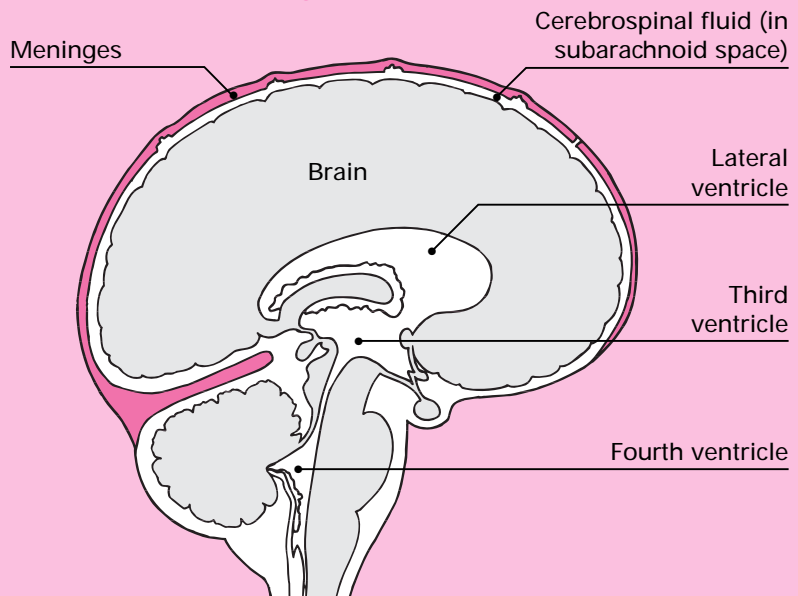


Quadriplegia

Meningitis

The brain and spinal cord are surrounded by three membranes known as the meninges. From the outside in, the meninges are the dura mater, the arachnoid, and the pia mater. Cerebrospinal fluid is held between the arachnoid and pia mater meninges. Meningitis is an infection of the fluid and membranes, caused mainly by bacteria or viruses. The disease can cause brain damage and occasionally death.

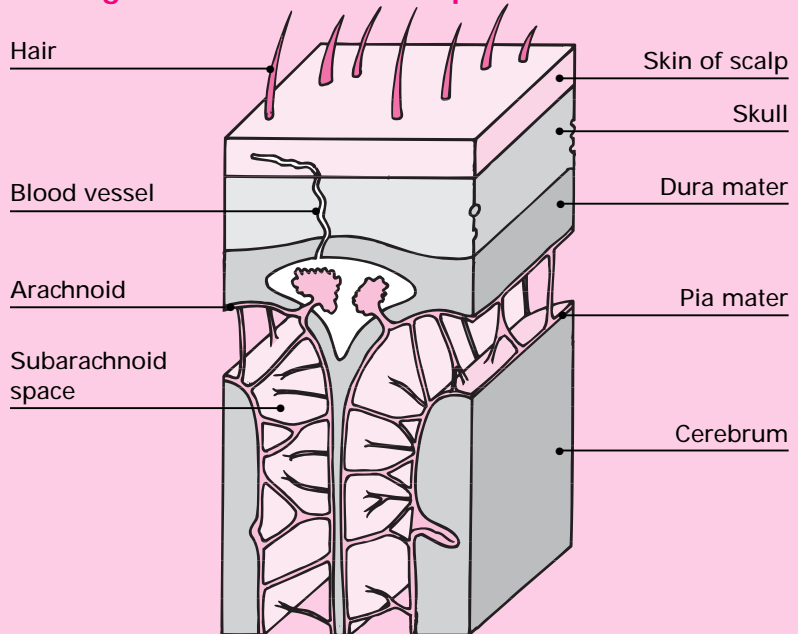
Cross section through the brain



Cerebral hemorrhage

A cerebral hemorrhage is bleeding inside the brain. This is caused by a break in a blood vessel. This may be caused by high blood pressure, hardened arteries, or a weakness in the vessel wall. Cerebral hemorrhages are one cause of a stroke because they disrupt the blood supply. Bleeding into the cerebrospinal fluid that surrounds the brain and spinal cord between two membranes is called a subarachnoid hemorrhage.

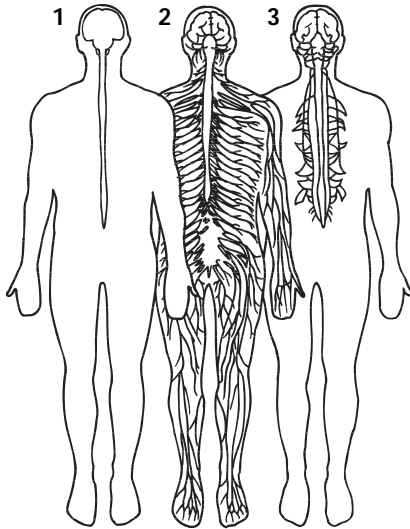
Meninges and subarachnoid space



The spinal cord is the main connection between the body and the brain. It is classed as part of the central nervous system. The spinal cord extends from the brainstem at the base of the brain about two-thirds down the back. It is held inside rings of bone called vertebrae. A column of these bones form the spine. The spinal cord is connected to the rest of the body by 61 spinal nerves. These are connected to both receptors and effectors. Simple reflex actions, such as the knee-jerk response and blinking of the eyes, are controlled entirely by the spinal cord.

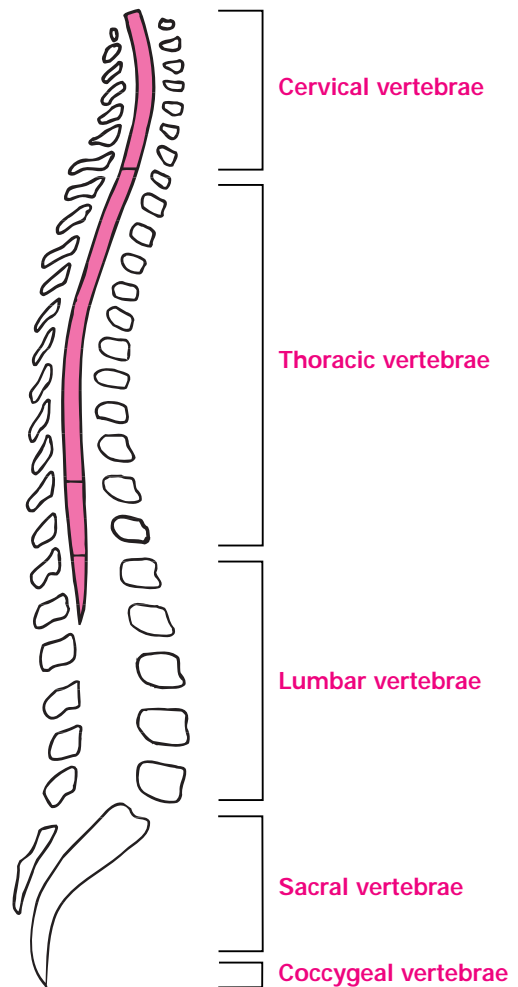
Three-in-one

Along with the brain, the spinal cord forms the central nervous system (1). Most of the nerves in the peripheral nervous system—the somatic (2) and autonomic (3)—extend from the cord.



The spine

The spinal cord is protected inside the spine, or vertebral column. The spine is divided into five sections, in descending order: cervical, thoracic, lumbar, sacral, and coccygeal.



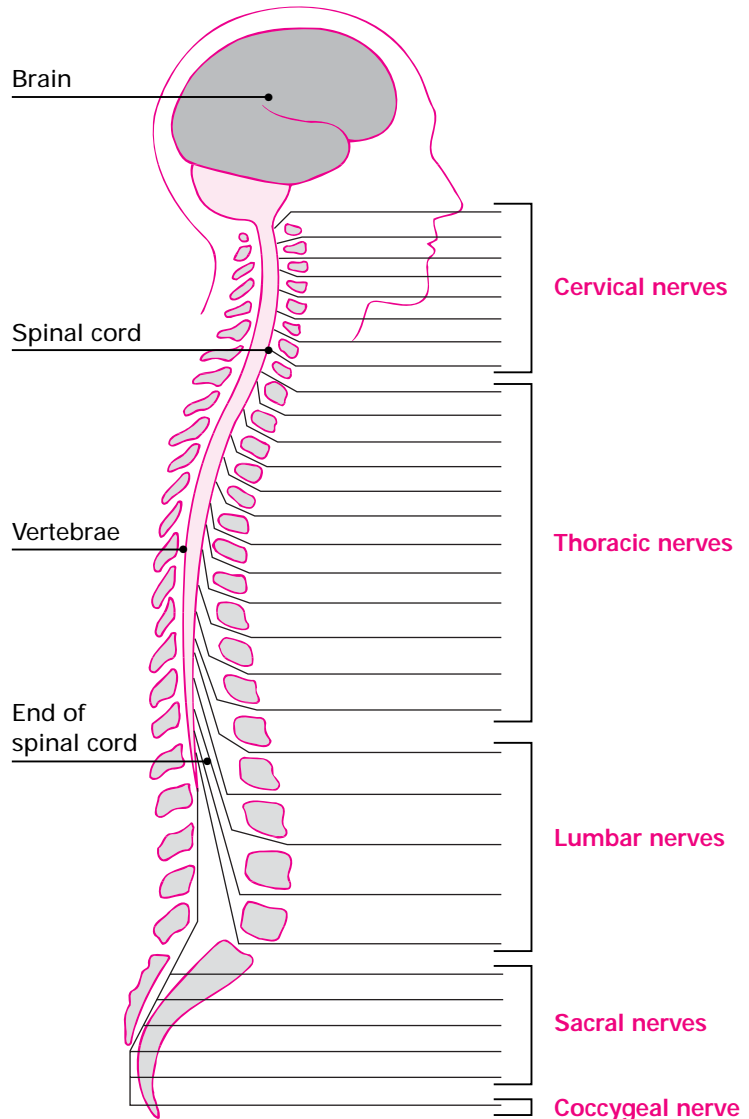
Location and structure

Housed by protective vertebrae, the spinal cord runs from the brain and ends at the first lumbar vertebra, where lumbar nerves carry information to and from the lower regions of the body.

Spinal nerves

There are 30 pairs of spinal nerves, plus a single nerve, leaving the spinal cord and traveling to the rest of the body. These are divided into the following groups:

- eight pairs of cervical nerves supplying the throat, chest, arms, and hands;
- 12 pairs of thoracic nerves supplying the part of the body from the top of the breastbone to the bottom of the ribs and the abdomen;
- five pairs of lumbar nerves supplying the front of the legs and feet;
- five pairs of sacral nerves;
- the coccygeal nerve supplying the soles of the feet and backs of the legs.



The spinal cord

The spinal cord is not just a uniform cable of nerves extending from the brainstem. It changes in shape and size at different points along the spine. The spinal cord terminates in the lower back

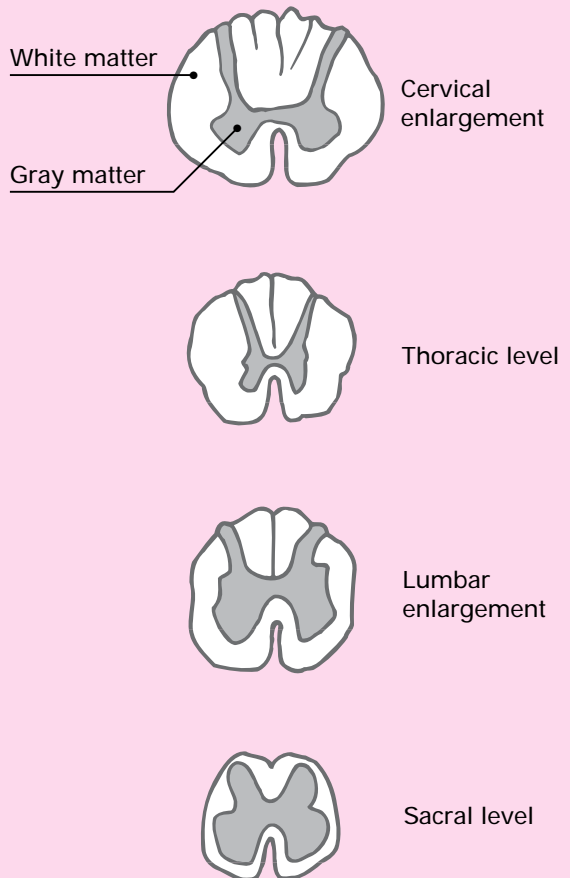
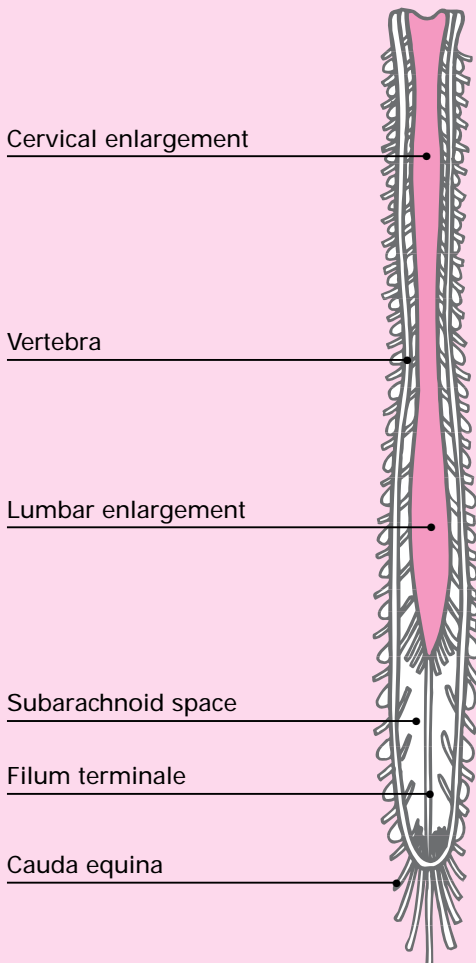
region, but the filum terminale extends to the very tip of the spine. The spinal cord is enclosed in meninges. The subarachnoid space between these membranes contains fluid.

Section through spinal cord

The cord is housed inside vertebrae. The spinal nerves that serve the lower body form bundles called cauda equina.

Transverse sections through spinal cord

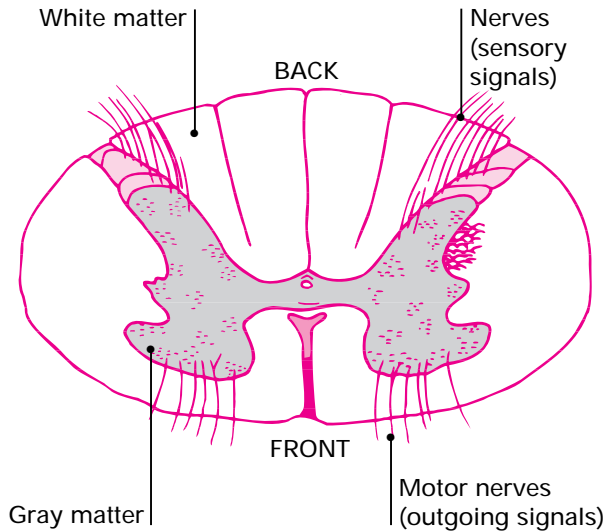
The proportions of white and gray matter vary at points along the cord.



Function of the spinal cord

The spinal cord is a two-way pathway of nerves conducting information to and from the brain.

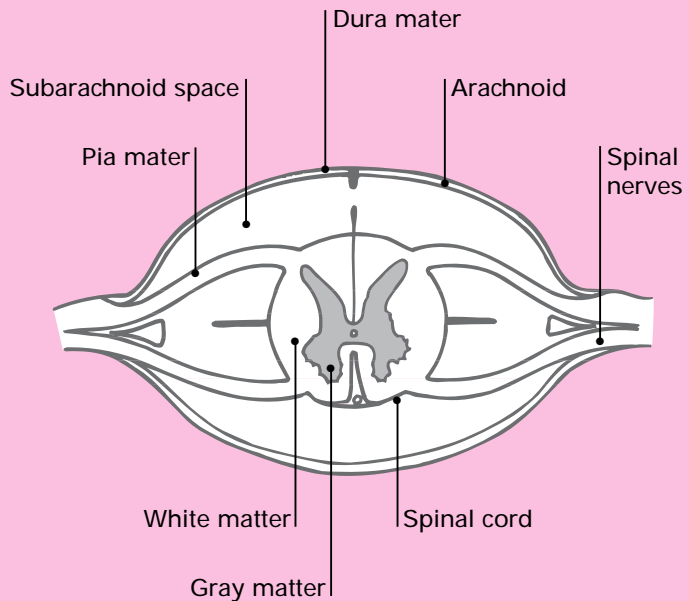
- White matter conducts signals up and down the spinal cord.
- Butterfly-shaped gray matter transmits signals into and out of the cord.
- Nerves arising from the part of the gray matter facing the front of the body carry outgoing signals and control muscles.
- Nerves carrying sensory signals from the body's surface, and from deeper structures such as muscles, enter the spinal cord from the opposite side.



Spinal cord structure

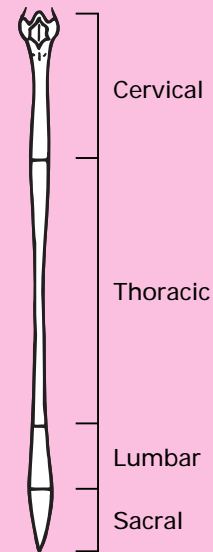
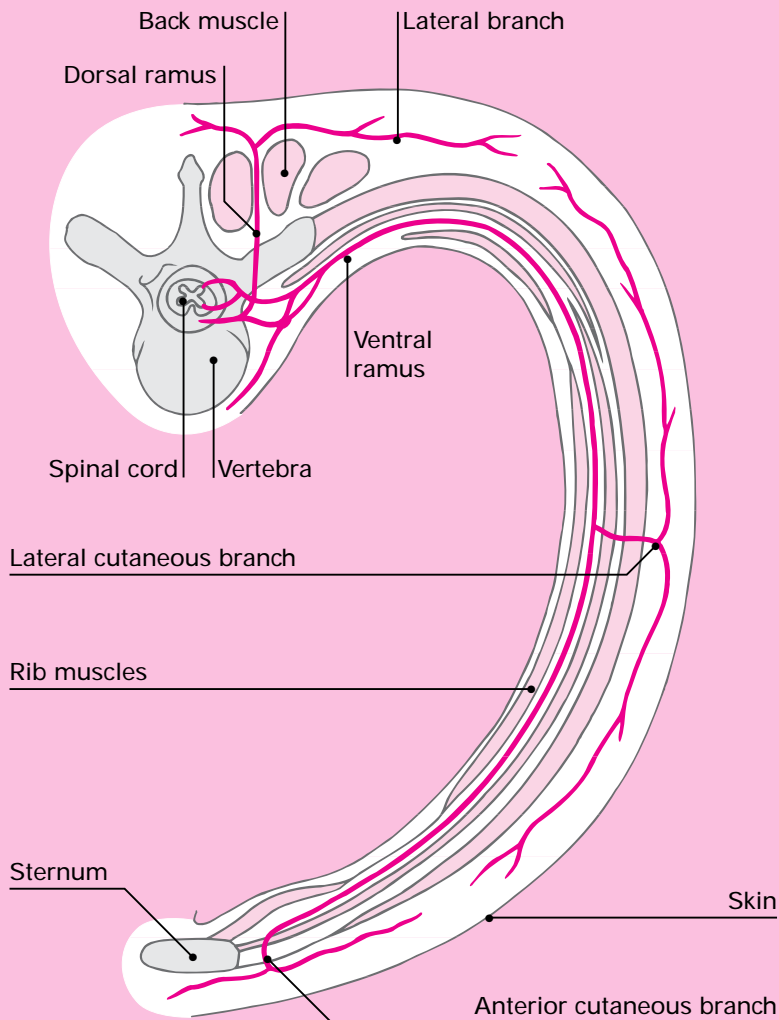
As part of the central nervous system, the spinal cord is surrounded by three membranes called meninges. From the outside in, these are the dura mater, the arachnoid, and the pia mater. The subarachnoid space between the second and third meninges contains cerebrospinal fluid. Spinal nerves pass through the membranes as they connect to the white matter of the spinal cord. The white matter is made up of myelinated nerve fibers used for carrying impulses at high speeds. The gray matter is unmyelinated cells.

Transverse section through spinal cord and its membranes



Course of a typical thoracic spinal nerve

This thoracic spinal nerve is serving a region of the ribcage and upper back. Soon after it emerges from the spinal cord, the nerve divides. The dorsal ramus passes through back muscles to the tissue beneath the skin of the back. The ventral ramus runs through rib muscles. Two branches serve the rest of the dermatomes (see opposite page).



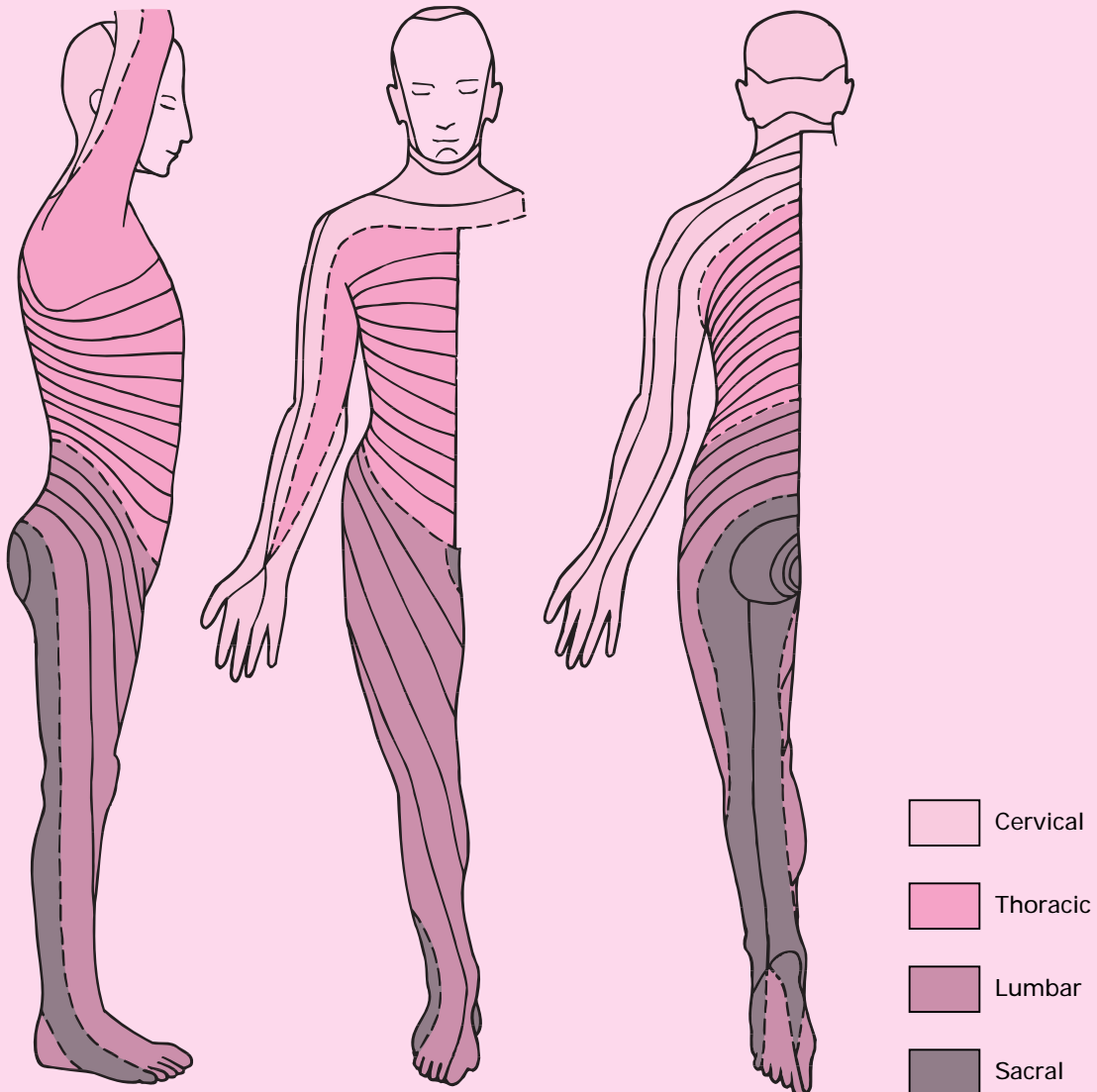
Spinal nerves

- Most spinal nerves are paired. One nerve serves one half of the body.
- Only the single coccygeal (tail) nerve is not paired, although it soon divides.
- Spinal nerves form a ganglion before they enter the spinal cord.

Dermatomes

The receptors in the skin, such as those sensitive to touch, heat, and cold, are connected to the brain via spinal nerves. Each spinal nerve carries signals from certain areas of the body surface called

dermatomes. Cervical nerves serve the head, neck, and arms. The torso is served by thoracic nerves, while lumbar and sacral nerves serve the legs, feet, and buttocks.



The cranial nerves

There are 12 pairs of cranial nerves. They are mainly concerned with the head and neck areas.

1 Olfactory nerve This carries smell signals from the lining of the nostril.

2 Optic nerve This sends the brain signals that code images formed on the retina at the back of the eye.

3 Oculomotor nerve This works four of the six muscles that control the eyeball and the muscle that controls the pupil.

4 Trochlear nerve This works the eyeball's superior oblique muscle and coordinates with the oculomotor and abducens nerves.

5 Trigeminal nerve This transmits sensations from the face. It also activates the jaw muscles that chew.

6 Abducens nerve This controls the outer muscle of the eye.

7 Facial nerve This works the muscles that control facial expression. It also brings sensations to the brain from taste buds on the front of the tongue.

8 Acoustic nerve This carries nerve impulses that code sounds detected by the ear. It also sends signals from the organs of balance in the ear.

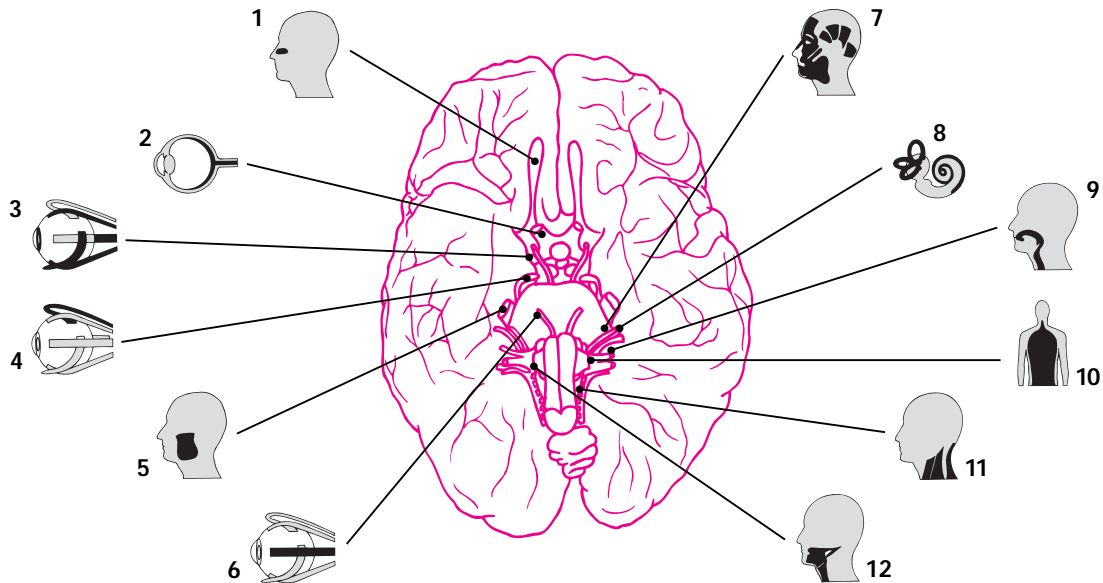
9 Glossopharyngeal nerve This carries taste sensations and signals from the throat to stimulate swallowing.

10 Vagus nerve This carries impulses from and to the pharynx and the main organs. It helps to regulate breathing, heartbeat, and digestion.

11 Accessory nerve This controls the turning of the head and shoulders.

12 Hypoglossal nerve This carries signals from the brain to the tongue and effects the movement of the tongue.

Base of brain showing cranial nerves



Cranial nerves**Nerves****Main function****Olfactory nerve**

Sense of smell.

Optic nerve

Sense of sight.

Oculomotor nerve

Motor supply to muscles that move eyes, eyelids, and lens and pupil size.

Trochlear nerve

Motor supply to superior oblique muscle (that moves eye).

Trigeminal nerveSensory input from eye, face, lining of the nose, teeth, gums, and front of the tongue.
Motor supply to chewing muscles.**Abducens nerve**

Motor supply to lateral rectus muscle (that moves eye).

Facial nerveMotor supply to muscles of facial expression; salivary glands; tear gland; mucous glands of nose and mouth.
Taste input from the tongue, and sensations from outer ear.**Acoustic nerve**

Sense of balance, head position, and hearing.

Glossopharyngeal nerveMotor supply to stylopharyngeus muscle and parotid salivary gland.
Sense of taste from posterior third of tongue; sensory input from blood pressure receptors in carotid artery.**Vagus nerve**Motor supply to pharynx, larynx, trachea, bronchi, lungs, heart, esophagus, stomach, intestines, liver, pancreas, and kidneys.
Sensory input from pharynx, larynx, and thoracic and abdominal organs.**Accessory nerve**

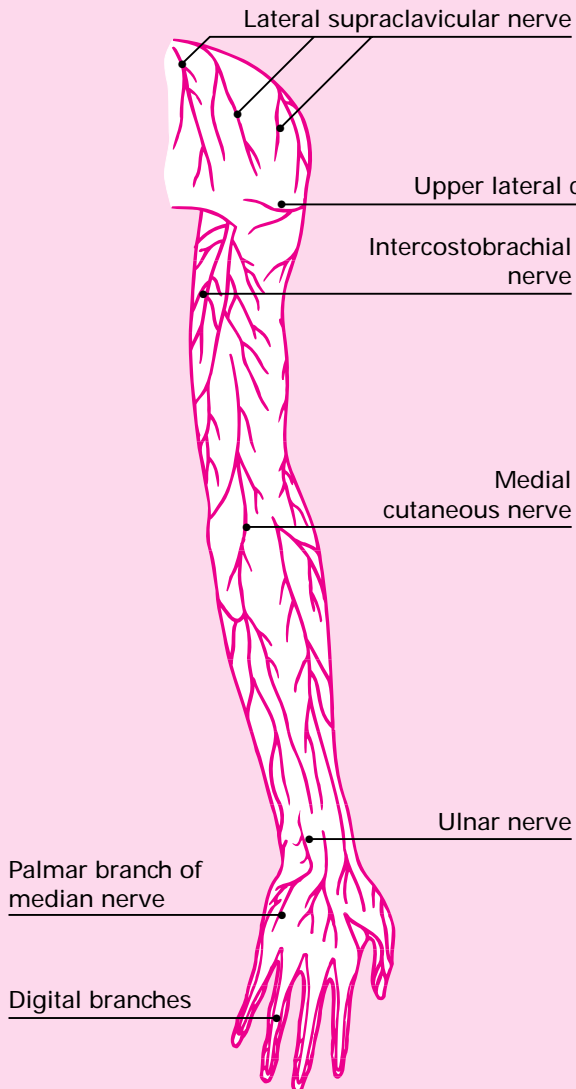
Motor supply to sternocleidomastoid and trapezius muscles (which control head movements); also muscles of soft palate, pharynx, and larynx.

Hypoglossal nerve

Motor supply to muscles controlling tongue (except palatoglossus muscle).

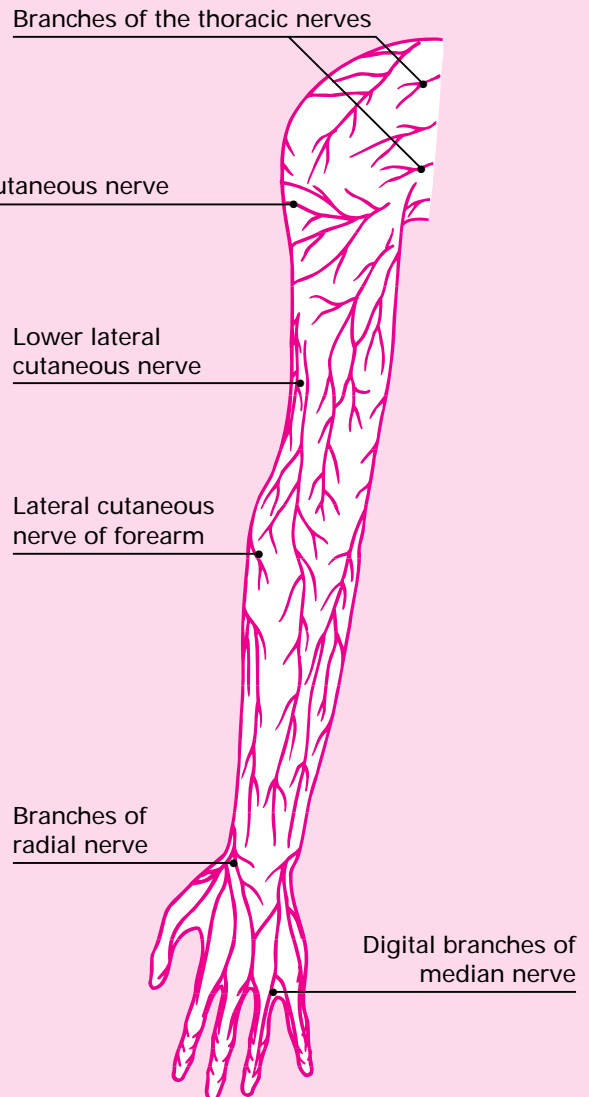
Left arm: anterior view

Deep nerves control the muscles that bend the arm at the elbow and flex the wrist and fingers. The many receptors in the palm of the hand and the fingertips are also served by cutaneous nerves.



Left arm: dorsal view

Among other things, these nerves control the muscles that straighten the elbow, wrist, and fingers. The nerves are named after their position in the arm, the place from where they have originated, or the function they serve.

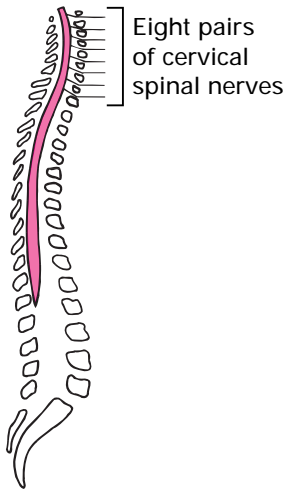


Cervicobrachial plexus

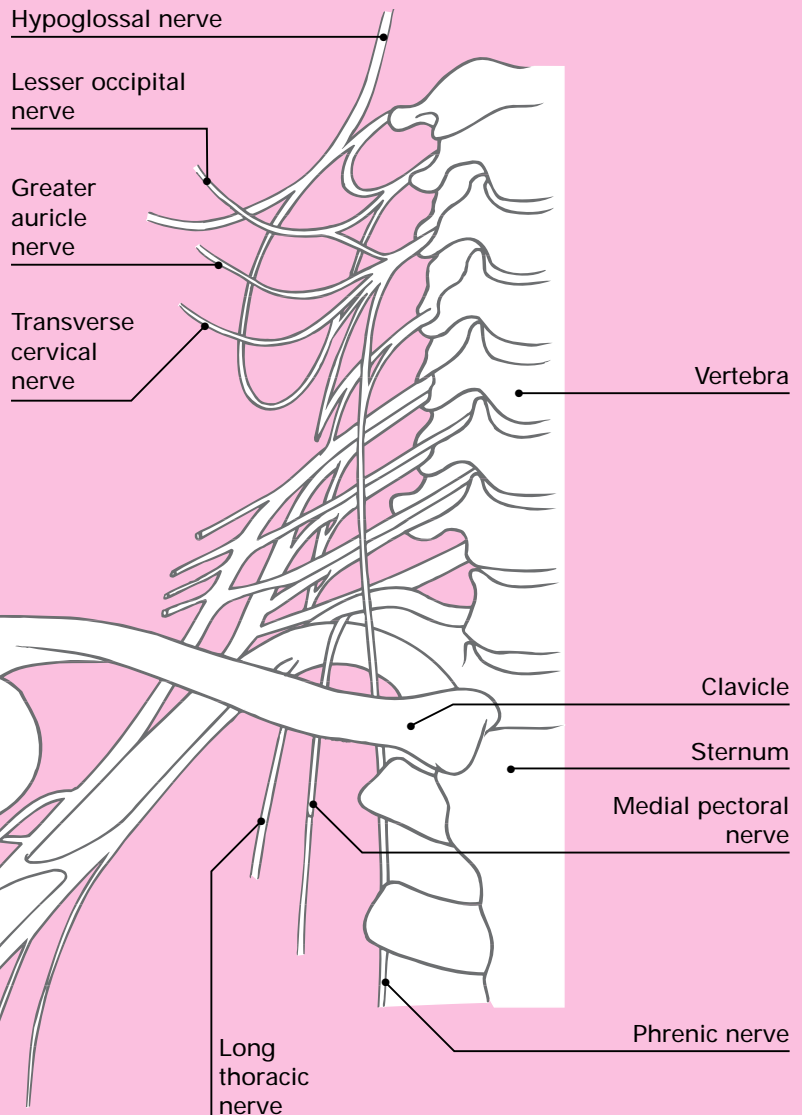
The nerves that serve the arm originate at the cervicobrachial plexus in the cervical level of the spinal cord.

Other nerves connected to the spinal cord in this region serve the neck, chest, and back.

Cervical region

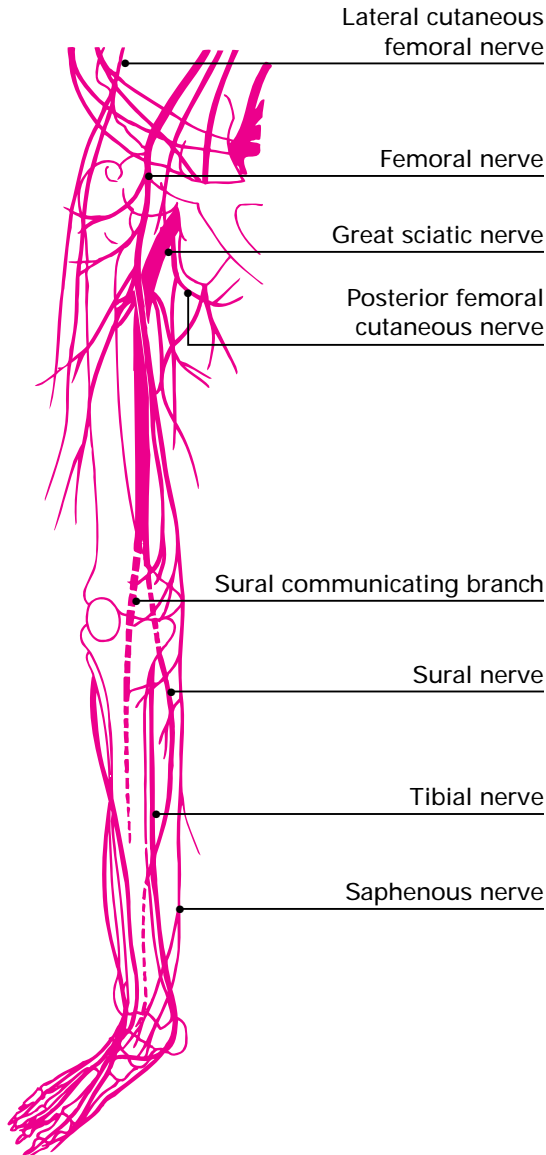


Cervical region of spinal cord



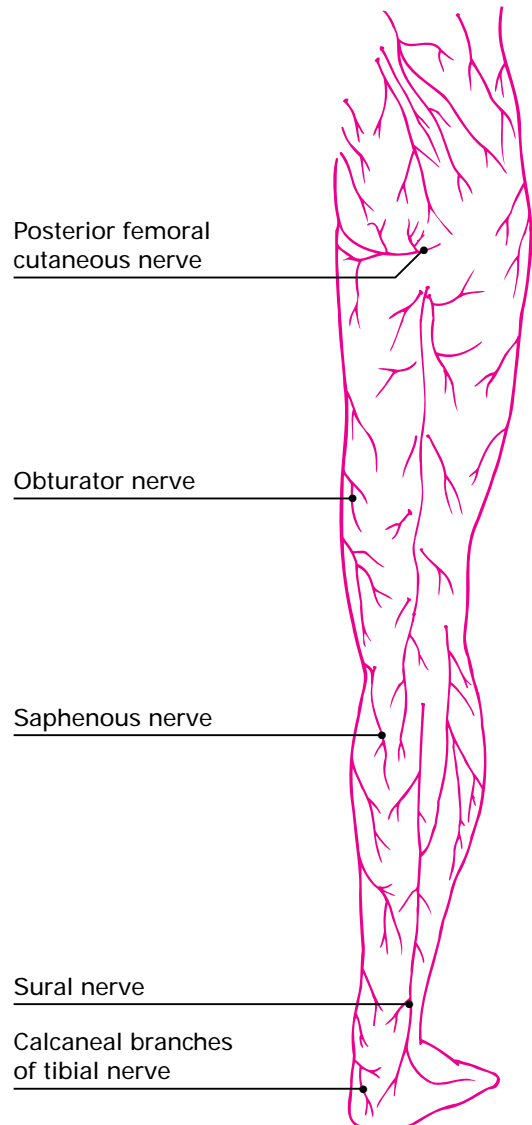
Deep nerves of right leg (anterior view)

Most of these deep nerves control the large muscles that move the leg. They are linked to the lumbar spinal cord.



Cutaneous nerves of left leg (posterior view)

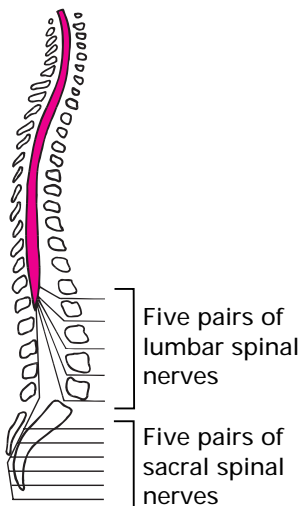
The nerves near the surface of the leg are concerned with carrying sensory information from cutaneous receptors.



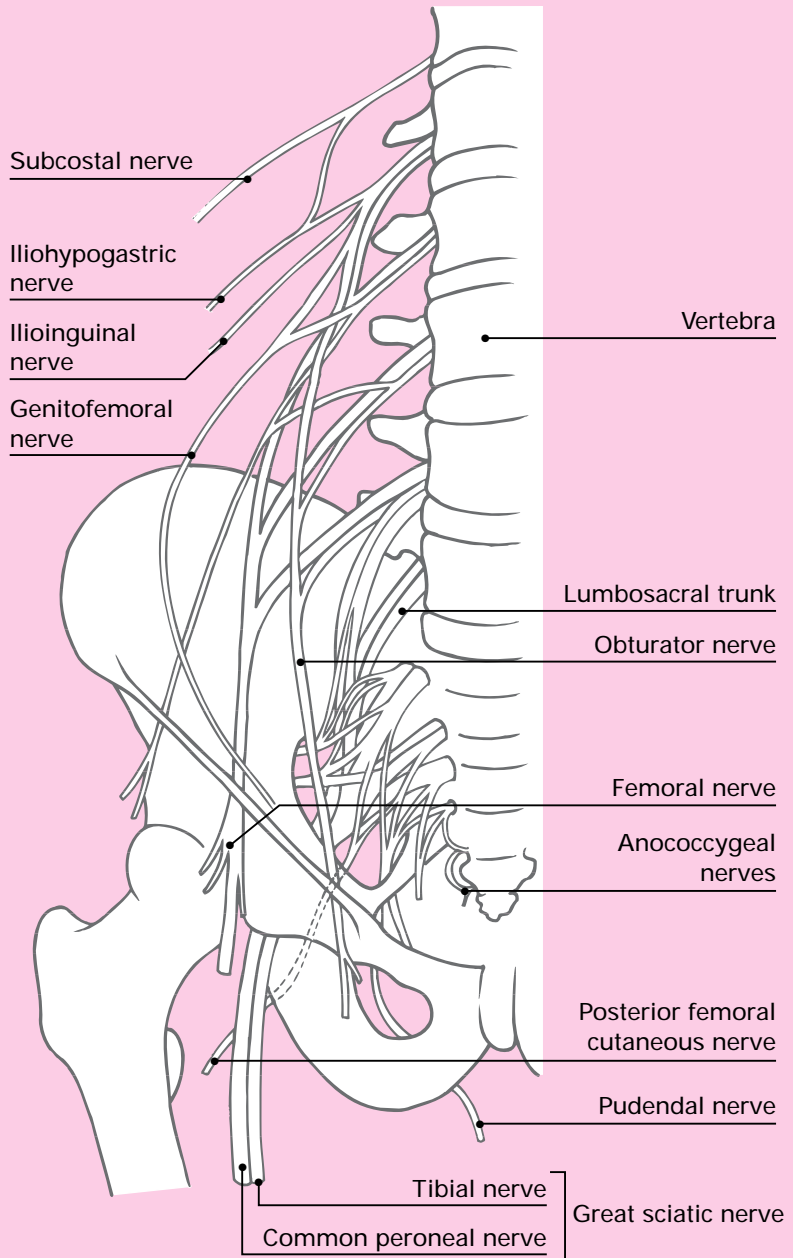
Lumbosacral plexus

The nerves of the leg, buttocks, groin, and intestines emanate from the lumbar and sacral regions of the spinal cord, forming the lumbosacral plexus. Since the spinal cord terminates in the lumbar region, many of these nerves form bundles called cauda equina (literally “horse tails”) that hang below the spinal cord. Most of the nerves pass through the pelvic girdle.

Lumbar and sacral region



Spinal cord showing lumbar and sacral regions



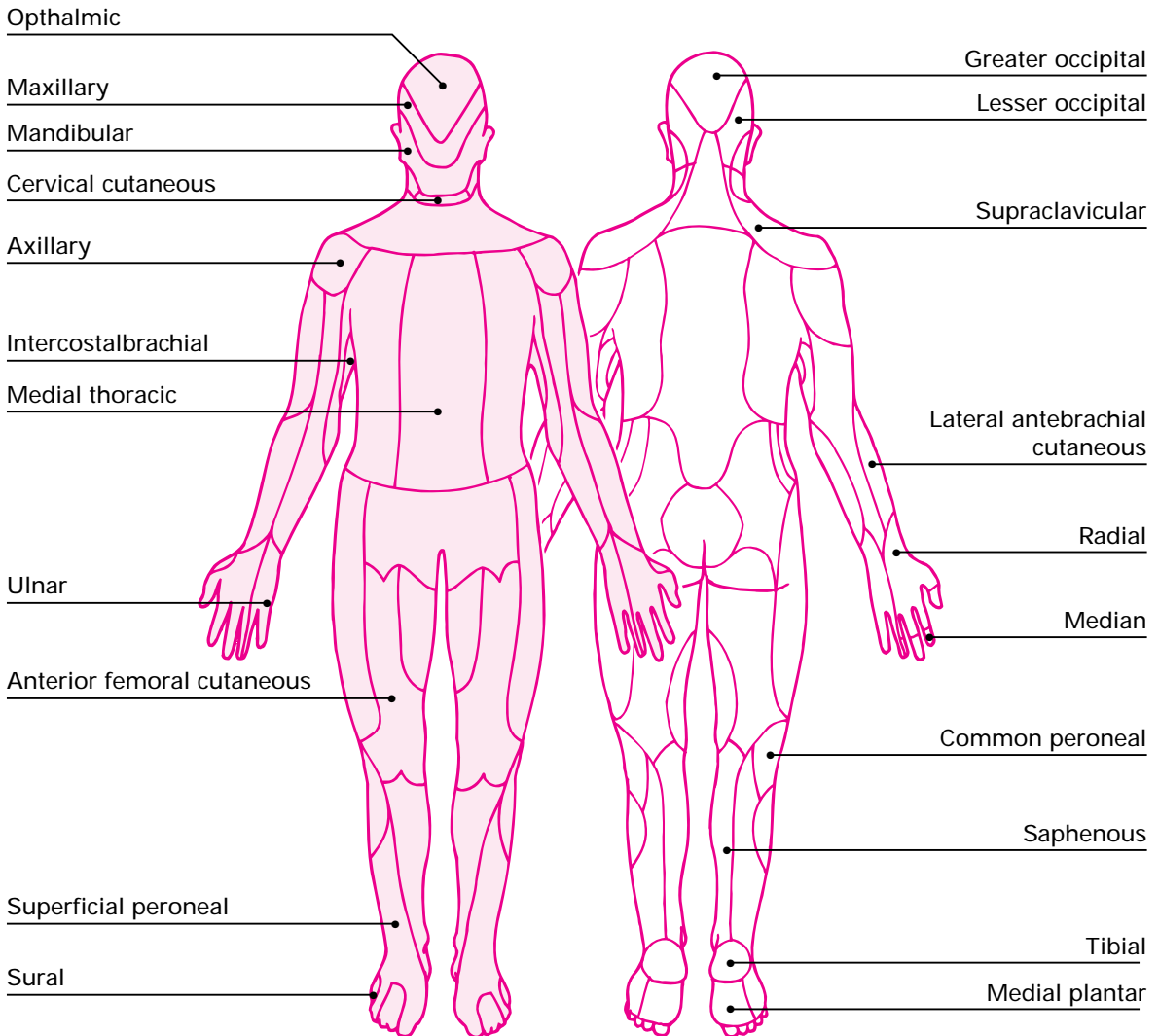
Sensory innervation

Each pair of spinal and cranial nerves is responsible for carrying sensory information from a specific region of the

body's surface to the brain. The same nerves also contain efferent neurons that carry the motor response.

Sensory innervation (anterior view)

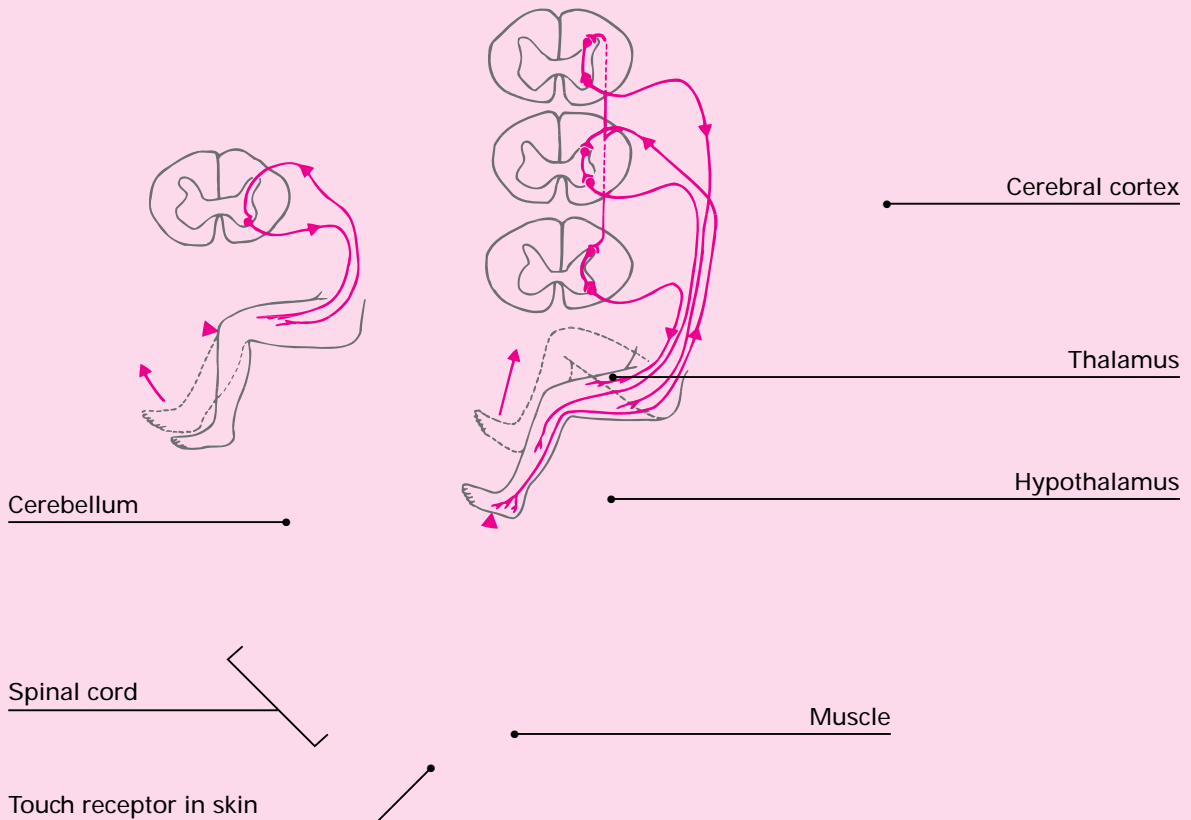
Sensory innervation (posterior view)



Nerve pathways

The diagram below shows how sensory impulses travel through the nervous system from a receptor in the skin to the spinal cord and brain. The signal is

directed to several regions. The spinal cord controls any reflex actions, the cortex creates the sensation, and the cerebellum coordinates the movements.



Neural circuits

- The impulses for simple reflex actions do not enter the brain.
- Signals to and from the cortex are directed through the thalamus.

Nerves of the cervicobrachial plexus

Nerve	Muscle supply	Sensory supply
Axillary nerve	Deltoid; teres minor	Skin of lateral and posterior upper arm
Median nerve	Forearm flexors, some hand muscles	Skin of radial palm; palmar skin of radial three and a half digits
Musculocutaneous nerve	Coracobrachialis; biceps brachii; brachialis	Skin of lateral forearm
Radial nerve	Triceps brachii; forearm extensors	Skin of posterior arm; skin of radial back of hand and three and a half digits
Ulnar nerve	Wrist flexors; intrinsic hand muscles	Skin of medial side of wrist, hand, and ulnar one and a half digits

Nerves of the sacral plexus

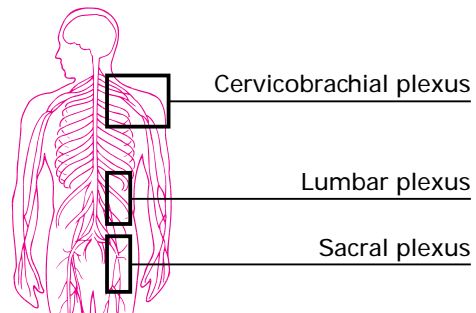
Anococcygeal nerve	None	Skin around anus
Inferior gluteal nerve	Gluteus maximus	None
Perforating cutaneous nerve	None	Skin of lower medial buttock
Posterior femoral cutaneous nerve	None	Skin of lower buttock and posterior thigh
Pudendal nerve	Perineal muscles	Genitals
Sciatic nerve	Muscles of lower leg and foot	Skin of leg and foot
Superior gluteal nerve	Gluteus medius; gluteus minimus; tensor fasciae latae	None

Nerves of the lumbar plexus

Nerve	Muscle supply	Sensory supply
Femoral nerve	Sartorius, rectus femoris, vastus lateralis, vastus intermedius, vastus medialis, pectineus muscles	Skin of anterior thigh, anteriomedial leg, and medial surface of foot and big toe
Genitofemoral nerve	Cremaster muscle	Skin of upper medial thigh and scrotum or labia majora
Iliohypogastric nerve	External oblique, internal oblique, and transversus abdominis muscles of lower abdominal wall	Skin of lower abdominal wall
Ilioinguinal nerve	External oblique, internal oblique, and transversus abdominis muscles of lower abdominal wall	Skin of lower abdominal wall and genital area
Lateral femoral cutaneous nerve	None	Skin of lateral thigh
Obturator nerve	Adductor longus, adductor brevis, adductor magnus, gracilis, obturator externus muscles	Skin of medial thigh

Plexi of spinal nerves

The spinal nerves associated with each level of the spinal cord form plexi (singular: plexus). These interlacing networks exist in pairs, each a mirror image of the other, on either side of the spine. They carry nerve impulses to and from specific parts of the body.



Protection for the brain

There are many layers of tissue, some protective, some supportive, between the brain and the outside air.

Skin of the scalp, with hair, fat, and tissues.

Periosteum, a thin membrane covering the skull.

Skull, housing the brain; its fused bones and domed shape give it strength.

Dura mater, a tough, inelastic outer meninge (membrane) immediately within the skull.

Between layers of dura mater are venous sinuses (channels that carry off used blood and cerebrospinal fluid).

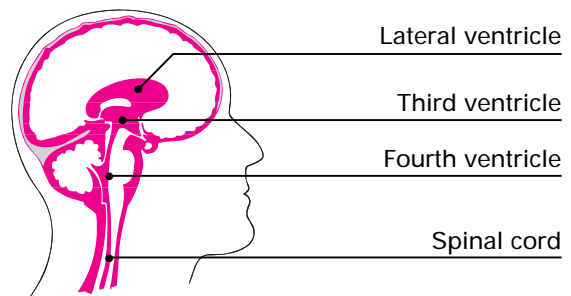
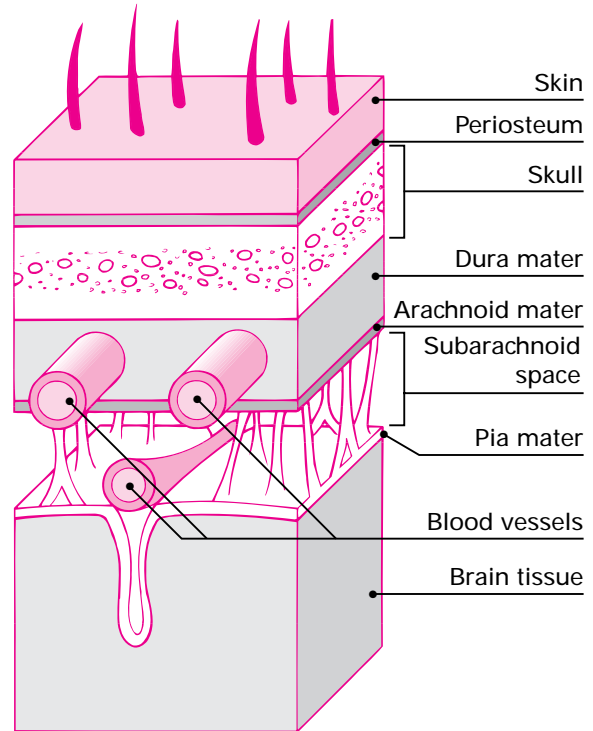
Arachnoid mater, an elastic membrane attached to the dura mater. Within it are arachnoid granulations (valves that control the flow of cerebrospinal fluid).

Blood vessels providing nourishment and oxygen for brain tissues.

Subarachnoid space through which cerebrospinal fluid circulates around the brain and spinal cord.

Pia mater, a thin membrane on top of the irregular surface of the brain itself.

Brain tissue, the soft tissue of the cerebral and cerebellar hemispheres.



Cerebrospinal fluid

The nervous system is protected against injury by cerebrospinal fluid which circulates through the subarachnoid space around the brain and spinal cord and through ventricles (fluid-filled cavities) in the brain. It is a clear, watery substance containing proteins, glucose, urea, and salts, and it serves as both a shock absorber for the central nervous system and a supplier of nutrients. It is made within the ventricles of the brain.

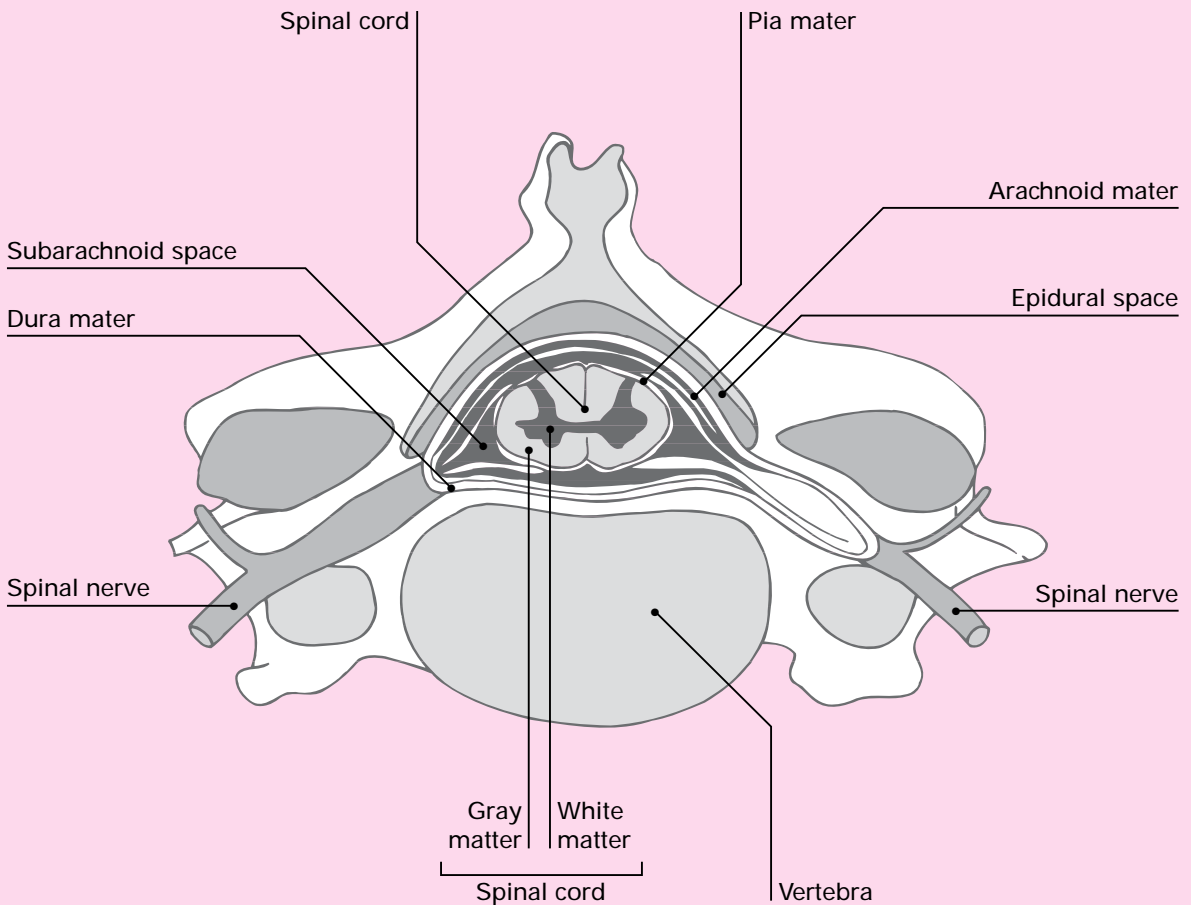
Ventricles

Within the brain lie several ventricles. These produce cerebrospinal fluid (from filtered blood plasma), which then circulates around the brain, spinal cord, and through the ventricles. The ventricles comprise two lateral ventricles under the cerebrum, the third ventricle above the brainstem, and the fourth ventricle between the pons and cerebellum. (The lateral ventricles were once called the first and second ventricles.)

Cross-section structure

The spinal cord, like the brain, is protected by bone, cerebrospinal fluid, and layers of tissue. The elements of the spinal cord are as listed here.

- Vertebra
- Epidural space, which contains fat cells and veins
- Dura mater
- Arachnoid mater
- Subarachnoid space filled with cerebrospinal fluid
- Pia mater
- The spinal cord containing gray and white matter
- The root of the spinal nerve



Disorders of the nervous system

Carpal tunnel syndrome A disorder with an unknown cause that results in pain in the fingertips and thumb. It is associated with repetitive actions causing tensions in the hand.

Multiple sclerosis (MS) The progressive destruction of the outer part of nerve cells, which affects their ability to transmit impulses.

Neuralgia Pain caused by nerve damage or irritation.

Neuritis The inflammation of a nerve or nerves.

Neurosyphilis The term used when the sexually transmitted disease syphilis (caused by a bacterium) attacks the nervous system.

Numbness Often temporary loss of sensation due to obstruction of impulses passed along sensory nerves. Can be caused by blood supply to a nerve being cut off after a person has remained in the same position for a long time (also causes “pins and needles”); by drugs (anesthesia); or by damage to the nervous system.

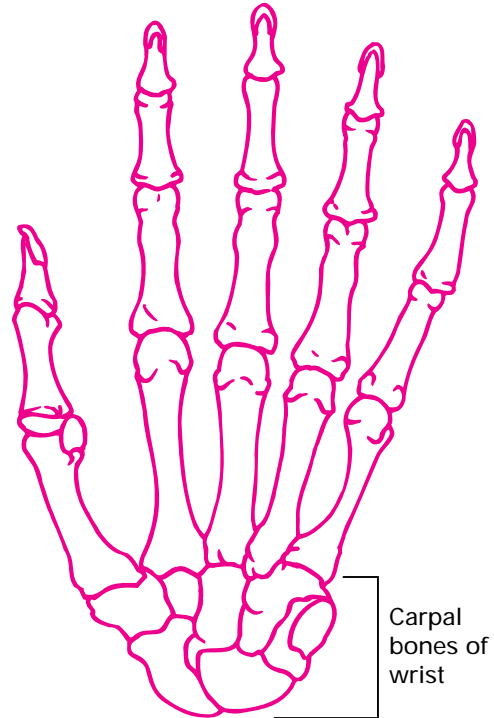
Paralysis The loss of the ability to use motor nerves resulting from damage to the spinal cord.

Paresthesias Altered or abnormal sensations in the skin.

Poliomyelitis (polio) A viral infection that attacks the nervous system causing paralysis and sometimes death.

Sciatica Pain in the sciatic nerve (main nerve of the legs) caused by pressure or inflammation.

Shingles An infection of the peripheral nervous system caused by the chickenpox virus herpes zoster.

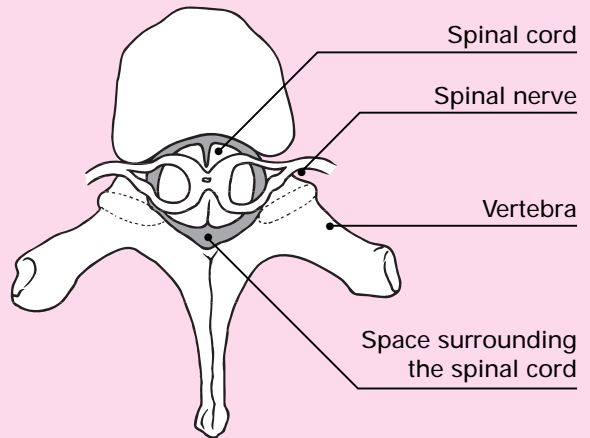


Carpal tunnel syndrome

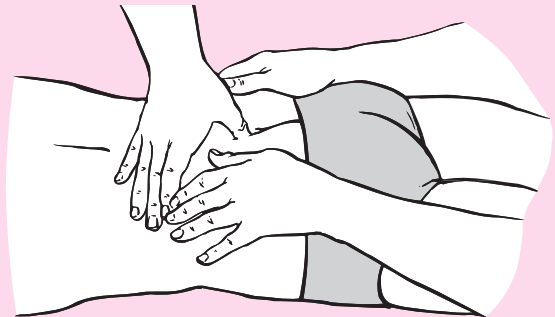
This is a condition characterized by pain and tingling, or numbness, in the thumb and fingers. It can affect either or both hands. The cause is unknown, although it is believed to result from pressure on the median nerve in the wrist. This nerve passes through a tunnel formed by the wrist bones—the carpals. If tissues within the wrist swell due to injury or infection, they press on and pinch the nerve.

Epidural anesthesia

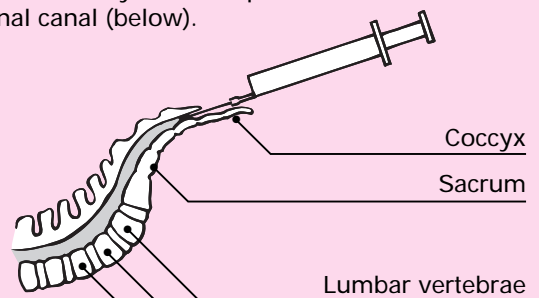
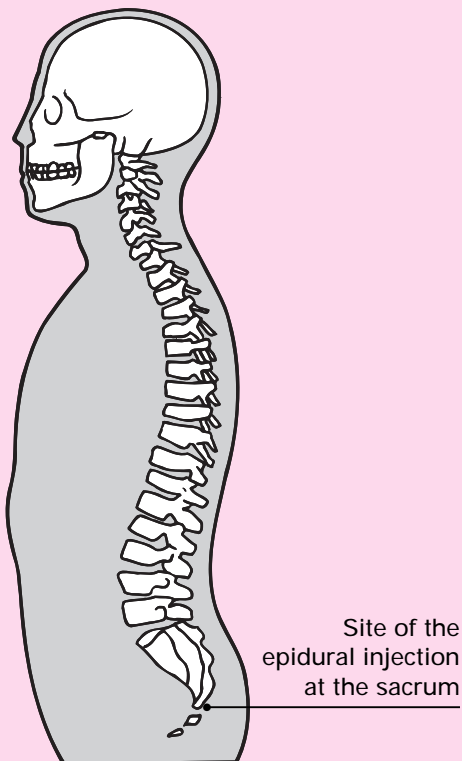
An epidural injection administers drugs into the epidural space between the vertebrae and the dura mater of the spinal cord. The epidural space contains veins, arteries, and fat. Epidural injections are used to treat swelling, inflammation, and pain caused by neurological conditions that affect nerve roots, such as a slipped disk and to manage the pain of childbirth. A local anesthetic is given prior to the main procedure to numb the area. The medication used usually contains an anesthetic or a muscle relaxant, and a corticosteroid. The injection is sometimes called a cortisone shot.



The optimum position may need to be exposed before the injection is actually made (above).



The mixture of anesthetic and corticosteroid is injected slowly into the space around the spinal canal (below).



Involuntary body processes, such as the action of the digestive system or sweating, are controlled by the autonomic nervous system (ANS). Along with the somatic nervous system, the ANS makes up the peripheral nervous system. The peripheral nervous system connects the rest of the body to the central nervous system (the brain and spinal cord). The main role of the autonomic nervous system is one of regulation. For example, it keeps the body at the correct temperature and controls breathing.

Regulation

- The autonomic nervous system keeps the body stable, so its vital processes can continue unaffected.
- The two parts of the autonomic system are involved in preparing the body to respond appropriately to events.

Autonomic nervous system

The autonomic nervous system (ANS) regulates involuntary (not under conscious control) activities. It consists of two parts: the sympathetic and parasympathetic nervous systems. These two systems work in opposition to each other in order to maintain homeostasis (a balance) of conditions within the body.

Sympathetic nervous system

Output from this system steps up internal bodily activity. It stimulates the body to react to emergencies by increasing the heart rate, dilating the pupils, and switching blood supply from the intestines (causing a sinking feeling, nausea, or even incontinence) and skin (causing it to become pale) to the muscles and brain. The work of the sympathetic nervous system is often called the “fight or flight” response because it makes the body defend itself or move away from danger.

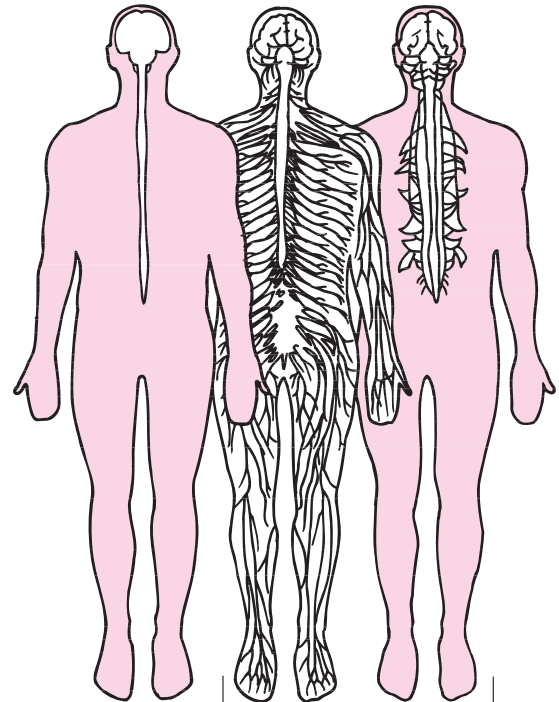
Parasympathetic nervous system

In broad terms, this part of the autonomic nervous system does the opposite to the sympathetic system. It decreases the heart rate, contracts the pupils, and feeds blood away from the brain and muscles to the digestive system and the skin.

Autonomic nervous system

The autonomic nervous system is part of the peripheral nervous system. It controls involuntary body processes.

Central NS Somatic NS Autonomic NS



Peripheral NS

Organization

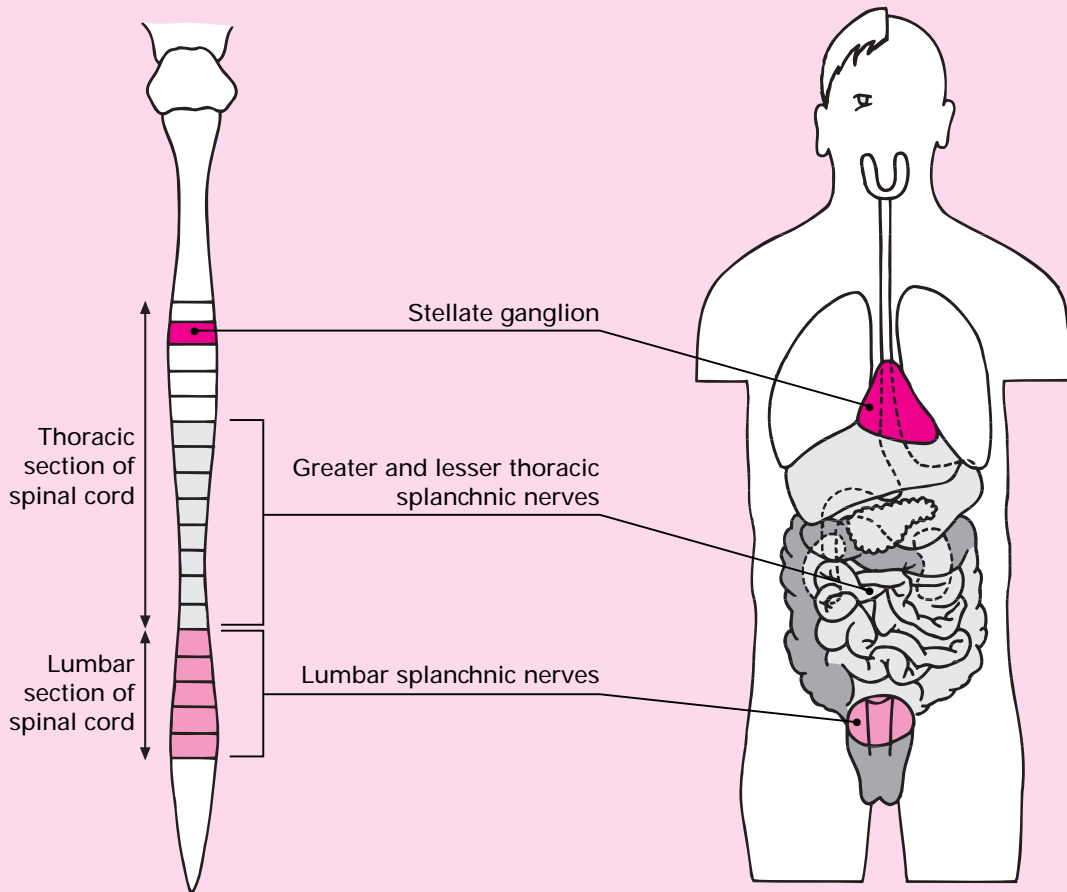
Organ affected	Sympathetic stimulation	Parasympathetic stimulation
Heart	• Accelerates the heartbeat	• Slows the heartbeat
Eye	• Dilates the pupils	• Constricts the pupils
Sweat glands	• Stimulates sweat secretion	• Generalized secretion
Tear glands	• Inhibits secretion	• Stimulates crying
Salivary glands	• Decreases secretion	• Stimulates secretion
Gastric fluids	• Inhibits secretion	• Stimulates secretion
Intestinal fluids	• Inhibits secretion	• Stimulates secretion
Lungs (bronchial tubes)	• Dilates	• Constricts
Blood vessels in skin in skeletal muscle in digestive tract	• Constricts • Dilates • Usually inhibits defecation	• Dilates • Dilates • Increases peristalsis
Liver	• Releases glucose and decreases bile secretion	• Increases bile secretion
Stomach	• Decreases activity	• Increases activity
Intestines	• Decreases activity	• Increases activity
Kidney	• Decreases volume of urine	• None
Pancreas	• Inhibits secretion	• Promotes secretion
Bladder	• Relaxes the bladder	• Contracts the bladder
Hair follicles	• Produces "goose pimples"	• None

Sympathetic system

The autonomic nervous system is connected to the brain, especially the medulla oblongata and hypothalamus, by cranial nerves and spinal cord. The sympathetic autonomic nervous system is linked entirely via the spinal cord. The nerves pass through sympathetic

ganglia, which form a chain, or trunk, on either side of the spinal cord. Nerves connect the ganglia to different parts of the body. For example, the stellate ganglion is linked to the heart and lungs. The splanchnic (visceral) nerves are part of the abdominal aortic plexus.

Origins of nerves and neural ganglia



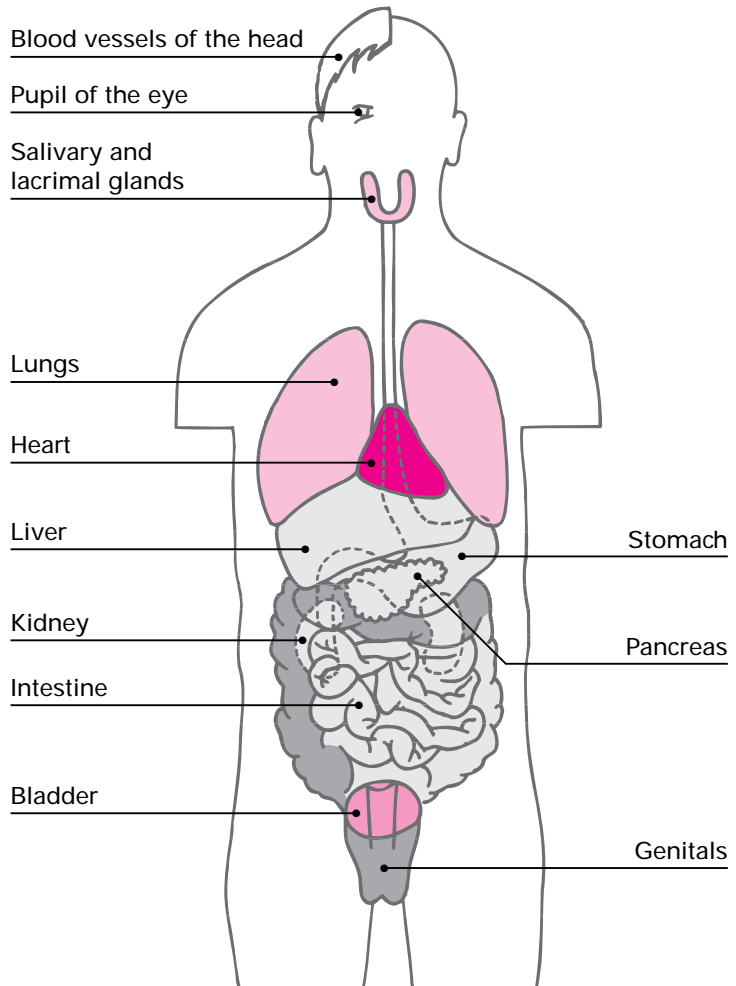
Sympathetic links

The nerves of the sympathetic nervous system link to the main body organs, such as the stomach and other digestive structures, kidneys, and the genitals. Nerves also connect to the small blood vessels and sweat glands in the skin. Nerves that serve one particular area tend to be clustered into a ganglion, such as the celiac ganglion, which connects the main part of the digestive system.

Sympathetic hormone

- The hormone norepinephrine (also called noradrenaline) causes the “fight or flight” response. Among other things, it dilates the trachea and releases sugar into the blood.

Major areas affected by the sympathetic nervous system



Solar plexus

- The solar plexus is a sympathetic ganglion, which is a major link to the adrenal gland.
- Neurons in the adrenal gland produce the hormone norepinephrine.

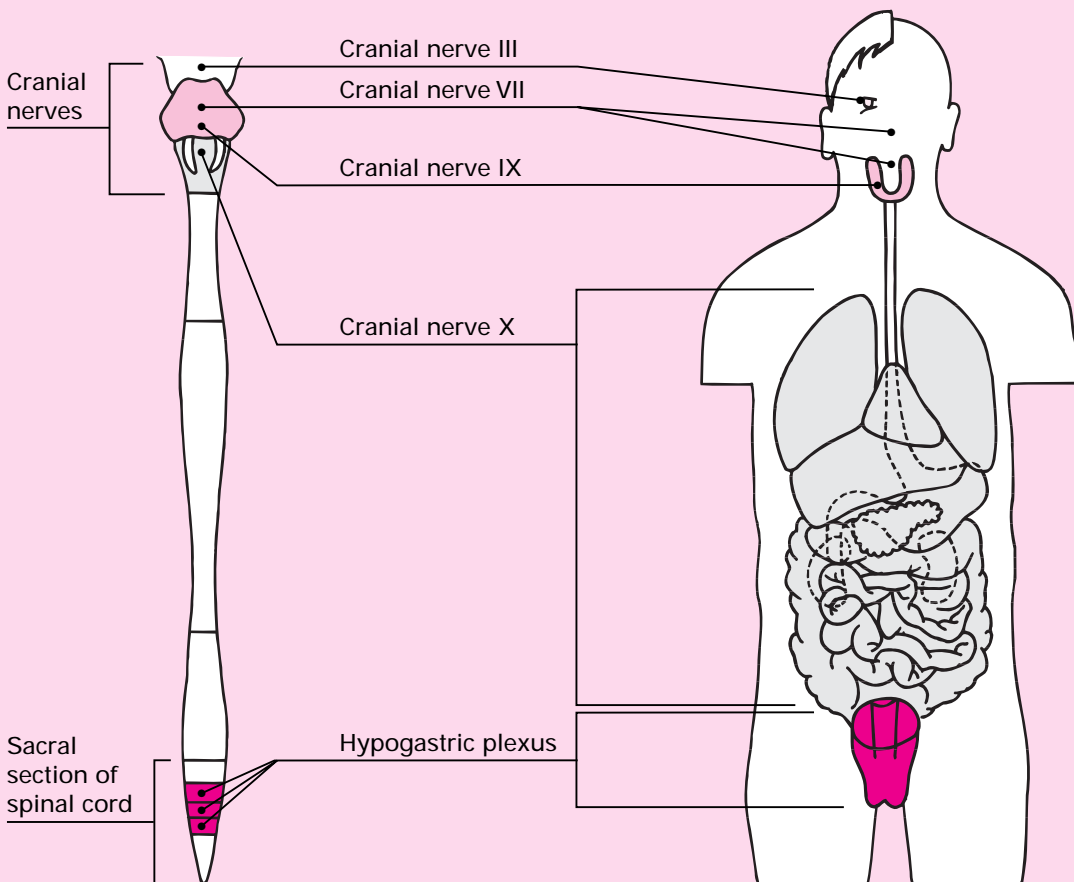
Parasympathetic system

Unlike the sympathetic autonomic nervous system, the parasympathetic system is connected directly to the brain via cranial nerves. The vagus nerves (cranial nerve X), which serve the heart and other vital organs, are among the most important pair of them.

Other parts of the parasympathetic system, such as the nerves that serve the rectum, bladder, and genitals, are connected to the sacral section at the base of the spinal cord, via the hypogastric (meaning "beneath the stomach") plexus.

Cranial nerves

- Pairs of the cranial nerves originate in the medulla oblongata, part of the brainstem.
- Parasympathetic neurons produce the neurotransmitter acetylcholine.



Parasympathetic links

Stimulation by the parasympathetic system causes the heartbeat to slow and blood pressure to lower. The pupils constrict, reducing the amount of light getting into the eye. The blood supply to the skin and visceral organs is increased. The smooth muscles that line the intestines and stomach begin to produce peristaltic waves. These movements, which are inhibited by the sympathetic system, churn the contents of the gut and force it down to the rectum.

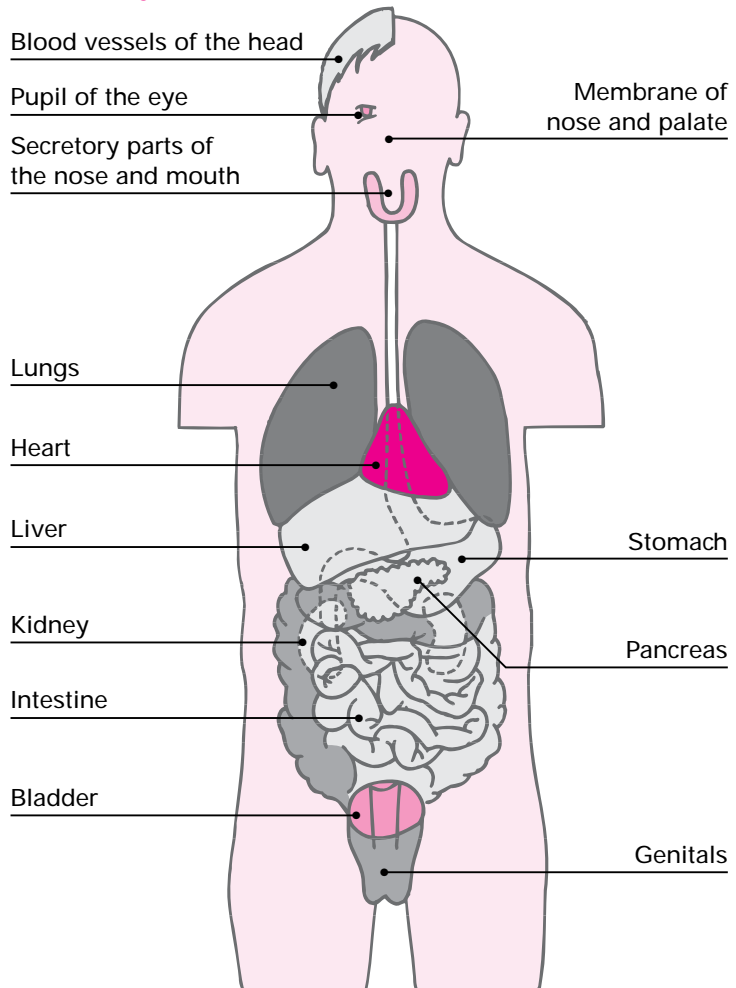
Conscious control

- Although the ANS is often described as being involuntary, a certain amount of control can be applied. Meditation can be used to alter many autonomic functions.

The body at rest

- The parasympathetic nervous system is dominant during sleep, when the heart rate is slower and respiration is deeper and more regular.

Major areas affected by the parasympathetic nervous system



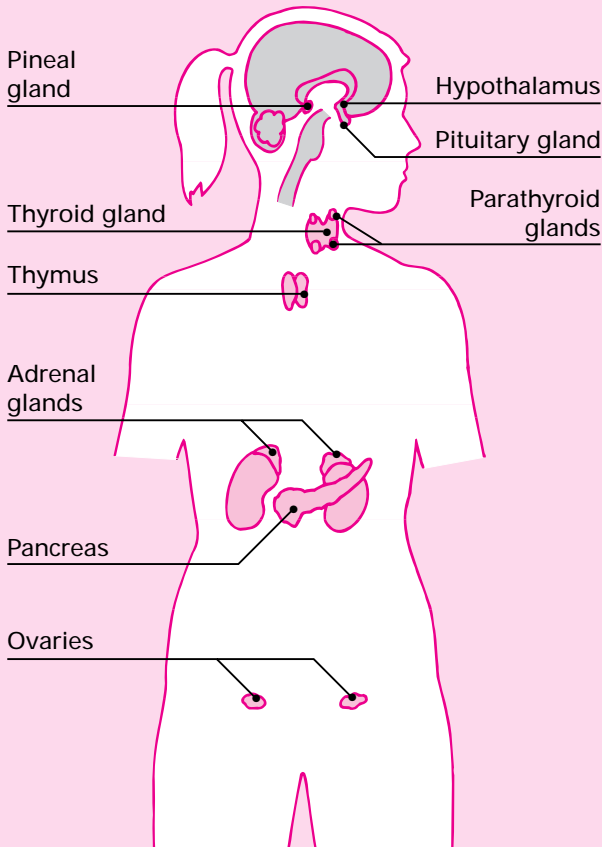
Endocrine glands secrete hormones into the blood circulatory system, which transports them to all parts of the body where they affect tissues to influence bodily growth, development, activity, and repair. Hormone output depends largely on negative feedback processes. Organs included in the endocrine system are the hypothalamus, pituitary gland, pineal gland, thyroid, parathyroid glands, thymus, adrenal glands, pancreas, testes, and ovaries.

Glands

- The pineal gland is also called the epiphysis.
- The pituitary gland is often called the hypophysis.
- The hypothalamus is part of the brain, where it controls the rest of the body's glands with hormones.

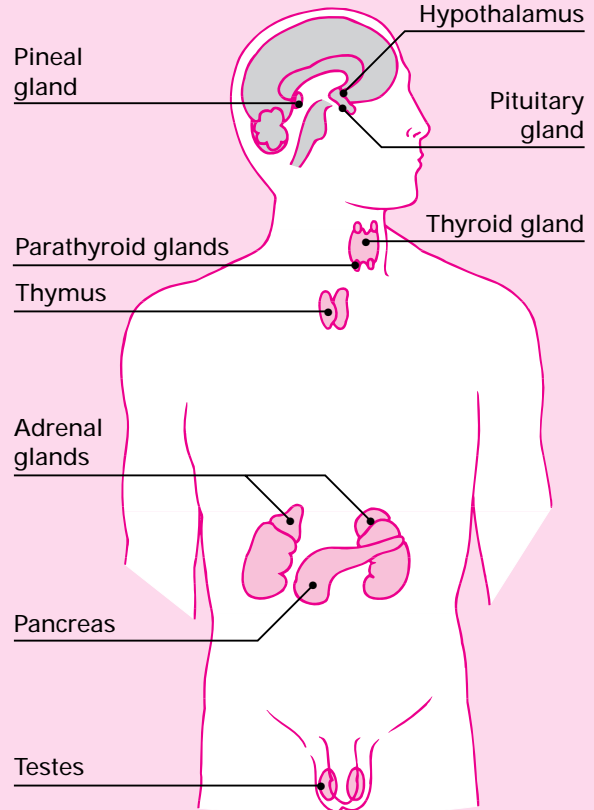
Female endocrine system

The female gonads (ovaries) are positioned in the pelvis.



Male endocrine system

The male gonads (testes) are held in the scrotum, positioned outside the viscera.



ENDOCRINE SYSTEM: KEY WORDS

Adrenal glands Endocrine glands located one on each kidney. The cortex and medulla produce a range of hormones.

Antidiuretic hormone (ADH) A pituitary hormone that decreases urine output and increases blood pressure.

Corticosteroids Hormones produced in the cortex of the adrenal glands.

Endocrine glands Ductless glands releasing hormones into the blood.

Epinephrine A hormone from the adrenal medulla that prepares the body for “fight or flight” under stress.

Estrogens Female sex hormones, mainly from the ovaries.

Follicle-stimulating hormone (FSH) A pituitary hormone that stimulates egg and sperm production in the gonads.

Gland A structure that synthesizes and secretes a fluid.

Glucagon A pancreatic hormone that breaks down glycogen to glucose.

Glucocorticoids Corticosteroids that help control long-term stressors.

Gonadocorticoids Sex hormones produced in the adrenal cortex.

Gonads Male and female reproductive organs with endocrine functions.

Growth hormone A pituitary hormone.

Hormones Chemical substances released into the blood by glands to influence other parts of the body.

Hypothalamus A part of the brain with endocrine functions.

Insulin A pancreatic hormone that lowers glucose levels in the blood.

Islets of Langerhans Regions of the pancreas that produce glucagon and insulin.

Luteinizing hormone (LH) A pituitary hormone that triggers sex hormone output.

Mineralocorticoids Adrenal hormones that regulate blood salt levels.

Norepinephrine A hormone from the adrenal medulla and also a neurotransmitter.

Ovaries Female sex organs that produce ova (eggs) and sex hormones.

Oxytocin A pituitary hormone that stimulates contractions during labor and triggers the milk ejection reflex.

Pancreas An abdominal organ that produces pancreatic juice and hormones.

Parathyroid glands Four glands on the thyroid gland.

Pineal gland An endocrine gland in the brain that secretes melatonin.

Pituitary gland A three-lobed, pea-sized gland below the hypothalamus. It produces growth hormone, hormones that act on other endocrine glands, oxytocin, and ADH. It is often called the body’s “master gland.”

Progesterone Female sex hormone that helps prepare the uterus to receive eggs.

Prolactin A pituitary hormone that stimulates milk production.

Steroids Hormones made from sterol fats.

Testes Male sex organs that produce sperm and sex hormones.

Testosterone Male sex hormone mainly produced in the testes.

Thymus An endocrine gland located behind the sternum. It produces thymosin.

Thyroid An endocrine gland at the front of the neck, producing thyroid hormone.

Thyroid hormone Made up of triiodothyronine (T_3) and thyroxine (T_4), thyroid hormone.

A hormone is a chemical produced in one part of the body that has an effect on several other parts. In this way, hormones are chemical messengers. The name *hormone* is derived from the Greek for “to set in motion.” Most hormones are produced by endocrine glands but a few come from tissues, such as the stomach, whose primary role is not as a gland.

Hormones, for example thyroxine, regulate metabolism, the processes that convert food into energy and living structures. Hormones are also involved in growth and development. For example, the sex hormones play a vital role in controlling how a body matures. Other hormones control blood composition or prepare the body for periods of stress.

Endocrine system

Gland	Hormones secreted	Chief actions of hormones
Pituitary gland	By the anterior pituitary: Growth hormone	Promotes growth of skeletal muscles and long bones.
	Prolactin	Stimulates milk production.
	Thyroid-stimulating hormone	Stimulates thyroid gland.
	Adrenocorticotrophic hormone	Stimulates adrenal cortex.
	Follicle-stimulating hormone	Stimulates ovarian follicles.
	Luteinizing hormone	Triggers progesterone production and ovulation (females); stimulates testosterone production in males.
	By the posterior pituitary: Oxytocin	Stimulates uterine contractions in labor and produces “let-down” reflex to cause milk ejection.
	Antidiuretic hormone (ADH)	Causes decrease in urine output and increase in blood pressure.
Pineal gland	Melatonin	May play a role in body’s diurnal cycle and regulate onset of sexual maturation (especially in females).
Thyroid gland	Thyroid hormone, which is made up of triiodothyronine (T_3) and thyroxine (T_4)	Controls rate of metabolism needed for normal tissue growth and development (especially of nervous and reproductive systems).

Gland	Hormones secreted	Chief actions of hormones
Parathyroid gland	Parathyroid hormone	Regulates calcium levels in blood
Thymus	Thymosin	Controls maturation of T-lymphocytes (white blood cells).
Pancreas	Insulin Glucagon	Increases uptake of glucose from blood into cells. Increases breakdown of glycogen stored in liver.
Adrenal (suprarenal) glands	By the adrenal medulla: Epinephrine (adrenaline) and norepinephrine (nonadrenaline) By the adrenal cortex: Mineralocorticoids Glucocorticoids Gonadocorticoids (mostly male sex hormones produced by both sexes)	Prepares for short-term stress, the autonomic “fight or flight” response. Regulates blood salts. Helps control long-term stressors. Thought to contribute to onset of puberty; female sex drive.
Testes	Testosterone	Stimulates development of male reproductive system and secondary sexual characteristics and promotes sperm production.
Ovaries	Estrogens Progesterone	Maturation of female reproductive system and development of secondary sexual characteristics in females; acts with progesterone to produce menstrual cycle. Acts on uterus in pregnancy and acts with estrogens to produce menstrual cycle.

What are hormones?

Hormones are produced in minute amounts by the endocrine glands and by some cells in nonendocrine organs. They are chemical messengers—substances that coordinate the activity of cells and organs by activating enzymes.

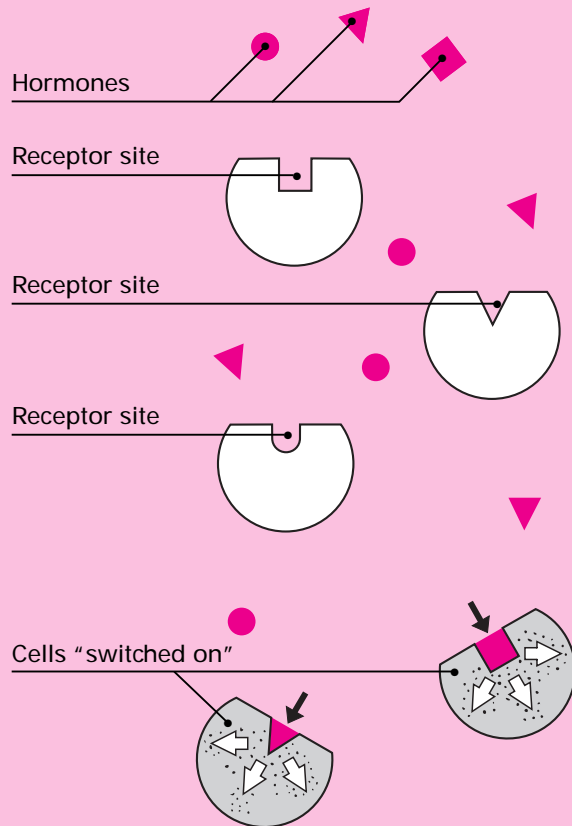
- Released into the blood, hormones circulate around the body but affect only those cells and organs (called target cells and organs) that are receptive to them.
- These target cells and organs have receptor sites that “match” a particular hormone. When a site is matched with an appropriate hormone, the receptor is activated and the cell is “switched on.”

Types of hormones

There are two main types of hormones that circulate through the body.

- Polypeptides, which make up most of the body's hormones, are derived from amino acids.
- Steroids, produced by the testes, ovaries, and adrenal cortex, are derived from cholesterol.
- Another type is the prostaglandin. Sometimes called tissue hormones, these are not classed as hormones but have hormone-like effects. They do not circulate throughout the body but affect only cells within the tissue producing the prostaglandins.

Hormones at work



Negative feedback

The level of hormones in the blood is controlled by the negative feedback mechanism. This maintains equilibrium: if the level of a hormone in the blood falls, more is secreted; if the level of a hormone rises, less is secreted. Some diseases and disorders, such as tumors, can result in hypersecretion (the secretion of too much hormone) or hyposecretion (secretion of too little hormone).

How hormones are triggered

Hormone secretion is triggered by hormonal, humoral, and neural stimuli.

Hormonal stimulus

Endocrine organs are stimulated to release hormones by other hormones. For example, the hypothalamus produces hormones that stimulate the anterior (front) lobe of the pituitary gland. This in turn secretes its own hormones that stimulate other endocrine glands, including the thyroid gland, the adrenal cortex, and, in men, the testes. When hormones secreted by these endocrine glands reach a certain level in the blood, negative feedback inhibits the further release of anterior pituitary hormones.

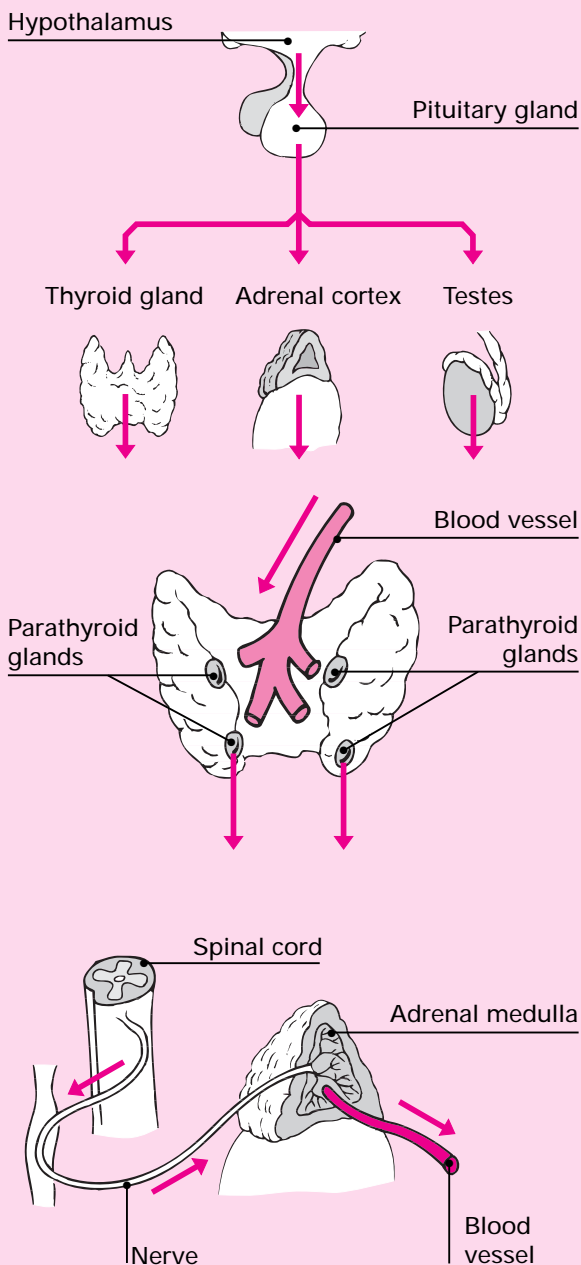
Humoral stimuli

The presence in the blood of substances other than hormones can stimulate the release of hormones. For example, when the level of calcium (naturally present in the blood) begins to fall, this stimulates the parathyroid glands to release parathyroid hormone. Parathyroid hormone acts in such a way as to increase the calcium level, which then ends the stimulus to produce parathyroid hormone.

Neural stimuli

Sometimes the nervous system stimulates the release of hormones. For example, during periods of stress, nerves stimulate the adrenal medulla to secrete the hormones norepinephrine and epinephrine.

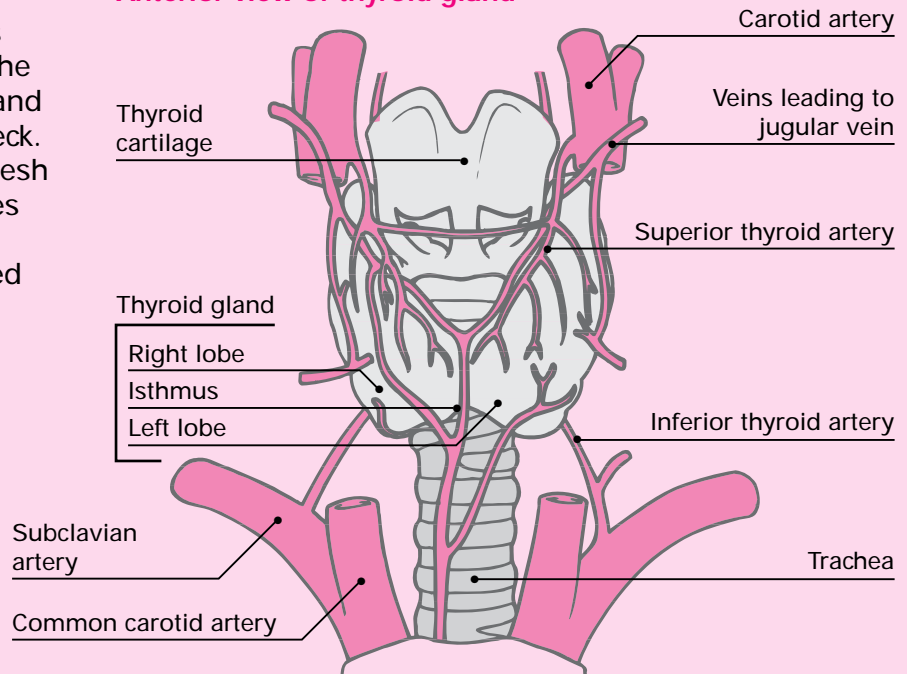
The stimuli that trigger hormones



The thyroid

The thyroid gland is positioned around the trachea (windpipe) and esophagus in the neck. It is supplied with fresh blood by two arteries and its secreted hormones are carried away by veins connected to the jugular vein.

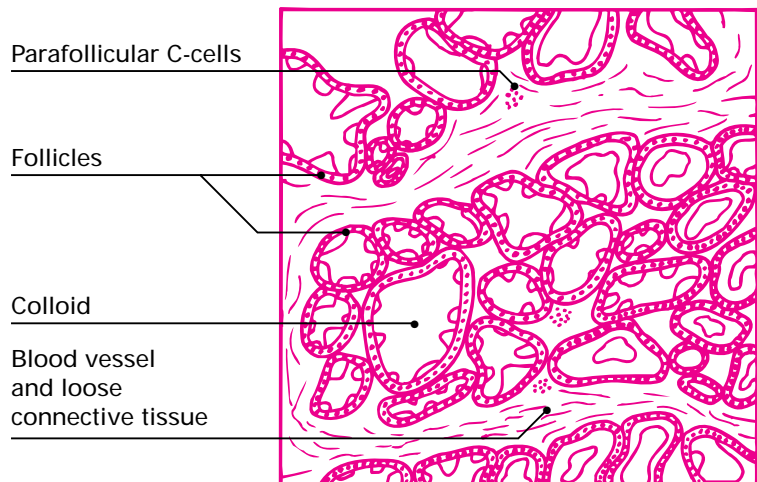
Anterior view of thyroid gland



Section of thyroid

Thyroxine is produced by follicles. These are rings of cells (cuboidal epithelium) that secrete the hormone forming a central colloid space. Calcitonin is secreted by clusters of parafollicular C-cells which are positioned among the follicles. Small blood vessels running through the gland collect the hormones and take them to the rest of the body.

Microscopic section through thyroid gland



Thyroid and parathyroid

Glands and hormones

Thyroid

Thyroxine,
triiodothyronine

Calcitonin



Target tissues

Most body cells

Bone

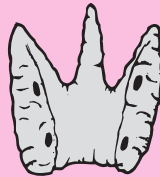Effects

- Controls the rate at which the body uses stored energy.

- Inhibits the breakdown of bone and decreases the amount of calcium in the blood.

Parathyroids

Parathyroid hormone (PTH) or parathormone



Bones, kidneys,
digestive tract

- Increases the amount of calcium in the blood.
- Decreases the amount of phosphate in the blood.
- Stimulates the breakdown of bone.

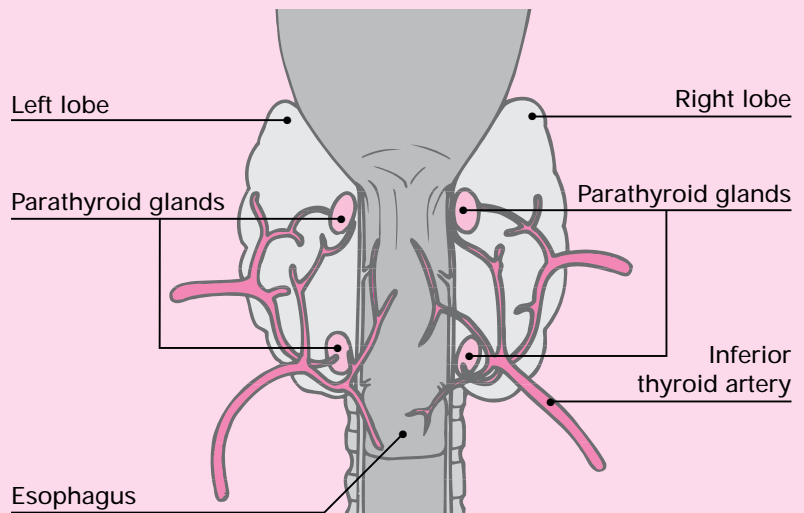
Parathyroid glands

The four parathyroid glands are located on the back of the thyroid gland. The glands work together to produce parathyroid hormone (PTH).

Parathyroid hormone

- Parathyroid hormone regulates the amount of calcium and phosphate in the blood.
- These substances are used in bones and help muscles and nerves work.

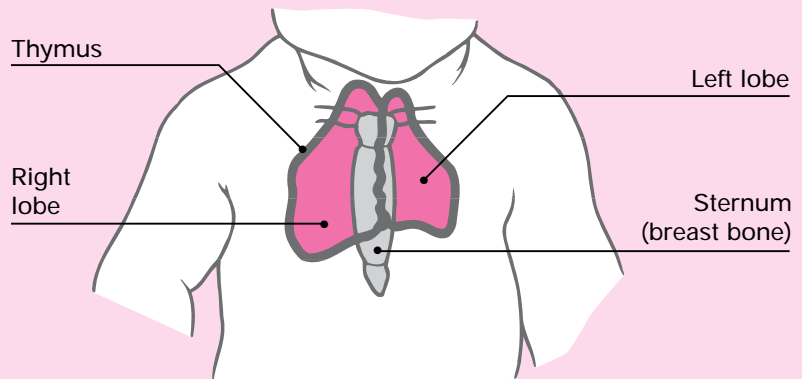
Posterior view of thyroid and parathyroid gland



The thymus in a child

The thymus is an organ in the chest used to develop a person's immune system. The thymus fills a large part of a newborn's chest and produces lymphocytes (white blood cells). The organ produces thymosin, a hormone associated with lymphocyte production. The thymus grows for about 12 years and then begins to shrink.

Anterior view of thymus in newborn child

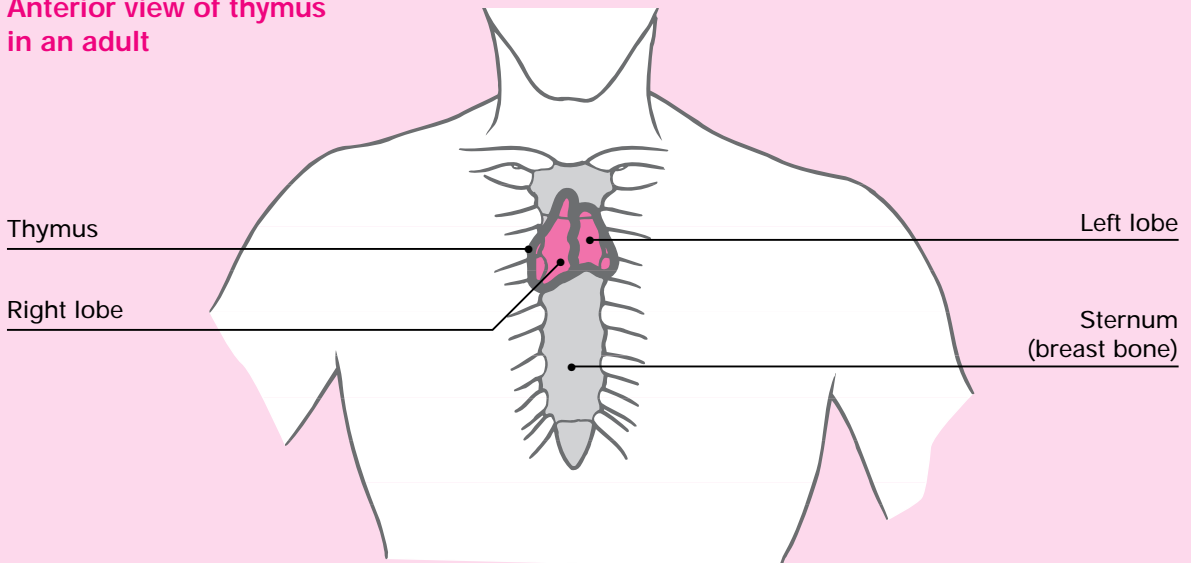


The thymus in an adult

After the age of 12, the thymus begins to shrink as the lymph nodes and spleen take over its role in the immune system.

The thymus of older adults may be hard to locate among the fatty tissue around the breast bone.

Anterior view of thymus in an adult

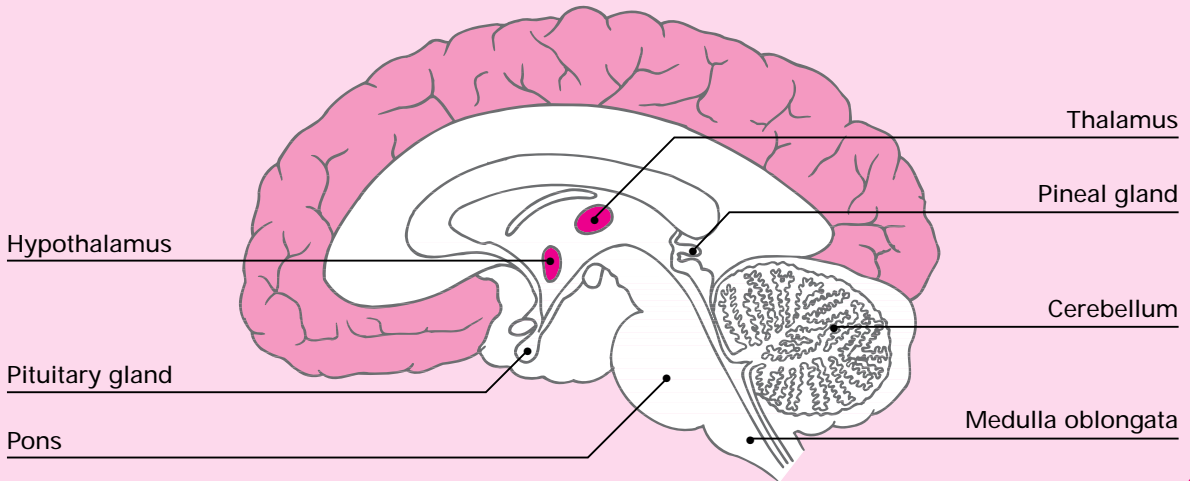


The brain

The brain produces hormones itself, and is associated with two glands, the pineal and pituitary. The hypothalamus produces hormones that control these

glands. The pituitary's hormones are involved in fertility and growth. The pineal gland produces melatonin, which regulates the body's rhythms.

Cross section through the brain



Thymus and pineal gland

Glands and hormones

Thymus

Thymosin



Target tissues

Immune system tissues

Effects

- Associated with the production of T-lymphocytes

Pineal gland

Melatonin



Hypothalamus

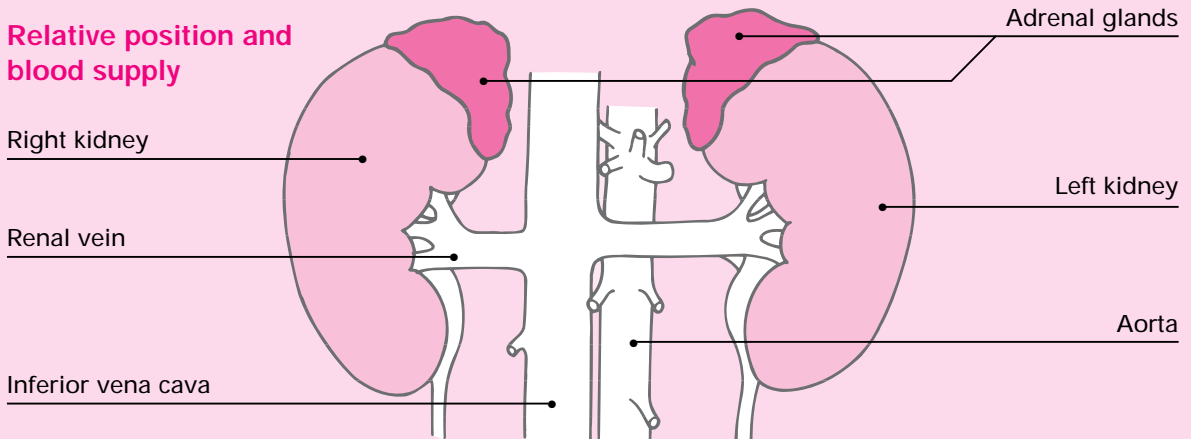
- May inhibit a hormone affecting the ovaries
- May regulate activities such as sleep

Adrenal glands

The body has two adrenal glands. Each one is pyramid-shaped and located on the top of a kidney. The glands are also called suprarenal (above the kidney) glands. The adrenal glands produce

epinephrine and norepinephrine, the hormones associated with the autonomic nervous system. Other parts of the glands produce sex hormones and other regulatory hormones.

Relative position and blood supply

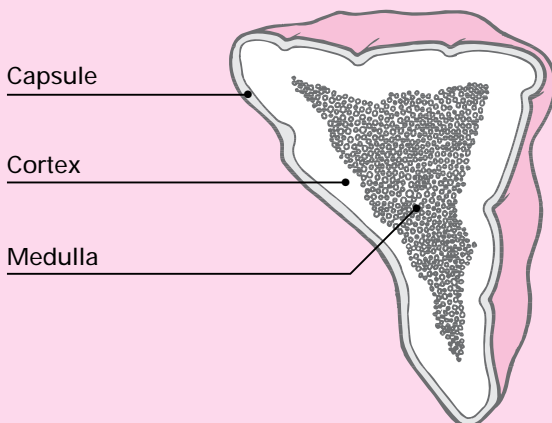


Internal structure

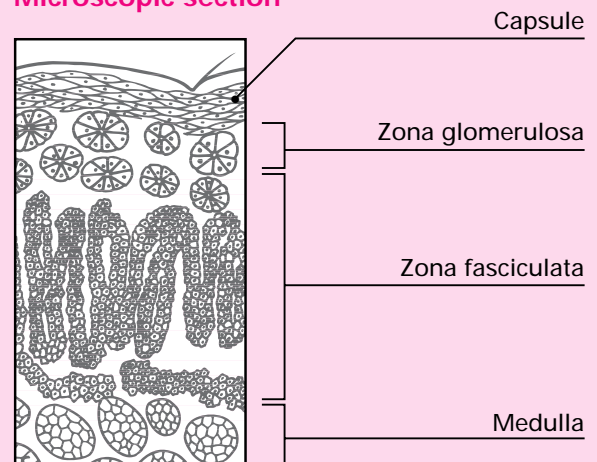
There are two sections in an adrenal gland: the outer cortex and inner medulla. The medulla is controlled by nerves and makes stress hormones.

The cortex is more complex, being made of several layers. Each layer produces hormones that regulate blood chemistry and sexual development.

Transverse section



Microscopic section



Two glands in one

The adrenal glands could be thought of as two separate glands due to the distinct division between the cortex and medulla.

The medulla is innervated by many neurons from the sympathetic nervous system. With its role in preparing the body for stress, the adrenal medulla can be viewed as an extension of the autonomic nervous system. The adrenal cortexes, however, make a range of steroidal hormones. These play a vital role

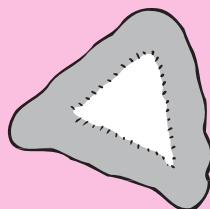
in regulating the body. There are two types of adrenal steroids. The mineralocorticoids, such as aldosterone, control the amount of water, sodium, and potassium in the body. Glucocorticoids, such as cortisol, are involved in the metabolism of glucose and other substances. The adrenal cortex also produces sex hormones, mainly male ones in both sexes. However, the sex hormones from the gonads drown out the effects of the adrenal ones.

Adrenal glands

Glands and hormones

Adrenal cortex

Mineralocorticoids
(aldosterone)



Glucocorticoids
(cortisol)

Androgens and
estrogens

Target tissues

Kidney

Most body
tissues

Most body
tissues

Effects

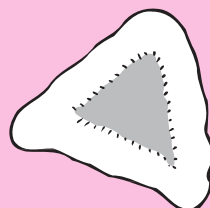
- Regulate the level of minerals (sodium and potassium) in the blood.
- Increase water retention.

- Increase the level of glucose (sugar) in the blood.
- Inhibit inflammation.
- Inhibit the immune response.

- Effect is usually masked by hormones from the ovaries and testes.

Adrenal medulla

Epinephrine
(adrenaline)
norepinephrine
(noradrenaline)



Heart, blood
vessels, liver,
adipose tissue,
and several
others

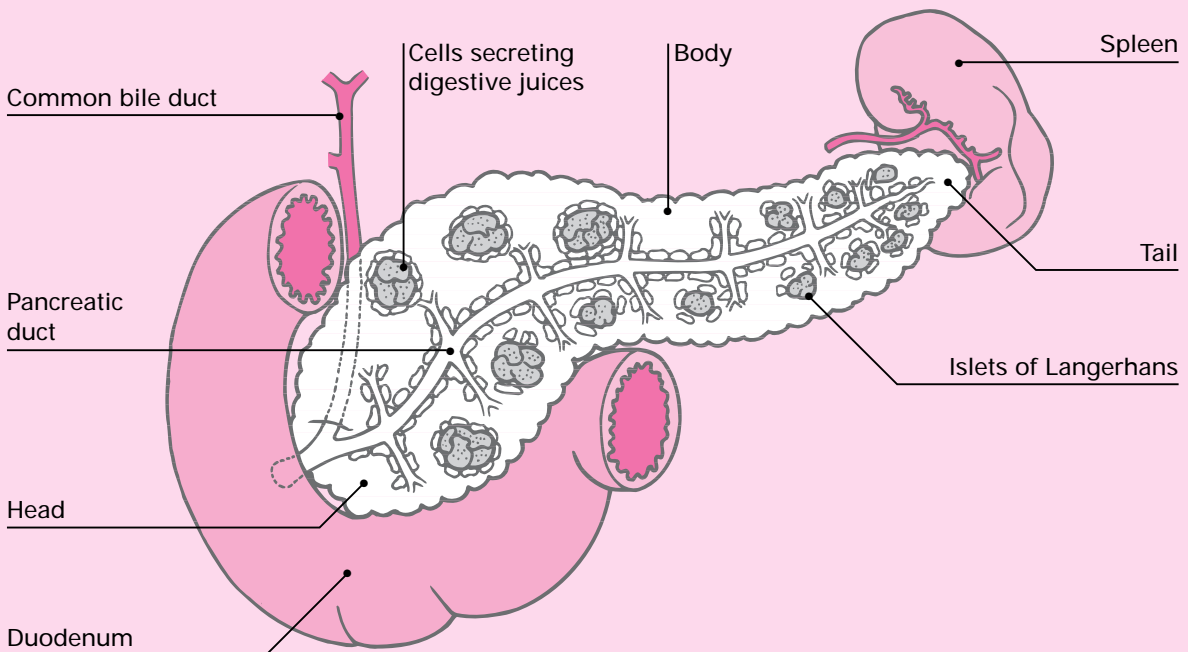
- Increase heart rate and blood pressure.
- Increase blood flow to skeletal muscles (epinephrine only).
- Increase the level of glucose in the blood.

The pancreas

This is an organ positioned under the stomach. The pancreas has an endocrine role, but it is also an exocrine gland (one with a duct). In its endocrine function, the pancreas produces insulin and glucagon, two hormones that control the amount of sugar in the blood. These

hormones are produced by structures called the Islets of Langerhans. The pancreas also secretes digestive juices into the duodenum (small intestine). These juices, which are mixed with bile, are a mixture of enzymes used to digest food.

Anterior view and schematized section



Islets of Langerhans

- These contain two types of cell. Each type produces one of the pancreatic hormones, insulin or glucagon.
- Damaged islets can cause diabetes.

Digestive organ

- The pancreas is a thin organ located inside a loop in the duodenum.
- Digestive juices contain salts that neutralize stomach acids.


Pancreas

Glands and hormones

Pancreas

Glucagon

Insulin



Target tissues

Liver

Liver, skeletal muscles, adipose

Effects

- Increases the level of glucose in the blood
- Decreases the level of glucose in the blood
- Promotes the storage of glucose
- Decreases the level of potassium in the blood

Microscopic section

The islets of Langerhans are areas of secretory cells found throughout the pancreas. The islets are surrounded by cells that secrete digestive juices. Inside the islets, B-cells secrete insulin.


Glucagon is secreted by A-cells. The digestive juices drain into a central duct that connects to the duodenum. The hormones, however, are collected by capillaries running through the islets.

Microscopic section through the pancreas

Cells secreting digestive juices

B-cells secreting insulin

A-cells secreting glucagon



Capillaries

Negative feedback: effects of glucagon and insulin

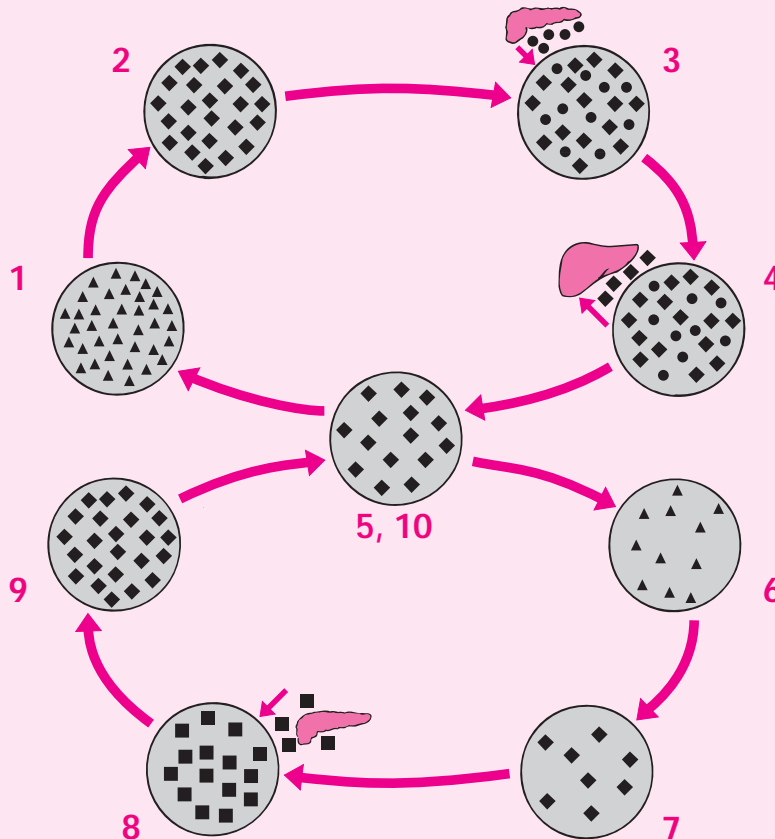
The activity of glucagon and insulin provides an example of how negative feedback maintains an equilibrium (balance) of hormones in the body.

When blood sugar levels are high

- 1 After eating, the blood has a high level of carbohydrates.
- 2 Carbohydrates are converted into glucose, increasing blood sugar levels.
- 3 The high glucose level stimulates beta cells in the pancreas to secrete insulin.
- 4 Insulin increases the uptake of glucose by the liver, adipose tissue, and muscle.
- 5 The blood sugar level falls until a normal blood sugar level is reached.

When blood sugar levels are low

- 6 As a result of skipping a meal, the blood has a low level of carbohydrates.
- 7 The blood sugar level falls.
- 8 The low glucose level stimulates the alpha cells in the pancreas to secrete glucagon.
- 9 Glucagon results in the manufacture and release of glucose into the blood.
- 10 The blood sugar level rises until a normal blood sugar level is reached.



Hormones produced by non-endocrine glands

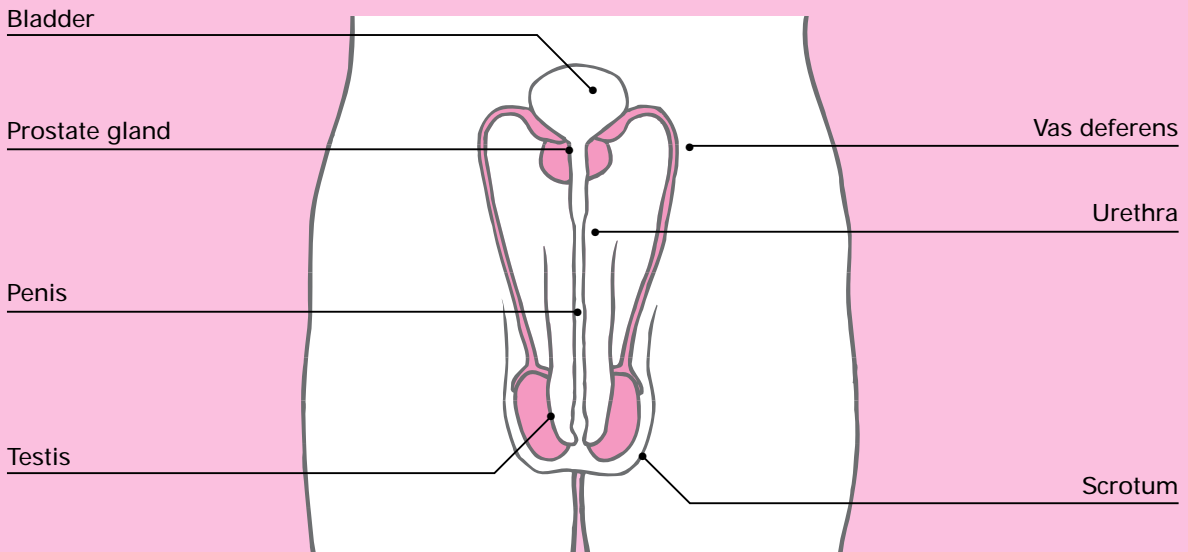
Organ	Hormone	Target tissue	Effect
Stomach	Gastrin	Stomach	<ul style="list-style-type: none"> Stimulates glands to produce hydrochloric acid.
Duodenum of small intestine	Intestinal gastrin	Stomach	<ul style="list-style-type: none"> Stimulates the secretion of acid and peptin by the stomach.
		Pancreas	<ul style="list-style-type: none"> Stimulates the release of pancreatic juices.
		Liver	<ul style="list-style-type: none"> Increases the release of bile.
	Cholecystokinin	Stomach	<ul style="list-style-type: none"> Inhibits secretory activity.
		Pancreas	<ul style="list-style-type: none"> Stimulates the release of juices.
		Gallbladder	<ul style="list-style-type: none"> Stimulates the release of bile.
Kidney	Erythropoietin	Bone marrow	<ul style="list-style-type: none"> Stimulates the production of red blood cells.
	Active vitamin D ₃	Intestine	<ul style="list-style-type: none"> Stimulates the transport of calcium.
Heart	Atrial natriuretic factor	Kidney	<ul style="list-style-type: none"> Inhibits the reabsorption of sodium and release of renin.
		Adrenal cortex	<ul style="list-style-type: none"> Inhibits the secretion of aldosterone.

Male sex glands

The sex glands (sometimes called gonads) are the ovaries in women and the testes in men. The two testes are

outside the body inside the scrotum. Their main function is to produce sperm, which is released through the penis.

The male reproductive tract



Location and structure

The testes are the primary male reproductive organs, located within the testicles.

Functions

The testes are responsible for producing semen and sperm, but they also have specialized cells with an endocrine function. These secrete male sex hormones called androgens, the principal androgen being testosterone. Testosterone is responsible for:

- the growth and development of male reproductive organs and maintenance of their adult size;

- the growth and distribution of body hair;
- the enlargement of the larynx (and voice changes);
- increased skeletal and muscular growth;
- the male sexual drive.

How testosterone is triggered

Testosterone is secreted in response to hormones released by the hypothalamus and anterior lobe of the pituitary gland. The level of testosterone is regulated by a negative feedback process.

Female sex glands

The ovaries are the primary female reproductive organs, located in the lower abdomen on either side of the uterus. They produce the ova (eggs) for reproduction, but each also produces structures—the ovarian follicles and the corpus luteum—which have an endocrine function associated with reproduction.

Functions

The ovarian follicles secrete the hormone estrogen, which at the beginning of puberty promotes:

- maturation of the female reproductive organs, such as the uterus and vagina;
- development of breasts;
- growth and distribution of body hair;

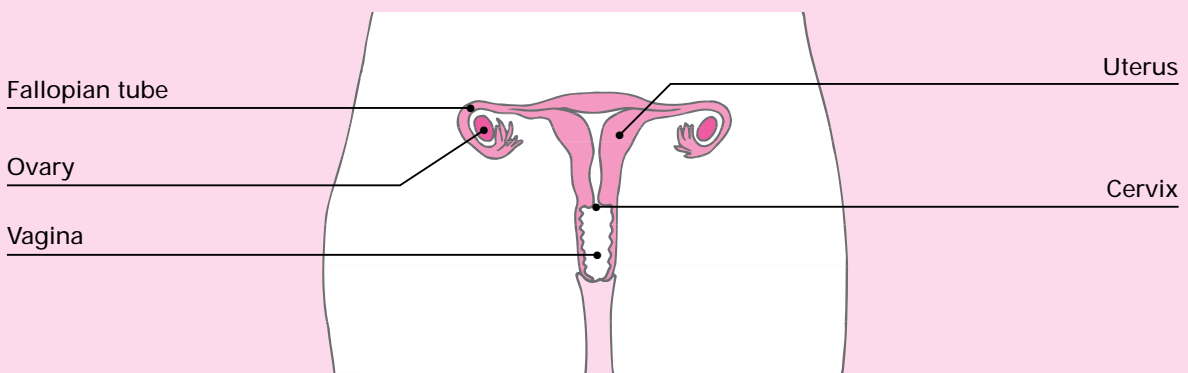
- distribution of fat in the hips, legs, and breasts.

The corpus luteum secretes some estrogen but mostly progesterone which causes the lining of the uterus to thicken in preparation for pregnancy. Both estrogen and progesterone are responsible for changes that occur during the menstrual cycle.

How estrogen and progesterone are triggered

Like testosterone, estrogen and progesterone are secreted in response to hormones released by the hypothalamus and pituitary gland. The levels of estrogen and progesterone are regulated by negative feedback.

The female reproductive tract



Pituitary control over ovulatory cycle

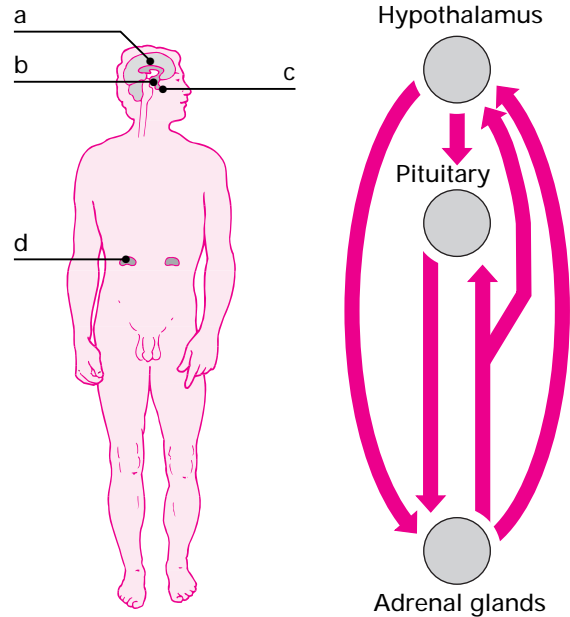
The ovaries are controlled by the anterior pituitary gland. Under the influence of estrogen produced by an ovarian follicle, the pituitary produces follicle-stimulating hormone (FSH) and luteinizing hormone (LH). These hormones cause the follicle

to ripen and release an ovum during ovulation. The remains of the follicle forms a corpus luteum, which produces progesterone. If the ovum is not fertilized the progesterone level drops and menstruation begins.

The chemistry of stress

The organs primarily involved in the body's reaction to stress are:

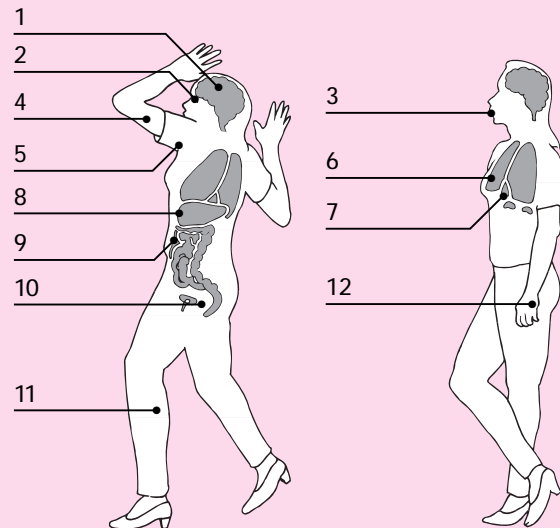
- The brain (**a**) which perceives a threat.
- The hypothalamus (**b**) which secretes a releasing hormone telling the pituitary gland (**c**) to secrete adrenocorticotrophin (ACTH) into the blood.
- ACTH reaches the adrenal glands (**d**). The adrenal cortex produces corticoids, hormones that help the body cope with stress. The medulla, or center, of the gland releases epinephrine (also called adrenaline), which increases the heart rate and intensifies other activities taking place in the body. Hormone levels in the blood are monitored by the hypothalamus and the pituitary gland.



How stress affects the body

In stressful situations the hormones epinephrine and norepinephrine act on many parts of the body with dramatic results. Among the changes that take place are the following.

- 1 Hair may stand on end.
- 2 The pupils of the eyes dilate.
- 3 The output of saliva falls.
- 4 The skin turns pale as blood vessels supplying it contract.
- 5 The body sweats, ready to cool itself if there is great activity.
- 6 The chest expands and breathing becomes faster and deeper in order to deliver more oxygen to muscles.
- 7 The heart beats faster and harder, and blood pressure rises.
- 8 Glucose is released from the liver to provide food for muscles.
- 9 The blood supply to the digestive



system is diverted and digestion slows.

10 The bladder and rectum may empty.

11 Muscles tense, ready for action.

12 If the skin is broken, blood coagulates more quickly.

Disorders of the endocrine system

Addison's disease Caused by undersecretion of adrenal steroid hormones. Results in weakness, nausea, low circulation, and bronzing of the skin.

Adenoma A tumor of an endocrine gland.

Adrenogenital syndrome Oversecretion of adrenal sex hormones, resulting in intense masculinizing of the body.

Aldosteronism Overproduction of the adrenal hormone aldosterone, resulting in a decrease in the body's potassium store.

Cretinism Dwarfism and mental retardation caused by too little thyroxine in childhood.

Cushing's syndrome Caused by oversecretion of glucocorticoid hormones from the adrenal glands. Results in a redistribution of body fat and other effects.

Diabetes insipidus Effect of underproduction of the hormone ADH.

Diabetes mellitus Condition characterized by frequent thirst and urination and due to excess amounts of sugar in the blood. Results from a lack of insulin, which controls blood sugar.

Gigantism Oversecretion of growth hormone in childhood, resulting in taller-than-average stature. If the oversecretion occurs in adulthood, the condition is acromegaly, resulting in a thickening of facial bones and fingers.

Glucagon deficiency A blood-sugar disorder caused by a lack of glucagon produced by the pancreas.

Goiter An abnormal growth of thyroid tissue due to lack of iodine.

Gynecomastia Excessive growth of the male mammary gland (breast) caused by oversecretion of feminizing hormones.

Hypersecretion Overproduction (of a

hormone). Underproduction is called hyposecretion.

Hyperthyroidism Oversecretion of the thyroxine by the thyroid, resulting in increased metabolic and heart rates, circulation, and blood pressure.

Hypoglycemia Low blood sugar, which can cause anxiety, tremors, weakness, and even unconsciousness and death.

Hypothyroidism Undersecretion of thyroxine, resulting in a very low metabolic rate and sluggish activity, sometimes accompanied by obesity.

Myxedema Accumulation of water in skin resulting from thyroid hormone deficiency in adults.

Pituitary dwarfism Undersecretion of growth hormone from the pituitary gland in childhood, resulting in smaller-than-average stature.

Seasonal affective disorder (SAD) Condition resulting from changes in the body's level of the hormone melatonin. The level varies seasonally: It is higher in winter and lower in summer, when increased daylight inhibits its production. Symptoms include tiredness and depression.

Simmond's disease Undersecretion of pituitary hormones during adulthood, resulting in symptoms of deficiency of thyroid, adrenal, and sex hormones.

Tetany Muscle twitches, spasms, and convulsions resulting from a lack of calcium in the blood. It may be caused by a dysfunction in the parathyroid glands (hypoparathyroidism), or by an infection.

Thyrotoxicosis Overactivity of the thyroid gland, often due to an autoimmune disease of the thyroid.

Adipose tissue Connective tissue containing numerous fat cells.

Adrenal glands (*or* Suprarenal glands) Endocrine glands located on each kidney. The cortex and medulla produce a range of hormones.

Afferent Directed toward a central organ or part of the body.

Alimentary canal (*or* Gastrointestinal tract *or* Gut) The digestive tract: a tube starting at the mouth and ending at the anus.

Anus The lower end of the rectum, forming the outlet of the alimentary canal.

Aorta The largest artery, arising from the left ventricle of the heart.

Appendix (*or* Vermiform appendix) A short, wormlike tube opening into the cecum but closed at the other end. It contains lymphoid tissue, which is involved in immunity.

Arteriole A small artery supplying blood from a main artery to a capillary.

Artery A blood vessel transporting blood from the heart to elsewhere in the body.

Atrioventricular valve (*or* AV valve) A valve between a ventricle and an atrium. The right atrioventricular valve (*or* tricuspid valve) has three cusps. The left atrioventricular

valve (mitral valve or bicuspid valve) has two cusps.

Auditory Relating to hearing.

Axillary Relating to the armpit.

Backbone See **Vertebral column**.

Basal ganglia Paired structures deep in the forebrain: they help coordinate and control willed muscle movements.

Basophil A type of white blood cell that is readily stained by basic dyes.

Biceps A muscle with two heads: biceps brachii in the upper arm and biceps femoris in the thigh.

Bile ducts Tiny tubes that carry bile (a liver secretion) from the liver to the duodenum.

Bladder A sac, especially the muscular bag inside the pelvis where urine collects before being expelled from the body.

Blood A sticky red fluid consisting of colorless plasma, red blood cells (Erythrocytes), white blood cells (Leukocytes), and platelets (thrombocytes).

Blood pressure The pressure of blood against blood-vessel walls, especially artery walls.

Bone The hard, dense connective tissue that forms the skeleton's components.

Bone marrow Soft red and yellow substances that fill cavities in bone.

Bowel See **Large intestine**.

Brain The body's chief control center, consisting of billions of interconnected nerve cells.

Brainstem A stalklike part of the brain, between the cerebrum and spinal cord. It contains the midbrain, pons, and medulla oblongata.

Breast A female breast consists mainly of a mammary (milk-secreting) gland embedded in fatty tissue.

Breastbone See **Sternum**.

Bronchiole A small subdivision of a bronchus, ending in tiny air sacs called alveoli.

Bronchus The main tubes branching from the lower end of the trachea and forming the main airways to and from the lungs (plural: bronchi).

Capillary The tiniest type of blood vessel, connecting an arteriole and a venule.

Cardiac Relating to the heart.

Cardiovascular Relating to the heart and blood circulatory system.

Cartilage Gristle: dense, white connective tissue cushioning bones.

Cecum The first part of the large intestine, forming a blind pouch.

Cell The basic unit of the body, usually comprising an outer membrane, cytoplasm, a nucleus, and organelles.

Central nervous system

(CNS) The brain and spinal cord.

Cerebellum The largest part of the hindbrain. It helps coordinate muscular movements.

Cerebral cortex The cerebrum's thin outer layer of gray matter.

Cerebral hemisphere Either of the two halves of the cerebrum.

Cerebrospinal fluid A clear fluid filling the brain's ventricles and surrounding the brain and spinal cord to protect them from injury.

Cerebrum The upper, major part of the brain, comprising cerebral hemispheres and diencephalon.

Cervix A neck, especially the neck of the uterus (womb) where it opens into the vagina.

Clavicle Either of the two collarbones.

Clitoris An erectile, pea-sized organ above the opening of the vagina; it is highly sensitive and is involved in female sexual response.

CNS See **Central nervous system**.

Coccyx Four fused vertebrae forming the "tail" of the backbone.

Collagen A fibrous protein that is a major constituent of connective tissue.

Colon The part of the large intestine between the cecum and rectum.

Connective tissue Tissue that supports, binds, or separates more specialized body tissues or acts as packing.

Corium See **Dermis**.

Cornea The transparent circular area at the front of the eye, which acts as a lens.

Coronary arteries Supply the heart muscle.

Corpuscles A term often used for red and white blood cells.

Cortex The outer layer of the brain.

Cranial nerves Twelve pairs of nerves linking the underside of the brain with parts of the head, neck, and thorax.

Cranium The part of the skull that contains the brain.

Cutaneous Relating to the skin.

Cuticle See **Epidermis**.

Deoxyribonucleic acid (DNA) A nucleic acid in the cell's chromosomes containing the cell's coded genetic instructions.

Dermis (or **Corium**) The layer of skin below the epidermis, containing nerves, blood vessels, glands, and hair follicles.

Diaphragm A muscular sheet used in breathing. It separates the thorax (chest) and abdomen (belly).

Digestion The chemical and mechanical breakdown of foods into substances that can be absorbed by the body.

DNA See **Deoxyribonucleic acid**.

Duodenum The upper part of the small intestine, where most chemical digestion takes place.

Ejaculation The discharging of semen from the penis.

Endocardium The membrane that lines the heart and the heart valves.

Endothelium The cell layer that lines the inside of the heart, blood vessels, and lymph vessels.

Enzymes Biological catalysts: proteins that speed up chemical reactions without undergoing change themselves.

Epidermis (or **Cuticle**) The skin's outer layer.

Epiglottis A cartilage flap behind the tongue that is closed during swallowing to stop food from entering the larynx.

Epiphysis See **Pineal gland**.

Epithelium The cell layer covering the body, and lining the alimentary canal and respiratory and urinary tracts.

Erythrocytes Red blood cells.

Esophagus (or **Gullet**) The muscular tube through which food travels between the pharynx and the stomach.

Fallopian tubes (or Uterine tubes or Oviducts) The tubes through which ova (eggs) travel from the ovaries to the uterus.

Femur The thigh bone: the long bone between the hip and the knee.

Follicle A small secreting cavity or sac. Ova (egg cells) develop in follicles in the female ovaries.

Forebrain The front part of the brain comprising diencephalon and telencephalon.

Gallbladder A pear-shaped bag where bile is stored, below the liver.

Gametes Sex cells: sperm in males; ova in females.

Gastric Of the stomach.

Gastrointestinal tract See **Alimentary canal**.

Genes Basic biological hereditary units, consisting of DNA, located on chromosomes.

Genitalia Sex organs.

Gland A structure that synthesizes and secretes a fluid.

Gonads Primary reproductive organs: the ovaries and testes.

Granulocytes White blood cells with cytoplasm that contains granules: basophils, eosinophils, and monocytes.

Gray matter The darker tissue of the brain and spinal cord mainly consisting of neurons' cell bodies and dendrites.

Gullet See **Esophagus**.

Gut See **Alimentary canal**.

Heart The hollow, muscular, fist-sized organ that pumps blood around the body.

Hemoglobin The iron-rich, oxygen-transporting pigment in red blood cells that gives them their color.

Hepatic Relating to the liver.

Hepatic portal vein See **Portal vein**.

Hindbrain Brain structures below the midbrain, comprising the pons, medulla oblongata, and cerebellum.

Hormones Chemical substances released into the blood by endocrine glands to influence organs or tissues in other parts of the body.

Hypophysis See **Pituitary gland**.

Hypothalamus A part of the brain with endocrine functions.

Ileum The last part of the small intestine.

Immune system The body's defense system against infective organisms or other foreign bodies. It includes the lymphatic system.

Involuntary muscle Muscle that is not under conscious control. See also **Smooth muscle**.

Jejunum The middle part of the small intestine.

Joint The junction between bones.

Karyotype The chromosome complement of a person or species: the genome.

Kidney A bean-shaped organ that filters wastes from blood to form urine.

Lactation Milk production by the mammary glands.

Large intestine (or Bowel) The lower part of the alimentary canal, comprising the cecum, colon, and rectum.

Larynx The cartilaginous voice box.

Leukocytes White blood cells. They attack invading microorganisms and help to combat injuries.

Ligament Fibrous tissue that connects bones.

Liver The largest organ in the body, it is involved in various metabolic processes.

Lungs The two organs of respiration, filling most of the chest cavity inside the rib cage and above the diaphragm.

Lymph A transparent fluid that leaks from blood vessels into tissue spaces.

Lymph gland See **Lymph node**.

Lymph node (or Lymph gland) One of the "knots" in the lymphatic system, which contain lymphocytes and macrophages that filter the lymph passing through the nodes.

Lymphatic system A network of lymph vessels and lymph nodes. Vessels collect lymph from body tissues and return it to the blood after harmful substances have been filtered out in the lymph nodes.

Mammary glands The milk-producing structures in the breast.

Medulla oblongata The lowest part of the brain stem, containing the vital centers that control heartbeat and respiration.

Meiosis A type of cell division that produces daughter cells (sperm and ova) each with half as many chromosomes as the parent cell.

Meninges Three protective membranes surrounding the brain and spinal cord.

Menopause When a woman ceases to have menstrual periods.

Menstruation Menstrual periods: the monthly flow of blood and uterine lining from the vagina of nonpregnant females of childbearing age.

Metabolism The array of continuous chemical changes that maintain life in the body.

Mitosis Ordinary cell division in which both daughter cells have as many chromosomes as the parent cell.

Mucous membranes The mucus-secreting linings of the

digestive, respiratory, reproductive, and urinary tracts.

Nasal Relating to the nose.

Nasal cavity The space inside the nose between the base of the skull and the roof of the mouth.

Nerve A bundle of nerve fibers (axons) that transmit impulses to (in the case of sensory nerves) or from (in the case of motor nerves) the central nervous system.

Nervous system The coordinated networks of neurons that control the body. It is divided into the central nervous system (brain and spinal cord), and the peripheral nervous system (the somatic and autonomic nervous systems).

Neuron (*or* Neurone) A nerve cell: the basic unit of the nervous system.

Neurone *See* **Neuron**.

Neurotransmitter A chemical released at nerve endings to transmit nerve impulses across synapses.

Nucleic acids Molecules that store genetic information.

Nucleus The control center of a cell, which contains coded genetic instructions.

Olfactory Relating to smell.

Optic Relating to the eye.

Organ A body part with different types of tissue that performs a particular task.

Organelles Tiny structures (miniorgans) in a cell's cytoplasm with particular tasks.

Ovaries Female sex organs that produce ova (eggs) and sex hormones.

Oviducts *See* **Fallopian tubes**.

Ovulation The release of a ripe egg from a female's ovary.

Ovum An egg; a female sex cell (plural: ova).

Palate The roof of the mouth.

Pancreas An abdominal organ that produces pancreatic juice and the hormones glucagon and insulin.

Parasympathetic nervous system The part of the autonomic nervous system that predominates when the body is at rest.

Parathyroid glands Four pea-sized endocrine glands on the thyroid gland. They produce parathyroid hormone, which controls blood calcium level.

Pelvis A bony basin formed by the two hip bones, the sacrum, and the coccyx.

Pericardium The double-layered membrane that encloses the heart and attaches it to the diaphragm and sternum.

Peristalsis Waves of muscular contraction that propel substances through passageways, such as the alimentary canal.

Phagocytes Types of leukocytes that engulf and destroy microorganisms and foreign bodies.

Pharynx The throat.

Pineal gland (or Epiphysis) An endocrine gland in the brain that secretes melatonin.

Pituitary gland (or Hypophysis) A three-lobed, pea-sized gland below the hypothalamus. It produces growth hormone, hormones that act on other endocrine glands, oxytocin, and ADH. It is often called the body's "master gland."

Plasma The fluid part of blood.

Pleura The membrane that covers the lungs (visceral pleura) and lines the chest wall (parietal pleura).

Plexus A network of nerves (or blood or lymph vessels).

Portal vein (or Hepatic portal vein) Drains blood from digestive organs to the liver.

Prostate gland A gland situated below the bladder in males. It produces a sperm-activating fluid that forms nearly a third of the semen's volume.

Pudendum See **Vulva**.

Pulmonary Relating to the lungs.

Receptor A structure, such as a sensory nerve ending, specialized to detect environmental stimuli.

Rectum The last part of the colon, where feces collects before leaving the body.

Reflex action The body's automatic response to a stimulus, such as blinking.

Renal Relating to the kidney.

Respiration 1) Breathing; 2) Taking in oxygen and giving out carbon dioxide; 3) Deriving energy from food with or without using oxygen.

Respiratory system In humans, the mouth, nose, pharynx, larynx, trachea, bronchi, bronchioles, alveoli, and lungs.

Ribonucleic acid (RNA) A nucleic acid concerned with protein synthesis.

Ribs Twelve pairs of bones that protect the chest cavity and assist breathing by moving up and out during inspiration and down and in during expiration.

Salivary glands The lingual, parotid, sublingual, and submandibular glands that produce saliva.

Serum Blood plasma that does not contain clotting factors but does contain antibodies.

Sinus A cavity, such as the channels draining venous blood from the brain.

Skeleton The bony framework that protects and supports the body's soft tissues.

Skin The body's waterproof covering; its largest organ, comprising two main layers: the epidermis and dermis.

Small intestine The alimentary canal between the stomach and large intestine, comprising the duodenum, jejunum, and ileum. Most digestion occurs here.

Smooth muscle (or Unstriated muscle or Involuntary muscle) Muscle without striped fibers that automatically operates internal organs such as the stomach, bladder, and blood vessels.

Sphincter A ring-shaped muscle that contracts to close an orifice.

Spinal cord The cable of nerve tissue running down inside the vertebral column (spine) and linking the brain with nerves supplying most of the body.

Spine See **Vertebral column**.

Sternum The breastbone.

Subcutaneous tissue The sheet of connective tissue below the dermis.

Suprarenal glands See **Adrenal glands**.

Suture An immovable fibrous joint between the skull bones.

Taste buds Tiny sensory organs of the tongue and palate, distinguishing salty, sweet, sour, and bitter tastes.

Teeth Bonelike structures in the jaws. Different types (incisors, canines, premolars, molars) are specialized to tear, crush, and/or grind food.

Tendons Bands of fibrous connective tissue joining muscles to bones.

Testis (*or* Testicle) One of a pair of primary male sex organs that manufacture sperm (plural: testes).

Thalamus A brain structure above the hypothalamus. It sends sensory impulses to the cerebral cortex, links sensations with emotions, and affects consciousness.

Thymus An endocrine gland located behind the sternum. It produces thymosin.

Thyroid An endocrine gland at the front of the neck, producing thyroid hormone.

Tissue A collection of similar cells that perform a particular task.

Trachea (*or* Windpipe) The tube between the larynx and the bronchi.

Tubule A tiny tube.

Tunica A tissue layer forming a coating. Blood vessels have three such layers (intima, media, adventitia).

Unstriated muscle *See* **Smooth muscle**.

Ureter The tube conveying urine from a kidney to the bladder.

Urethra The passage taking urine from the bladder to the body's exterior.

Urinary system The kidneys, ureters, bladder, and urethra.

Urine Liquid waste excreted by the kidneys.

Uterine tubes *See* **Fallopian tubes**.

Uterus (*or* Womb) A hollow muscular organ located above the bladder. Inside it, a fertilized ovum develops into a fetus.

Uvula A conical tag hanging from the back of the palate. It helps to keep food out of the nasal cavities.

Vagina The muscular passage between the vulva and cervix (neck of the uterus).

Vascular Relating to or richly supplied with vessels, especially blood vessels.

Vein A blood vessel that transports blood from capillaries back to the heart. Veins contain valves to prevent the backflow of blood.

Venous Relating to veins.

Ventricle A cavity: one of the two lower chambers of the heart.

Venule A small vein.

Vermiform appendix *See* **Appendix**.

Vertebra A bone of the vertebral column (plural: vertebrae).

Vertebral column (*or* Backbone *or* Spine) The column of vertebrae between the skull and the hip bones, supporting the body and shielding the spinal cord. It has five sections: cervical, thoracic, lumbar, sacral, and coccygeal.

Vestibule A space before a passage begins, as in the inner ear beyond the oval window, between the semicircular ducts and cochlea.

Vocal cords Two belts of tissue stretched across the larynx which produce sounds when air rushes past them.

Vulva (*or* Pudendum) The external female genitals.

White matter The paler tissue of the brain and spinal cord comprised mainly of myelin-sheathed nerve fibers.

Windpipe *See* **Trachea**.

Womb *See* **Uterus**.

There is a lot of useful information on the internet. There are also many sites that are fun to use. Remember that you may be able to get information on a particular topic by using a search engine such as Google (<http://www.google.com>). Some of the sites that are found in this way may be very useful, others not. Below is a selection of Web sites related to the material covered by this book. Most are illustrated, and they are mainly of the type that provides useful facts.

Facts On File, Inc. *takes no responsibility for the information contained within these Web sites. All the sites were accessible in January 2005.*

Anatomy of the Human Body: Gray's Anatomy

Online version of the classic *Gray's Anatomy of the Human Body*, containing over 13,000 entries and 1,200 images.
<http://www.bartleby.com/107/>

Biology Online

A source for biological information, suitable for homework, research projects, and general interest, with hundreds of biology Web site links.
<http://www.biology-online.org>

BIOME

A guide to selected, quality-checked internet resources in the health and life sciences.
<http://biome.ac.uk>

Health Sciences & Human Services Library

Provides links to selected Web sites that may be useful to both students and researchers.
<http://www.hshsl.umaryland.edu/resources/lifesciences.html>

Human Anatomy Online

Interactive resource, with visual keys to text on the human body.
<http://www.innerbody.com>

North Harris College Biology Department

Tutorials and graphics on biology, human anatomy, human physiology, microbiology, and nutrition.
<http://science.nhmccd.edu/biol/>

Open Directory Project: Neurology

Comprehensive list of internet resources.
http://dmoz.org/Health/Medicine/Medical_Specialties/Neurology/

The Biology Project

Structured tutorials on life sciences. Particularly strong on cell biology, human biology, and molecular biology.
<http://www.biology.arizona.edu>

University of Nebraska: Brains Rule!

Information, interactive games, and lesson plans on the human brain; includes "Ask the Brain Expert" and "Meet a Neuroscientist" features.
<http://www.brainsrule.com>

University of Texas: BioTech Life Sciences Resources and Reference Tools

Enriching knowledge of biology and chemistry, for everyone from high school students to professional researchers. The Dictionary and Science Resources are particularly useful.
<http://biotech.icmb.utexas.edu>

- A**
- acetylcholine 13, 22, 80
 - adrenal glands 28, 85, 92–93
 - disorders 101
 - hormones 82, 83, 87
 - stress 48, 100
 - sympathetic nervous system 79
 - adrenocorticotrophic hormone (ACTH) 28, 48, 100
 - anesthesia 75
 - antidiuretic hormone (ADH) 28, 84, 101
 - arachnoid layer 10, 11, 55, 72
 - spinal cord 59, 73
 - autonomic nervous system (ANS) 7, 8, 9, 10, 11, 76–81
 - adrenal glands 92, 93
 - development 35
 - peripheral nervous system 6
 - smoking 52
 - spinal cord 56
 - axons (nerve fibers) 6, 11, 13, 14, 16
 - memory 45
 - motor neurons 22, 23
 - neural circuits 15
 - sensory neurons 20
 - synapses 18
- B**
- balance 7, 42, 62
 - brain (CNS) 6, 10, 11, 32–55
 - autonomic nervous system 76
 - central nervous system 6, 8, 9
 - cerebrospinal fluid 40
 - development 34–35
 - disorders 30, 54–55
 - endocrine glands 26, 27
 - functions 42–43
 - hormone production 91
 - memory 44
 - parasympathetic nervous system 80
 - protection 72
 - sensory neurons 20, 21
 - sleep 46
 - stress 48, 100
 - stroke 31
 - structure 33, 36–41
 - white matter 13
 - brainstem 10, 33, 37, 41, 42, 43
 - breathing,
 - autonomic nervous system 76
 - brain 33
 - hindbrain 6
 - medulla oblongata 43
 - sleep 46, 47
 - stress 48, 100
 - vagus nerve 62
- C**
- central nervous system (CNS) 6, 8, 9, 10, 11, 32, 56
 - development 34
 - motor units 23
 - neurons 15, 16
 - reflex arcs 24
 - cerebellum 6, 10, 33, 36, 41
 - balance 42
 - development 34–35
 - function 43
 - movement control 42
 - nerve pathways 69
 - cerebral cortex 11, 48, 69
 - cerebral hemorrhage 31, 54, 55
 - cerebrospinal fluid 40, 55, 72
 - spinal cord 59, 73
 - cerebrum and cerebral hemispheres 10, 32, 33
 - development 34–35
 - function 42, 43
 - movement control 42
 - optical cortex 7
 - structure 36–39
 - ventricles 40
 - consciousness 6, 10, 11, 43
 - sleep 46
 - corpus callosum 33, 37, 38, 39
 - cortex 10, 36, 38, 39
 - functions 42
 - optical 7
 - corticosteroids 83
 - cranial nerves 10, 62–63
 - development 34
 - parasympathetic system 80
 - peripheral nervous system 6–7
 - sensory innervation 68
- D**
- dendrites 6, 10, 12, 13, 14, 15, 16
 - memory 45
 - motor neurons 22
 - sensory neurons 20
 - synapses 18
 - dermatomes 10, 21, 60, 61

diabetes 94, 101
 diencephalon 6, 10, 11, 33, 38
 development 34
 function 43
 digestion and digestive organs,
 autonomic nervous system 7, 8, 76, 77
 hormones 96
 parasympathetic nervous system 81
 stress 100
 sympathetic nervous system 79
 vagus nerve 62
 dura mater 11, 55, 59, 72, 73, 75
 spinal cord 59, 73

E
 ears 6, 7, 10
 balance 42
 cranial nerves 7, 62
 emotions 11, 32, 37, 38, 39
 cerebrum 10, 43
 stress 48
 endocrine system 7, 26–29
 glands 82, 83, 84, 86, 87
 disorders 101
 epinephrine 11, 83, 85, 87, 92, 100
 estrogens 26, 83, 85, 99
 eyes 6, 7, 10, 33
 balance 42
 development 35
 optic nerve 62
 sensory neurons 20
 sleep 46

F
 follicle-stimulating hormone (FSH) 28, 83, 84, 99

G
 ganglia 14, 16, 60, 78, 79
 gray matter 10, 32, 38
 spinal cord 58, 59, 73
 growth hormone 26, 27, 28, 82, 83, 84, 101

H
 headache 30, 49, 53
 hearing 33, 43
 heart and heartbeat 10
 autonomic nervous system 8, 9, 76
 brain 33
 medulla oblongata 43
 parasympathetic nervous system 80, 81
 sleep 46, 47
 stress 48, 100
 sympathetic nervous system 79
 vagus nerve 7, 62
 heat receptors 6, 25
 hormones and hormonal system 7, 86–101
 brain 10, 91
 disorders 101
 endocrine glands 88–95
 endocrine system 26, 27, 28, 82–85
 negative feedback 96
 non-endocrine glands 97
 sex glands 98–99
 stress 48, 100
 sympathetic nervous system 11

hypothalamus 10, 11, 38, 83
 brain 33
 endocrine glands 26, 27, 28, 29
 function 43
 hormones 82, 87, 91
 nerve pathways 69
 sex hormones 98, 99
 stress 100

I
 insulin 26, 83, 85, 94, 95, 96
 intelligence 32, 33, 43, 54
 islets of Langerhans 83, 94, 95

L
 learning 10, 45
 limbic system 7, 37, 39, 43
 luteinizing hormone (LH) 28, 83, 84, 99

M
 medulla oblongata 6, 10, 33, 37, 41, 43, 80
 melatonin 83, 84, 91, 101
 memory 10, 33, 39, 44–45
 Alzheimer's disease 30
 amnesia 54
 cerebrum 43
 meninges 10, 11
 cerebrospinal fluid 40
 meningitis 30, 40, 54, 55
 spinal cord 58, 59
 menstrual cycle 85, 99
 mental illness 48–49
 mind 10, 11, 32, 33
 memory 44
 stress 48
 moods 32, 39, 53

motor cortex 36, 42
 motor end plate 12, 13, 14, 22, 23, 25
 motor (efferent) nerves 6, 9, 10, 11, 15, 22–23
 motor units 23
 reflex arcs 24, 25
 spinal cord 59
 spinal nerves 70, 71
 multiple sclerosis (MS) 74
 myelin 11, 12, 13, 16, 59

N
 nerve pathways 20, 24, 69
 nerves and nerve cells (neurons) 6, 11, 12, 14–15, 16
 autonomic nervous system 7
 brain 32, 35
 dermatomes 21
 disorders 30, 54–55
 gray matter 10
 memory 44, 45
 motor 22–23
 nerve impulse 13, 16, 17
 neural circuits 15
 reflex arcs 24–25
 sensory 20–21
 synapses 18–19
 neuroglia cells 12, 13, 35
 neurotransmitters 13, 18, 19, 22
 nodes of Ranvier 13, 16
 norepinephrine (noradrenaline) 13, 79, 83, 85, 87, 92

O
 olfactory system 7, 36, 62, 63
 optic nerve 7, 36, 62, 63

ovaries 28, 82, 83, 85, 98, 99
 oxytocin 28, 83

P
 pain 6, 21, 25
 pancreas 26, 82, 83, 85, 94–95, 96
 paralysis 54, 74
 parasympathetic nervous system 7, 9, 10, 11, 76, 80–81
 parathyroid glands 82, 83, 87, 89, 101
 peripheral nervous system (PNS) 6, 8, 9, 10, 11, 14
 autonomic nervous system 76
 ganglia 14
 neurons 15
 spinal cord 56
 pia mater 11, 55, 59, 72, 73
 pineal gland 27, 82, 83, 84, 91
 pituitary gland 10, 82, 83, 84, 91
 endocrine system 26–29
 hormonal stimuli 87
 sex hormones 98, 99
 stress 48, 100
 pons 6, 10, 11, 36, 42, 43
 balance 42
 pressure receptors 6, 7
 progesterone 83, 85, 99
 prolactin 28
 proprioceptors 6
 prostaglandin 86

R
 receptors 6, 7, 13
 afferent system 9
 dermatomes 60

hand 64
 nerve pathways 69
 neural circuits 15
 reflex arcs 24
 sensory neurons 20–21
 spinal cord 56
 reflex actions 6, 11, 15, 24–25, 56, 69
 respiration 10

S
 saliva and salivary glands 77, 79, 100
 Schwann cells 12, 13, 16
 sciatic nerve 66, 70, 74
 senses 6, 7, 43, 44, 48
 sensory cortex 42
 sensory (afferent) nerves 11, 59, 66, 68–69
 nerve endings 13
 neurons 6, 9, 11, 20, 21, 24, 25
 spinal nerves 70, 71
 sensory organs 20
 sex hormones 26, 28, 83, 84, 85, 93
 adrenals 92
 pituitary gland 26
 sex organs 98–99
 sight 33, 43
 skin 6, 7, 72
 autonomic nervous system 76
 dermatomes 10
 hormones 29
 nerves 68, 69
 parasympathetic nervous system 81
 reflex arcs 25
 sensory supply 20, 21, 70, 71

stress 48, 100
 sympathetic nervous system 79
 skull (cranium) 6, 7, 29, 32, 72
 sleep 30, 46–47, 81
 smell 36, 62, 63
 somatic nervous system (SNS) 8, 9, 11, 56
 sound 6, 7, 62
 speech 33, 36, 43
 spina bifida 30
 spinal cord 11, 32, 56–75
 central nervous system 6, 8, 9, 10
 cerebrospinal fluid 40
 development 34
 epidural anesthesia 75
 medulla oblongata 37
 nerve pathways 69
 neural circuits 15
 parasympathetic nervous system 80
 reflex arcs 24, 25
 sensory neurons 20, 21
 spinal nerves 7
 structure 58–59, 73
 sympathetic nervous system 78
 white matter 13
 spinal nerves 7, 11, 21, 57, 60, 65, 67
 brachial plexus 10

dermatomes 21, 60
 development 34
 epidural anesthesia 75
 neural circuits 15
 peripheral nervous system 6
 sensory innervation 68
 spinal cord 56, 57, 58, 59, 73
 steroids 83, 86, 93
 stress 9, 48–51
 stroke 30, 31, 55
 subarachnoid space 72, 73
 sweat and sweat glands 7, 76, 77, 79, 100
 sympathetic nervous system 7, 9, 10, 11, 78–79
 adrenal glands 92, 93
 autonomic nervous system 76
 synapses 6, 13, 15, 16, 18–19
 memory 45
 reflexes 24, 25
 sensory neurons 20

T

taste 6, 7, 62, 63
 testes 28, 82, 83, 85, 87, 98
 testosterone 26, 83, 85, 98
 thalamus 10, 11, 33, 38, 39
 development 34
 function 43

movement control 42
 nerve pathways 69
 thinking 6, 36, 43
 thymus gland 82, 83, 85, 90, 91
 thyroid gland 28, 83, 84, 88, 89, 101
 endocrine system 26
 hormonal stimuli 87
 hormones 82, 83
 tibial nerve 66, 67, 68
 tongue 6, 7, 62, 63
 touch 6, 7, 21, 60, 69

V

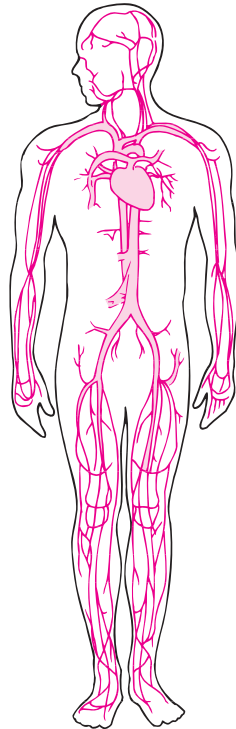
vagus nerve 7, 62, 63, 80
 ventricles 40, 41, 72
 vertebrae 56, 57, 58, 73, 75
 vertebral column (spine) 6, 11, 56, 57, 58
 vestibular system 7
 visual cortex 42
 voluntary control 8, 9, 10, 15, 43

W

water level 28
 white matter 11, 13
 brain 32, 38, 39
 spinal cord 58, 59, 73

THE FACTS ON FILE
ILLUSTRATED GUIDE TO
THE HUMAN BODY

HEART AND CIRCULATORY SYSTEM



THE DIAGRAM GROUP

The Facts On File Illustrated Guide to the Human Body: Heart and Circulatory System

Copyright © 2005 The Diagram Group

Editorial: Lionel Bender, David Harding, Denis Kennedy,
Gordon Lee, Jamie Stokes, Barbara Taylor

Scientific consultant: Stephen Rudd

Design: Anthony Atherton, Richard Hummerstone,
Lee Lawrence, Kim Richardson, Ben White

Illustration: Pavel Kostal, Kathleen McDougall

Picture research: Neil McKenna

Indexer: Jane Parker

All rights reserved. No part of this book may be reproduced or utilized in any form or by any means, electronic or mechanical, including photocopying, recording, or by any information storage or retrieval systems, without permission in writing from the publisher. For information contact:

Facts On File, Inc.
132 West 31st Street
New York NY 10001

Library of Congress Cataloging-in-Publication Data

The Facts On File illustrated guide to the human body. Heart and circulatory system / the Diagram Group.
p. cm.

Includes index.

ISBN 0-8160-5982-9 (hc : alk. paper)

1. Cardiovascular system—Juvenile literature. 2. Heart—Juvenile literature. I. Title: Illustrated guide to the human body Heart and circulatory system. II. Title: Heart and circulatory system. III. Diagram Group.

QP103.F33 2005

612.1—dc22

2004022927

Set ISBN: 0-8160-5979-9

Facts On File books are available at special discounts when purchased in bulk quantities for businesses, associations, institutions, or sales promotions. Please call our Special Sales Department in New York at 212/967-8800 or 800/322-8755.

You can find Facts On File on the World Wide Web at
<http://www.factsonfile.com>

Printed in the United States of America

EB Diagram 10 9 8 7 6 5 4 3 2 1

This book is printed on acid-free paper.

Note to the reader

This book is not intended to serve as a medical textbook for either physicians or patients. The information and advice it contains should not be used or relied upon without consulting the advice of a qualified physician. The publishers disclaim any responsibility for the accuracy of the information or advice that this book contains and any responsibility for any consequences that may result from any use or reliance thereon by the reader.

Contents

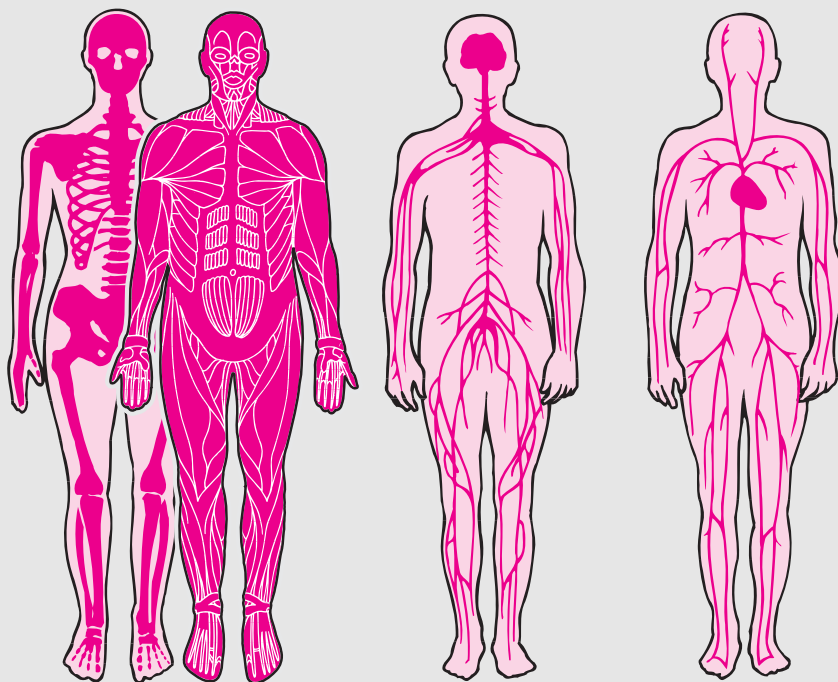
Introduction: About this book	4	Leg and foot	64
SECTION 1		Blood pressure	66
BLOOD SYSTEM		Circulatory disorders	68
Introduction	6	SECTION 4	
Heart and circulation	8	BLOOD	
Cardiovascular key words	10	Introduction	70
Heart	12	Blood cells	72
Blood vessels	14	Blood cell development	74
Arteries	16	Bone marrow and spleen	76
Capillaries	18	Bleeding and blood clotting	78
Veins	20	Blood groups and transfusions	80
Blood pressure and pulse	22	Blood disorders and defenses	82
Heart and exercise	24	SECTION 5	
Blood disorders	26	LYMPHATIC SYSTEM	
SECTION 2		Introduction	84
HEART		Lymph circulation	86
Introduction	28	Lymph nodes	88
The heart and thorax	30	Lymph disorders	90
Heart muscle	32	SECTION 6	
Controlling heart rate	34	IMMUNITY & DEFENSE	
Inside the heart	36	Introduction	92
Flow of blood through the heart	38	Lines of defense	94
Heart valves	40	Immunity and antibodies	96
The cardiac cycle	42	Cellular immunity	98
Stress, diet, and exercise	44	Immune and defense disorders	100
Keeping your heart healthy	46	Glossary of the human body	102
Heart disorders 1	48	Web sites to visit	108
Heart disorders 2	50	Index	109
SECTION 3			
CIRCULATION			
Introduction	52		
Veins	54		
Aorta and venae cavae	56		
Head, face, and neck	58		
Lungs and digestive tract	60		
Arm and hand	62		

This book is a concise, illustrated guide to the anatomy, physiology, well-being, and disorders of the human heart and circulatory systems. It has been written and illustrated specially for students and laypeople interested in medicine, health, fitness, and first aid. The subject is dealt with in clear steps, so that the reader can steadily acquire a good overall understanding. Explanatory texts, diagrams, illustrations, captions, and fact boxes are combined to help readers grasp important information at a glance. A glossary of scientific and jargon words defines medical terms in everyday language. A list of Web sites provides links to other relevant sources of information, and the index enables quick access to articles.

There are six sections within the book. The first section looks at the organization and structure of the blood circulatory system. The following three sections survey each major component of the system, from the heart to types of blood cells. Section 5 looks at the lymphatic system, which functions in parallel with the blood system. The last section deals with how blood cells provide a defense against infection. Within each section, discussion and illustration of the structure and function of the anatomical parts are followed by principles of healthcare, fitness, and exercise. These are followed by a survey of the main disorders and diseases affecting the region. Information is presented as double-page topics arranged in subsections.

Human body systems

This book is one of eight titles in THE FACTS ON FILE ILLUSTRATED GUIDE TO THE HUMAN BODY series, which looks at each of the major body systems in turn. Some of the titles in the series include more than one system. The skeletal and muscular systems, and the blood and lymphatic systems, for example, work in conjunction and so are treated together. There is a separate title for human cells and genetics, which are the building blocks and underlying chemistry of all body systems.



**Skeletal and
Muscular Systems**

**Brain and
Nervous System** **Heart and
Circulatory System**

Section 1: BLOOD SYSTEM surveys the heart, blood vessels, capillaries, cardiovascular exercise, and circulation disorders.

Section 2: HEART looks at heart muscle, heart beat, blood flow, stress, and cardiac disorders.

Section 3: CIRCULATION focuses on the network of arteries, capillaries, and veins, and discusses blood pressure.

Section 4: BLOOD features the many types of blood cells, blood groups, and blood clotting.

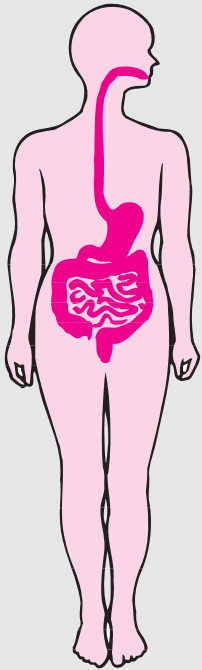
Section 5: LYMPHATIC SYSTEM looks at how circulating white blood cells, proteins, and fats are channeled from tissue spaces into the blood circulatory system.

Section 6: IMMUNITY AND DEFENSE examines how certain white blood cells


respond to injuries, transplants, and infections.

This book has been written by anatomy, physiology, and health experts for non-specialists. It can be used:


- as a general guide to the way the human body functions
- as a reference resource of images and text for use in schools, libraries, or in the home
- as a basis for examination preparation for students of human biology, medicine, nursing, physiotherapy, and general healthcare.



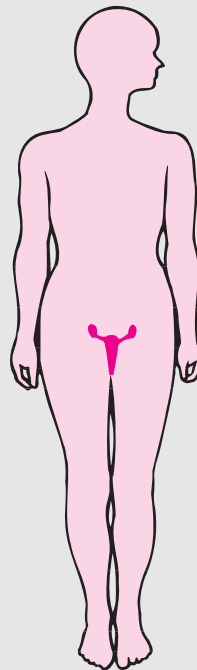
Digestive System



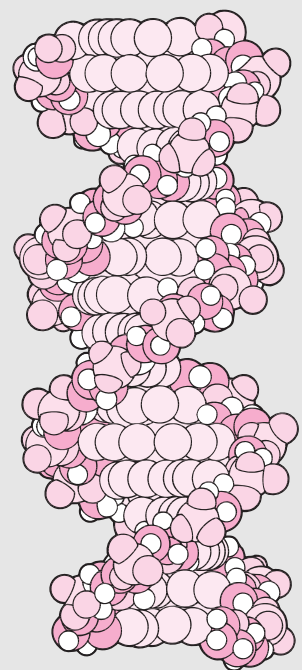
The Senses



Respiratory System



Reproductive System



Cells and Genetics

The cardiovascular system circulates blood around the body, supplying cells with oxygen and nutrients and removing waste products. The main parts of this closed system are the heart and a network of tubes (arteries, veins, and capillaries) to transport the blood. Most arteries carry red, oxygenated blood; most veins carry blue, deoxygenated blood.

Heart facts

- A person's heart beats 100,000 times a day.
- Each heart chamber holds the same volume of blood—about 2.5–2.8 fluid ounces (70–80 ml).

Heart This muscular pump lies in a sac (the pericardium) between the lungs, and it pumps blood around the body. It has four chambers: an (upper) atrium and a (lower) ventricle on each side of the muscular septum that divides the heart lengthwise. Atria receive blood from veins; ventricles pump blood into arteries. Valves within the heart control the flow of blood in and out of the heart.

Arteries These branching blood vessels take blood from the heart to the body tissues. The body's main artery is the aorta. Arterioles are tiny arteries that regulate blood supply to capillaries.

Veins The veins are blood vessels that transport blood to the heart. Valves in veins allow the blood to flow only in one direction. The largest veins are the inferior and the superior vena cava. The smallest are the venules that take blood from capillaries. In portal systems, such as the hepatic portal system, veins take blood between two different sets of tissue, such as the digestive system and the liver. Venous sinuses (wide channels) drain blood from the brain.

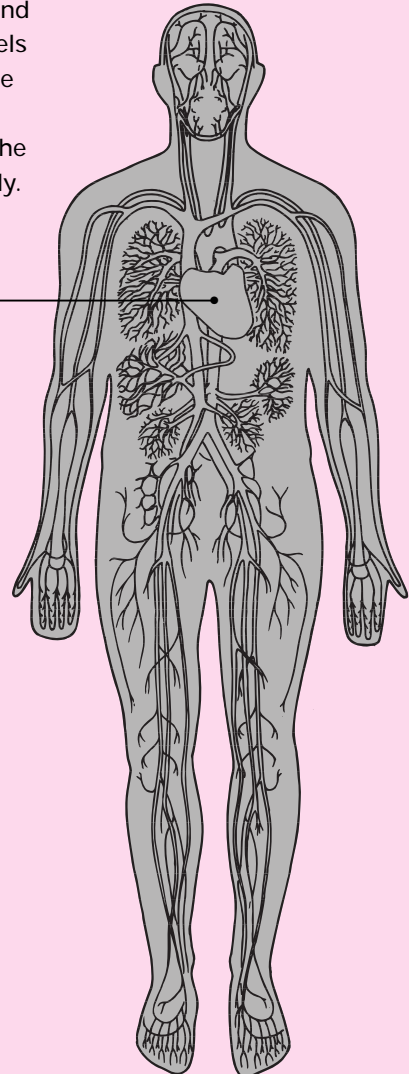
Capillaries These tiny tubes link arterioles with venules. Capillaries exchange substances with nearby tissues via capillary cell walls.

Blood The major components of this complex fluid are: plasma (blood fluid), erythrocytes (red cells), leukocytes (white cells), and

Cardiovascular system

The heart and blood vessels make up the circulatory system of the human body.

Heart



thrombocytes (platelets). There are four main blood groups: A, B, AB and O. Blood types have to be carefully matched for blood transfusions or for transplant surgery.

Bone marrow This is a red or yellow tissue contained within bone cavities. Red marrow produces red blood cells. Yellow marrow is mostly fat tissue.

Spleen A large organ below the diaphragm, the spleen stores and releases red blood cells, eliminates damaged red blood cells, and makes cells that produce antibodies.

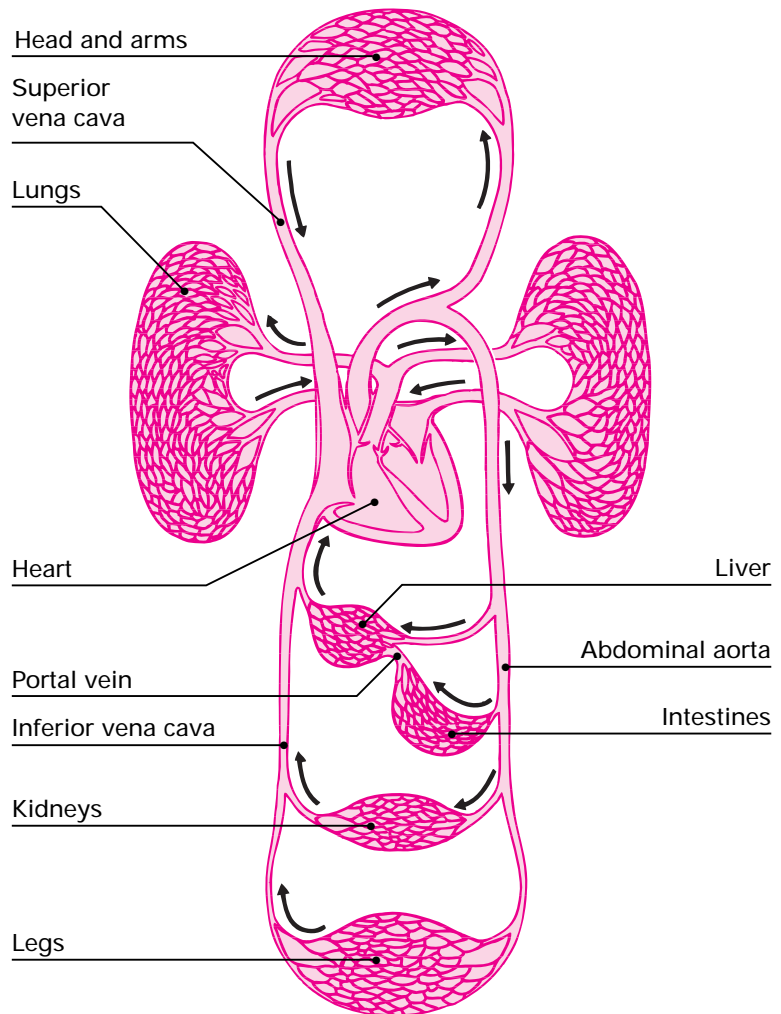
Lymphatic system This drainage system is related to the blood system. Blind-ended tubes run parallel to arteries and veins and carry colorless fluids (lymph) from body tissues to the blood. Some lymphatic vessels contain enlargements called lymph nodes, which help with the immune response and produce lymphocytes that kill bacteria.

Blood facts

- In a tiny drop of blood, there are five million red cells, and 10,000 white cells.
- The circulatory system contains about 90,000 miles (150,000 km) of vessels.

How blood circulates around the body

The pulmonary circulation pumps blood to and from the lungs. The systemic circulation pumps blood to and from all other parts of the body.



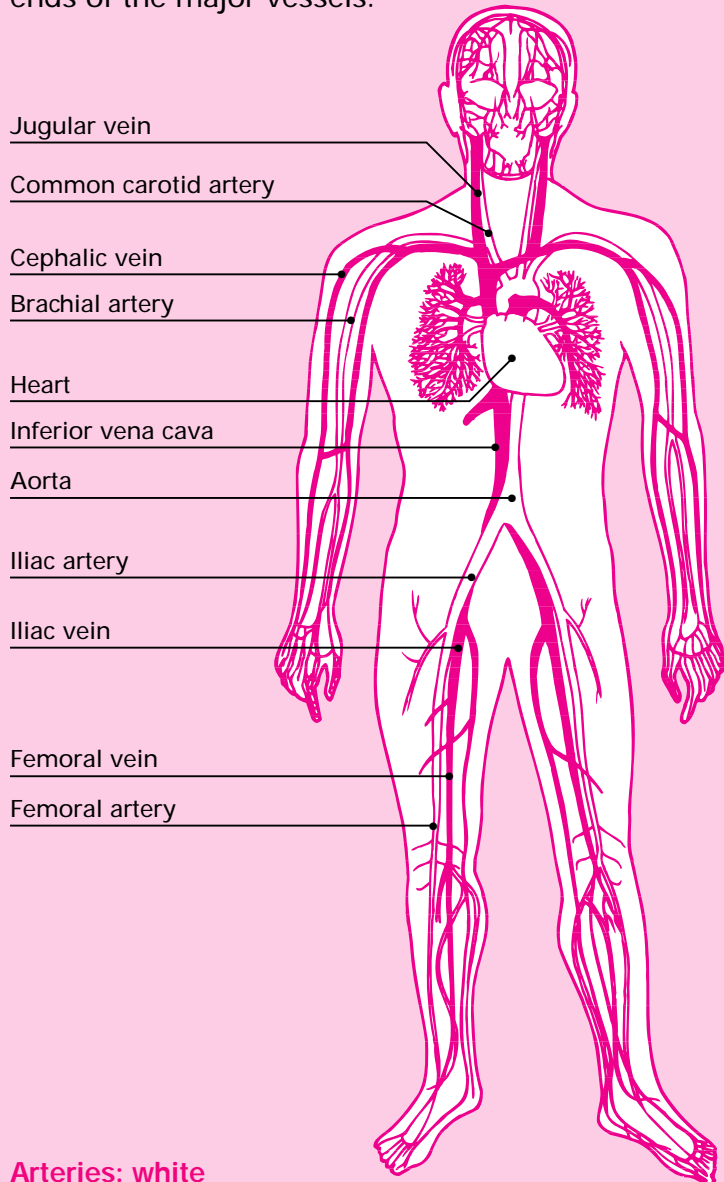
The heart is a hollow muscle about the size of a grapefruit. It is the strongest muscle in the body. Lying within the rib cage, the heart is well protected against damage by the surrounding bones. The mass of the heart lies centrally in the chest, but the apex, where the beat is most easily felt, tapers toward the left. The heart begins to pump less than a month after conception, and by adulthood is pumping about 3,000 gallons (11,356 l) of blood per day, at an average rate of 70 beats a minute. The rate at which a heart beats is affected by a variety of factors, such as body temperature, emotions, hormones, drugs, activity, blood pressure, heart disease, and age. A newborn baby has a heart rate of about 140 beats per minute; in a 10 year old it is about 90; and in an adult it is about 60–90.

Circulation facts

- On average, blood takes about one minute to complete a full circuit around the body.
- The aorta is the largest artery and the vena cava is the largest vein.
- The average body contains 9 pints (5 l) of blood.

Major arteries and veins

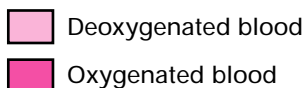
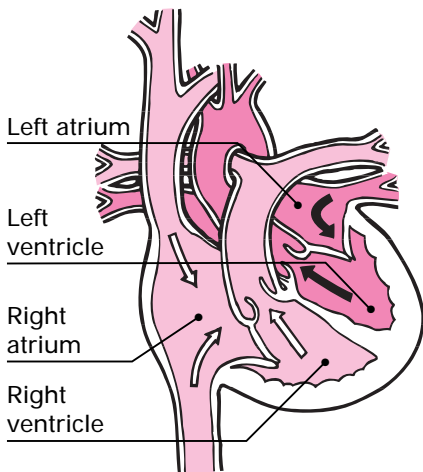
The networks of arteries and veins are superimposed mirror images. Capillary systems form the links between the ends of the major vessels.



Arteries: white
Veins: color

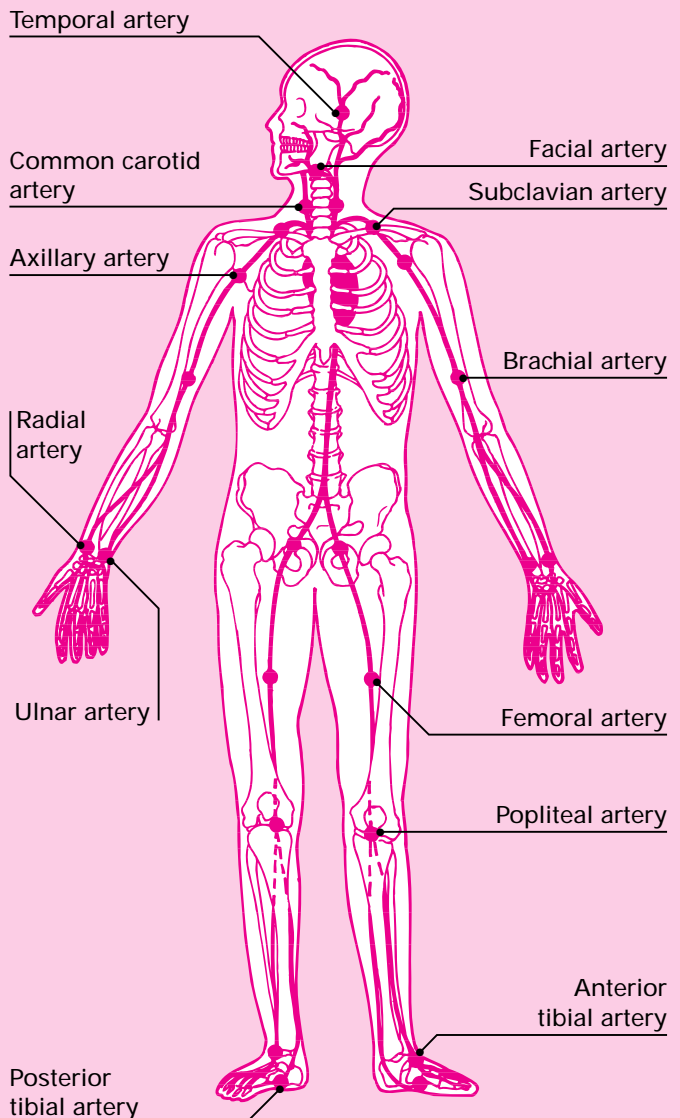
Blood flow through the heart

This diagram shows the path that blood takes through the heart. Deoxygenated blood enters the upper chamber (atrium) of the right side of the heart and is then pumped by the lower chamber, or right ventricle, to the lungs for oxygenation. The reoxygenated blood returns to the left atrium and is pumped to the body by the left ventricle. There is a system of valves which open to let blood through, then close to prevent any backflow. This keeps blood flowing in the same direction.



Arteries and pressure points

In the case of an injury, pressure can be applied to certain arteries that are close to the surface in order to stem the flow of blood. These pressure points are also the places where a pulse is most easily taken.



CIRCULATION: KEY WORDS

Aorta The largest artery, arising from the left ventricle of the heart.

Arteriole A small artery supplying blood from a main artery to a capillary.

Artery A blood vessel transporting blood from the heart to elsewhere in the body.

Blood pressure The pressure of blood against blood-vessel walls, especially the walls of arteries.

Brachial artery Major artery supplying the arm and hand.

Brachial vein Drains the arm and hand.

Capillary The tiniest type of blood vessel, connecting an arteriole and a venule.

Cardiac veins Drain the heart muscle.

Carotid artery Either of the two main arteries in the neck, one on each side.

Cephalic vein Drains the arm and hand.

Coronary arteries Supply the heart muscle.

Diastole The interval between contractions of the heart.

Endothelium Single layer of wide, flat cells lining the heart, blood vessels, and lymph vessels.

Femoral artery Supplies the thigh and skin of the lower abdomen.

Femoral vein Drains deep parts of the leg.

Heart The hollow muscular organ that pumps blood around the body.

Hepatic artery Supplies the liver.

Hepatic vein Drains the liver.

Iliac artery Supplies the pelvis region and the leg.

Iliac vein Drains the pelvis region and leg.

Inferior vena cava The major vein draining the body below the diaphragm.

Jugular vein Drains the head.

Lumen The cavity inside a blood vessel.

Popliteal vein Drains the calf.

Pressure point A place where pressure can be applied to an artery in order to control bleeding.

Pulmonary artery Carries deoxygenated blood from the heart to a lung.

Pulmonary circulation The system of blood vessels transporting blood between the heart and the lungs.

Pulmonary vein Carries oxygenated blood from a lung to the heart.

Pulse The regular throbbing of an artery, which can be felt as it expands each time the heart pumps blood through it.

Renal artery Supplies the kidney, ureter, and adrenal gland.

Renal vein Drains the kidney, ureter, adrenal gland, diaphragm, ovary, or testis.

Subclavian artery Supplies the head, neck, spinal cord, thyroid, larynx, chest muscles, and arm.

Subclavian vein Drains the head, neck, and shoulder.

Superior vena cava Drains the body above the diaphragm, except the heart and lungs.

Systole A contraction of the heart that pumps blood through the body.

Tibial artery Supplies lower leg and foot.

Tunica A tissue layer forming a coating. Arteries and veins have three such layers (intima, media, adventitia).

Vasa vasorum Tiny blood vessels in the walls of other blood vessels.

Vein A blood vessel that transports blood from capillaries back to the heart. Valves in veins prevent backflow of blood.

Venule A small vein.

HEART: KEY WORDS

Aortic arch The part of the aorta leading from the ascending aorta and forming an arch up, over, and to the rear of the heart.

Atrioventricular valve (or AV valve) A valve between a ventricle and an atrium.

Atrium Either of the two upper chambers of the heart, which receive blood from the veins (plural: atria).

Bicuspid valve A heart valve with two cusps (flaps): the mitral valve.

Cardiac Relating to the heart.

Cardiac cycle The sequence of events involved in the pumping action of the heart. The atria contract together and force blood into the ventricles. The ventricles then both contract to pump blood into the aorta and the pulmonary artery.

Cardiac muscle Involuntary striated muscle of a type that occurs only in the heart.

Coronary arteries The right and left coronary arteries are branches of the aorta that supply the heart muscle with blood.

Coronary sinus The wide terminal portion of the coronary vein which empties into the right atrium.

Cuspid Consisting of cusps (flaps). Bicuspid heart valves have two cusps, and tricuspid valves have three.

Endocardium The membrane that lines the heart and the heart valves.

Myocardium The main part of the heart wall, comprising cardiac muscle.

Pericardium The double-layered membrane that encloses the heart and attaches it to the diaphragm and sternum.

Ventricle One of the two lower chambers of the heart.

BLOOD: KEY WORDS

Blood A sticky red fluid comprising plasma, red blood cells (erythrocytes), white blood cells (leukocytes), and platelets (thrombocytes).

Blood type Any of various types of blood (notably A, B, AB, O, Rh-positive, Rh-negative) named for the antigen(s) they do or do not contain.

Corpuscles A term often used for red and white blood cells.

Erythroblast An immature cell from which an erythrocyte develops.

Erythrocytes Red blood cells, which transport oxygen and carbon dioxide using hemoglobin.

Granulocytes White blood cells with cytoplasm that contains granules. Agranulocytes do not have these granules.

Hemoglobin The iron-rich, oxygen-transporting pigment in red blood cells that gives them their color.

Leukocytes White blood cells. They attack invading microorganisms and help to combat injuries.

Monocytes Phagocytic leukocytes formed in the bone marrow.

Neutrophil The most plentiful type of white blood cell. A type of granulocyte.

Phagocytes Types of leukocytes that engulf and destroy microorganisms and foreign bodies.

Plasma The fluid part of blood.

Platelets See **Thrombocytes**.

Serum Blood plasma that does not contain clotting factors but does contain antibodies.

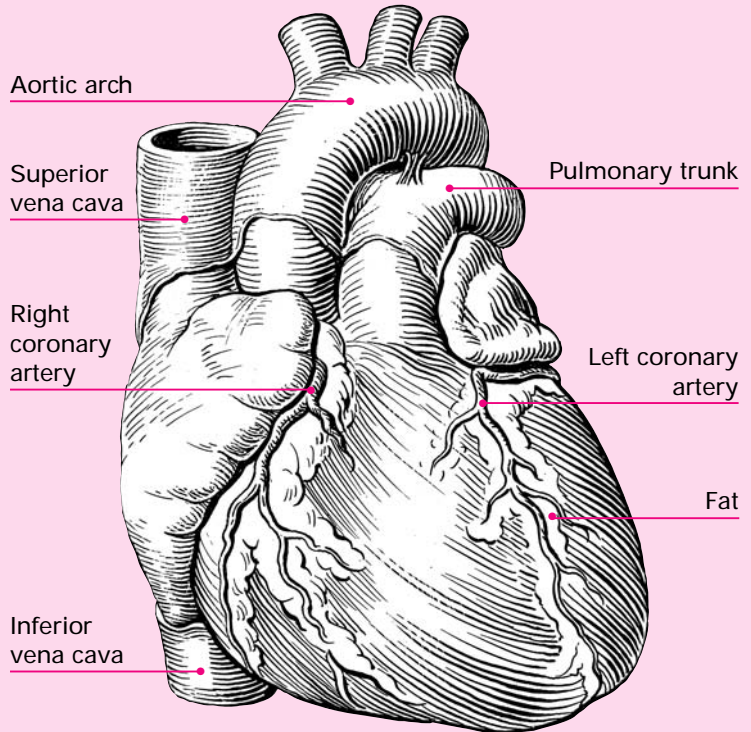
Thrombocytes (or Platelets) Disc-shaped, non-nucleated structures in blood that promote clotting.

Heart blood vessels

The largest arteries of the heart are the aorta, which carries oxygenated blood away from the heart, and the pulmonary arteries, which carry oxygen-poor blood from the heart to the lungs. The largest veins of the heart are the two venae cavae, which drain blood from the body to the heart, and the pulmonary veins, which carry oxygen-rich blood from the lungs to the heart.

Blood from inside the heart cannot seep through to reach the heart muscle, so this has a separate network of vessels called the coronary system, which comes from the aorta.

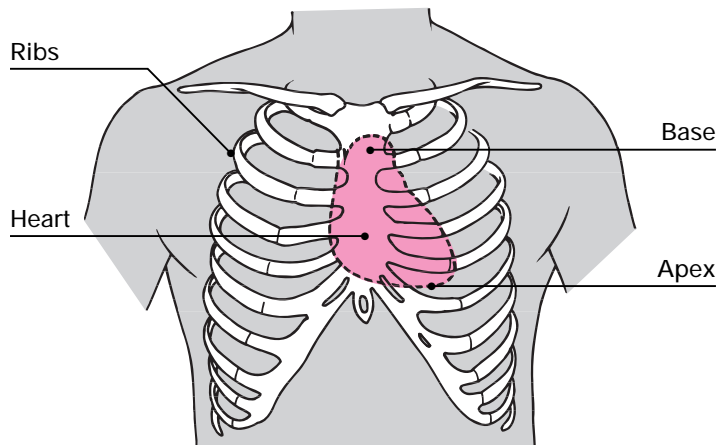
External view of the heart from the front



Heart location

The heart is located in the center of the thorax. Two-thirds of the heart lies to the left of the body's midline. The upper part of the heart (the base) lies just below the second rib, while the bottom of the heart (the apex) is located between the fifth and sixth ribs.

Relative position in thorax



Circulation

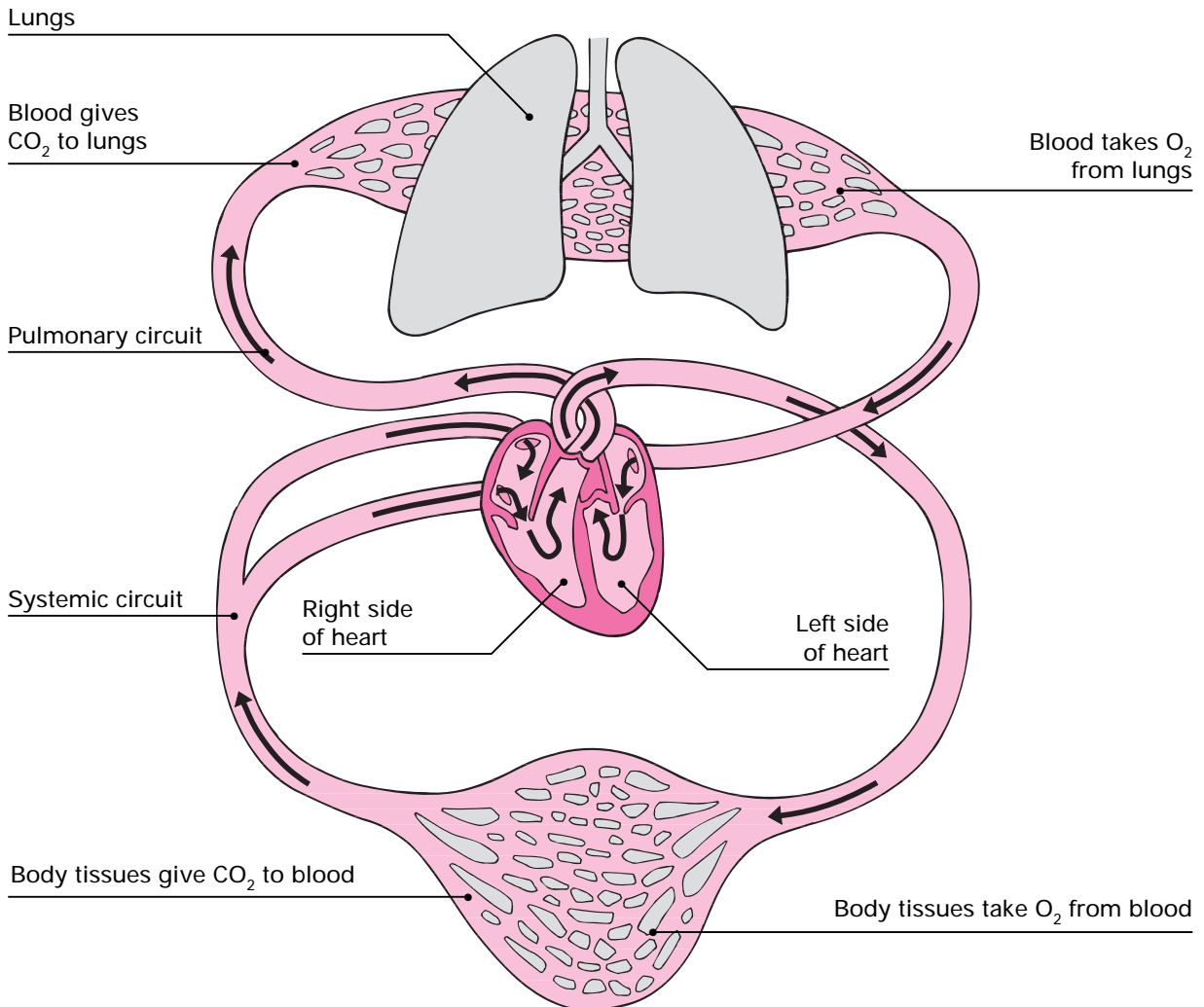
Circulation is referred to as either pulmonary or systemic.

Pulmonary circulation

The right side of the heart pumps blood to the lungs and returns blood to the left side of the heart. This is called the pulmonary circuit. Blood gains oxygen from the lungs and loses carbon dioxide to them.

Systemic circulation

The left side of the heart pumps blood to tissues, which return blood to the right side of the heart. This is called the systemic circuit. Blood in the systemic circuit gives oxygen to tissues and gains carbon dioxide from them.



Arteries

Arteries are the blood vessels that carry blood away from the heart. They branch into smaller vessels called arterioles, which link up with capillaries in the capillary network. The muscular arteries and arterioles can be dilated or constricted by the autonomic nerves supplying smooth muscle. This allows adjustment of blood flow to organs and tissues, such as increased flow to the intestine after a meal.

Major arteries

Carotid artery

Subclavian artery

Pulmonary artery

Coronary artery

Aorta

Hepatic artery

Gastric artery

Renal artery

Iliac artery

Femoral artery

Arteries of brain: side view

Frontopolar artery

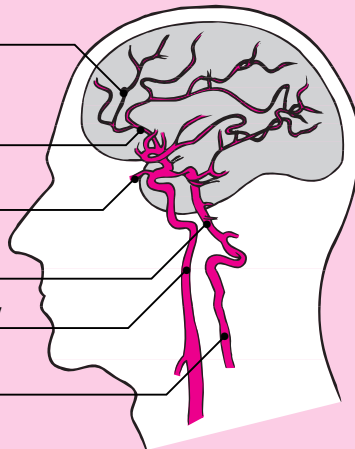
Anterior cerebral artery

Ophthalmic artery

Basilar artery

Interior carotid artery

Vertebral artery



Veins

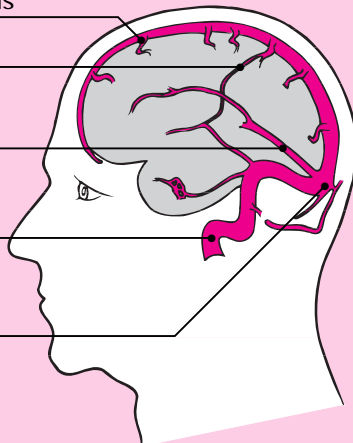
Veins are the blood vessels that carry blood to the heart. They can collapse or expand to accommodate variations in blood flow. Movement relies on the surrounding muscles, which contract and compress the thin walls of the vein. In the capillary network, blood drains into tiny venules, which join together to form veins. Veins become larger and less branched as they move away from the capillaries and toward the heart.

Major veins

Jugular vein
Subclavian vein
Superior vena cava
Pulmonary vein
Cephalic vein
Inferior vena cava
Hepatic vein
Hepatic portal vein
Renal vein
Iliac vein
Femoral vein
Great saphenous vein

Veins of brain: side view

Superior sagittal sinus
Anastomotic vein
Straight sinus
Sigmoid sinus
Confluence of the sinuses



Structure of arteries

Arteries have three layers of tissue in their walls. The outermost layer (tunica adventitia) is made mainly of connective tissue fibers, which reinforce the artery wall. The middle layer (tunica media) is a thick layer of elastic and muscular fibers, which helps the arteries withstand and absorb the waves of pressure created by the heart ventricles pumping blood along them. An inner layer (tunica intima) of flat epithelial cells (endothelium) lines the arteries, as it does the inner surface of the whole circulatory system.

Artery facts

- Blood is pumped into the aorta at a speed of almost a mile an hour (30 to 40 cm/sec).
- The walls of large arteries have their own blood vessels called the vasa vasorum (vessels of the vessels).

Structure of an artery

Lumen (central canal)

Tunica intima (inner layer)

Endothelium of tunica intima

Tunica media (middle layer)

Smooth muscle of tunica media

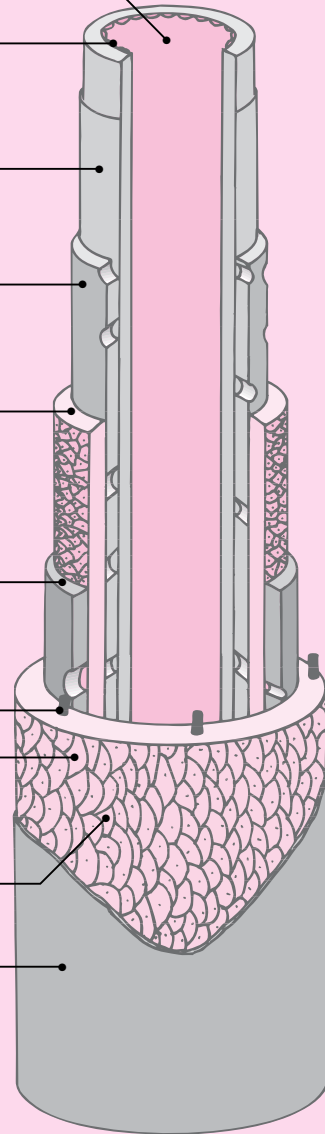
External elastic membrane

Vasa vasorum
(blood vessels of artery)

Tunica adventitia (outer layer)

Cells of adventitia

Fiber covering



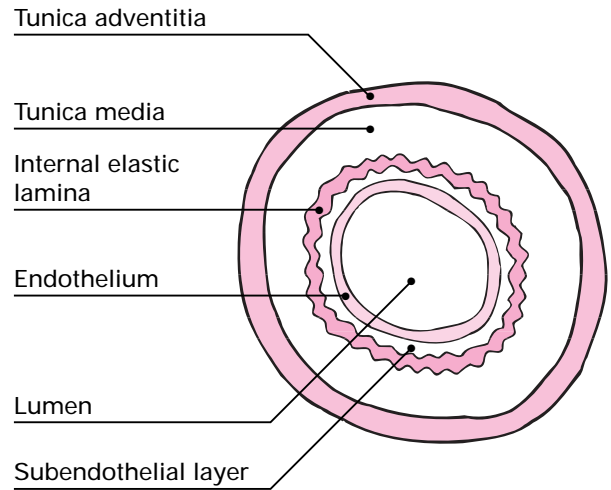
Characteristics of arteries

The blood flowing through arteries is under high pressure, so the arterial walls are thicker and more muscular than the walls of veins. This allows the arteries to expand with the surge of pressure at each heart beat and smooth out the blood flow. Unlike veins, arteries do not need valves to prevent the backflow of blood because the blood flows strongly along arteries in one direction.

Artery facts

- The word "artery" comes from the Greek word for windpipe.
- The pulmonary arteries are the only arteries that transport deoxygenated blood.

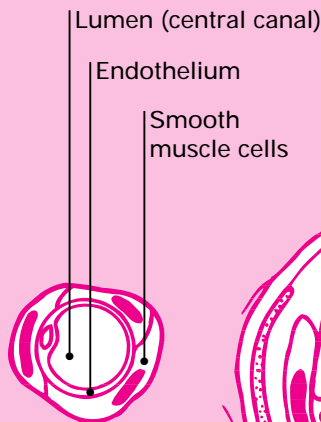
Cross section of an artery



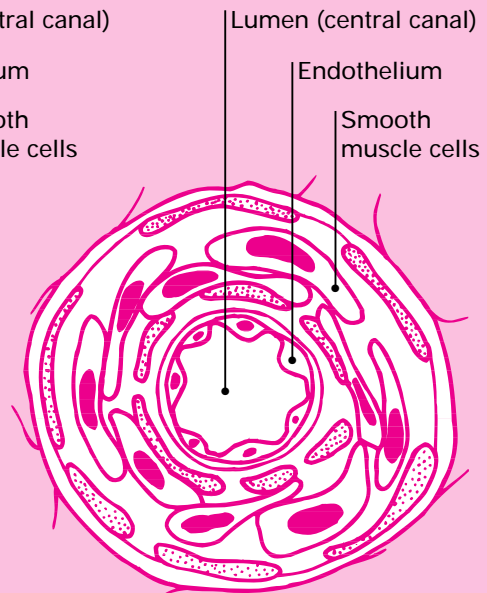
Arteriole structure

Arterioles have three coverings, or tunicae. As their walls contain a large number of smooth muscle cells, arterioles can dilate or constrict more easily than arteries, helping to control the flow of blood into capillaries and organs. An arteriole can dilate to increase blood flow to capillaries by as much as 400 percent.

Cross section of a small arteriole



Cross section of a large arteriole



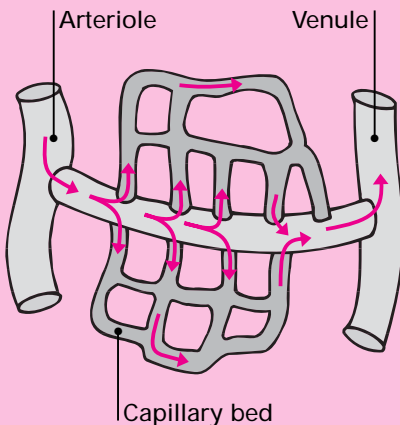
Structure of capillaries

Capillaries are microscopic blood vessels whose walls are extremely thin—usually only one endothelial cell thick. A capillary wall has only one layer, the tunica intima. There are several different types of capillaries, classified according to their structure.

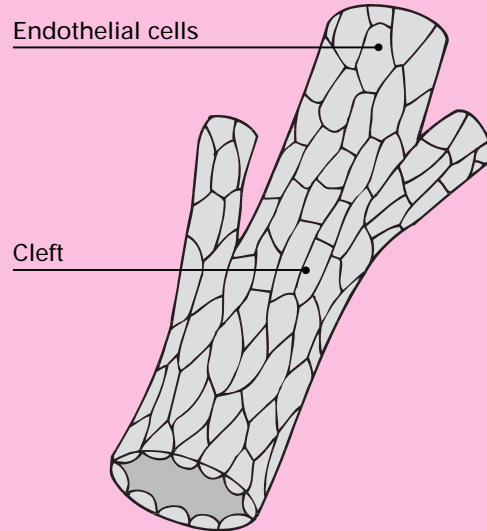
- Continuous capillaries are abundant in the skin and muscles. Their cell walls contain intercellular clefts (gaps).
- Fenestrated capillaries have cells connected by thin membranes called fenestrations (pores).
- Sinusoidal capillaries have fenestrations and a wider lumen than other types. They are modified to allow large molecules to pass between their walls. They are found only in the liver, bone marrow, lymphoid tissue, and some endocrine organs.

The capillary network

The networks of capillaries linking arteries and veins are known as capillary beds. Each capillary bed provides a link between many arterioles and venules.

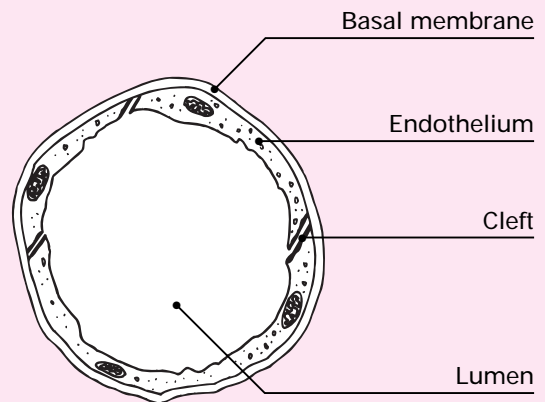


Capillary external structure



Cross section of a capillary

A continuous capillary, showing the clefts, or gaps, between endothelial cells.

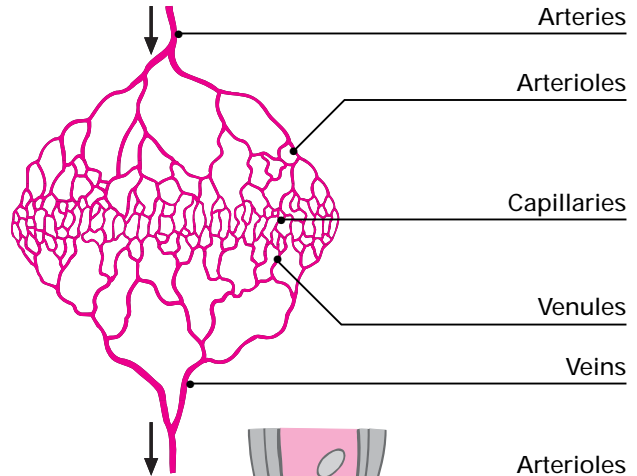


Functions

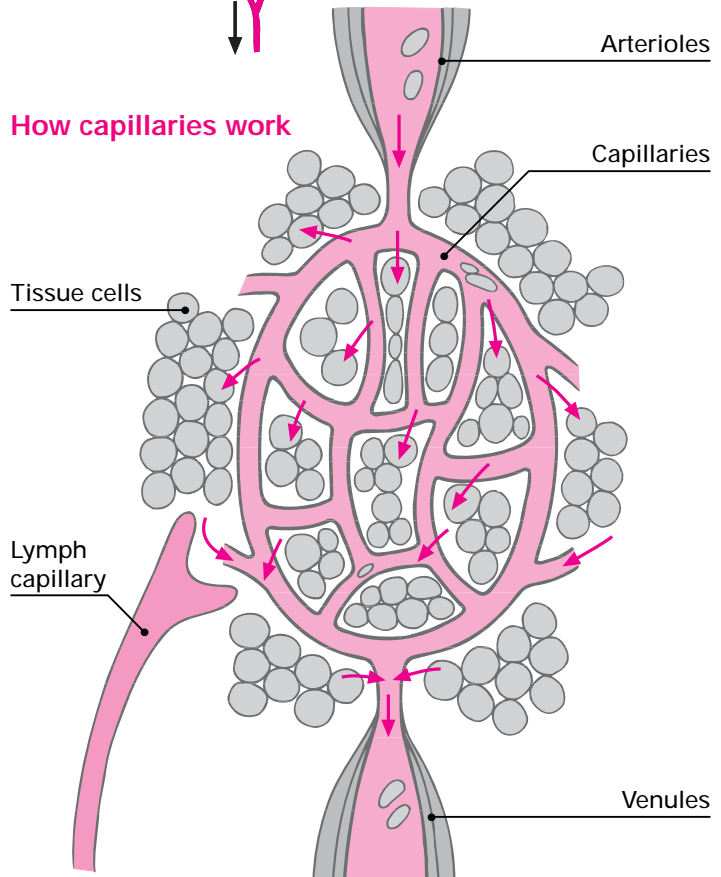
Capillaries link arteries and veins and also assist with the exchange of gases, nutrients, and waste products between the blood and body tissues. Substances pass through the capillary wall by a variety of processes, such as diffusion, osmosis, and filtration. Blood stays in the capillaries for only a second or so but as the capillaries are very short, this is long enough for the exchange of substances.

Oxygenated blood arrives at the capillary bed from arterioles and delivers oxygen and nutrients to cells. Waste products (such as CO_2) pass out of cells and into capillaries. Deoxygenated blood in capillaries is then transferred to venules to be transported out of the area.

Capillary network supplied by several arteries



How capillaries work



Capillary facts

- If all the capillaries in an adult body were connected, they would stretch about 60,000 miles (96,000 km).
- Capillaries are about 600 times narrower than a medium vein.

Structure of veins

The walls of veins have the same three layers as arteries but the middle layer, the tunica media, is much thinner. The outer layer, the tunica adventitia, is the thickest layer in veins but is thinner than the tunica media in arteries. Veins usually contain valves to prevent the backflow of blood. These valves are formed from folds of the innermost layer, the tunica intima. They are especially abundant in the legs, where blood has to overcome the downward pull of gravity to return to the heart.

Vein facts

- Most veins carry deoxygenated blood but the four pulmonary veins carry oxygenated blood.
- The largest veins, the venae cavae, are named after the Latin "cava," meaning cavern, because of their great size.
- Like arteries, veins have their own blood vessels, small vasa vasorum.

Structure of a vein

Lumen (central canal)

Tunica intima (inner layer)

Valves

Endothelium of tunica intima

Tunica media (middle layer)

Smooth muscle of tunica media

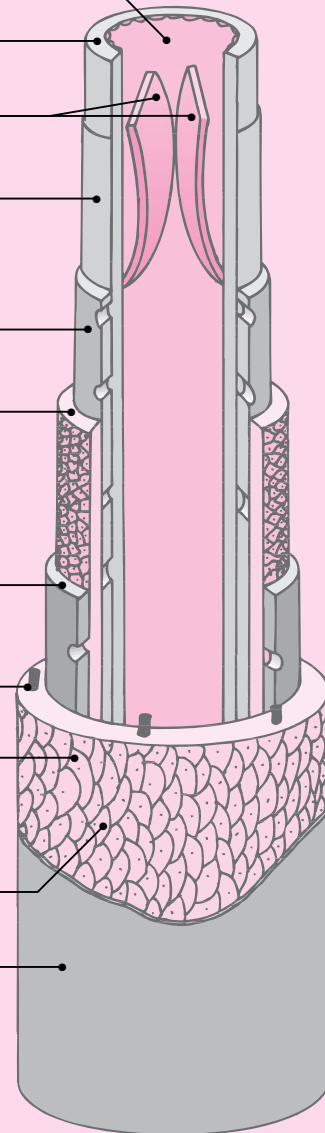
External elastic membrane

Vasa vasorum
(blood vessels of artery)

Tunica adventitia (outer layer)

Cells of adventitia

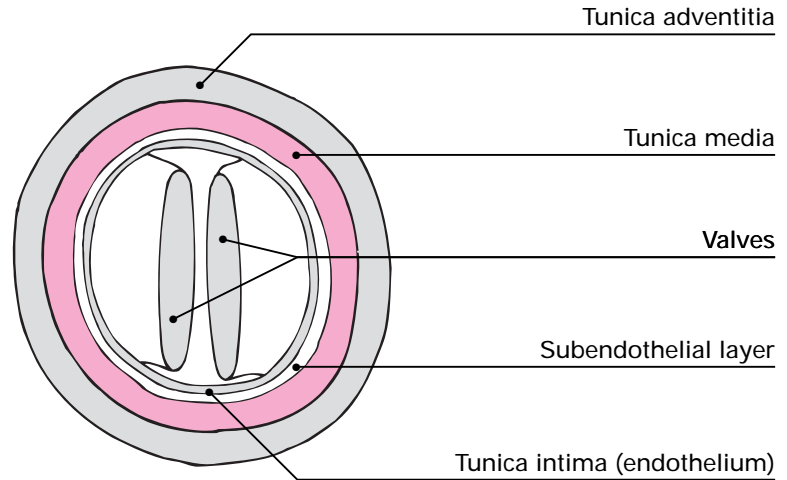
Fiber covering



Characteristics of veins

The blood flowing through veins is at low pressure and flows slowly. Veins are more flexible than arteries and they collapse if blood pressure is not maintained. Many veins are sheathed in skeletal muscle that contracts to compress the walls of the veins and drive blood toward the heart. Valves ensure the correct direction of flow. They swing open for each pulse of blood, then flap shut to prevent backflow.

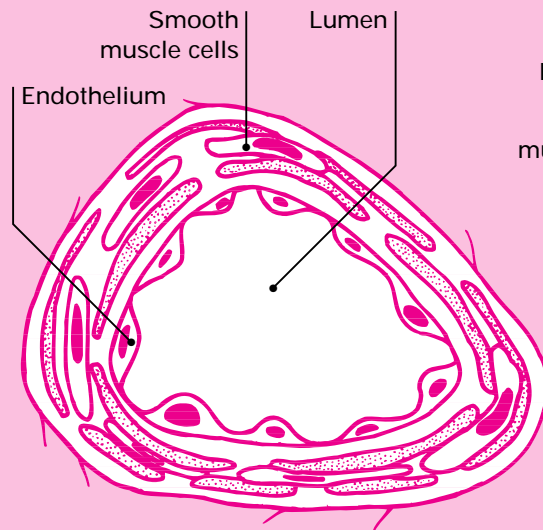
Cross section of a vein



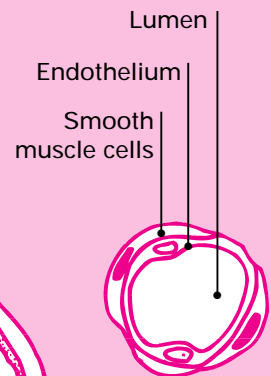
Venule structure

Venules are tiny veins that link up with capillaries and drain blood from them. Those venules nearest to capillaries consist mainly of endothelium and a thin outer layer, called the tunica adventitia. These venules are easily affected by inflammation and allergic reactions. They eventually unite to form larger venules with a thin middle layer as well.

Cross section of a large venule



Cross section of a small venule



Measuring blood pressure

Blood pressure is the pressure or push of blood against the walls of blood vessels. Blood flows along a pressure gradient (from higher to lower pressure) and this keeps blood flowing. Blood pressure is measured using two instruments simultaneously, a sphygmomanometer to measure blood pressure, and a stethoscope to listen to the sound of blood as it pumps through the brachial artery in the arm. The sphygmomanometer records pressure in “mm Hg” (millimeters of mercury). For example, a blood pressure of 110 mm Hg is equal to the pressure exerted by a column of mercury 110 mm high.

Types of blood pressure

Two types of blood pressure are measured.

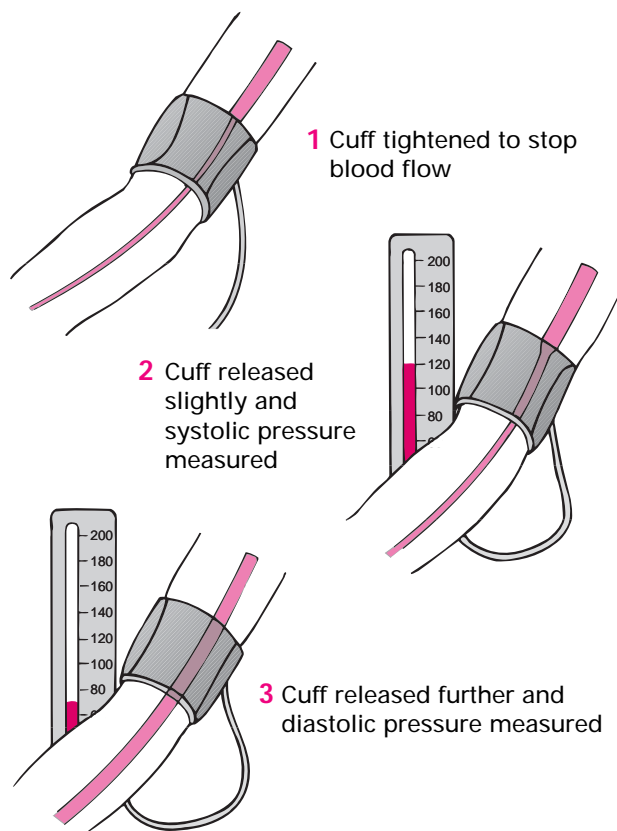
- Systolic pressure is that pressure exerted on the walls of the aorta leading directly from the heart and other large arteries. It is produced when the heart contracts (beats).
- Diastolic pressure is the pressure that can be measured when the heart relaxes between beats.

Blood pressure readings

“Normal” blood pressure is around 120/70—i.e., a systolic reading of 120 mm Hg and a diastolic reading of 70 mm Hg. Many factors affect blood pressure, however, and a healthy adult can have a reading that varies greatly from this figure.

1 The cuff of the sphygmomanometer is inflated until it is tight enough to stop the flow of blood in the brachial artery. At this point, pressure on the cuff is greater than pressure in the artery and no sounds can be heard through the stethoscope.

2 Pressure in the cuff is gradually released until the blood is able to flow into the



constricted artery. It is at this point that the blood can be heard pumping and a measurement of systolic pressure is taken. Usually this is when the sphygmomanometer mercury level reads about 120 mm Hg.


3 Pressure in the cuff is reduced further until the blood is able to flow freely through the artery. The point at which blood is able to flow freely is indicated by muffled sounds through the stethoscope. This is a measure of diastolic pressure, often around 70 mm Hg.

Blood pressure fact

- Blood pressure is higher in the feet than in the arms because of gravity.

The pulse

Your pulse is the measure of your heartbeat—its speed, strength, and regularity. The best place to feel the pulse is at the wrist. You should learn to take your pulse there in order to assess your fitness and also as a check against exercising too strenuously. This method of taking your pulse is described to the right. The pulse test shown below is an excellent way of checking a fitness program. If you do the test every two weeks, and plot the results on a graph, you will be able to see how your fitness is improving.

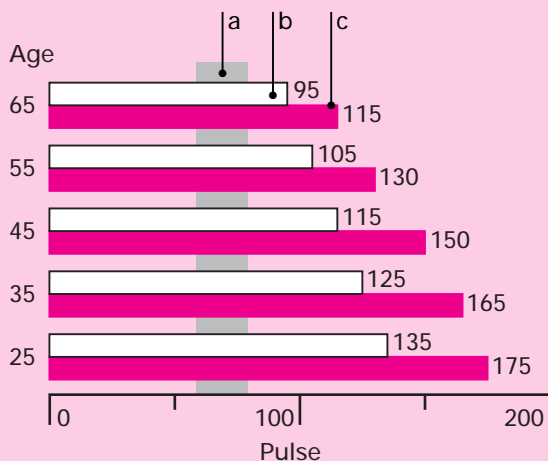
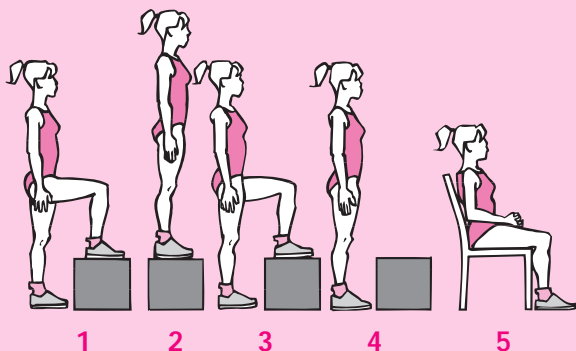


Taking your pulse

The illustration above shows the place on the wrist where the pulse is most easily felt. Place the first three fingers of your right hand on the inside of your left wrist, and count the number of beats for 30 seconds. Multiply by two for the rate per minute.

Pulse test (below)

- 1** Step up with one foot onto a bench or low chair about 16 inches (41 cm) high.
- 2** Bring the other foot up onto the top of the bench.
- 3** Step down again with one foot.
- 4** Bring the other foot down to the floor. Repeat 24 times a minute for two minutes.
- 5** Sit down for two minutes, then take your pulse and record the result.



Pulse rates (above)

This diagram shows a selection of maximum recommended pulse rates for various ages. (a) shows the typical pulse range for people at rest; (b) shows pulse ratings by age for people unused to exercise; and (c) shows the maximum levels to which you should raise your pulse when you are fitter.

Regular, sensible exercise is one of the greatest gifts that you can give your heart. Of course, a heart unused to exertion should not be subjected to sudden or strenuous exercise as this can be dangerous. The level and intensity of exercise should be increased only gradually, over several weeks, as you feel yourself becoming fitter and more capable.

Good and bad lifestyles

The age of convenience has removed many of the natural exercise activities from our lives. Automobiles, trains, and airplanes have taken the time and effort out of travel, and electric tools and gadgets have reduced the amount of time spent in manual labor. Television has brought an enormous increase in sports spectatorship rather than participation, and the pollution and overcrowding of more urban environments has made walking a far less appealing exercise than it used to be. Despite the recent crazes for jogging, health clubs, and so on, the population in general has become more and more sedentary.

Medical advice and self-care

If you are middle-aged or elderly, or if you have been unused to exercise for several years or longer, then it is strongly advisable to consult a doctor before embarking on exercise of any sort. He will confirm that you are in a suitable condition to begin exercising, and will advise you on how quickly or how slowly to increase your level of exercise. You should also look after yourself by losing any excess weight and by making sure that you do not exercise too strenuously if you are overweight. It is advisable to check your pulse regularly so that you do not exceed the recommended maximum for your age and fitness level—you can do this by referring to the pulse diagrams that appear on page 23.

Exercise in daily activities

Your daily routine can be altered to provide many opportunities for exercise. Instead of taking the car to work, try walking or cycling; if you take a bus or train, get off a couple of stops early and walk the rest of the way. Use stairs rather than the elevator. Use your lunch hours for walking rather than just eating, drinking, and sitting around. Join a sports club with members of your family or friends, and encourage one another to play regularly. Avoid drinking alcohol and smoking, so that the good you are doing your body by exercising is not counteracted.

How to tackle exercise

Set aside regular times to exercise, otherwise the activity will be squeezed out of your routine. Choose an exercise that you enjoy; the exercise time should be a pleasure, not an endurance test. Take regular rests during your exercise period, especially in the early weeks, and check your pulse; if you are near your maximum rating, stop for a while until your pulse slows, and then continue.

Remember that all exercise activities should be built up very slowly over a few weeks. Never exercise to the point of exhaustion. Stop at once if you feel faint, dizzy, or sick; if you become pallid or very short of breath; if you get spots before the eyes; or if you experience pains in the chest or head.

Always precede and follow an exercise session with gentle calisthenic, or mobility, exercises, such as bending and stretching. These exercises allow the blood flow to speed up and slow down gradually. This protects the heart from strain and stops the blood from “pooling” in the legs when exercise has stopped but the heart is still pumping strongly. It is unwise to drink very cold drinks or take a cold shower immediately after exercising as the shock to the body can strain the heart.

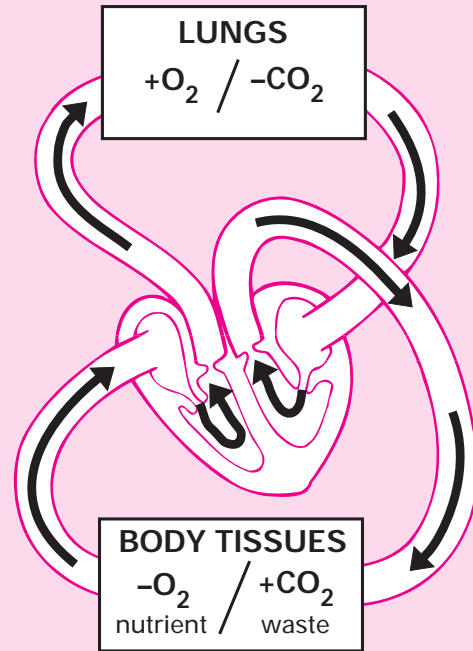
Helping the heart

Exercise strengthens the muscular walls of the heart so that they pump blood more efficiently and the general blood circulation improves. This enables the body's other muscles to work harder, because more oxygen is reaching them and the waste substances that they produce are being dispersed more rapidly. As a result, a person who exercises regularly feels fitter and more capable of exertion.

Aerobic exercises, those that take extra air into the lungs, are excellent for strengthening the heart and providing the blood with plenty of oxygen. Such exercises include: brisk walking, jogging, swimming, cycling, jumping, or skipping. More strenuous aerobic activities include racket sports and cross-country skiing.

Circulation and exchange


Lungs—oxygen passes into blood in exchange for carbon dioxide.



Body tissues—carbon dioxide and waste products—pass into blood in exchange for oxygen and nutrients.

The fit and unfit heart

The fit heart is an efficient heart. It only has to pump the blood slowly as it is pumping a large volume at one time, and also pumping it strongly. The normal pulse of a trained endurance runner may be as low as 40 beats per minute. The unfit heart, on the other hand, is an inefficient heart. It has to pump the blood rapidly as it pumps a small volume of blood at a time and its pumping action is poor. The pulse rate of a sedentary worker can be as high as 80–90 beats per minute.



Blood disorders

Agranulocytosis A condition in which blood lacks granulocytes, the white blood cells that protect the body against bacterial infections. It is a result of a defect in bone marrow.

Anemia A condition in which the blood has an abnormally low ability to carry oxygen. There are many different types, including aplastic anemia (the destruction of red bone marrow resulting in the production of fewer blood cells); hemolytic anemia (blood cells are damaged through bacterial infection, for example); hemorrhagic anemia (blood is lost through a wound, for example); iron-deficiency anemia (resulting, for example, from an inadequate intake of iron-rich food or an inability to absorb iron efficiently); pernicious anemia (lack of vitamin B₁₂ causes red blood cells to swell, reducing their oxygen-carrying capacity); and sickle-cell anemia (red blood cells become crescent shaped and rupture easily).

Erythroblastosis fetalis A rare blood disease of the newborn that can result in the destruction of red blood cells. It is caused by the mixing of bloods of different Rhesus (Rh) groups.

Erythroedema A condition, also known as acrodynia or pink disease, that causes a mild fever, restlessness, weakness, and redness of the face, fingers, and toes. It is usually caused by a poisoning of the blood by minerals used in medicines such as laxatives. It is mostly restricted to children and is now rare.

Hemophilias Several different bleeding disorders caused by lack of the factors necessary for blood clotting. They are

hereditary diseases transmitted by unaffected mothers (carriers) almost always to sons.

Infectious mononucleosis (glandular fever) A contagious disease caused by a virus that affects white blood cells.

Leukemia (cancer of the blood) An increase in the number of white blood cells that interferes with normal body processes. There are different types of leukemia, named according to which of the many white blood cell types are affected. Lymphocytic leukemia, for example, affects lymphocytes.

Leukopenia A decrease in the number of white blood cells.

Multiple myeloma A tumor of the bone marrow that adversely affects production of new red and white blood cells.

Polycythemia An abnormal increase in the number of red blood cells, which causes the blood to flow sluggishly. There are two types: non-specific and that caused by too little oxygen in the blood. The latter is usually associated with a respiratory disorder often caused by smoking.

Rhesus disease A condition in which red blood cells are destroyed as a result of the mixing of bloods of incompatible groups. The Rhesus factor is a substance present in red blood cells of most people (Rhesus positive, or Rh+). People who lack the factor are Rhesus negative, Rh-.

Septicemia Blood poisoning caused by bacteria or the toxins they produce. In some cases, it can be fatal.

Thrombocytopenia A deficiency in blood platelets (which help the clotting process) resulting in bleeding from small vessels.

Heart disorders

Angina pectoris Condition characterized by pain in the chest and sometimes left arm, especially during times of stress or exertion.

Arrhythmia Abnormal heart rate or rhythm: tachycardia (faster than normal heart rate) and bradycardia (slower than normal heart rate).

Cardiac arrest The heart ceases to beat effectively.

Cardiomyopathy A disease of the heart's muscle that results in a decrease in the efficiency with which it contracts and circulates blood.

Carditis Inflammation of the heart.

Congenital heart defects Heart defects in newborn babies.

Constrictive pericarditis The pericardium (lining) of the heart is scarred or diseased, preventing the heart from expanding properly.

Coronary artery disease Causes a reduced supply of oxygen and other nutrients to the main heart muscle.

Coronary heart disease Usually referred to as coronary artery disease.

Fibrosis of cardiac muscle Scarring of heart muscle.

Myocardial infarction Commonly called heart attack, a condition in which obstruction of blood flowing to the heart muscle results in tissue death. It is most often caused by atherosclerosis.

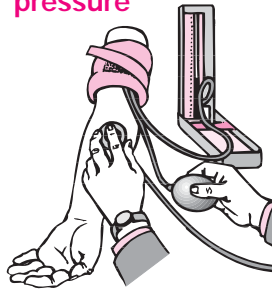
Myocarditis Inflammation of the myocardium (main heart muscle) that can weaken the heart, impairing its function.

Palpitations Sensation of a heartbeat that is rapid or irregular in some way.

High and low blood pressure

Both high and low blood pressure are bad for the body's circulation. High blood pressure (hypertension) can cause blood vessels to rupture. If this happens in the brain, it causes a stroke. High blood pressure may be an inherited problem, but it is also related to factors such as stress, obesity, a diet that is high in salt and saturated fats, aging, and a lack of physical activity. Low blood pressure (hypotension) can also be dangerous. If the pressure in the arteries falls low enough, blood stops circulating. Massive bleeding, or hemorrhage, causes death in this way.

Taking blood pressure



Recovering from a faint

Fainting

This happens when the brain is briefly starved of oxygen. It can occur through shock, or fear, on jumping up after kneeling, after a long soaking in a hot bath, or in early pregnancy. Warning signs are turning pale, a cold sweat on the face, dizziness, and nausea. If you feel dizzy and about to faint, sit with your head between your knees as shown in the diagram above right. This improves blood flow to the brain and should prevent actual blackout. If a person does faint, lie him or her down with the feet raised and loosen tight clothing around the neck, chest, and waist. Recovery takes no more than a minute or two.

The heart is the core of the cardiovascular system. This double pump beats automatically, night and day, to keep blood circulating around the body. A heart “beat” is a sudden tightening of the muscle in the walls of the heart. This squeezes blood out of the heart chambers and into the blood vessels. A specialized type of heart muscle called myocardium gives the heart its special pumping ability.

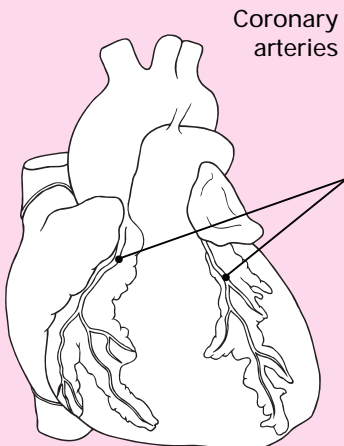
Heart facts

- The average adult human heart is five inches long and three inches wide (12 cm by 9 cm). It measures two and a half inches (6.3 cm) from front to back.
- An adult's heart weighs about 10.5 ounces (300 g).

Blood for the heart

The heart muscle needs a generous supply of oxygen to keep it working efficiently. This oxygen is delivered by the two coronary arteries, which cover the surface of the heart with a network that looks rather like a crown. The term “coronary” comes from the Latin word “coronarius,” meaning “belonging to a crown or wreath.” Structures and events involving the heart often make use of the word “coronary.”

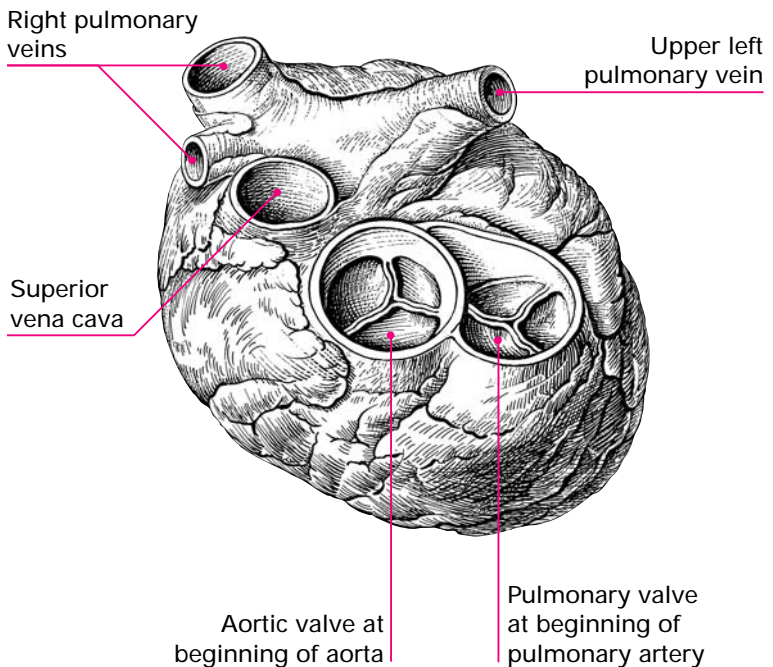
Front view



Heart valves

Working within the heart muscle are valves that allow blood to flow through the heart in only one direction. The heart valves also prevent the backflow of blood in the major arteries and veins.

Heart from above



Arteries and veins of the heart

The largest arteries and veins of the heart form the beginning of the pulmonary (lung) and systemic (body) circulations. Two large veins called venae cavae drain oxygen-poor blood from the body to the heart. The pulmonary arteries carry this blood from the heart to the lungs. The pulmonary veins carry oxygen-rich blood from the lungs back to the heart. The aorta then carries this oxygen-rich blood to the body.

Heart facts

- The heart beats some two and a half billion times during a 70-year lifetime.
- About five percent of all the blood pumped by the heart goes to its own muscle tissue.
- The heart pumps roughly 3,000 gallons (11,356 l) of blood in a day.

Heart from behind

Left subclavian artery

Left common carotid artery

Innominate (brachiocephalic) artery

Aortic arch

Superior vena cava

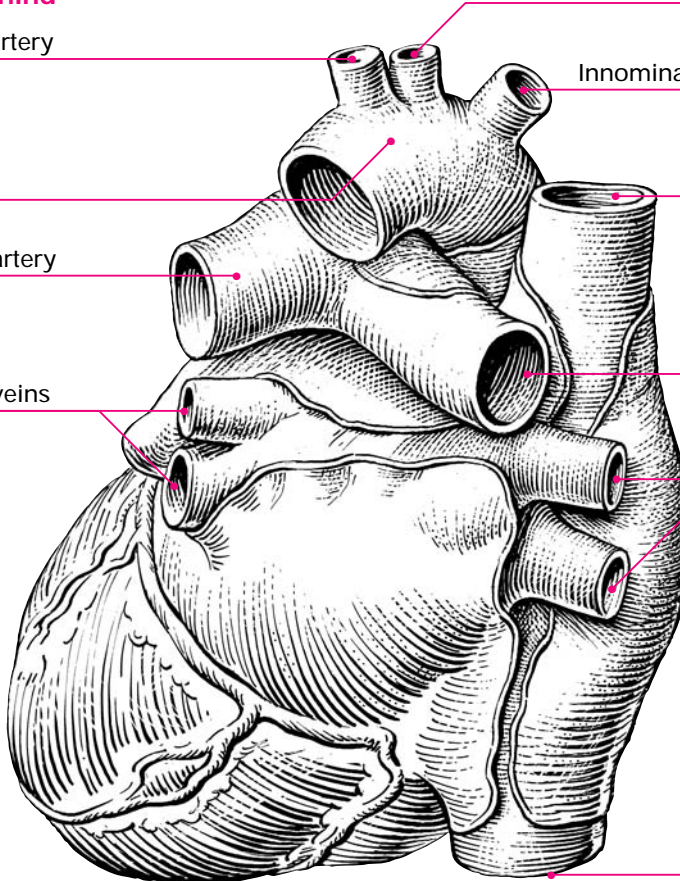
Left pulmonary artery

Right pulmonary artery

Left pulmonary veins

Right pulmonary veins

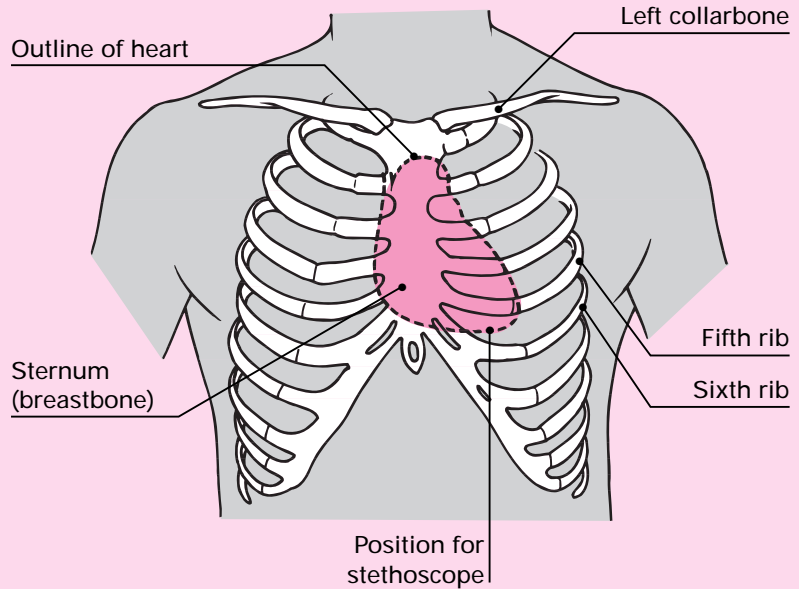
Inferior vena cava



Heart beats

To listen to the heart beating, doctors and nurses position a stethoscope between the fifth and sixth ribs on a line leading down from the middle of the left collar bone. This area is directly over the apex of the heart, which moves forward when the heart ventricles contract and strikes the wall of the thorax. This can be felt from the outside of the chest as a heartbeat.

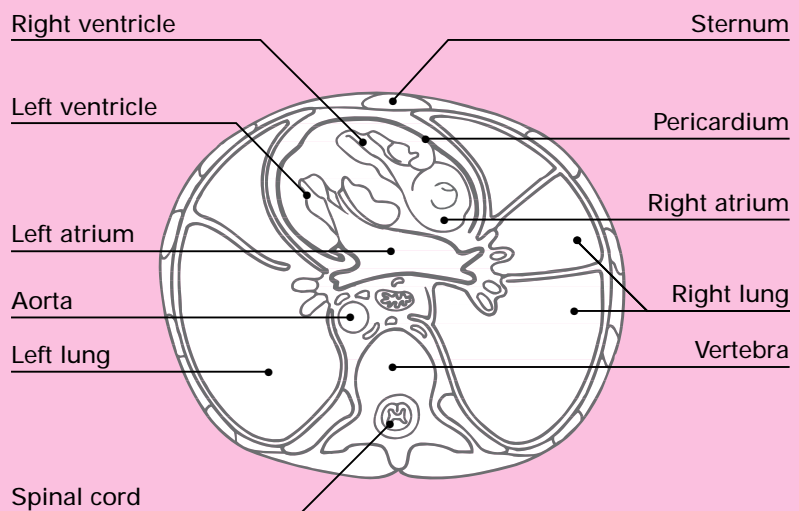
The heart and ribs



Position of the heart

The heart lies in the thoracic cavity, which is sandwiched in between the breastbone in front and the thoracic vertebrae behind. By pressing rhythmically on the lower part of the breastbone with the heel of the hand, it is possible to compress the heart in order to maintain blood flow if the heart stops beating. This technique can help to save a person's life.

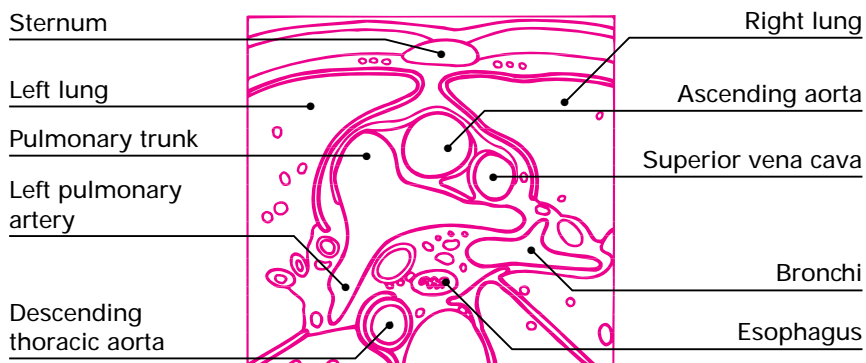
Cross section at level of 8th vertebra



Organs and blood vessels in and around the heart

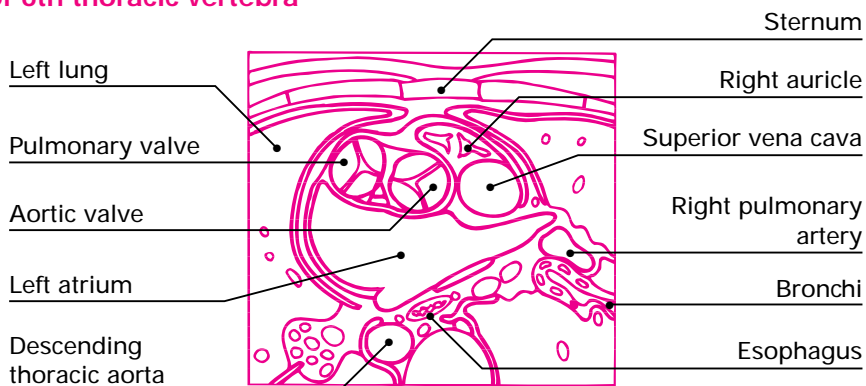
Cross section at level of 5th thoracic vertebra

The heart lies in between the two lungs and in front of the descending aorta and the esophagus. Above the heart there are the ascending aorta, the superior vena cava, and the pulmonary arteries



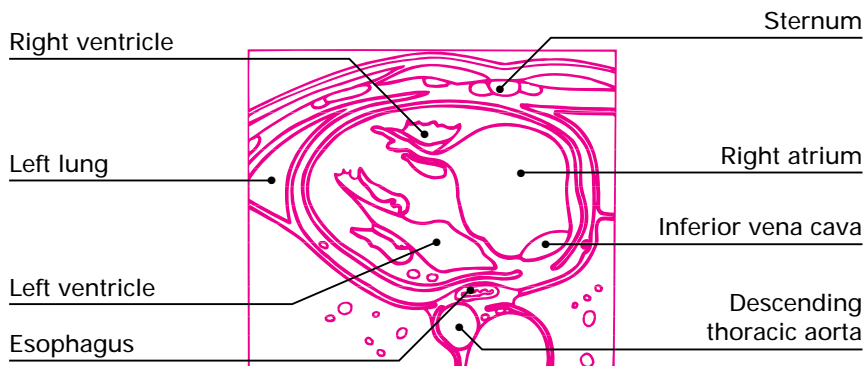
Cross section at level of 6th thoracic vertebra

The heart is positioned closer to the front of the thoracic cavity than to the back, directly behind the sternum. The heart's apex is located on the diaphragm below.



Cross section at level of 7th thoracic vertebra

The right ventricle (lower chamber) of the heart is located partly in front of the left ventricle. The left ventricle faces toward the left side and the back of the thorax.



Heart's pumping power

The middle layer of the heart's wall is a thick layer of heart, or cardiac, muscle, known as myocardium ("myo" means muscle). The myocardium consists of three spiral layers of cardiac muscle attached to a framework of dense fibrous tissue that forms the "skeleton" of the heart. The spiral is the best arrangement for squeezing blood out of the heart's chambers. The thickest heart muscle is in the wall of the left ventricle, which pumps blood all the way to the fingers and toes and back again. The right ventricle only has to pump blood to the lungs, so its walls are less than

half as thick as those of the left ventricle. The atrial walls have much less muscle than the ventricle walls and so are quite thin. The left atrial wall is, however, thicker than the right atrial wall. Rings of cardiac muscle around the tricuspid and mitral inlet valves lock them tightly shut when the ventricles pump blood to the body and lungs.

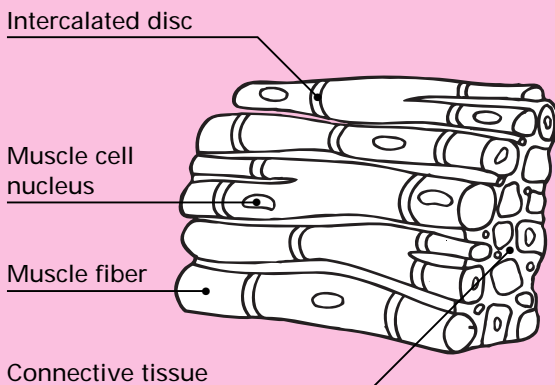
Cardiac muscle contains bundles of actin and myosin filaments and contracts in the same way as other body muscles. But it differs from other muscles in the way that nerve signals travel through the fibers and stimulate the muscle to contract.

Heart muscle structure

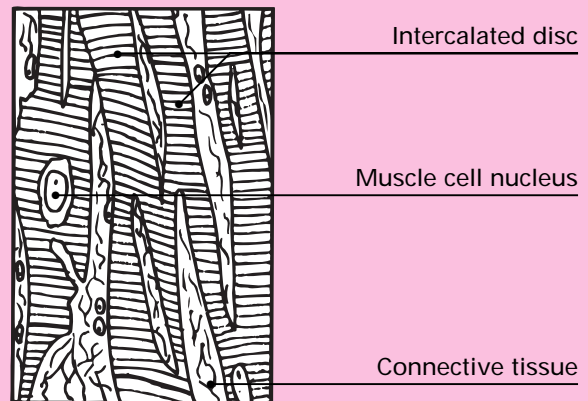
Cardiac muscle is different from the other two types of muscle in the body. It has stripes, like skeletal muscle, but works as a coordinated unit, rather than as a group of separate units, as skeletal muscle does. Cardiac muscle cells act

together because they are connected by intercalated discs. These electrical connectors allow nerve impulses to travel through the heart without stopping.

Cardiac muscle fibers



Longitudinal section of cardiac muscle



Coronary vessels

Blood flows into the heart muscle through the right and left coronary arteries. These arteries branch off the aorta behind the flaps of the aortic semilunar valve. Coronary veins drain deoxygenated blood from the heart muscle into the right atrium of the heart.

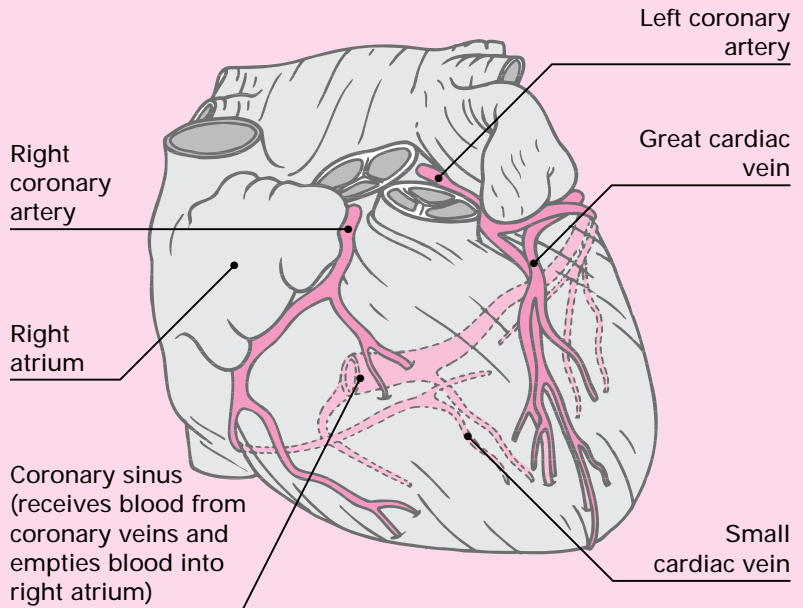
Automatic heart

Heart muscle responds to the autonomic or involuntary nervous system, as well as to its own internally generated electrical commands. It is not under conscious control, and works automatically, like the smooth muscle that lines the stomach and other internal organs.

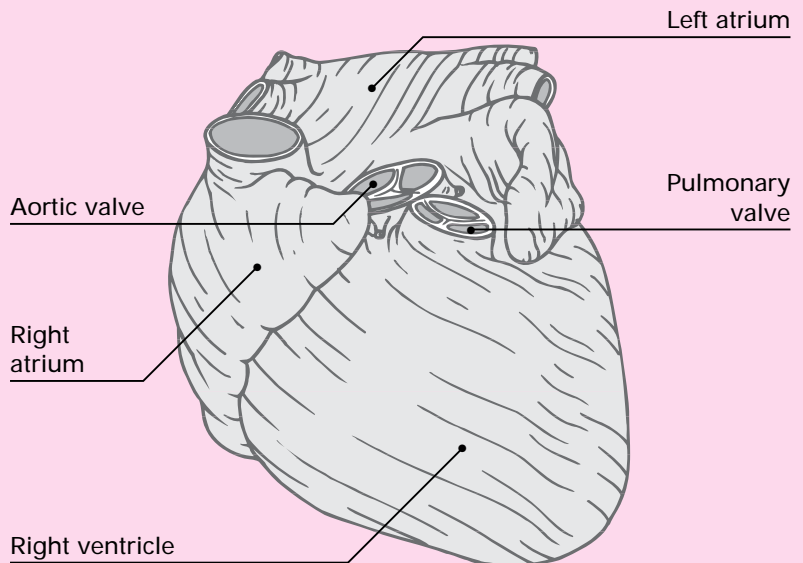
Muscle facts

- The fibrous skeleton of the heart, together with the valves inside the heart, make up about half of the heart's weight.
- The wall of the left ventricle is up to half an inch (1.3 cm) thick in some places.

Front view showing coronary vessels



Front view showing heart muscles

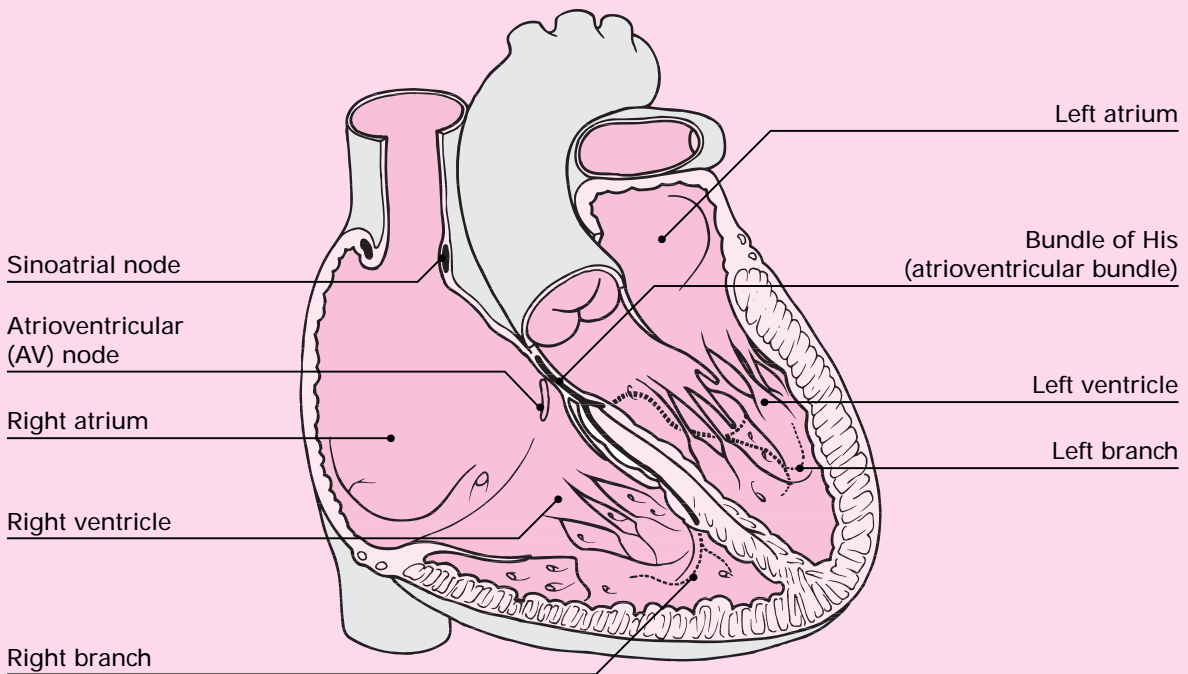


The heart's conduction system

The heart muscle has the ability to contract rhythmically on its own. Like other muscles, it requires an electrical impulse (signal) in order to do this. Although the rate at which the heart

beats is controlled by signals from the autonomic nervous system, the heart has its own built-in conduction system for generating impulses and coordinating contractions.

Section showing impulse-conducting system



Factors affecting stroke volume

The amount of blood pumped by a ventricle each time it contracts depends on the amount of blood in it and the force of the contraction. These are affected by a number of factors.

Activity Exercise increases the speed of blood returning to the heart, which in turn increases the stroke volume.

Injury Severe blood loss causes stroke volume to decrease.

Disease Because the heart is a muscle it is prone to disorders and disease in the same way other muscles are, and this can affect its size and ability to contract.

Factors affecting heart rate

The rate at which a heart beats is affected by a variety of factors.

Body temperature Higher body temperature results in an increased heart rate; a lower body temperature reduces the heart rate.

Emotions Excitement, anger, anxiety, and fright, for example, all cause the heart to beat faster. Depression and grief can decrease the heart rate.

Chemicals Chemicals present in the blood (such as hormones) affect the heart rate, as do chemicals taken as drugs.

Age Our resting heart rates gradually slow down as we get older.

Gender Men tend to have lower heart rates than women, with 70–72 beats per minute compared to 78–82 for women.

Activity Vigorous exercise, for example, increases the heart rate; during periods of relaxation the heart rate slows down.

Physical condition The resting heart rate of people who exercise tends to be lower than that of the inactive.

Blood pressure Stimuli affecting blood pressure in general also affect heart rate.

Heart disease Various diseases and disorders of the heart can affect heart rate.

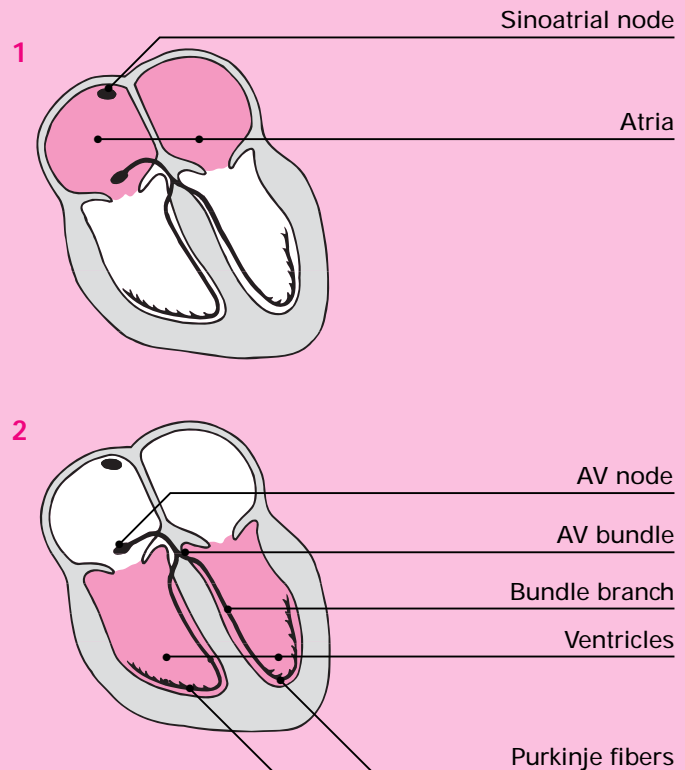
How contractions occur

Four structures in the heart wall generate strong impulses and conduct them rapidly to certain regions of the heart wall.

1 An impulse is generated and conducted by the sinoatrial node (the heart's pacemaker). This spreads through the atria, causing them to contract.

2 At the AV node, the impulse is relayed via the AV bundle, bundle branches, and Purkinje fibers to the ventricles. This causes the ventricles to contract.

In this way, contraction of the atria is always followed by contraction of the ventricles. This synchronization forces the heart to beat faster and more efficiently.

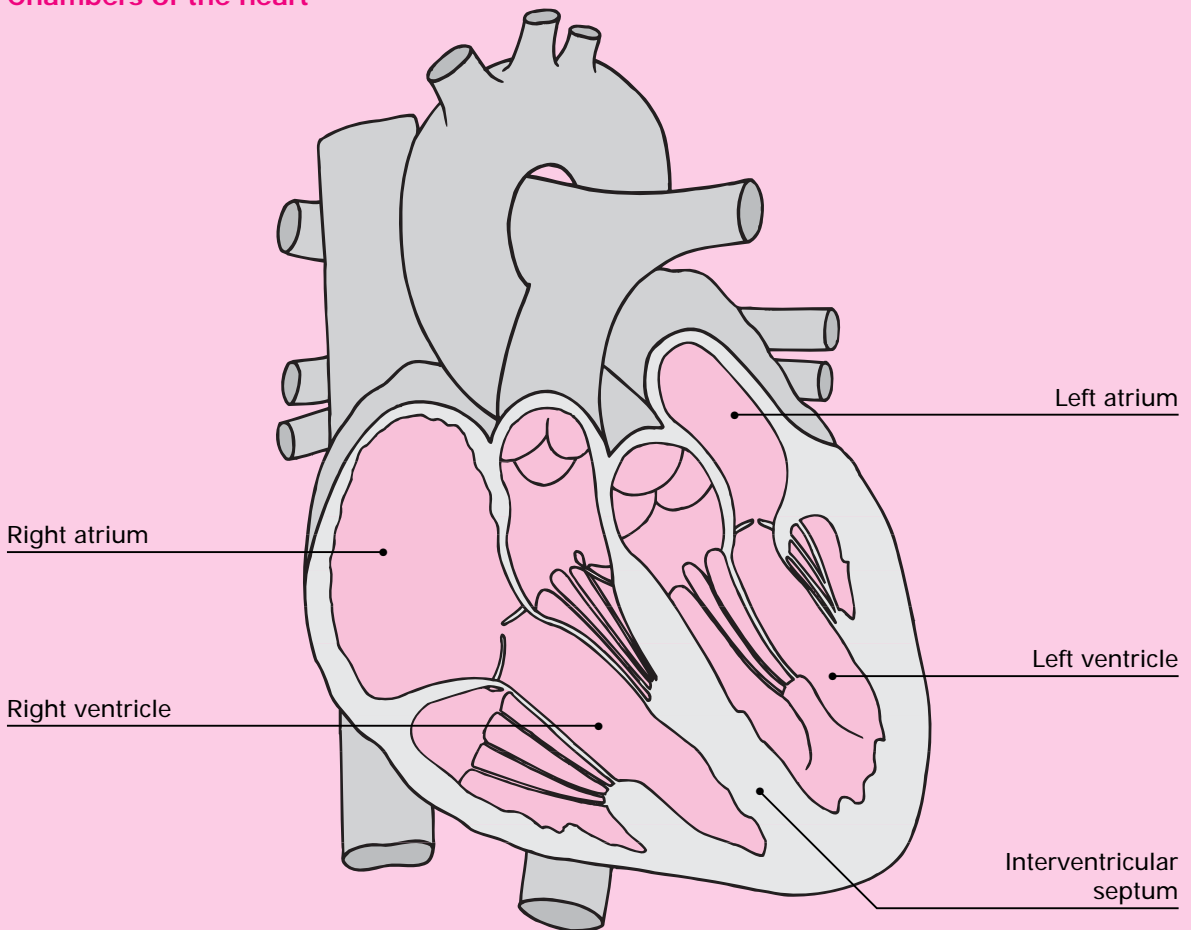


Atria and ventricles

The heart is a hollow organ that contains four chambers. A wall of muscle called the septum divides the heart into right and left sides. The four chambers are the right atrium, the left atrium, the right ventricle, and the left ventricle. The atria are often called

receiving chambers, because they receive blood. The two ventricles are larger than the two atria. Their walls are also thicker and more muscular because they are responsible for the pumping action of the heart. The ventricles are sometimes called discharging chambers.

Chambers of the heart

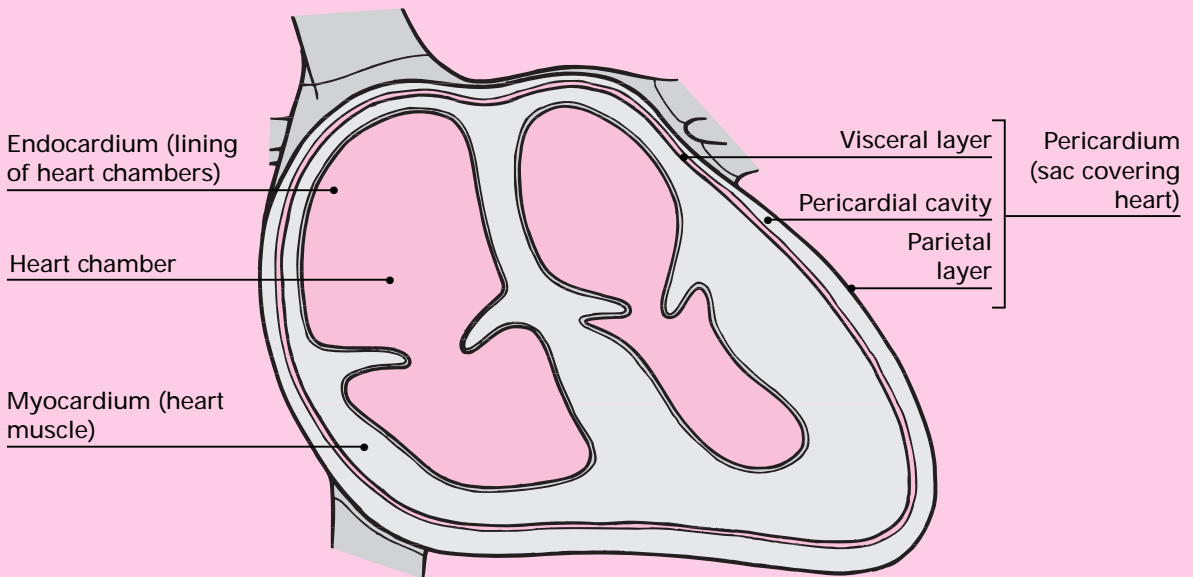


Coverings and linings

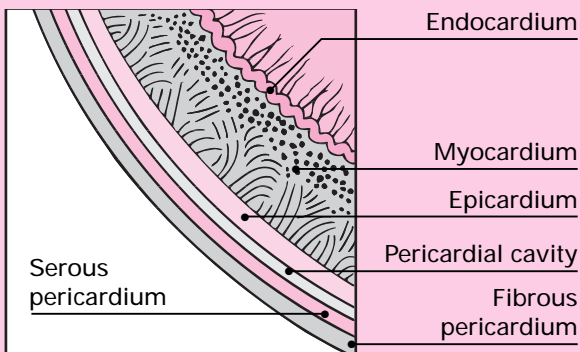
A protective sac called the pericardium covers the heart. Its tough outer layer, the fibrous pericardium, is linked by ligaments to the breastbone, spine, and other parts of the chest cavity. This anchors the heart firmly in position. Inside the fibrous pericardium are two

more layers of pericardium with a fluid-filled space in between. This helps the two layers to slip against each other without friction while the heart beats. The innermost layer of pericardium forms the outer layer of the heart, so it is called epicardium ("upon the heart").

Cross section of heart showing structure of heart wall



Detailed structure of the heart wall



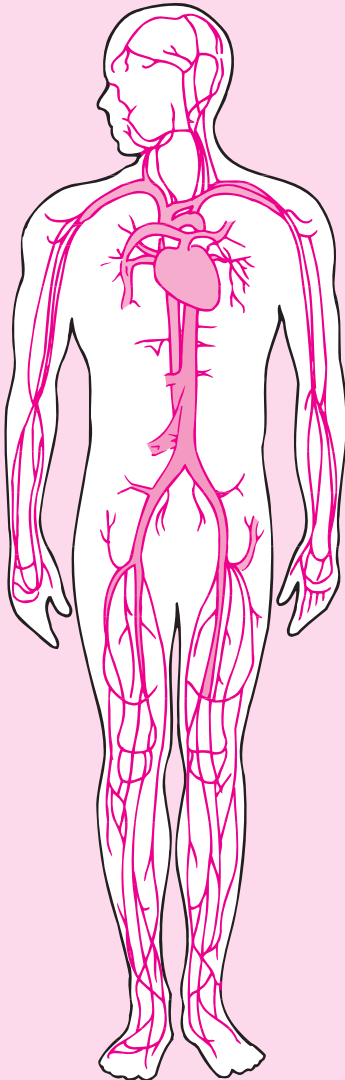
Heart facts

- "Atrium" means "entrance hall," while "ventricle" means "little belly."
- Each atrium has a flaplike structure called an auricle, meaning "little ear." The function of the auricle is not known.

Blood vessels of the heart

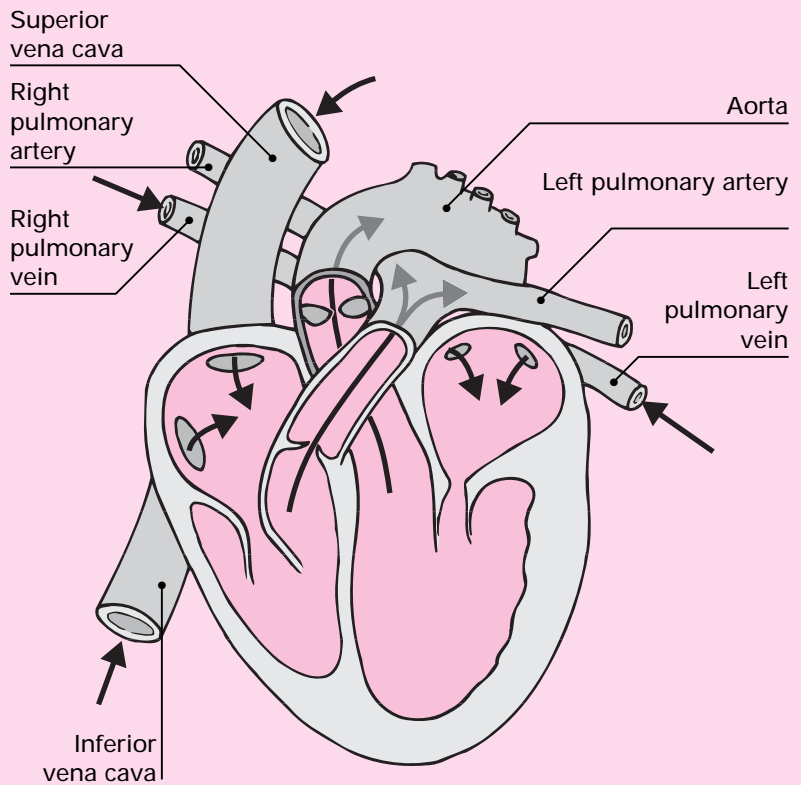
Heart and blood system

Here the heart is shown with the main blood vessels that lead to and from it.



Blood to the heart

Blood from the body enters the heart through two large veins, called the superior (upper) vena cava and the inferior (lower) vena cava (plural: venae cavae). Blood from the lungs enters the heart through the pulmonary veins.



Blood from the heart

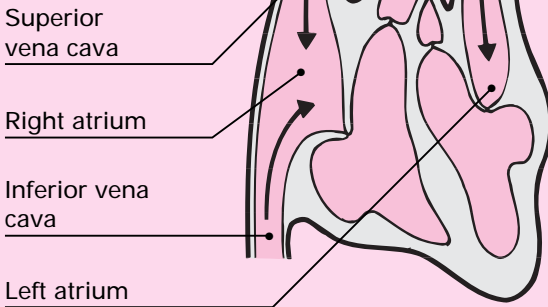
Blood from the heart is pumped to the body through the aorta. The aorta is called the ascending aorta as it extends upward from the heart, the aortic arch where it bends, and the descending aorta where it continues downward. Blood from the heart is pumped to the lungs through the pulmonary arteries.

Filling of chambers in the heart

Blood enters the two upper chambers (atria) of the heart. Then it is pumped into the two lower chambers (ventricles).

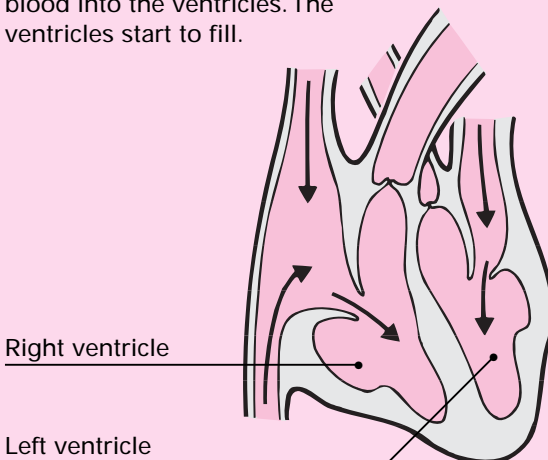
Blood enters the atria

1 Blood from the venae cavae fills the right atrium of the heart and blood from the pulmonary veins fills the left atrium of the heart.



Blood is pumped into the ventricles

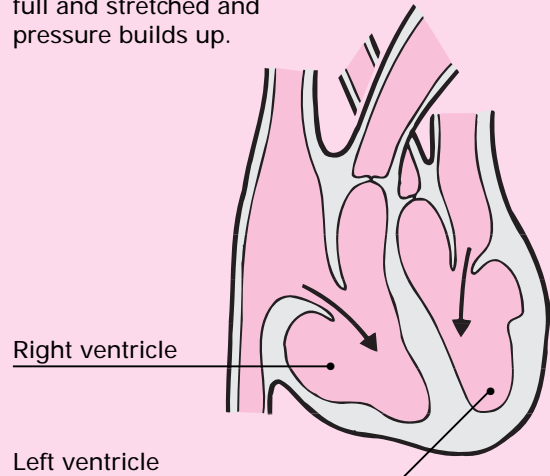
2 The atria contract, forcing blood into the ventricles. The ventricles start to fill.



Finally, it is pumped out of the two ventricles and leaves the heart.

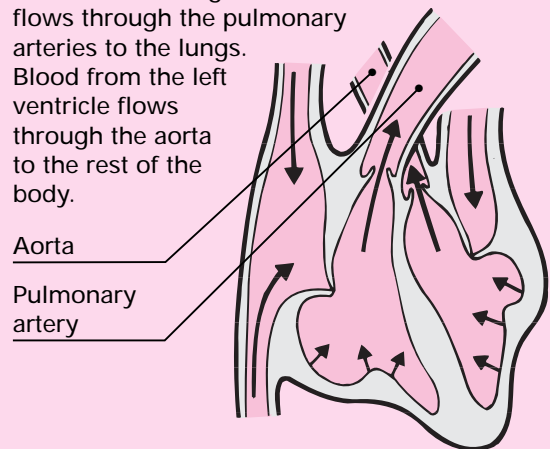
Ventricles fill with blood

3 The two ventricles become full and stretched and pressure builds up.



Blood leaves the ventricles

4 The two ventricles contract, pumping blood out of the heart. Blood from the right ventricle flows through the pulmonary arteries to the lungs. Blood from the left ventricle flows through the aorta to the rest of the body.



Structure of valves

The four heart valves are in two pairs: atrioventricular (AV) valves between atria and ventricles, and semilunar ("half-moon") valves between ventricles and main arteries. The valves are made of tough, rubbery flaps, called cusps, which grow out of the heart wall. Joined to the free ends of the AV valves are a number of cords called chordae tendineae (heart strings) attaching them to muscles in the wall of the ventricle. The heart strings keep the AV flaps pointing in the direction of the blood flow, stopping them being turned "inside out" and forced through into the atria. The semilunar valves do not have heart strings. Blood flowing the wrong way makes the cusps balloon out so that their edges seal tight.

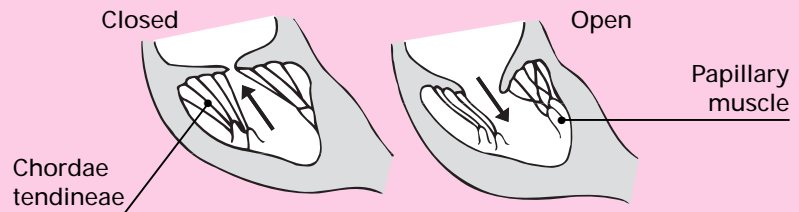
Valve facts

- As the heart valves slap shut to prevent the backflow of blood, they make a "lub-dub" sound. The "lub" is the AV valves closing, while the "dub" is the sound of the semilunar valves shutting.

Atrioventricular valves

The tricuspid valve consists of three cusps, while the bicuspid, or mitral, valve has only two cusps. They both stop blood flowing back from ventricles to atria.

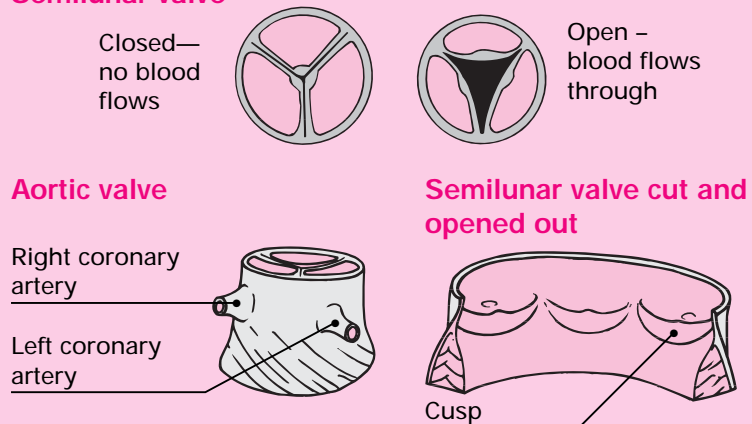
Tricuspid valve



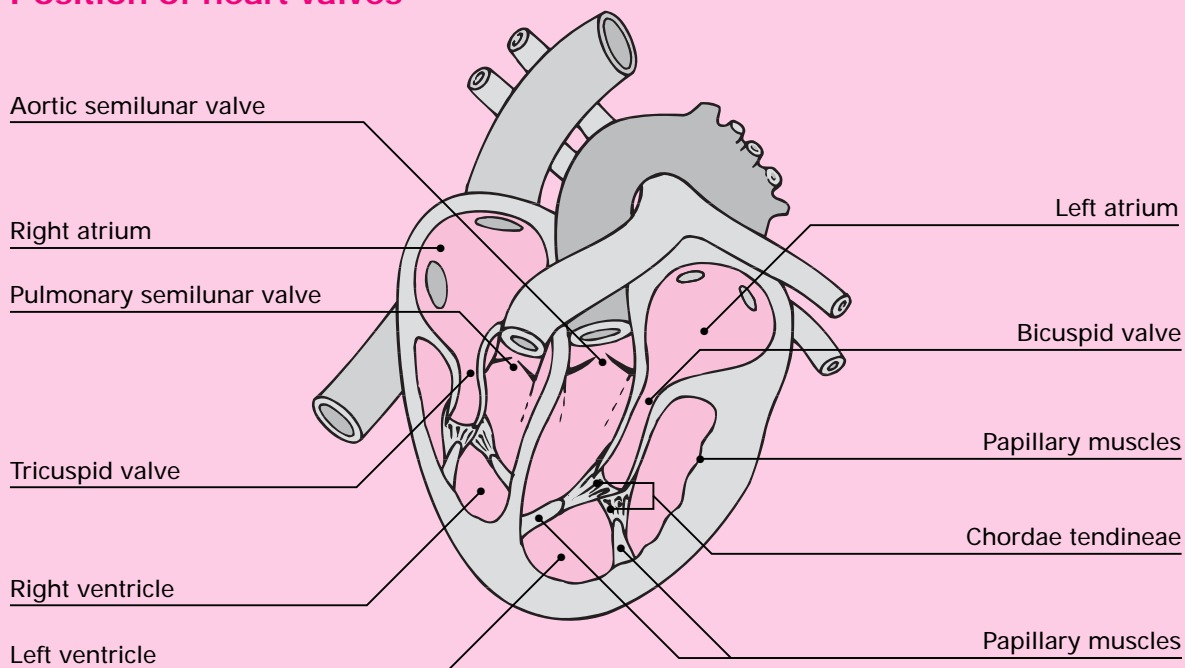
Semilunar valves

The aortic semilunar valve and pulmonary semilunar valve are located at the base of the two large arteries leaving the heart (the aorta and pulmonary artery). Each is crescent-shaped and consists of three cusps.

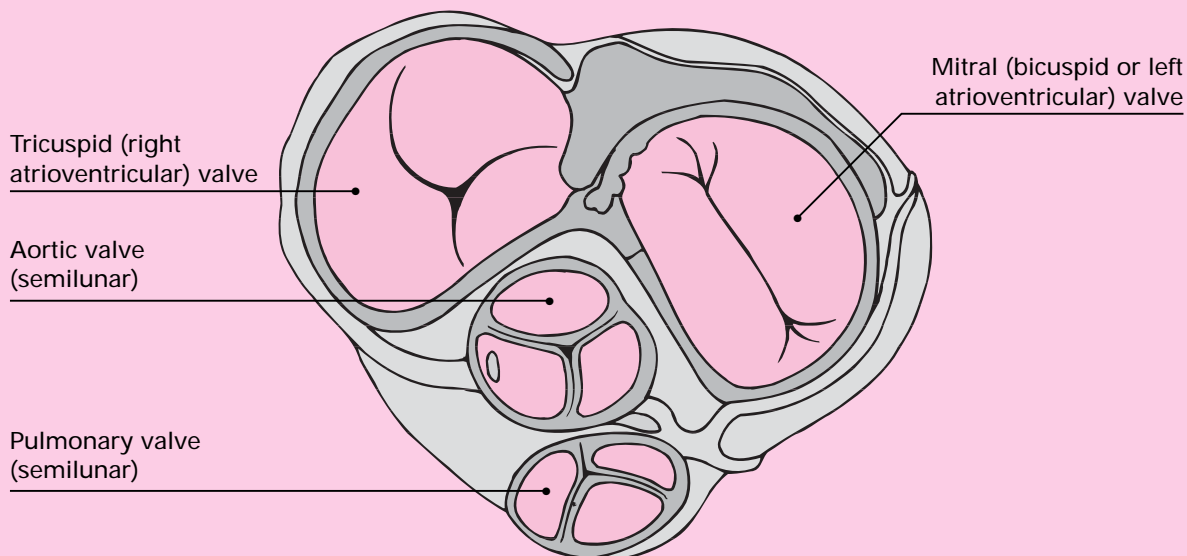
Semilunar valve



Position of heart valves



Heart valves viewed from above



A complete heartbeat is called the cardiac cycle. One heartbeat means the contraction (also called systole) and relaxation (diastole) of the atria, followed by the contraction and relaxation of the ventricles. Each cardiac cycle takes about 0.8 seconds to complete if the heart beats at an average of 72 beats per minute. In a normal heartbeat, the two atria contract simultaneously while the two ventricles relax. When the two ventricles contract, both atria relax. During a typical heartbeat, the atria contract for about 10 percent of the time and the ventricles for about 40 percent. The direction of blood flow through the heart is controlled by the atrioventricular (AV) and semilunar valves.

Atrioventricular (AV) valves

AV valves prevent the backflow of blood from the ventricles to the atria when the heart contracts.

1 Blood fills the atria. The AV valves are closed.

2 Pressure in the atria rises, forcing the valves open. The ventricles begin to fill with blood.

3 As the ventricles become full, the AV valves close. This prevents blood from returning to the atria.

Semilunar valves

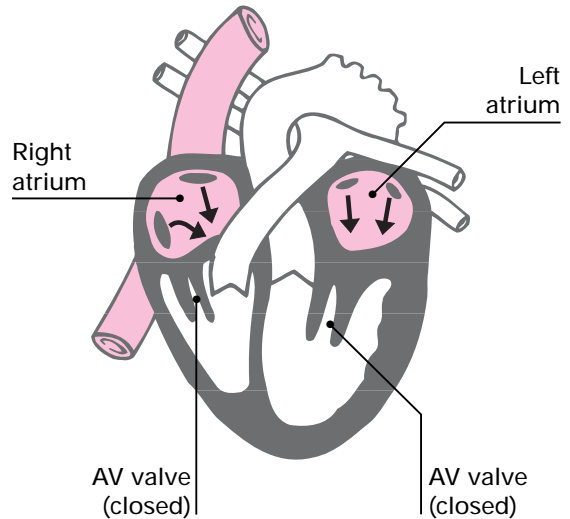
The semilunar valves prevent the backflow of blood into the ventricles.

4 The ventricles contract until pressure exceeds that of blood in the aorta and pulmonary artery.

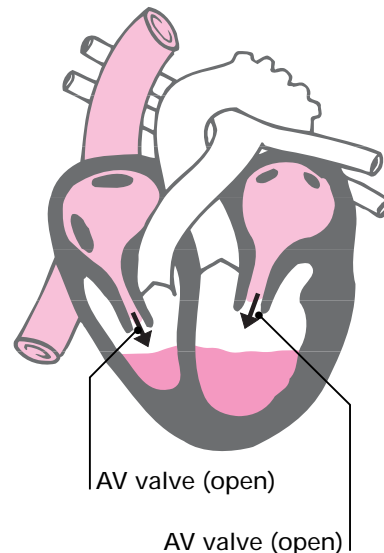
5 The semilunar valves are forced open and blood flows out of the heart.

6 The ventricles relax and blood begins to flow backward toward the heart. The cusps of the semilunar valves are filled with blood and they close. Blood is prevented from flowing back into the ventricles.

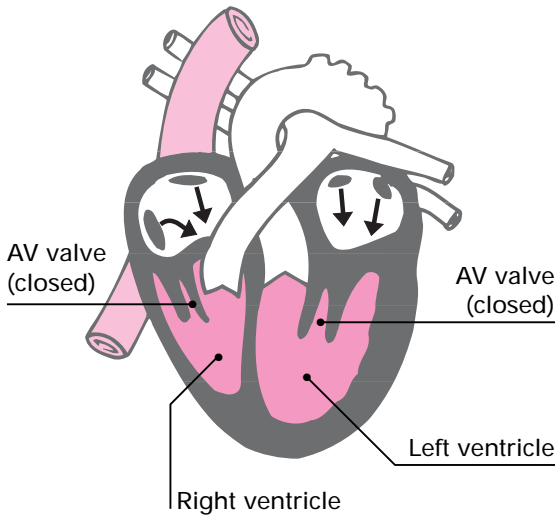
- 1** Atria fill with blood
Atrioventricular valves are closed




- 2** Atria contract
AV valves open



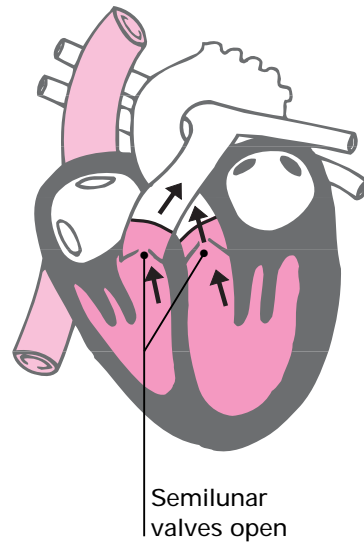
- 3** AV valves close
Ventricles are full of blood



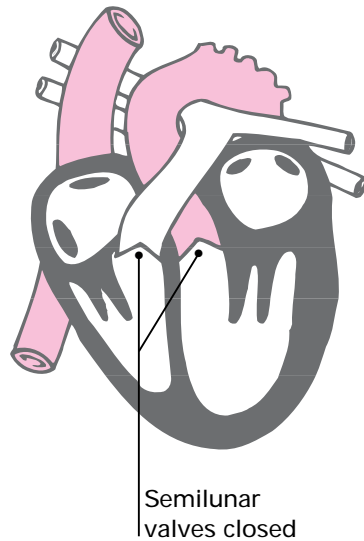
- 4** Atria relax
Ventricles contract



- 5** Semilunar valves open



- 6** Ventricles relax
Semilunar valves close



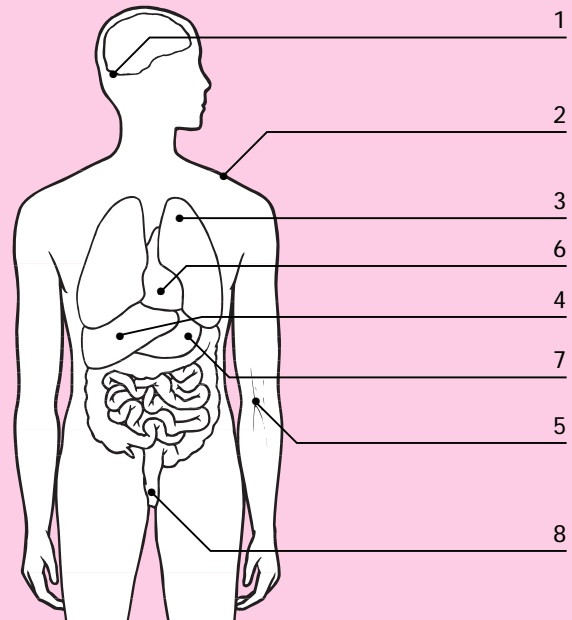
Just as the condition of the body and circulation can affect the heart, so the condition of the mind is reflected in the state of the heart. Stress is one of the major contributing factors to heart disease, partly because it alters the body's systems (such as the blood cholesterol level) in such a way that the heart can be damaged, and partly because those who live under stress are apt to develop conditions that strain the heart, such as high blood pressure from overwork, respiratory

problems from smoking, poor circulation from lack of exercise, and so on. The stressed person usually has a busy schedule and therefore frequently skips meals, has a few drinks instead of eating, or eats snacks or takeout foods to stave off hunger pangs. These eating habits affect the body adversely. Conscious removal of both the causes and effects of stress recondition the heart and alter the outlook so that heart disease is far less likely to occur.

Stress and the circulation

The illustration shows some of the parts of the body that may be affected by the action of stress on the heart and circulation.

- 1** Pituitary gland; this releases adrenocorticotrophin hormone (ACTH) into the bloodstream, which stimulates the release of adrenaline and other hormones.
- 2** Skin; pallor may occur as blood is diverted away from the skin to the muscles.
- 3** Lungs; the rate of breathing speeds up and increases the oxygenation of the blood.
- 4** Liver; this releases extra sugar into the blood in order to provide the body with extra energy if required.
- 5** Blood; the serum cholesterol level of the blood tends to be higher in people under stress. The levels of fibrinogen, platelets and lymphocytes in the blood are all increased; these are defense mechanisms, intended to prepare for the repair of damaged tissues.
- 6** Heart; the heart rate speeds up dramatically, in order to transport



oxygen and nutrients to the muscles more rapidly.

- 7** Spleen; this releases more red cells into the blood to assist in carrying the extra oxygen from the lungs.
- 8** Genitals; stress can often cause impotence. Although the origins may be psychological, excessive tiredness and lack of relaxation experienced under stress can be precipitating factors.

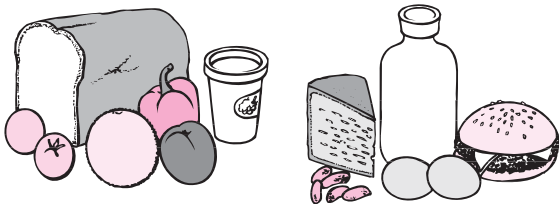
Dietary guidelines

Do:

- reduce your overall intake of fats as well as cholesterol in your diet;
- eat smaller portions of meat—no more than 6 oz (170 g) a day;
- increase your intake of fresh vegetables and fruits (except avocados and olives, which are comparatively high in fat, and so best avoided);
- eat breads, cereals, and flour products that do not contain much fat or sugar; and
- substitute whole milk with skim milk, and eat low-fat yogurt.

Don't:

- let fats account for more than 30–35% of your daily food consumption;
- eat food that contains more than 300 mg of cholesterol daily;
- eat more than three egg yolks per week;
- use saturated fats (animal fats) in cooking;
- eat meat that is obviously fatty—even lean meat contains fat;
- eat nuts, which have a high fat content;
- eat whole-milk dairy products; or
- just substitute butter with margarine—use a low-fat spread instead.



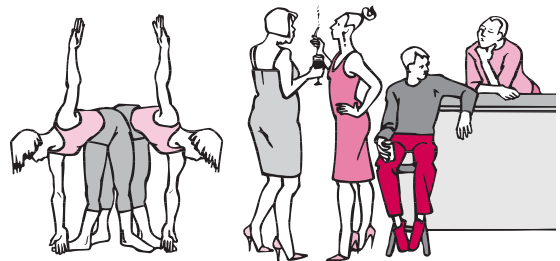Exercise guidelines

Do:

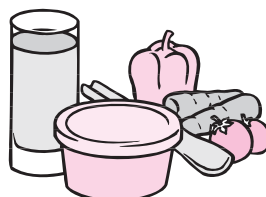- choose an exercise that you enjoy and is within your capabilities;
- check up with a doctor if you have any health doubts;
- lose any excess weight;
- warm up and cool down with appropriate exercises each time;
- walk instead of using other transport whenever possible;
- keep a close check on your pulse rate, both during and after exercise; and
- vary your exercise activity if you get bored.

Don't:

- exercise strenuously without medical supervision;
- exceed the recommended pulse limit for your level;
- continue to exercise if you feel pain or discomfort.
- eat large meals;
- exercise within one and a half hours of eating a meal;
- ever smoke, or drink heavily;
- exercise strenuously if you are overweight;
- exercise against the clock; or
- force yourself to do an exercise activity that you dislike.



It has become increasingly evident that an analysis of diet plays a very important role in the understanding of heart disease. Doctors originally realized that a high intake of cholesterol, found particularly in saturated animal fats, was associated directly with atherosclerosis, and patients were put on low-cholesterol diets. However, the serum cholesterol in their blood tended still to remain high, and further research revealed that if the body is low in cholesterol, the liver manufactures it from other fats in the diet. So it became evident that blood cholesterol could only be kept low on a diet low in fats of all kinds, and this has become the almost unanimous recommendation from health sources for a diet toward a healthier heart. When planning your diet, remember to seek dietary advice from a specialist if you or other members of your family have high blood pressure or a history of heart disease.



Low-fat snacks

Plenty of nutritious low-fat snacks can be eaten in large quantities without significant fat intake. Fruit juice, fresh fruit, and raw vegetables such as carrots, celery, lettuce, cucumber, tomato, pepper, cauliflower, cabbage, and spring onion can all be eaten freely.



High-fat snacks

If you take a packed lunch to work or have a snack meal in the evening, avoid snack foods that can be very high in fat. Cheese and whole milk, although high in protein and low in sugar, are also high in fat. Potato chips and hamburgers should also be avoided.

Reducing fat in the diet

Meat is a major enemy of people on a low-fat diet. Fish is generally much lower in fat, although the cholesterol content is relatively high. The high fat contents of many meats can be reduced by careful preparation and cooking. Cut all visible fat from meat before cooking. Grill bacon, sausages, and chops on a rack so that the fat drips away. To cook fish, wrap it in foil so the moisture is retained and there is

no need to brush with oil or fat.

Virtually all store-bought cakes, pastries, cookies, and crackers are high in fat, although most breads are low. Chocolate, peanuts, and potato chips are all very high in fat. For home baking, replace butter with unsaturated margarine; instead of cream, use skim milk. Eggs are very high in cholesterol and so should be avoided. Many recipes can be made leaving out

the eggs, and if this does not work, use low-cholesterol dried egg.

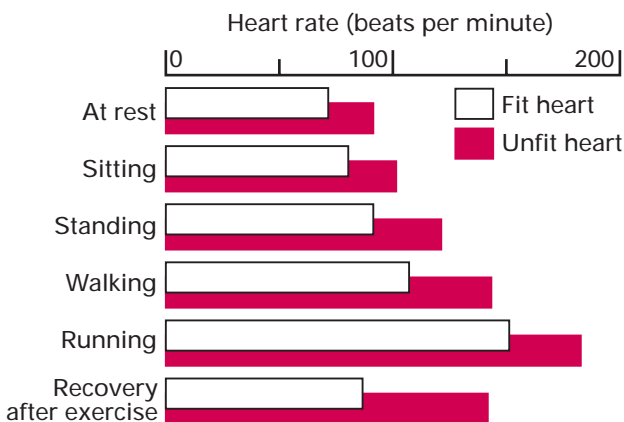
It is much better to make your own snack food. Delicious low-fat sandwiches can be made with combinations such as: cottage cheese with pineapple or celery, salmon and cucumber, chicken and tomato, or green salad. People on a low-fat diet are advised to avoid all cheeses except cottage cheese.

Type A and type B

Personality type is now considered to be a definite risk factor in heart disease, although the direct link is uncertain. Type A, the type most likely to develop heart disease, is the person who drives himself or herself relentlessly, is tense, is often under stress of various kinds, has few or no philosophical or religious beliefs, and has few relaxing hobbies. Type B is more relaxed and easy-going, and takes life at a gentler pace. It is unclear as yet whether type A's likely heart problems come from genetic makeup or lifestyle.

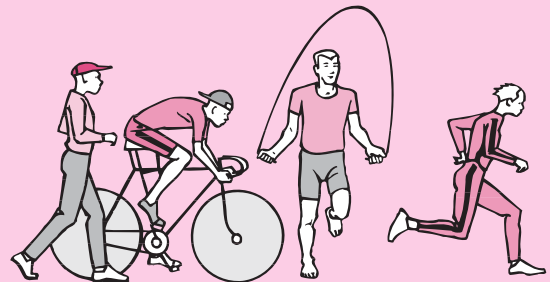
The fit and unfit heart

The diagram below shows the comparative amounts of work done by a fit heart and an unfit heart during various activities. The higher the heart rate, the harder the heart is having to work; when the heart rate is low, the heart is being used efficiently. The unfit heart has to work much harder all the time, and so may be under a constant strain. A healthy heart works under a self-imposed maximum pulse rate of about 190 beats per minute, which means that even under severe, unplanned stress it is unlikely to increase its work to a dangerously fast rate.



Exercise and fitness

Before and after every session of scheduled exercise, gentle warming up exercises should be done to speed up and slow down the flow of blood gradually. These exercises also allow the body to warm up and cool down gradually so that there is no temperature shock, such as might be experienced after vigorous exercise on a very cold morning. Warming up exercises include bending to the left and right with one arm curved over your head and the other hand on your hip. An alternative exercise is jumping up in the air with your arms raised and legs apart. For those starting out on a regular course of exercise for the first time in several years, begin with less strenuous activities such as walking or swimming. As your fitness increases, you can move on to more aerobic activities such as running, racket sports, or canoeing. Exercise for only a few minutes each time for the first week or so, then gradually increase as you feel yourself getting fitter and more capable. Rather than exercising against the clock, or setting targets, make relaxation and enjoyment the key elements of your exercise sessions.



Heart attacks

The term “heart attack” is usually used to describe a sudden blockage in a heart artery. A more accurate term is “myocardial infarction” (MI). If a heart artery is blocked for more than a few minutes, the muscle cells (myocardium) may become permanently damaged. If the amount of muscle damage is small, there will be enough good muscle left for the heart to work again once the heart attack is over. Heart attacks can start at any time of the day or night, when a person is resting or being active. Sometimes, a heart attack can be brought on by unusually energetic activity or by massive stress. People with a family history of heart attacks may be more likely to have a heart attack themselves. People with diabetes are also more likely to have heart problems although the reason for this is not clear.

Heart attacks occur more often in men than women and mostly in people over 40.

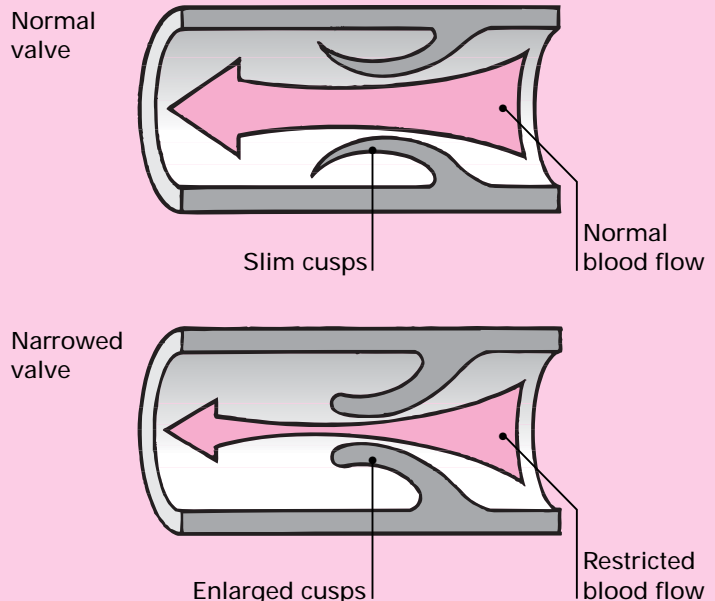
Artery blockage

The most common reason for heart arteries to become blocked is due to a buildup of layers of fatty material (cholesterol) inside the arteries. The walls of these damaged arteries may crack and a blood clot may form on top of the crack. This can suddenly block off the artery completely. Occasionally, the blockage is caused by a spasm of the muscle walls of the coronary arteries. It can also be due to a very fast heart rate, when the heart muscle demands more oxygen than the blood supply can provide. Heart attacks cause severe pain and other symptoms such as sweating, nausea, or shortness of breath.

Valvular heart disease

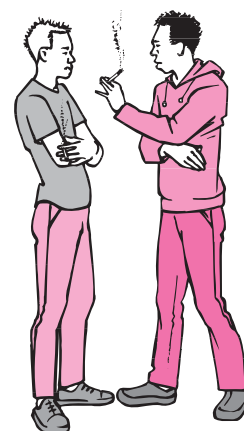
The main causes of valvular heart disease are: being born with abnormal heart valves (congenital heart disease), the long-term effect of rheumatic fever, and aging of the heart. A disease of heart muscle called cardiomyopathy can also cause thickening of the muscle around the valve, and lead to valvular heart disease. Problems with the heart valves disrupt blood flow, which may weaken the heart and cause it to enlarge.

Cross sections through heart valves



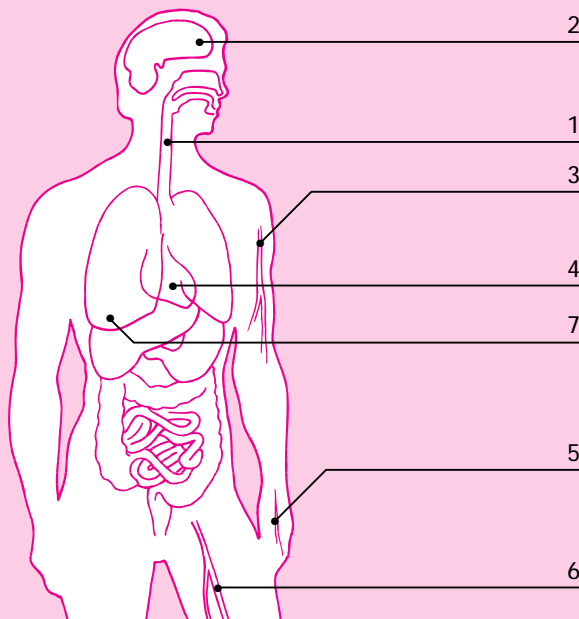
Smoking

Medical research has proved that smoking constitutes a grave health risk, with more and more diseases proving to be associated with, or aggravated by, smoking. Women who smoke while pregnant can cause damage to their babies. If a smoker continues to smoke after a heart attack, this doubles their risk of having another heart attack within one year. The risk of having a heart attack starts to reduce as soon as a person gives up smoking, and is half as likely to happen within one year of stopping smoking. Advice on giving up smoking can be obtained from doctors, nurses, and pharmacists, as well as “stop-smoking” help groups.



Effects of smoking

This diagram illustrates some of the parts of the body affected when a pipe, cigar, or cigarette is smoked. These effects wear off gradually when the smoking stops, but if smoking is frequent or continuous, the affected parts of the body have no time to revert to their normal states.



1 Nicotine enters the bloodstream, subduing the transmission of nerve signals, and paralyzing the cilia of the airways, which trap harmful particles. Nicotine also inhibits the alveolar phagocytes which destroy bacteria and viruses.

2 The toxins carbon monoxide and cyanide in the smoke may cause a headache.

3 Blood pressure rises because nicotine causes the blood vessels to constrict.

4 The heart rate increases, and so the reserve energy of the heart is decreased, rendering the person less capable of physical exertion or strain.

5 The blood vessels to the hands and feet are constricted, leading to poor general circulation.

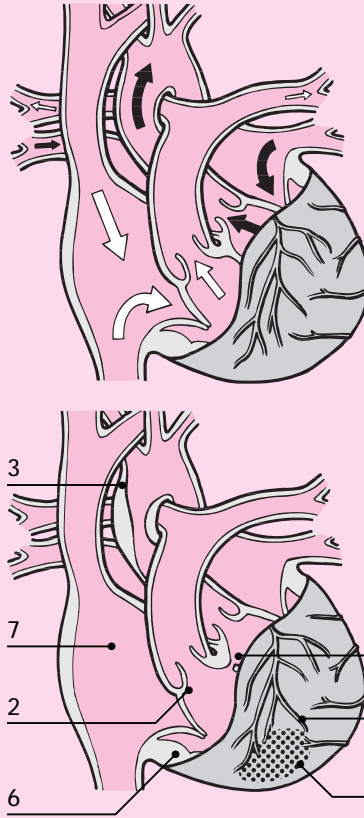
6 Certain chemicals contribute to the raising of serum cholesterol levels in the bloodstream.

7 The lungs fill with a mixture of air and tobacco smoke, which deposits minute amounts of tar inside the lungs.

Heart problems

The top illustration shows the direction of blood flow through a normal heart. The lower illustration shows some of the problems that can affect the heart.

- 1** Congenital malformations. Babies can be born with heart problems, sometimes involving a hole in the wall between the chambers of the heart.
- 2** Diseases of the valves. These can either be congenital, or the result of disease or infection.
- 3** Diseases of the blood vessels. Deposits of fat can be laid down within the walls of the vessels, usually the larger arteries. This is often associated with a raised cholesterol and fat level in the blood.
- 4** Coronary artery problems. The heart gains its blood supply by a system of vessels called the coronary artery circulation. Like the other arteries, this may have fatty deposits in the walls; if the deposits completely block the vessel then a heart attack results. The area of the



heart muscle supplied by that vessel is starved of oxygen and dies. If this process happens to vessels that supply the brain with blood, then a stroke is the result. There are various factors that make heart attacks more likely. The most important ones to be avoided are cigarette smoking, raised blood pressure, being

overweight, lack of exercise, and stress.

- 5** Scar from an old heart attack. If a heart attack occurs the scar is permanent, but by avoiding the factors that make heart attacks more likely, the damage can be minimized.

6 Problems with the heart muscle. The heart is a muscular pump; if the blood pressure is raised, which may happen for a variety of reasons (such as kidney disease), the heart enlarges and the valves may work inefficiently. The increase in pressure within the blood vessels may cause damage to the anatomy of the vessel walls and cause a rupture. The most frequent site for this is within the skull, and a stroke is the result.

- 7** Problems with the heart pacemaker. The heart beats in response to small electrical impulses arising in a bundle of nerve fibers at the center of the heart. If this pacemaker is not functioning correctly, disturbances of the rhythm of the heart result.

Heart disorders

Angina pectoris Pain or discomfort in the chest, which is caused by inadequate oxygen supply to the heart, sometimes as a result of narrowed coronary arteries. Angina often happens during exercise or stress.

Arrhythmia Abnormal heart rate or rhythm caused by a disruption of the heart's conduction system, which generates and transmits electrical impulses in the heart. It can be caused by coronary artery disease, stress, exertion, or some drugs.

Bradycardia A slow heart rate—below 60 beats a minute.

Cardiomegaly Enlargement of the heart. There are a number of causes.

Congenital heart defects Heart defects in newborn babies including: ventricular septal defect (the wall between two ventricles does not form properly), coarctation of the aorta (the aorta is narrowed), pulmonary stenosis (the pulmonary semilunar valve is narrowed), and tetralogy of Fallot (multiple defects).

Cor pulmonale Disease of the heart caused by disease of the blood vessels to the lungs or disease of the lungs themselves.

Endocarditis Inflammation of the endocardium (inner heart lining) often resulting from infection by bacteria.

Epicarditis Inflammation of the epicardium (outer lining of the heart).

Fibrillation Rapid, irregular contractions of the heart.

Heart block Electrical impulses in the heart are blocked at points in the conduction system.

Heart failure The heart pumps less blood than the body needs and so is not capable of

supplying the oxygen demands of the tissues. Results in congestion of blood and lack of nutrition to tissues.

Mitral valve prolapse Improper closure of the mitral valve (the valve between the left atrium and ventricle). Also called floppy valve syndrome.

Myocardial infarction Commonly called heart attack, a condition in which obstruction of blood flowing to the heart muscle results in tissue death. It is most often caused by atherosclerosis of the coronary arteries.

Palpitations Rapid or irregular heartbeat caused by drugs, emotions, or heart disorders.

Pericarditis Inflammation of the bag (pericardium) that encloses the heart. Too much fluid may be produced in the pericardial space, so that the heart is compressed and unable to fill properly. The two layers of the pericardium become stuck together, restricting the heart's movement.

Pulmonary atresia A complete blockage between the heart and the main pulmonary artery.

Stokes-Adams syndrome A sudden attack of unconsciousness accompanying heart block.

Tachycardia A fast heart rate—above 100 beats a minute.

Tricuspid atresia The heart has no tricuspid valve; the right ventricle is usually small. There is a reduced flow of blood to the lungs.

Valvular stenosis Narrowing of a heart valve, which causes the heart to work harder to push blood around the body.

The circulation of blood means the way that blood flows in a circular pathway around the body. From the left ventricle of the heart, blood flows through blood vessels to all parts of the body, and back to the right atrium of the heart. To complete the circuit and reach the left ventricle again, the blood has to flow to the lungs and back again, entering the heart through the left atrium.

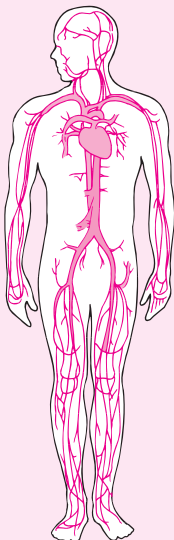
Circulation facts

- The combined surface of the capillaries is 6,000 square yards (557.4 m²)—an area larger than a soccer field.
- The great arteries that emerge from the heart are often called “trunks.”

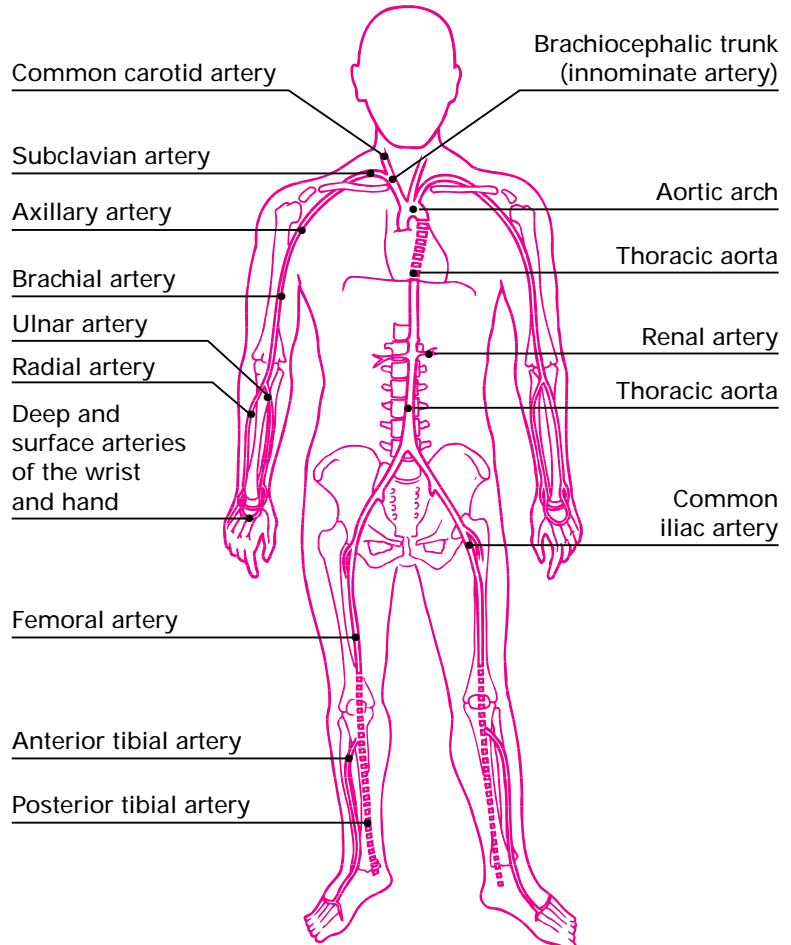
Arteries

Blood leaves the heart through the aorta, which branches into the carotid artery to the neck, and the brachial arteries to the arms. The aorta runs down to the abdomen, where it divides into the iliac arteries feeding the legs.

Circulatory system



Arteries front view



Main arteries**Artery****Areas supplied**

Anterior tibial artery	Front of lower leg
Aorta	Heart, whole body
Axillary artery	Chest wall, shoulder, breast
Basilar artery	Brain—pons, cerebellum, posterior cerebrum
Brachial artery	Arm, hand
Brachiocephalic trunk	Right of head and neck, right arm, right thoracic wall
Bronchial artery	Lower trachea, bronchial tree
Carotid arteries	Head, face, neck
Celiac trunk	Lower esophagus, stomach, liver, upper duodenum, pancreas, spleen
Cerebral arteries	Brain—cerebrum
Common iliac artery	Pelvis, legs
Coronary arteries	Heart muscle
Facial artery	Face, tonsil, soft palate
Femoral artery	Thigh, skin of lower abdomen
Gastric arteries	Stomach
Hepatic artery	Liver
Inferior mesenteric artery	Splenic flexure of colon, descending colon, sigmoid colon, proximal rectum
Intercostal arteries	Intercostal muscles, vertebrae, spinal cord, back muscles
Lumbar arteries	Spinal cord, vertebrae, psoas (loin muscles), quadratus lumborum, and other back muscles
Peroneal artery	Calf muscles
Posterior tibial artery	Back of lower leg
Pulmonary artery	Carries deoxygenated blood from heart to lung
Radial artery	Lateral forearm (thumb side)
Renal artery	Kidney, proximal ureter, adrenal gland
Subclavian artery	Head, neck, spinal cord, thyroid, larynx, chest muscles, arm
Superior mesenteric artery	Lower duodenum, jejunum, ileum, cecum, ascending colon, upper two-thirds of transverse colon
Temporal artery	Parotid gland, temporomandibular joint, temple
Ulnar artery	Medium forearm (little finger side)
Vertebral artery	Spine, cerebellum in brain

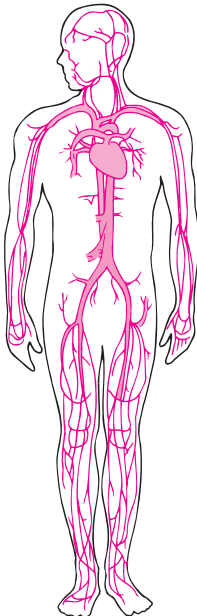
Veins

All over the body, blood low in oxygen drains into veins that eventually link up with the venae cavae. These large veins return blood from the body to the heart. Pulmonary veins carry high-oxygen blood from the lungs to the heart.

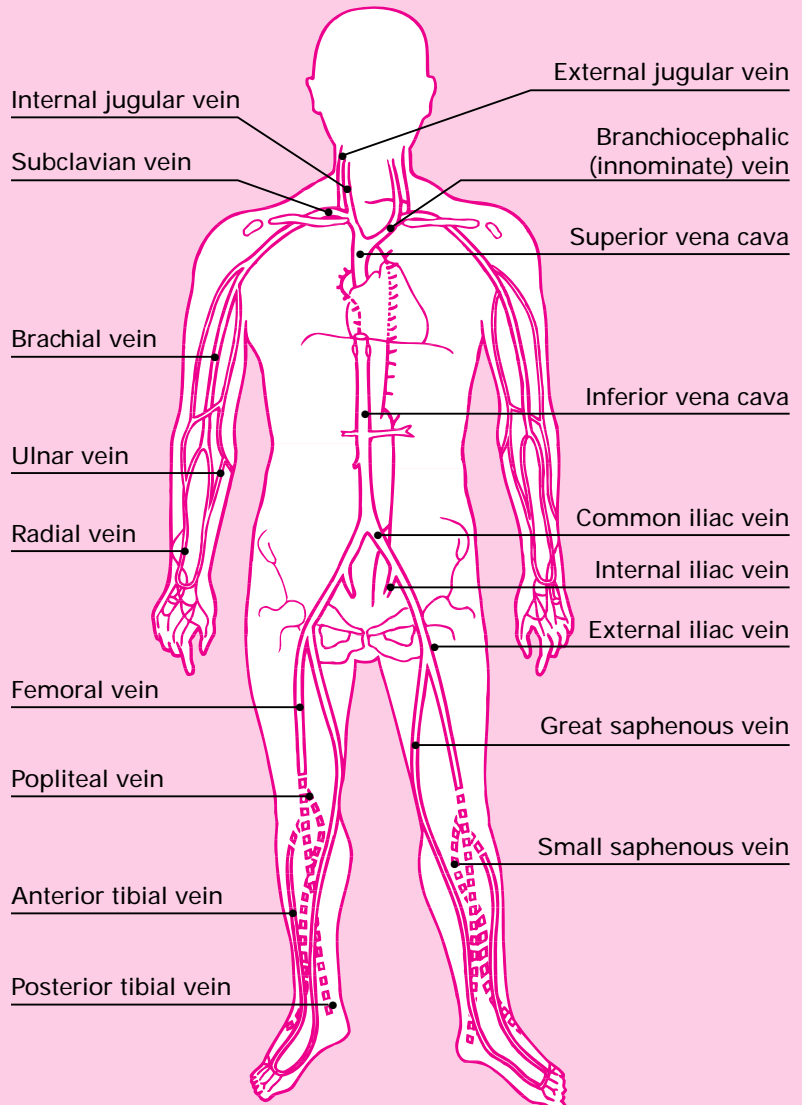
Veins facts

- In the venae cavae near the heart, the blood pressure is almost zero.
- The internal jugular vein drains deoxygenated blood from the brain, and also from the face.

Circulatory system



Veins front view



Main veins**Vein**

Anterior tibial vein

Azygos vein

Basilic vein

Brachial vein

Brachiocephalic

(innominate) vein

Cardiac veins

Cerebral veins

Common iliac vein

External jugular vein

Facial vein

Femoral vein

Gastric vein

Great saphenous vein

Hemiazygos vein

Hepatic vein

Inferior vena cava

Intercostal veins

Internal jugular vein

Medial antebrachial vein

Median cubital vein

Mesenteric veins

Popliteal vein

Portal vein

Posterior tibial vein

Pulmonary vein

Radial vein

Renal vein (left)

Renal vein (right)

Small saphenous vein

Subclavian vein

Superior vena cava

Ulnar vein

Areas drained

Front of lower leg

Lateral and posterior abdominal and thoracic walls,
esophagus, bronchi in lungs

Medial side of hand and forearm

Arm, hand

Head, neck, arm, anterior thoracic wall

Heart muscle

Brain—cerebrum

Leg, pelvis

Head, neck, shoulder

Face

Deep parts of leg

Stomach

Superficial parts of inner side of leg

Left lower posterolateral thoracic wall

Liver

Body below diaphragm

Intercostal spaces

Head, neck, shoulder

Hand, anterior forearm

Hand, forearm

Small and large intestines

Calf

Drains blood from digestive organs to liver

Back of lower leg

Carries oxygenated blood from lung to heart

Deep parts of back of hand and forearm

Left kidney, left ovary or testis, left ureter, left adrenal
gland, left side of diaphragm

Right kidney

Superficial part of lower leg

Head, neck, shoulder

Body above diaphragm (except heart and lungs)

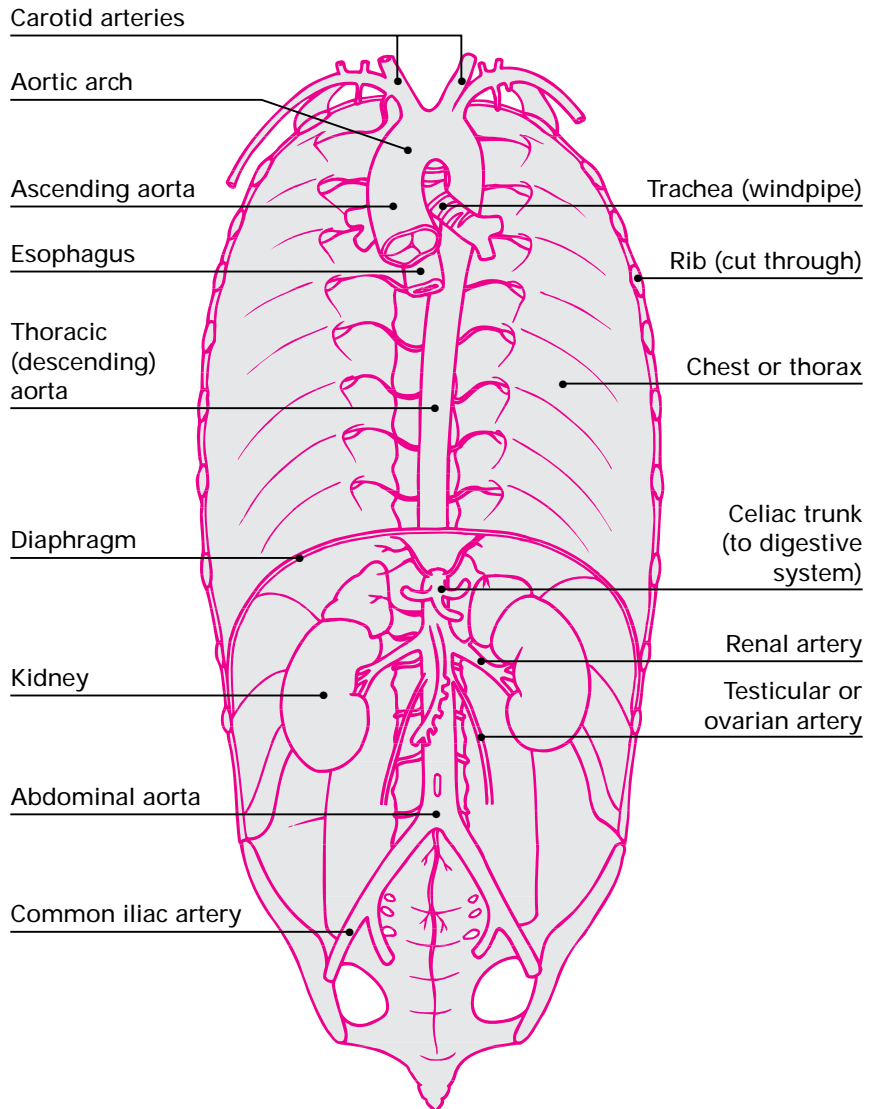
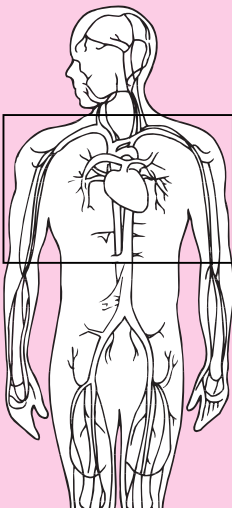
Deep parts of palm and forearm

Aorta

The aorta is the main artery in the body, carrying blood from the heart to the other major arteries. It is in front of the spine but behind the esophagus. There are four main sections: the ascending aorta (which branches into the coronary

arteries); the aortic arch (which branches into arteries for the head, neck, and arms); the thoracic, or descending, aorta; and the abdominal aorta. Within the abdomen, arteries branch off the aorta to organs such as the kidneys.

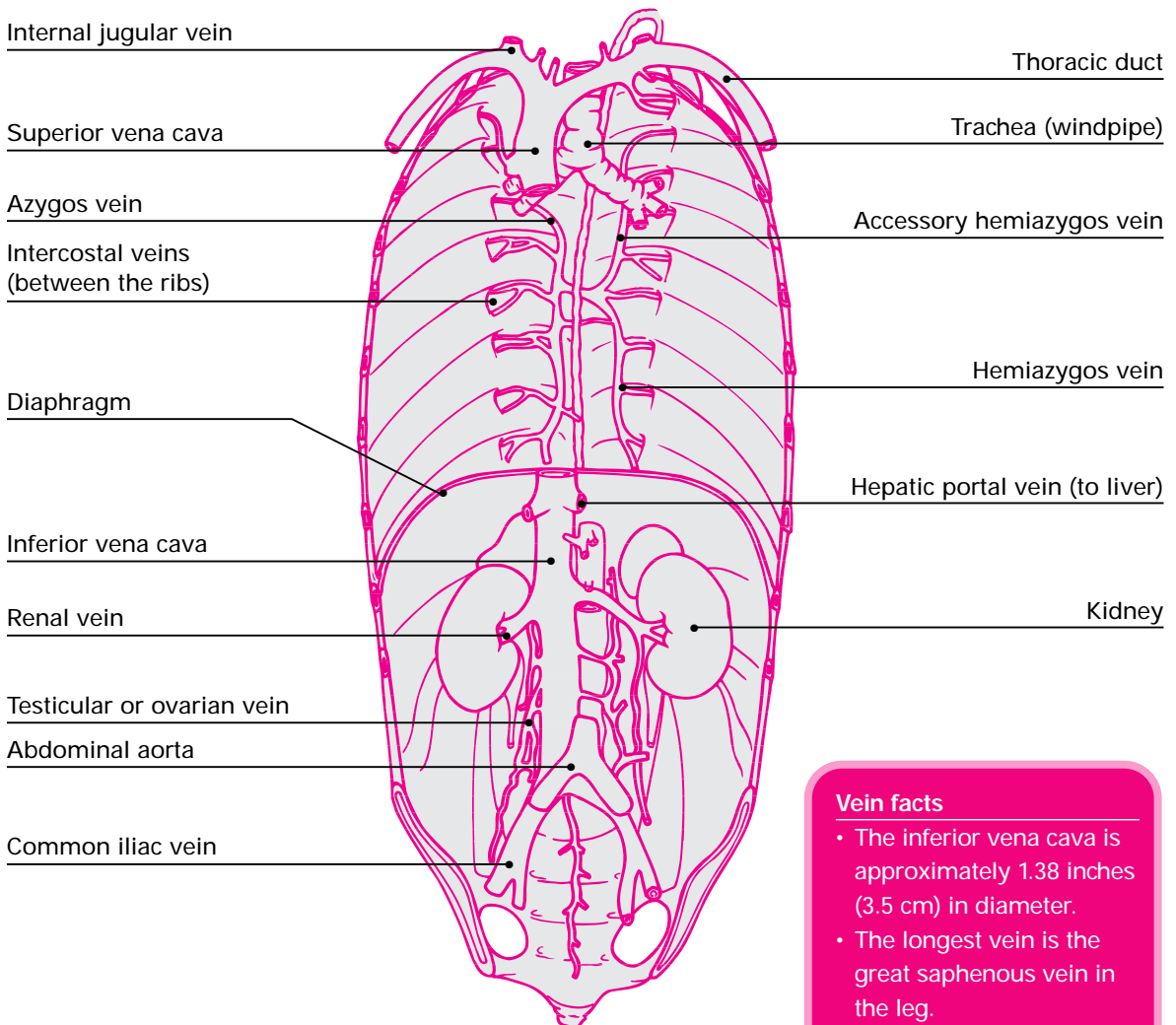
Position of aorta and venae cavae in the body



Venae cavae

The venae cavae are the largest veins in the body. All the veins from the upper part of the body eventually drain into the superior vena cava, which is above the heart. The venous blood from the lower part of the body drains into the

inferior vena cava, which is below the heart. Both venae cavae empty their blood into the right atrium of the heart. The inferior vena cava is larger than the superior vena cava, and is the largest blood vessel in the body.



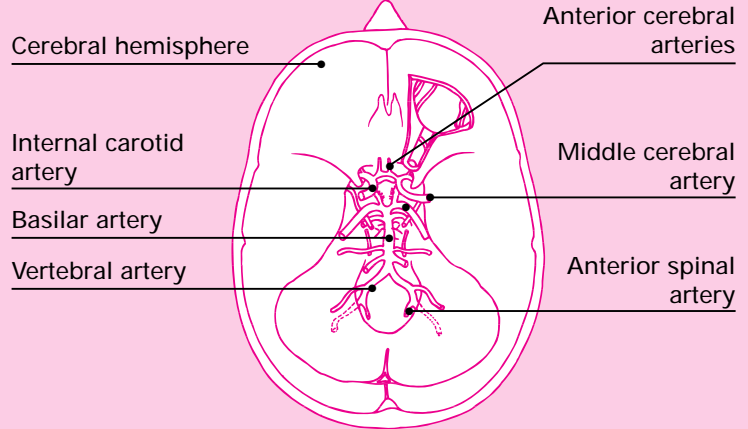
Vein facts

- The inferior vena cava is approximately 1.38 inches (3.5 cm) in diameter.
- The longest vein is the great saphenous vein in the leg.

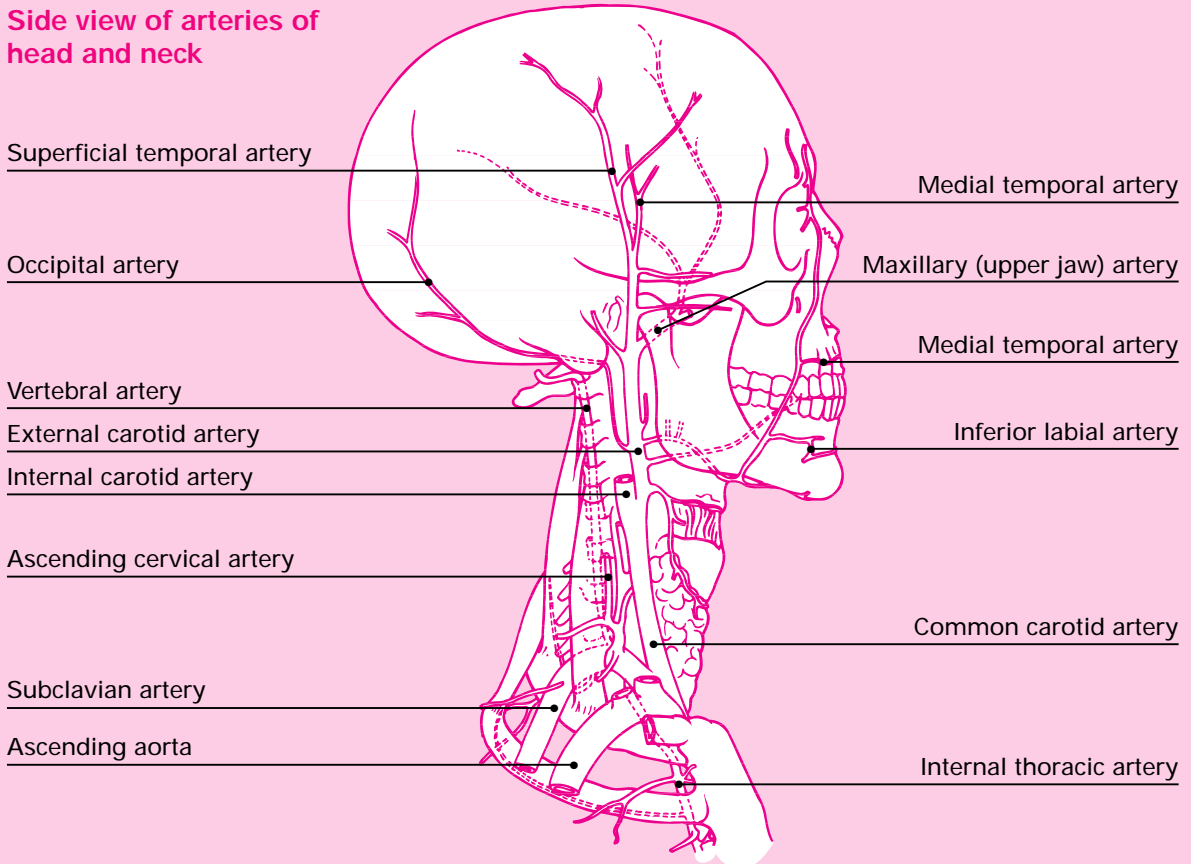
Arteries of face and neck

Arteries running through the neck keep the brain well supplied with oxygen. If this oxygen supply should fail for more than a few minutes, the brain begins to die. The two vertebral arteries join to make the basilar artery, which branches into two and terminates as the two posterior cerebral arteries. These supply the cerebral hemispheres of the brain.

Arteries at base of skull



Side view of arteries of head and neck

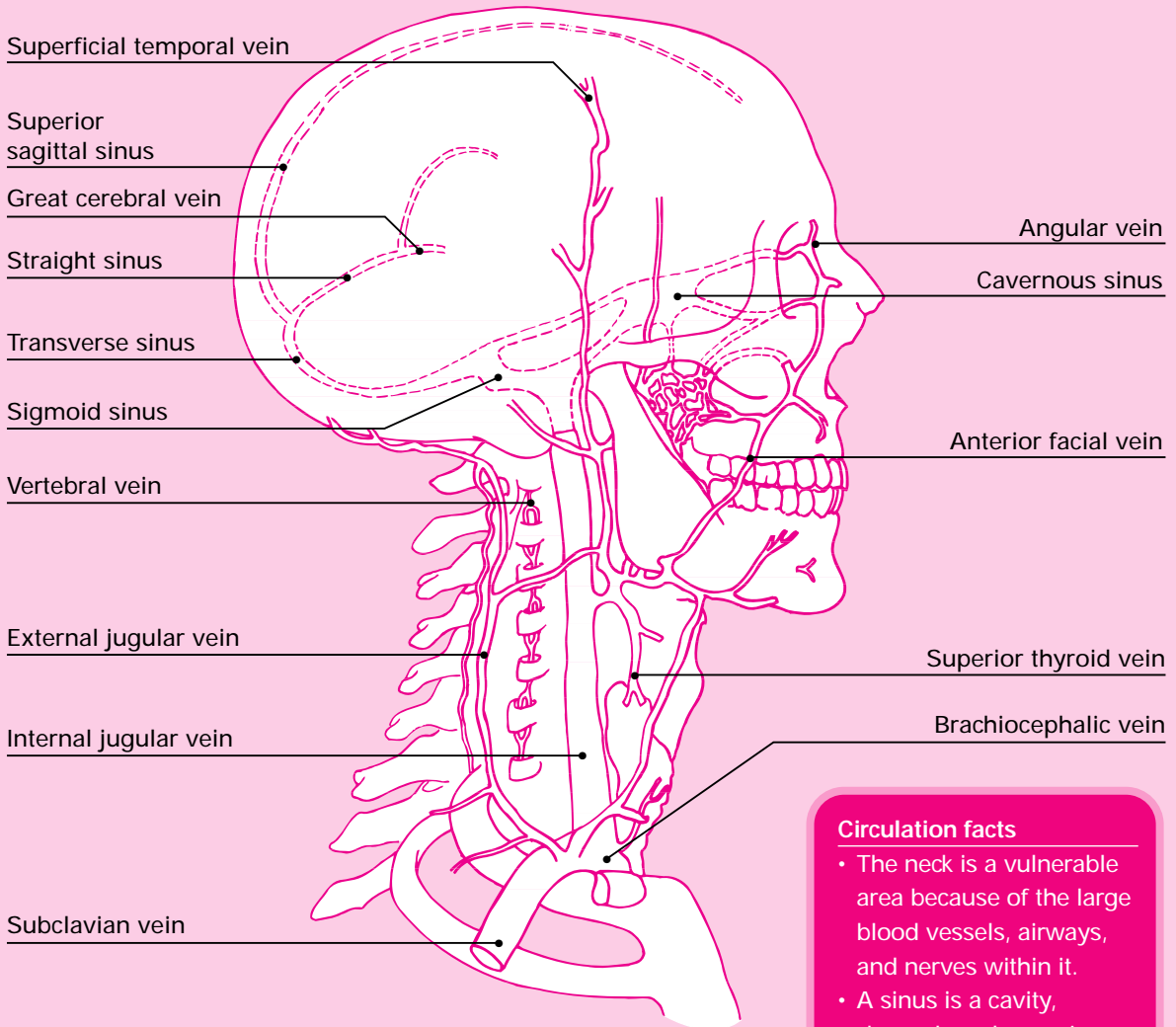


Veins of face and neck

The principal neck veins are the large internal jugular veins, which drain oxygen-poor blood from the brain, skull, and much of the face. The internal

jugular veins join subclavian veins to form brachiocephalic veins, which drain into the superior vena cava. The external jugular vein also drains into the subclavian vein.

Side view of veins of head and neck



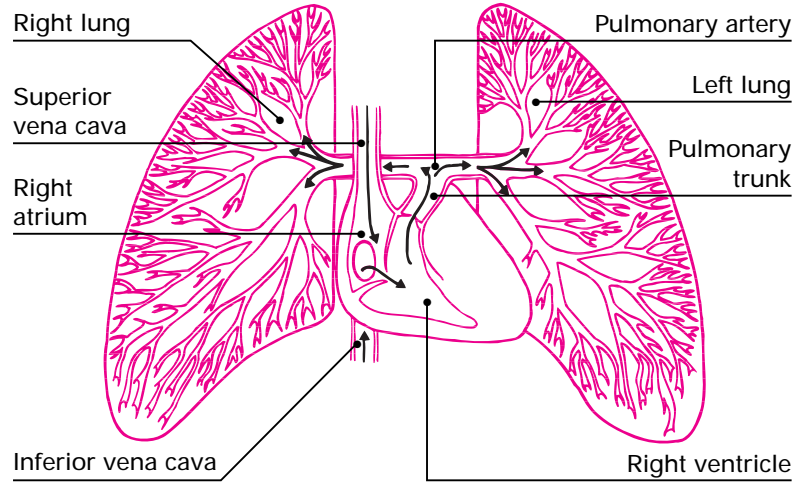
Circulation facts

- The neck is a vulnerable area because of the large blood vessels, airways, and nerves within it.
- A sinus is a cavity, channel, or depression.

Blood supply to the lungs

Pulmonary circulation is the supply of blood to and from the lungs. The pulmonary trunk and two pulmonary arteries carry deoxygenated blood from the right ventricle of the heart to the lungs. Gases are exchanged in the pulmonary capillaries and then four pulmonary veins (two from each lung) carry oxygenated blood from the lungs to the left atrium of the heart. Each pulmonary vein enters the heart through a separate opening.

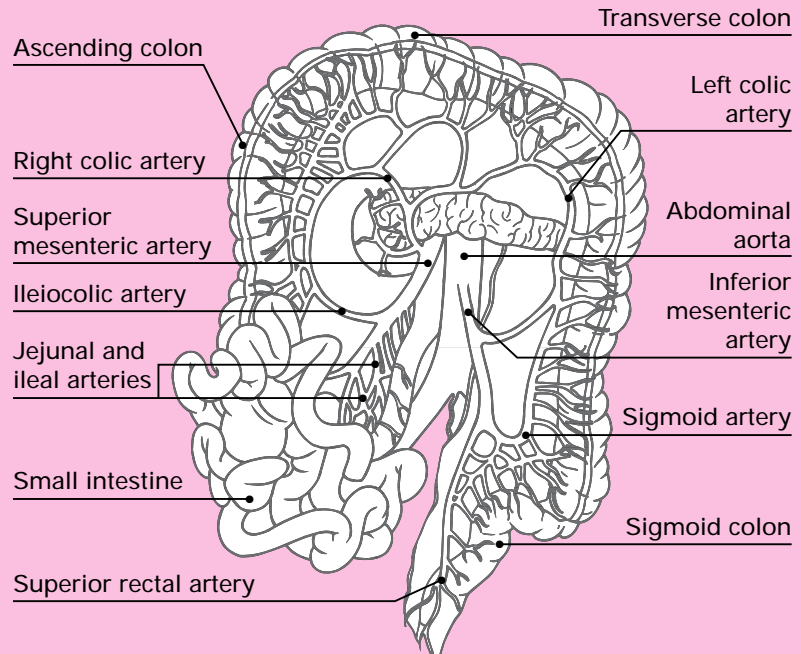
Circulation in right heart and pulmonary artery



Blood supply to the intestines

This diagram shows the blood supply to the intestines, which are coiled inside the abdomen. The small intestine (made up of the duodenum, jejunum, and ileum), and transverse colon (middle part of the large intestine), have been moved aside to show the arteries more clearly.

Front view of abdomen



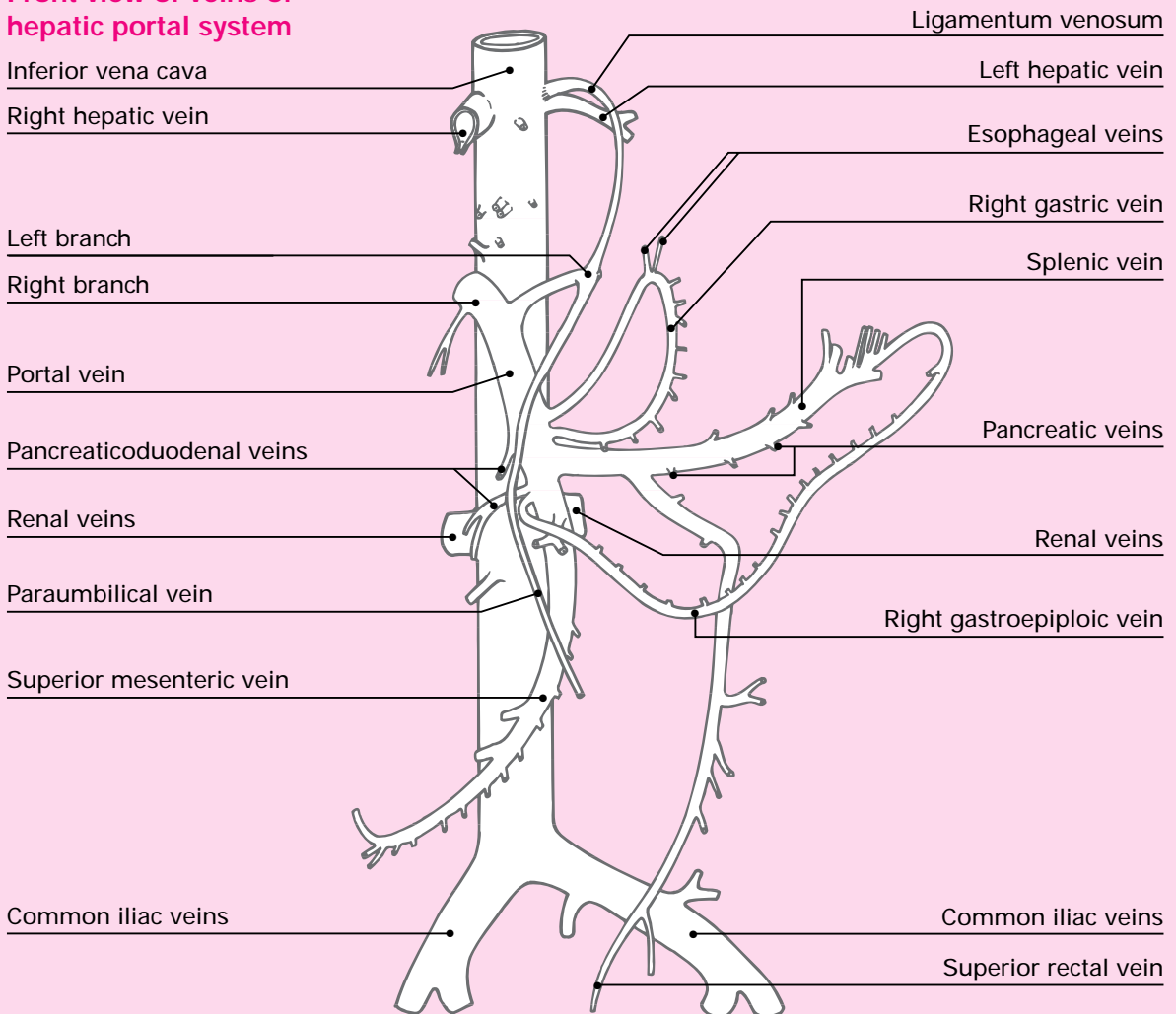
Blood supply to the liver

Veins from the stomach, spleen, pancreas, intestines, and gallbladder send their blood to the liver instead of to the inferior vena cava. The liver removes excess glucose and detoxifies any poisonous substances before sending the blood through the hepatic veins to the inferior vena cava. This means that blood passes through two capillary beds—one in the digestive organs and one in the liver.

Circulation facts

- There are two portal systems. One is in the liver and the other is in the brain, moving blood from the hypothalamus to the pituitary gland.

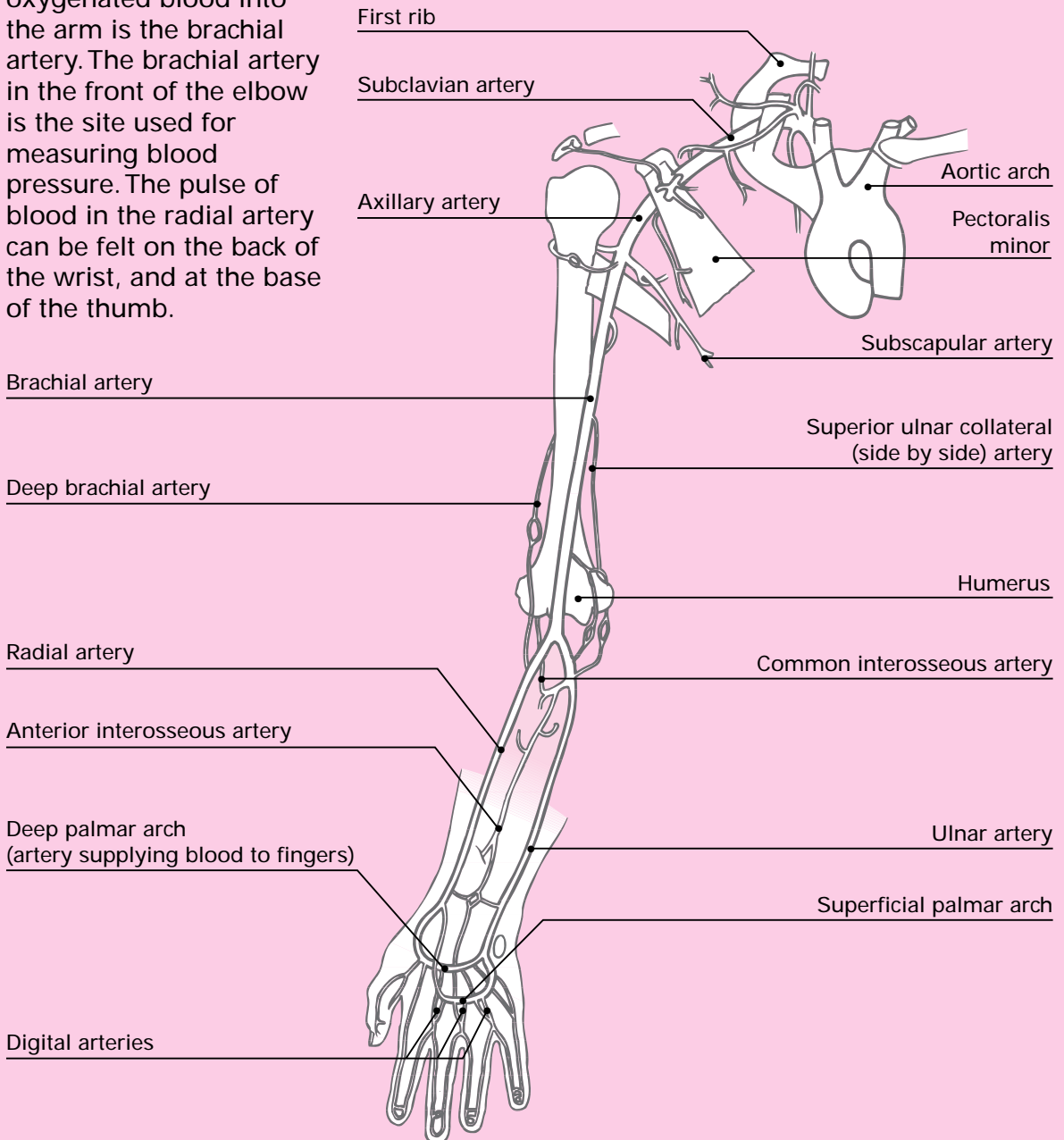
Front view of veins of hepatic portal system



Arteries of the arm

The main artery bringing oxygenated blood into the arm is the brachial artery. The brachial artery in the front of the elbow is the site used for measuring blood pressure. The pulse of blood in the radial artery can be felt on the back of the wrist, and at the base of the thumb.

Front view of right arm

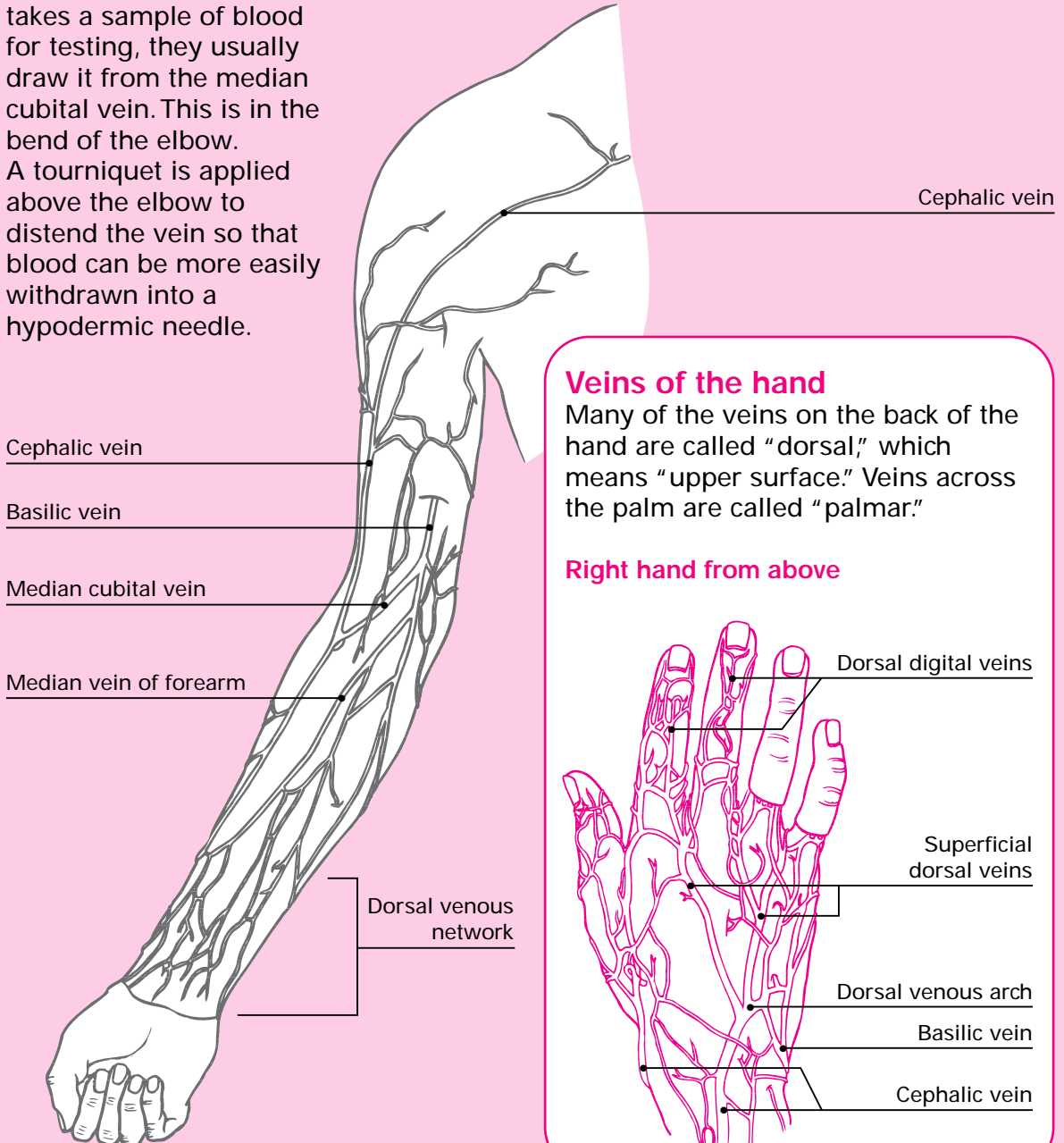


Sampling blood

When a doctor or nurse takes a sample of blood for testing, they usually draw it from the median cubital vein. This is in the bend of the elbow.

A tourniquet is applied above the elbow to distend the vein so that blood can be more easily withdrawn into a hypodermic needle.

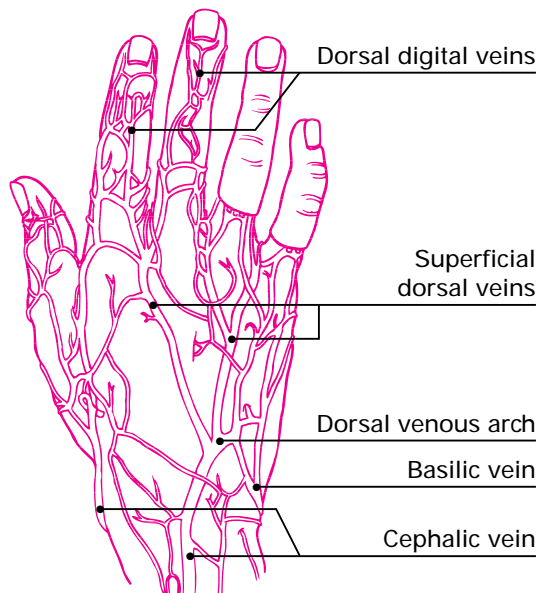
Veins of right arm (front view)



Veins of the hand

Many of the veins on the back of the hand are called "dorsal," which means "upper surface." Veins across the palm are called "palmar."

Right hand from above

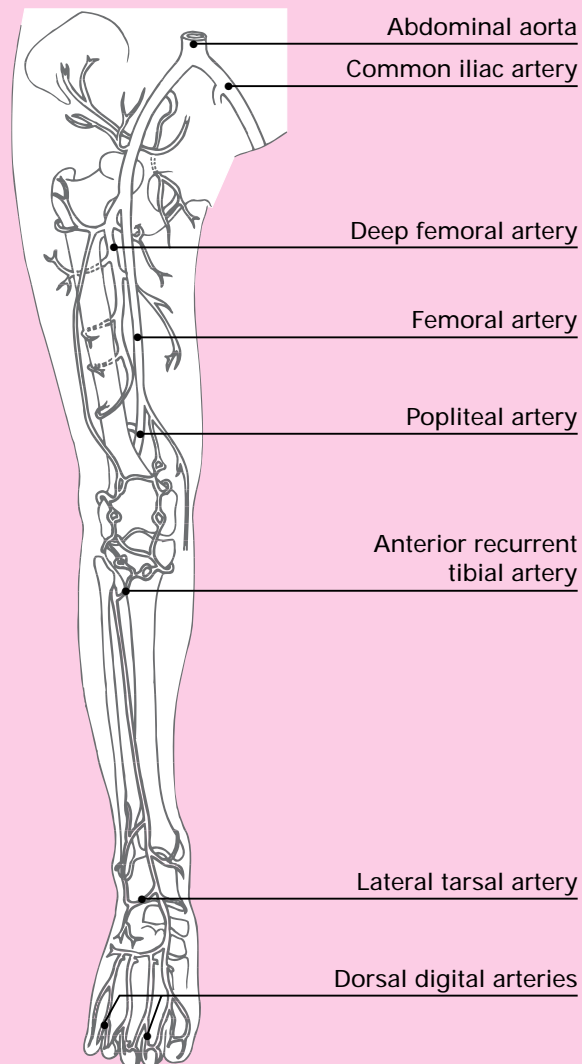


Arteries of the leg

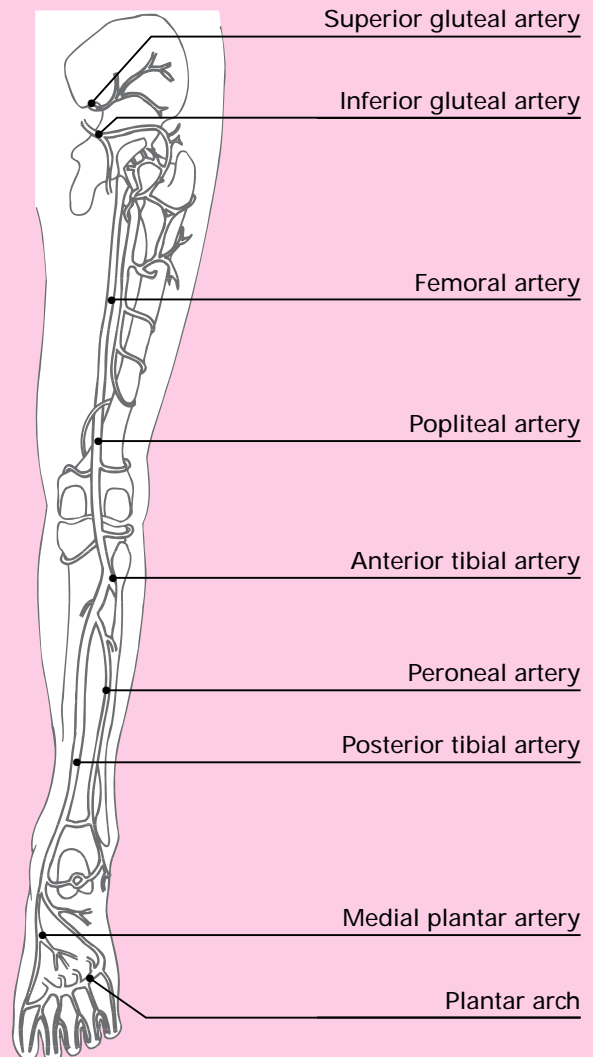
The external iliac artery brings oxygenated blood into the leg and becomes the femoral artery on the front of the thigh. The femoral artery becomes the popliteal artery on the back

of the knee. Just beyond the knee joint, the popliteal artery terminates by dividing into the tibial arteries. The anterior tibial artery continues over the ankle to become the dorsal foot artery.

Front view showing arteries



Back view showing arteries

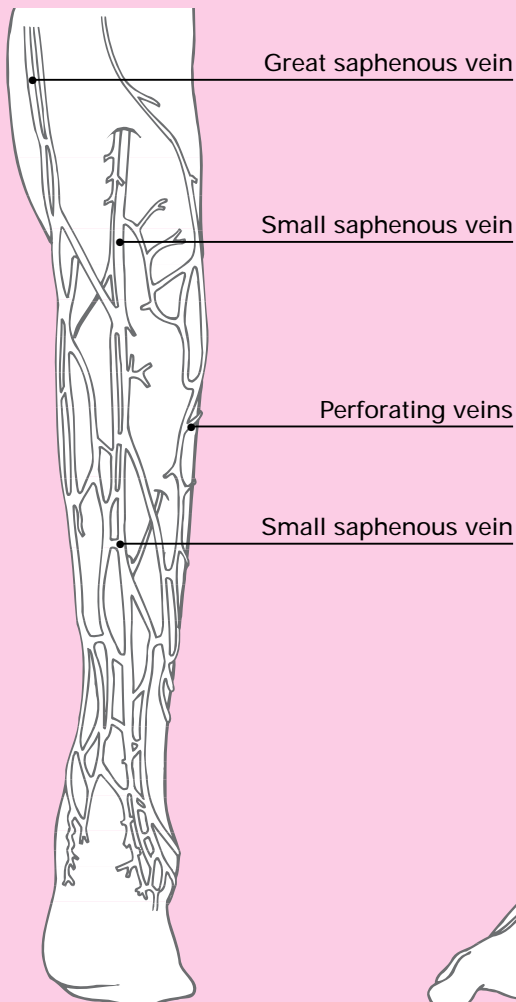


Veins of lower leg

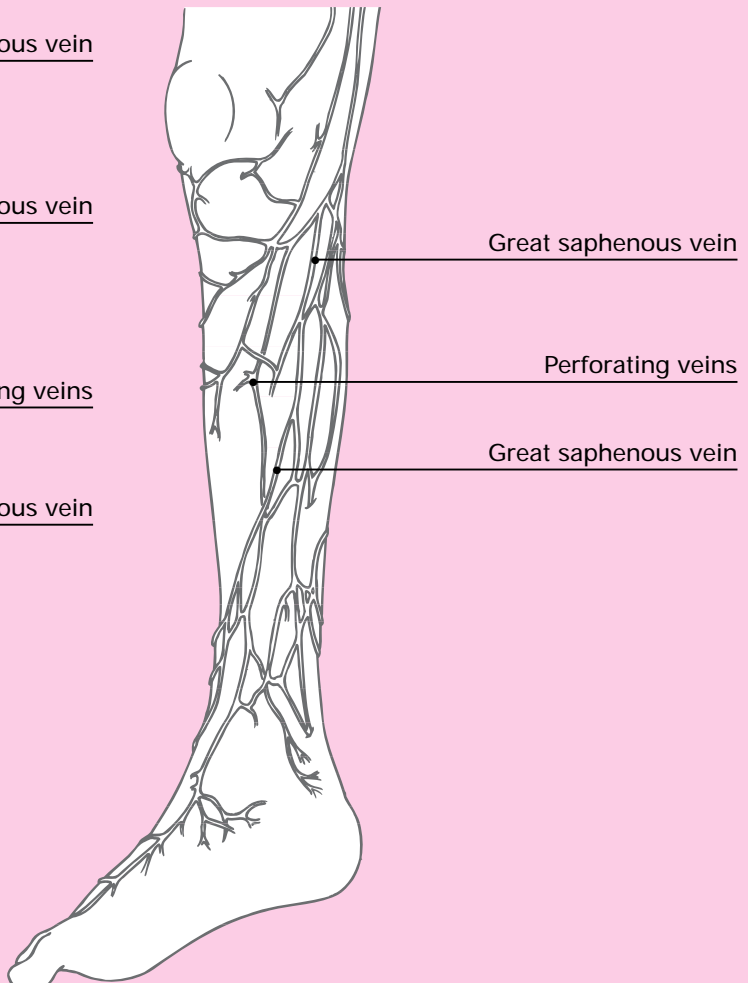
The superficial veins of the leg are the small saphenous vein and the great saphenous vein. The great saphenous vein stretches from the foot to the pelvis. The superficial veins are under

the skin but link with deep veins, such as the femoral vein and tibial veins. The femoral vein becomes the external iliac vein, which is the main tube draining blood back to the heart.

Back view showing superficial veins of lower leg



Side view showing superficial veins of lower leg



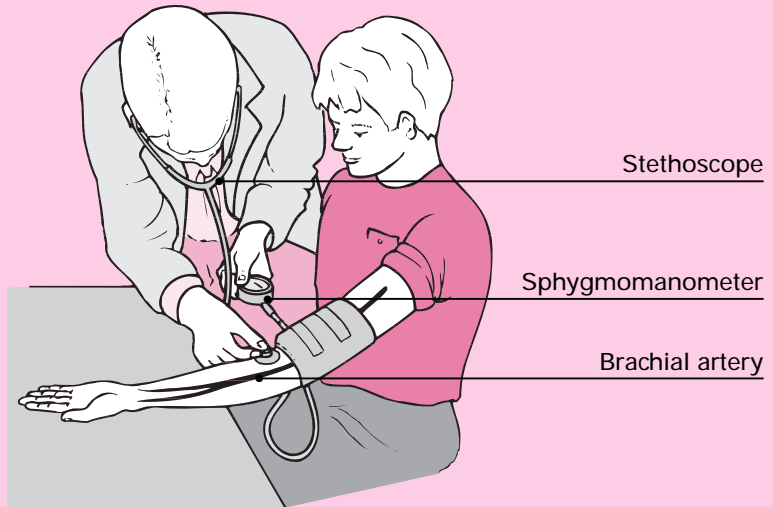
Understanding blood pressure

Blood pressure is the force per unit area exerted on the wall of blood vessels by blood within those vessels. It rises and falls under different conditions, such as sleeping, exercising, and periods of stress.

- Blood flows from a high-pressure region to a low-pressure region.
- Blood is forced through arteries by the contraction of the heart, and pressure is therefore higher in arteries than in veins.
- Larger blood vessels (such as main arteries like the aorta) have higher pressure than smaller vessels (such as capillaries) because the size of the vessel has an influence on the resistance to blood flow and the blood's velocity (speed).

Measuring pressure

- An inflatable cuff with a pressure gauge (a sphygmomanometer), and a stethoscope, can be used to measure blood pressure (see page 22 and diagram above). The sounds heard through the



stethoscope are called Korotkoff sounds and there are five phases: Initial “tapping” sound; sounds increase in intensity; sounds at maximum intensity; sounds become muffled; and, finally, sounds disappear.

- An oscillotonometer consists of two overlapping cuffs and allows blood pressure to be read without a stethoscope. The larger cuff works like the sphygmomanometer cuff, while the smaller cuff amplifies the pulses so these can be seen as movements of a needle on a pressure gauge.

Automatic blood pressure measurement

- Automatic devices work in a similar way to the oscillotonometer. One cuff is wrapped around the arm and the machine inflates this to a level greater than systolic pressure (when the heart contracts). As the cuff deflates slowly, a sensor measures the changes in the pressure of the cuff caused by the pulse.
- Electronic monitors can also be used to measure arterial blood pressure in critically ill patients by inserting a small tube directly into an artery, such as radial or brachial.

High and low blood pressure

Blood pressure varies during the day. It is usually highest in the morning or if someone is feeling anxious or stressed. The following factors can all contribute to high blood pressure: being overweight; drinking too much alcohol; eating too much salt; and lack of exercise. If you have a family history of high blood pressure, you have a greater chance of suffering from high blood pressure. Severe kidney disease can

also cause high blood pressure.

Low blood pressure does not usually produce any symptoms, although people may feel dizzy or faint when they stand after sitting or lying down. There is usually no need to treat low blood pressure, and people with low blood pressure tend to live longer than people with high, or even “normal” blood pressure.

Factors affecting blood pressure

Four major factors affect blood pressure.

- Cardiac output is the volume of blood pumped by the heart in one minute. If cardiac output increases (as when the heart beats faster during periods of excitement, for example), blood pressure increases. If cardiac output decreases (during periods of relaxation, for example), blood pressure decreases.
- Blood volume is the amount of blood in the body. When blood volume decreases (as a result of severe bleeding, for example), blood pressure decreases. When blood volume increases (as a result of a transfusion, for example), blood pressure rises.
- Peripheral resistance is the resistance that blood faces when traveling through arterioles (tiny arteries) and capillaries. Increased peripheral resistance (e.g. blood vessels constricted by tight muscles during periods of tension, for example) results in increased blood pressure. Reduced peripheral resistance (for example, when blood vessels dilate) results in reduced blood pressure.
- Viscosity is the “stickiness” of blood. If blood can flow smoothly through arteries and veins, pressure against the artery walls is relatively low. When blood becomes thick and sticky, the heart has to work harder to pump it around the body, and blood pressure rises.

Pulse

The pulse is the wave of pressure that is generated by the expansion and recoil of the arteries.

- As one pulse is transmitted with every heartbeat, the pulse can be used to measure heart rate.
- The pulse can be felt on any of the arteries that are close to the surface.
- The locations where the pulse is most easily taken are also known as pressure points.

Blood vessel and circulatory disorders

Aneurysm A blood-filled protrusion in the wall of a vein or an artery. If an aneurysm is not treated, the vessel will eventually burst, and if the vessel is in the brain, a stroke may occur.

Arteriosclerosis Term for a number of disorders (including atherosclerosis) that cause thickening and hardening of an artery, so that their walls lose their elasticity.

Atherosclerosis The main cause of coronary artery disease. Cholesterol and other deposits build up inside the walls of arteries, narrowing the lumen and reducing the elasticity of the vessel walls. This can cause heart attacks or prevent the heart from beating with a regular rhythm.

Chilblains Painful or itchy swellings that may occur on cold hands, feet, or ears because of poor circulation.

Clotting Blood clots may form if vessels are roughened by deposits or injured by accident, surgery, or childbirth.

Ecchymosis Hemorrhage (bleeding) within the skin that causes a discolored, sometimes bluish, patch; a bruise.

Embolus A blood clot that floats freely in the circulatory system and eventually blocks an artery.

Fainting Falling over or passing out caused by a briefly reduced blood flow to the brain.

Hemangioma A purplish birthmark resulting from abnormal blood vessel distribution.

Hemorrhoids Hemorrhoids (piles) are varicose veins that occur in the rectum and anus when faulty valves let blood flow the wrong way and pool. The surrounding vein swells and may grow inflamed.

Hypertension High blood pressure.

Symptoms include light-headedness, lethargy, morning headache, flushed face, and ringing in the ears. The causes of high blood pressure are often unknown, but some cases are caused by kidney disease.

Hypotension Low blood pressure.

Petechia A tiny spot in the skin caused by bleeding within the skin.

Pulmonary embolism A blockage of one of the arteries of the lungs.

Purpura Multiple points of bleeding within the skin. Characteristic of several disorders.

Raynaud's disease Sudden contraction of arteries in the fingers and toes.

Stroke Caused by a blocked or burst artery affecting the brain. Confusion, dizziness, slurred speech, or paralysis of limbs may mean that a stroke has occurred. In a severe attack, the person loses consciousness almost immediately. Recovery depends on age, general health, and the site and size of the damage. Treatment consists mainly of rest and careful nursing, physiotherapy, and (if needed) speech therapy. Drugs are sometimes used to lower blood pressure.

Thrombophlebitis A blood clot and inflammation that affects deep or surface leg veins. It often occurs in the bedridden, but exercising the legs helps to prevent it. Cramping pain and swelling in the calf may suggest deep-vein thrombosis, and requires medical treatment.

Varicose veins Swollen superficial veins in the legs caused by faulty valves. Blood pools in the veins, making them bulge (surrounding muscle prevents this happening to the deep veins).

Common leg problems

The illustration on the right plots the sites of some of the problems that commonly affect the legs.

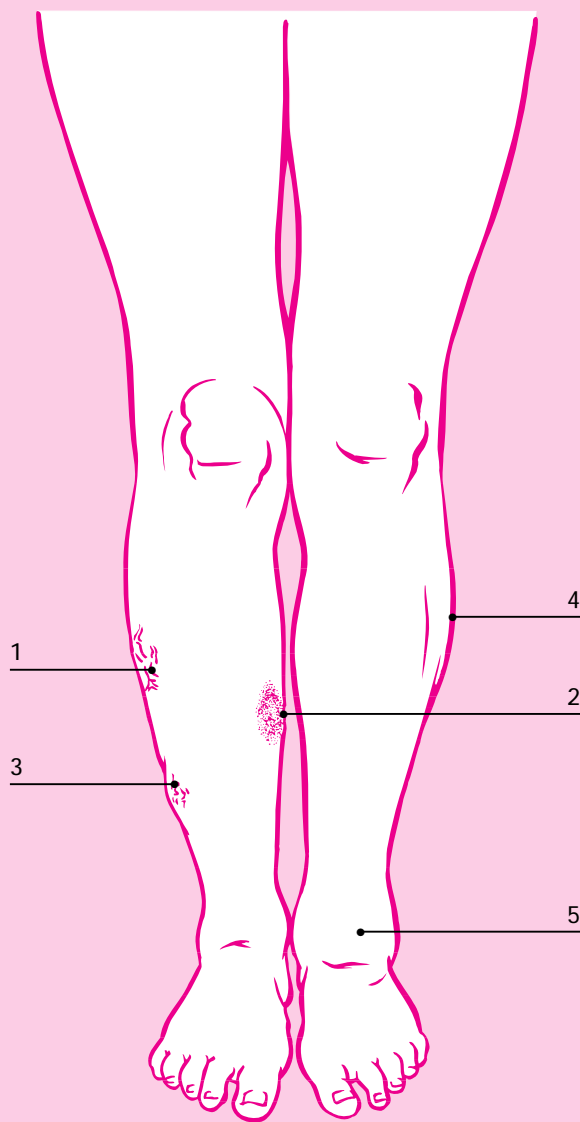
1 Varicose veins; these are engorged blood vessels that are no longer capable of helping to pump the blood up the leg.

2 Phlebitis; this condition is caused by the clotting of blood in the surface veins of the leg, and can have serious complications.

3 Varicose ulcer; ulcers of this type are usually caused by varicose veins, and involve breakdown of the surrounding tissue, and often intense itching.

4 Cramp; the intense pain of cramp is often experienced in the calves, and is caused by the muscle going into spasm. This may be because of a salt deficiency, or the legs may have been exercised earlier without allowing sufficient time for them to warm up and cool down.

5 Swollen ankles; the accumulation of fluid in the ankles causes them to swell and feel tender and heavy. Obesity, pregnancy, excessive water retention, lack of exercise, and heart failure are all contributory factors.



Circulation facts

- About 10 percent of people are born with faulty valves that may cause varicose veins if they stand for long periods so that the calf muscles cannot pump blood "uphill."
- The insides of the eyelids are usually pale if a person is anemic.

Blood is the fluid that is pumped around the body in the circulatory system. Most adults have about 10 pints (4.7 l) of blood, which makes up about seven to nine percent of their total body weight. The main functions of blood are the transportation of substances, the regulation of temperature, water content, and pH (acid-base balance), and the protection of the body against harmful “invaders” and disease.

Blood facts

- Blood really is thicker than water and flows four or five times more slowly.
- In a drop of blood, there are about five million red blood cells, 7,500 white blood cells and 300,000 platelets.

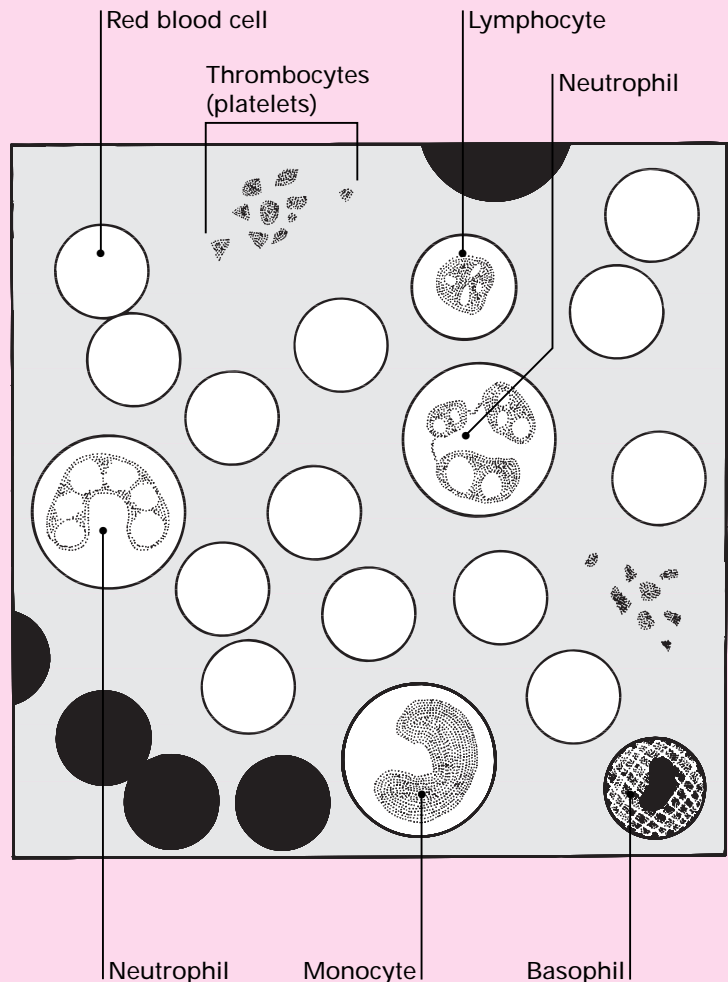
Blood components

The liquid part of blood is a clear, yellowish, watery fluid called plasma. This contains dissolved sugars, salts, wastes, body proteins, hormones, and other chemicals. Suspended in the plasma are red blood cells, white blood cells and platelets, which together make up the “formed elements” of blood. The red color of blood in the arteries is due to a protein called hemoglobin carried by red blood cells. Hemoglobin is bright red when transporting oxygen in the arteries and a darker bluish-red in the veins when it has given up its oxygen.

Red and white blood cells

Red blood cells transport oxygen and carbon dioxide, while white blood cells clean the blood, remove debris, and destroy microorganisms that invade the body. Red blood cells have no nuclei or internal organelles, but white blood cells are “complete” cells with nuclei and other internal structures. White blood cells with granules in their cytoplasm include neutrophils and basophils. Lymphocytes and monocytes have few granules.

Relative size and shape of the main components of blood



General blood cell formation

Red blood cells, white blood cells, and platelets are continually being destroyed, and the body must make new ones to take their place. Blood cell formation is called hematopoiesis or hemopoiesis. It occurs mainly in red bone marrow, which is found in the breastbone, ribs, and hipbones in adults. Some lymphocytes and monocytes are formed by lymphatic tissue, which is mainly in the lymph nodes, thymus, and spleen.

The formation of red blood cells

This is called erythropoiesis. Red blood cells carry oxygen. If the oxygen level of the blood drops (not the number of red cells), the body is stimulated to produce more red blood cells, i.e. more cells to carry oxygen. The oxygen level of the blood may drop because of:

- reduced numbers of cells (caused by excessive bleeding or excess red blood cell destruction);

- reduced availability of oxygen due to high altitudes or illness (such as pneumonia);
- increased demands for oxygen (common after aerobic exercise).

The life cycle of a red blood cell

1 A low level of oxygen in the blood stimulates the kidneys to produce a hormone called erythropoietin.

2 The level of erythropoietin rises.

3 This promotes the formation of red blood cells in red bone marrow.

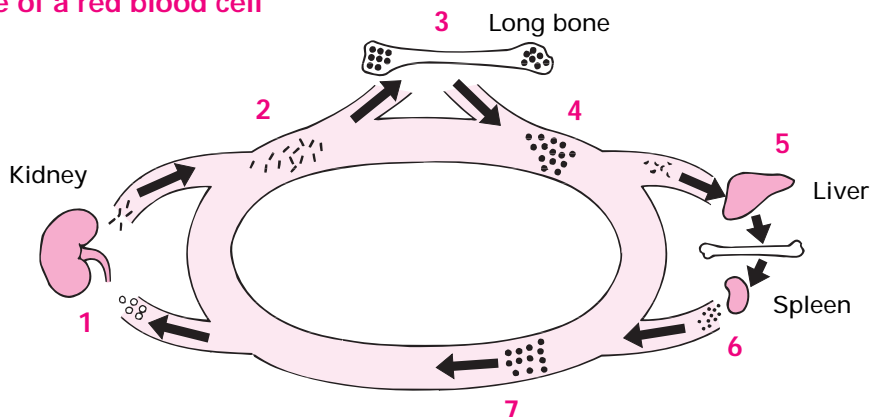
4 New red blood cells are released into the bloodstream.

5 Old and damaged red blood cells are engulfed by white blood cells living in the bone marrow, liver, and spleen. Hemoglobin (oxygen-carrying part of the cell) is broken down and reused.

6 This releases the raw materials for further red blood cell formation.

7 New red blood cells are released into the blood.

The life cycle of a red blood cell



Components

Blood is a special type of connective tissue in which formed elements (red and white blood cells) are suspended in plasma (a nonliving fluid). Relative percentages of blood components are: plasma (55%), white blood cells and platelets (1%), red blood cells (44%).

Formed elements

Erythrocytes (red blood cells).

Leukocytes (white blood cells).

Thrombocytes (platelets).

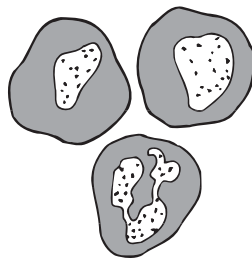
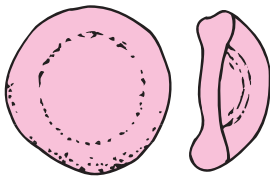
White blood cells include neutrophils, eosinophils, basophils, lymphocytes, and monocytes.

Plasma

This is the liquid portion of the blood. In addition to the formed elements, it contains:

- water;
- salts;
- proteins (for example, albumin, globulin, fibrinogen);
- nutrients;
- waste products; and
- hormones.

Erythrocytes
(red blood cells)



Leukocytes
(white blood cells)

Thrombocytes
(platelets)



Functions

Transport

- Carries oxygen and nutrients to cells.
- Transports waste gases (e.g. carbon dioxide) from cells to the lungs to be expelled.
- Transports wastes from cells to the kidneys to be eliminated.
- Carries hormones from the endocrine glands to where they are needed.

Regulation

- Regulates body temperature by dissipating heat from active areas (such as muscles).
- Helps regulate the water content of cells.
- Contains buffers that keep pH levels in tissues normal.

Protection

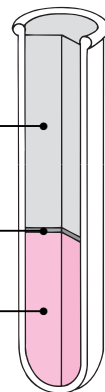
- Clotting helps prevent hemorrhage when blood vessels are damaged.
- Certain white blood cells help protect against harmful microorganisms by engulfing them.
- Antibodies in plasma help protect against disease.

Blood components



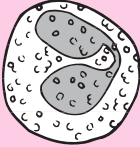

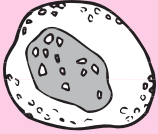


Plasma

White cells
and platelets

Red cells



Types of blood cell

Cell type		Functions	Number per drop of blood	Lifespan
Erythrocytes (red blood cells)		• Transport oxygen and carbon dioxide	4–6 million	100–200 days (120 average)
Leukocytes (white blood cells)		• Engulf bacteria	3,000–7,000	6 hours— several days
Granulocytes Neutrophils				
Eosinophils		• Kill parasitic worms • Counteract allergic reactions	100–400	8–12 days
Basophils		• Release histamine and anticoagulant heparin	20–50	few hours— several days
Agranulocytes Lymphocytes		• Produce antibodies and assist with immune response	1,500–3,000	hours—years
Monocytes		• Engulf bacteria	100–700	months
Platelets		• Assist blood clotting	250,000–500,000	5–10 days

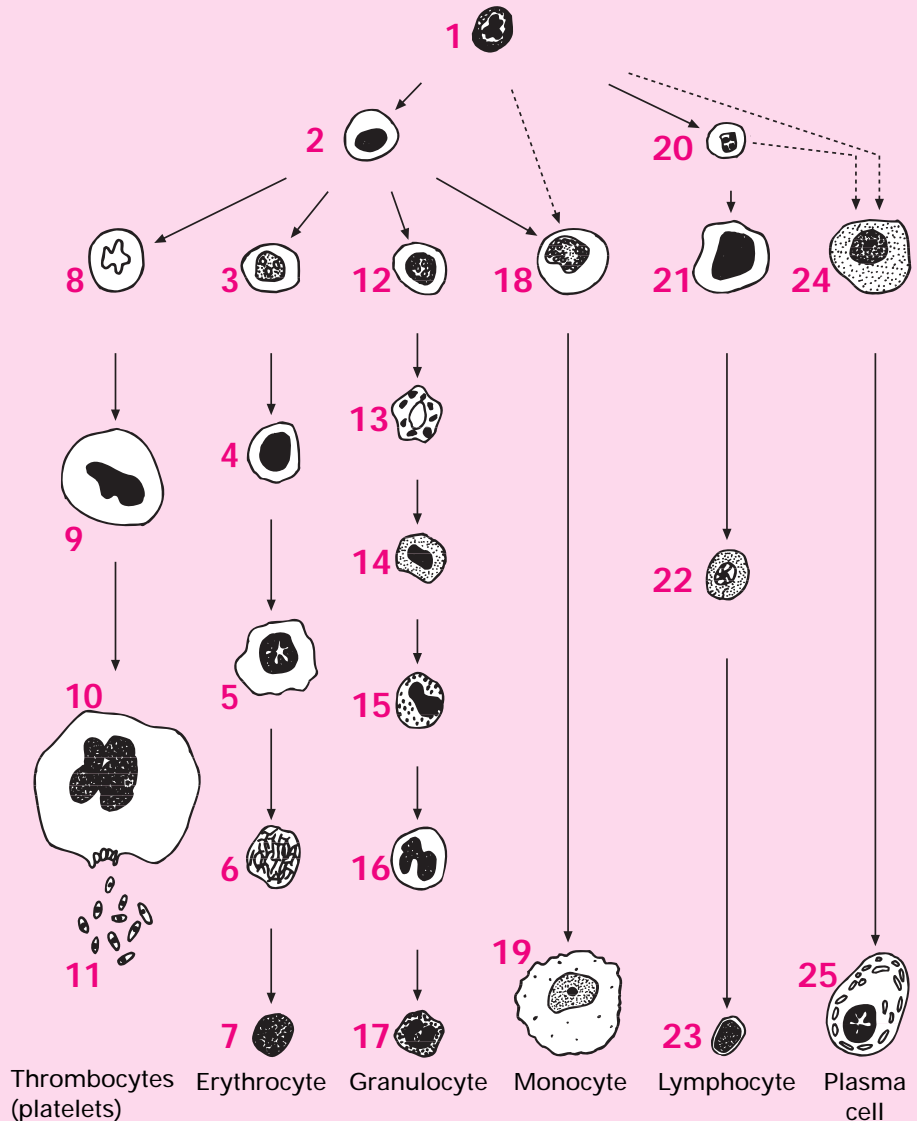
Blood cell development

All blood cells arise from the same type of stem cell called a hematopoietic stem cell or hemocytoblast. The diagram below shows the stages in development of the different components of blood. From left to right these are: platelets, red

blood cells, white blood cells, and plasma cells. The granulocyte white blood cells (neutrophils, basophils, and eosinophils) have multilobed nuclei, whereas monocytes and lymphocytes have single nuclei.

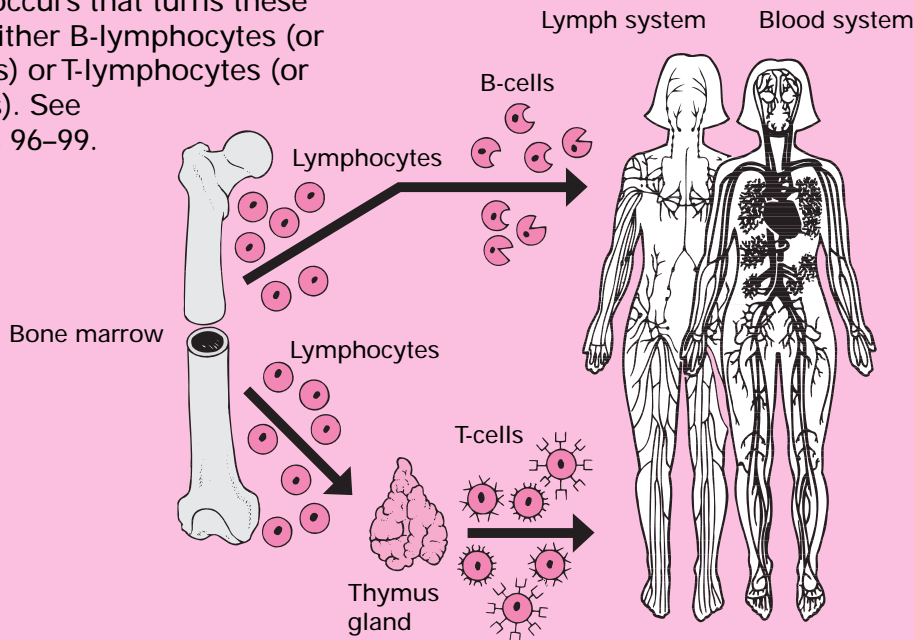
Key to diagram

1–7 Formation of red blood cells. Hemocytoblasts (1) differentiate into erythroblasts (4), which make hemoglobin. The erythroblast loses its nucleus and becomes an immature red blood cell called a reticulocyte (6). This enters the bloodstream, loses its cell organelles and matures into an erythrocyte (7).
8–11 Platelets formed by fragmentation.
12–17 Formation of granulocytes.
18–19 Formation of monocytes.
20–23 Formation of lymphocytes.
24–25 Immature and mature plasma cells.



Lymphocyte development

Lymphocytes are small white blood cells with few granules in their cytoplasm, and a large, round nucleus that takes up most of the cell. All lymphocytes originate in the bone marrow. During fetal development, only one type of immature lymphocyte is produced by the bone marrow. A process of differentiation then occurs that turns these into either B-lymphocytes (or B-cells) or T-lymphocytes (or T-cells). See pages 96–99.



B-lymphocytes

Those lymphocytes that are to become B-cells (white blood cells that produce antibodies) probably remain in the bone marrow. Here, the cells duplicate and learn how to recognize one specific antigen (substance that provokes an immune response). The mature B-cells then travel to the lymphatic system and blood system. When B-cells are activated, they enlarge and become plasma cells.

T-lymphocytes

Those lymphocytes that are to become T-cells (white blood cells that attack and kill other cells) travel to the thymus gland (part of the lymphatic system). Here, the cells duplicate and learn how to recognize one specific

antigen. The mature T-cells then travel to the lymphatic system and blood system, where they circulate until called into action. Both B- and T- cells help to protect the body from its own defense system.

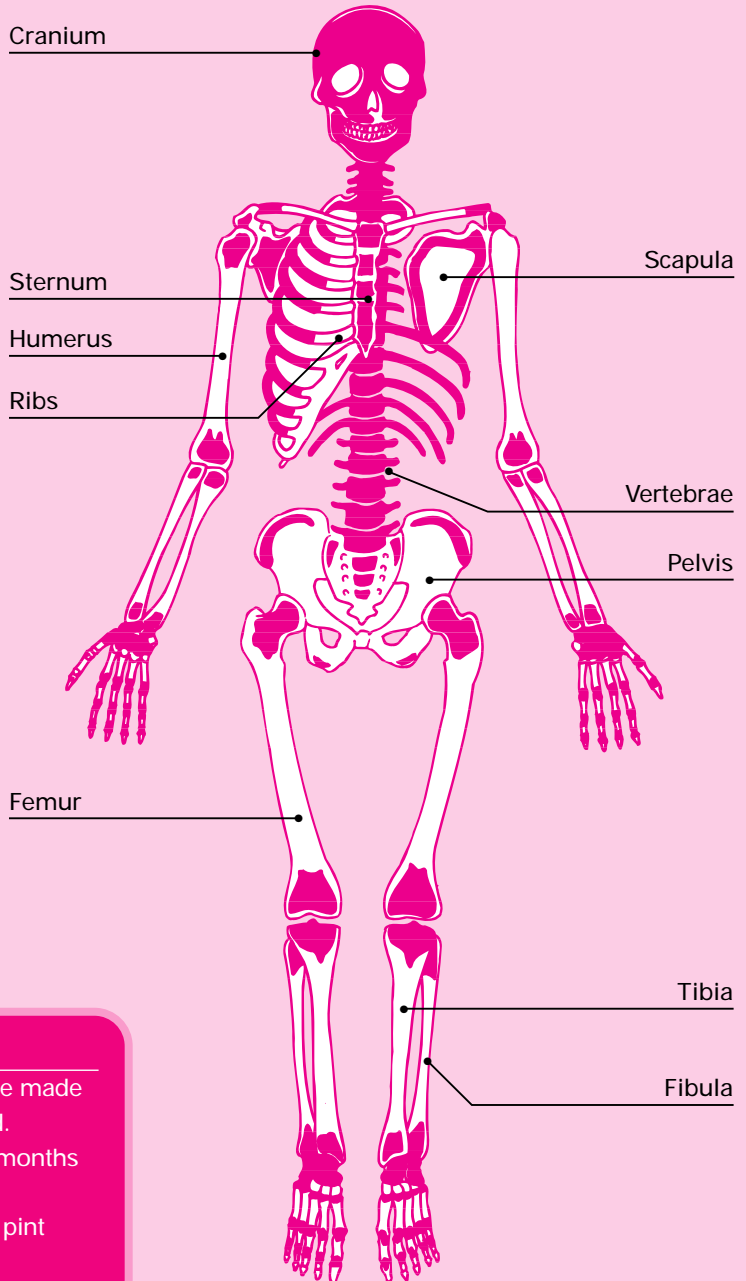
Bone marrow

Red bone marrow is soft connective tissue found inside some bones. It is the main blood-making tissue in an adult. At birth, all the bone marrow in the body is red marrow, but by adolescence, most of this is replaced by yellow marrow, which stores fat. Yellow marrow can produce red blood cells under stress, but does not normally do so. Red marrow in adults is found in the ends of long bones, such as the femur (thigh bone) and humerus (upper arm bone), where it fills in small spaces in the spongy bone. It is also found in some short bones, such as the sternum (breastbone), ribs, cranium (skull), and vertebrae.

Blood facts

- About 200 billion red blood cells are made daily—about 2.5 million per second.
- Red blood cells live for about four months before they break apart and die.
- The spleen may contain about one pint (more than 500 ml) of blood.

Sites of red bone marrow in an adult

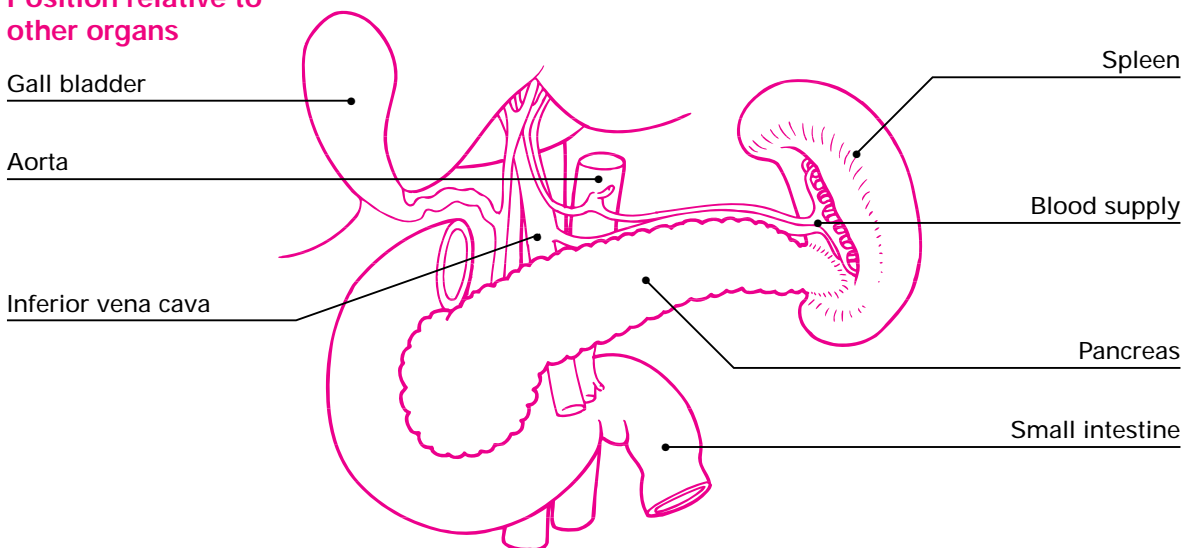


Spleen

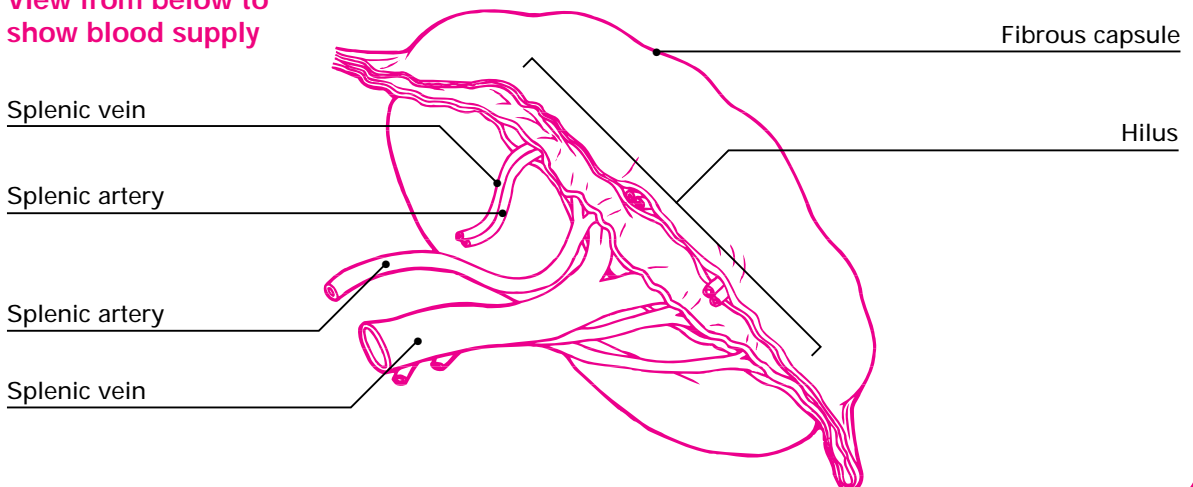
The spleen, located in the upper left abdomen, is the largest lymphoid gland in the body. It is made up of small islands of white pulp scattered throughout red pulp. The white pulp consists of masses of lymphocytes

surrounding small branches of the splenic artery. As blood flows through the pulp, old or damaged blood cells, debris, and bacteria are filtered out. The spleen also stores iron from the old red cells and serves as a reservoir for blood.

Position relative to other organs



View from below to show blood supply



Preventing blood loss

Since much of the blood in the circulatory system is under high pressure, serious loss of blood can occur after an injury. The body has three ways of preventing uncontrolled bleeding. These are:

- the constriction of blood vessel walls to restrict the flow of blood;
- the clumping together of platelets to form platelet plugs (platelet aggregation); and
- the process of blood clotting.

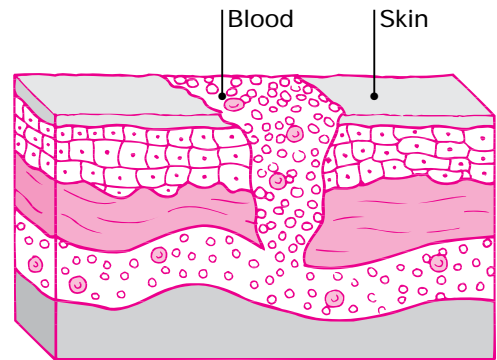
Clotting is essential for the healing of wounds, but it is life threatening if it occurs in an unbroken blood vessel and obstructs the flow of blood to a vital organ, such as the heart.

Blood clotting

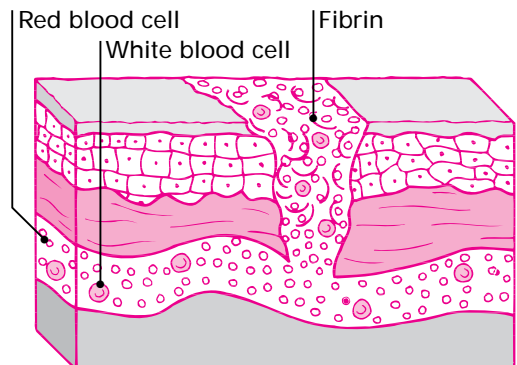
Blood clotting prevents excessive blood loss from a wound. It involves converting blood from a liquid into a gel by means of a process called coagulation. This complicated process is a series of chemical reactions that involves more than 30 different substances. There are three main stages in the clotting process. Firstly, clotting factors are released by injured tissue cells and platelets. Secondly, chemical reactions form an insoluble mesh of fibrin threads across the injury. Thirdly, platelets and blood cells become trapped in the mesh. The jelly-like mass shrinks and serum oozes out, leaving a brittle lump, or "clot" over the wound. This seals off the leak while the damage is repaired underneath.

How a blood clot forms

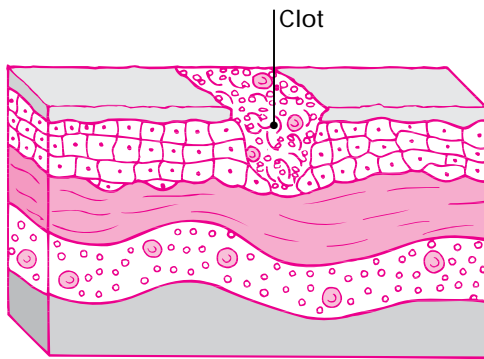
1 When the skin is cut, blood wells to the surface. Platelets (tiny blood cells) accumulate at the site of injury. An enzyme called thromboplastin is released into the blood. This activates a series of reactions to produce a protein called thrombin.



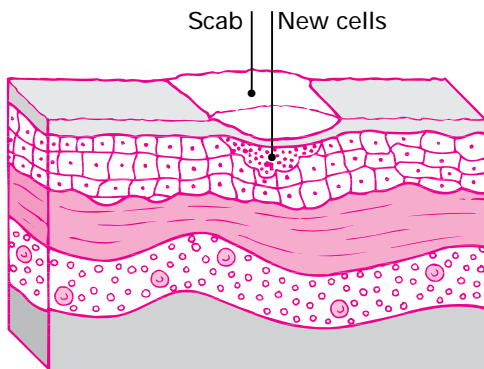
2 Thrombin interacts with fibrinogen (a soluble protein), also present in blood, to make the insoluble protein fibrin. Fibrin forms microscopic threads, which trap red and white blood cells and platelets to form a clot that seals the opening of the wound.



3 A new clot is 99 percent water but it soon contracts and dries out. The mesh of fibrin threads and the dead blood cells harden to form a scab. This prevents further blood loss and helps to stop bacteria and other germs from infecting the wound.



4 Beneath the scab, new cells form. Once the old, damaged cells have been replaced, the scab drops off. If the scab is removed before this process has been completed, further bleeding may occur and a new scab may form to seal and protect the wound.



Bleeding

Clotting factors in the blood usually seal a small cut quickly. It may help if you press a clean cloth pad (such as a folded handkerchief) against the wound. If bleeding persists, add more layers of cloth, increasing the pressure and keeping the injured part still. A clot should form within about five minutes.

To stop heavy bleeding, press the wound edges together with a clean cloth or even your fingers (provided they are clean and free from cuts and abrasions), and raise the cut limb. Prevent shock by lying the patient down with his or her feet above head level. If possible, clean a small wound with antiseptic, and sterile gauze swabs. Then cover it with clean gauze kept in place by a bandage or adhesive tape, and seek medical aid.



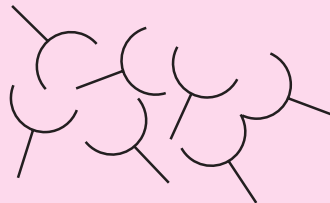
Press a pad against the wound

Antigens and antibodies


Blood is grouped according to specific antigens and antibodies related to red blood cells. Many antibodies react with antigens to make them clump together, or agglutinate. Two antigens (A and B) on the surface of some red blood cells are referred to as agglutinin A and agglutinin B.

Blood plasma contains antibodies that may react with agglutinin A or agglutinin B to make the red blood cells agglutinate or break down.

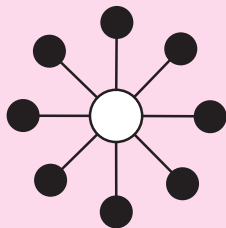
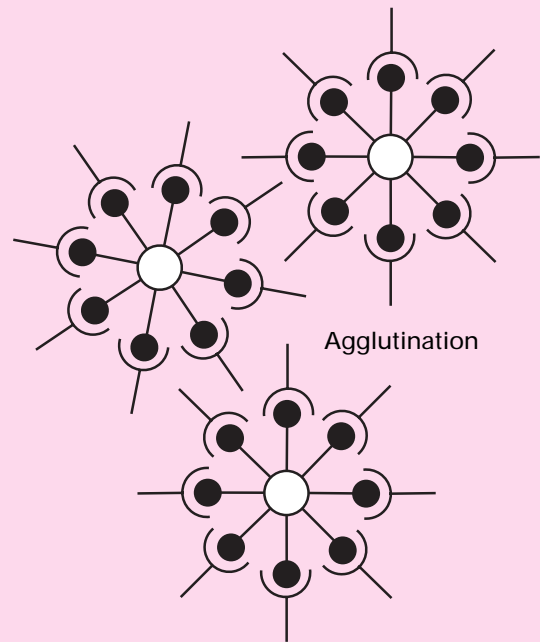
The reaction of antibodies to agglutinogens



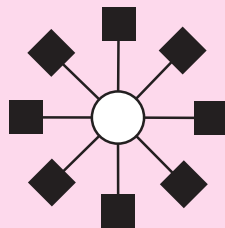
Anti-A antibodies



Anti-B antibodies



Agglutinin A



Agglutinin B

Anti-A antibody attacks agglutinin A, while anti-B antibody attacks agglutinin B. The blood does not contain antibodies to attack its own red blood cells. But if a person is given a blood transfusion of

blood with a different agglutinin, the antibodies will attack the agglutinin on the "foreign" blood. This can lead to harmful effects such as fever, jaundice, kidney failure and even, in some cases, death.

Blood facts

- When blood is transfused (transferred) from one person to another, the Rh type and blood group type must be matched very carefully.

Blood typing

Putting blood into different groups is called blood typing. There are four blood groups (types): A, B, AB, and O. They are named according to the agglutinogens on the red blood cells.

This table shows that people with type A blood have agglutininogen A and anti-B antibody; people with type B blood have agglutininogen B and anti-A antibody; people with type AB blood have agglutinogens A and B but neither anti-A nor anti-B antibodies; and people with type O blood have neither agglutinogens A nor B but do have anti-A and anti-B antibodies.

Blood group	Agglutininogen	Antibody
Type A	A	anti-B
Type B	B	anti-A
Type AB	A and B	neither
Type O	neither	both

People with type O blood are called “universal donors” as their blood can be given to people of any blood group.

The Rh factor

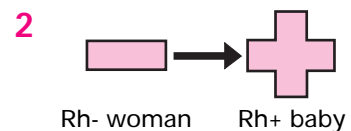
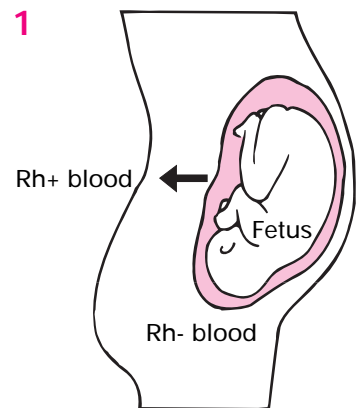
This was first studied in rhesus monkeys (hence the name). It is similar to the ABO blood grouping system in that it is based on the agglutinogens (substances that promote blood clotting) present on the surface of some red blood cells. People are Rh positive (Rh+) if they have Rh agglutinogens. People without Rh agglutinogens are termed Rh negative (Rh-).

Hemolytic disease

The process of red blood cell destruction in a fetus is called hemolytic disease. It affects newborn babies with Rh+ blood whose mothers have Rh- blood.

1 If Rh+ blood from a fetus mixes with a mother's Rh- blood (through a damaged blood vessel for instance), the mother develops anti-Rh agglutinins (antibodies).

2 During another pregnancy with a Rh+ fetus, the anti-Rh agglutinins pass through the placenta, from the mother to the fetus. This causes agglutination of the fetus's red blood cells, damaging the unborn baby.

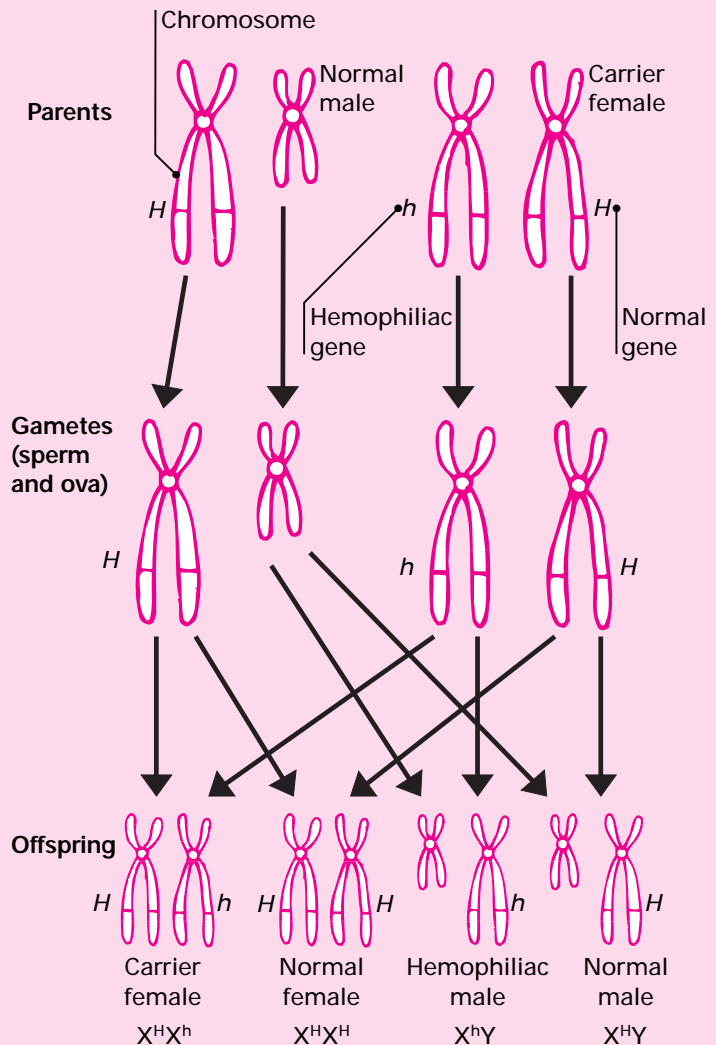


Hemophilia

A person with hemophilia lacks a protein needed to make blood clot quickly, so a minor injury may result in profuse bleeding that is life-threatening. Certain forms of hemophilia are sex-linked, and are caused by a recessive gene (h) on the X (female) chromosome.

Inheriting hemophilia

A woman has two X chromosomes. If she has a single hemophilia gene (genotype $X^H X^h$), she is a carrier for hemophilia, but she does not have the condition herself. Her second X chromosome bears a normal gene (H, which codes for the vital blood-clotting protein). A man has one X and one Y chromosome. If he has only one hemophilia gene (genotype $X^h Y$), this will be expressed and he will have the condition.



Blood facts

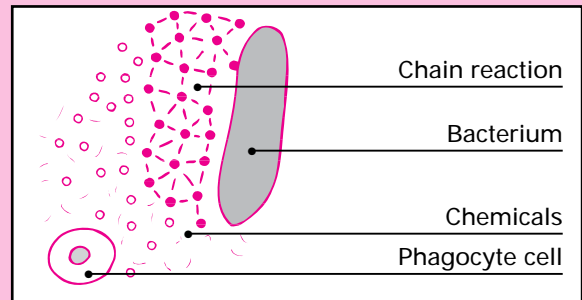
- There is no known permanent cure for hemophilia.
- Sickle cell anemia affects one in 500 African Americans.
- There are about 100 blood antigen systems in addition to the ABO and Rh systems.

Hemophiliac females

For a woman to suffer from hemophilia, she needs to have two hemophilia genes ($X^h X^h$), one on each X chromosome. She would need to inherit the gene from both her parents. This is less likely than inheriting one gene from one parent, and is the reason why fewer women suffer from hemophilia than men.

Chemical defenses

Complement is a group of proteins that circulates in the blood in an inactive form. One of the proteins in the group is activated if it contacts a foreign particle or bacterium. The activated protein sets off a chain reaction that activates the others in the group. During this stage, chemicals are released that attract phagocytic (“engulfing”) cells (see diagram). Also, other chemicals are released that cause the wall of the foreign cell to become sticky. This makes it easier for the phagocytes to grip and engulf the foreign cell. Meanwhile,



complement attaches itself to the remaining foreign cells, forming holes in the surfaces of the cells. Water passes into the foreign cells, forcing them to burst.

Sickle-cell anemia

Sickle-cell anemia is a serious hereditary disease caused by an abnormal form of hemoglobin. It causes the red blood cells to become rigid, rough, and crescent-shaped like a sickle, instead of the normal disk. Sick cells do not carry or release oxygen as well as normal red blood cells. They clog capillaries and other small blood vessels, reducing blood supply to some tissues, and causing swelling, pain, and tissue destruction.

A person who inherits only one defective gene develops a form of the disease called sickle-cell trait. Most people with sickle-cell trait have no symptoms of the disease. On the other hand, if two defective genes are inherited, more of the defective hemoglobin is produced and the blood cells become severely distorted.

Symptoms of this form of the disease include chronic anemia (caused by destruction of red cells), fatigue, bone and kidney changes (such as decreased bone marrow activity), increased susceptibility to infection, stroke (especially in children), and even death. Geneticists believe that sickle-cell anemia is an adaptation to coping with malaria, since sickle-cell anemia provides resistance to malaria. When the red cells of a person with sickle-cell anemia are invaded by the malarial parasite, they stick to blood vessel walls, become deoxygenated, take on the sickle shape, and are then destroyed. The malarial parasite is destroyed, along with the sickle cells. People with sickle-cell anemia are usually black, and can trace their hereditary origins to places where malaria is a problem.

The lymphatic system is a network of vessels and organs that drains lymph from all over the body back into the blood. Lymph is a body fluid that contains lymphocytes (white blood cells), proteins, and fats. This is a drainage system that works alongside the cardiovascular system (heart and blood vessels). The lymphatic system is also important to the immune system, the body's natural defense.

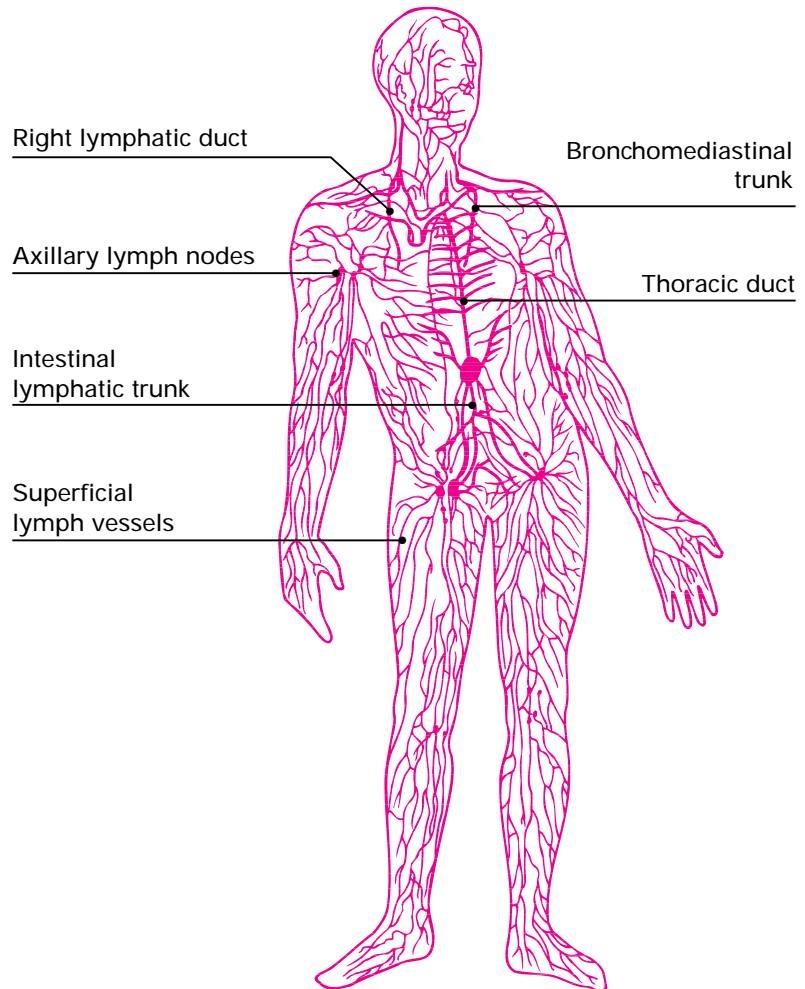
Lymph facts

- The largest lymph vessels are the lymphatic ducts: the right lymphatic duct and the thoracic duct.
- Lymphatic capillaries are more porous than blood capillaries and let through larger molecules.

Lymph vessels

Lymph vessels are blind-ended and run parallel to veins and arteries. They are thin-walled and, like veins, the larger vessels have valves that prevent backflow. The valves give these vessels a beaded appearance. The flow of lymph relies on pressure supplied by muscle action and breathing. In addition, the muscles of the lymph vessel walls contract to help move lymph through the system.

The lymphatic system does not have a pump comparable to the heart. Lymph ducts divide into lymphatic trunks, again into lymphatic vessels, and finally into lymphatic capillaries. Unlike blood, lymph does not flow through the system in a continuous loop.

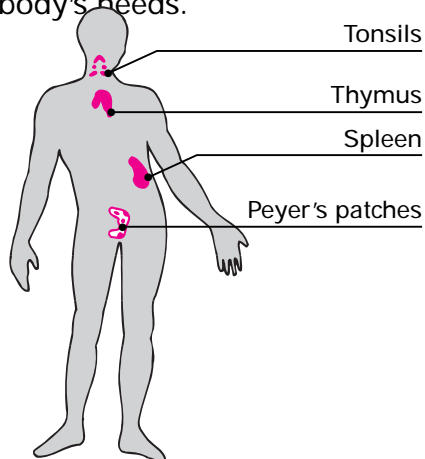


Lymph nodes

Some lymph vessels contain enlargements called lymph nodes. These contain cells that remove bacteria and help with the immune response; they are essential to the functioning of the immune system.

Other lymphatic organs

Other organs involved in the lymphatic system are the spleen, the thymus, and the tonsils. Peyer's patches and MALT (mucosa-associated lymphatic tissue) are important lymphatic tissues. The spleen filters and cleanses blood, destroying worn-out or damaged blood cells and returning their products to the liver for reuse. It also acts as an organ of blood-cell formation if the bone marrow is unable to produce enough to meet the body's needs.



LYMPHATIC SYSTEM: KEY WORDS

Axillary lymph nodes

The lymph nodes located in the armpit.

Cisterna chyli An enlarged part of the thoracic duct that receives lymph from several lymphatic vessels.

Cubital lymph nodes

The lymph nodes at the elbow.

Immune system The body's defense system against infective organisms or other foreign bodies. It includes the lymphatic system.

Immunoblast

(or Lymphoblast) A nucleated precursor of a lymphocyte.

Inguinal lymph nodes

The lymph nodes in the groin area.

Lymph A transparent fluid that leaks from blood vessels into tissue spaces. It is collected by the lymphatic system.

Lymph ducts The largest lymph vessels: the right lymphatic duct and the thoracic duct.

Lymph gland See Lymph node.

Lymph node (or Lymph gland) One of the "knots" in the lymphatic

system, which contain lymphocytes and macrophages that filter the lymph passing through the nodes.

Lymph trunks Major lymph vessels, including the subclavian, jugular, and lumbar trunks.

Lymph vessels See Lymphatic system.

Lymphatic capillaries

The tiniest tubes of the lymphatic system. They are microscopic.

Lymphatic system

A network of lymph vessels and lymph nodes. Vessels collect lymph from body tissues and return it to the blood after harmful substances have been filtered out in the lymph nodes.

Lymphoblast See Immunoblast.

Lymphocyte A type of white blood cell that is formed in the lymph nodes and produces antibodies.

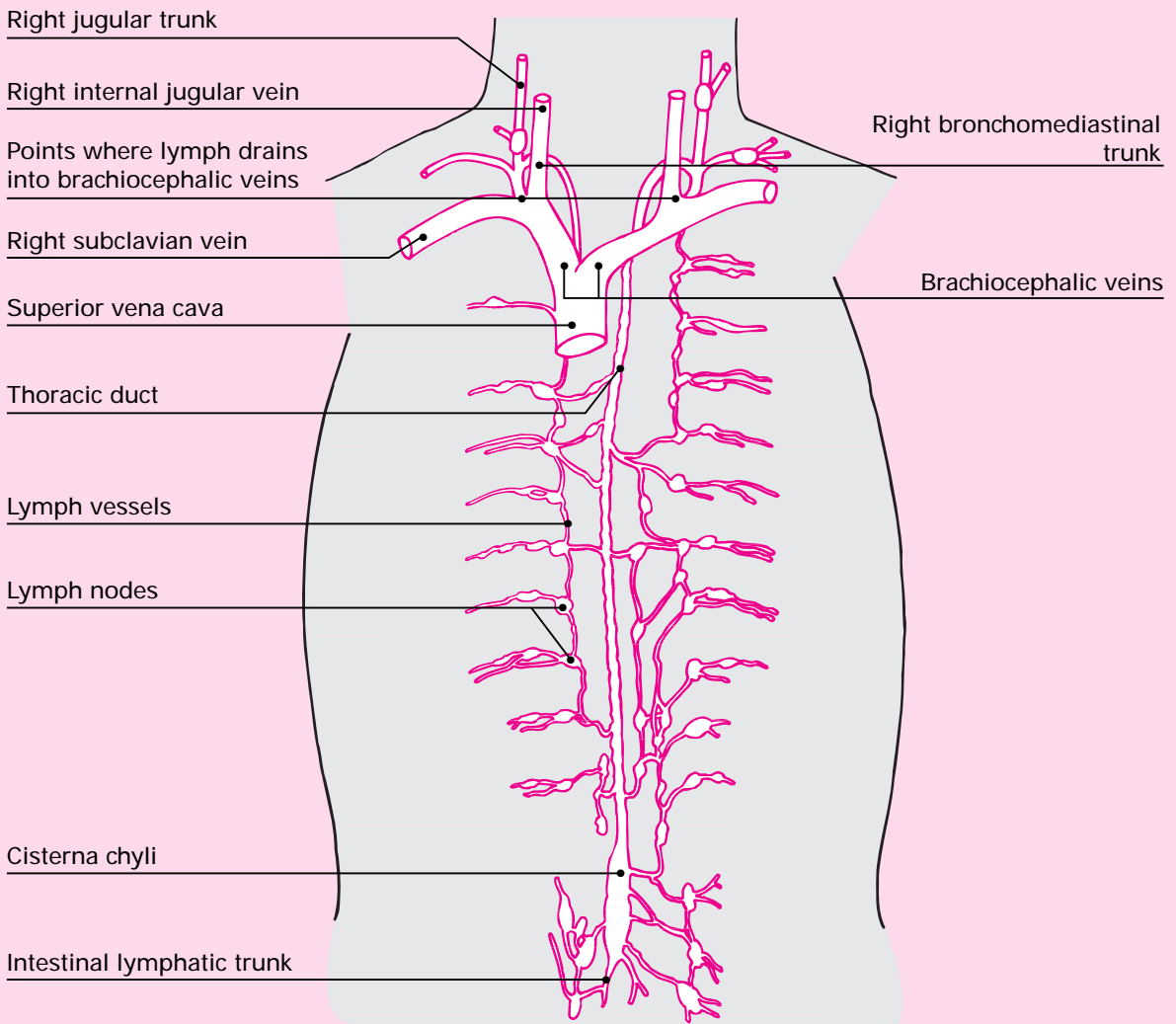
Macrophages Large cells that scavenge cell debris and foreign bodies. They occur mainly in connective and lymphatic tissue.

Lymphatic system

Cells of the body are bathed in interstitial, or tissue, fluid. Much of this fluid enters blood capillaries but the remainder enters the lymphatic system before it returns to the blood. It first enters the lymphatic capillaries. Then it

flows through increasingly larger lymph venules and veins. Finally, the fluid enters the right lymphatic duct or thoracic duct, which empty their contents into the subclavian veins of the blood circulatory system.

Major lymph vessels and their immediate tributaries



Lymph drainage

The right lymphatic duct drains lymph from the top right quadrant of the body. The thoracic duct drains lymph from the whole of the rest of the body. The cisterna chyli is a storage area for lymph

in the abdominal region of the thoracic duct. At major limb joints are clusters of lymph nodes (see page 88). Nodes vary in size from as small as a pinhead to over $\frac{2}{5}$ inch (10 mm) in diameter.

Front view

Lymph nodes are clustered in groups of up to 50 in the armpits and around the groin.

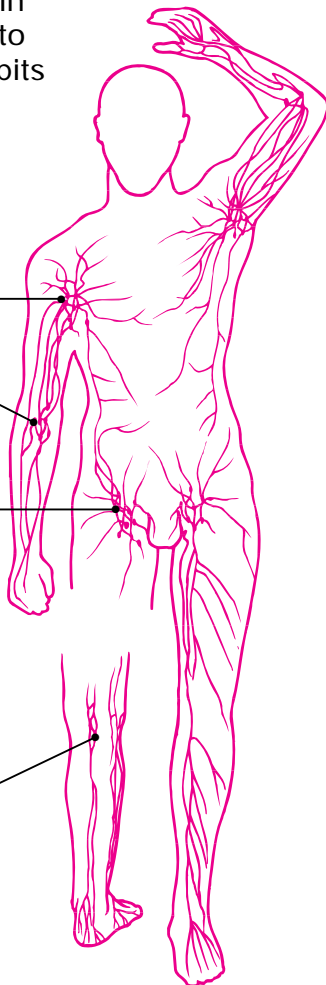
Axillary lymph nodes

Superficial cubital lymph nodes

Superficial inguinal lymph nodes

Rear view of leg

Superficial popliteal lymph nodes



Side view of head, neck, and trunk

Occipital lymph nodes

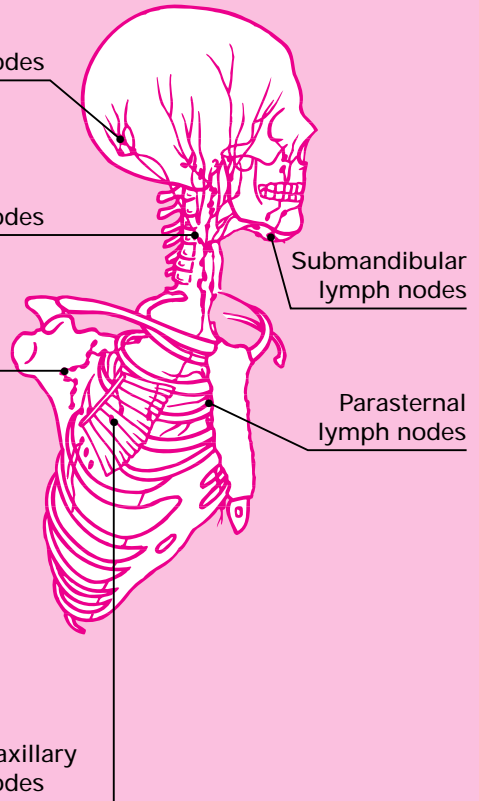
Cervical lymph nodes

Axillary lymph nodes

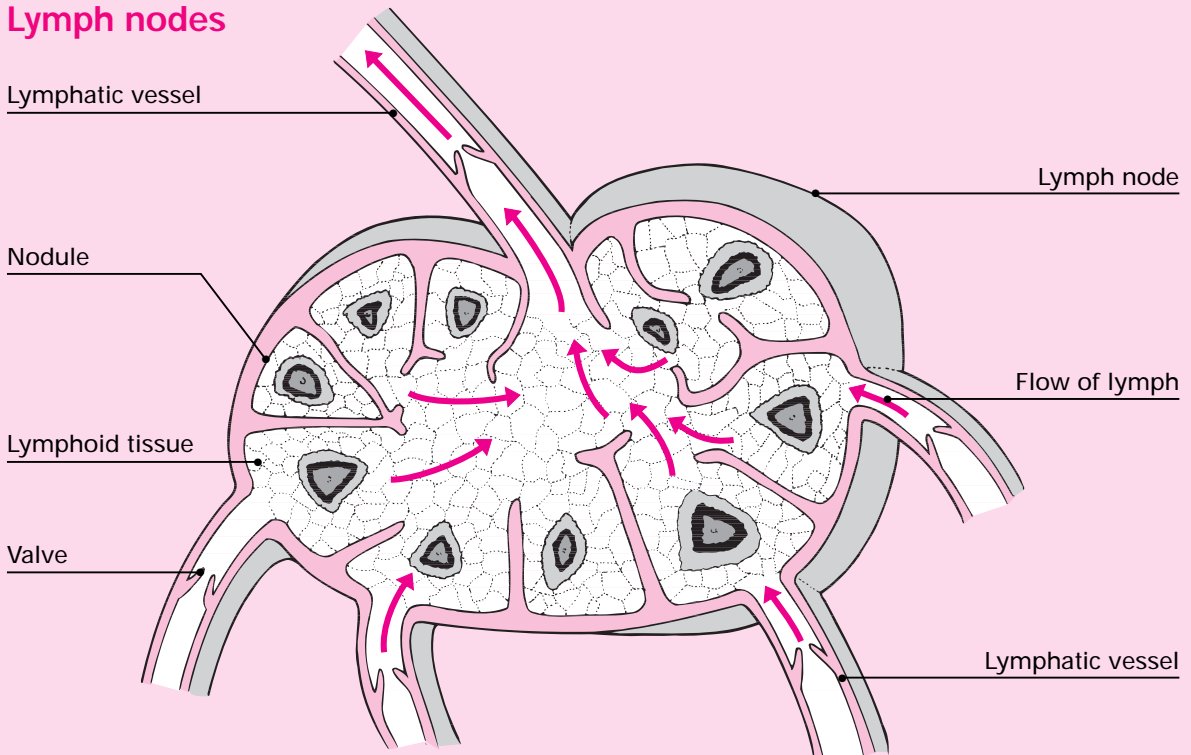
Submandibular lymph nodes

Parasternal lymph nodes

Pectoral axillary lymph nodes



Lymph nodes



Structure

- Lymph nodes (or glands) are small organs that lie along lymph vessels throughout the body. Clusters of them are also found in the groin, armpits, and neck.
- Each node consists of a fibrous outer bag containing lymphoid tissue. This is a dense mass of connective tissue that houses lymphocytes (white blood cells) and macrophages ("engulfing" white blood cells).
- Lymphoid tissue is grouped into nodules.
- Lymph enters and leaves the node through lymphatic vessels.
- Valves prevent the backflow of lymph.

Functions

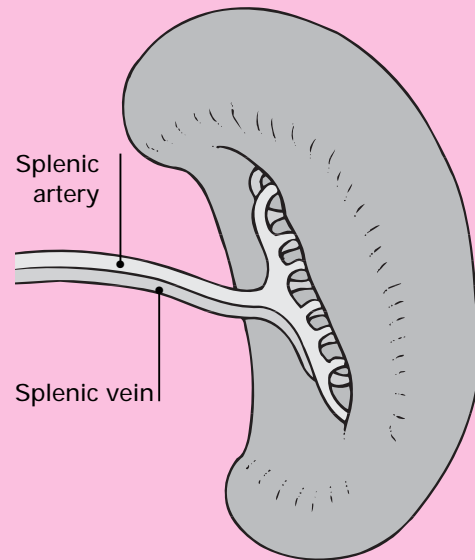
- Lymph nodes filter lymph. Infectious agents, damaged or cancerous cells, and other debris are trapped in the fibrous tissue.
- Lymphocytes and macrophages in the nodes cleanse lymph by destroying bacteria, viruses, and other harmful substances.
- When the nodes are busy fighting infection, large numbers of bacteria or viruses are trapped in them. This can cause the nodes to become swollen and painful.

Spleen

- The spleen resembles a lymph node in structure, but it is much larger.
- It is made of two types of tissue: red pulp and white pulp.
- Red pulp is lymphoid tissue largely comprising blood, lymphocytes (white blood cells), and macrophages ("engulfing" white blood cells).
- White pulp is mainly lymphocytes.
- Blood enters the spleen by the splenic artery and leaves through the splenic vein.

The main functions of the spleen are to:

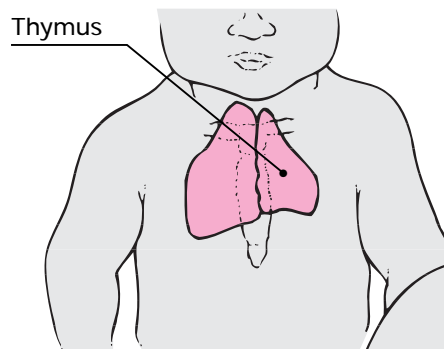
- filter the blood;
- produce lymphocytes; and
- house lymphocytes and macrophages, which destroy harmful substances and clear up debris.



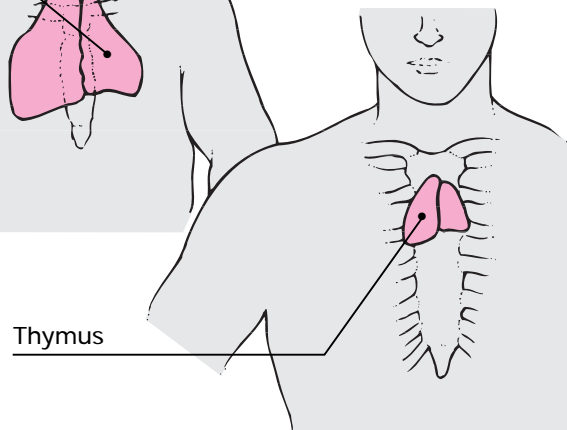
Thymus

- The thymus consists of two lobes of lymphoid tissue in the upper chest.
- It is much larger in children than in adults because the main task of the thymus—the production and development of a special type of lymphocyte called a T-lymphocyte (or T-cell)—is carried out before adulthood.

Thymus in a child



Thymus in an adult



Lymph disorders

Adenitis Inflammation of the adenoids, small lymph glands at the back of the nasal cavity, a symptom of a wide variety of infectious diseases.

AIDS Acquired Immunodeficiency Syndrome—a late, life-threatening, but not inevitable, stage of HIV infection.

Burkitt's lymphoma A tumor of lymphoid tissue, common among children in Africa, that is thought to be caused by a viral infection spread by mosquitoes.

Enlarged spleen A typical symptom of a range of diseases that include typhoid fever, malaria, syphilis, and HIV.

HIV Human Immunodeficiency Virus—an infection that destroys the body's immune system and can lead to AIDS. The virus, which is transmitted through body fluids, attacks antibody-producing lymphocytes.

Hodgkin's disease A malignant disease of unknown cause that affects the lymph nodes, spleen, and other organs related to white blood cells.

Immunodeficiency Any breakdown or failure of the body's immune system.

Leukopenia A condition in which the number of some white blood cells (leukocytes) is greatly reduced.

Leukemia A disease in which the number of white blood cells (lymphocytes) is permanently increased. It has many causes, the most important being a malignant (cancerous) uncontrolled production of lymphocytes.

Lymphadenitis A general inflammation of the lymphatic glands.

Lymphadenoma The medical name for Hodgkin's disease.

Lymphangiectasis Any abnormal widening of the lymph vessels.

Lymphatism A general enlargement of lymphatic tissue throughout the body.

Lymphemia Medical name for lymphatic leukemia.

Lymphocythemia Another name for lymphatic leukemia.

Lymphoedema A swelling of all or part of an organ due to the obstruction or damage to the lymph vessels draining it.

Lymphogranuloma inguinale A venereal (sexually transmitted) disease in which the lymph glands of the groin become enlarged.

Lymphogranuloma venerum Another name for lymphogranuloma inguinale.

Lymphoma A tumor of lymphoid tissue.

Lymphopathia venerum Another name for lymphogranuloma inguinale.

Lymphosarcoma A malignant growth of lymph glands and nodes, including the spleen.

Poradenitis venerea Another name for lymphogranuloma inguinale.

Splenic anemia A chronic disease, of unknown cause, in which the spleen becomes enlarged and the number of red blood cells (erythrocytes) falls far below normal.

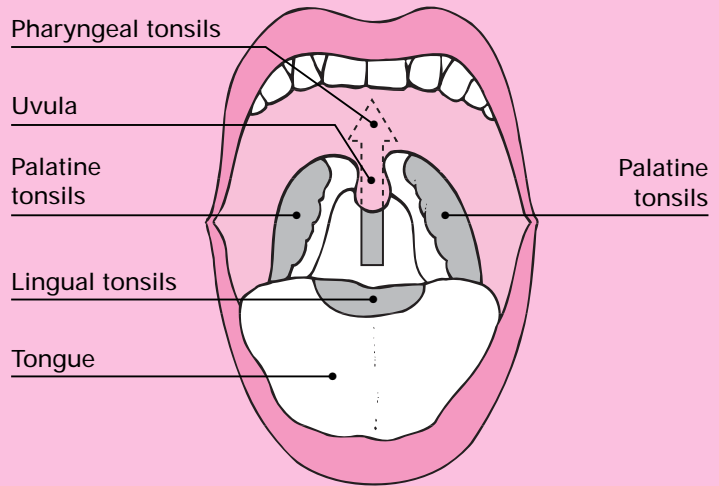
Status lymphaticus The medical name for lymphatism.

Tonsillitis Inflammation of the tonsils, a symptom of a wide variety of infectious diseases. The adenoids, neighboring lymph glands, usually become inflamed at the same time.

Tonsils

- Tonsils are paired masses of lymphoid tissue.
- There are three pairs of tonsils. The pharyngeal tonsils are at the top of the pharynx at the rear of the nasal cavity. The palatine tonsils lie under the lining of the throat behind the uvula. The lingual tonsils are at the back of the tongue.
- The main function of the tonsils is to protect against harmful substances that may enter the body through the nose and mouth.

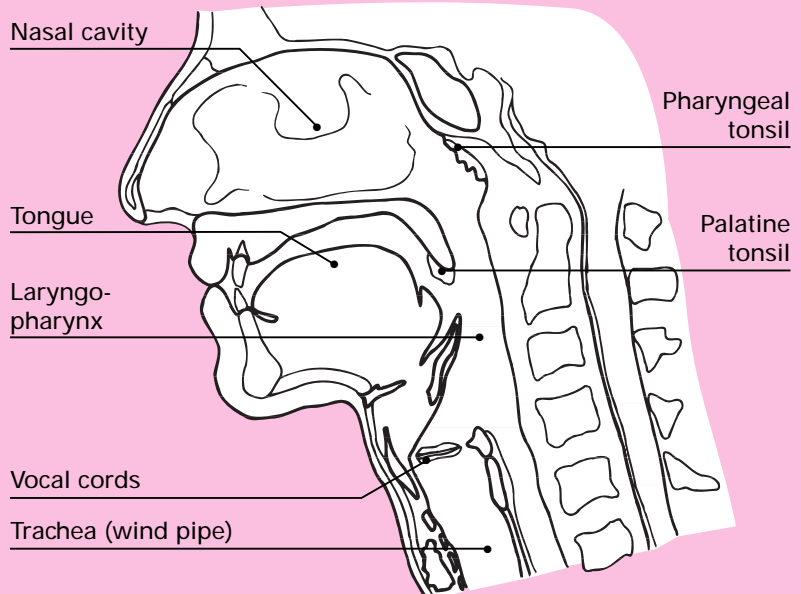
View of extended tongue



Pharynx

A section through the nose and throat region of the head shows how the tonsils are at the crossroads of the air passageways. In this way, they serve as the first line of defense from the exterior and as such they are prone to chronic infection. In the past, whenever the tonsils became repeatedly infected, it was customary to have them surgically removed. Nowadays, tonsillitis can be kept under control and treated with antibiotics.

Side view of pharynx



The immune and defense systems protect and defend the body against pathogens (disease-causing organisms such as bacteria and viruses) and other harmful substances, and are also involved in the response to transplanted tissues and organs. They can be divided into two complementary systems: the nonspecific (not aimed at particular harmful substances) and the specific (aimed at particular harmful substances). The lymphatic system is also involved in immunity.

Nonspecific defense system

Also called innate (inborn) immunity, this system provides the first and second lines of defense against pathogens.

First line of defense

This aims to stop the invading pathogens from entering the body. It is provided by barriers to entry such as:

- skin;
- mucous membranes (organ linings that secrete a thick, slimy fluid);
- bodily fluids (such as saliva and tears); and
- chemical secretions (such as stomach acid).

Second line of defense

This aims to stop the spread of pathogens that manage to cross the first line. It involves:

- inflammatory and fever response mechanisms;
- cellular defenses (using phagocytes—“engulfing” cells; and cytotoxic—

- “natural killer”—cells); and
- chemical defenses (using the proteins interferon and complement).

Specific defense system

Also called adaptive immunity, the specific defense system provides the third line of defense against pathogens. This system is commonly known as the immune system.

Third line of defense

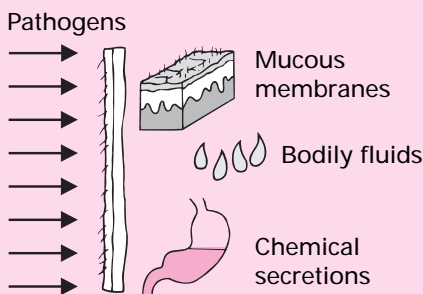
This is more specialized than the previous lines as it provides particular defenses for different pathogens and it “remembers” those that it has encountered before. There are two types of specific defense mechanism:

- humoral, which produces antibodies (proteins that attack foreign proteins in the body); and
- cellular, which uses specialized white blood cells to attack invaders.

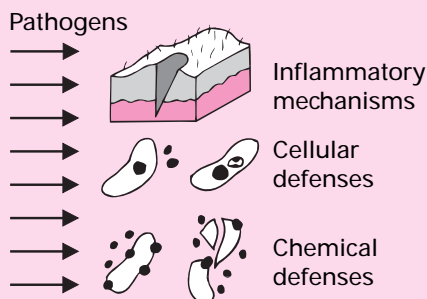
Fever facts

- A general inflammatory response causes fever—a raised body temperature.
- The purpose of a fever is to speed up the chemical reactions of the defense system and thereby destroy invading pathogens.

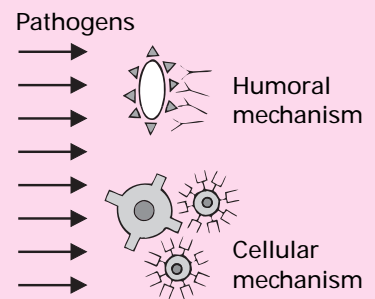
First line of defense



Second line of defense



Third line of defense



Types of immunity

Immunity Immunity is the specialized resistance to a specific disease. A person can become immune to a certain disease in a variety of ways.

Acquired Immunity that is not inherited has to be acquired in some way.

Inborn Humans are immune from birth to certain diseases (such as canine distemper). This immunity is inherited.

Natural If a person is exposed—accidentally—to a certain disease in the course of everyday life, then natural immunity may result.

Artificial If a person is deliberately exposed to a certain infectious disease (by immunization, for example), then the acquired immunity is said to be artificial.

Active Active natural immunity occurs when a person's own immune system responds to the harmful agent. If a person develops measles, for example, he or she will usually actively acquire natural immunity to subsequent infections.

Active Active artificial immunity occurs when a person's own immune system responds to the harmful agent. Injection of a weakened form of the harmful agent (for example, a polio vaccination) results in active artificial immunity.

Passive Passive natural immunity occurs when the immunity to disease is transferred from one individual to another. A newborn baby, for example, passively acquires natural immunity to certain diseases through its mother's breast milk.

Passive Passive artificial immunity occurs when antibodies to a disease developed by another person—or, more rarely, by an animal—are injected into an individual. An example of this would be the injection of a snake antivenin.

First line of defense

Skin

Skin covers most of the body's outer surface. It is made up of closely packed cells that contain keratin (tough, fibrous protein) in the outer layer. This makes it difficult for pathogens to cross unbroken skin.

Mucous membranes

Mucous membranes are the linings of many of the body's cavities, tubes, and organs. They contain goblet cells that secrete mucus (thick, slimy fluid). In some parts of the body (the respiratory tract, for example), the mucous membrane is covered with tiny, hairlike projections called cilia. The sticky mucus traps harmful substances, which stops them from entering the body. In the respiratory tract, cilia move the mucus toward the throat for swallowing, or trigger sneezing and coughing to remove the trapped particles.

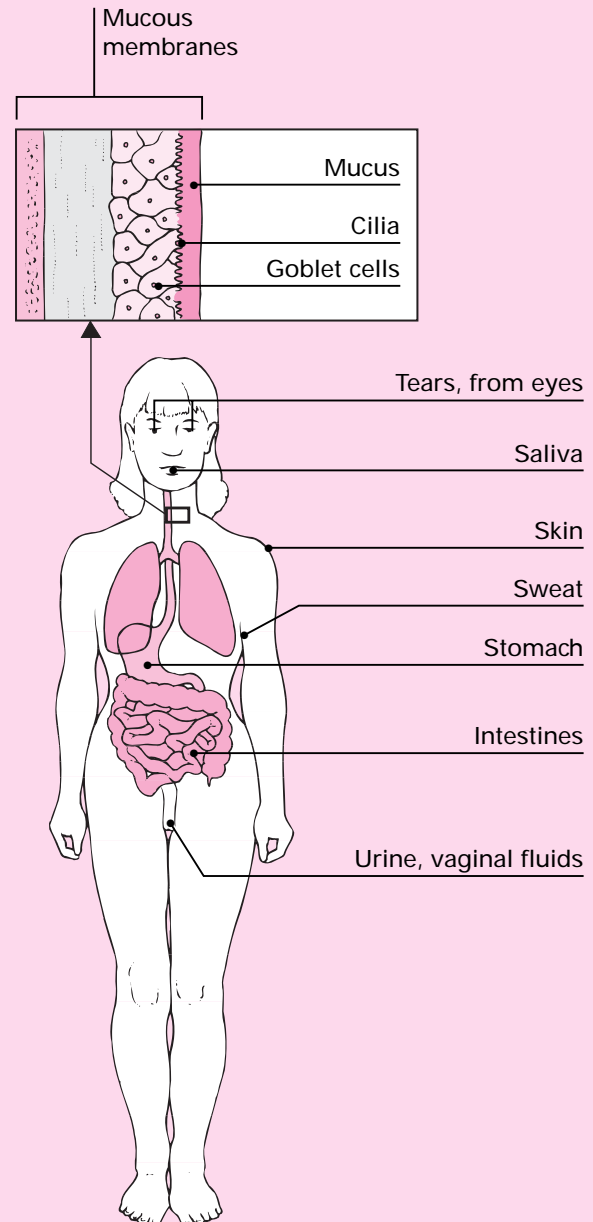
Bodily fluids

Certain bodily fluids such as tears, saliva, urine, and sweat help to wash away harmful substances.

Chemical secretions

Tears and saliva contain an enzyme (protein that acts as a biological catalyst) called lysozyme. This destroys microorganisms. Harmful substances that are swallowed can be destroyed by the digestive juices in the stomach and intestines. The chemicals in, or acidity of, some secretions such as sweat, urine, and vaginal secretions also help to destroy microorganisms.

First line of defense

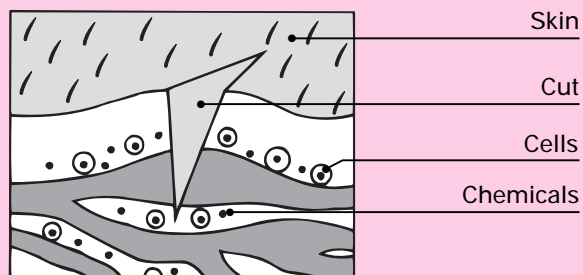


Second line of defense

Inflammation

The function of the inflammatory response is to prevent the spread of harmful substances and to promote tissue repair.

If the skin or mucous membrane (lining that secretes a thick, slimy fluid) is breached, broken, or cut, then pathogens can enter the body. Chemicals are released by the damaged cells that trigger the inflammatory response. Blood vessels in the area widen. This causes the typical redness and heat of inflamed areas. More fluid than usual leaks from the blood vessels into the surrounding tissue, causing pain



and swelling. The swelling makes access easier for the cells and chemicals that fight the invaders. These are attracted by other chemicals released in the area. If the cells and chemicals carry out their tasks successfully, then the tissue is repaired. If not, then the inflammatory response continues.

Third line of defense

For humoral defense, see pages 96–97. Cellular defense depends on phagocytes, which are white blood cells that engulf (“eat”) pathogens. The two main phagocytic cells are neutrophils and macrophages.

Neutrophils are small and granular. Normally, they are the first to leave the blood and travel to the site of infection. Neutrophils die after engulfing a few foreign particles.

Macrophages are larger white blood cells that have left the blood. As well as engulfing invaders, they are responsible for clearing up dead neutrophils and other damaged cells at the site of an

infection. Free macrophages roam the body. Others, such as Kupffer’s cells in the liver, are fixed—they stay in one organ. Phagocytes are attracted to sites of infection by chemicals released during inflammation. Once there, phagocytes must first contact and recognize the particle as foreign. The particle will then be “swallowed” by the phagocyte. The phagocyte’s cell membrane surrounds the particle and folds inward, forming a bag. This bag breaks away from the cell membrane and enters the cell. The phagocyte then digests the particle using enzymes (proteins that act as biological catalysts) released by lysosomes (fluid-filled particles).

Humoral immunity

Specific defense mechanisms provide the body's third line of defense against pathogens. This is more specialized than the previous first and second lines because:

- it is specific—it recognizes and provides particular defenses for specific antigens (substances that provoke an immune response);
- the immunity provided is systemic (not limited to the site of initial infection); and
- it uses “memory” to recognize previously encountered antigens, so that an even stronger attack can be launched against them.

The response to particular antigens is either humoral or cellular.

Antibody system

A humoral response involves the production of antibodies (proteins that attack specific antigens) by B-lymphocytes (or B-cells), a type of white blood cell. B-cells are assisted by helper T-cells (another type of white blood cell). Humoral immunity is mainly used against toxins, viruses outside body cells, and bacteria.

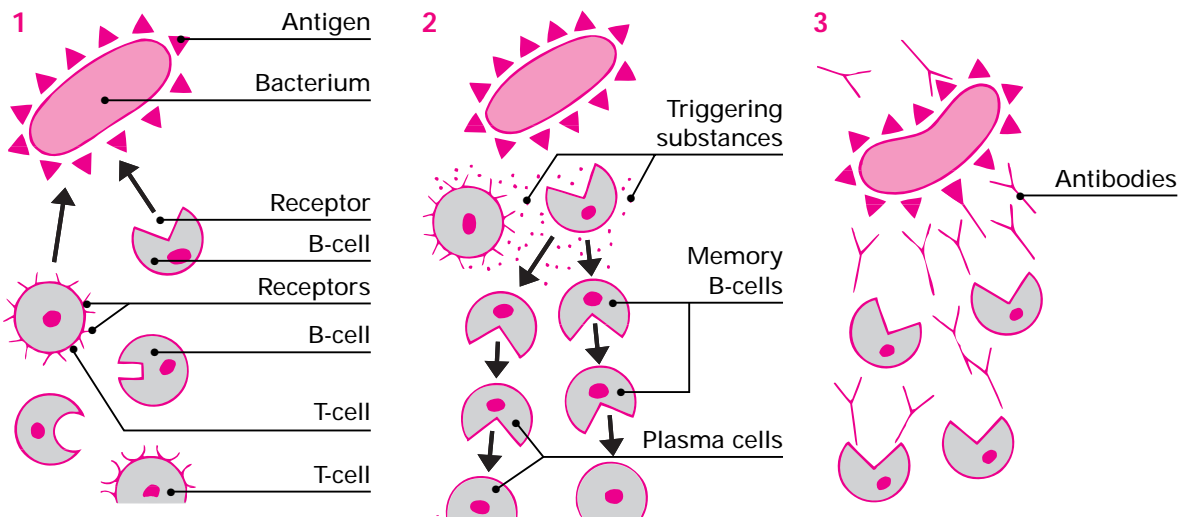
The primary response happens on the first contact with an antigen.

1 The antigens on a bacterium are recognized by B-cells and helper T-cells that have the right receptors for it.

2 The helper T-cells then secrete substances that trigger the B-cells to duplicate themselves. These copies are called plasma cells and memory B-cells.

3 Plasma cells produce antibodies that inactivate the antigens.

Primary response

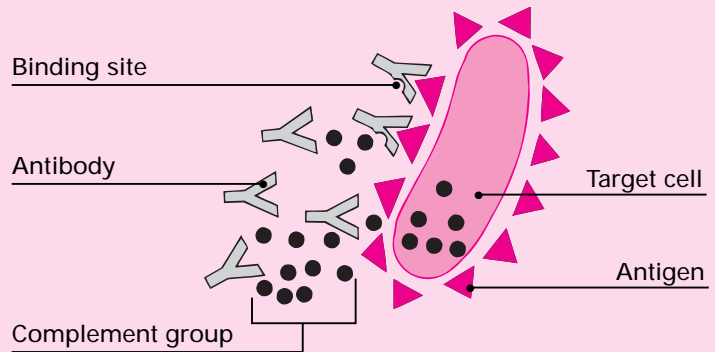


How antibodies work

Many bacteria, viruses, and toxins carry antigens (substances that trigger an immune response). The action of antibodies on these helps to inactivate the invader in three main ways: complement fixation, neutralization, and agglutination.

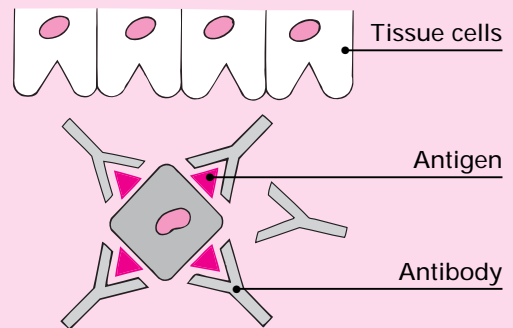
Complement fixation

Antibodies have sites to which the proteins of the complement group can bind. Once the antibody has bound to its target cell, it changes shape, revealing its complement-binding site. The attached complement will then kill the target cell.



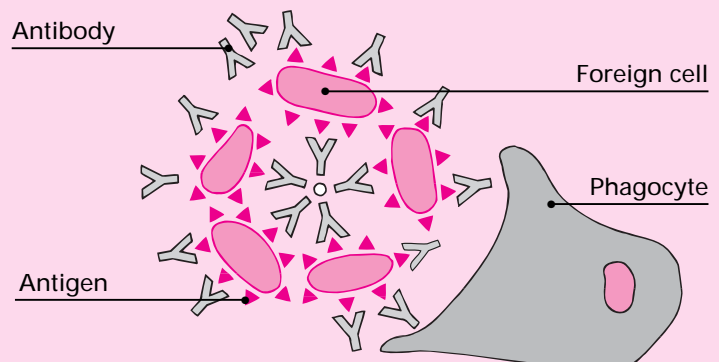
Neutralization

Antibodies can bind to certain sites on viruses, or toxic chemicals secreted by bacteria, to stop them from binding with tissue cells of the body. The invaders will eventually be "eaten" by phagocytes (engulfing white blood cells).



Agglutination

By grouping together to bind to more than one antigen, antibodies can develop clumps of foreign cells which are more easily captured and engulfed by phagocytes.



Cellular immunity

A cellular response uses T-lymphocytes (or T-cells) to attack antigens (substances that provoke an immune response). The T-cell is a type of white blood cell that only reacts to specific antigens. It differs from other cells of the immune system

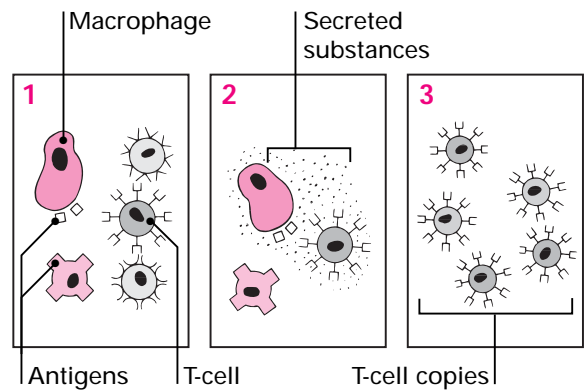
in that it can directly attack and kill infected body cells as well as foreign cells. Cellular immune responses are directed, in particular, against viruses, cancerous body cells, and parasites.

T-cells at work

1 First, the antigens on an abnormal body cell, or displayed in parts (called antigen presentation) by a macrophage, must be recognized by T-cells that are sensitized to them.

2 The macrophage and T-cell secrete substances that activate the T-cell.

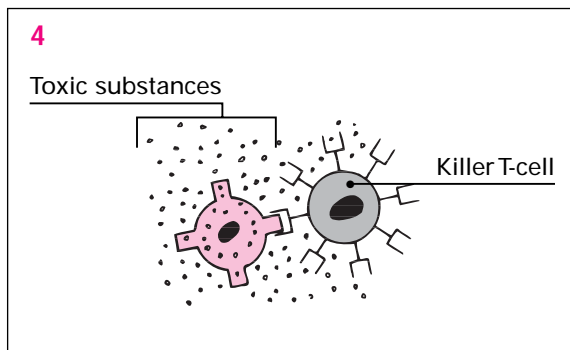
3 The activated T-cell then duplicates itself. These copies come in four subgroups: killer T-cells, helper T-cells, suppressor T-cells, and memory T-cells.



Killer T-cells

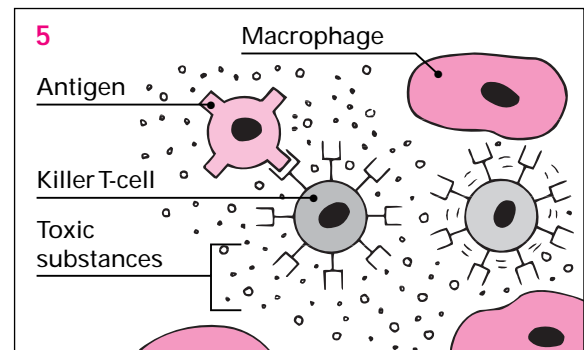
The killer T-cells are non-specific in their action. They directly attack the infected body cells or foreign cells.

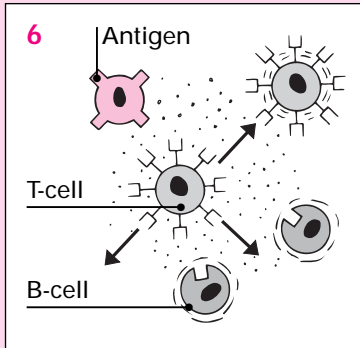
4 Once a killer T-cell has bound to an antigen, it releases toxic substances that kill the cell.



5 It can also release substances that:

- activate other white blood cells in the area to become “killer” cells;
- attract macrophages to the area; and
- stimulate macrophages into greater phagocytic activity.



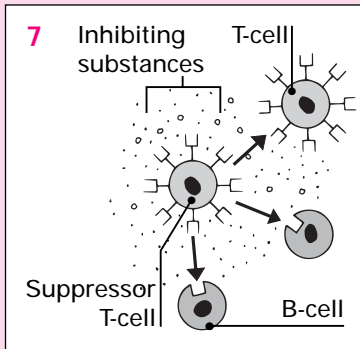


Helper T-cells

The helper T-cells are vital to the whole immune response. They act as “directors” of the process.

6 On recognition of the antigen, helper T-cells secrete substances that:

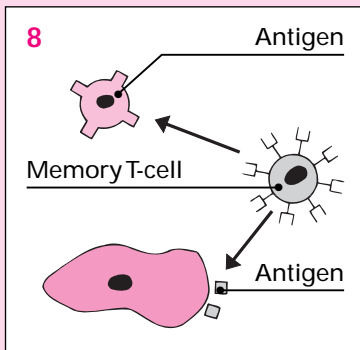
- stimulate the activation of both T-cells and B-cells (white blood cells that produce antibodies); and also
- attract other types of white blood cells to the area.



Suppressor T-cells

Some T-cells also have a regulatory effect on the immune response, but of a reverse nature.

7 After the threat has been eliminated, suppressor T-cells release substances that inhibit the activities of T-cells and B-cells. This brings the immune response to a halt and helps prevent autoimmune (“self”-inflicted) disorders.

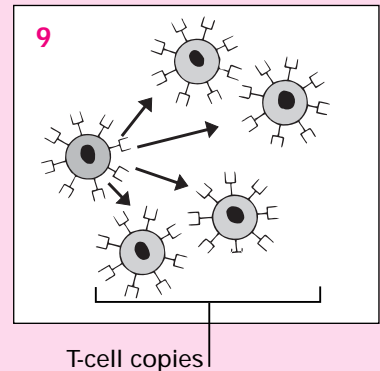


Memory T-cells

Some T-cells come into play on any subsequent contact with the same antigen. This secondary response may be years after the first meeting.

8 If the same antigen is found in the body again, then the memory T-cells will recognize it.

9 They can quickly initiate the immune response by producing the necessary T-cell duplicates: killer T-cells, helper T-cells, suppressor T-cells, and more memory T-cells.



Antigens

- Common antigens are viruses, bacteria, pollen, dust, fungal spores, and household chemicals.

Antibodies

- Antibody molecules outnumber the cells of the immune system by about 100 million to one.

AIDS and HIV

One of the most devastating immune disorders is acquired immunodeficiency syndrome (AIDS). It is caused by infection with the human immunodeficiency virus (HIV).

Transmission

- HIV is present in body fluids but only blood, semen, and cervical/vaginal secretions have been proved to transmit the virus.
- The major methods of transmission are sexual contact, blood transfusions, the use of nonsterile needles, and from mother to fetus during pregnancy.

Infection

- In a person who is infected with HIV, the immune system is weakened.
- This can lead to the development of AIDS, in which the individual is susceptible to a variety of infections and cancers.
- In an uninfected person, these illnesses would not commonly occur or would not be serious, but they take advantage of the damage done to the immune system of an infected person. For this reason, they are called opportunistic.
- Until recently, if AIDS had developed, the condition was usually fatal.
- AIDS-related complex (ARC) may also develop in those infected with HIV. The symptoms are weight loss, fever, diarrhea, and enlarged lymph nodes.

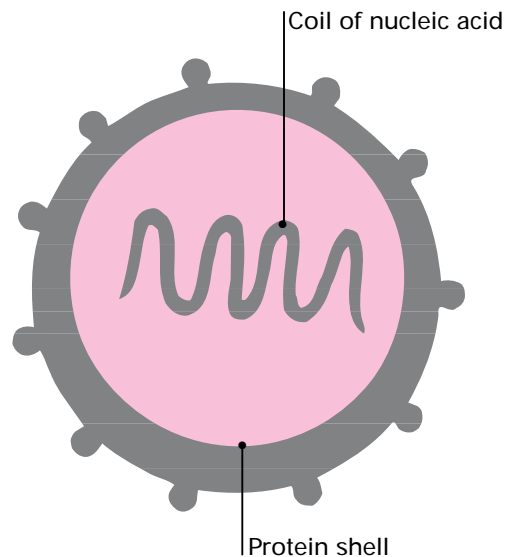
HIV multiplication

- Having entered the body, the virus mainly attacks certain white blood cells.
- The most affected are the helper T-cells, which are vital for regulating the immune system.
- Macrophages (“engulfing” white blood cells), which play an important part in the body’s defense against diseases, are also often affected.

HIV virus

- The HIV virus consists of some nucleic acid contained in a protein shell.
- An HIV virus invades a helper T-cell or another type of white blood cell (see pages 96–99).

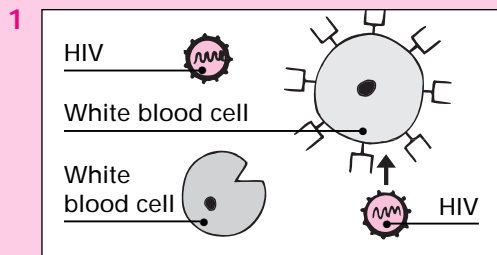
HIV virus



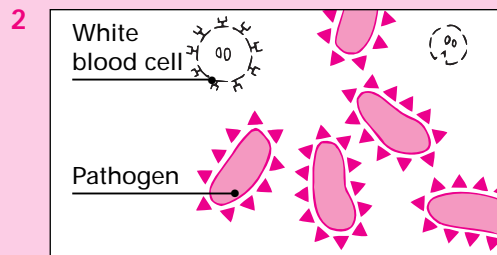
HIV and immunity

1 The HIV virus destroys white blood cells when it uses them to multiply.

2 As these cells are vital to the working of the immune system, the virus



eventually weakens the body's ability to defend itself against disease. So pathogens (disease-causing organisms) can easily invade the body and overwhelm the immune system.



Disorders of the immune and defense systems

Allergies or hypersensitivities

A hypersensitive reaction occurs when the body's immune system causes damage to tissue cells by fighting off a "threat"—such as pollen—that may actually be quite harmless.

Autoimmune disorders A person's immune system begins to attack the healthy organs and cells of his or her own body.

Autoimmune disorders can cause a variety of diseases.

Grave's disease An autoimmune disorder that leads to an overactive and enlarged thyroid gland.

Hashimoto's thyroiditis An autoimmune disorder in which the cells of the thyroid gland are attacked. This interferes with the production of hormones by the thyroid gland, causing fatigue and weight gain.

Multiple sclerosis (MS) A disease probably caused by an autoimmune disorder. It attacks the coverings of nerve fibers in the

brain and spinal cord. Symptoms vary in severity but can include paralysis.

Pernicious anemia Anemia is the lack of hemoglobin (oxygen-carrying part of blood). Pernicious anemia is due to a lack of vitamin B₁₂, and is often caused by an autoimmune disorder.

Rheumatoid arthritis An autoimmune disorder which attacks the joints and surrounding tissues, causing them to become painful, swollen, stiff, and even deformed.

Severe combined immunodeficiency (SCID) A birth defect in which babies lack sufficient T-cells and B-cells (white blood cells). These cells are vital to the working of the immune system. Sufferers have little or no protection against disease.

Systemic lupus erythematosus (SLE) A systemic (not localized) autoimmune disorder. It particularly affects the joints, skin, lungs, and kidneys.

Adipose tissue Connective tissue containing numerous fat cells.

Adrenal glands (*or* Suprarenal glands) Endocrine glands located on each kidney. The cortex and medulla produce a range of hormones.

Afferent Directed toward a central organ or part of the body.

Alimentary canal (*or* Gastrointestinal tract *or* Gut) The digestive tract: a tube starting at the mouth and ending at the anus.

Anus The lower end of the rectum, forming the outlet of the alimentary canal.

Aorta The largest artery, arising from the left ventricle of the heart.

Appendix (*or* Vermiform appendix) A short, wormlike tube opening into the cecum but closed at the other end. It contains lymphoid tissue, which is involved in immunity.

Arteriole A small artery supplying blood from a main artery to a capillary.

Artery A blood vessel transporting blood from the heart to elsewhere in the body.

Atrioventricular valve (*or* AV valve) A valve between a ventricle and an atrium. The right atrioventricular valve (*or* tricuspid valve) has three cusps. The left atrioventricular

valve (mitral valve or bicuspid valve) has two cusps.

Auditory Relating to hearing.

Axillary Relating to the armpit.

Backbone See **Vertebral column**.

Basal ganglia Paired structures deep in the forebrain: they help coordinate and control willed muscle movements.

Basophil A type of white blood cell that is readily stained by basic dyes.

Biceps A muscle with two heads: biceps brachii in the upper arm and biceps femoris in the thigh.

Bile ducts Tiny tubes that carry bile (a liver secretion) from the liver to the duodenum.

Bladder A sac, especially the muscular bag inside the pelvis where urine collects before being expelled from the body.

Blood A sticky red fluid consisting of colorless plasma, red blood cells (Erythrocytes), white blood cells (Leukocytes), and platelets (thrombocytes).

Blood pressure The pressure of blood against blood-vessel walls, especially artery walls.

Bone The hard, dense connective tissue that forms the skeleton's components.

Bone marrow Soft red and yellow substances that fill cavities in bone.

Bowel See **Large intestine**.

Brain The body's chief control center, consisting of billions of interconnected nerve cells.

Brainstem A stalklike part of the brain, between the cerebrum and spinal cord. It contains the midbrain, pons, and medulla oblongata.

Breast A female breast consists mainly of a mammary (milk-secreting) gland embedded in fatty tissue.

Breastbone See **Sternum**.

Bronchiole A small subdivision of a bronchus, ending in tiny air sacs called alveoli.

Bronchus The main tubes branching from the lower end of the trachea and forming the main airways to and from the lungs (plural: bronchi).

Capillary The tiniest type of blood vessel, connecting an arteriole and a venule.

Cardiac Relating to the heart.

Cardiovascular Relating to the heart and blood circulatory system.

Cartilage Gristle: dense, white connective tissue cushioning bones.

Cecum The first part of the large intestine, forming a blind pouch.

Cell The basic unit of the body, usually comprising an outer membrane, cytoplasm, a nucleus, and organelles.

Central nervous system

(CNS) The brain and spinal cord.

Cerebellum The largest part of the hindbrain. It helps coordinate muscular movements.

Cerebral cortex The cerebrum's thin outer layer of gray matter.

Cerebral hemisphere Either of the two halves of the cerebrum.

Cerebrospinal fluid A clear fluid filling the brain's ventricles and surrounding the brain and spinal cord to protect them from injury.

Cerebrum The upper, major part of the brain, comprising cerebral hemispheres and diencephalon.

Cervix A neck, especially the neck of the uterus (womb) where it opens into the vagina.

Clavicle Either of the two collarbones.

Clitoris An erectile, pea-sized organ above the opening of the vagina; it is highly sensitive and is involved in female sexual response.

CNS See **Central nervous system**.

Coccyx Four fused vertebrae forming the "tail" of the backbone.

Collagen A fibrous protein that is a major constituent of connective tissue.

Colon The part of the large intestine between the cecum and rectum.

Connective tissue Tissue that supports, binds, or separates more specialized body tissues or acts as packing.

Corium See **Dermis**.

Cornea The transparent circular area at the front of the eye, which acts as a lens.

Coronary arteries Supply the heart muscle.

Corpuscles A term often used for red and white blood cells.

Cortex The outer layer of the brain.

Cranial nerves Twelve pairs of nerves linking the underside of the brain with parts of the head, neck, and thorax.

Cranium The part of the skull that contains the brain.

Cutaneous Relating to the skin.

Cuticle See **Epidermis**.

Deoxyribonucleic acid (DNA) A nucleic acid in the cell's chromosomes containing the cell's coded genetic instructions.

Dermis (or **Corium**) The layer of skin below the epidermis, containing nerves, blood vessels, glands, and hair follicles.

Diaphragm A muscular sheet used in breathing. It separates the thorax (chest) and abdomen (belly).

Digestion The chemical and mechanical breakdown of foods into substances that can be absorbed by the body.

DNA See **Deoxyribonucleic acid**.

Duodenum The upper part of the small intestine, where most chemical digestion takes place.

Ejaculation The discharging of semen from the penis.

Endocardium The membrane that lines the heart and the heart valves.

Endothelium The cell layer that lines the inside of the heart, blood vessels, and lymph vessels.

Enzymes Biological catalysts: proteins that speed up chemical reactions without undergoing change themselves.

Epidermis (or **Cuticle**) The skin's outer layer.

Epiglottis A cartilage flap behind the tongue that is closed during swallowing to stop food from entering the larynx.

Epiphysis See **Pineal gland**.

Epithelium The cell layer covering the body, and lining the alimentary canal and respiratory and urinary tracts.

Erythrocytes Red blood cells.

Esophagus (or **Gullet**) The muscular tube through which food travels between the pharynx and the stomach.

Fallopian tubes (or Uterine tubes or Oviducts) The tubes through which ova (eggs) travel from the ovaries to the uterus.

Femur The thigh bone: the long bone between the hip and the knee.

Follicle A small secreting cavity or sac. Ova (egg cells) develop in follicles in the female ovaries.

Forebrain The front part of the brain comprising diencephalon and telencephalon.

Gallbladder A pear-shaped bag where bile is stored, below the liver.

Gametes Sex cells: sperm in males; ova in females.

Gastric Of the stomach.

Gastrointestinal tract See **Alimentary canal**.

Genes Basic biological hereditary units, consisting of DNA, located on chromosomes.

Genitalia Sex organs.

Gland A structure that synthesizes and secretes a fluid.

Gonads Primary reproductive organs: the ovaries and testes.

Granulocytes White blood cells with cytoplasm that contains granules: basophils, eosinophils, and monocytes.

Gray matter The darker tissue of the brain and spinal cord mainly consisting of neurons' cell bodies and dendrites.

Gullet See **Esophagus**.

Gut See **Alimentary canal**.

Heart The hollow, muscular, fist-sized organ that pumps blood around the body.

Hemoglobin The iron-rich, oxygen-transporting pigment in red blood cells that gives them their color.

Hepatic Relating to the liver.

Hepatic portal vein See **Portal vein**.

Hindbrain Brain structures below the midbrain, comprising the pons, medulla oblongata, and cerebellum.

Hormones Chemical substances released into the blood by endocrine glands to influence organs or tissues in other parts of the body.

Hypophysis See **Pituitary gland**.

Hypothalamus A part of the brain with endocrine functions.

Ileum The last part of the small intestine.

Immune system The body's defense system against infective organisms or other foreign bodies. It includes the lymphatic system.

Involuntary muscle Muscle that is not under conscious control. See also **Smooth muscle**.

Jejunum The middle part of the small intestine.

Joint The junction between bones.

Karyotype The chromosome complement of a person or species: the genome.

Kidney A bean-shaped organ that filters wastes from blood to form urine.

Lactation Milk production by the mammary glands.

Large intestine (or Bowel) The lower part of the alimentary canal, comprising the cecum, colon, and rectum.

Larynx The cartilaginous voice box.

Leukocytes White blood cells. They attack invading microorganisms and help to combat injuries.

Ligament Fibrous tissue that connects bones.

Liver The largest organ in the body, it is involved in various metabolic processes.

Lungs The two organs of respiration, filling most of the chest cavity inside the rib cage and above the diaphragm.

Lymph A transparent fluid that leaks from blood vessels into tissue spaces.

Lymph gland See **Lymph node**.

Lymph node (or Lymph gland) One of the "knots" in the lymphatic system, which contain lymphocytes and macrophages that filter the lymph passing through the nodes.

Lymphatic system A network of lymph vessels and lymph nodes. Vessels collect lymph from body tissues and return it to the blood after harmful substances have been filtered out in the lymph nodes.

Mammary glands The milk-producing structures in the breast.

Medulla oblongata The lowest part of the brain stem, containing the vital centers that control heartbeat and respiration.

Meiosis A type of cell division that produces daughter cells (sperm and ova) each with half as many chromosomes as the parent cell.

Meninges Three protective membranes surrounding the brain and spinal cord.

Menopause When a woman ceases to have menstrual periods.

Menstruation Menstrual periods: the monthly flow of blood and uterine lining from the vagina of nonpregnant females of childbearing age.

Metabolism The array of continuous chemical changes that maintain life in the body.

Mitosis Ordinary cell division in which both daughter cells have as many chromosomes as the parent cell.

Mucous membranes The mucus-secreting linings of the

digestive, respiratory, reproductive, and urinary tracts.

Nasal Relating to the nose.

Nasal cavity The space inside the nose between the base of the skull and the roof of the mouth.

Nerve A bundle of nerve fibers (axons) that transmit impulses to (in the case of sensory nerves) or from (in the case of motor nerves) the central nervous system.

Nervous system The coordinated networks of neurons that control the body. It is divided into the central nervous system (brain and spinal cord), and the peripheral nervous system (the somatic and autonomic nervous systems).

Neuron (*or* Neurone) A nerve cell: the basic unit of the nervous system.

Neurone *See* **Neuron**.

Neurotransmitter A chemical released at nerve endings to transmit nerve impulses across synapses.

Nucleic acids Molecules that store genetic information.

Nucleus The control center of a cell, which contains coded genetic instructions.

Olfactory Relating to smell.

Optic Relating to the eye.

Organ A body part with different types of tissue that performs a particular task.

Organelles Tiny structures (miniorgans) in a cell's cytoplasm with particular tasks.

Ovaries Female sex organs that produce ova (eggs) and sex hormones.

Oviducts *See* **Fallopian tubes**.

Ovulation The release of a ripe egg from a female's ovary.

Ovum An egg; a female sex cell (plural: ova).

Palate The roof of the mouth.

Pancreas An abdominal organ that produces pancreatic juice and the hormones glucagon and insulin.

Parasympathetic nervous system The part of the autonomic nervous system that predominates when the body is at rest.

Parathyroid glands Four pea-sized endocrine glands on the thyroid gland. They produce parathyroid hormone, which controls blood calcium level.

Pelvis A bony basin formed by the two hip bones, the sacrum, and the coccyx.

Pericardium The double-layered membrane that encloses the heart and attaches it to the diaphragm and sternum.

Peristalsis Waves of muscular contraction that propel substances through passageways, such as the alimentary canal.

Phagocytes Types of leukocytes that engulf and destroy microorganisms and foreign bodies.

Pharynx The throat.

Pineal gland (or Epiphysis) An endocrine gland in the brain that secretes melatonin.

Pituitary gland (or Hypophysis) A three-lobed, pea-sized gland below the hypothalamus. It produces growth hormone, hormones that act on other endocrine glands, oxytocin, and ADH. It is often called the body's "master gland."

Plasma The fluid part of blood.

Pleura The membrane that covers the lungs (visceral pleura) and lines the chest wall (parietal pleura).

Plexus A network of nerves (or blood or lymph vessels).

Portal vein (or Hepatic portal vein) Drains blood from digestive organs to the liver.

Prostate gland A gland situated below the bladder in males. It produces a sperm-activating fluid that forms nearly a third of the semen's volume.

Pudendum See **Vulva**.

Pulmonary Relating to the lungs.

Receptor A structure, such as a sensory nerve ending, specialized to detect environmental stimuli.

Rectum The last part of the colon, where feces collects before leaving the body.

Reflex action The body's automatic response to a stimulus, such as blinking.

Renal Relating to the kidney.

Respiration 1) Breathing; 2) Taking in oxygen and giving out carbon dioxide; 3) Deriving energy from food with or without using oxygen.

Respiratory system In humans, the mouth, nose, pharynx, larynx, trachea, bronchi, bronchioles, alveoli, and lungs.

Ribonucleic acid (RNA) A nucleic acid concerned with protein synthesis.

Ribs Twelve pairs of bones that protect the chest cavity and assist breathing by moving up and out during inspiration and down and in during expiration.

Salivary glands The lingual, parotid, sublingual, and submandibular glands that produce saliva.

Serum Blood plasma that does not contain clotting factors but does contain antibodies.

Sinus A cavity, such as the channels draining venous blood from the brain.

Skeleton The bony framework that protects and supports the body's soft tissues.

Skin The body's waterproof covering; its largest organ, comprising two main layers: the epidermis and dermis.

Small intestine The alimentary canal between the stomach and large intestine, comprising the duodenum, jejunum, and ileum. Most digestion occurs here.

Smooth muscle (or Unstriated muscle or Involuntary muscle) Muscle without striped fibers that automatically operates internal organs such as the stomach, bladder, and blood vessels.

Sphincter A ring-shaped muscle that contracts to close an orifice.

Spinal cord The cable of nerve tissue running down inside the vertebral column (spine) and linking the brain with nerves supplying most of the body.

Spine See **Vertebral column**.

Sternum The breastbone.

Subcutaneous tissue The sheet of connective tissue below the dermis.

Suprarenal glands See **Adrenal glands**.

Suture An immovable fibrous joint between the skull bones.

Taste buds Tiny sensory organs of the tongue and palate, distinguishing salty, sweet, sour, and bitter tastes.

Teeth Bonelike structures in the jaws. Different types (incisors, canines, premolars, molars) are specialized to tear, crush, and/or grind food.

Tendons Bands of fibrous connective tissue joining muscles to bones.

Testis (*or* Testicle) One of a pair of primary male sex organs that manufacture sperm (plural: testes).

Thalamus A brain structure above the hypothalamus. It sends sensory impulses to the cerebral cortex, links sensations with emotions, and affects consciousness.

Thymus An endocrine gland located behind the sternum. It produces thymosin.

Thyroid An endocrine gland at the front of the neck, producing thyroid hormone.

Tissue A collection of similar cells that perform a particular task.

Trachea (*or* Windpipe) The tube between the larynx and the bronchi.

Tubule A tiny tube.

Tunica A tissue layer forming a coating. Blood vessels have three such layers (intima, media, adventitia).

Unstriated muscle *See* **Smooth muscle**.

Ureter The tube conveying urine from a kidney to the bladder.

Urethra The passage taking urine from the bladder to the body's exterior.

Urinary system The kidneys, ureters, bladder, and urethra.

Urine Liquid waste excreted by the kidneys.

Uterine tubes *See* **Fallopian tubes**.

Uterus (*or* Womb) A hollow muscular organ located above the bladder. Inside it, a fertilized ovum develops into a fetus.

Uvula A conical tag hanging from the back of the palate. It helps to keep food out of the nasal cavities.

Vagina The muscular passage between the vulva and cervix (neck of the uterus).

Vascular Relating to or richly supplied with vessels, especially blood vessels.

Vein A blood vessel that transports blood from capillaries back to the heart. Veins contain valves to prevent the backflow of blood.

Venous Relating to veins.

Ventricle A cavity: one of the two lower chambers of the heart.

Venule A small vein.

Vermiform appendix *See* **Appendix**.

Vertebra A bone of the vertebral column (plural: vertebrae).

Vertebral column (*or* Backbone *or* Spine) The column of vertebrae between the skull and the hip bones, supporting the body and shielding the spinal cord. It has five sections: cervical, thoracic, lumbar, sacral, and coccygeal.

Vestibule A space before a passage begins, as in the inner ear beyond the oval window, between the semicircular ducts and cochlea.

Vocal cords Two belts of tissue stretched across the larynx which produce sounds when air rushes past them.

Vulva (*or* Pudendum) The external female genitals.

White matter The paler tissue of the brain and spinal cord comprised mainly of myelin-sheathed nerve fibers.

Windpipe *See* **Trachea**.

Womb *See* **Uterus**.

There is a lot of useful information on the internet. There are also many sites that are fun to use. Remember that you may be able to get information on a particular topic by using a search engine such as Google (<http://www.google.com>). Some of the sites that are found in this way may be very useful, others not. Below is a selection of Web sites related to the material covered by this book. Most are illustrated, and they are mainly of the type that provides useful facts.

Facts On File, Inc. *takes no responsibility for the information contained within these Web sites. All the sites were accessible in January 2005.*

Anatomy of the Human Body: Gray's Anatomy

Online version of the classic *Gray's Anatomy of the Human Body*, containing over 13,000 entries and 1,200 images.
<http://www.bartleby.com/107/>

Biology Online

A source for biological information, suitable for homework, research projects, and general interest, with hundreds of biology Web site links.
<http://www.biology-online.org>

BIOME

A guide to selected, quality-checked internet resources in the health and life sciences.
<http://biome.ac.uk>

Health Sciences & Human Services Library

Provides links to selected Web sites that may be useful to both students and researchers.
<http://www.hshsl.umaryland.edu/resources/lifesciences.html>

Human Anatomy Online

Interactive resource, with visual keys to text on the human body.
<http://www.innerbody.com>

North Harris College Biology Department

Tutorials and graphics on biology, human anatomy, human physiology, microbiology, and nutrition.
<http://science.nhmccd.edu/biol/>

Open Directory Project: Cardiology

Comprehensive list of internet resources.
http://dmoz.org/Health/Medicine/Medical_Specialties/Cardiology/

The Biology Project

Structured tutorials on life sciences. Particularly strong on cell biology, human biology, and molecular biology.
<http://www.biology.arizona.edu>

The Heart: An Online Exploration

Interactive exploration of the human heart and related body systems, with a glossary.
<http://sln2.fi.edu/biosci/heart.html>

University of Texas: BioTech Life Sciences Resources and Reference Tools

Enriching knowledge of biology and chemistry, for everyone from high school students to professional researchers. The Dictionary and Science Resources are particularly useful.
<http://biotech.icmb.utexas.edu>

- A**
- ACTH 44
 - adenoids 90
 - allergic reactions 21, 73, 101
 - anemia 26, 68, 101
 - sickle cell 82, 83
 - aneurysm 68
 - angina pectoris 27, 51
 - antibodies 7, 11, 72, 73, 80, 96–97, 99
 - immune system 92
 - white blood cells 75
 - antigens 11, 75, 80, 96–97, 98, 99
 - aorta 6, 7, 8, 10, 11, 12, 56
 - blood pressure 22
 - blood vessels 14, 16, 33, 38
 - circulation 52, 53
 - heart 29, 30, 31
 - aortic valve 28, 31, 33, 40, 41
 - arteries 6, 8, 10, 14, 52–53
 - aneurysm 26
 - arm 62
 - blood pressure 66
 - capillaries 19
 - disorders 27, 48, 68, 69
 - head 58
 - heart 12, 29, 48, 50
 - leg 64
 - pressure points 9, 10
 - structure 16, 17
 - valves 28
 - arteriole 6, 10, 14, 17
 - blood pressure 66
 - capillaries 18, 19
 - atherosclerosis 27, 46, 68
 - atria 6, 9, 11, 30, 32, 33, 36, 37
 - cardiac cycle 42, 43
 - circulation 52
 - pulmonary circulation 60
 - pumping action 39
 - valves 40, 41
 - atrioventricular node 34, 35
 - atrioventricular valve 11, 40, 41, 42, 43
 - autoimmune disorders 99, 101
 - autonomic nervous system 14, 33, 34
- B**
- babies 8, 93
 - heart disorders 27, 49, 50, 51
 - basophils 70, 72, 73, 74
 - bicuspid (mitral) valve 11, 40, 41
 - bleeding 9, 67, 71, 78–79
 - hemophilia 26, 82
 - blood 8, 11, 67, 70–83
 - circulation 6, 7, 8–9, 10, 11, 13, 52–69, 54
 - clotting 78–79
 - components 70, 72–73
 - coronary vessels 33
 - disorders 26
 - exercise 25
 - heart 28, 29
 - key words 11
 - lymph system 84
 - pulmonary circulation 60
 - spleen 89
 - stress 44
 - veins 15
 - blood cells 70, 71–73, 74
 - blood groups 7, 11, 80–81, 82
 - blood pressure 10, 22, 66–67
 - arteries 16, 17, 62
 - disorders 27
 - heart problems 50
 - heartbeat 8, 35
 - high 44, 46, 67, 68
 - low 27, 67
 - smoking 49
 - veins 21
 - blood transfusions 7, 80
 - blood volume 67
 - body temperature 8, 35, 72, 92
 - bone marrow 7, 11, 18, 71, 75, 76
 - brachial artery 8, 9, 10, 52, 53, 62
 - blood pressure 22, 66
 - brachial vein 10, 54, 55
 - brain 6, 52, 54
 - blood vessels 14, 15, 55, 58, 59, 68
 - fainting 27
 - heart problems 50
 - portal system 61
 - stroke 50, 68, 83
- C**
- capillaries 6, 8, 10, 18, 19
 - arterioles 14, 17
 - blood pressure 66
 - liver 61
 - lymph 85, 86
 - pulmonary circulation 60
 - sickle cell anemia 83
 - veins 15
 - venules 21
 - carbon dioxide 13, 70, 72, 73
 - capillaries 19
 - exercise 25

- cardiac cycle 11, 42–43
- cardiac (heart) muscle 11, 32–33, 34
- cardiac veins 10, 55
- carotid arteries 8, 9, 10, 14, 52, 53, 56, 58
- cephalic vein 8, 10, 15
- cholesterol 44, 45, 46
 - heart problems 48, 50
 - smoking 49
- circulation 6, 7, 8–9, 11, 13, 44, 52–69
 - key words 10
- clotting 11, 68, 72, 73, 78–79
 - disorders 26, 69, 82
- complement 83, 92, 97
- coronary arteries 10, 11, 12, 14, 28, 40, 53, 56
 - disease 27
 - heart problems 48, 50, 51
- D**
- deoxygenated blood 6, 9, 10, 53, 54
 - capillaries 19
 - coronary vessels 33, 59
 - heart 12, 29
 - pulmonary circulation 17, 60
 - veins 20
- diastole 10, 22, 42
- diet 44, 45, 46
- E**
- endothelium 10, 16, 17, 18, 20, 21
- eosinophils 72, 73, 74
- epicardium 37
- erythrocytes (red blood cells) 6, 7, 11, 72
- exercise 24, 25, 44, 45, 47
 - blood pressure 66, 67
 - cardiac output 67
 - heart problems 50, 51
 - heart rate 23, 24, 34, 35
- F**
- fainting 27, 68
- femoral vessels 8, 10
 - artery 9, 14, 52, 53, 64
 - vein 15, 54, 55, 65
- fibrinogen 44, 78
- G**
- granulocytes 11, 70, 74
- H**
- heart 8, 28–51
 - arteries 14, 29
 - blood flow through 9, 13, 38–39, 42–43
 - blood pressure 22, 66
 - blood vessels 12, 38, 55
 - cardiac muscle 11, 32–33, 34
 - circulation 6, 7, 8–9, 10, 11, 13, 52–69
 - conduction system 34
 - contractions 35
 - coverings and linings 37
 - disorders 27, 50, 51
 - key words 11
 - location 8, 12, 30, 31
 - pulmonary circulation 60
 - stroke volume 34
 - valves 28, 40–41, 42–43
 - veins 15, 29
- heart problems 27, 34, 35, 46, 48–49, 50–51
 - heart attack 27, 48, 49, 50, 51
- heart failure 51, 69
 - personality type 47
 - stress 44
- heart rate 34–35
 - fitness 47
 - problems 27, 48, 50, 51
 - pulse 67
 - rhythm 50, 51
 - smoking 49
 - stress 44
- heart valves 6, 9, 28, 31
 - problems 48, 50
- heartbeat (cardiac cycle) 28, 29, 30, 42–43
 - arteries 17
 - blood pressure 66
 - rate (pulse) 6, 8, 23
- hemoglobin 11, 70, 71
 - red blood cell development 74
 - sickle cell anemia 83
- hemophilia 26, 82
- hemorrhoids (piles) 68
- hepatic portal system 6, 15, 57
- hepatic vessels 10, 14, 15, 53, 55, 61
- HIV & AIDS 90, 100–101
- hormones 8, 35, 44, 70, 72
- hypertension 68
- hypotension 27
- I**
- iliac vessels 8, 10
 - artery 14, 52, 53, 56, 64
 - vein 15, 54, 55, 57, 61, 65
- immune system 7, 73, 92–101
 - disorders 90, 100–101
 - lymph 84, 85, 90

immunity 92–93, 96–97
 inferior vena cava 6, 8, 10,
 12, 15, 29, 38, 57
 blood supply 61
 circulation 54, 55
 pumping action 39
 inflammation 21, 92, 95
 intestines, blood supply 60

J

jugular vein 8, 10, 15, 59
 circulation 54, 55
 venae cavae 57

K

kidney 7, 56, 71, 72
 blood vessels 10, 55, 56

L

leukemia 26, 90
 leukocytes (white blood
 cells) 6, 7, 11, 72, 73
 liver
 blood cells 71
 blood vessels 53, 55, 61
 capillaries 18
 circulation 6, 7
 stress 44
 lumen 10
 lungs 9, 10, 52, 53, 54
 blood 72
 blood vessels 38, 39, 68
 exercise 25
 heart 12, 30, 31, 51
 pulmonary circulation 7,
 13, 29, 60
 smoking 49
 stress 44
 lymph 7, 18, 19, 75, 90
 lymph nodes (glands) 7,
 71, 84, 85, 86
 HIV 100

 position 87
 spleen 77
 structure 88
 lymph vessels 10, 84, 85,
 86, 87
 lymphatic system 7, 84–91
 lymphocytes 7, 70, 72, 73,
 84
 antibodies 96, 98
 development 74, 75
 lymph 85
 lymph nodes 88
 spleen 77, 89
 stress 44
 thymus 89
 lymphoma 90

M

macrophages 95, 98
 HIV 100
 lymphatic system 85,
 88, 89
 mitral valve 11, 40, 41, 51
 heart problems 51
 monocytes 11, 70, 72, 73, 74
 multiple sclerosis 101
 myocardial infarction 27,
 48, 51
 myocardium 11, 28, 32, 37,
 48
 myosin 32

N

neutrophils 11, 70, 72, 74,
 95
 nutrients 6, 19, 25, 44, 72

O

oxygen and oxygenated
 blood 9, 10, 11, 58, 72
 anemia 26, 83
 blood vessels 55

capillaries 19
 circulation 6, 13, 54
 exercise 25
 fainting 27
 heart 12, 28, 29
 heart problems 48, 50, 51
 hemoglobin 70
 pulmonary circulation
 20, 60
 red blood cells 71, 73
 stress 44

P

pacemaker 50
 palpitations 27, 51
 pericardium 6, 11, 30, 37,
 51
 phagocytes 11, 49, 92, 95,
 97
 pituitary gland 44
 plasma 6, 11, 70, 72, 80
 plasma cells 74, 75, 96
 platelets (thrombocytes)
 11, 44, 70, 71, 72
 clotting 78
 development 74
 portal systems 6, 7, 55, 61
 pressure points 9, 10
 proteins 70, 72, 83, 84
 pulmonary artery 11, 14,
 17, 60
 circulation 53
 heart 12, 29, 31
 valve 40, 41
 pulmonary circulation 7,
 10, 13, 29, 60
 pulmonary embolism 68
 pulmonary valve 28, 31, 33
 pulmonary vein 10, 15, 38,
 55
 circulation 54, 60
 heart 12, 28, 29

pulse 9, 10, 23, 24, 67
 blood pressure 66
 exercise 25, 45
 wrist 62

R

red blood cells
 (erythrocytes) 11, 74
 antibodies 80
 blood 70, 72
 development 74
 disorders 90
 production 7, 71, 76
 stress 44
 renal artery 10, 14, 52, 53,
 56
 renal vein 10, 15, 55, 57,
 61
 Rhesus disease 26
 Rhesus (Rh) factor 81

S

semilunar valves 40, 41, 42,
 43
 septum 6, 36
 serum 11
 sickle cell anemia 82, 83
 sinoatrial node
 (pacemaker) 34, 35
 sinuses 15, 33, 59
 skin 18, 44, 78, 92, 94, 95
 smoking 44, 45, 49, 50
 sphygmomanometer 22,
 66
 spleen 7, 44, 71, 76, 77, 89
 blood supply 61
 disorders 90
 lymph 85
 stress 27, 44, 47
 blood pressure 66, 67
 heart problems 48, 50, 51
 stroke 50, 68, 83

subclavian vessels 10
 artery 9, 14, 29, 52, 53,
 58, 62
 vein 15, 54, 55, 59, 86
 superior vena cava 6, 7, 10,
 15, 29, 38, 57
 blood vessels 55, 59
 circulation 54
 heart 12, 28, 31
 pumping action 39
 systemic circulation 7, 13,
 29
 systole 10, 22, 42

T

T-cells 96, 98–99
 tachycardia 51
 temporal vessels 9, 53, 58,
 59
 thrombocytes (platelets) 7,
 11
 thymus 75, 85, 89
 tibial vessels 9, 10, 53, 54,
 55
 tonsils 85, 90, 91
 transfusion 67, 100
 transplant surgery 7
 tricuspid valve 32, 40, 41,
 51
 tunica 10

V

valves 32, 40–41
 arteries 28
 heart 6, 9, 11, 28, 31,
 42–43
 heart problems 48, 50,
 51
 lymphatic system 84, 88
 veins 6, 20, 21, 26, 28,
 69
 varicose veins 68, 69

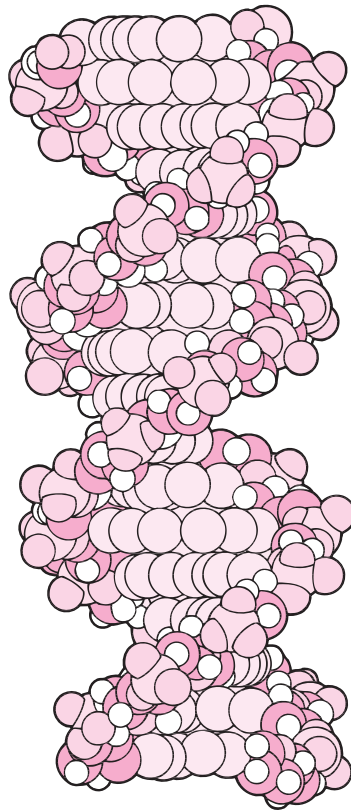
vasa vasorum 10, 16, 20
 veins 8, 10, 15, 20, 21
 arm 63
 blood pressure 66
 capillaries 19
 circulation 6, 54–55
 disorders 68, 69
 hand 63
 heart 12, 29
 leg 65
 valves 28
 vena cava 8, 57
 venae cavae 8, 20, 57
 circulation 54
 heart 12, 29
 pumping action 29
 ventricles 6, 9, 11, 36, 37
 capillaries 18, 19
 cardiac cycle 42–43
 circulation 52
 contraction control 34
 heart 30, 31
 heart muscle 32, 33
 pulmonary circulation 60
 pumping action 39
 structure 21
 valves 40, 41
 venules 6, 10
 venules 19, 21

W

waste products 6, 19, 25,
 70, 72
 white blood cells
 (leukocytes) 11, 73
 antibodies 96, 98, 99
 blood 70, 72
 development 74
 disorders 26, 101
 immune system 92
 phagocytes 95
 production 71

THE FACTS ON FILE
ILLUSTRATED GUIDE TO
THE HUMAN BODY

CELLS AND GENETICS



THE DIAGRAM GROUP

The Facts On File Illustrated Guide to the Human Body: Cells and Genetics

Copyright © 2005 The Diagram Group

Editorial: Lionel Bender, David Harding, Tom Jackson
Denis Kennedy, Gordon Lee, Jamie Stokes

Scientific consultant: Stephen Rudd

Design: Anthony Atherton, Richard Hummerstone,
Lee Lawrence, Kim Richardson, Ben White

Illustration: Pavel Kostal, Kathleen McDougall

Picture research: Neil McKenna

Indexer: Jane Parker

All rights reserved. No part of this book may be reproduced or utilized in any form or by any means, electronic or mechanical, including photocopying, recording, or by any information storage or retrieval systems, without permission in writing from the publisher. For information contact:

Facts On File, Inc.
132 West 31st Street
New York NY 10001

Library of Congress Cataloging-in-Publication Data

The Facts On File illustrated guide to the human body. Cells and genetics / the Diagram Group.

p. cm.

Includes index.

ISBN 0-8160-5980-2 (hc : alk. paper)

1. Cytology—Juvenile literature. 2. Human genetics—Juvenile literature. I. Title: Illustrated guide to the human body. Cells and genetics. II. Title: Cells and genetics. III. Diagram Group.

QH582.5.F33 2005

611'.0181—dc22

2004026104

Set ISBN: 0-8160-5979-9

Facts On File books are available at special discounts when purchased in bulk quantities for businesses, associations, institutions, or sales promotions. Please call our Special Sales Department in New York at 212/967-8800 or 800/322-8755.

You can find Facts On File on the World Wide Web at
<http://www.factsonfile.com>

Printed in the United States of America

EB Diagram 10 9 8 7 6 5 4 3 2 1

This book is printed on acid-free paper.

Note to the reader

This book is not intended to serve as a medical textbook for either physicians or patients. The information and advice it contains should not be used or relied upon without consulting the advice of a qualified physician. The publishers disclaim any responsibility for the accuracy of the information or advice that this book contains and any responsibility for any consequences that may result from any use or reliance thereon by the reader.

Contents

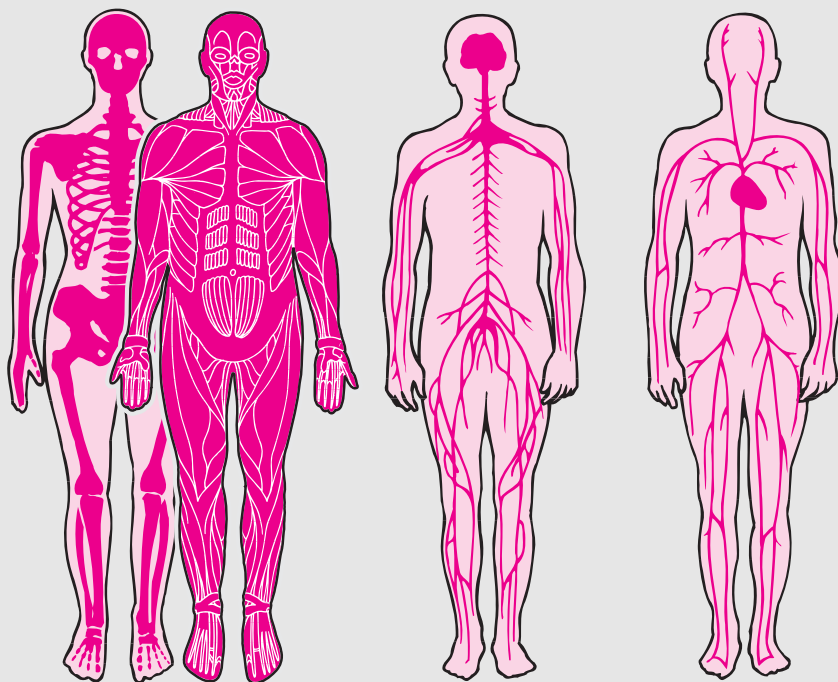
Introduction: About this book	4	
SECTION 1		
CELL STRUCTURE		
Introduction	6	Cell death 62
Cells, tissues, and organs	8	Cancer cells 64
Cell membrane	10	
Cytoplasm	12	SECTION 4
Cytoskeleton	14	CHROMOSOMES
Endoplasmic reticulum	16	Introduction 66
Ribosomes	18	Chromosome number and function 68
Golgi apparatus	20	Alleles 70
Nucleus	22	DNA structure 72
Lysosomes	24	DNA function 74
Mitochondria	26	Genes and gene expression 76
Other organelles	28	DNA replication 78
Intercellular junctions	30	DNA repair 80
Cilia and flagella	32	Mutations in DNA 82
Extracellular matrix	34	Chromosomal changes 84
SECTION 2		
HOW CELLS WORK		
Introduction	36	SECTION 5
Diffusion and osmosis	38	HEREDITY
Active transport	40	Introduction 86
Membrane potentials	42	How inheritance works 88
ATP and cellular respiration	44	Sex determination 90
Protein synthesis	46	Genetic disorders 92
Cell signaling	48	Chromosomal disorders 94
Types of cells	50	Genes and cancer 96
SECTION 3		
CELL LIFE CYCLE		Genetic testing 98
Introduction	52	Gene therapy 100
Controlling the cell cycle	54	
Mitosis	56	Glossary of the human body 102
Meiosis	58	Web sites to visit 108
Stem cells and specialization	60	Index 109

This book is a concise, illustrated guide to the anatomy, physiology, well-being, and disorders of human cells, chromosomes, and genes. It has been written and illustrated specially for students and laypeople interested in cell biology, medicine, health, and hygiene. The subject is dealt with in clear steps, so that the reader can steadily acquire a good overall understanding. Explanatory texts, diagrams, illustrations, captions, and fact boxes are combined to help readers grasp important information at a glance. A glossary of scientific and jargon words defines medical terms in everyday language. A list of Web sites provides links to other relevant sources of information, and the index enables quick access to articles.

There are five sections within the book. The first section looks in detail at the microscopic structure of human body cells. The second section describes and illustrates the chemical processes that take place within these cells. Section 3 focuses on cell growth and division. Section 4 deals with the structure and function of chromosomes, the genetic material within cells. Section 5 looks at the processes and outcomes of heredity and inheritance. Within sections 3 and 4, discussion and illustration of the structure and function of the cell components are followed by principles of cell disorders. Section 5 looks at medical advances in genetics. Information is presented as double-page topics arranged in subsections.

Human body systems

This book is one of eight titles in THE FACTS ON FILE ILLUSTRATED GUIDE TO THE HUMAN BODY series, which looks at each of the major body systems in turn. Some of the titles in the series include more than one system. The skeletal and muscular systems, and the blood and lymphatic systems, for example, work in conjunction and so are treated together. There is a separate title for human cells and genetics, which are the building blocks and underlying chemistry of all body systems.



**Skeletal and
Muscular Systems**

**Brain and
Nervous System Heart and
Circulatory System**

Section 1: CELL STRUCTURE explores the organization and internal structure of cells, looking at each organelle in turn.

Section 2: HOW CELLS WORK focuses on cell “biochemistry,” the chemical processes of living material.

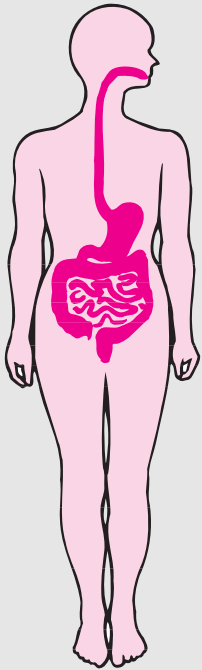
Section 3: CELL LIFE CYCLE looks at the stages of cell growth, division, and multiplication. It also describes how non-specific “stem” cells give rise to colonies of specialized body cells.

Section 4: CHROMOSOMES features the body’s genetic blueprint, surveyed at the molecular level. It also looks in detail at the double-helix structure and functioning of deoxyribonucleic acid (DNA).


Section 5: HEREDITY summarizes the processes of inheritance and reveals how changes to genes at the molecular level influence large-scale metabolic and physical characteristics.

This book has been written by anatomy, physiology, and health experts for non-specialists. It can be used:


- as a general guide to the way the human body functions
- as a reference resource of images and text for use in schools, libraries, or in the home
- as a basis for examination preparation for students of human biology, medicine, nursing, physiotherapy, and general healthcare.



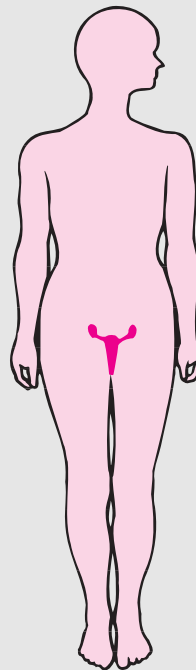
Digestive System



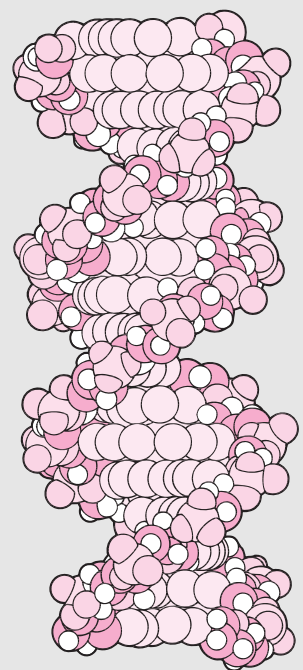
The Senses



Respiratory System



Reproductive System



Cells and Genetics

There are many different types of human cells, for example, blood cells, nerve cells, and muscle cells. Each cell type has a structure adapted to perform particular tasks. However, all human cells (and those of other animals) share a similar basic structure and contain a range of internal structures known as organelles. Human cells even share features with plant cells.

Cell facts

- A cell's organelles are surrounded by a liquid called cytoplasm.
- Mitochondria release energy from food.

Basic cell structure

- The cell is surrounded by a narrow fatty layer called the cell or plasma membrane.
- The nucleus is the cell's control center containing its DNA.
- The nuclear membrane is another fatty layer that encases the nucleus.
- Chromosomes are bar-like structures found inside the nucleus. They hold the DNA and are only clearly visible just before and during cell division.
- The cytoplasm, a gel-like fluid, surrounds the nucleus.
- Organelles are suspended in the cytoplasm. Each organelle has a particular job.
- Centrioles are a pair of rod-shaped organelles involved in cell division.

Basic cell structure

Mitochondrion

Endoplasmic reticulum

Nuclear membrane

Ribosome

Lysosome

Vacuole

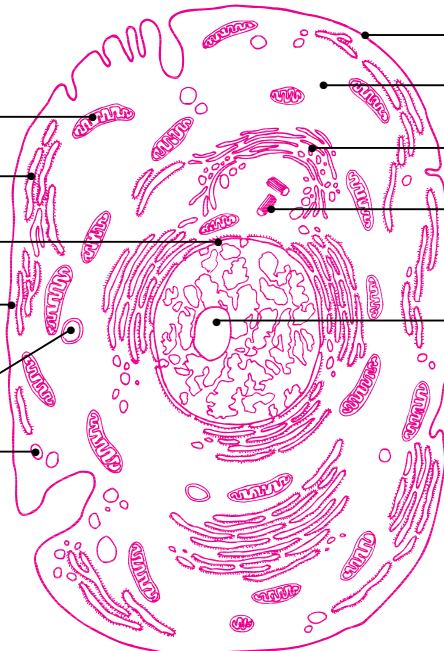
Plasma membrane

Cytoplasm

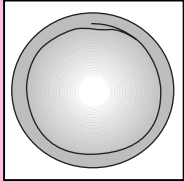
Golgi apparatus

Centriole

Nucleus

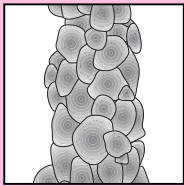


Cellular scale

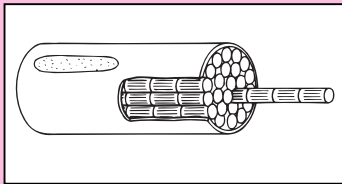


A micron, or micrometer (μm) is 1 millionth of a meter, or $\frac{1}{2500}$ inch.


300 μm human egg cell



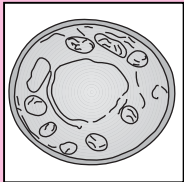
10 μm stomach wall cell



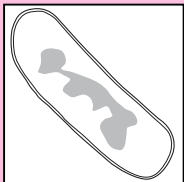
1–30 mm muscle cells



7.5 μm red blood cell



5 μm yeast cell



1.5 μm E. coli bacterium

Cellular scale

Human cells come in a wide range of sizes. A human egg cell (ovum) is comparatively large. At 300 μm in diameter, it is just about visible to the naked eye. Most other cells in the body are a fraction of this size. The cells that line the stomach are relatively large. Like skin cells, these are gradually shed. Muscle fibers, or myofibrils, would at first glance appear to be the largest body cells since they can be anything from 1 mm to almost 3 cm long. However, although these fibers are bound by a single cell membrane, they are not really a single cell since they are multinucleated—they may contain many thousands of nuclei each.

Red blood cells are at the smaller end of human cells. They lack many of the internal features of other cells.

Single-celled organisms, such as yeast (a fungus) and bacteria tend to be small. It would take about 500 bacteria, each 1.5 μm long, to cover the period at the end of this sentence.

Levels of organization

The body is a single organism (living creature) made up of many different substances and structures. These can be arranged into levels of increasing complexity called levels of organization, beginning with the most basic.

1 Biochemistry: atoms and molecules make the substances that are the building blocks (for example, water and protein) of all the other levels.

2 Cells are the smallest living units of the body.

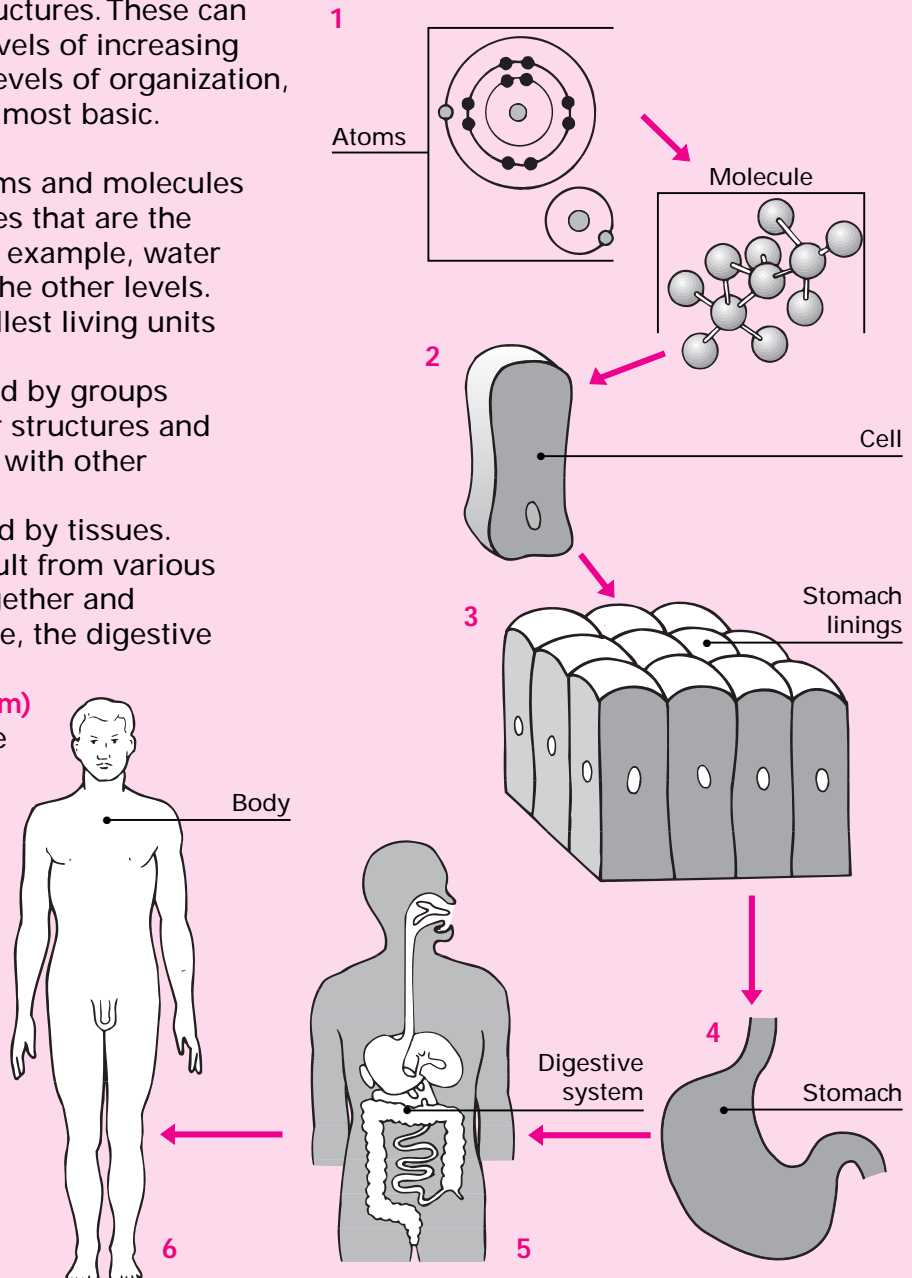
3 Tissues are formed by groups of cells with similar structures and functions (together with other substances).

4 Organs are formed by tissues.

5 Body systems result from various organs working together and include, for example, the digestive system.

6 The body (organism) is the sum of all the levels existing and operating together.

Structures of the body



Cells, tissues, and organs

It is estimated that the human body contains about 100 trillion cells. These are specialized to perform certain functions and have a wide variety of shapes and sizes. They are organized into separate structures within the body.

Tissues

Cells of the same type are organized into layers or other types of groupings known as tissues.

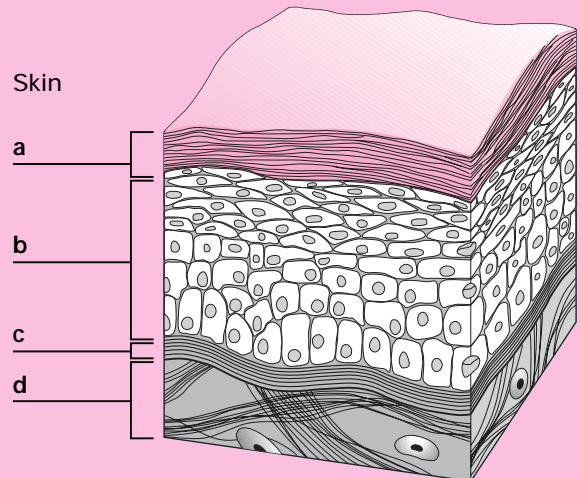
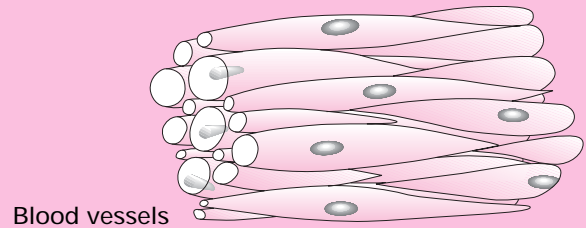
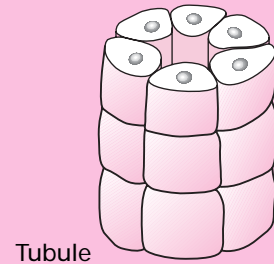
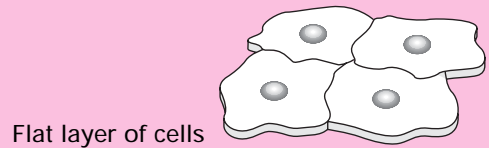
The cells in tissues are devoted to a narrow range of functions. Examples of tissues include:

- cells arranged to form a thin layer of tissue (epithelium) as found in the lining of the mouth;
- cells forming a tubule (small tube) as in a kidney tubule; and
- muscle cells arranged in a sheet of muscle tissue, as occurs in the wall of arterial blood vessels.

Organs

Tissues of different kinds are themselves grouped together to form the organs of the body. These include the skin, heart, liver, and kidneys. For example, human skin contains several distinct layers of tissue:

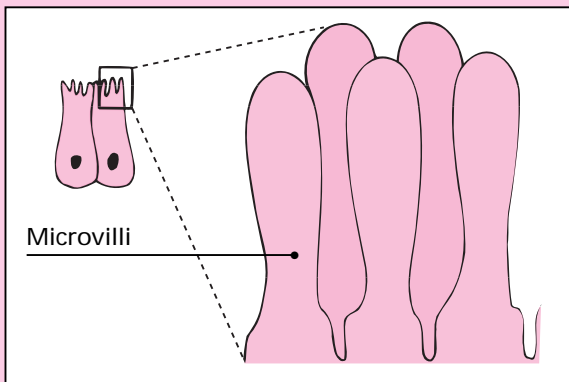
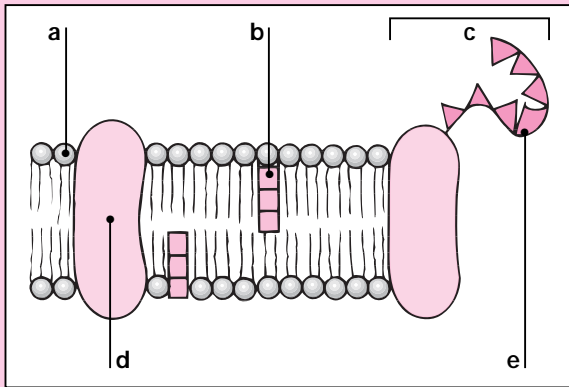
- a protective layer of dead cells (a) to prevent infection, and drying out;
- epidermal cells (b), some of which form the hair follicles;
- a basement membrane (c) separating the epidermis from the dermis; and
- the dermis layer (d), which includes cells responsible for maintaining the strength and integrity of the skin, as well as sensory nerve endings, blood vessels, and muscle fibers.



Cell membrane structure

The cell membrane is a thin sheet of fats, or lipids, interspersed with large protein molecules. A lipid molecule has two halves: a water-soluble end and a water-repelling one. A membrane is a double layer of phospholipid molecules. The water-repelling ends form the outer surfaces and the water-soluble ends mingle in between.

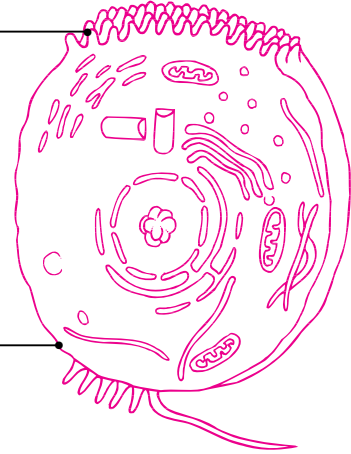
The cell membrane controls the flow of materials in and out of the cells, and maintains the cell's integrity.



Cell membrane

Microvilli

Cell membrane



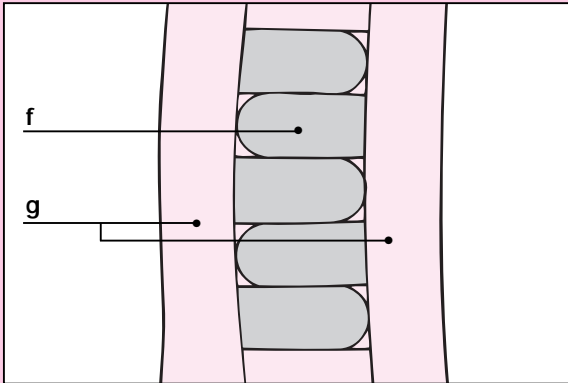
Lipid bilayer

This fatty double layer contains:

- Phospholipids (**a**)—fat molecules containing phosphorus;
- cholesterol (**b**)—fat molecules that stabilize the lipid layer; and
- glycoproteins (**c**) which are made up of protein (**d**) and carbohydrate (sugar) molecules (**e**) on the extracellular (outer) surface of the protein.

Microvilli

These are tiny, fingerlike projections, or folds, of the cell membrane itself. The function of microvilli is to increase the surface area of the cell. This allows the cell to absorb more substances from their surroundings and also to secrete molecules more efficiently.

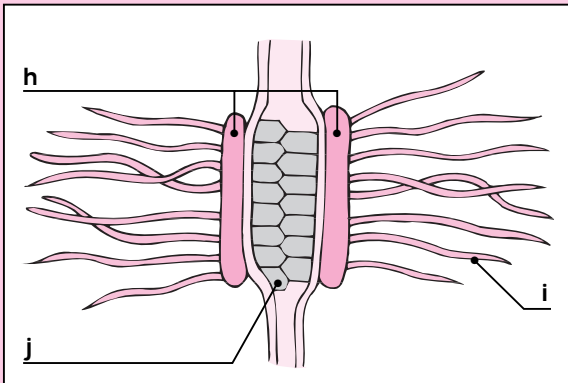


Types of cell junction

(See also page 30.)

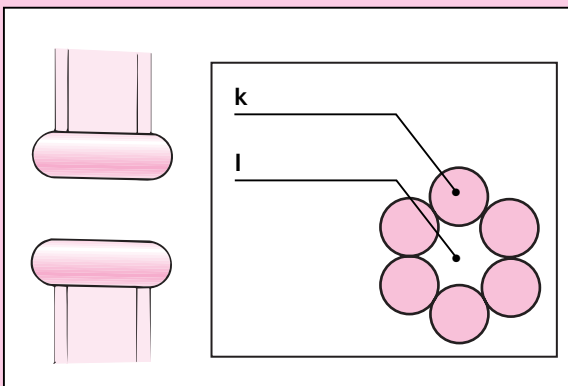
Tight, or impermeable, junction

This is formed by protein molecules (f) of neighboring cell membranes (g) fusing together. Tight junctions are found between the epithelial cells that line the digestive tract.



Desmosome, or anchoring, junction

At these junctions, on the insides of the neighboring cells, are rivetlike thickenings called plaques (h). These are attached to the opposite side of the cell membrane by keratin filaments (flexible protein strands also used in hair) (i). Linker proteins (j) extend from the plaques and cross the space between the cells.



Gap, or communicating, junction

Proteins (k) pass through both the membranes of two adjacent cells. The proteins are arranged into groups (connexons) which form a hollow channel (l) through the cell membranes. These junctions are found in heart muscles and in the muscles of the gut.

Selective barrier

The cell membrane is a protective barrier that controls what substances travel in and out of the cell. Although

oxygen and carbon dioxide pass through freely, other substances have difficulty getting through the membrane.

The cytoplasm

The cytoplasm (semifluid mixture) is the cellular material outside of the nucleus (control center) and inside the cell (plasma) membrane. In humans, as well as all plants and other animals, cytoplasm consists of cytosol (a gel-like fluid), cytoplasmic organelles (miniorgans), and inclusions (chemical substances). Prokaryotic cells (those of bacteria and primitive algae) have a cytoplasm and inclusions, but no organelles.

As a whole, the cytoplasm assists in the movements of organelles and the transport of substances within the cell; provides an environment in which biochemical reactions can occur; and helps to support and shape the cell.

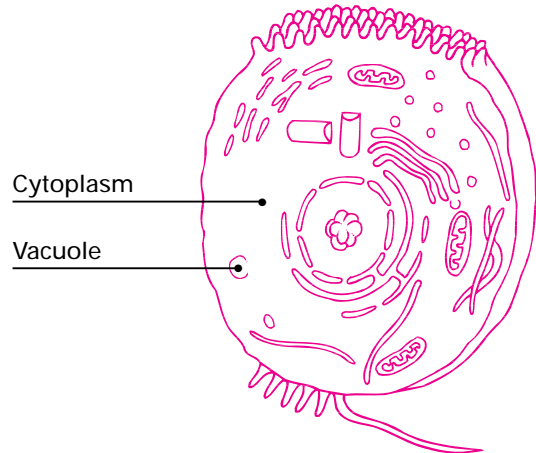
Cytosol

This is a gel-like, semitransparent fluid mostly comprised of water. It contains dissolved sugars, salts, and other solutes. Larger molecules, such as proteins, form colloids. The cytosol holds the other elements of the cytoplasm in suspension. Many vital substances, such as starch, are stored in the cytosol in this way until they are needed by the organelles in the cell.

The cytosol is able to change from a semifluid to a more solid state (in conjunction with the cytoskeleton). This is important for many cell functions.

Inclusions are substances stored in the cytosol. The inclusion depends on the cell type. In adipocytes (fatty cells), the lipid (fat) droplet is an inclusion. Pigments (colorings) such as melanin in skin cells also count as inclusions.

Cytoplasm



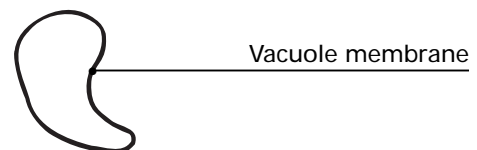
Vacuole

This is a large, membrane-enclosed, sac that can occupy up to 90 percent of the cell's volume. The vacuole

- helps maintain cell shape and osmotic balance;
- stores sugars, salts, and toxins; and
- pushes the cytoplasm to the edge of the cell, which aids the intercellular transport of substances.

The vacuole membrane controls the movement of substances between the cytoplasm and the vacuole.

A cell vacuole



Storing mucus

Many glands store their products in the cytoplasm before secreting them. Goblet cells are the most common unicellular glands. They secrete mucus (thick, slimy fluid), which protects surfaces from abrasion, catches foreign objects, and lubricates passageways. The mucus is stored in the cytoplasm before it is released.

Goblet cell

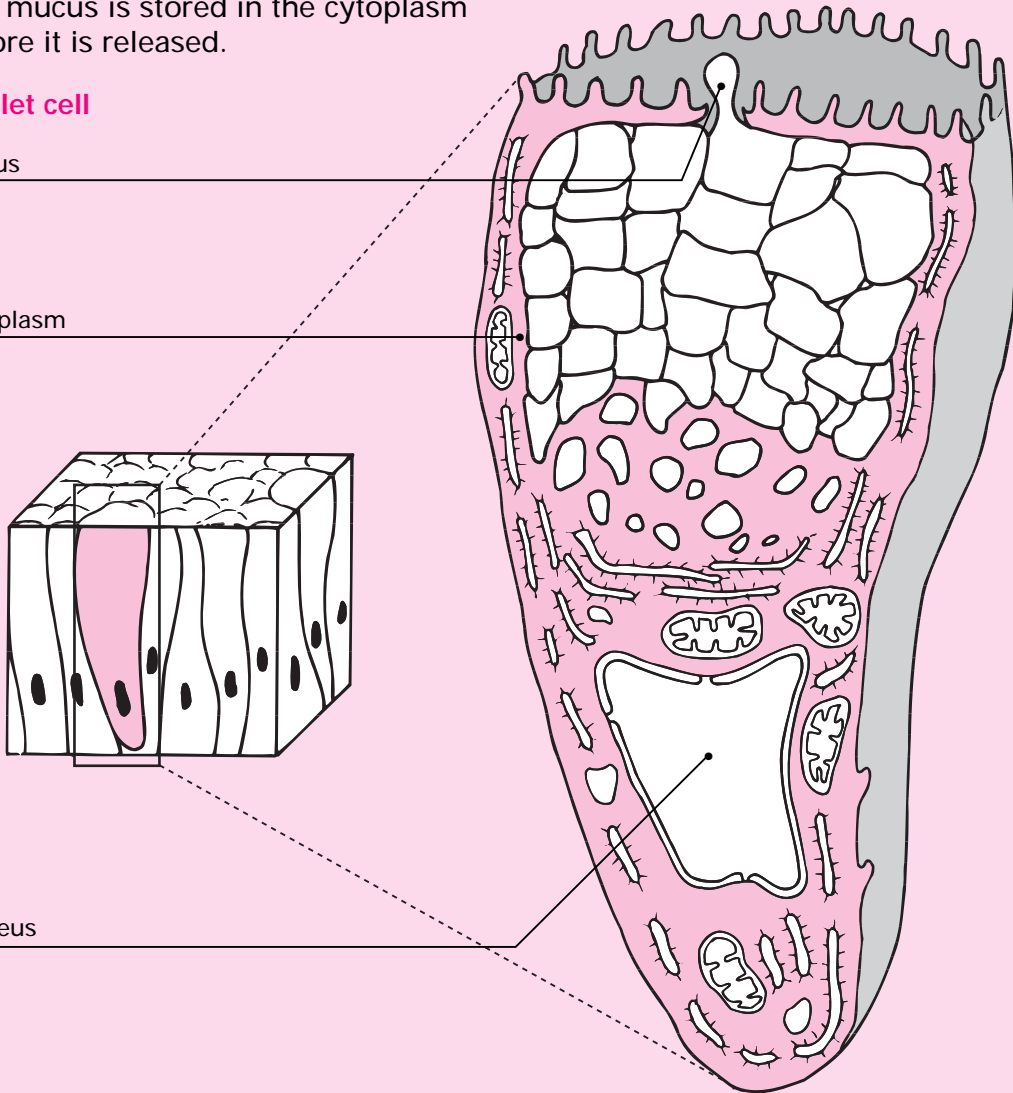
Mucus

Cytoplasm

Nucleus

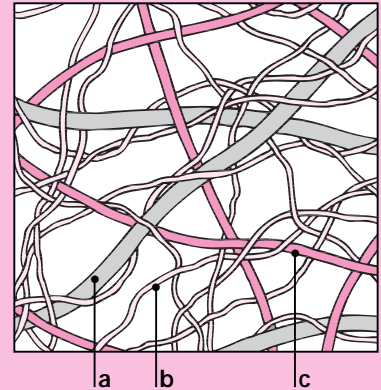
Exocrine gland facts

- Exocrine glands, such as goblet cells, release substances from the body.
- Goblet cells are commonly located in the digestive, respiratory, and reproductive tracts.



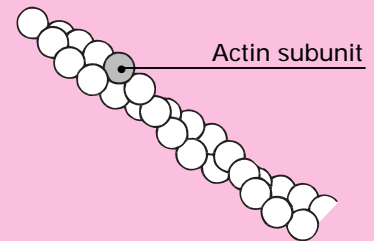
The cytoskeleton structure

The cytoskeleton is a kind of intracellular scaffolding. It consists of a complex network of tiny protein fibers and tubes suspended in the cytosol (gel-like fluid) inside a cell. The cytoskeleton is a dynamic structure that constantly changes as the cell grows and especially when it divides. It comprises three types of protein structures: microtubules (tiny tubes) (a); microfilaments (tiny fibers) (b); and intermediate filaments (c). None of these has a covering membrane.



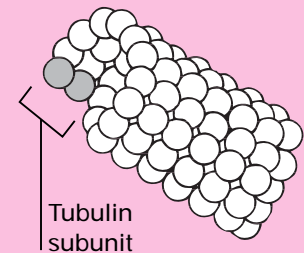
Microfilaments

- Microfilaments are thin strands of the protein actin.
- They are 5–9 nanometers (nm) wide.
- The actin subunits are arranged in two chains.
- Actin has the ability to contract (shorten).
- Microfilaments form bundles, flat meshes, or three-dimensional networks.
- They are most abundant at the periphery of the cell.
- They are frequently broken down and reassembled.



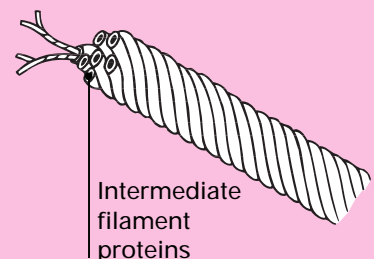
Microtubules

- Microtubules are hollow cylinders of tubulin protein.
- They are about 20–25 nm wide.
- The tubulin subunits are spherical.
- Microtubules radiate from the centromere (structure at the cell center).
- Like microfilaments, they are frequently being broken down and reassembled.
- Organelles are arranged along the microtubules.



Intermediate filaments

- These are fibers made from a range of protein.
- Intermediate filaments are about 10 nm wide.
- These filaments extend throughout the cytoplasm. They are attached to the cell membrane and may span the cell from one side to the other.
- Intermediate filaments form a mesh inside the nucleus.
- Intermediate filaments are the most permanent and stable part of the cytoskeleton.



Ameboid movement

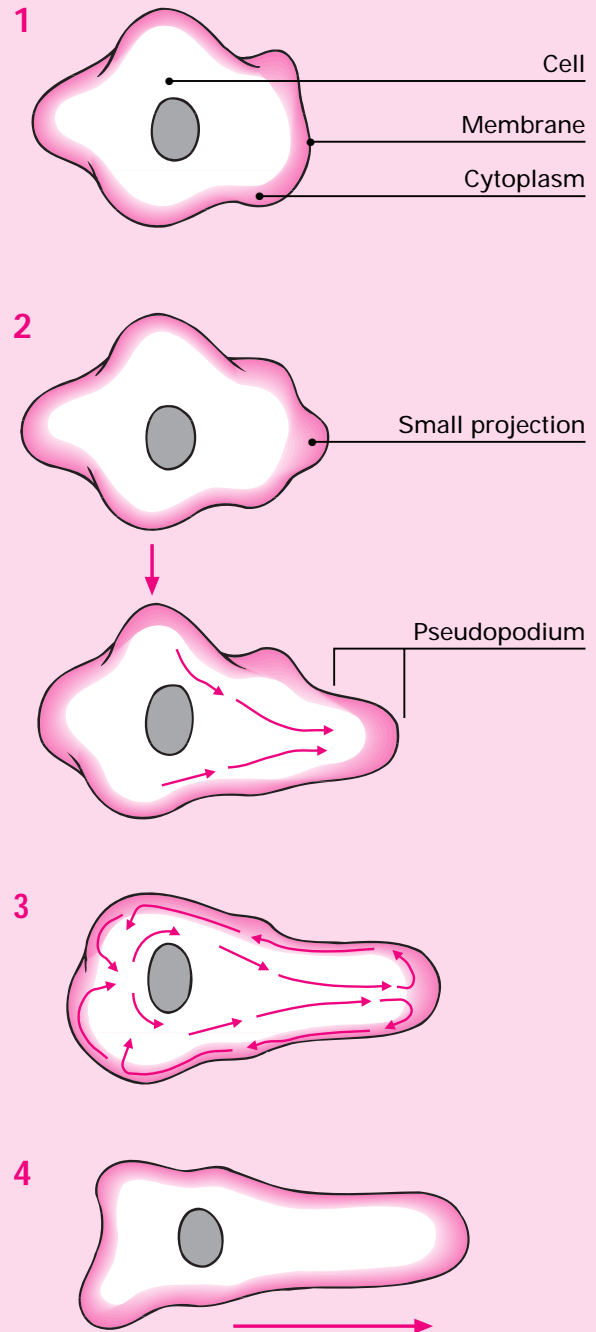
The cytoskeleton is involved in ameboid movement used by white blood cells in humans and a range of cells in the natural world. The movement involves a pseudopodium (false foot).

1 Inside the cell, its cytoplasm comprises a fluid endoplasm and a more-solid ectoplasm. In a stationary cell, the endoplasm is found in the center and the ectoplasm is closer to the cell membrane.

2 In order for the cell to move, the ectoplasm forms a small projection. Endoplasm flows in and the projection becomes a pseudopodium.

3 As endoplasm reaches the end of the pseudopodium, it is converted into ectoplasm. As this ectoplasm flows back along the cell membrane, the pseudopodium is lengthened further. Simultaneously, the reverse is happening at the rear of the cell; the ectoplasm is converted into endoplasm and travels to the front of the cell, bringing the rear forward (**4**).

Microfilaments are involved in generating ameboid movement, although it is not known exactly what their role is. It may be that the microfilaments fold up in the endoplasm and open out in the ectoplasm. This would squeeze the endoplasm forward. The microfilaments may slide against each other moving the endoplasm forward, or the microfilaments disintegrate at the front and reassemble at the rear, taking the endoplasm with them.

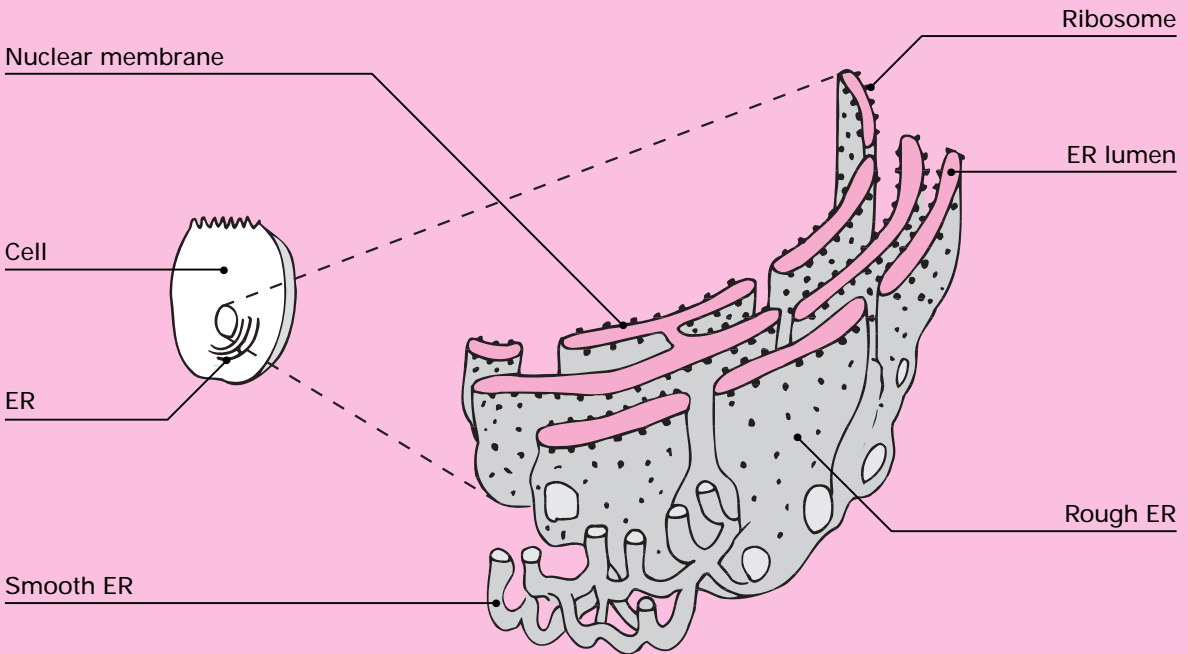


Endoplasmic reticulum structure

Endoplasmic reticulum (ER) is a type of organelle inside a cell. ER is a network of fluid-filled tubes. There are two types of ER, rough and smooth. A cell may have both or only one, depending on its function.

- Rough ER is joined to the nuclear membrane. Its external surface is studded with ribosomes (organelles involved with protein formation).
- Smooth ER is continuous with rough ER but has no ribosomes.

Rough and smooth ER



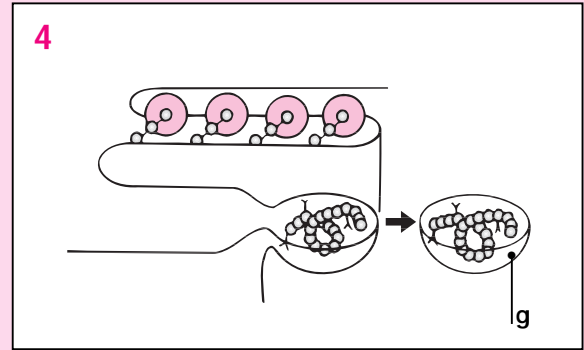
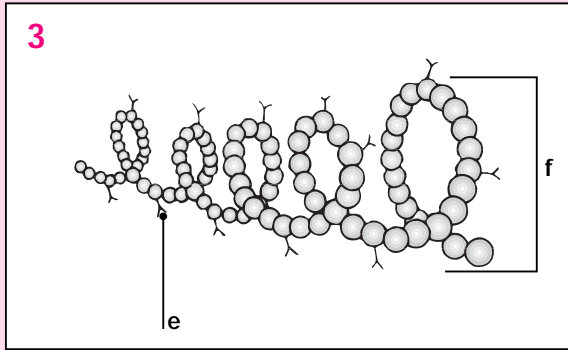
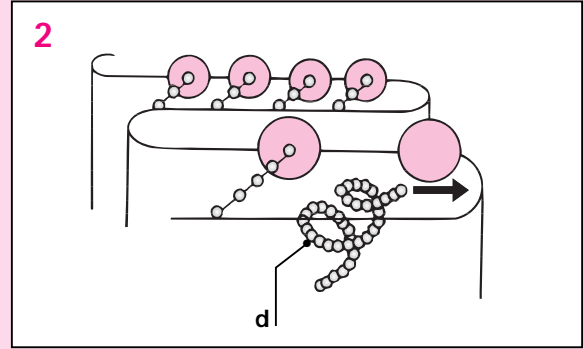
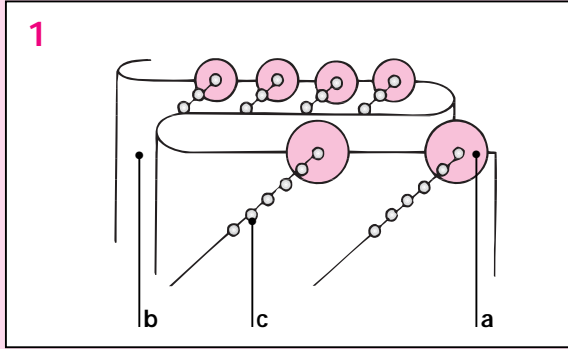
Reticulum facts

- More than half of the membranes inside a cell are used to form the ER.
- The ER extends from the nucleus all over the cell forming a meshwork. As a result, no portion of the cytoplasm is far from the ER.

Intracellular transport facts

- A single highly-folded membrane surrounds the entire ER.
- The space inside the ER is called the lumen.
- Proteins made by the ER travel through the lumen before being released.

Endoplasmic reticulum functions

**Rough ER**

- Manufactures the building blocks of cell membranes (phospholipids and cholesterol).
- Helps make and transport proteins.
- The external face provides a site for chemical reactions.

Protein synthesis and transport

- 1** Ribosomes (a) on the rough ER wall (b) manufacture protein strands (c).
- 2** Within the lumen, the protein strands fold into distinctive shapes unique to their chemical structure, identifying them as specific proteins (d).
- 3** Sugars (e) may be added to proteins to form glycoproteins (f).

- 4** Completed proteins are encased in membranous vesicles (tiny membrane sacs) (g), which pinch off the ER and travel to other sites in the cell.

Smooth ER

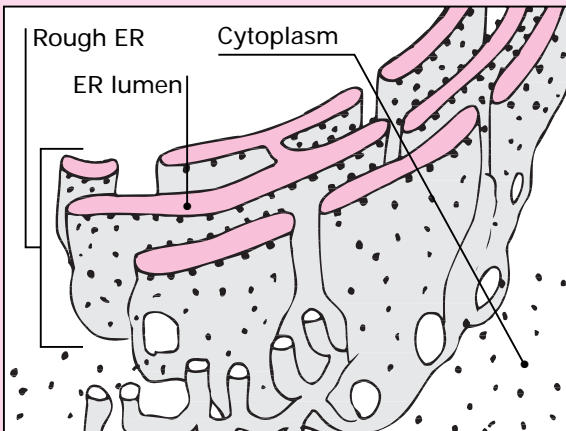
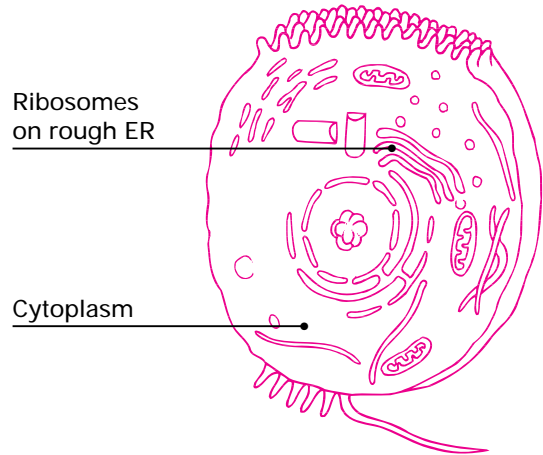
Enzymes (biological catalysts) embedded in its membrane walls are involved with chemical reactions concerning:

- the making of cholesterol;
- the making of sex hormones (steroids, hormones made from cholesterol);
- processing fats;
- the detoxification of poisons; and
- muscle cell contraction.

Location and structure

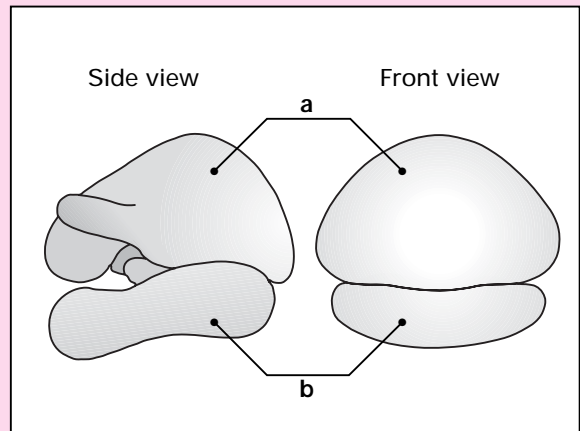
Ribosomes are organelles found inside a human cell. They are also found in all other plant and animal cells. Ribosomes are used to decode DNA (deoxyribonucleic acid) into proteins. They are tiny, round granules. Ribosomes are located on the rough endoplasmic reticulum (giving it the "rough" appearance). They are also found individually throughout the cytoplasm.

Ribosome



Close to the nucleus

Ribosomes are most obvious on the rough ER, where most of the cell's proteins are manufactured. Ribosomes read mRNA (messenger ribonucleic acid) molecules, a type of nucleic acid copied from the cell's DNA, that are carried from the nucleus through the ER lumen.



Decoders

Ribosomes have two parts, a large (a) and a small (b) subunit. They are made of rRNA (ribosomal ribonucleic acid) and proteins. Each ribosome is just over 20 nm in diameter and 30 nm in height. mRNA molecules are passed between the two units. At this point the three-letter code of the mRNA is translated.

Functions of ribosomes

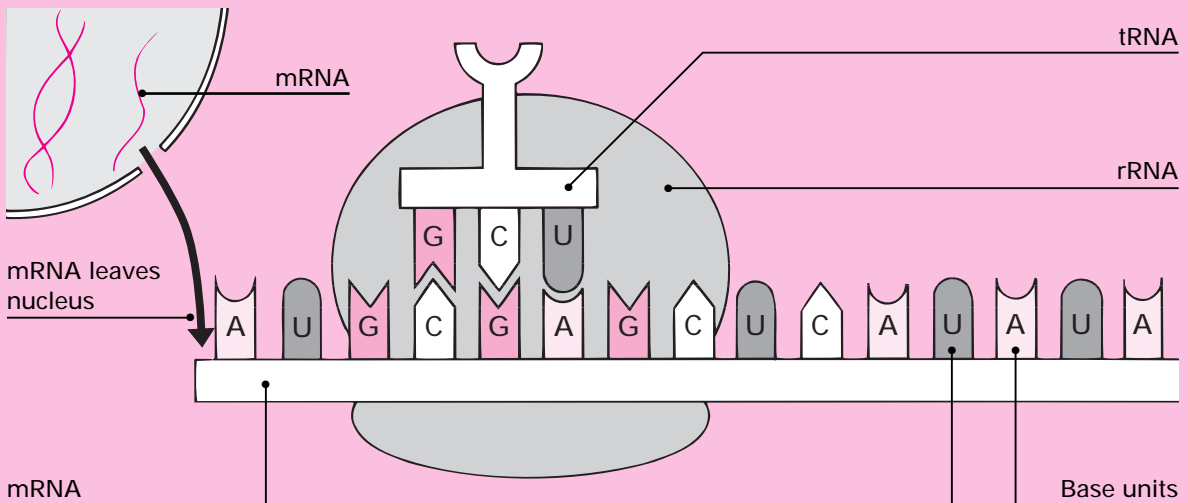
When held between the ribosomal subunits, the single strand of mRNA comes into contact with another type of nucleic acid called tRNA (transfer RNA). tRNA molecules are coded to attach to specific amino acids, the building blocks of proteins.

The mRNA codes for particular amino acids using three-letter "words," or codons. The letters in each word correspond to bases, special units lined up along the RNA molecule. The bases are guanine (G), cytosine (C), adenine (A), and uracil (U). The four bases form pairs of opposites: G with C and A with

U. Therefore, each codon of mRNA bonds to a corresponding tRNA molecule made up of the opposite bases. In so doing, the tRNA places the correct amino acid into its right position for the protein being produced.

Free ribosomes (those not attached to rough ER) are involved in making proteins, such as enzymes, to be used by the cell itself. Membrane-bound ribosomes (those attached to rough ER) are mostly involved in making proteins that will be used in the cell membrane or exported out of the cell.

DNA on chromosome
in nucleus



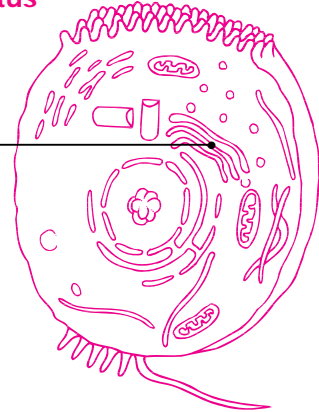
The Golgi apparatus

The Golgi apparatus, or complex, is an organelle found in most human cells. It is usually located near the nucleus at the center of the cell. It is named after the 19th-century Italian anatomist Camillo Golgi, and is associated with the secretion of substances from the cell.

- The Golgi apparatus is a stack of four to six flat, membrane-enclosed, disk-shaped sacs known as cisternae. The stacked cisternae resemble a pile of dishes.
- A large number of membranous vesicles (tiny membrane sacs) surround each Golgi apparatus. Most vesicles are located on the side of the Golgi apparatus nearest to the rough endoplasmic reticulum (ER).
- Each Golgi stack has two “faces,” or sides. The cis face is on one side and the trans face is on the other. In general, the cis face looks toward the rough ER and the trans face toward the cell (plasma) membrane surrounding the cell. These faces are functionally and biochemically different, and contain very different enzymes (biological catalysts).
- Each face is connected to its own network of branching and interconnected tubules (tiny tubes). These are known as the cis-Golgi and trans-Golgi networks.
- Proteins and lipids travel from the ER to the cis face in the vesicles, where they enter the cisternae. These substances are then released through the trans face in other vesicles.

Golgi apparatus

Golgi apparatus

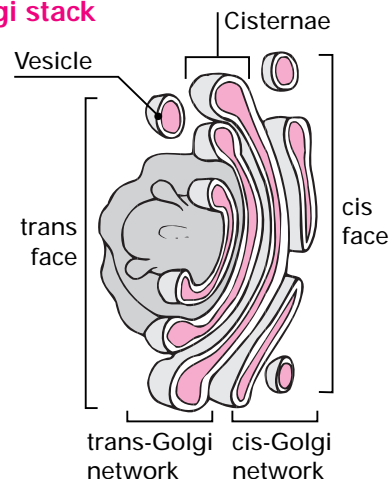


Golgi apparatus facts

The Golgi apparatus prepares and delivers proteins and other molecules ready for:

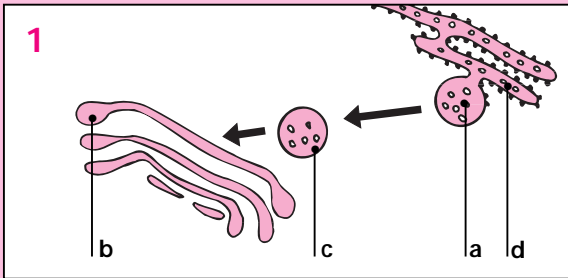
- secretion from the cell;
- inclusion in lysosomes (sacs of digestive enzymes); and
- incorporation into the cell.

Golgi stack

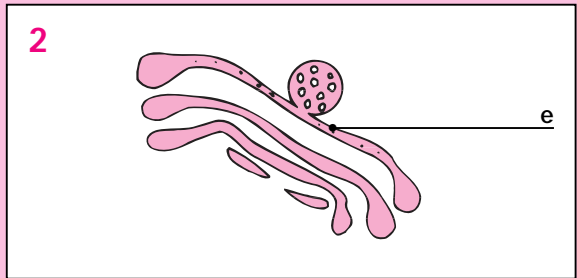


Protein preparation and delivery

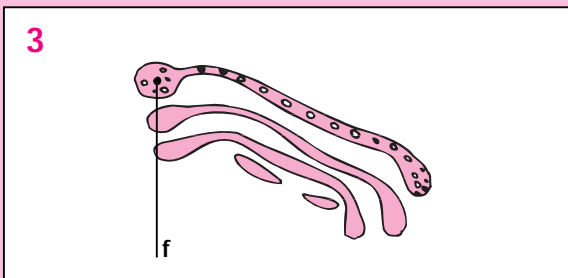
1 Proteins (a) are delivered to the Golgi apparatus (b) in vesicles (c) sent by the rough endoplasmic reticulum (d).



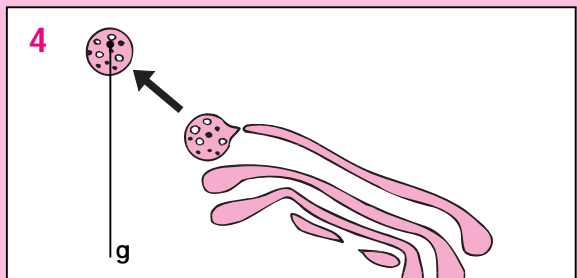
2 The vesicles fuse with the membranes of the cis face (e) of the Golgi apparatus.



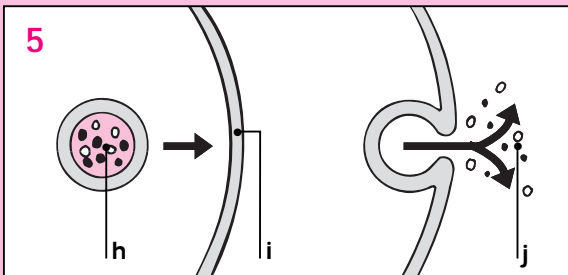
3 Within the lumen (internal space) of the cisternae, the proteins are packaged into Golgi vesicles (f).



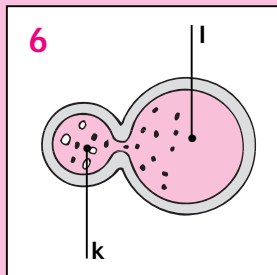
4 These vesicles (g) pinch off from the trans face of the Golgi stack and move to other parts of the cell.



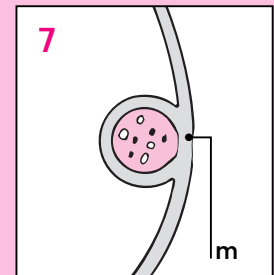
5 Vesicles containing proteins for secretion (h) merge with the cell membrane (i) and eject their contents (j). This process is called exocytosis.



6 Vesicles (k) containing enzymes fuse with lysosomes (l).



7 Membrane components are fused with the cell membrane (m).



Nucleus structure

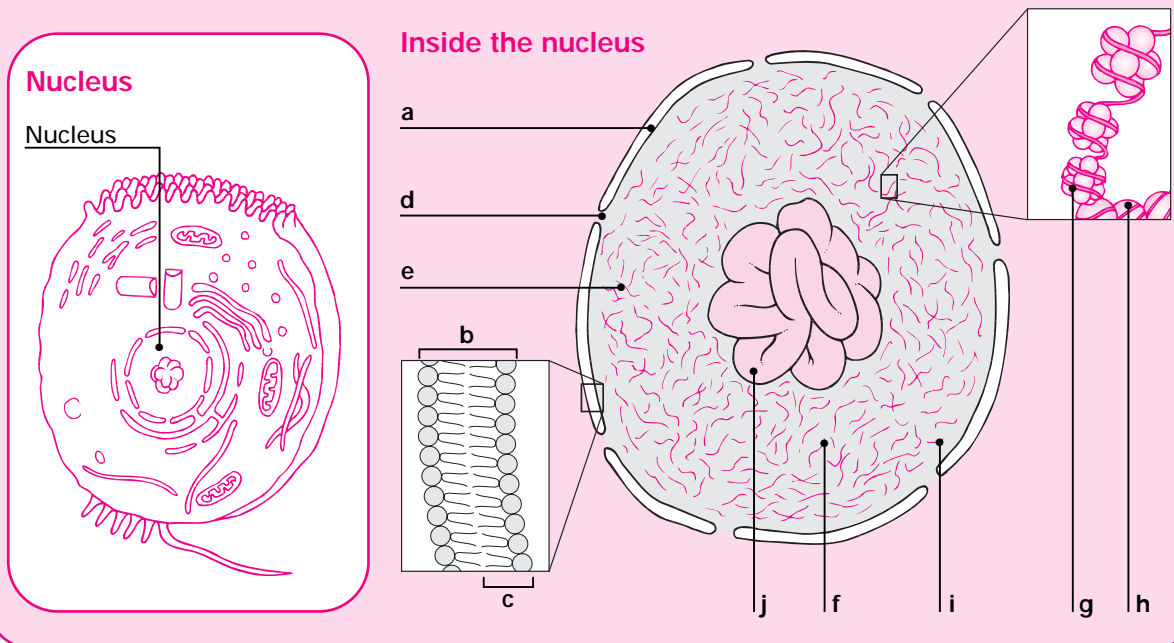
The nucleus is usually located at the center of a cell. Its shape often reflects the cell's shape. For example, flat cells have flat nuclei.

A nucleus consists of:

- The **nuclear envelope** (a). This is made up of two membranes. Like the cell membrane, each nuclear membrane consists of a phospholipid bilayer (b)—two layers of phospholipid molecules (c).
- **Nuclear pores** (d) At certain points, the nuclear membranes fuse to form holes in the nuclear envelope.
- **Nucleoplasm** (e) This is a gel-like fluid containing vital chemicals, such as nutrients and salts. The nucleolus and chromatin are suspended in the nucleoplasm.
- **Chromatin** (f) An amorphous dark area

made up of strands of DNA (deoxyribonucleic acid) (g). The DNA is wound around histone proteins (h) comprised of chromatin fibers (i). A clump of eight histones on a DNA strand comprises one nucleosome. Normally, chromatin is not visible under a light microscope. During cell division, however, chromatin condenses to form chromosomes, which are visible under a light microscope.


- **The nucleolus** (j) This is a compact ball of RNA (ribonucleic acid) and proteins. It does not have an outer membrane. Every nucleus has one or more nucleoli.



Nucleus shapes

The nuclei in different cells have a range of shapes. Red blood cells, or erythrocytes, do not have nuclei at all. The different white blood cells (leukocytes) have unusual nuclei. Neutrophils (1) have multilobed nuclei. Eosinophils (2) have just two lobes. The nucleus of a basophil cell (3), is hard to see behind the granules of histamine it contains. Lymphocytes (4) are small cells, and their nuclei fill almost the entire cell. Monocytes (5) are very large cells. Their nuclei are often kidney-bean shaped.



Erythrocytes (red blood cells)



Leukocytes (white blood cells)
1 Neutrophil




2 Eosinophil

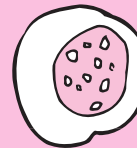

3 Basophil

4 Lymphocyte

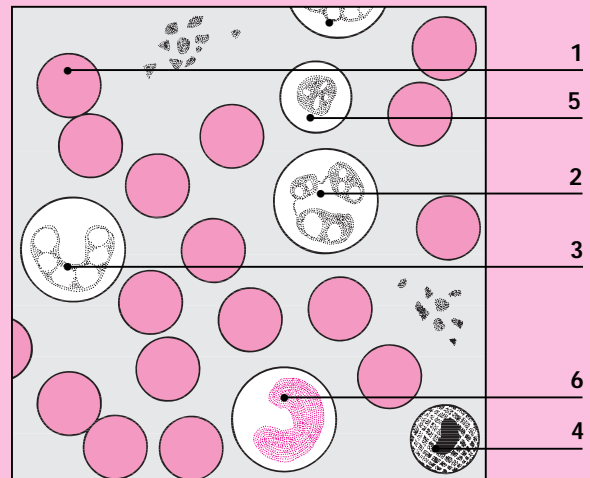


5 Monocyte



Blood components

The nucleus is the largest, most important organelle in most human cells. However, mature red blood cells (1) do not contain a nucleus. As a result, red blood cells cannot undergo cell division. The red blood cell is nucleated at an early stage of development, but then ejects its nucleus to become largely a vessel for hemoglobin (a blood protein). Nucleated blood cells include neutrophils (2), eosinophils (3), and monocytes (6), which kill invading organisms. Basophils (4) produce histamines to fend off infections, and lymphocytes (5) produce antibodies.



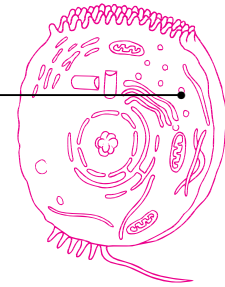
Lysosomes structure and function

Lysosomes are generally round, single-membrane sacs suspended in the cell's cytoplasm (semifluid mixture). Lysosomes contain many different digestive enzymes (biological catalysts used to break down large molecules into their constituents) and have an internal pH of 5 (acidic), which helps with the digestive processes that take place inside. The number of lysosomes in a cell varies from one to several hundred. They are especially prevalent in phagocytes, "engulfing" white blood cells, such as neutrophils and eosinophils, which need to break up the harmful material they absorb. The contents of lysosomes also break down glycogen (stored carbohydrate); destroy

injured, redundant, or harmful tissues and cells by releasing their enzymes—a process known as autolysis (cell self-destruction)—and provide sites where substances, such as bacteria, poisons, cellular debris, and malfunctioning organelles can be safely digested within the cell.

Lysosome

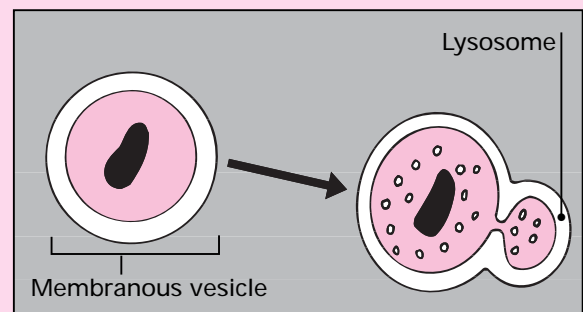
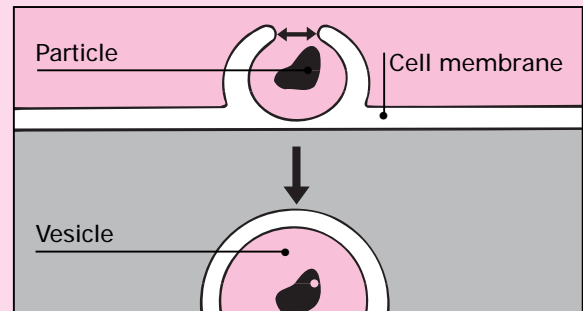
Lysosome



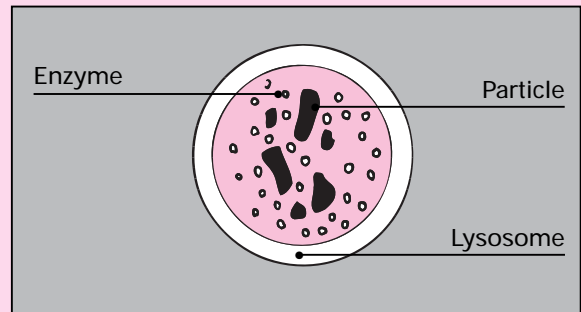
A lysosome at work

The particle enters the cell by a process such as phagocytosis (cell "eating"). This takes place by endocytosis: the cell membrane engulfs the particle, which is then released into the cell inside a large membranous vesicle.

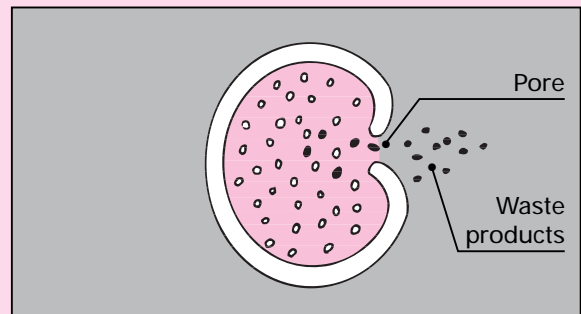
The phagocytic vacuole or large membranous vesicle formed fuses with a lysosome so the contents of the two bodies mix.



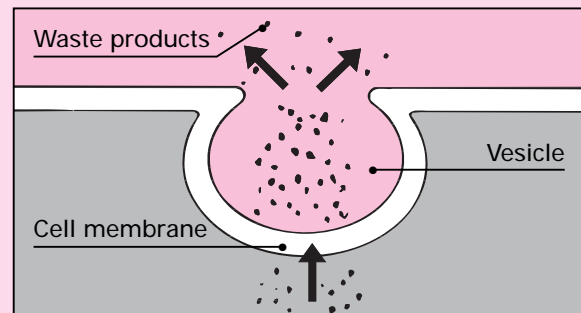
The enzymes in the lysosome digest the particle's molecules. Many of the enzymes break down the molecules by hydrolysis. This is a chemical process that takes oxygen and hydrogen atoms out of a molecule to form water. This also causes the large molecules to break into smaller units.



The resulting harmless waste products are released through a pore in the lysosome into the cytoplasm. Many of these substances, such as water, amino acids, or phosphate compounds, are useful to the cell and are recycled.

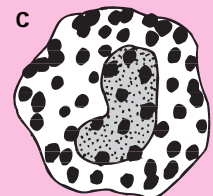
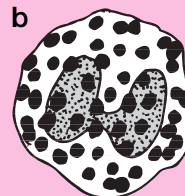
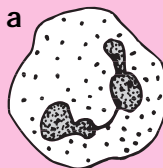


The unwanted wastes are secreted from the cell by exocytosis. This process is the opposite of endocytosis. The waste is enclosed in a vesicle. The membrane of this vesicle then fuses with the cell membrane. In this way, the vesicle is opened on the outside of the cell, and its contents are released.



Cells plus lysosomes

Neutrophils (a), eosinophils (b), and basophils (c) are known as granulocytes. The granular appearance of a and b is caused by their many lysosomes. Basophils contain granules of histamine.



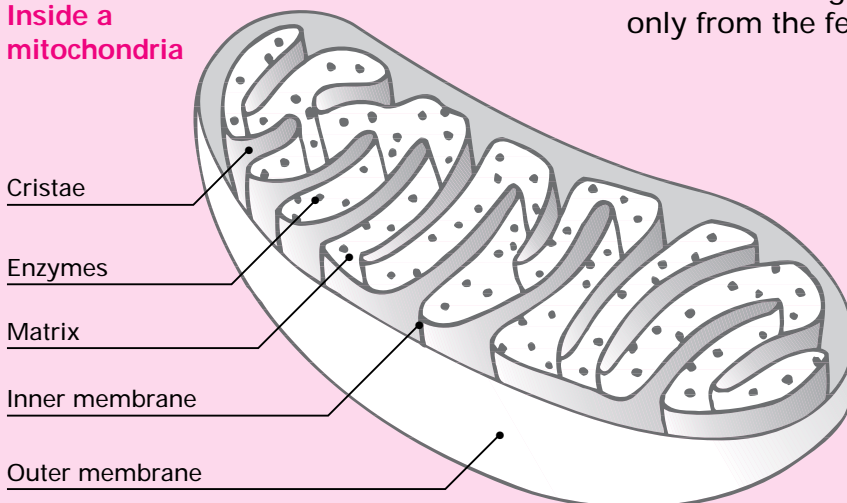
The cell's power plants

Mitochondria (singular: mitochondrion) are membrane-bound organelles found inside all human cells. They release energy from nutrients derived from food. Mitochondria are scattered throughout the cytoplasm.

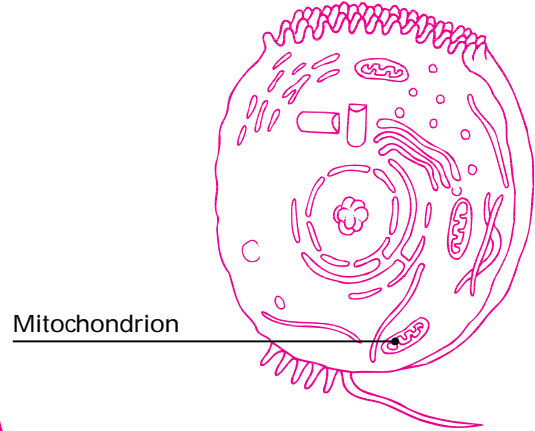
Mitochondria are often depicted as sausage-shaped, rod-shaped, or spherical, depending on which cell the example is from. In a living cell, however, they are constantly changing shape. Each mitochondrion has:

- a smooth outer membrane;
- an inner membrane heavily folded into cristae (shelf-like structures);
- a matrix (gel-like substance inside the inner membrane);
- enzymes (biological catalysts) dissolved in the matrix and embedded in the cristae; and
- its own genes—mitochondrial DNA (deoxyribonucleic acid), or mtDNA is

Inside a mitochondria

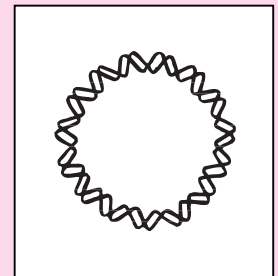


Mitochondria



usually found in a double-stranded circular plasmid (simple, bacteria-like DNA). Mitochondria possess this DNA because it is thought that they were once a type of free-living bacteria, which started to live and function within other cells. In sexually-reproducing organisms, the mitochondrial genome is derived only from the female.

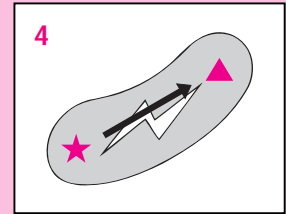
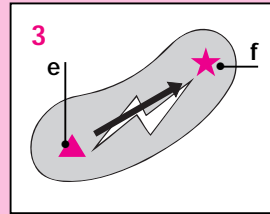
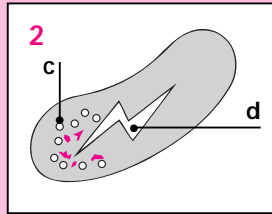
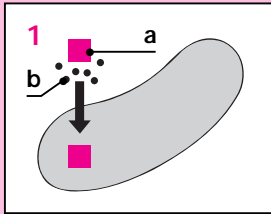
Mitochondrial DNA plasmid



Function of mitochondria

Mitochondria are involved in cellular respiration: the production of the cellular energy storage molecule ATP (adenosine triphosphate). Fatty acids

and amino acids (building blocks of proteins) and glucose (simple sugar) can all be broken down to give energy. Glucose is the example given below.



Cellular respiration

1 Glucose (a) and oxygen (b) enter the mitochondrion.

2 Enzymes (c) break the glucose down, releasing energy (d).

3 This energy is used to bind a phosphate group to ADP (adenosine

diphosphate) (e) to make ATP (f). Carbon dioxide and water are also formed.

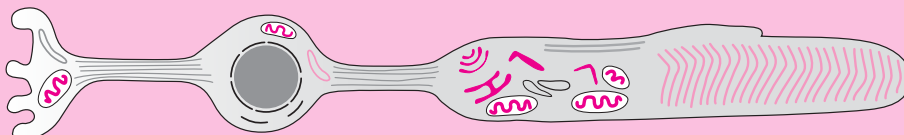
4 When the cell needs energy, the bond that holds the phosphate to ATP is broken. This releases energy and converts the ATP back into ADP.

Features

- Mitochondria can fuse with each other and then separate.
- They are most concentrated in areas in which energy expenditure is greatest.
- Cells that consume a lot of energy, such as light-sensitive rod cells (below), have many mitochondria. Cells using less energy have fewer mitochondria.
- The number of mitochondria in a cell changes according to need. If, for

- instance, a resting muscle is repeatedly stimulated to contract, the number of mitochondria in its cells will increase.
- A mitochondrion always arises from a previous mitochondrion. They replicate in the same way as bacteria.
- Mitochondria will often attach themselves to contractile proteins such as actin myofibrils in a muscle cell.
- Muscle diseases are linked to mtDNA.

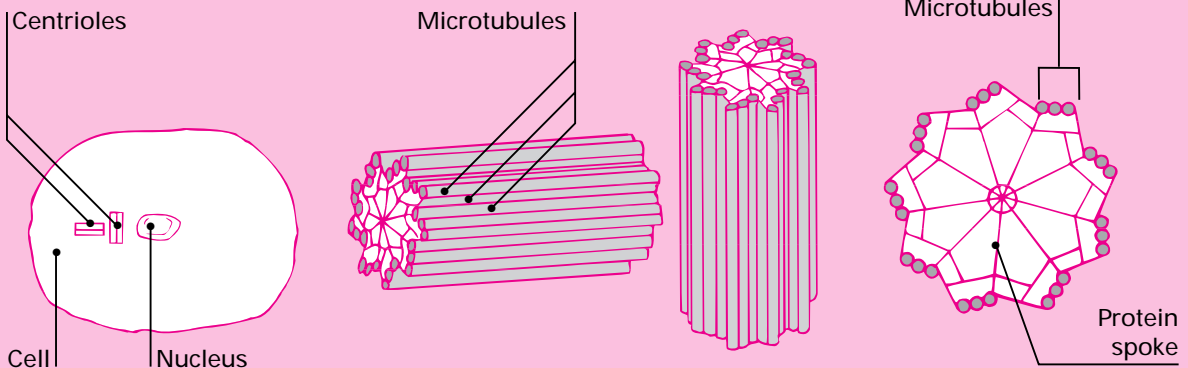
Rod cells



Centrioles

Centrioles are a type of organelle. They occur in pairs and lie at right angles to each other near the nucleus (control center) of the cell. They are bundles of

microtubules (tiny tubes) like those used in the cytoskeleton. The microtubules are arranged in nine groups of three, forming a tube.



Cilia and flagella formation

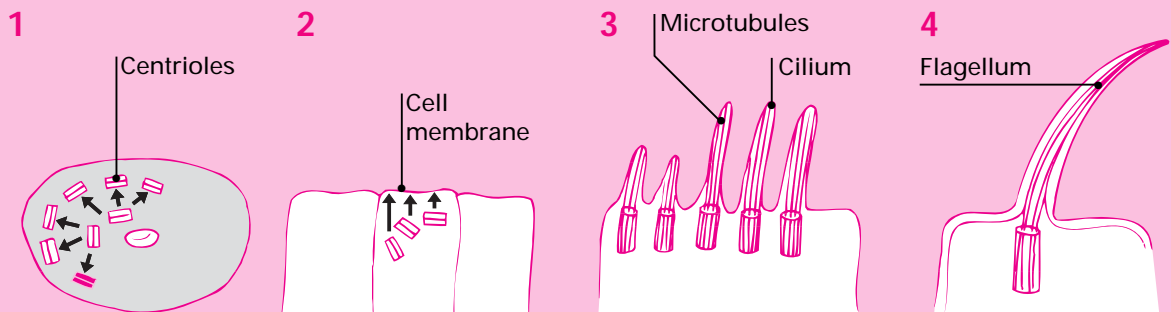
Centrioles form the bases of cilia and flagella (movable projections from the cell membrane).

- 1 The centrioles multiply.
- 2 They migrate to the cell membrane.

3 Each centriole sprouts microtubules that push the cell membrane outward to form cilia.

4 A flagellum results when microtubules form a single, longer projection.

Centrioles and flagella



Peroxisomes

Peroxisomes are a type of organelle found in human body cells, and those of all plants and animals. They are single-membrane sacs suspended in the cell's cytoplasm. Peroxisomes are very similar to lysosomes, but tend to be smaller.

They contain powerful enzymes (biological catalysts). The number of peroxisomes in a cell varies from one to several hundred. They are especially prevalent in the liver and kidney cells. Peroxisomes are formed by growth and binary fission (simple division into two) of other peroxisomes.

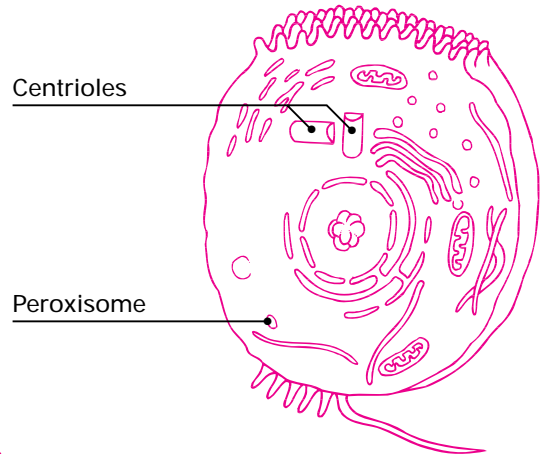
Functions

- Peroxisomes detoxify harmful and poisonous substances such as alcohol, hydrogen peroxide, and formaldehyde.
- Peroxisomes disarm dangerous free radicals.

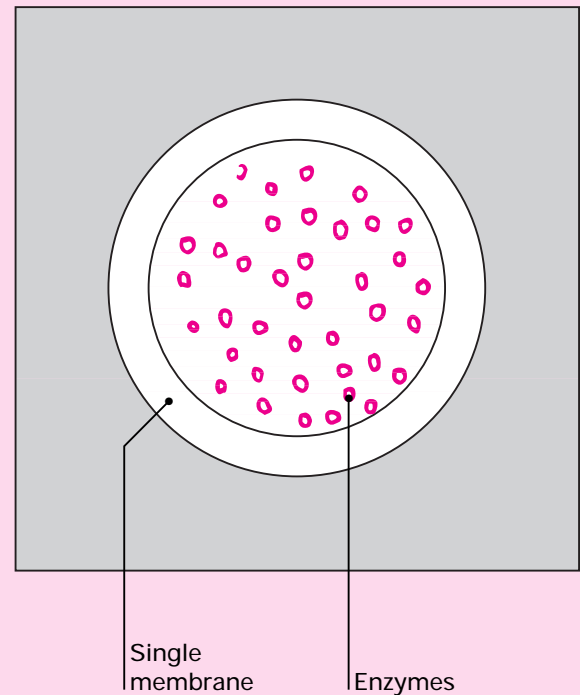
These are energetic chemicals with unpaired electrons. They can scramble the structure of vital compounds such as DNA (deoxyribonucleic acid), proteins, and lipids (fats).

- Peroxisomes also break down fatty acids. Although free radicals and hydrogen peroxide are natural by-products of cell activities, if they accumulate in tissues to certain levels they can become very harmful.

Centrioles and peroxisomes



Structure of peroxisome



Tight intercellular junctions

Tight, or impermeable, junctions are formed by protein molecules of neighboring cells fusing together like a zipper. There is no intercellular space between cells at a tight junction.

Tight junctions are found in epithelial tissues. These tissues:

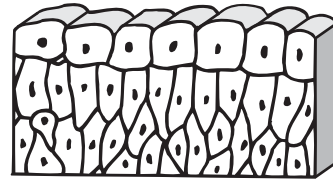
- cover the body surface as skin;
- line internal cavities; and
- form glands.

A special type of epithelial tissue called endothelium lines the walls of the heart, blood, and lymph vessels. In the brain, the endothelial cells of capillaries (the smallest blood vessels) have tight junctions. Tight junctions between epithelial cells are formed only between those parts of the cell junctions near the free surface.

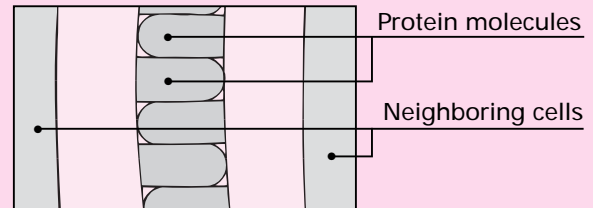
Functions

Cells that transport substances across their cell membranes have tight junctions. For example, the cells that line the intestine absorb nutrients through pores in the exterior surface of the cell membrane. The nutrients then move through the cell and out another pore to the extracellular matrix on the other side of the cell, and then into a blood vessel. The entry pores must be kept separate from those that allow passage out of the cell for this process to work efficiently. The presence of tight junctions near the outer surface is thought to maintain this separation. Without the tight junctions, the entry pores could migrate into the region of the exit pores.

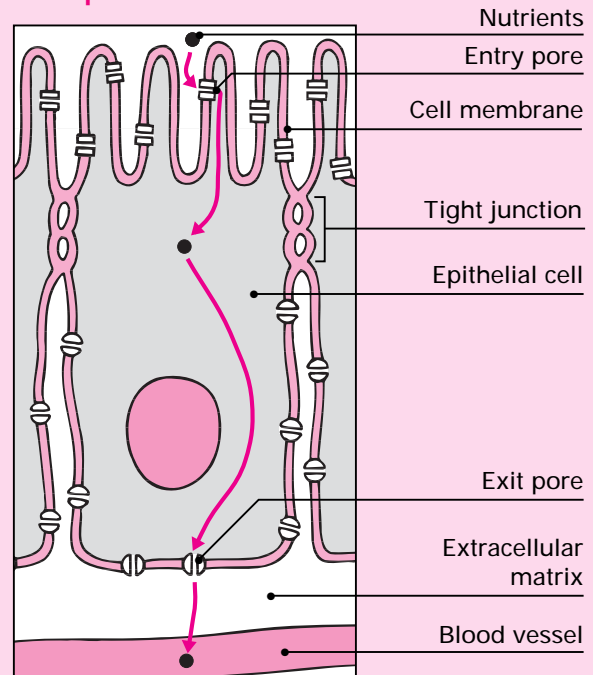
Epithelial cells



Intercellular junctions



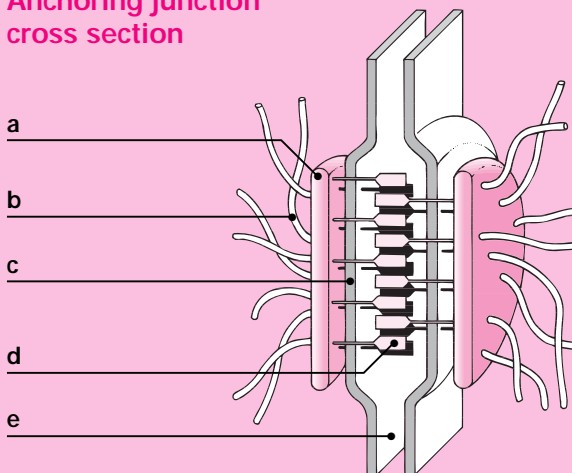
Transport across membranes



Anchoring junctions

At an anchoring junction, on the insides of the neighboring cells, are rivet-like thickenings called plaques (a). Each plaque is made of protein. Keratin filaments (b) attach the plaques to the insides of the cell membranes (c). These filaments are part of the cell's cytoskeleton. Thinner proteins called transmembrane linker proteins (d) cross the space between the cells (e).

Anchoring junction cross section



Locations

There are two types of anchoring junction: desmosomes and hemidesmosomes. Desmosomes have larger transmembrane linker proteins than the other junctions. These linkers are called cadherins. Anchoring junctions are used to connect epithelia (lining cells) to a basement membrane. Together with gap junctions, desmosomes form intercalated discs (complex junctions) between cardiac muscle cells.

Functions

- Anchoring junctions bind cells together in sheets or masses that form strong structural units.
- The networks that these junctions form in tissues distribute tension, helping to prevent tearing. This is why anchoring junctions are prevalent in areas that are subjected to the mechanical stress of pulling and stretching.
- Within intercalated disks, for example, desmosomes prevent adjacent cells from separating during heart contractions.

Gap junctions

There are three main types of communicating junctions:

- gap junctions;
- synapses (nerve cell junctions); and
- plasmodesmata.

Transmembrane proteins are arranged into groups (connexons) with hollow channels at the center. A gap junction comprises several hundred connexons.

Gap junctions form channels through which ions and small molecules can pass from one cell to the next, resulting in the chemical and electrical coupling of cells.

In unborn babies, gap junctions enable nutrients to be distributed around the body before the circulatory system is developed.

Cilia

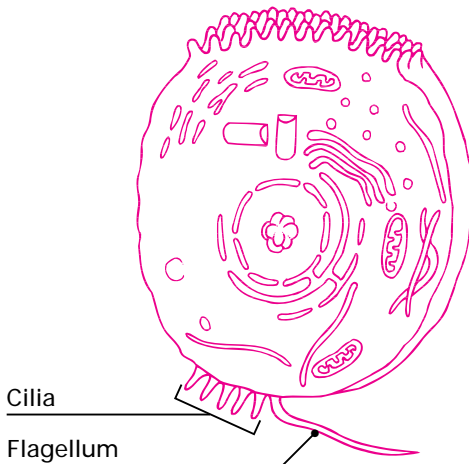
(Singular: cilium) These appear in large numbers as tiny, hairlike fronds on the cell's exposed surface. Each cilium is made of bundles of microtubules (tiny tubes) covered by the cell membrane.

Function

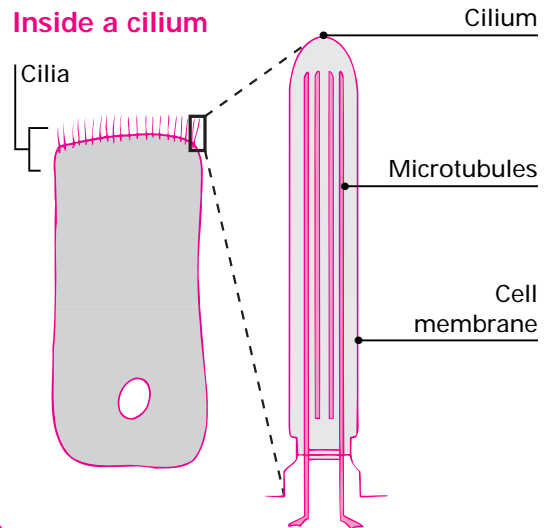
Cilia's wave-like movement enables them to carry matter in one direction

over the cell's surface. Ciliated cells that line the airways move mucus (thick, slimy fluid) toward the pharynx (throat) to be removed by swallowing. This gets rid of the airborne dust and bacteria trapped in the mucus and helps clean and protect the lining.

Cilia and flagellum



Inside a cilium

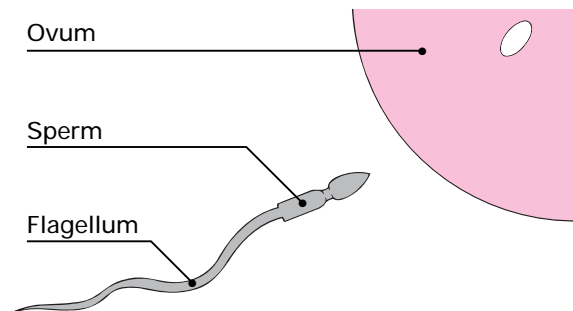


Flagella

(Singular: flagellum) These are structurally the same as cilia but are longer and occur singly in humans.

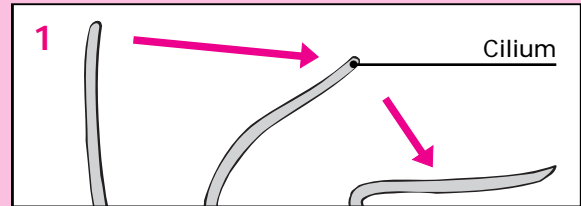
Function

Flagella are used to move the cell itself. The only example of human cells with flagella are sperm (male sex cells). The sperm uses its flagellum to propel itself toward the female egg cell (ovum).

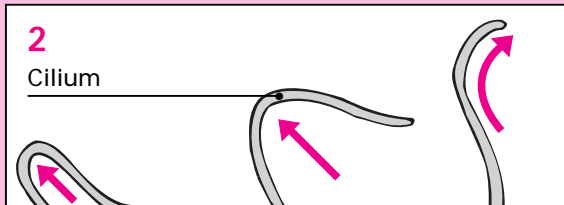


Ciliary motion

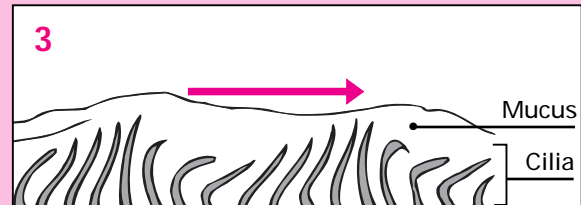
There are two phases to each ciliary motion. The power stroke (1), and the recovery stroke (2). The motions of cilia are coordinated to make a wave travel across the cell surface (3). This propels substances across the cell.



Power stroke



Recovery stroke

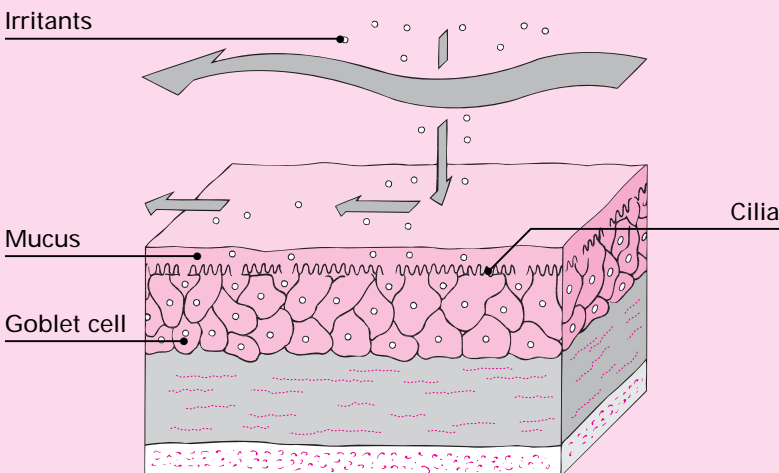


Direction of propulsion

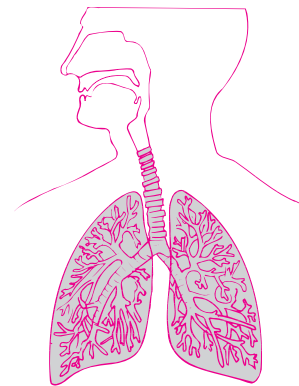
Cilia in body airways

The nose, mouth, windpipe, and lungs are lined with ciliated goblet cells. These cells secrete mucus on the surface of the airways. Irritants are trapped in the mucus and the cilia on the goblet cells propel the mucus toward the throat where it is swallowed.

The respiratory mucosa



Windpipe and lungs

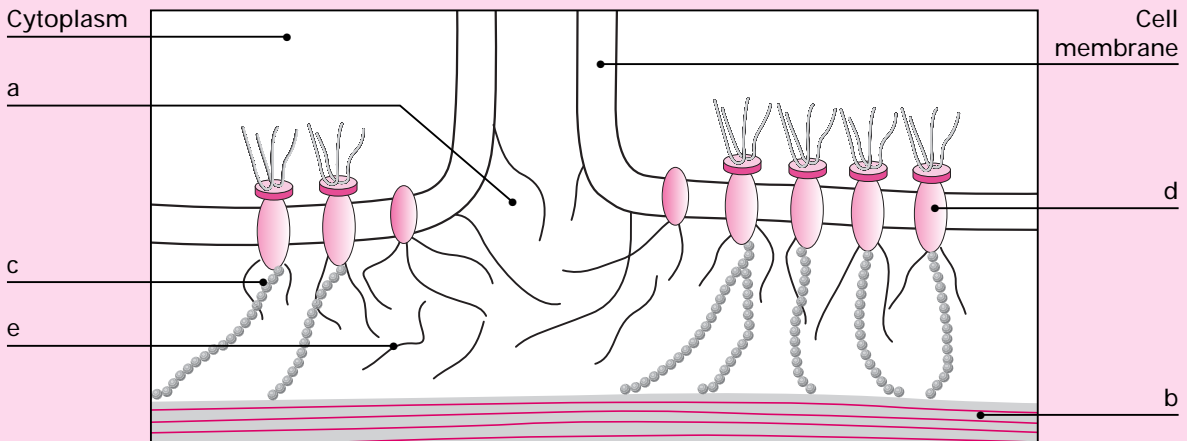


The extracellular matrix

Multicellular animals, such as humans, are made up of tissues—groups of cells organized and coordinated to perform particular functions. To function properly, these cells require a particular environment, which is provided by the extracellular matrix (ECM) (**a**).

The components of the ECM are secreted by the cells themselves. The main constituents belong to three

classes of proteins. Collagens (**b**) are insoluble fibers that form various chains, bundles, or other structures. Multiadhesive matrix proteins (**c**) bind to cell-adhesion molecules (**d**) in cell membranes and to other ECM components. Proteoglycans (proteins with attached polysaccharide chains) (**e**) contain water and form the bulk of the matrix or attach to cell surfaces.



Functions of the ECM

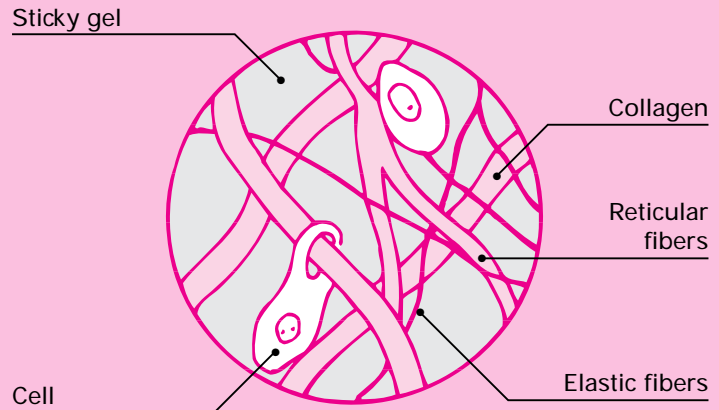
- Helps bind cells together.
- Gives strength and protection to tissues.
- Provides a framework in which tissues can develop and cells can move.
- Allows communication with and between cells, for example via hormones, neurotransmitters, and other signal molecules contained in the ECM.

Connective tissue

- This consists of cells within a relatively large amount of extracellular matrix.
- Examples include cartilage, bone, tendon, and adipose (fat tissue).
- The components, and the properties, of connective tissues vary according to their position and function. For example, bone must be strong and fairly rigid, whereas adipose must be supple and provide heat insulation.

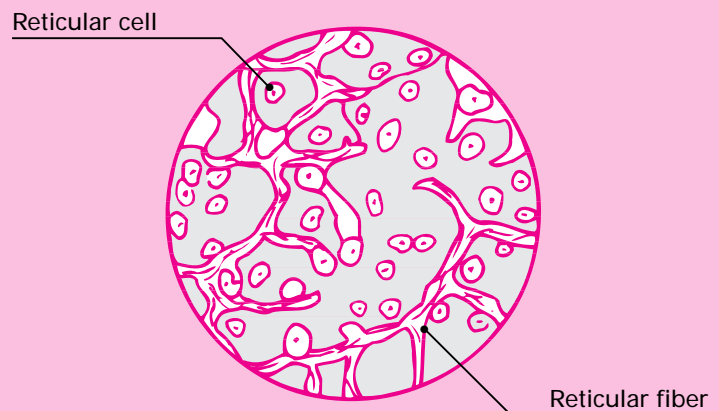
Areolar connective tissue

Areolar tissue is located beneath the skin, between muscles, where it lines internal passageways; and around certain blood vessels and nerves, especially those inside organs. Its main role is to bind internal organs together so they do not move around too much and it adds strength and elasticity to certain parts of the body. Areolar tissue is made up of a few cells held in a mesh of stringy collagen fibers, elastic fibers, and netlike reticular fibers. All this is embedded in a matrix of soft sticky gel.



Reticular connective tissue

This type of connective tissue is found around lymph nodes (swellings in lymph ducts), bone marrow at the center of bones; and around the spleen, an organ associated with immunity and the lymphatic system. Its main function is one of support. It provides a framework upon which these organs rest. The tissue is made up of reticular cells that are held in a web of delicate reticular fibers. The reticular cells are a type of fibroblast. Fibroblasts are the cells that secrete the ECM constituents of all types of connective tissues.



Humans are eukaryotic, as are all other animals, plants, fungi, and many single-celled organisms, such as amoebas. Eukaryotes all have the same basic cell plan, containing a range of organelles. Bacterial cells are prokaryotic. They are smaller than eukaryotic ones and do not have any obvious internal structures. It is widely accepted that eukaryotic cells evolved from cooperatives of several prokaryotes. These prokaryotes now form a cell's organelles.

Cell type facts

- Human cells, like those of other animals, are surrounded by a cell membrane.
- Plant cells, unlike animal cells, also have a cell wall.
- Cell membranes are held together by cholesterol.

Cell metabolism step-by-step

1 DNA (deoxyribonucleic acid) in the nucleus (the cell's control center) is copied into mRNA (messenger ribonucleic acid).

2 mRNA passes through pores in the nuclear envelope and enters the cytoplasm (semifluid mixture) outside the nucleus.

3 The nucleolus (a sphere of RNA and proteins) in the nucleus manufactures rRNA (ribosomal RNA).

4 rRNA leaves the nucleus and enters the cytoplasm where it is made into ribosomes (tiny, granular particles). Some ribosomes become attached to the rough endoplasmic reticulum (rough ER). Others remain loose in the cytoplasm. Ribosomes are involved in manufacturing the proteins coded by the cell's DNA.

5 In the cytoplasm or inside the lumen of the rough ER, mRNA attaches itself to ribosomes.

6 tRNAs (transfer RNAs) read the protein-synthesis information carried by the arrangement of a chain of nucleotide units as part of the mRNA molecules.

7 The specific amino acids (protein building blocks) that the tRNAs carry are bonded into polypeptide chains. A typical protein is made up of several polypeptides.

8 The polypeptide chains produced by ribosomes are folded up into their correct shapes inside the rough ER to produce proteins. The shape of the protein defines its chemical properties and its metabolic function.

9 Proteins are shipped in vesicles (tiny membranous sacs) from the rough ER to the Golgi apparatus.

10 The vesicles fuse with the wall of the Golgi apparatus.

11 The Golgi apparatus sorts, perhaps alters, and finally packages the proteins in Golgi vesicles.

12 Some proteins are shipped to the cell membrane in this way and then incorporated into the membrane.

13 Other proteins (such as hormones and digestive enzymes) are secreted through the cell membrane by exocytosis to perform tasks elsewhere.

14 Some enzymes are delivered for inclusion in lysosomes.

15 Lysosomes engulf and use enzymes to digest harmful substances.

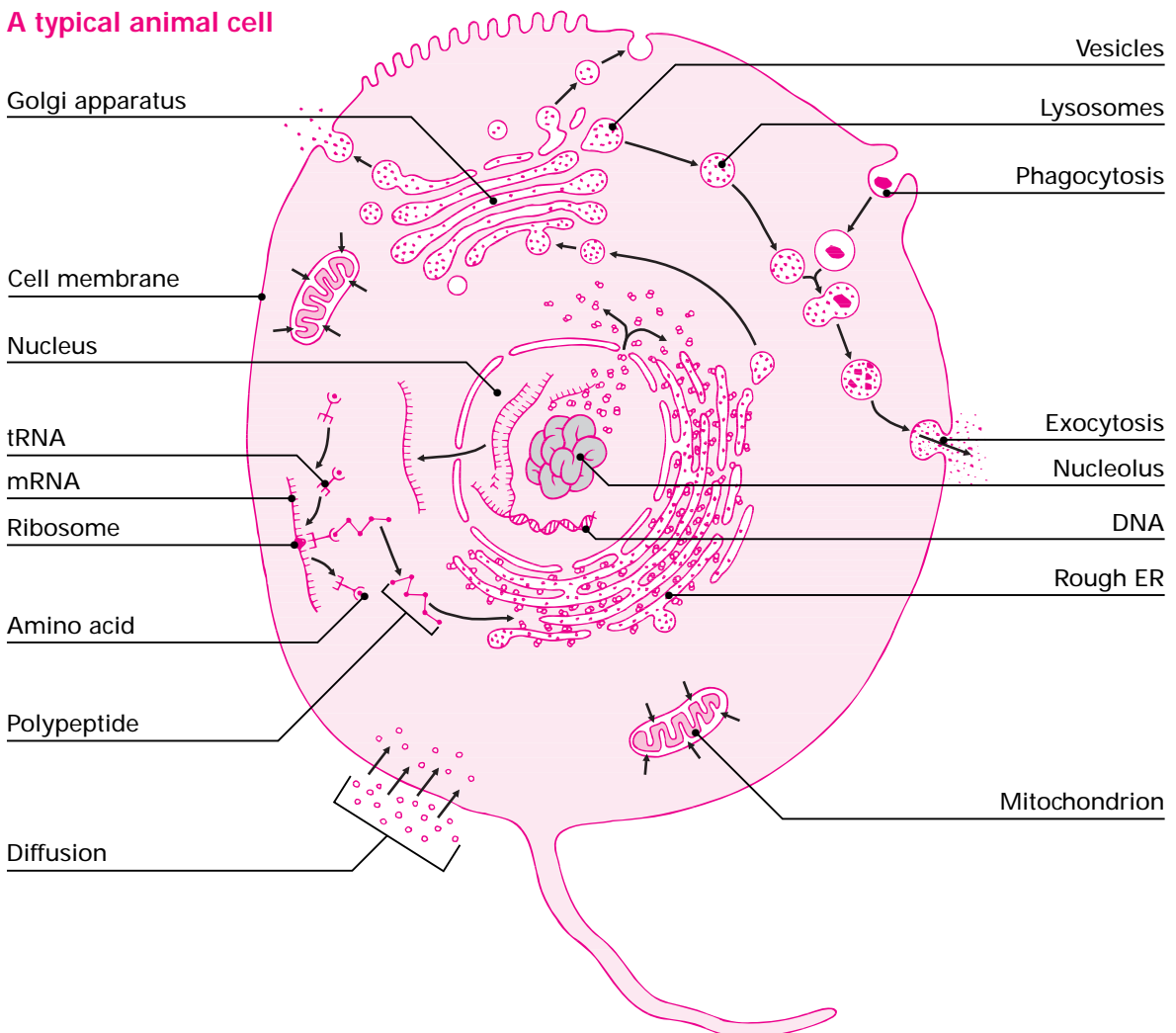
16 The digested particles are then expelled from the cell by exocytosis.

17 The cell is constantly taking in substances. Phagocytosis (cell "eating") is one example of an active (energy-using) transport system.

18 Simple diffusion of small molecules across the cell membrane is an example of passive transport (without energy).

19 Mitochondria take in fuels, such as glucose sugar, to produce the energy storage molecule ATP (adenosine triphosphate), which the cell needs to carry out its activities.

A typical animal cell



Cell membrane structure

The cell (plasma) membrane is made up of a variety of molecules, including phospholipids, proteins, and cholesterol. Most of these are able to move about within the membrane.

Phospholipids

A double layer, about 5 nm thick, of phospholipid molecules comprises much of the cell membrane. Phospholipids are modified lipids (fats) that contain phosphorus. They are divided into two main parts: a head and a tail. As the polar heads are water-seeking (hydrophilic) and the nonpolar tails are water-repelling (hydrophobic), the phospholipid molecules orient themselves with their heads pointing outward and their tails in contact.

Proteins

Intrinsic proteins pass through the membrane and protrude on either side. Extrinsic proteins are attached to the surface or one half of the lipid bilayer. Structural (or fibrous) proteins are strandlike and connect to the cell's cytoskeleton. They may also connect the cell to adjacent cells or to the extracellular matrix.

Functional (or globular) proteins are generally spherical and include sensors and receptors; for example, glycoproteins, enzymes, and transport proteins (channel proteins and carrier proteins).

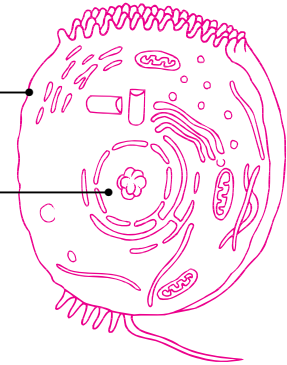
Cholesterol

Cholesterol is a steroid that gives the bilipid layer extra strength.

Cell membrane

Cell membrane

Nucleus



Cell membrane

Phospholipids

Phospholipid

Cholesterol

Extrinsic proteins

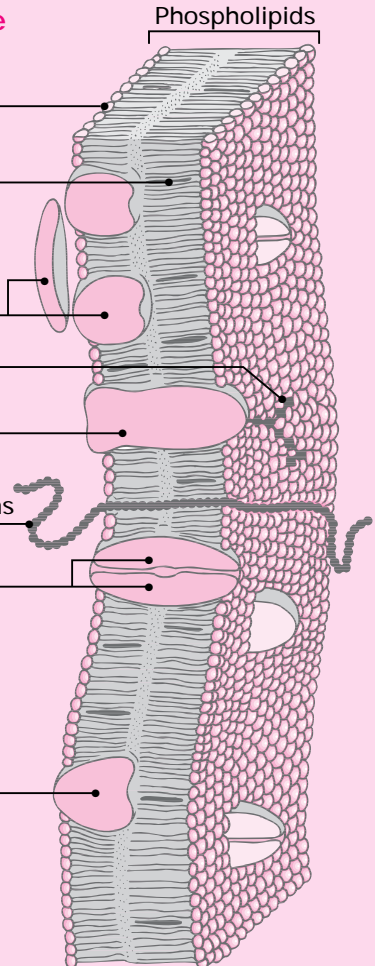
Glycoproteins

Intrinsic protein

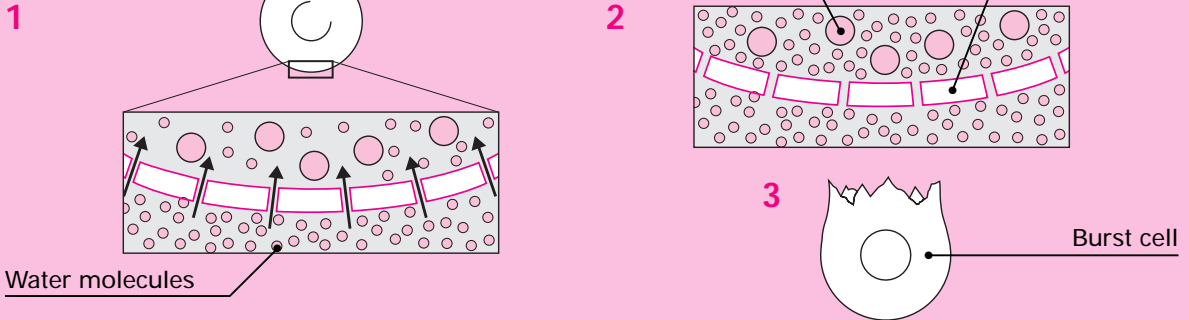
Structural proteins

Channel proteins

Carrier proteins



Osmosis



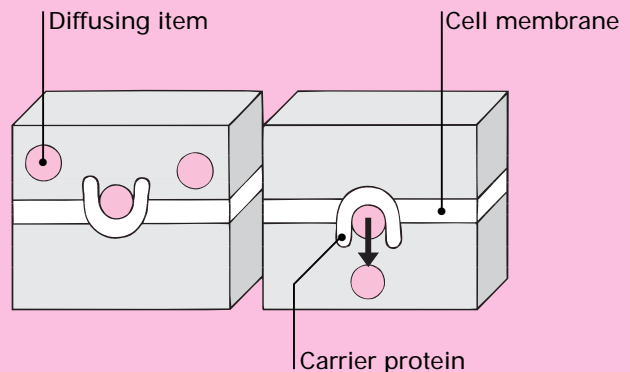
1 The contents of a cell form a highly concentrated solution. Large molecules, such as proteins, are blocked from diffusing in and out of the cell by the membrane. However, smaller molecules, such as water, can move freely. When a cell is placed in weak solution, its concentrated contents cannot disperse. Instead water diffuses into the cell to make the contents less concentrated, and in the process make the external solution stronger. This type of diffusion is called osmosis.

2 This process continues until the cell contents have the same concentration as the solution outside the cell.

3 Since water has flowed into the cell, it will swell up. If the cell is in a very weak solution or pure water, so much water will diffuse into it that the cell will eventually burst. The opposite happens if a cell is placed in a stronger solution. The cell loses water by osmosis, and its contents become more concentrated. The cell shrinks and becomes crinkled, a process known as crenation.

Facilitated diffusion

Most substances cannot dissolve in both lipids and water, so they cannot cross a cell membrane. Some, such as water, diffuse through channels made of protein. Large items bind to a carrier protein straddling the membrane. This chemical reaction makes the protein change shape. As it does so it moves the item to the other side of the membrane.



Active transport

In active transport, the cell uses energy supplied by ATP (adenosine triphosphate) to transport substances across its membrane.

Active transport is used if a particle:

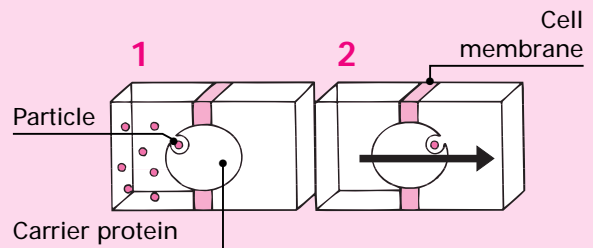
- is too large to pass through the membrane pores;

- cannot dissolve through the lipid bilayer (fatty double layer) of the cell membrane; or
- needs to be moved against the direction of diffusion, from an area of lower concentration to an area of higher concentration.

Solute pumping

1 A carrier protein, called a solute pump, powered by ATP, combines with the particle.

2 It then transports the particle across the cell membrane. Amino acids and most types of ion are transported across the membrane in this way.



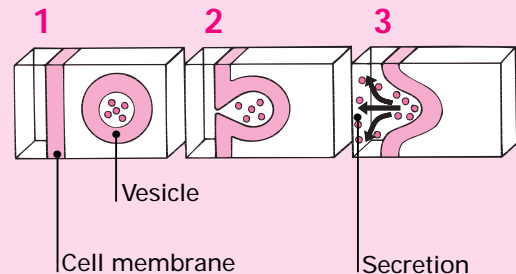
Exocytosis

This is how substances, such as hormones, mucus, and waste products are secreted from a cell.

1 A membrane-covered vesicle (sac) carries the substance.

2 The sac fuses with the cell membrane.

3 The particle is ejected from the cell.



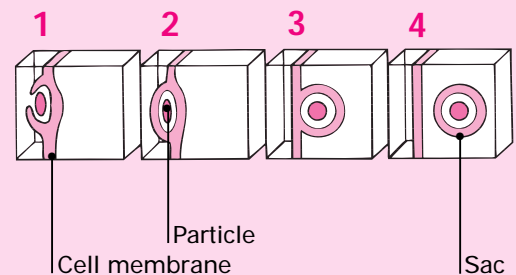
Phagocytosis

Engulfing other cells or particles by a cell. This is generally used by white blood cells to destroy foreign bodies such as bacteria and viruses.

1 Part of the cell membrane protrudes around the particle.

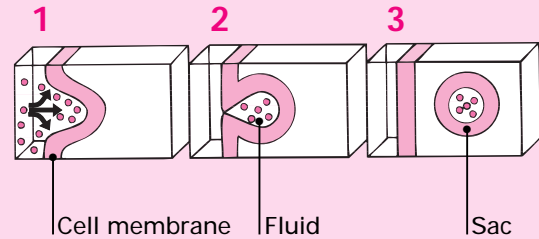
2 The membrane encloses the particle.

3–4 The sac formed separates from the inner surface of the cell membrane. Enzyme-containing sacs (lysosomes) then destroy the contents.



Pinocytosis

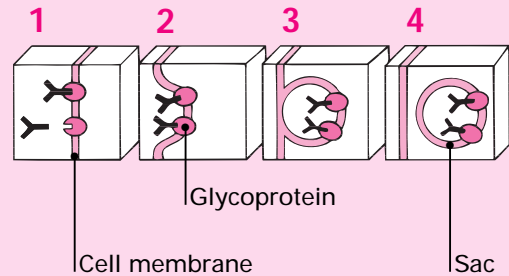
This process follows a similar sequence to phagocytosis, but is used to transport fluids into the cell across the cell membrane. The fluids include water and the various solutes dissolved in it and liquids containing proteins and fats.



Receptor-mediated endocytosis

1 Molecules, generally glycoproteins, in the cell membrane act as receptor sites for certain hormones, minerals, and fats, such as cholesterol.

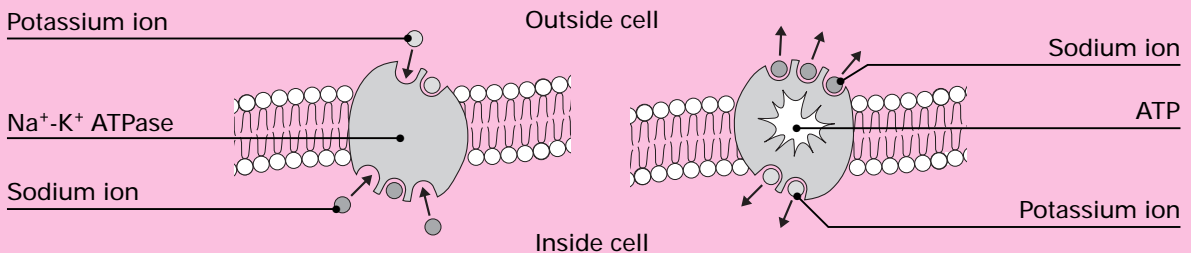
2–4 Once a substance is attached to the receptor, the membrane folds inward and the small sac created separates from the inside of the cell membrane.



The sodium-potassium pump

An enzyme called $\text{Na}^+\text{-K}^+$ ATPase acts as an ion pump. It is powered by ATP. In one go, this pump can transport three sodium ions out of the cell and two potassium ions back into the cell. This ensures that there are more potassium ions inside the cell than outside and that the reverse is true for sodium. This is important for cells, such as neurons, that need to carry electric potentials.

- All ions are pumped in the opposite direction to diffusion.
- The pump has to function almost continuously to maintain the correct levels of these ions.
- Nearly a third of the energy used by a typical cell is used to keep the pumps operating. In the case of electrically active cells, it uses up to two-thirds of the total energy.



Membrane potentials

All cells contain large negatively-charged molecules, especially proteins, that are effectively trapped inside the cytoplasm by the cell membrane. These play a significant part in creating the resting, or normal, electrical potential across a cell's membrane. Other mechanisms add to and maintain the

membrane potential. These depend on the properties of the cell membrane itself, such as its selective permeability to ions and its ability to actively transport ions from one side to the other with pumps. Gated ion channels, for example, allow specific ions through the membrane only when opened.

Resting potential

In a "resting" human cell the membrane potential is due mainly to open potassium ion (K^+) channels in the cell membrane that permit ions to diffuse out of the cell to where they are less concentrated. These are known as the resting K^+ channels. This results in an overall buildup of positive ions outside of the cell, leaving the interior electrically negative relative to the exterior.

Diffusion of sodium ions (Na^+) into the cell, which would counteract this charge difference, is prevented because most of the sodium channels remain closed. The diffusion of potassium ions depends on the cell maintaining a high internal concentration of potassium ions. The cell achieves this by using energy to actively pump potassium ions into the cell, and sodium ions out of the cell by means of the sodium-potassium pump Na^+-K^+ ATPase.

Ion distribution

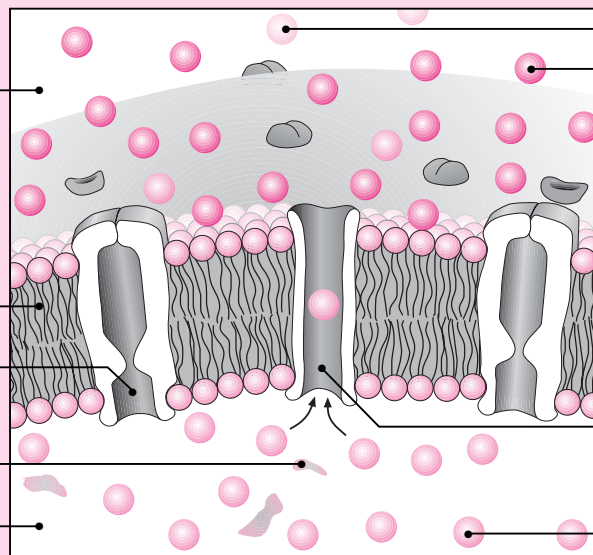
Exterior

Cell membrane

Closed Na^+ channel

Negatively charged protein

Interior



Cl^- ion

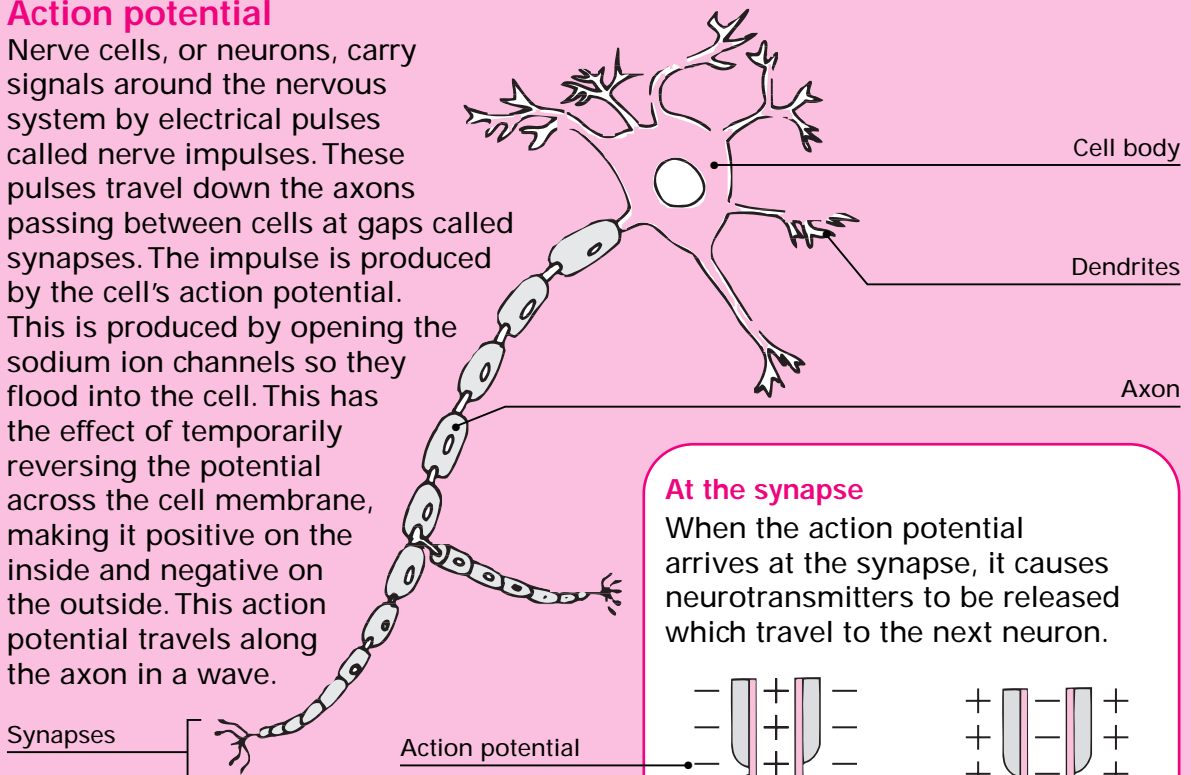
Na^+ ion

Open K^+ channel

K^+ ion

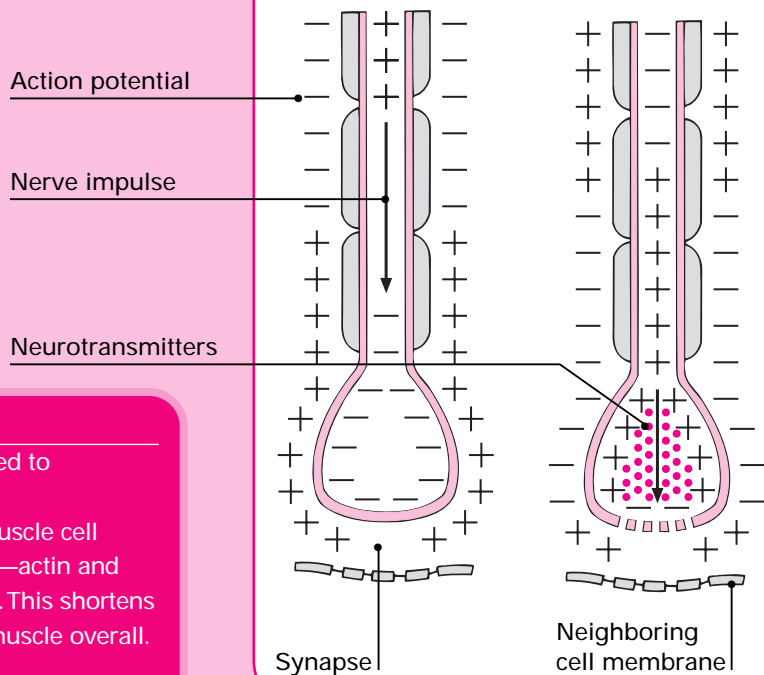
Action potential

Nerve cells, or neurons, carry signals around the nervous system by electrical pulses called nerve impulses. These pulses travel down the axons passing between cells at gaps called synapses. The impulse is produced by the cell's action potential. This is produced by opening the sodium ion channels so they flood into the cell. This has the effect of temporarily reversing the potential across the cell membrane, making it positive on the inside and negative on the outside. This action potential travels along the axon in a wave.



At the synapse

When the action potential arrives at the synapse, it causes neurotransmitters to be released which travel to the next neuron.



Muscle contraction facts

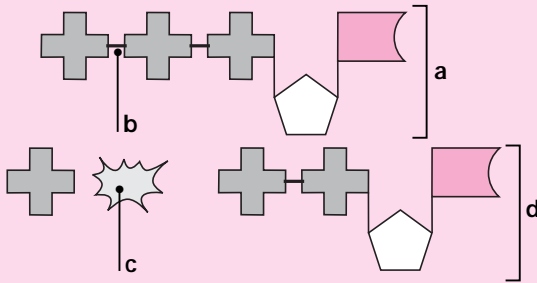
- A similar action potential is used to stimulate muscle contractions.
- The change of potential in a muscle cell causes two proteins in the cell—actin and myosin—to overlap each other. This shortens the length of the cell and the muscle overall.

Adenosine triphosphate

Without ATP, all metabolic processes would soon stop.

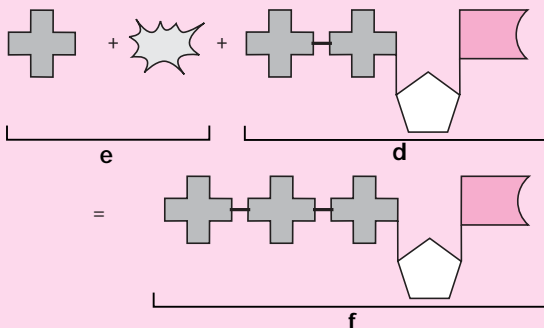
Releasing energy

ATP (a) functions by releasing the energy it stores in its phosphate bonds. Breaking one bond (b) releases just enough energy (c) to fuel most biochemical tasks. The loss of a phosphate group converts ATP into ADP (d) (adenosine diphosphate).



Production

A high-energy phosphate group (e) is transferred to ADP (d) to turn it into ATP (f). This is an example of phosphorylation (the addition of phosphate). It occurs during cellular respiration, which is the breakdown of the sugar glucose to release enough energy to form ATP.

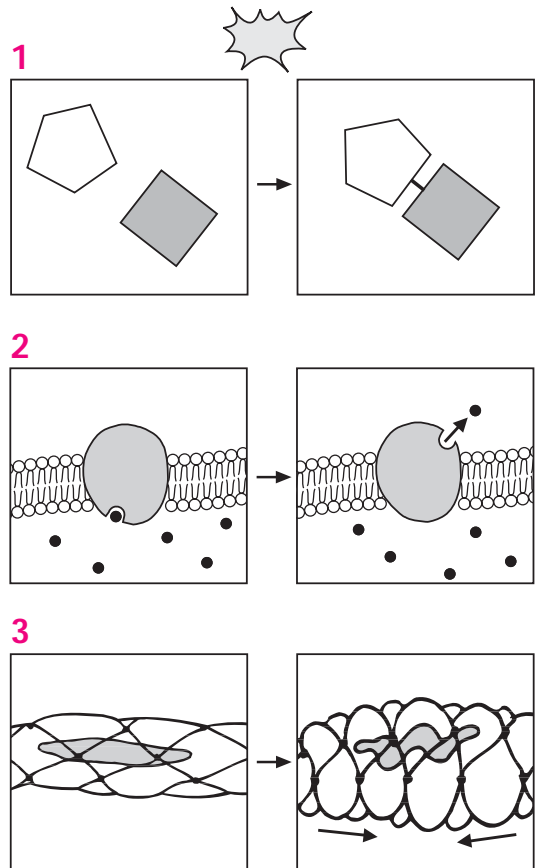


Cellular fuel

The energy stored in ATP is used for both catabolic (destructive) and anabolic (constructive) processes.

ATP powers processes such as:

- 1 chemical reactions that require energy input to proceed;
- 2 active (energy-using) transport across the cell (plasma) membrane; and
- 3 mechanical tasks such as the contraction of muscle cells.

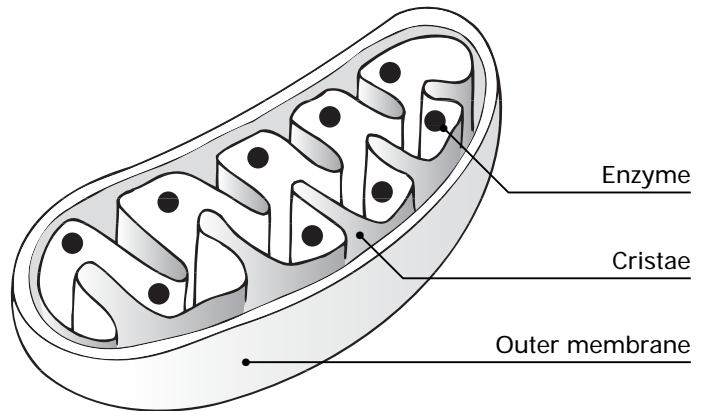


Cellular respiration

Cellular respiration is the breakdown of the sugar glucose. This releases enough energy to phosphorylate many ADP molecules to produce the chemical energy storage molecule ATP. This can be summarized as a simple equation (see below). In reality, cellular respiration occurs in a series of complex stages, called the Krebs' cycle. At points in this cycle, electrons are released, which are used in phosphorylation.

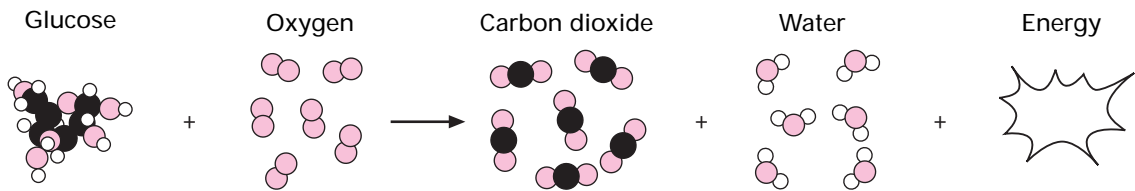
Mitochondria key

Mitochondria are the sites of cell respiration. The enzymes involved are embedded in the folded cristae.

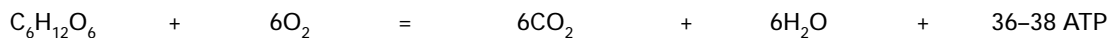


Oxidizing glucose

Molecules



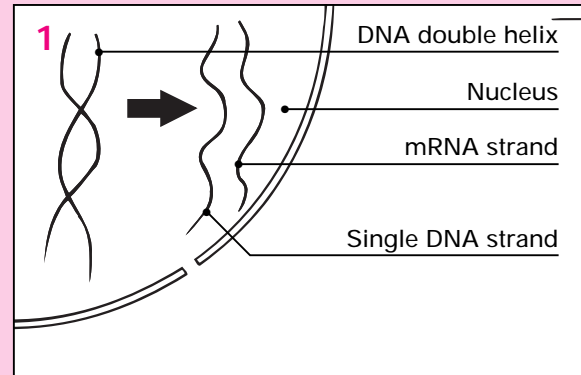
Chemical formulae



● Carbon atoms ○ Hydrogen atoms ● Oxygen atoms

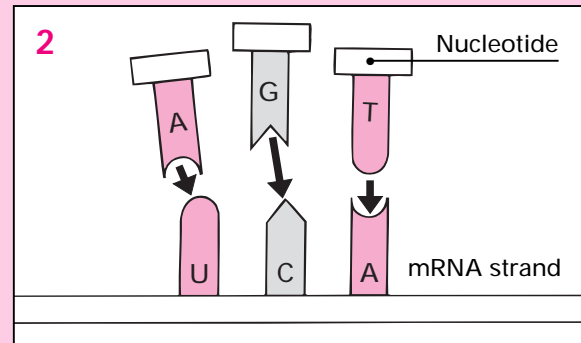
Transcription phase

1 Proteins are chains of amino acids. There are about 20 amino acids used by human cells. The order of each chain defines the shape and function of the protein. A cell's DNA (deoxyribonucleic acid) contains the code for all the proteins the body needs. Inside the nucleus, the DNA separates into two single strands. One of these strands serves as a template to produce a strand of mRNA (messenger ribonucleic acid).

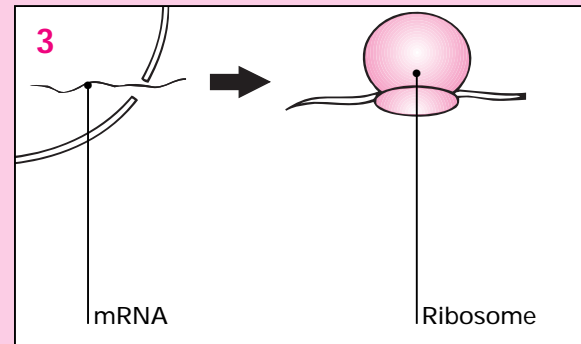


2 DNA and other nucleic acids are composed of chains of units called nucleotides. The four nucleotides are the "letters" of the DNA code. The mRNA nucleotides attach to exposed complementary DNA nucleotides, making a strand of mRNA.

A = adenine C = cytosine
G = guanine T = thymine
U = uracil



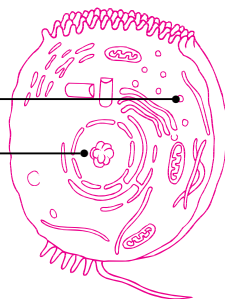
3 The mRNA leaves the nucleus and attaches to a ribosome on the rough endoplasmic reticulum (rough ER).

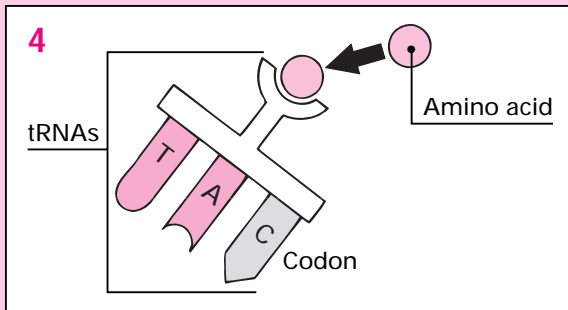


Eukaryotic cell

Ribosome

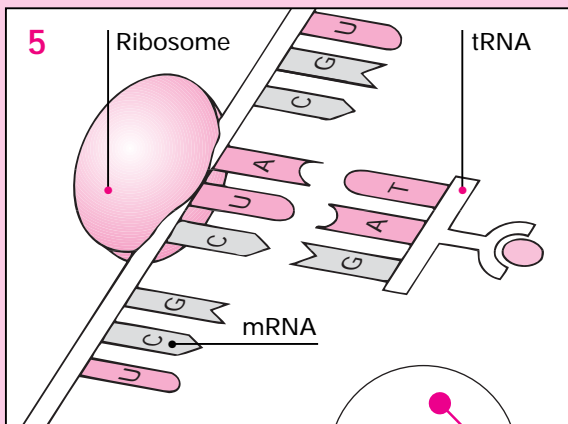
Nucleus



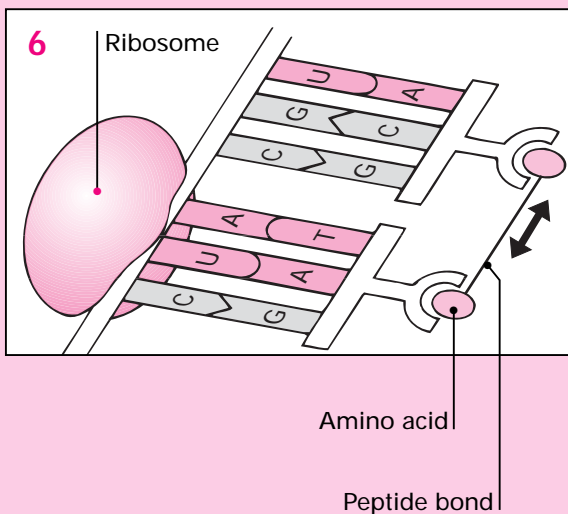


Translation phase

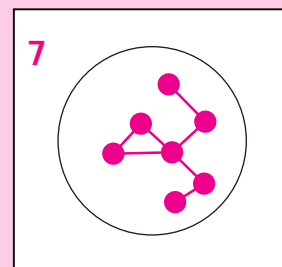
4 In the cell's cytoplasm, a tRNA (transfer RNA) molecule with a specific three-letter code, or codon, attaches to a specific amino acid.



5 The mRNA codon inside the ribosome attracts a tRNA with the appropriate complementary bases.



6 The tRNA temporarily bonds with the mRNA. This brings the amino acid that it is carrying into contact with an amino acid on a neighboring tRNA. The two amino acids become linked together by a peptide bond.



7 When it is complete, the chain of bonded amino acids forms a highly folded protein.

Cell signaling

Cells need to communicate with each other for various reasons.

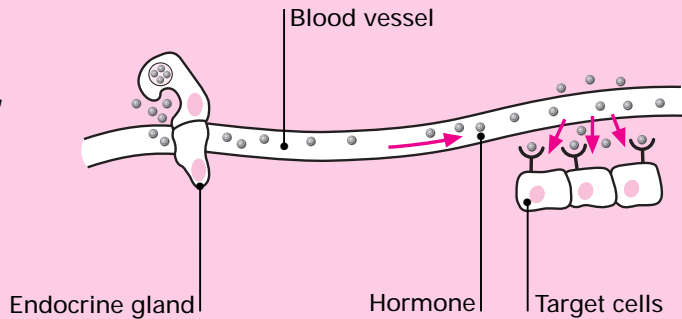
- The development and coordination of the many types of tissues, with their numerous constituent cells, depends on cell-to-cell communication.
- Adjoining tissue cells often establish permanent connections via specialized junctions in their cell membranes.
- Cells also release signaling molecules

into the extracellular environment to convey messages to neighboring cells.

- These signaling molecules bind tightly and specifically to receptor proteins in the target cell.
- The binding of the extracellular signal is usually the first step in a sequence of reactions leading to a particular response in the target cell—a process known as signal transduction.

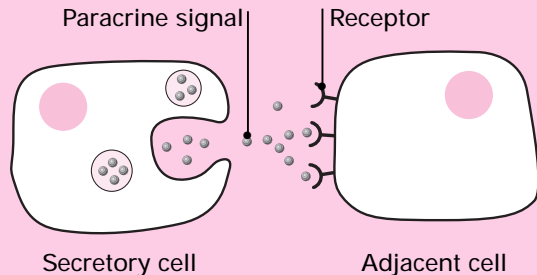
Endocrine

- Chemicals called hormones are released from endocrine glands, such as the thyroid or pituitary, and travel some distance within the body, usually via the bloodstream, to influence target cells. Most hormones perform several different roles.



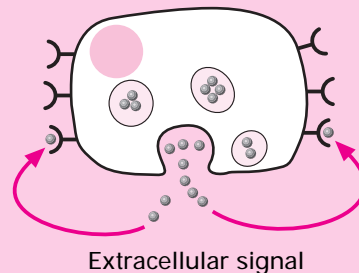
Paracrine

- Chemical signals are released from cells to affect target cells only in the vicinity. ("Para" means "beside.")
- For example, nerve impulses are transmitted between adjacent nerve cells by paracrine signals called neurotransmitters.



Autocrine

- Cells are affected by chemical signals released by themselves.
- For example, cells release growth factors that influence their own development.



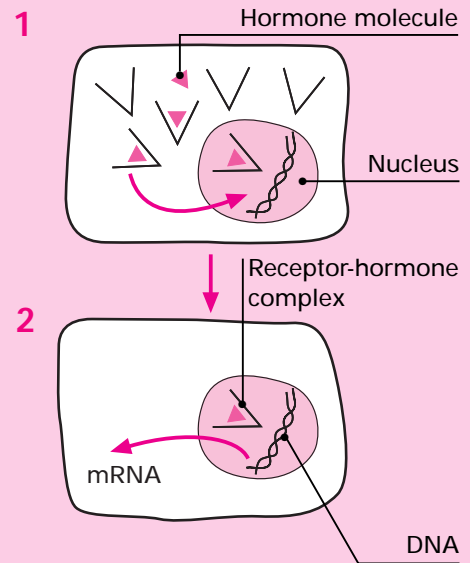
Lipid-soluble hormones

These substances can diffuse across cell membranes. They include the steroid hormones (for example, testosterone, progesterone, and cortisol) and the thyroid hormones (thyroxine and triiodothyronine).

Lipid-soluble hormones are carried in the blood by carrier proteins. The hormone molecules are released from their carrier, leave the blood vessel, and enter adjacent tissue cells.

1 The molecules cross the plasma membrane of a cell and bind to receptors in the cytosol.

2 The bound receptor-hormone complexes enter the cell nucleus and alter the transcription of certain genes in the nuclear DNA. This affects the production of particular proteins, and therefore the activity of the cell.

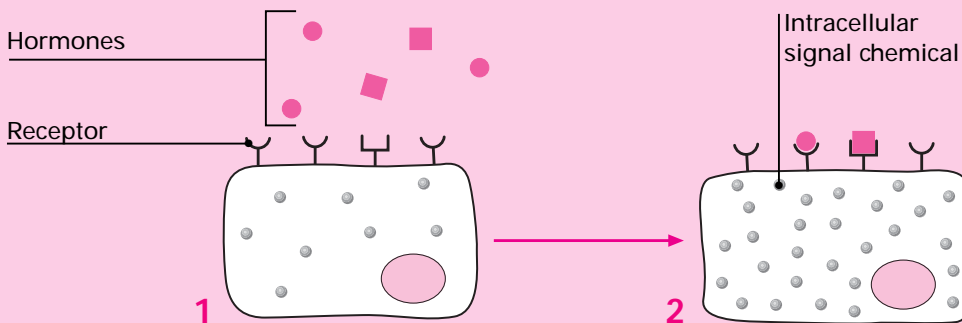


Water-soluble hormones

- These cannot diffuse across cell membranes and bond to receptors on the cell's surface instead.
- They include peptide hormones (for example, insulin and growth factors) and small non-peptide molecules (for example, epinephrine, and histamine).
- Although prostaglandins are lipid-soluble hormones, they too bind to cell-surface receptors.

1 Signal molecules bind to receptors on the cell surface, causing a change in the conformation (three-dimensional shape) of the receptor protein.

2 This can lead to various changes within the cell. For example, the binding may trigger an increase in the concentration of a second messenger—an intracellular signal chemical that affects the cell's activities.



Cell type**Adipocytes****Description**

Each cell contains a large droplet of fat

Function

- Store food as fat
- Cushion and insulate body parts

Chondrocytes

Large and circular cells found in cartilage

- Maintain cartilage
- Immature chondrocytes (known as chondroblasts) form cartilage

Epithelial cells

There are three main types: flat, cuboidal, and columnar

- Line the body
- Act as a protective barrier
- Absorb or secrete substances

Erythrocytes

Toroidal (donut-shaped) red blood cells with no functioning nuclei

- Transport oxygen and carbon dioxide around the bloodstream

Fibrocytes

Long, flat, and branching cells found in connective tissues

- Maintain connective fibers, such as tendons and ligaments
- Immature fibrocytes, called fibroblasts, form connective tissues

Leukocytes

White blood cells of various shapes that are all larger than erythrocytes

- Fight infection by destroying invading germs

Neurons

Cell body has extensions coated in fat

- Transmit nerve impulses

Osteocytes

Circular cells found in bones

- Maintain bones
- Immature osteocytes, called osteoblasts, form bones

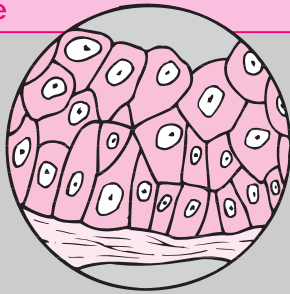
Tissue groups

Cells that work together to perform a certain function or set of functions are grouped into tissues. There are four main groups of tissue: Epithelial tissues line the body's internal and

external surfaces; connective tissues, such as bone, give the body its structure; muscular tissues produce movement; and nervous tissue coordinates the body.

Tissue type

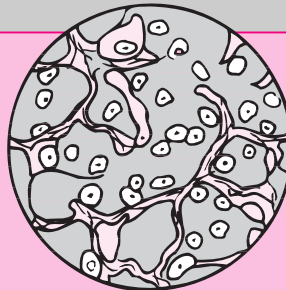
Epithelial



Location


- lungs
- lining of blood and lymph vessels
- lining of parts of the digestive and respiratory tracts etc.
- skin

Connective



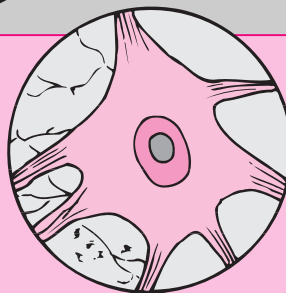
- under skin
- at joints
- between other tissues and organs
- skeleton
- bloodstream

Muscular



- muscular system
- heart
- walls of blood and lymph vessels
- parts of digestive tract etc.

Nervous



- brain
- spinal cord
- nerves

Most cells have life cycles. They are formed, grow, differentiate into a specific cell type, reach maturity, and—when necessary—divide to reproduce. Those that do not reproduce reach maturity and then remain functional for the remainder of their lifespan; in the case of nerve cells this can be for as long as 100 years. The cell cycle varies considerably from one cell type to another. The life cycle of a cell has two main periods: interphase and cell division.

Cell division facts

Cells need to divide to:

- replace dead, lost, or damaged cells;
- repair damaged tissue;
- enable the body to grow;
- make sex cells for reproduction.

Basic cell structure

Cell membrane

This envelops the cell and controls which materials enter and exit

Golgi apparatus

This structure is involved in secreting substances from the cell

Nuclear membrane

This is a double membrane that surrounds the nucleus

Nucleus

The nucleus is where most of the cell's DNA is stored

Centrioles

The centrioles are part of the cytoskeleton and are involved in cell division

Cytoplasm

A gel-like fluid that contains the organelles

Chromatin

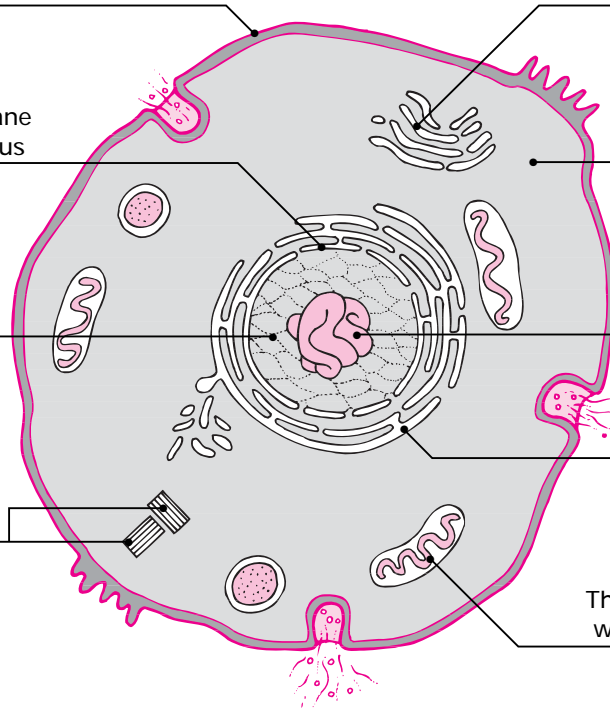
Substance that contains the cell's DNA strands

Endoplasmic reticulum

Network of fluid-filled tubes

Mitochondrion

The power plant of the cell where energy is produced



Most human cells will contain these structures. An exception is red blood cells, which do not have nuclei since

they do not need to reproduce. During cell division the DNA is doubled so each new cell will contain a full set of genes.

Interphase and cell division

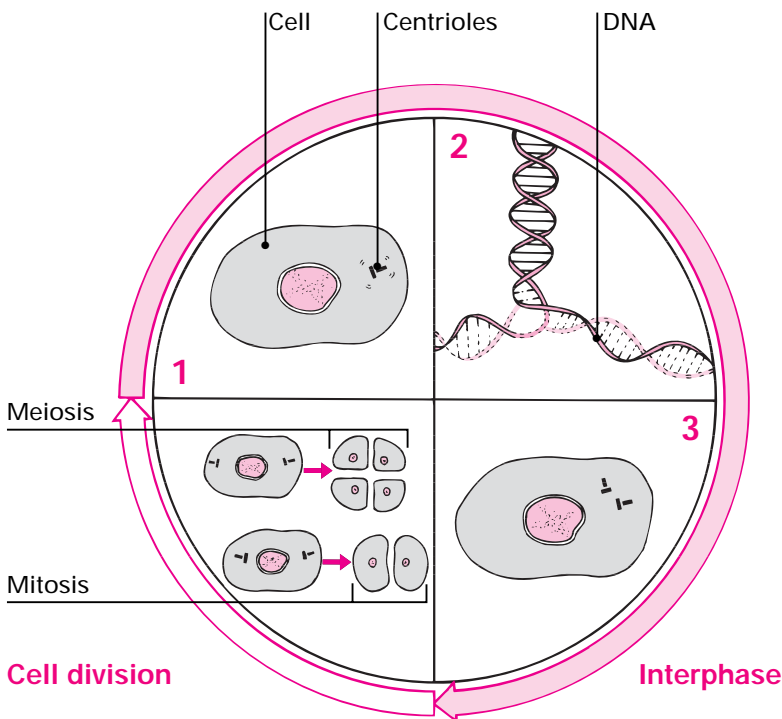
The time when a cell is not dividing is known as the interphase. It has three subphases: growth₁, synthetic, and growth₂. During these phases, important changes occur in preparation for cell division.

1 Growth₁ (or G₁) This is a period of rapid growth for the cell. It is also the time when the small rod-shaped structures called centrioles begin to make copies of themselves. Cells spend a varying amount of time at this stage depending on their function, age, and the surrounding temperature. For cells

that divide rapidly, it may only last a few minutes. For others, it can last for months or even years.

2 Synthetic (or S) During this phase, strands of deoxyribonucleic acid (DNA), which make up the bar-shaped chromosomes, duplicate themselves. This ensures that future copies of the cell will receive the same genes (inheritable coded units of DNA).

3 Growth₂ (or G₂) The final preparations for cell division are made. The centrioles finish replicating, and each cell now has two pairs.



Cell division

Cell division (mitotic or M phase) is the process by which cells reproduce. There are two main ways in which cells divide: by mitosis or meiosis.

Mitosis is the process in which the parent cell divides to make two daughter cells identical to itself.

Meiosis is the process by which cells used for sexual reproduction—sperm and ova (eggs)—are produced. Four cells are produced in meiosis, each with half a set of DNA.

Cell cycle control

Precise control of the events of the cell cycle is essential for normal growth and development of the body. Breakdown in the control mechanisms can lead to abnormal mitosis and cell division, or uncontrolled proliferation of cells, which produces cancerous tumors.

Cdks are crucial controllers

DNA replication, mitosis, and other processes of the cell cycle are performed in a particular sequence by numerous enzymes and other proteins. Control is exerted by a small group of enzymes called cyclin-dependent kinases (Cdks).

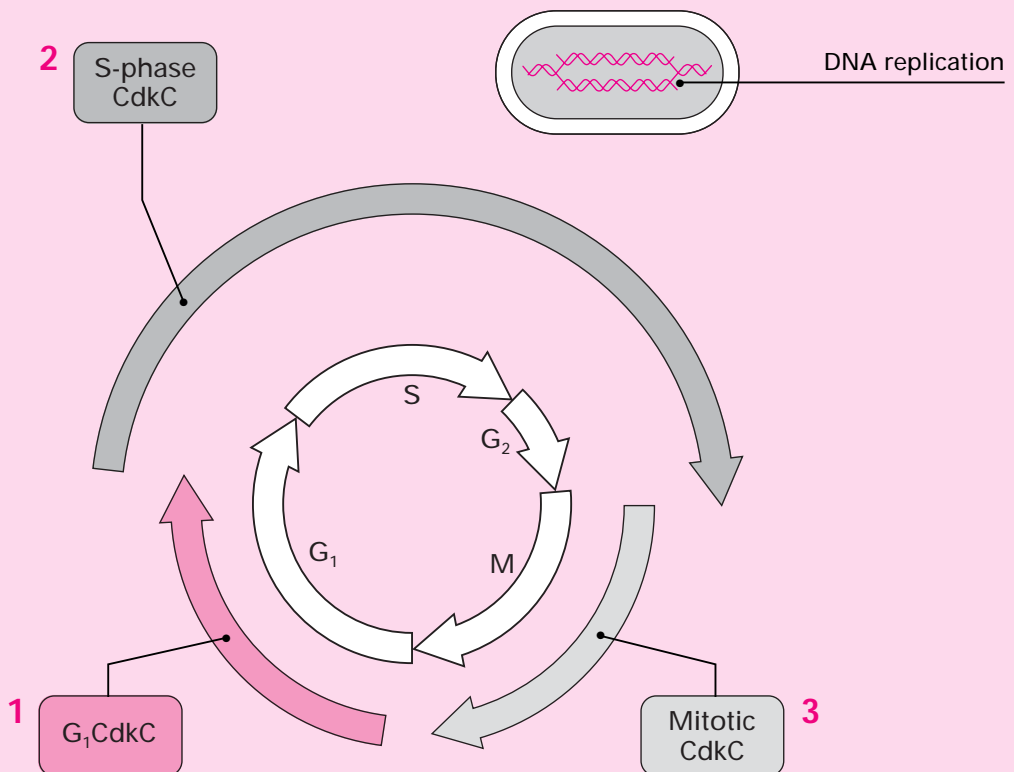
Cyclins in cell-cycle phases

The different phases of the cycle are controlled by different types of cyclins. Their concentrations rise and fall in sequence, as they are synthesized and then broken down.

1 G₁ phase Cell starts the cell cycle and synthesizes G₁ Cdk-cyclin (CdkC) complexes, which activate transcription factors that copy the genes that encode enzymes needed for protein synthesis.

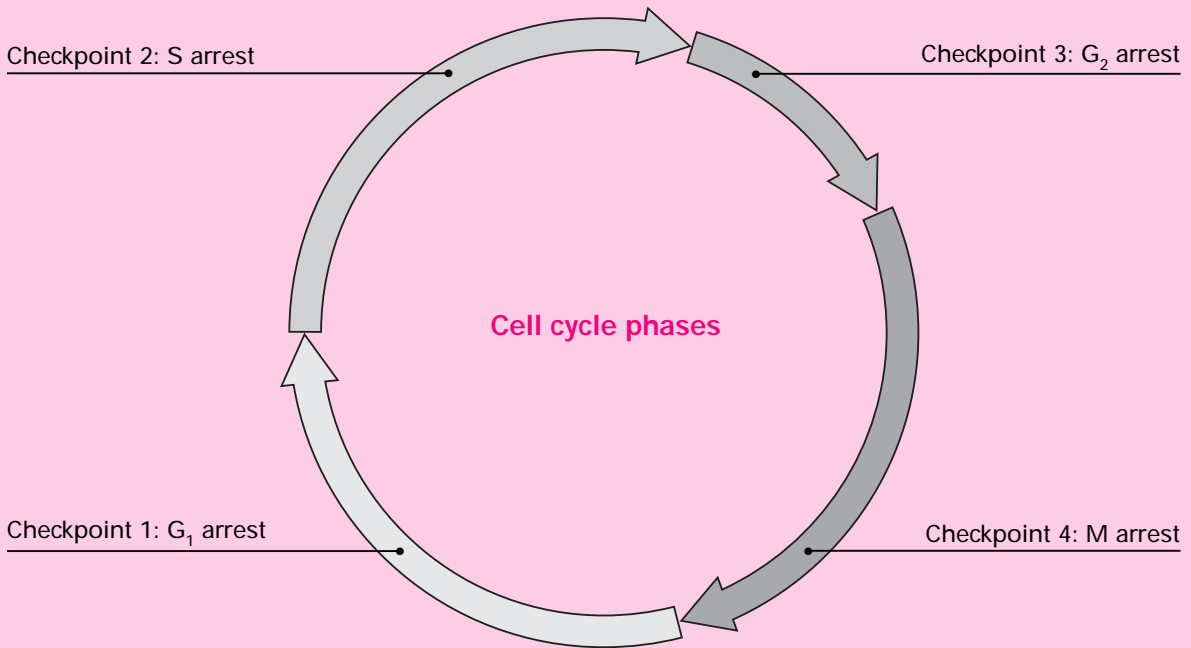
2 S phase S-phase CdkCs activate the enzymes that perform DNA replication.

3 G₂ phase Mitotic CdkCs are synthesized in an inactive form.



Cell cycle checkpoints

- Cells monitor their progress through the cell cycle at four checkpoints.
- These are points where the cycle stalls (arrests) if certain processes have not been completed, or if there is damage to the cell's DNA.
- Such checkpoints ensure that the cell does not start mitosis prematurely, which could have disastrous consequences for the cell.
- For example, if chromosomes enter mitosis while they are still replicating, they become separated into fragments, leading to the death of the cell.



Checkpoint control and arrest

Checkpoint 1 Damage to DNA causes G₁ arrest and allows cell to replace damaged or lost DNA nucleotides before they are copied during S phase.

Checkpoint 2 The presence of unreplicated DNA causes S arrest and allows cell to complete DNA replication before mitosis.

Checkpoint 3 Damaged DNA causes G₂ arrest, enabling the cell to repair double-strand breaks in DNA that otherwise

would cause fragments to separate from chromosomes during mitosis.

Checkpoint 4 Delayed or faulty assembly of the mitotic spindle causes M arrest, in which the crucial phase of mitosis is delayed, and chromosomes remain in a condensed state. This prevents abnormal segregation of chromosomes, which would produce daughter cells with too many or too few chromosomes.

Mitosis: Prophase to metaphase

Mitosis is the process by which most body cells reproduce themselves. The parent cell shown here has only four chromosomes in its nucleus (control center), rather than the actual 46 found in human body cells.

Before mitosis begins

1 The pair of centrioles (rod-shaped structures) duplicates itself, so that there are two pairs just before cell division. The deoxyribonucleic acid (DNA), which forms the chromatin (fibers of genetic material) in the nucleus, also duplicates.

Mitosis

This process is divided into four stages: prophase, metaphase, anaphase, and telophase. Cell division ends with cytokinesis.

Prophase

2 The pairs of chromatin threads coil up and condense to make chromosomes. Each chromosome is made up of two identical parts called chromatids. These are joined together by beadlike centromeres, making the chromosomes appear X-shaped.

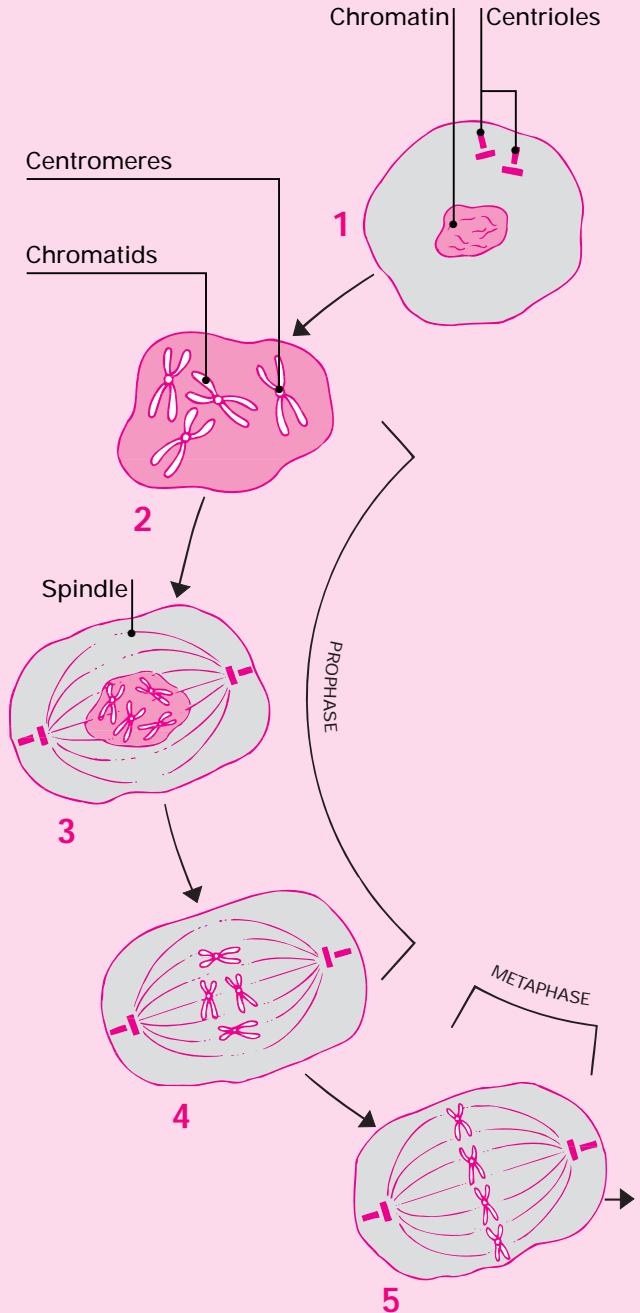
3 The centrioles move apart.

A network of threads called the mitotic spindle (made of microtubules like those used by the cytoskeleton) develops between them. As the spindle grows, it pushes the centrioles to opposite ends of the cell.

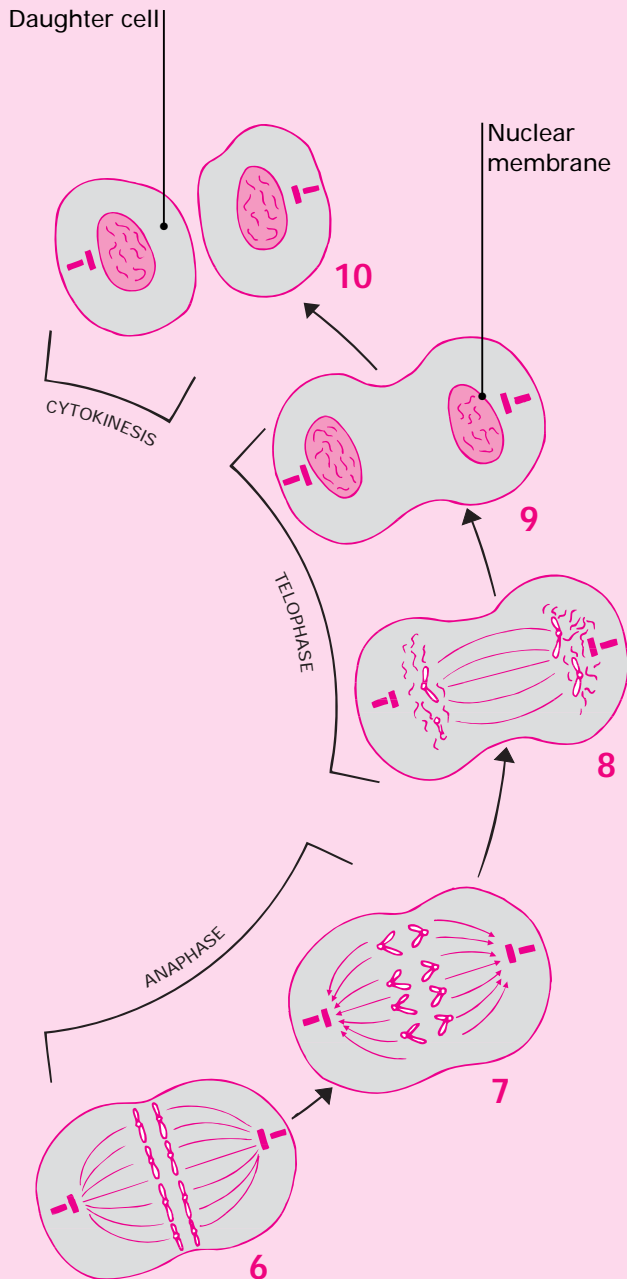
4 The cell nucleus breaks apart.

Metaphase

5 The chromosomes line up in the middle of the cell on the spindle.



Mitosis: Anaphase to cytokinesis



Anaphase

6 The chromosomes split apart at their centromeres. Each chromatid is now a daughter chromosome.

7 The spindle fibers retract toward the centrioles, pulling each set of chromosomes toward either end of the cell. The cell lengthens.

Telophase

8 The chromosomes in each half of the cell uncoil and become chromatin threads again.

9 The spindle disappears and nuclear membranes form around each mass of chromatin.

Cytokinesis

10 The cytoplasm (gel-like fluid) of the cell divides. This is called cytokinesis. The cell splits into two identical daughter cells.

Cell division facts

- Mitosis can also be viewed as two separate processes: nuclear division which replicates the nuclear material, and cytokinesis, in which the cell contents are divided in two.
- Daughter cells produced by mitosis are genetically identical to each other.

Meiosis: Prophase 1

Meiosis is the process by which reproductive or sex cells (ova—eggs—or sperm) are produced. Usually, human body cells have 46 chromosomes. Egg and sperm cells have only 23 chromosomes—half the normal amount. Thus, when the sperm fertilizes the egg, the zygote (fertilized egg) has the correct number of 46 chromosomes. The reduction division of meiosis is the process that results in cells with only 23 chromosomes. The parent cell shown here has only four chromosomes, rather than the actual 46 found in human body cells.

Before meiosis begins

1 The centriole (rod-shaped structure) duplicates itself, so that there are two just before cell division. The chromosomes in the nucleus duplicate themselves, too.

First meiotic division

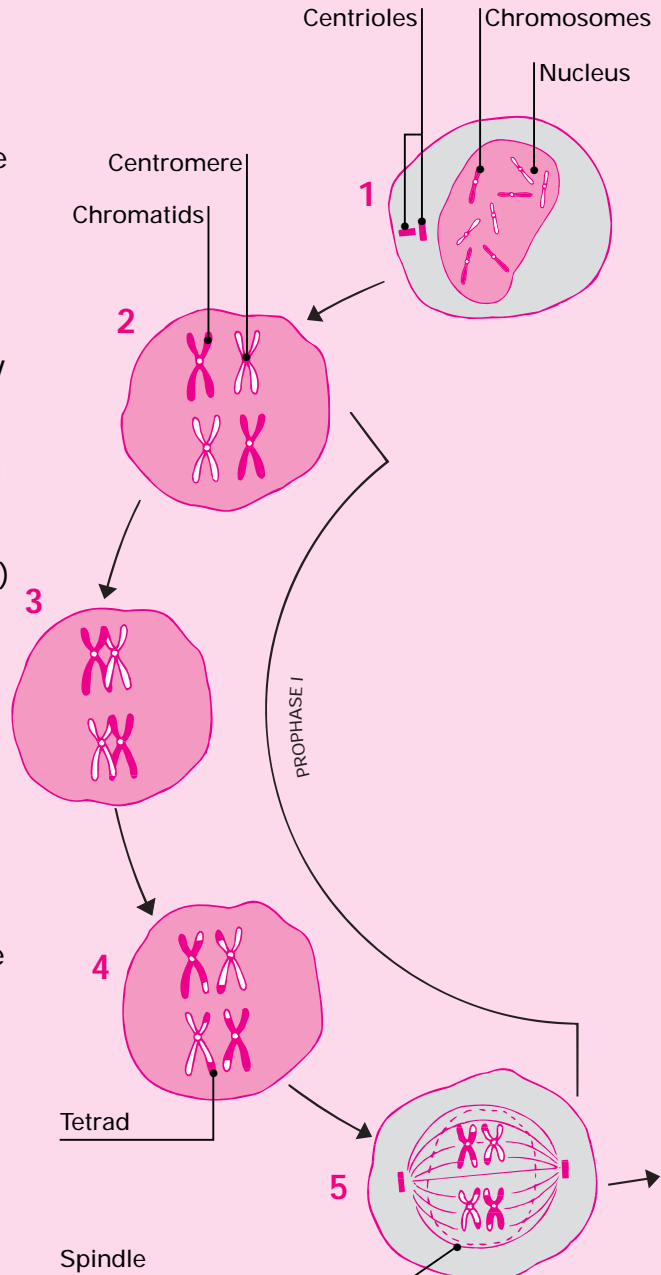
This division is split into four phases: prophase 1, metaphase 1, anaphase 1, and telophase 1. The division ends with cytokinesis.

Prophase I

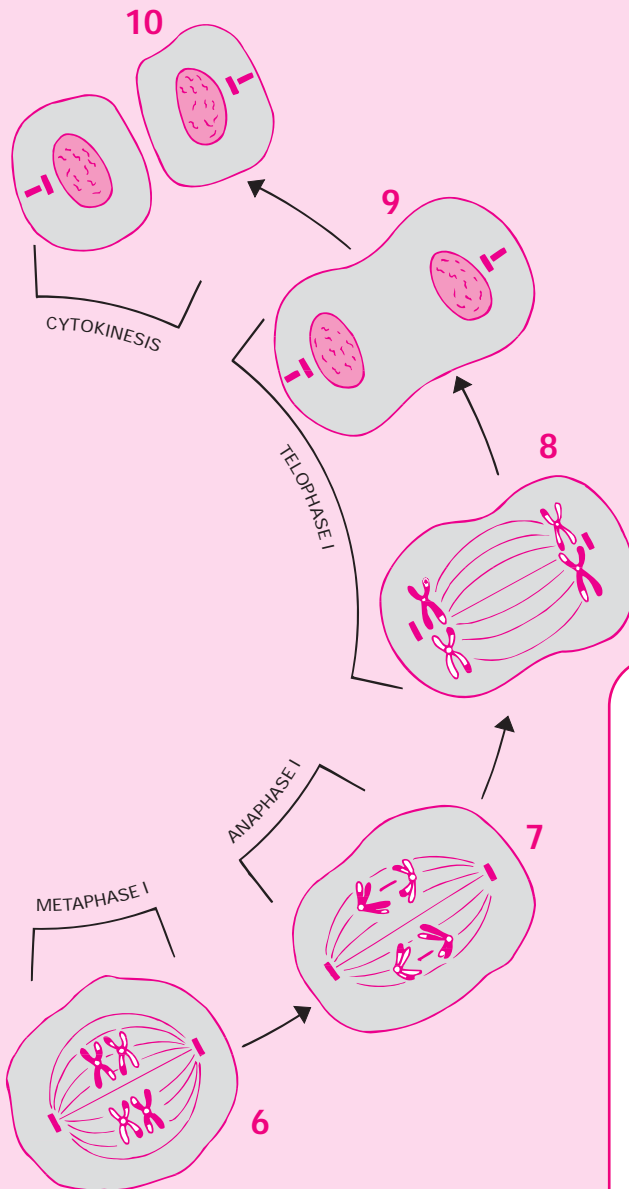
2 The chromosomes pair up, with the two parts (chromatids) joined at the centromeres. Groups of four chromatids are called tetrads.

3–4 The chromatids in each tetrad swap genetic material. This is called crossover. It ensures that each sex cell has a unique mix of genes.

5 Meanwhile, the nuclear membrane breaks down and a spindle forms between the two centrioles.



Meiosis: Metaphase 1 to cytokinesis



Metaphase I

6 The tetrads line up in the middle of the spindle.

Anaphase I

7 The spindle fibers retract and pull the chromosomes toward opposite ends of the cell. This splits up the tetrads, but the chromatids remain in their original pairs.

Telophase I

8 The chromatids remain joined as they move to opposite ends.

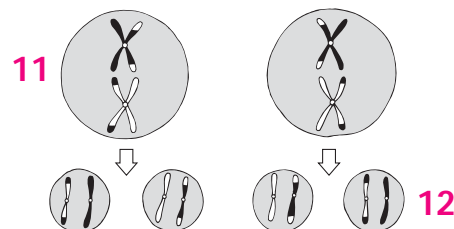
9 Nuclear membranes reform around each of the chromosomes and the spindle disappears.

Cytokinesis

10 The cytoplasm divides. This is called cytokinesis. Two daughter cells result. Each of these cells has the genetic material of one pair of chromatids from each tetrad.

Second meiotic division

This second division halves the chromosomes in each cell. It is similar to mitosis, except that the chromosomes are not duplicated first. Both the cells divide, resulting in four cells with two chromosomes each, half the original number.



Stem cells overview

Stem cells are undifferentiated cells that produce the specialized cells needed for tissues and organs.

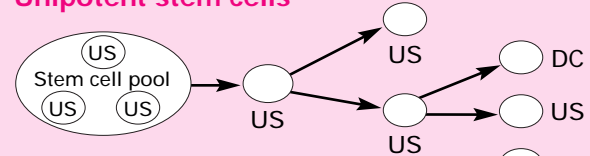
An early embryo contains stem cells with the potential to develop into any of the differentiated cells found in the body; they are the starting point for many developmental pathways.

Various types of stem cells remain active throughout adult life in many of the body's tissues. For example, intestinal stem cells continually divide to replenish the cells of the gut lining, while stem cells in bone marrow give rise to differentiated blood cells, such as lymphocytes and erythrocytes.

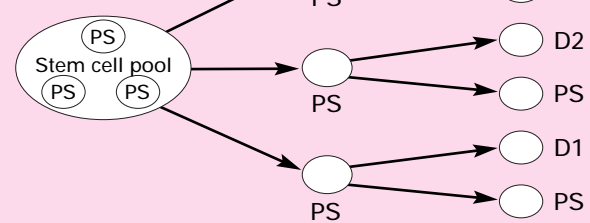
Unipotent versus pluripotent

- Stem cells may undergo asymmetric cell division to yield another stem cell and a more specialized cell that is somewhat differentiated and therefore restricted in its developmental potential.
- Stem cells that divide to produce just one type of differentiated cell (DC) are called unipotent (US). That is, they have a single capability.
- Pluripotent ("having many capabilities") stem cells (PS) might produce two, three, or more types of differentiated cells (D1, D2, D3).

Unipotent stem cells

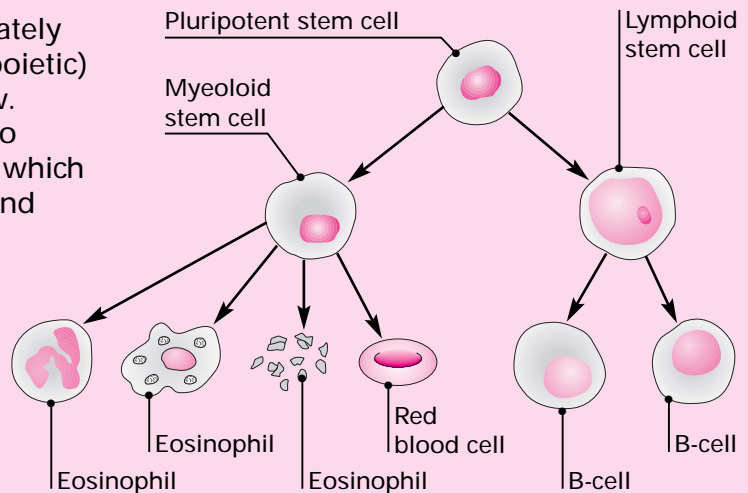


Pluripotent stem cells



Bone marrow stem cells

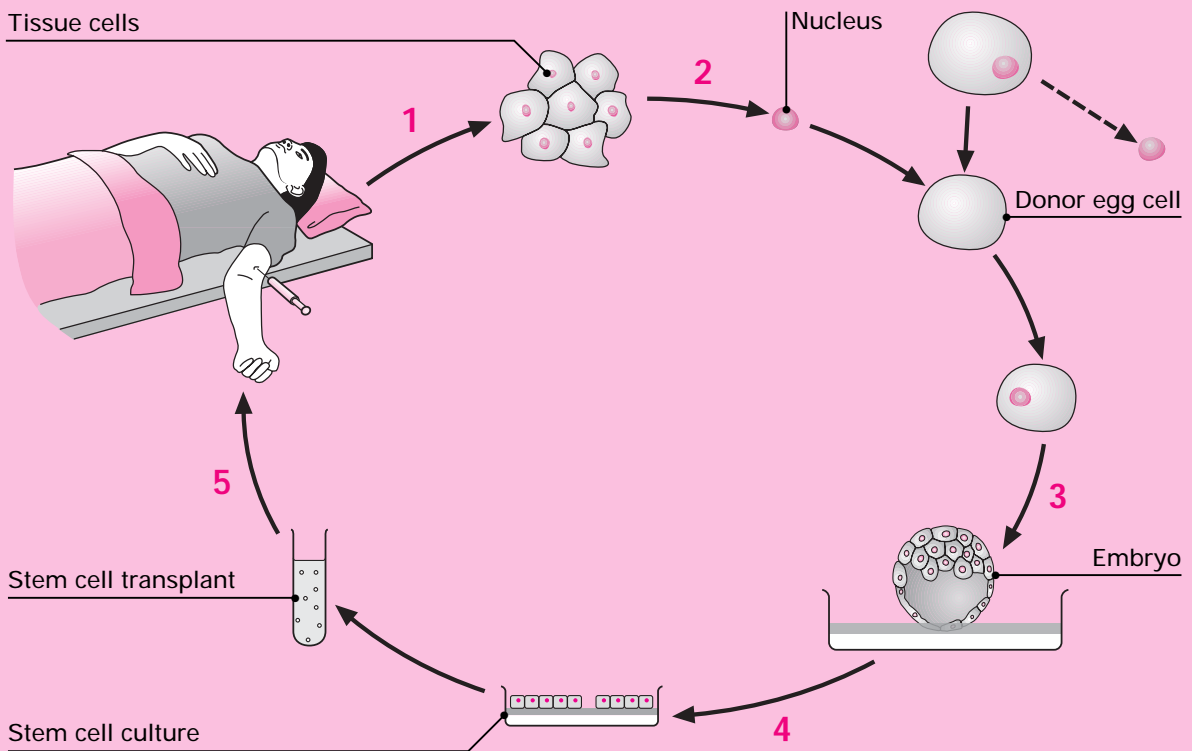
- All blood cells originate ultimately from blood-forming (hematopoietic) stem cells in the bone marrow.
- Pluripotent stem cells divide to produce myeloid stem cells, which remain in the bone marrow, and lymphoid stem cells, which travel to the thymus.
- Myeloid stem cells produce red blood cells, eosinophils, platelets, and macrophages.
- Lymphoid stem cells give rise to leukocytes, such as B-cells and T-cells.



Embryonic stem cells

The early human embryo is mainly composed of pluripotent stem cells with the potential to form virtually any tissue in the body. After about 14 days the stem cells have already become

specialized to produce only certain body parts. Scientists have devised methods of culturing embryonic stem cells, as a prolific new source of these cells, with vast therapeutic possibilities.



Principles of therapeutic stem cell use

- 1** Tissue cells are removed from the patient.
- 2** A nucleus is taken and injected into a donor egg cell from which the nucleus has been removed.
- 3** The egg cell is stimulated to divide and form an embryo (a process called cloning).

- 4** Stem cells are isolated from the embryo and cultured.
- 5** The appropriate type of stem cells are transplanted to treat the patient.

Programmed cell death

The body has a mechanism for bringing about the orderly death and disposal of certain cells.

This is called programmed cell death, or apoptosis, and it occurs during development and as part of aging.

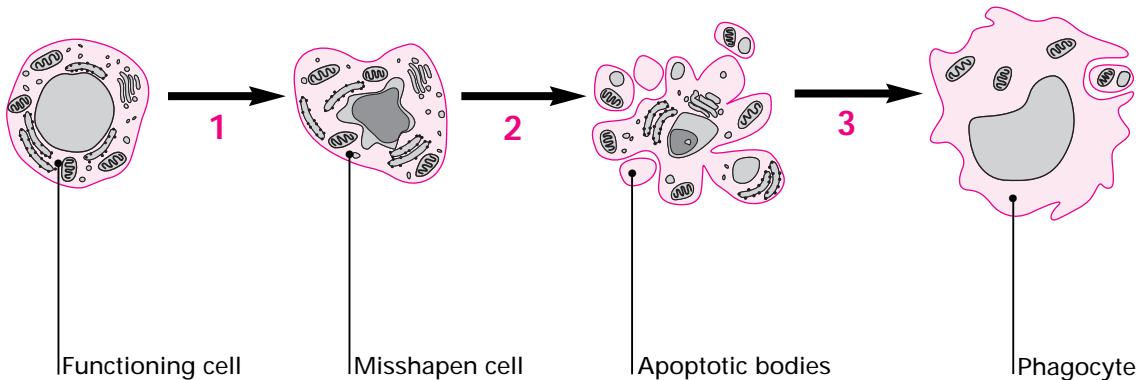
It is distinguished from cell death brought about by disease or injury, in which the damaged cells typically swell and burst, releasing their contents and causing pain and inflammation.

Events of cell death

1 The cell becomes slightly misshapen and starts to shrink. In the nucleus the chromosomes become condensed.

2 The nucleus and cytoplasm start to fragment, forming apoptotic bodies.

3 Surrounding phagocytic cells, such as macrophages, engulf the apoptotic bodies and digest them. The digested material is ejected from the phagocyte and recycled by new cells.



Caspases

Apoptosis involves the activation of enzymes called caspases. These promote processes that cleave certain key cell constituents, such as the

proteins in the nuclear envelope, endoplasmic reticulum, and the cytoskeleton, so that the cell can begin to be dismantled.

Control of cell death

Two different mechanisms control when cells embark on apoptosis:

Cessation of trophic signals

Most cells require continual extracellular signals to stay alive. These survival signals are called trophic factors. In the absence of trophic signals, the cell activates a "suicide" program of apoptosis.

Sending "murder" signals

Specific extracellular signals activate apoptosis and effectively "murder" a cell. This can happen when immune cells cause apoptosis of, for example, viral-infected or malignant cells. Cell murder is also an essential process during development, as a way of removing unneeded cells.

Importance of cell death during development

Apoptosis is used to orchestrate removal of entire structures, especially during an embryo's development. For example, killing of cells will allow structures, such as the fingers and toes, to take shape.

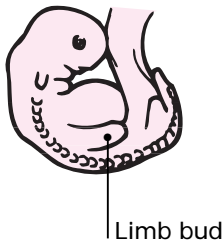
Cell death is also a crucial part of regulating the formation of the nervous

system. In the central nervous system, up to 85 percent of the neurons are programmed to die during development. Neurons are unusual cells, however, in that once the nervous system has matured, they cannot be replaced if they die. This is why injuries to the nervous system can leave permanent disability.

Cell death during development of human leg

Shaded areas indicate where cell death is occurring, to shape the digits on the developing limb bud.

Human embryo



Development of leg

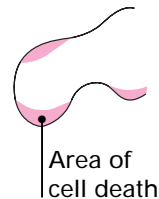
3.5 days



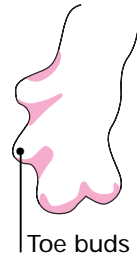
5 days



10 days



14 days

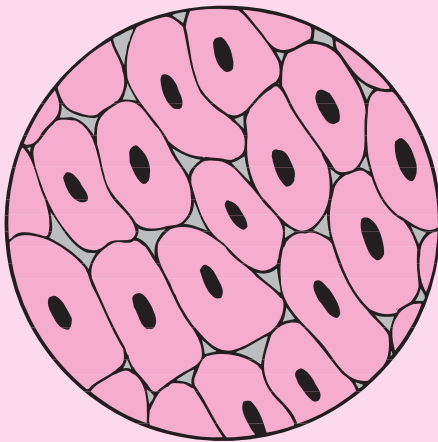


Developing cancer

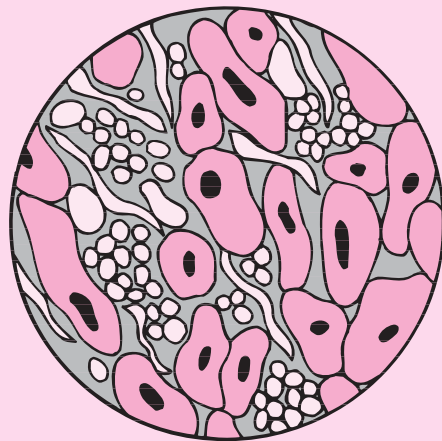
When cell division goes wrong, cancer can develop. Cancer is a form of neoplasm (abnormal cell growth, or tumor). It is more harmful than other formations of rapidly dividing cells, such as warts. Cancerous growths are

malignant and not benign (localized and relatively harmless). Malignant growths are able to metastasize (spread around the body through the blood and lymph vessels) and damage surrounding tissues.

Normal cells



Cancerous cells



Causes

Cancer is commonly associated with aging, but it is not known exactly why it develops.

Carcinogens

Certain agents, called carcinogens, play a role in causing cancer. Known carcinogens include:

- chemicals in tobacco;
- ultraviolet (UV) rays in sunlight;
- high-energy radiation (for example, nuclear radiation or X-rays);
- asbestos fibers; and
- some fungi.

Viruses

Certain viruses have also been associated with cancer, including:

- human immunodeficiency virus (HIV), linked with the otherwise rare Kaposi's sarcoma;
- hepatitis B, linked with liver cancer;
- papilloma virus, linked with cancer of the cervix (the neck of the uterus).

Other factors

Other factors that may influence the development of cancer are:

- diet;
- inherited tendencies;
- stress;
- alcohol; and
- continued irritation of membranes.

Types of cancer

Cancers are classified according to where they originate in the body. Most often, a cancer begins in a major organ of the digestive, respiratory, reproductive, urinary, or lymphatic

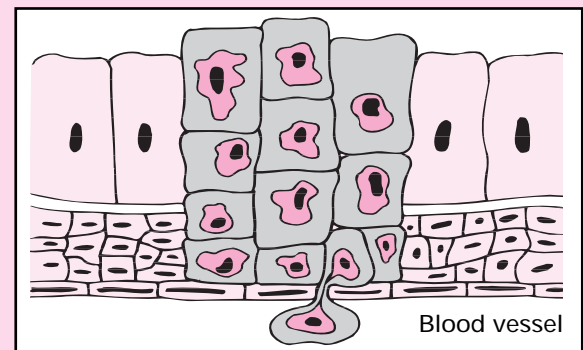
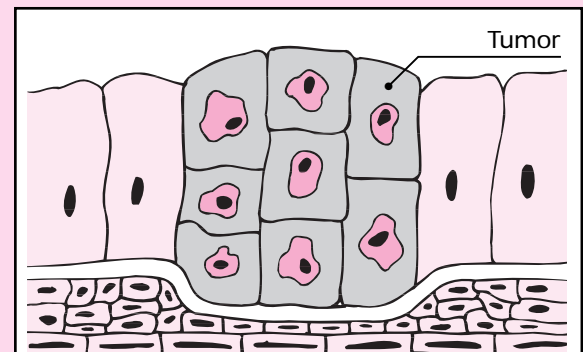
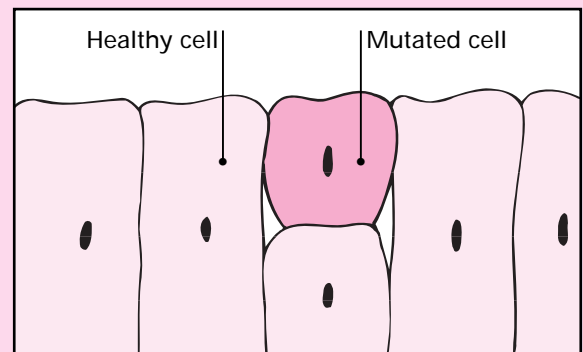
systems. Carcinomas are the most common cancers and start in epithelial tissue (skin and organ linings). Sarcomas are cancers that start in connective tissue, such as cartilage.

Development and spread

Deoxyribonucleic acid (the cell's inherited blueprint, or DNA) undergoes mutation (a change in the code it carries). This change might be triggered by a carcinogen, or it could just be a random event. The mutated cell can then begin to divide rapidly.

The multiplying cancerous cells invade surrounding tissues (such as nerves, muscle, and bone), causing damage to healthy cells and any other structures in the local region. This causes pain and a loss of certain body functions.

Eventually, cancerous cells can break into a nearby blood or lymph vessel. They are then able to metastasize (travel around the body) and develop secondary cancerous sites in tissues a long way from the primary site.



A gene provides each cell in the body with instructions for making (synthesizing) a particular protein (or part of a protein). Each protein, either directly or indirectly, determines a particular measurable characteristic or cell function. Proteins are formed either as enzymes (proteins that control biochemical reactions) or structural proteins (proteins that form part of the cell or other structure).

Gene facts

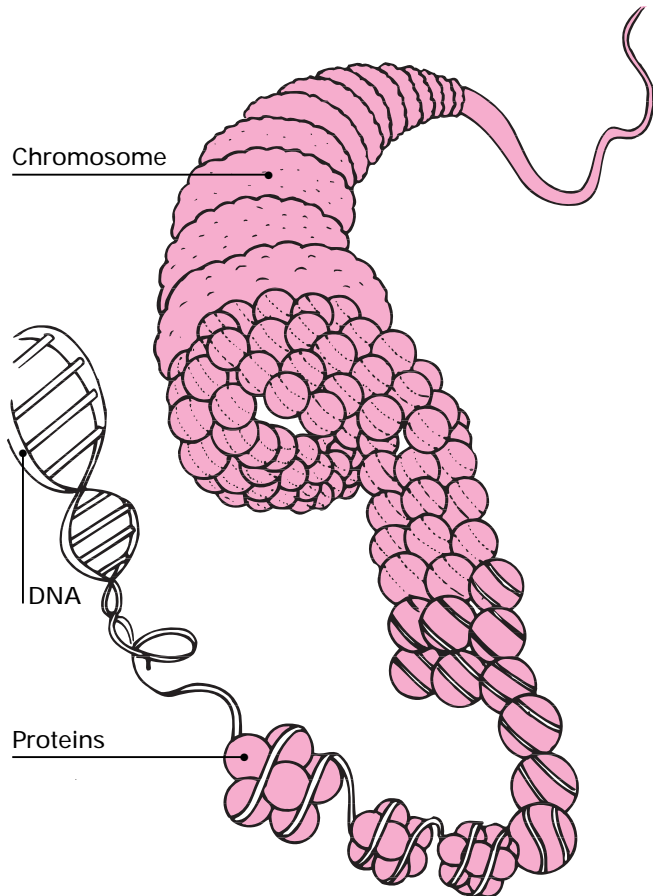
- A healthy cell has two sets of its genes, one from each of the parents.
- Each copy of the gene is an allele. Only one allele is "expressed" by the cell.

Where and when genes are active

Except for sex cells, all human cells contain a set of about 30,000 genes. Which genes manufacture proteins depends on where in the body a cell is situated. For example, the gene for eye color will be activated only in the cells of the eye's iris. The genes for the enzyme proteins involved in digestion will be activated only in the cells of the stomach lining.

Structure of a chromosome

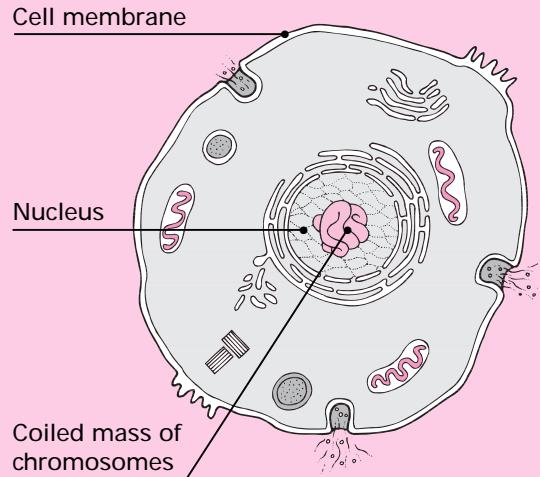
A chromosome consists of proteins called histones, and a spiral (or helix) of two strands of deoxyribonucleic acid (DNA). The DNA is coiled around the histones, which then coil themselves up forming a supercoil carrying several hundred or thousand genes. Genes provide the "blueprint" for a human body, from eye color to height. Tiny variations in genetic information make each person unique.



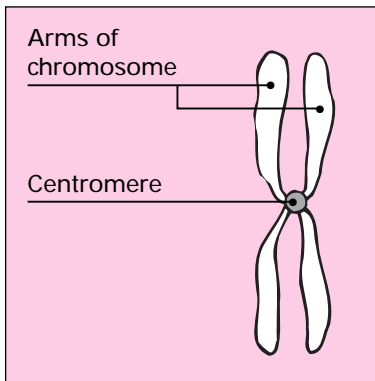
Basic structure of a chromosome

- Chromosomes are usually diffuse, threadlike structures, not easily distinguishable from each other within the nucleus.
- Just before and during cell division the chromosomes condense (become shorter and fatter), so that their different shapes become visible under a microscope.
- The chromosome also copies itself, making two identical chromatids that meet at a narrow point called the centromere.
- The centromere can be in the middle (metacentric), closer to one end than the other (acrocentric), or very near one end (telocentric).

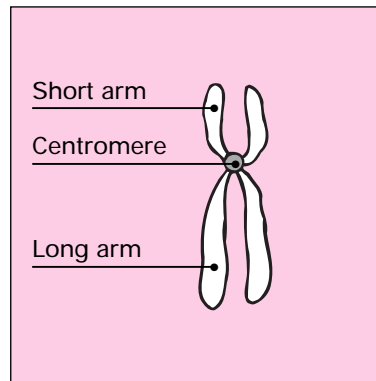
Chromosome location



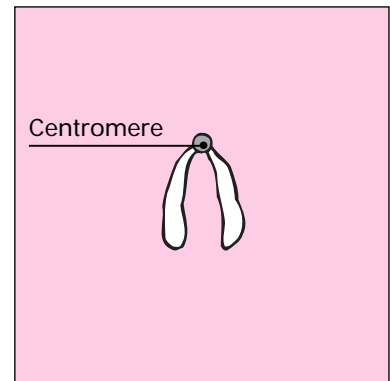
Metacentric



Acrocentric



Telocentric



Symbiotic DNA

Not all the DNA in a human cell is part of the genetic code. A segment of DNA that codes for a polypeptide is called a cistron. So a cistron of DNA equates to an inheritable gene. However, cistrons are made up of introns and exons. Exons are sections that contain code, while

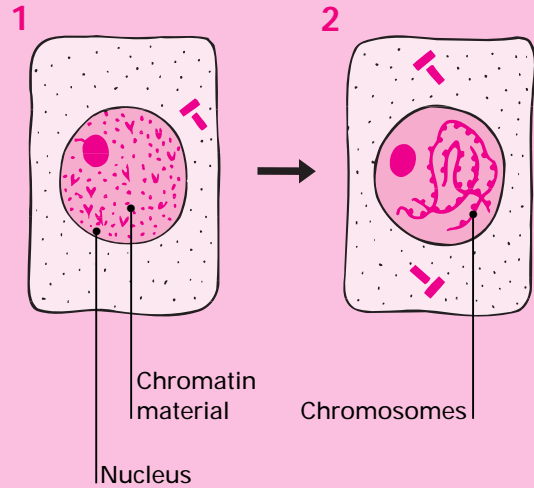
introns do not. The introns are passed on during reproduction along with the exons, but play no role in the functioning of the cell. Therefore the DNA in introns is symbiotic, since it harmlessly relies on the exons for survival.

Genes and chromosomes

Inherited factors that determine the characteristics of an individual are called genes. They are coded on strands of DNA located on the chromosomes in the nucleus of each cell.

Appearance of genetic material

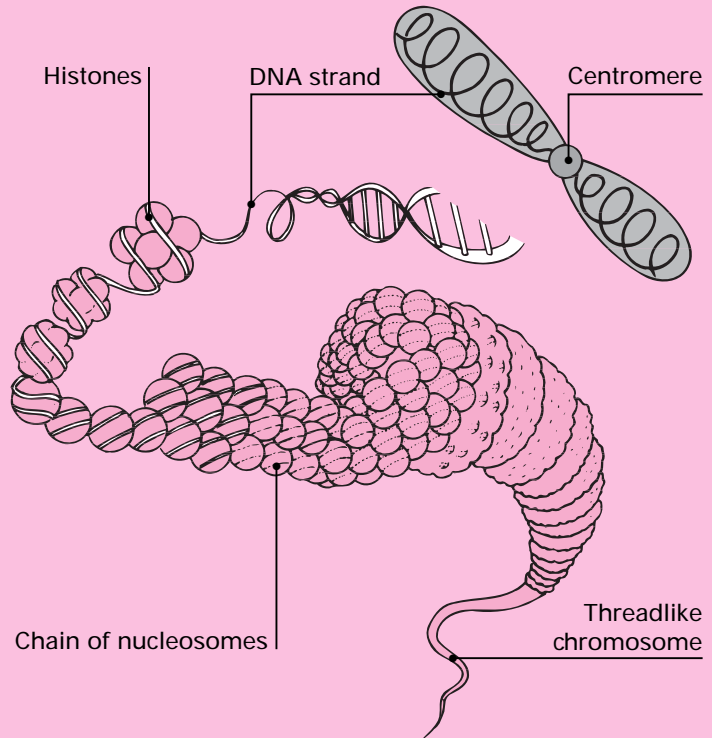
For most of a cell's life, the chromosomes are not visible but are dispersed within the nucleus as diffuse chromatin material. When a cell is about to divide, the chromatin material coils up very tightly into chromosomes that are then visible under a microscope.



Structure of a chromosome

A small beadlike structure called a centromere divides the chromosome into arms.

Each chromosome is made up of a chain of nucleosomes. These are histone proteins with deoxyribonucleic acid (DNA) wrapped around them.



Formation of chromosomes

Just before cell division occurs, the threadlike chromosomes become more tightly coiled. They condense to form the shorter, thicker, rod-shaped chromosomes.

Karyotypes: chromosome numbers

Homologous pairs

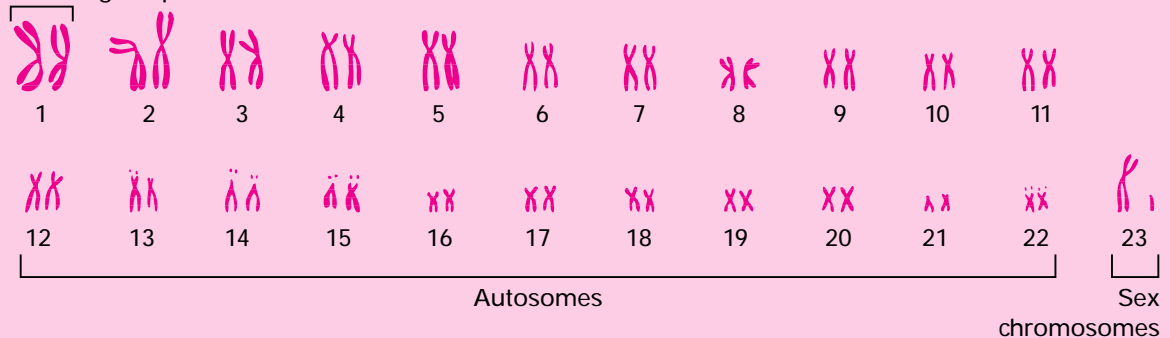
In nonreproductive cells there are two sets of chromosomes, one set inherited from each parent. Each chromosome belongs to a homologous pair with another from the other set. Paired chromosomes look similar and carry the same genes. There are 23 homologous pairs of chromosomes in human cells.

Autosomes and sex chromosomes

In humans, all but one of the pairs are called autosomes, since they are fundamentally alike. The 23rd pair determines the sex of the individual. In male humans, the 23rd pair is not alike in appearance, with one chromosome smaller than the other. In females, the sex chromosomes are the same size.

Chromosomes from a cell of a human male shown arranged in homologous pairs

Homologous pair



Function

Each chromosome carries several thousand genes (inherited units of DNA). These provide information that is the “master plan” or design, of a person. Genes determine features such as hair, skin, and eye color, the shape of facial features, height, and possibly, some personality traits. Tiny differences or variations in the information the genes carry make each person unique.

Chromosome fact

- Apart from sperm and ova (or eggs) all human cells contain 46 chromosomes
- This number is unique to humans. Not all DNA is held within the chromosomes, however. Some is found in the mitochondria.

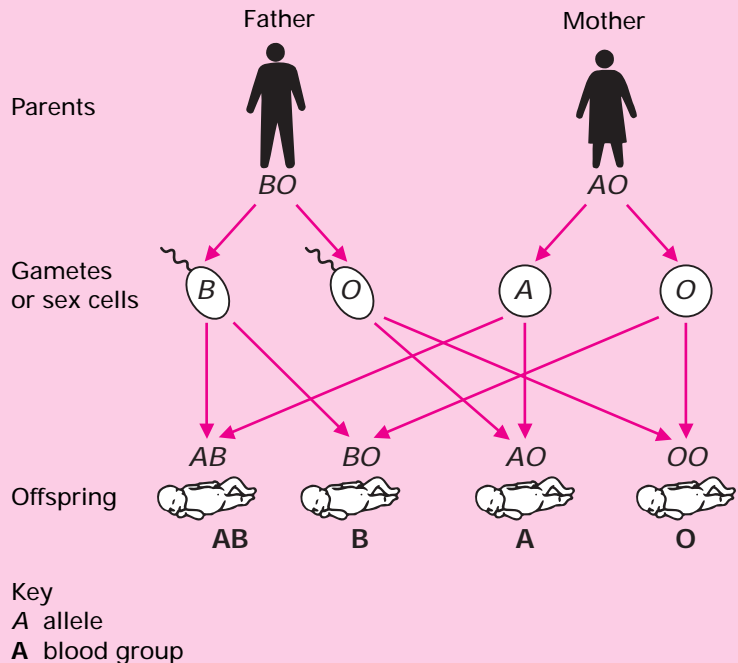
Alleles

The word “gene” has several definitions. In its basic form, a gene is the smallest unit of inheritance, which can be recognized as being passed on from cell to cell. It is also a section of DNA that contains the code for a certain characteristic, such as eye color. Everyone has colored eyes but they are not all the same color. This is because their eye-color genes are not all the same. The different forms of a gene

are called alleles. A gene may have two or more alleles. In general, everyone inherits two alleles of each gene, one from their mother and one from their father. The allele used to determine an inherited characteristic is decided by a system of dominance. Some dominant alleles are expressed in preference to recessive (undominant) ones, while other pairs of alleles are both expressed.

ABO blood groups

In the ABO system, the gene that determines a person's blood group has three major alleles: A, B, and O. Each of these alleles contains the code for a chemical marker, or antigen, that appears on the surface of blood cells. (In the case of O, it codes for a lack of antigens.) A human inherits two of these alleles and this defines their blood group: A, B, AB, or O. Blood of one group cannot be mixed with another because it will cause clotting.



Inheriting a blood group

Multiple alleles, such as those for blood groups, are transmitted in the same way as genes that have only two alleles. This is because no matter how many alleles a gene has, an individual can have no more than two of them, and only one

will be passed on to their offspring. In the example above, the group-B father passes on either B or O alleles, while the group-A mother passes on A or O. They can produce offspring with any of the four blood groups.

Genotypes and phenotypes

As a person can only inherit one blood-group allele from each parent, there are six different ways that they can combine. These are all the genotypes (genetic makeup) for this trait. A person's actual blood group is their phenotype (expression) of these alleles.

A matrix, or grid, is used to work out all the possible genotypes from the mix of alleles.

Key
AO genotype
(A) blood group

	A	B	O
O	AO (A)	BO (B)	OO (O)
B	AB (AB)	BB (B)	BO (B)
A	AA (A)	AB (AB)	AO (A)

Dominant, codominant, and recessive alleles

The phenotype of a gene depends on the relationship between the two inherited alleles. One allele may be dominant over the other recessive one, while alleles of equal dominance might both be expressed in the phenotype, or appear as a mixture. Continuing with the blood group example, alleles A and B are dominant. They are always expressed in preference to O, which is the recessive allele. (Someone with blood group O has to have inherited two recessive O alleles from the parents.) The dominant A and B alleles are also codominant. This means that when both are present, both are

expressed. Each group produces a combination of antigens (markers) and antibodies (chemicals that attack antigens). There are two antigens in the ABO system: A and B. There are also two corresponding antibodies: anti-A and anti-B antibodies. The combination of these

defines the blood group. If a person has the alleles A and B, they will have both A and B antigens but neither antibodies (blood group AB). This is because A and B are codominant. Therefore, from nine possible genotypes, there are four phenotypes produced.

Blood group antigens and antibodies

Blood group	Antigen	Antibody
A	A	anti-B
B	B	anti-A
AB	AB	neither
O	neither	anti-A & anti-B

The double helix model of DNA

The structure of DNA consists of two chains of nucleotides intertwined to form a double helix, or spiral.

Each nucleotide consists of a sugar (deoxyribose), a phosphate group, and a base unit.

The DNA base might be a purine, such as adenine (A) or guanine (G), or a pyrimidine, such as thymine (T) or cytosine (C).

The sugar and phosphate groups link to form the “backbone” of each chain, while the bases project into the center of the helix.

The two strands run in opposite directions, and are held together by bonds between pairs of bases.

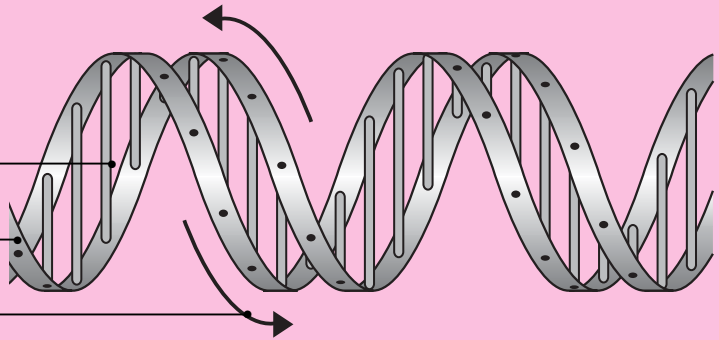
The base pairing is highly specific: adenine always pairs with thymine, and guanine with cytosine.

Spiral ladder arrangement of double helix

Paired bases forming crossbonds

Strands forming backbone

Direction of sugar-phosphate backbone

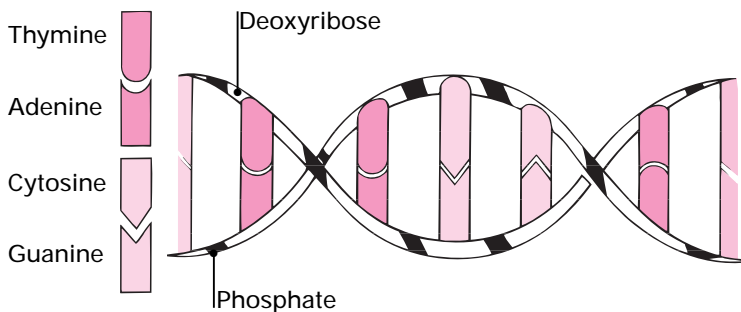


DNA pairs

The DNA molecule is a double helix—it looks like a twisted ladder.

The “sides” are formed by the sugar deoxyribose and phosphate. The “rungs” are formed by pairs of bases. The order of the bases is what makes up the genetic code. The code has four “letters,” one for each base. Several hundred bases in a row form a gene.

DNA pairs



Molecular double helix model

This is a more detailed molecular model of the DNA double helix. It provides a more accurate depiction of how the atoms are arranged than the simpler "ladder" model.

Major and minor grooves

A DNA double helix has two grooves that coil around its length. The larger one is called the major groove and the smaller one, the minor groove. Molecules interact with the exposed nucleotide bases in the major and minor grooves.

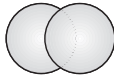
Major groove

Minor groove

Key

On the molecular model, atoms are represented as balls of relative sizes.

Atoms of a base



Phosphorus



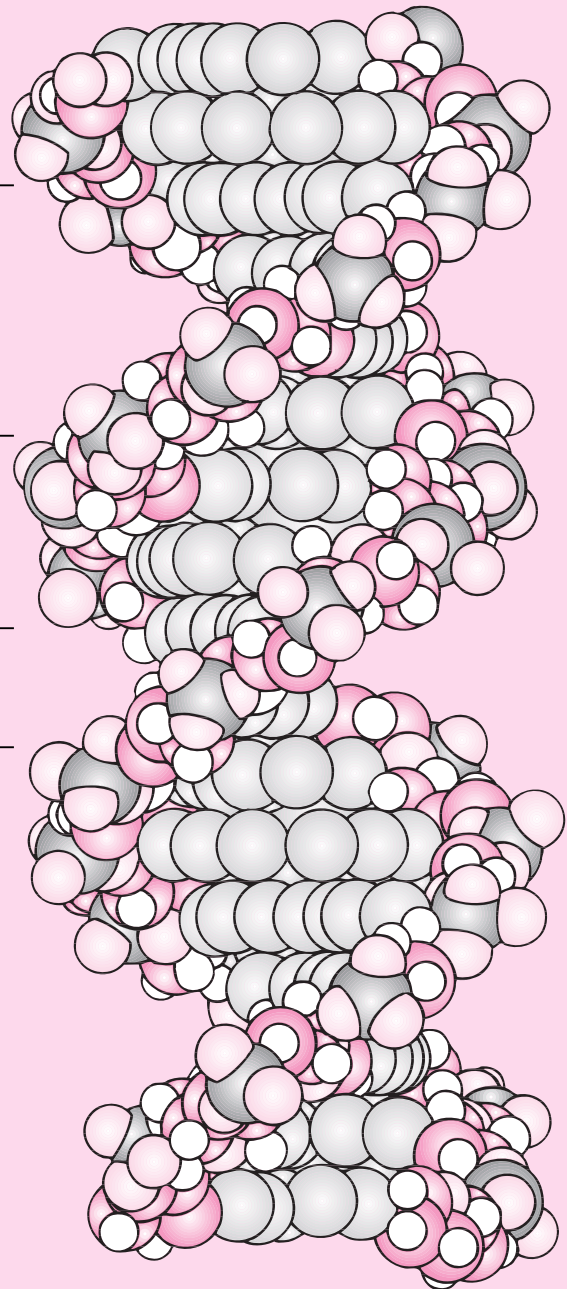
Hydrogen



Oxygen



Carbon



The importance of protein synthesis

DNA (deoxyribonucleic acid) functions primarily by directing the production of proteins. Each DNA molecule can carry thousands of genes. Every gene carries the plan for building a particular protein, or part of a particular protein. Which proteins are produced decides everything about a cell, from whether it is part of a muscle or the blood, and the human body as a whole, from the color of the hair and skin to a propensity to certain diseases.

The “Central Dogma”

This describes the flow of genetic information from DNA to protein: DNA makes ribonucleic acid (RNA), which makes protein. This involves two main stages: transcription and translation.

1 Transcription

The genetic information—the nucleotide sequence—carried by one strand of the DNA helix is transcribed onto an mRNA (messenger RNA).

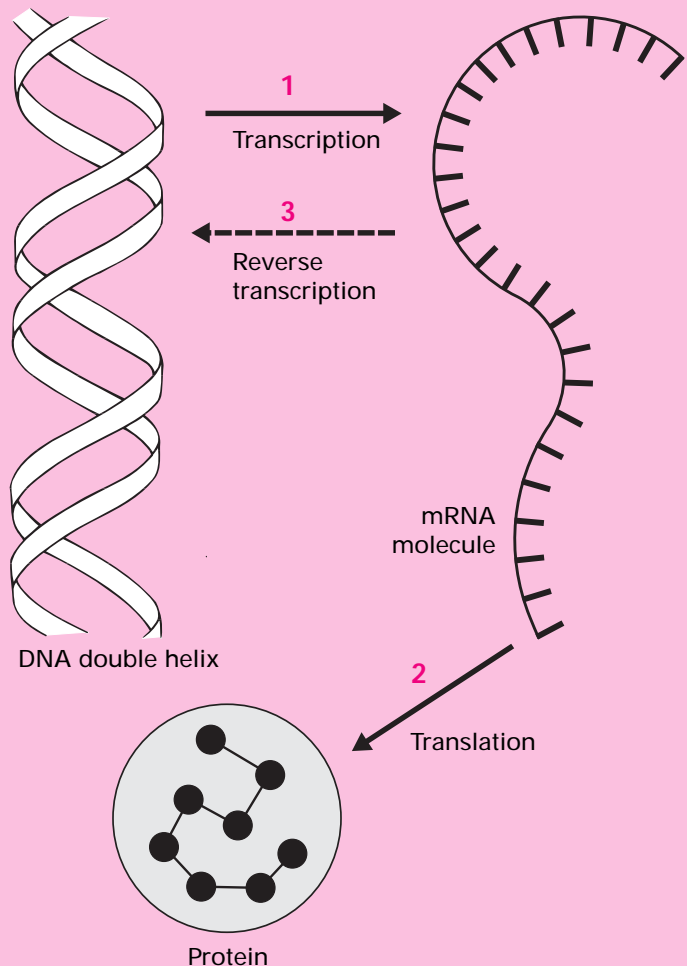
2 Translation

The information in the mRNA is then “read” by tRNA (transfer RNA) and translated into a sequence of amino acids that make a protein.

3 Reverse transcription

An enzyme called reverse transcriptase can make DNA by copying RNA, but there are no enzymes that can convert protein sequences into DNA or RNA sequences, and no enzymes that can make proteins directly from DNA.

From DNA to RNA to protein



Transcription

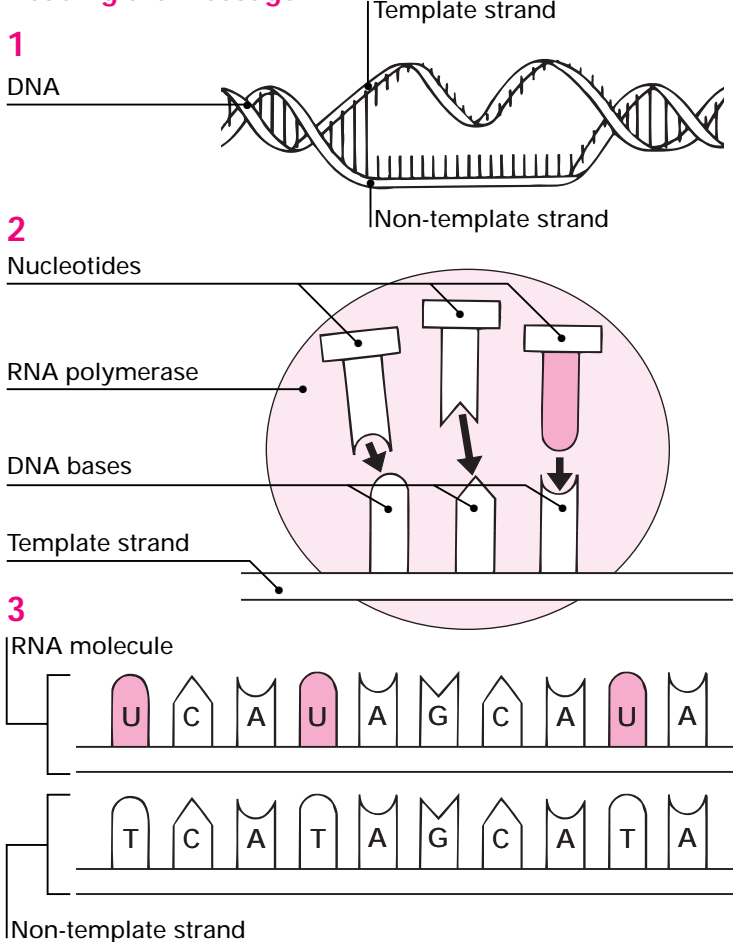
The process of making RNA from DNA is called transcription.

1 The two DNA strands that make up the double helix become detached from each other. They partly unwind from the helix. This exposes the genes (sequences of bases) and makes it possible to transcribe them. Just one of the strands serves as a template to produce the RNA strand.

2 The enzyme RNA polymerase binds to the DNA and moves along it, attaching free nucleotides to the exposed complementary DNA bases, making this a strand of mRNA.

3 The new mRNA molecule has exactly the same nucleotide sequence as one of the DNA strands—the one that was not acting as the template. However, RNA molecules do not have the base thymine. Instead they contain uracil. Uracil bonds to adenine, in the same way as thymine. The mRNA travels out of the nucleus to the ribosome where translation occurs.

Reading the message



Key:

Base on DNA strand

- ▢ A adenine
- ◻ T thymine
- ▤ G guanine
- ◊ C cytosine

Complementary base on RNA strand

- ◻ U uracil
- ▢ A adenine
- ◊ C cytosine
- ▤ G guanine

Gene expression

DNA is the genetic material, but other nucleic acids play a vital role in gene expression, the process of putting the information carried by genes into effect.

The expression of most genes results in the synthesis of a polypeptide within the cell.

Gene expression involves two main steps: transcription and translation.

Transcription

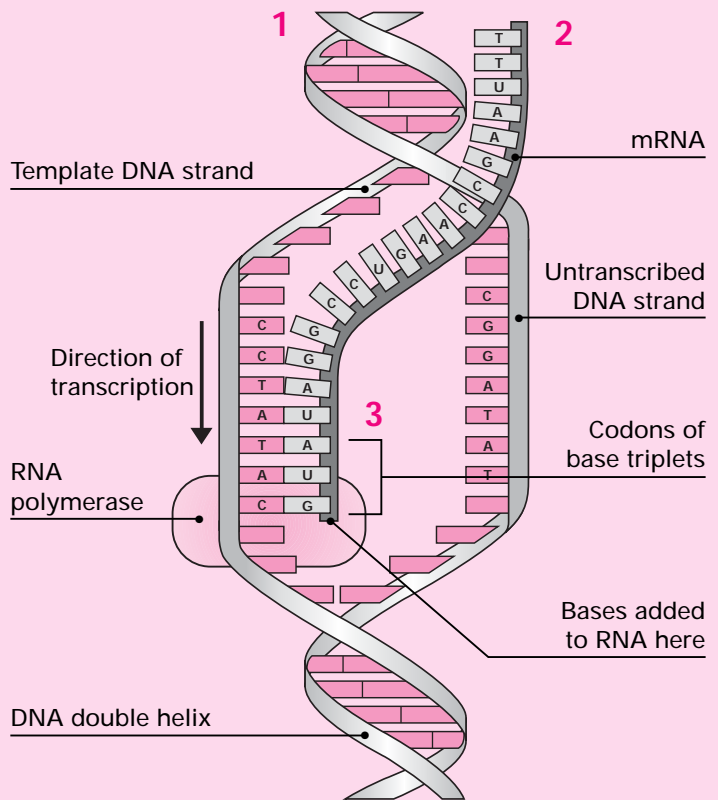
The cell does not get its instructions for assembling polypeptides directly from nuclear DNA. Instead, the base sequence of each gene is read across, or transcribed, into another single-stranded nucleic acid, called messenger RNA (mRNA).

1 The DNA strands of the gene unwind and one strand serves as a template for the assembly of mRNA, by the enzyme RNA polymerase. The other DNA strand is not transcribed, although this is the strand that is actually replicated.

2 The mRNA consists of a single chain of nucleotides, and resembles a single strand of DNA except that the base uracil (U) occurs instead of thymine (T).

3 The base sequence in mRNA is complementary to that of its DNA template, and carries the genetic code, in the form of base triplets, or codons. mRNA is made in the nucleus, and then moves into the cytoplasm, where polypeptide assembly takes place.

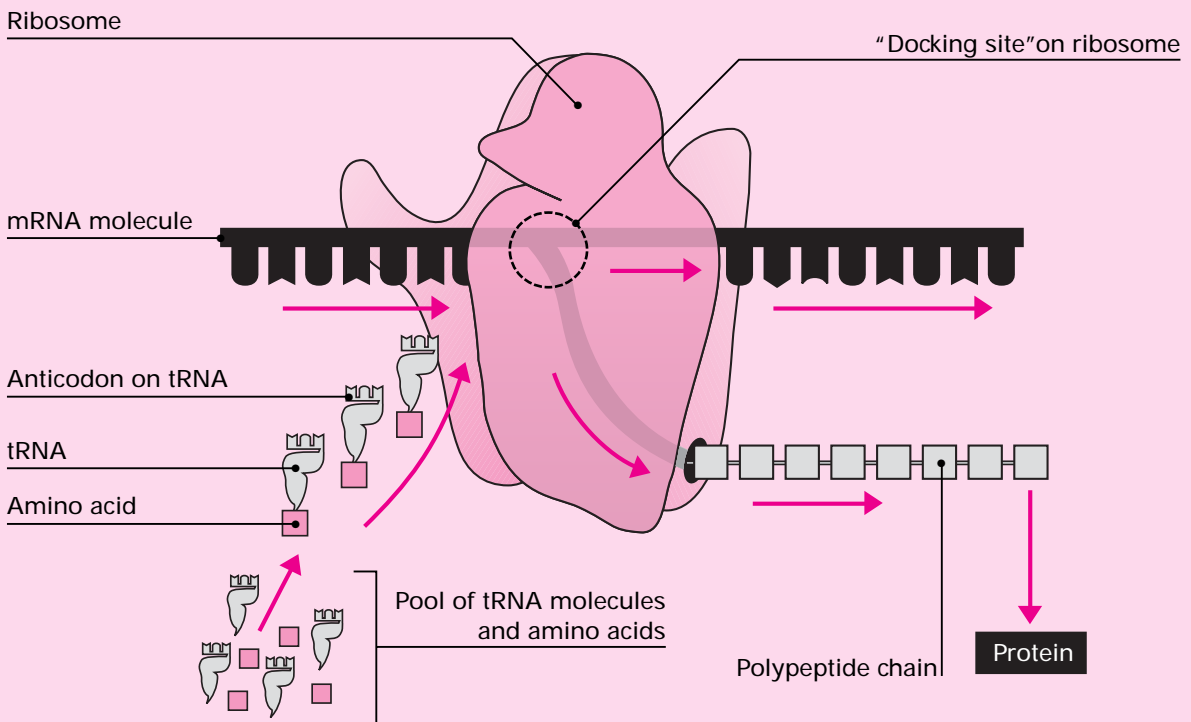
Gene transcription



Translation

- The base sequence of each mRNA molecule is “read” by a ribosome—a cluster of proteins and another type of RNA (called ribosomal RNA; rRNA).
- A third type of RNA, called transfer RNA (tRNA), brings amino acids to the assembly site.
- As the mRNA molecule feeds through the ribosome, amino acids are added to the end of the growing polypeptide chain. (Several polypeptide chains make up a protein.)
- Each type of tRNA bears an anticodon, which complements that of the mRNA codon currently inside the ribosome.
- Because of this, the amino acids are incorporated into the polypeptide chain in the correct order.

Gene translation



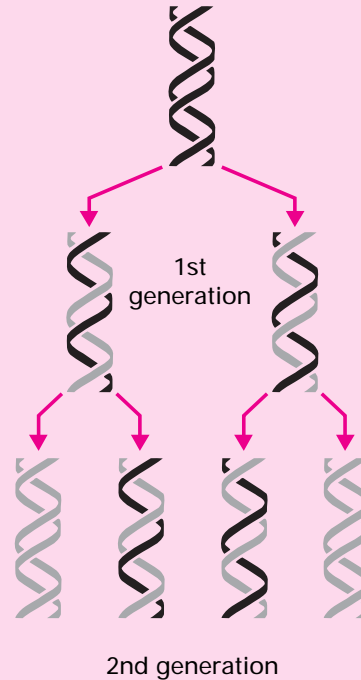
DNA replication

In order to ensure that daughter cells have the same genetic information as parent cells after cell division, it is essential that DNA (deoxyribonucleic acid) is replicated exactly.

Semi-conservative replication

The two parental strands of DNA unwind and a new strand forms on each original strand of DNA. Both of the first generation DNA helixes would, therefore, consist of one new and one old strand each. In theory DNA strands can persist forever, always forming the original half of a new double helix.

DNA replication







Step-by-step replication

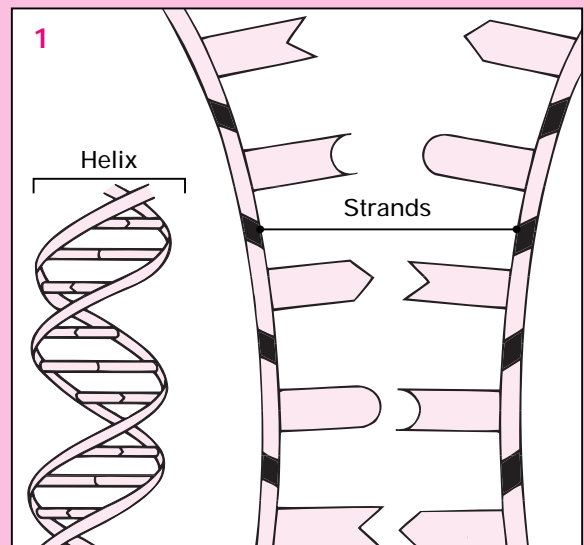
1 The DNA double helix uncoils and the two strands separate. These act as templates ("molds") for new strands.

Key

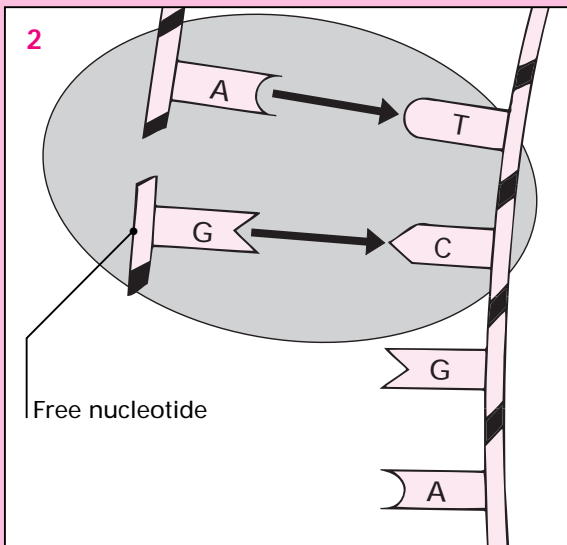
adenine  thymine
 guanine  cytosine

 phosphate group
 sugar (deoxyribose)

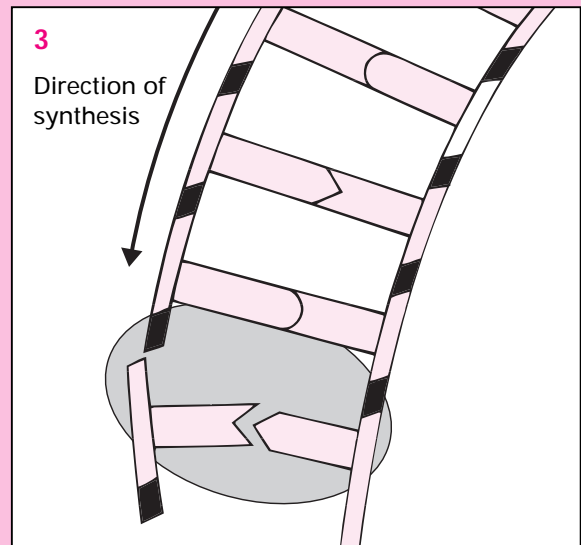
 DNA polymerase
 new DNA strand in final helix



2 In the presence of the enzyme DNA polymerase, free nucleotides (the building blocks of DNA) attach to exposed complementary bases on the original strands. Adenine (A) always attaches to thymine (T), and guanine (G) always attaches to cytosine (C).



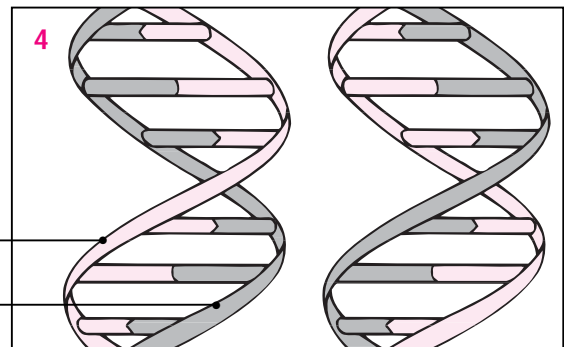
3 DNA polymerase then joins these free nucleotides, one at a time, onto the end of the DNA strand that is being synthesized. The DNA polymerase then moves on to the next nucleotide of the template DNA strand, allows a complementary nucleotide to pair with it, then joins that onto the new DNA strand. This process is repeated all along both of the original strands.



4 The end result is two DNA molecules identical to the original double helix. Each consists of one new and one old strand or series of nucleotides.

Original strand

New strand



DNA repair

To ensure normal gene function, it is vital that a cell maintains the correct sequence of bases in its DNA.

Changes in this sequence can arise because of:

- copying errors—DNA polymerase occasionally inserts the wrong base during DNA replication;
- spontaneous chemical changes in the DNA which can occur randomly in normal external environmental conditions; or
- mutagens—certain chemicals and types of radiation induce chemical changes in the DNA.

If changes in the DNA sequence become permanent, they are called mutations. When a body cell accumulates mutations, it may begin to malfunction and die, or possibly become cancerous. Moreover, defects in sex cells can be transmitted to the person's offspring. While nearly all mutations cause problems, a few actually produce benefits. Mutations are the driving force behind evolution by natural selection. Nevertheless, cells have several mechanisms to identify and repair changes in their DNA.

"Proofreading" by DNA polymerase

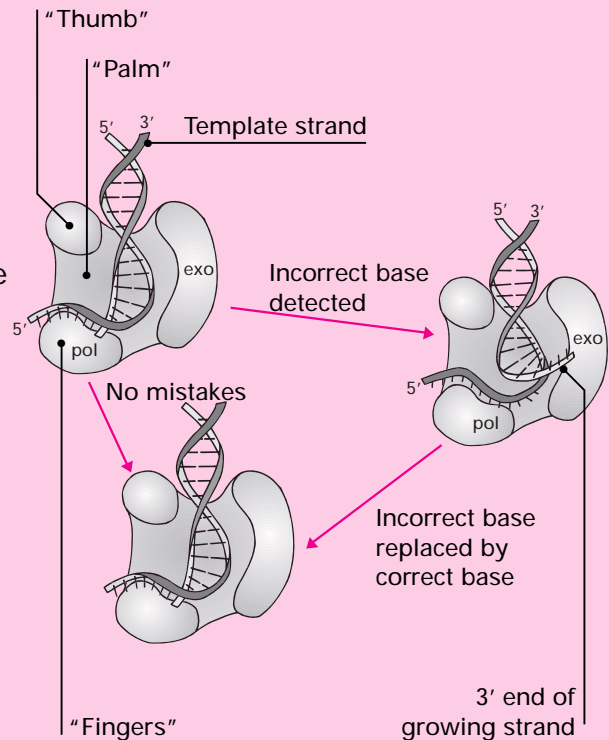
DNA polymerase can identify and remove a mismatched base while it is elongating a daughter DNA strand during DNA replication. It then inserts the correct base, complementary to the corresponding base in the template strand.

Model of DNA polymerase

This depicts the enzyme as similar to the inside of a partly-open right hand. The template strand is bound to the "fingers," and incoming nucleotides are added to the 3' end of the growing strand at a pol (polymerase) site between the "fingers" and the "palm."

If an incorrect base is added to the strand, the end of the new double-stranded DNA "melts" (the strands separate) enabling the daughter strand to be transferred to an exonuclease site (exo), where the incorrect base is replaced.

Enzyme "hand"

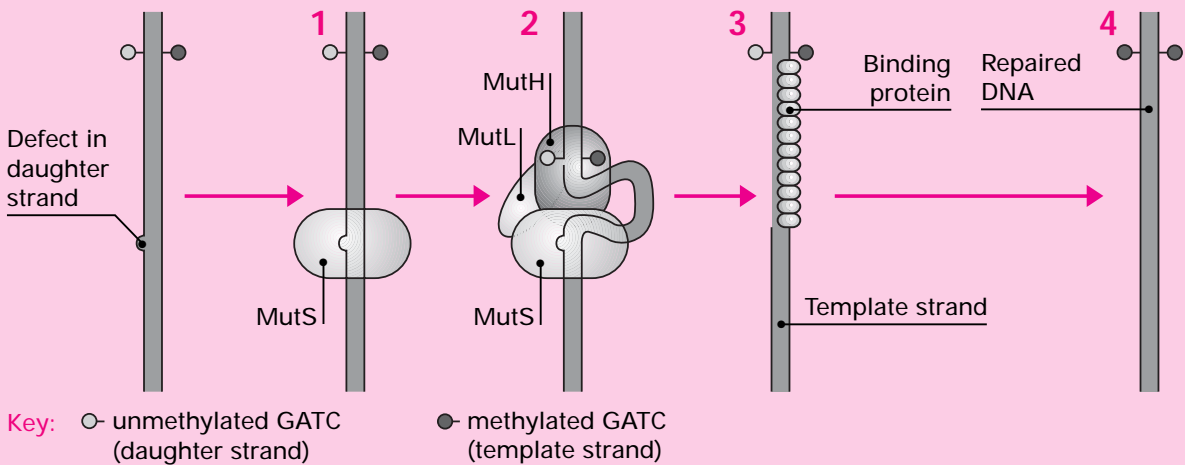


Mismatch repair

In spite of the proofreading capability of DNA polymerase, errors in base pairing still arise during DNA replication. One of the ways in which cells correct these errors is mismatch repair. Immediately after replication has taken place, various enzymes collaborate to identify and remove incorrectly paired bases from newly synthesized DNA strands. A DNA segment containing the mismatch is cut

out, and a new segment synthesized. The most crucial aspect of such a process is that the repair enzymes distinguish between the old template (parent) strand and the newly synthesized (daughter) strand, so that the incorrect daughter strand is the one being repaired using the correct base sequence (i.e., that of the template strand) as a reference.

Checking daughter strand



The repair process

The key components of mismatch repair in human cells are enzymes encoded by certain genes.

1 MutS (i.e., product of the *mutS* gene) binds to a mismatch.

2 MutH binds to a GATC (guanine; adenine; thymine; and cytosine) sequence near to the defect. (GATC sequences on the template strand are marked with a methyl group).

The nearby bound MutS recruits MutL, which links MutS to MutH. MutH then cuts out the segment of unmethylated daughter strand containing the defect.

3 Single-stranded binding protein protects the intact template strand.

4 A new segment of DNA is assembled to fill in the gap using the parent strand as template, and joined up (ligated) on either side by a ligase enzyme.

Mutations

A mutation is a sudden and inheritable alteration in the cell's genetic material—its DNA (deoxyribonucleic acid).

It is estimated that on average three mutations occur per cell division. These can occur during DNA replication prior to cell division or be caused by mutagens (mutagenic agents).

Examples of mutagens include:

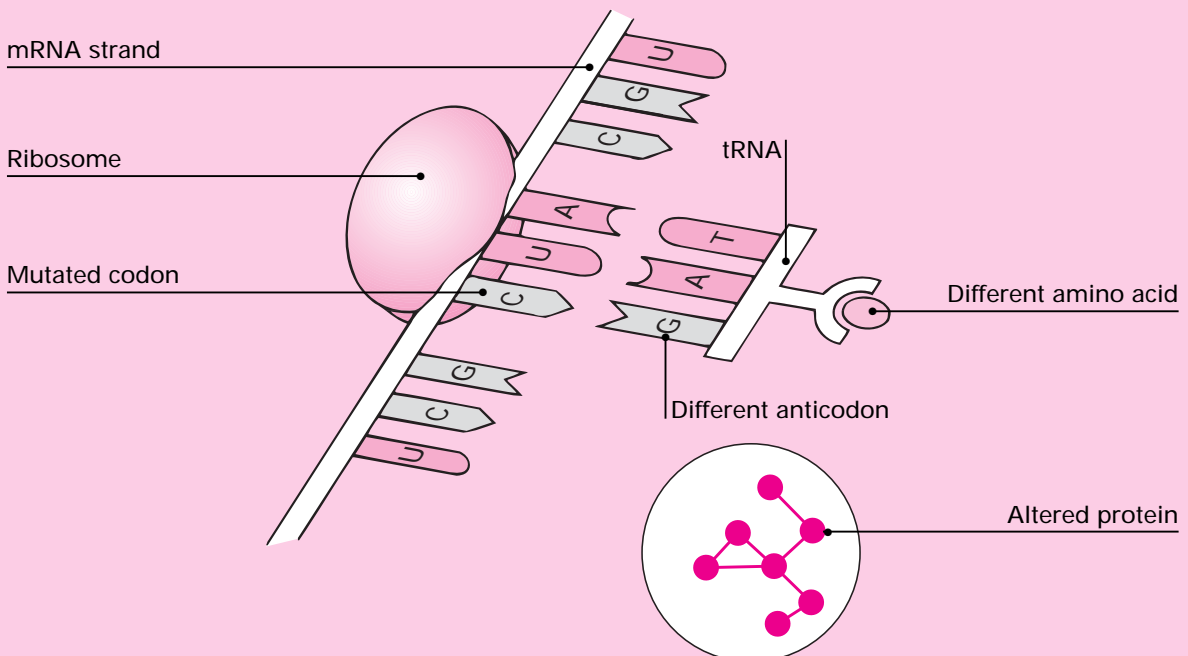
- various kinds of radiation, including nuclear radiation, X-rays, and ultraviolet (UV) light; and
- chemicals, such as the tars in tobacco smoke. Most mutations have no noticeable effect or are corrected by the cell's machinery after they arise. Some, however, are harmful, while a

tiny few produce a tangible benefit, making the body function better.

Types of mutation

A mutation that occurs in a reproductive cell may be passed on in the gametes (sex cells, such as ova and sperm). It will then be inherited by any offspring. A mutation that occurs in a non-reproductive cell will not be passed on to the offspring. It may, however, be passed on to other body cells that are produced from the mutant cell by cell division. Malignant tumors (cancers) are thought to arise from mutant cells in this way. There are two main types of mutation: gene mutations and chromosome mutations.

From codon to protein



Gene mutations

A small-scale change in the cell's genetic material is called a gene mutation. A single gene may be affected if a small amount of genetic material is:

a added; **b** lost; **c** rearranged; or **d** substituted.

The genetic code is based on groups of three bases called codons in the DNA. Small changes in the sequence of bases can have a major effect on the coded "words" or triple-base codons they form. This changes the structure and nature of the protein made by the gene. In the table (right) three-letter words have been used to represent the base triplets (codons) in DNA.

Mutating codons

Normal the old man saw the dog
(base triplets that code for the normal message)

Mutations

a the old man saw **ath** edo
(one base—"a"—has been added)

b the old **mns** awt hed ogt
(one base—"a"—in "man" has been lost)

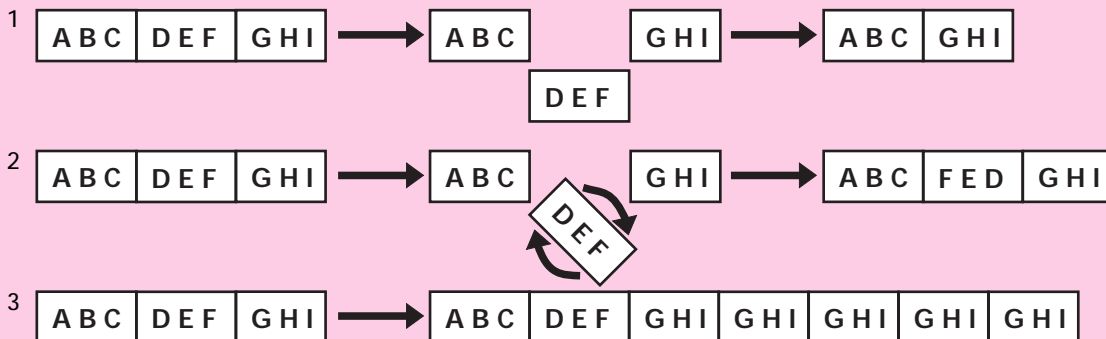
c the old man **was** the dog
(base triplet "saw" has been rearranged)

d the old man saw the **hog**
(base "d" in "dog" has been substituted by "h")

Chromosome mutations

A large-scale change in the cell's genetic material that affects several genes, or even an entire chromosome, is a chromosome mutation. Some of the

genes (represented below by blocks of letters) in the chromosome may be: **1** deleted; **2** rearranged; or **3** duplicated.



Chromosome mutations

These mutations are those that happen on a large scale, generally during cell division. They include deletion, duplication, inversions, and translocations.

Several genetic disorders, including Down syndrome, are caused by these changes.

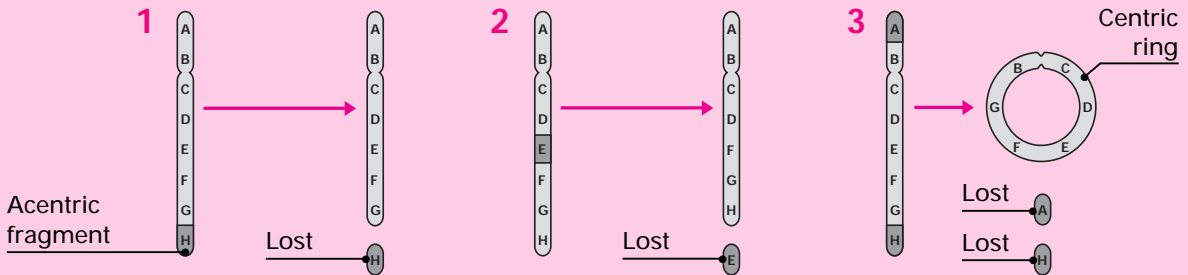
Origins of deletions

1 The chromosome tip breaks off, forming an acentric fragment (a fragment lacking a centromere). This fragment is lost, since it cannot attach to the spindle during nuclear division.

2 Two breaks occur along the

chromosome, a fragment is lost, and the broken ends rejoin.

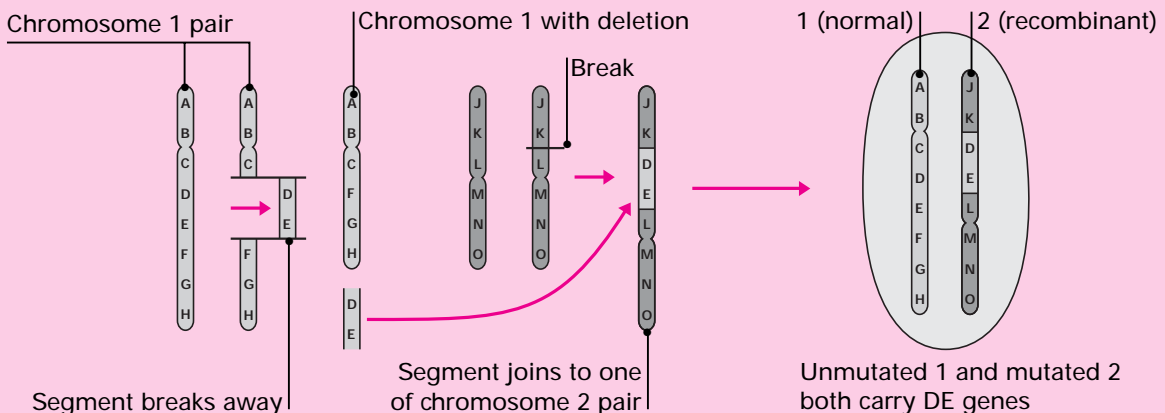
3 Both ends of the chromosome break off and are lost, and the broken ends rejoin forming a ring-shaped structure (a centric ring).



Origins of duplications

A chromosome break: These can occur before or during meiosis. A segment breaks from chromosome 1 and joins to

chromosome 2. The mutated chromosome 2 carries a duplication of an unmutated chromosome 1 into the daughter cell.



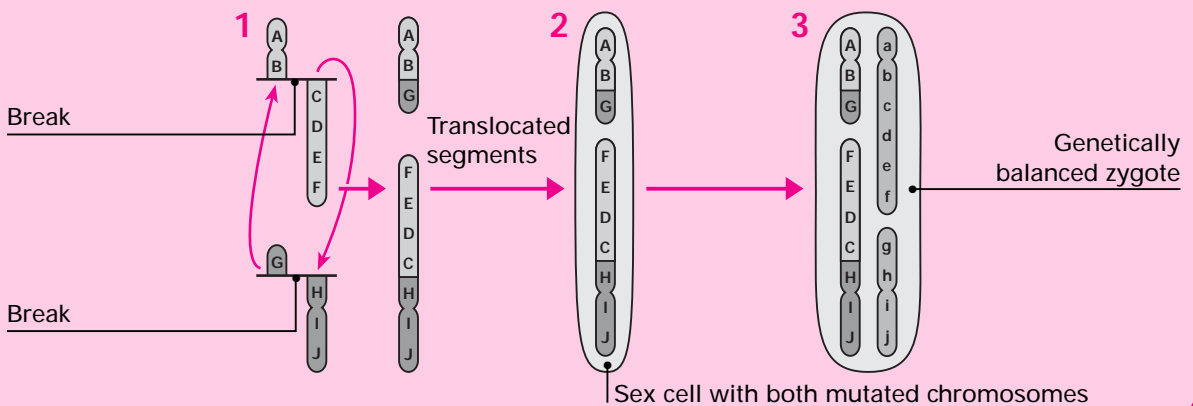
Reciprocal translocation

This involves segments simply changing places and no chromosomal material being lost. About one in 625 persons carries a reciprocal translocation. The process is as follows:

- 1 The acentric fragments from two non-paired chromosomes swap places.
- 2 On completion of meiosis, a sex cell

containing both mutated chromosomes still has the full complement of genes.

- 3 The sex cell can fuse with a normal sex cell to produce a genetically balanced zygote (the cell formed by the union of two gametes or sex cells), although chromosome pairs do not share the same genes.

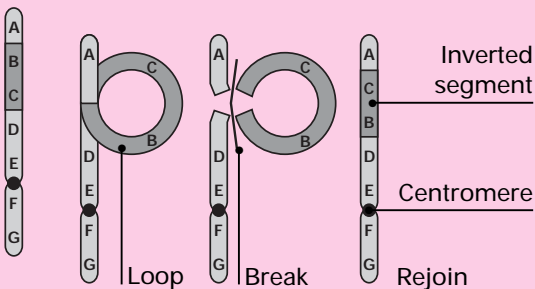


Origin of inversions

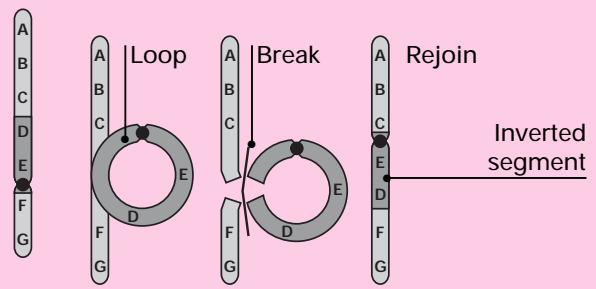
This occurs when a chromosome (segment BC) is looped on itself. Two breaks occur, and the segment BC rotates and reattaches. The gene order in the inverted segment is reversed.

Inversions that do not involve the centromere are called paracentric; those that include it are termed pericentric.

Paracentric inversion



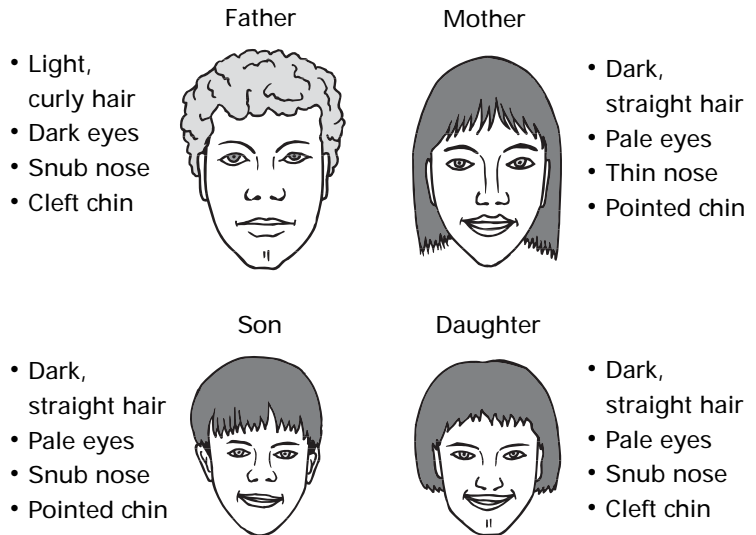
Pericentric inversion



Everyone is different. Human beings, like other organisms, show enormous variation in their appearance: we look different, have different personalities, and behave as individuals. All of us, however, have certain features, or characters, that we share with one or both of our parents. For example, you might have curly brown hair like your mother, and a dimpled chin like your father. Such characters have been transmitted from our parents to ourselves, and they are present from birth. The process by which characters are transmitted from parents to their offspring is called heredity. These characters are described as inherited characters. The units of inheritance are genes.

Inheritance of facial characters

- The most obvious inherited characters are usually facial ones, such as hair color, eye color, shape of the nose or mouth.
- The inheritance of facial characters can often be traced back over several generations of ancestors, for example by looking at old family photographs.



Acquired characters

- Not all characters are inherited. Some are not present at birth, but are acquired during our lives.
- Examples of acquired characters are the ability to skateboard, to speak a foreign language, or the loss of a finger in an accident.
- Acquired characters cannot be passed on to children.

Types of variation

Most characters vary either continuously or discontinuously.

Discontinuous variation

In this case a character, such as tongue rolling, shows two or more distinct and separate forms.

This is an inherited character, and an example of discontinuous variation. You can either do it, or you cannot. There is no intermediate state.

Tongue rolling



Height variation



Continuous variation

- Characters such as height and weight vary within a graded range of values.
- Individuals can fall anywhere between two extremes: two individuals can be very different, or differ only slightly, in respect of the same character.
- The majority of individuals tend to fall in the middle of the range.

Importance of mutations

Somatic mutations

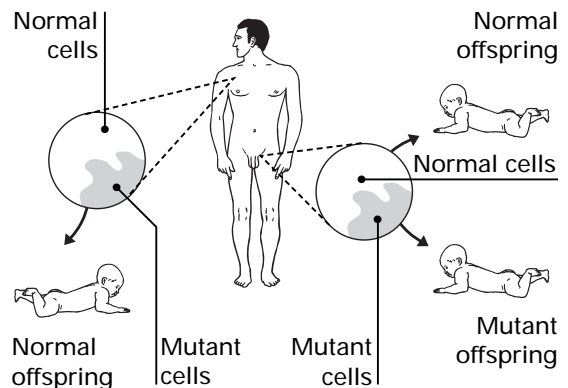
- These mutations occur in body cells and are transmitted only to cells that arise from divisions of the mutant cell(s).
- They can result in a subset of cells that are noticeably different in some way. This is known as a mosaic.
- They are not transmitted to offspring.

Germline mutations

- These arise in germ cells that give rise to gametes (sex cell).
- If the mutation enters a gamete, then it is transmitted to the person's offspring.

Somatic tissue

Germline tissue



Alleles

Genes for a particular feature occur in pairs: one gene on each chromosome of a homologous pair. These paired genes are called alleles.

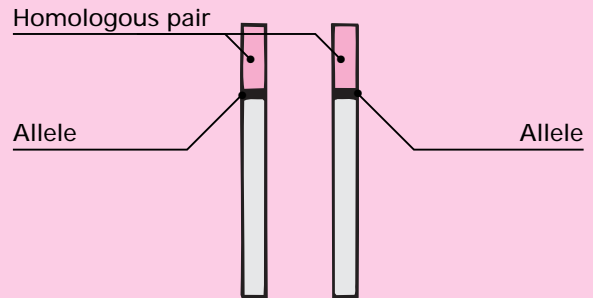
Homozygous alleles

When alleles are identical (they have the same DNA sequence), the individual is said to be homozygous for that gene. For example, both alleles might be for brown eyes (B). Homozygous means "same zygote." That is to say that every offspring produced by this individual will have at least one gene copy of B.

Heterozygous alleles

If the paired genes consist of different alleles, the individual is said to be heterozygous. For example, one allele might be for brown eyes (B) and the other for blue eyes (b). Heterozygous individuals produce two types of

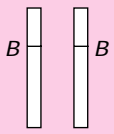
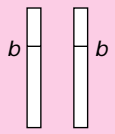
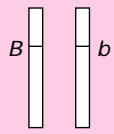
Paired genes on chromosomes



offspring, one with the B gene, the other carrying the b gene.

Dominant and recessive alleles

One allele may be dominant: its character (for example, brown eye color) is expressed in preference to the character of the other allele (for example, blue eye color). The "weaker" allele is called recessive.

	Homozygous		Heterozygous
Alleles			
Genotype	BB	bb	Bb
Phenotype	brown eyes	blue eyes	brown eyes

Simple inheritance

An inheritable character is determined by the action of a pair of alleles of a single gene, one of which is dominant and the other recessive. This pattern is called monohybrid or single-factor inheritance.

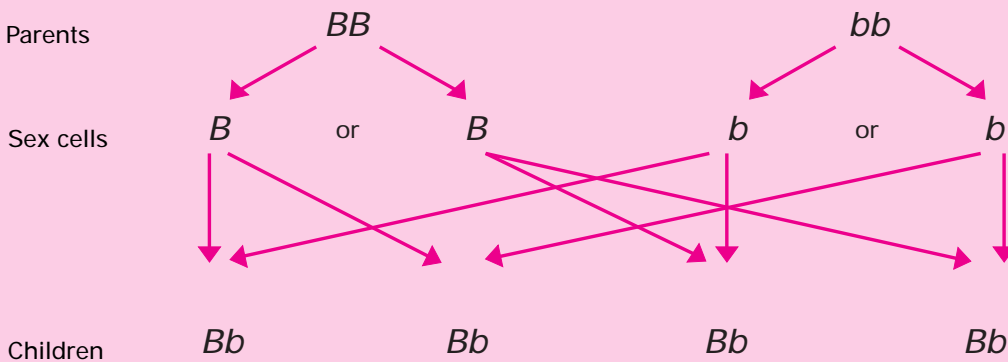
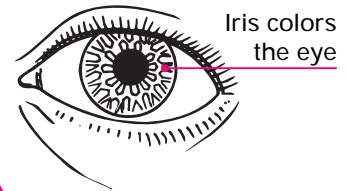
Unfortunately, very few human characters are inherited in such a simple manner. One classic example, eye color, is inherited simply, although its inheritance is not quite as straightforward as depicted opposite.

Inheritance of eye color

Homozygous parents

The allele for brown eyes (B) is dominant to that for blue eyes (b). If a homozygous man has brown eyes (genotype BB) and has children with a woman who is homozygous for blue eyes (genotype bb), each child will be heterozygous (genotype Bb) and have the father's eye color. Their mother's recessive gene will not be expressed.

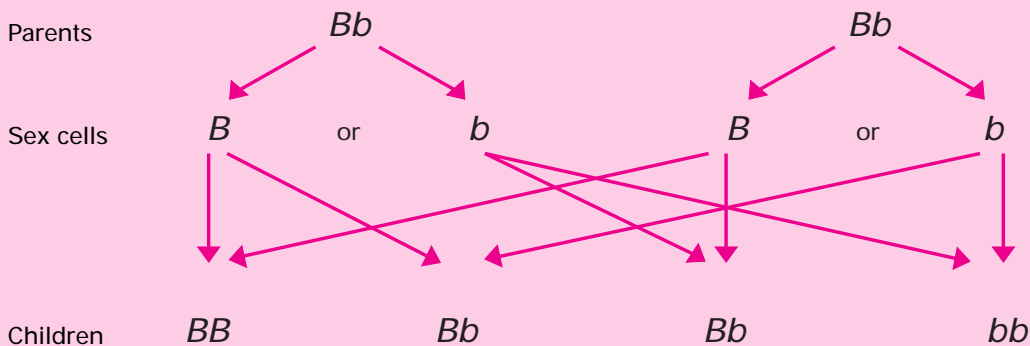
Eye color



Heterozygous parents

If a heterozygous (Bb) person has a child with a heterozygous (Bb) partner, three out of four children from this partnership would be expected to be brown-eyed. Of these, one would be homozygous (BB) and two heterozygous

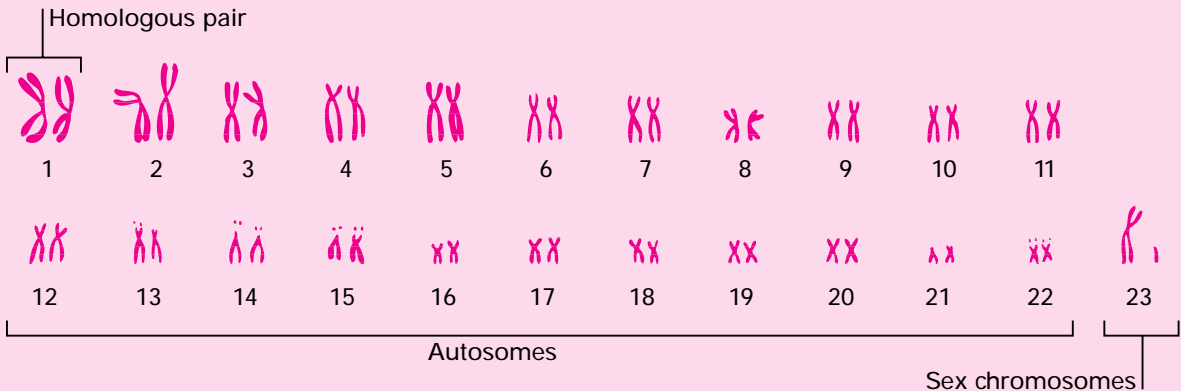
(Bb). The recessive allele (b) would be expressed only if one of the children were homozygous recessive (bb). The probability of the couple having a blue-eyed child would therefore be one in four.



Autosomes and sex chromosomes


Of the 23 homologous pairs of chromosomes, 22 pairs are called autosomes, since they are the same as each other. The 23rd pair is not always

the same and this determines the sex of the individual. The female sex chromosomes are the same, but the male ones, shown here, are not.




Sex chromosomes

One of the homologous chromosome pairs is responsible for determining the sex of an individual. The sex chromosomes exist in two forms, X and Y, so-called because of their characteristic shape during cell division. The difference between the sexes is that males provide only genetic material in their sex cells, while female ova also contain nutrients.



1 Female sex chromosomes

Female sex chromosomes are both X, giving the individual the genetic constitution (genotype) XX.



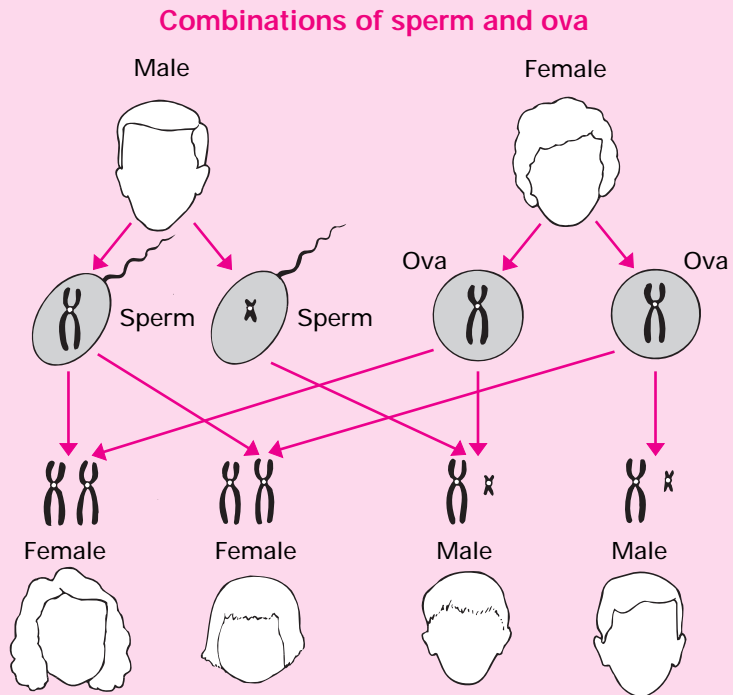
2 Male sex chromosomes

Males have one X chromosome and one smaller Y chromosome, giving the individual the genotype XY.

How sex is determined

1 Males are heterogametic. That means they produce gametes (sex cells) which contain with equal probability either an X or a Y chromosome. A female is homogametic. All her ova always carry an X chromosome.

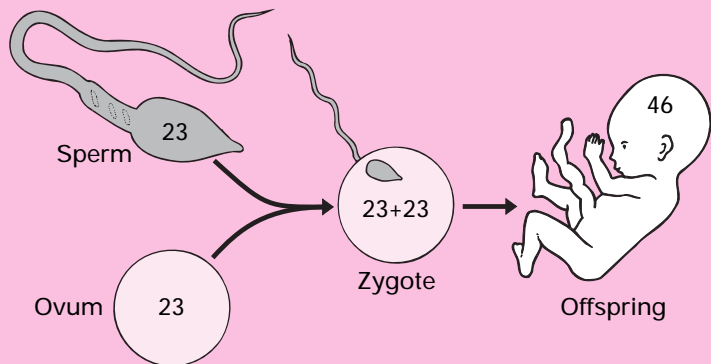
2 When a sperm and ovum fuse at fertilization, the sex of the resulting child is determined by the type of sex chromosome passed on in the father's sperm. There is an equal probability that offspring will be female or male.



Inheriting 46 chromosomes

One member of each pair of homologous chromosomes is inherited from the mother and the other from the father. A sperm and ovum each possesses only 23 chromosomes (the so-called haploid number). This ensures that when the sperm and the ovum fuse at fertilization, the offspring (zygote) has the normal human complement of 46 chromosomes (the diploid number) in each cell.

Fertilization



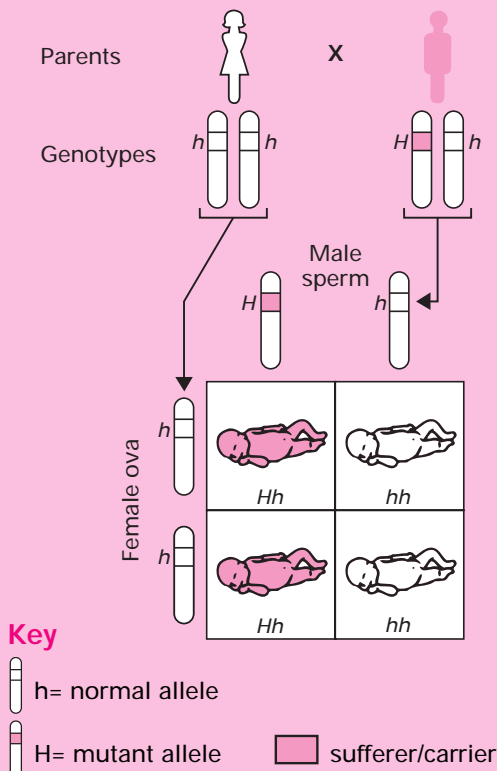
Inherited diseases

Diseases or conditions that are inherited are called genetic disorders. Some of the most common of these are caused by gene mutations (small-scale alterations in the cell's genetic material). About 20 percent of the 50,000 human genes may show variation (that is, they have two or more alleles). Much of this

variation probably does not affect the health or survival of the individual. Each person is probably a carrier of half a dozen recessive alleles for a severe disease. However, these alleles are only expressed if an individual is homozygous (has identical paired alleles) for the disease.

Dominant diseases

The children of a person with a dominant genetic disease on an autosomal chromosome have a two in four (50%) chance of inheriting it.



Pattern of inheritance

- An individual needs to inherit only a single mutant allele to suffer from an autosomal dominant condition.
- In such heterozygous individuals, the other, normal allele is either inadequate to meet the body's needs, or its function is blocked completely.
- In homozygous sufferers (who are rare), both alleles are defective; the disease can be more severe, or is lethal at an earlier age.

Characteristics of genetic disorders

- All affected individuals have at least one affected parent.
- Both males and females are equally likely to inherit and transmit the disease.
- All carriers also suffer from the disease.
- The disease will not appear among the descendants of unaffected parents.

Some autosomal dominant diseases

- **Familial hypercholesterolemia:** elevated levels of blood cholesterol leading to clogging of the arteries and premature death from heart attack.
- **Huntington disease:** progressive nervous degeneration causing muscular incoordination and dementia.
- **Li-Fraumeni syndrome:** causes cancers of multiple organs and tissues, including breast and brain tumors.
- **Marfan syndrome:** long limbs with loose joints, plus defects of the heart and arteries.
- **Neurofibromatosis:** defective nerves, bones, muscles and skin, with pigmented spots.
- **Retinoblastoma:** tumors of one or both retinas of the eyes.

Recessive diseases: cystic fibrosis

This gene mutation affects the mucous glands of the body, causing them to produce mucus (thick, slimy fluid) that is thicker than normal.

Effect on the pancreas

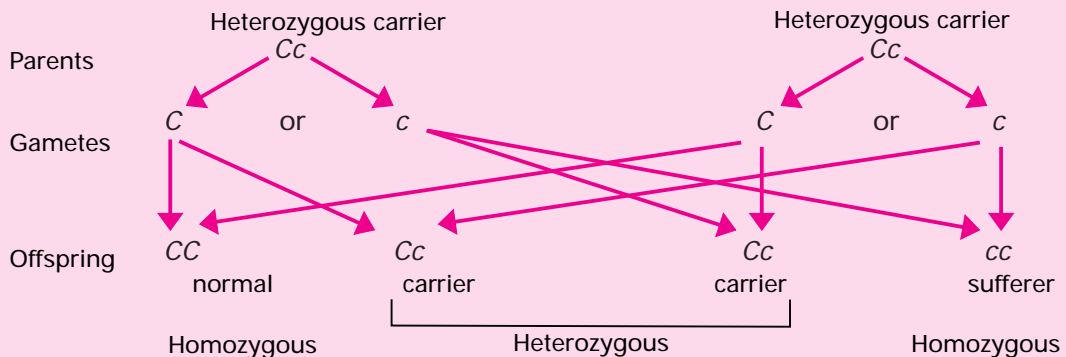
The thick mucus tends to block ducts in the pancreas, a glandlike organ that produces hormones and digestive enzymes. The blockages cause damage to pancreatic tissue and poor digestion of food in the small intestine.

Effect on the lungs

Breathing and gas exchange are impaired and infections such as pneumonia are more likely.

Genotype

Cystic fibrosis is caused by a recessive allele. Heterozygous individuals (Cc), although carriers, will be healthy because the normal allele is dominant. Homozygous individuals (cc) will actually have the disease.



Chromosome mutations

There are several conditions that can afflict humans in which an incorrect number of chromosomes is inherited by offspring. These conditions are caused by a mistake during meiosis—the cell division that leads to the formation of the gametes (sex cells), ova, or sperm.

Having an abnormal chromosome number is called aneuploidy, and a person or organism so affected is termed an aneuploid. The most common forms of aneuploidy are Turner's syndrome (lost chromosome) and Down syndrome (gained chromosome).


Down syndrome

This condition is caused by an extra chromosome in the 21st pair, so that the individual has 47 chromosomes instead of the normal 46. Although the extra chromosome can come from either parent, the risk of having an affected child does rise with the age of the mother. For women in their twenties, the figure is about one in 2,000; the risk rises with age, reaching more than one in 50 for women over 45.

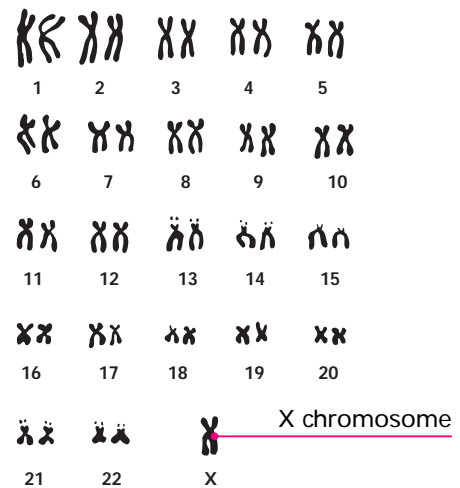
Turner's syndrome

In Turner's syndrome, the individual has a single X chromosome and lacks a second sex chromosome. The individual's sexual genotype (genetic constitution) is XO. Normally, a person is either XX (female) or XY (male). The condition results in certain characteristic physical features. The person is recognizably female in appearance but has incomplete sexual development and is infertile.

Down syndrome



Turner's syndrome



Klinefelter's syndrome

This is another example of aneuploidy in humans. Sufferers have the XXY combination of sex chromosomes, having received an extra X from either parent. Affected individuals are male and sterile, with tall, slightly feminine stature, and mildly impaired mental abilities. It occurs in about one in 1,000 male births.

Klinefelter's syndrome (XXY)

Low IQ

No male-pattern baldness

No beard

Tall

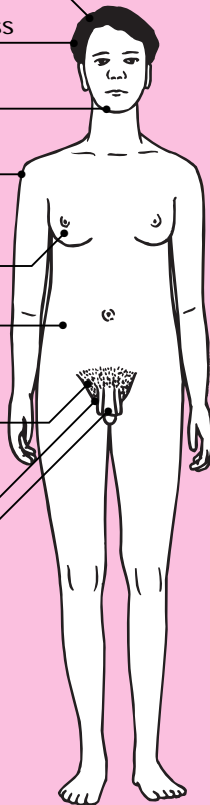
Breast development

Feminine physique

Female-pattern pubic hair

Wasting away of testicles

Sterile


**Chromosome 18 deletion**

The deletion of half of the long arm of chromosome 18 causes slow growth and impaired mental ability. There are also characteristic facial features, notably a downturned mouth with no midline indentation ("carp mouth"), and abnormally shaped ears.

Chromosome 18 deletion

Abnormal ears

"Carp" mouth

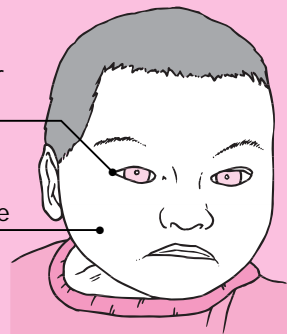
**Cat-cry syndrome**

This disorder is linked to a deletion of the short arm of chromosome 5. Newborn affected individuals typically have a round face with wide-set eyes and low-set ears. Growth is slow. They have a high-pitched cry, resembling that of a kitten when newborn.

Newborn baby with cat-cry syndrome

Wide-set eyes and fold in corner of each eye

Moon-shaped face



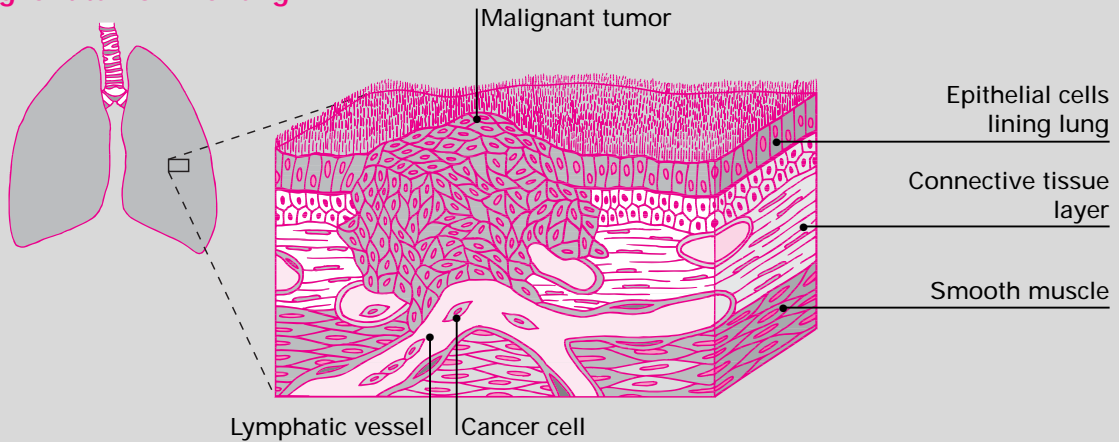
Cancer

Cancer is fundamentally a genetic disease, resulting from an accumulation of genetic defects. These defects disrupt the normal mechanisms that control cell growth and its proliferation, so that eventually the affected cell begins to divide uncontrollably and becomes cancerous.

Essential features of cancer cells:

- Divide in an uncontrolled way to form a growing malignant tumor.
- Lose the specialized features of surrounding normal tissue cells.
- Spread to adjacent tissues and to distant sites in the body (a process called metastasis).

Malignant tumor in a lung

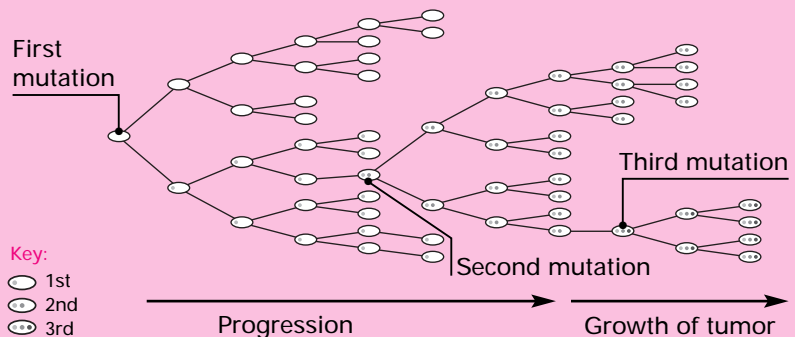


Lineage of a tumor

In this example, three mutations are required to transform a normal cell into a cancer cell (but this number varies depending on the type of cancer). With each successive mutational event—which may be years apart—the cell line becomes more and more abnormal. One cell carrying the third mutation is transformed

into a cancer cell, and its progeny form a tumor. Hence, all the numerous (perhaps billions) of cells

in a tumor are the descendants of a single cell, and represent a clone of cancer cells.



Colon cancer

The development of colon cancer in humans occurs in a series of steps. Each step involves a specific mutation in epithelial cells lining the large intestine (colon and rectum) and is characterized by changes in the appearance and behavior of the cells.

Sequence of events

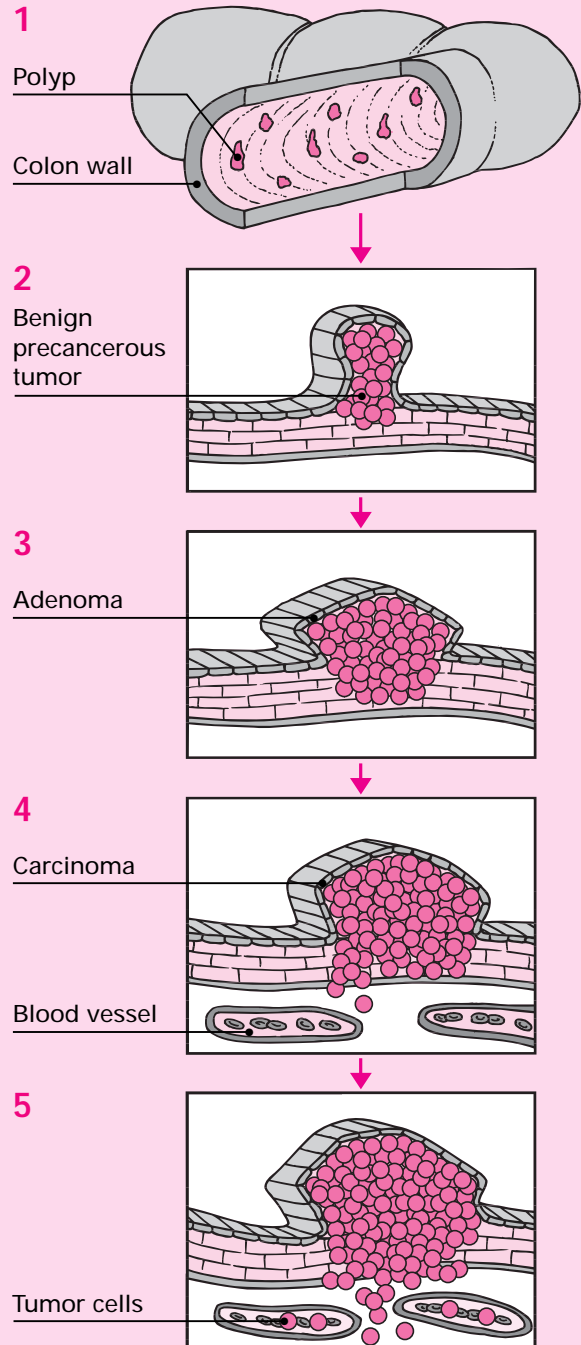
1 A mutation inactivates one of the tumor suppressor genes. This leads to the appearance of small growths (polyps) on the colon wall.

2 In one of the cells of a polyp there is a mutation producing an oncogene. (Oncogenes cause cancer.) This encodes a cancer-causing oncoprotein—an abnormal signal protein that is permanently “switched on.” The polyp cell gives rise to a small benign (harmless) precancerous tumor.

3 In a precancerous tumor cell, a mutation occurs that turns off another tumor suppressor gene. The affected cell grows more rapidly than others, and produces a larger, although still harmless, tumor (adenoma).

4 A mutation causes yet another tumor suppressor gene to switch off in a cell of the adenoma, resulting in a malignant cancer (carcinoma), which invades neighboring tissues.

5 Further genetic changes enable tumor cells to leave the original site and spread elsewhere via blood vessels—the process called metastasis.



Gene mapping

1 Creation of a DNA library

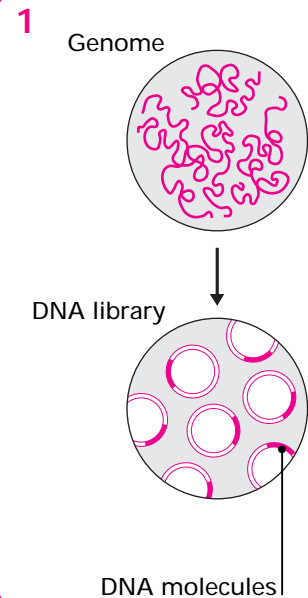
The genome (complete set of genes) of an organism is cloned to create a DNA library. This is a collection of recombinant DNA (deoxyribonucleic acid) molecules, each containing part of the original DNA.

2 Chromosome walking

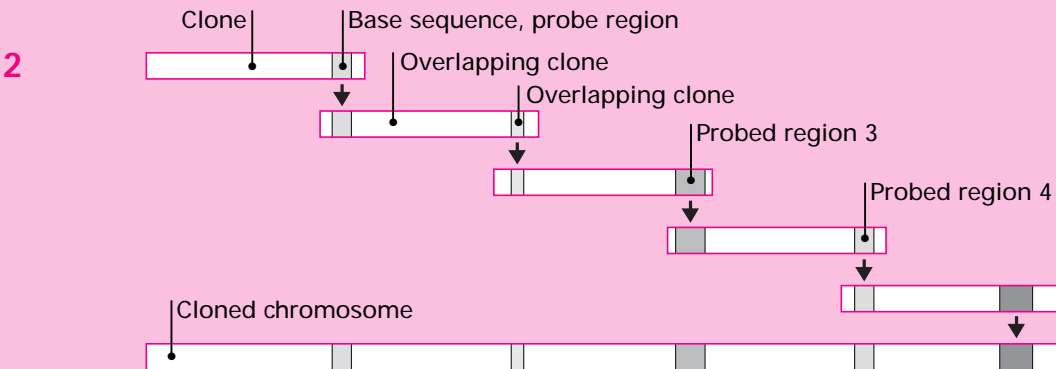
The base sequence of a region at the end of one clone is determined. This is used as a probe to find an overlapping clone. A region at the other end of this clone can then be sequenced and used as a probe to find the next clone. This can be continued until a whole chromosome is covered.

3 The physical map

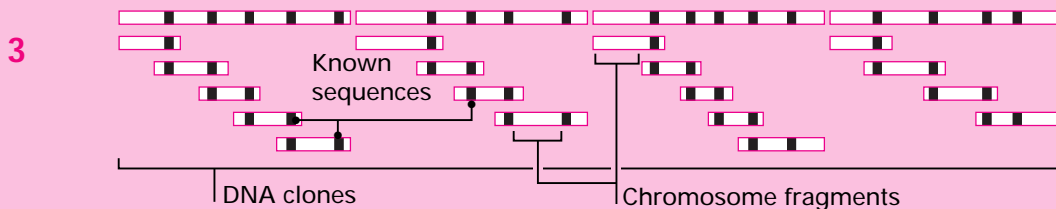
When a chromosome has been “walked,” a collection of ordered, overlapping clones has been created. The regions of known sequences comprise the physical map. The lengths of the rest of the chromosome fragments can then be measured.



Chromosome walking



The physical map



DNA fingerprinting

DNA fingerprinting (or genetic fingerprinting) is an example of the use of sophisticated biochemical techniques in the analysis of genetic material.

The uniqueness of genetic material

An individual's genetic material is unique to that person. The exception is in the case of identical twins (two individuals formed from a single fertilized egg). Their genetic material

is effectively identical, although somatic mutations during development make them look slightly different.

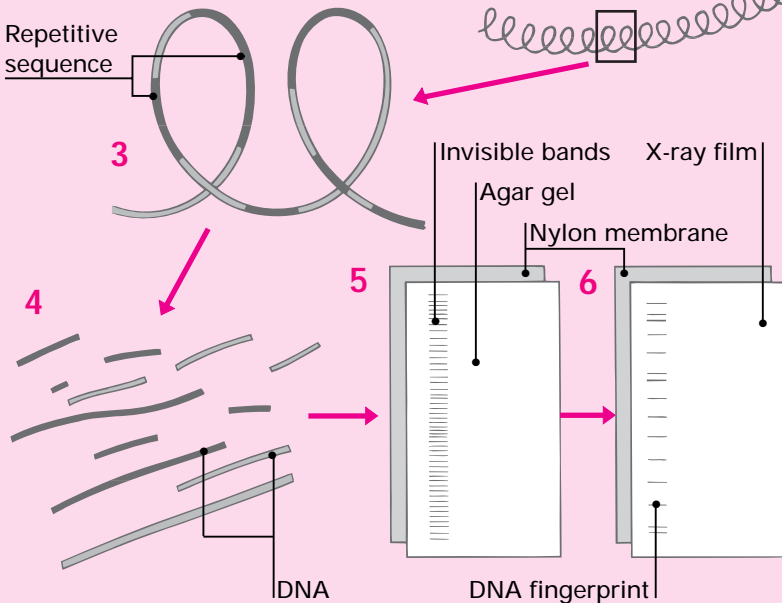
The hypervariability of DNA

Part of the DNA of each individual is hypervariable (it varies greatly between unrelated individuals). Such regions contain repetitive sequences. The number of repetitions and their exact location are unique to an individual.

Producing a DNA fingerprint

1–2 Each cell has a nucleus, which contains the DNA. This is carefully extracted.

3 The repetitive sequences are cut from the DNA using specific enzymes that act as chemical "scissors."



4–5 The resulting DNA fragments are separated into transparent bands in an agar gel by a process called electrophoresis. The bands that represent the hypervariable regions need to be selected.

The bands are made visible and selected by transferring the pattern to a nylon membrane and then adding a radioactive DNA probe that binds to the hypervariable regions. **6** X-ray film is placed alongside the membrane. The unique pattern of bands known as the DNA fingerprint appears on the developed film.

Analysis

DNA fingerprints are used chiefly by police forensic scientists to show that a person has left cells on an object or at a crime scene.

Gene therapy

Gene therapy involves inserting a healthy gene into a human body to replace or augment the functioning of a faulty gene. This technique, which is still in its infancy, promises to be particularly useful for treating inherited diseases involving gene mutations such as cystic

fibrosis, hemophilia, and thalassemia. However, it remains controversial.

Replacing faulty genes

One of the major problems in gene therapy is how to place new genes only into the cells that need them. Three methods are currently being developed.

Method of replacement	Diseases treated	Method of application
Copies of the healthy gene are applied directly to the surface of the affected cells, so that they take up the new gene. No operation is required.	<ul style="list-style-type: none"> • Cystic fibrosis (in which cells produce mucus that is thicker than normal). 	<ul style="list-style-type: none"> • Aerosol spray is used to deliver the new DNA to diseased lung tissue.
Diseased cells are removed from the body, copies of the healthy gene inserted into them, and the cells are then returned to the correct place in the body.	<ul style="list-style-type: none"> • Adenosine deaminase (ADA) deficiency (in which the gene producing the ADA enzyme is defective, preventing bone marrow from producing healthy white blood cells to combat infections). 	<ul style="list-style-type: none"> • Some bone marrow is removed, including stem cells, which later develop into white blood cells; • the bone marrow, including stem cells, is treated with the new gene; and • the treated cells are returned to the body's bone marrow.
New genes are injected into the bloodstream. The genes are programmed to be activated only when they enter specific target cells that have special characteristics.	<ul style="list-style-type: none"> • Skin cancer (melanoma). 	<ul style="list-style-type: none"> • Genes that cause cancerous cells to self-destruct are injected. • Melanoma cells contain a region of DNA, called a promoter, that switches on the self-destruct genes.

Using viruses in gene therapy

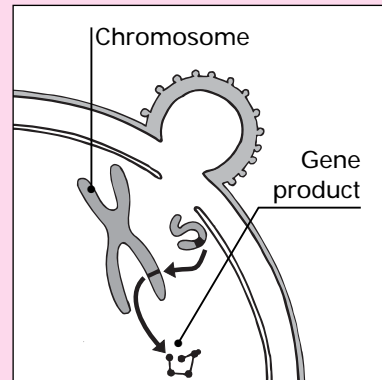
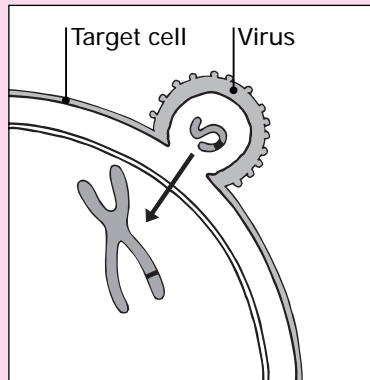
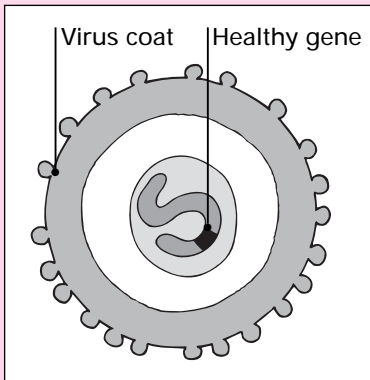
Once a healthy human gene has been isolated, placing it in the right cells is difficult enough, but it must also be inserted in the correct position within the rest of the cell's DNA so it can correct the problem.

Both of these difficulties can, in some cases, be overcome with the use of a virus (a piece of parasitic DNA). Viruses

are bits of DNA that cannot replicate themselves. Instead they insert themselves into the DNA of cells and harness the cell's machinery to make copies of themselves. Specially engineered viruses can be used as vectors (carriers) to take a therapeutic gene into a specific cell and position it on the right chromosome.

How a virus delivers a gene to the DNA

A virus is a strand of DNA (or possibly RNA) surrounded by a protein coat. The proteins protect the DNA and help it enter a cell.



1 The virus is encouraged to take up a copy of the healthy gene. The virus's own genetic material is modified in such a way that the virus cannot multiply and harm the target cells into which it is introduced.

2 The virus is delivered to the patient's target cells by any of the three methods described opposite. Once the virus reaches a target cell, it readily attaches itself to the cell membrane and empties the genetic material into the cell.

3 The healthy gene is then incorporated into the cell's DNA and the cell begins to manufacture the gene product that treats the patient's condition.

Adipose tissue Connective tissue containing numerous fat cells.

Adrenal glands (*or* Suprarenal glands) Endocrine glands located on each kidney. The cortex and medulla produce a range of hormones.

Afferent Directed toward a central organ or part of the body.

Alimentary canal (*or* Gastrointestinal tract *or* Gut) The digestive tract: a tube starting at the mouth and ending at the anus.

Anus The lower end of the rectum, forming the outlet of the alimentary canal.

Aorta The largest artery, arising from the left ventricle of the heart.

Appendix (*or* Vermiform appendix) A short, wormlike tube opening into the cecum but closed at the other end. It contains lymphoid tissue, which is involved in immunity.

Arteriole A small artery supplying blood from a main artery to a capillary.

Artery A blood vessel transporting blood from the heart to elsewhere in the body.

Atrioventricular valve (*or* AV valve) A valve between a ventricle and an atrium. The right atrioventricular valve (*or* tricuspid valve) has three cusps. The left atrioventricular

valve (mitral valve or bicuspid valve) has two cusps.

Auditory Relating to hearing.

Axillary Relating to the armpit.

Backbone See **Vertebral column**.

Basal ganglia Paired structures deep in the forebrain: they help coordinate and control willed muscle movements.

Basophil A type of white blood cell that is readily stained by basic dyes.

Biceps A muscle with two heads: biceps brachii in the upper arm and biceps femoris in the thigh.

Bile ducts Tiny tubes that carry bile (a liver secretion) from the liver to the duodenum.

Bladder A sac, especially the muscular bag inside the pelvis where urine collects before being expelled from the body.

Blood A sticky red fluid consisting of colorless plasma, red blood cells (Erythrocytes), white blood cells (Leukocytes), and platelets (thrombocytes).

Blood pressure The pressure of blood against blood-vessel walls, especially artery walls.

Bone The hard, dense connective tissue that forms the skeleton's components.

Bone marrow Soft red and yellow substances that fill cavities in bone.

Bowel See **Large intestine**.

Brain The body's chief control center, consisting of billions of interconnected nerve cells.

Brainstem A stalklike part of the brain, between the cerebrum and spinal cord. It contains the midbrain, pons, and medulla oblongata.

Breast A female breast consists mainly of a mammary (milk-secreting) gland embedded in fatty tissue.

Breastbone See **Sternum**.

Bronchiole A small subdivision of a bronchus, ending in tiny air sacs called alveoli.

Bronchus The main tubes branching from the lower end of the trachea and forming the main airways to and from the lungs (plural: bronchi).

Capillary The tiniest type of blood vessel, connecting an arteriole and a venule.

Cardiac Relating to the heart.

Cardiovascular Relating to the heart and blood circulatory system.

Cartilage Gristle: dense, white connective tissue cushioning bones.

Cecum The first part of the large intestine, forming a blind pouch.

Cell The basic unit of the body, usually comprising an outer membrane, cytoplasm, a nucleus, and organelles.

Central nervous system

(CNS) The brain and spinal cord.

Cerebellum The largest part of the hindbrain. It helps coordinate muscular movements.

Cerebral cortex The cerebrum's thin outer layer of gray matter.

Cerebral hemisphere Either of the two halves of the cerebrum.

Cerebrospinal fluid A clear fluid filling the brain's ventricles and surrounding the brain and spinal cord to protect them from injury.

Cerebrum The upper, major part of the brain, comprising cerebral hemispheres and diencephalon.

Cervix A neck, especially the neck of the uterus (womb) where it opens into the vagina.

Clavicle Either of the two collarbones.

Clitoris An erectile, pea-sized organ above the opening of the vagina; it is highly sensitive and is involved in female sexual response.

CNS See **Central nervous system**.

Coccyx Four fused vertebrae forming the "tail" of the backbone.

Collagen A fibrous protein that is a major constituent of connective tissue.

Colon The part of the large intestine between the cecum and rectum.

Connective tissue Tissue that supports, binds, or separates more specialized body tissues or acts as packing.

Corium See **Dermis**.

Cornea The transparent circular area at the front of the eye, which acts as a lens.

Coronary arteries Supply the heart muscle.

Corpuscles A term often used for red and white blood cells.

Cortex The outer layer of the brain.

Cranial nerves Twelve pairs of nerves linking the underside of the brain with parts of the head, neck, and thorax.

Cranium The part of the skull that contains the brain.

Cutaneous Relating to the skin.

Cuticle See **Epidermis**.

Deoxyribonucleic acid (DNA) A nucleic acid in the cell's chromosomes containing the cell's coded genetic instructions.

Dermis (or **Corium**) The layer of skin below the epidermis, containing nerves, blood vessels, glands, and hair follicles.

Diaphragm A muscular sheet used in breathing. It separates the thorax (chest) and abdomen (belly).

Digestion The chemical and mechanical breakdown of foods into substances that can be absorbed by the body.

DNA See **Deoxyribonucleic acid**.

Duodenum The upper part of the small intestine, where most chemical digestion takes place.

Ejaculation The discharging of semen from the penis.

Endocardium The membrane that lines the heart and the heart valves.

Endothelium The cell layer that lines the inside of the heart, blood vessels, and lymph vessels.

Enzymes Biological catalysts: proteins that speed up chemical reactions without undergoing change themselves.

Epidermis (or **Cuticle**) The skin's outer layer.

Epiglottis A cartilage flap behind the tongue that is closed during swallowing to stop food from entering the larynx.

Epiphysis See **Pineal gland**.

Epithelium The cell layer covering the body, and lining the alimentary canal and respiratory and urinary tracts.

Erythrocytes Red blood cells.

Esophagus (or **Gullet**) The muscular tube through which food travels between the pharynx and the stomach.

Fallopian tubes (or Uterine tubes or Oviducts) The tubes through which ova (eggs) travel from the ovaries to the uterus.

Femur The thigh bone: the long bone between the hip and the knee.

Follicle A small secreting cavity or sac. Ova (egg cells) develop in follicles in the female ovaries.

Forebrain The front part of the brain comprising diencephalon and telencephalon.

Gallbladder A pear-shaped bag where bile is stored, below the liver.

Gametes Sex cells: sperm in males; ova in females.

Gastric Of the stomach.

Gastrointestinal tract See **Alimentary canal**.

Genes Basic biological hereditary units, consisting of DNA, located on chromosomes.

Genitalia Sex organs.

Gland A structure that synthesizes and secretes a fluid.

Gonads Primary reproductive organs: the ovaries and testes.

Granulocytes White blood cells with cytoplasm that contains granules: basophils, eosinophils, and monocytes.

Gray matter The darker tissue of the brain and spinal cord mainly consisting of neurons' cell bodies and dendrites.

Gullet See **Esophagus**.

Gut See **Alimentary canal**.

Heart The hollow, muscular, fist-sized organ that pumps blood around the body.

Hemoglobin The iron-rich, oxygen-transporting pigment in red blood cells that gives them their color.

Hepatic Relating to the liver.

Hepatic portal vein See **Portal vein**.

Hindbrain Brain structures below the midbrain, comprising the pons, medulla oblongata, and cerebellum.

Hormones Chemical substances released into the blood by endocrine glands to influence organs or tissues in other parts of the body.

Hypophysis See **Pituitary gland**.

Hypothalamus A part of the brain with endocrine functions.

Ileum The last part of the small intestine.

Immune system The body's defense system against infective organisms or other foreign bodies. It includes the lymphatic system.

Involuntary muscle Muscle that is not under conscious control. See also **Smooth muscle**.

Jejunum The middle part of the small intestine.

Joint The junction between bones.

Karyotype The chromosome complement of a person or species: the genome.

Kidney A bean-shaped organ that filters wastes from blood to form urine.

Lactation Milk production by the mammary glands.

Large intestine (or Bowel) The lower part of the alimentary canal, comprising the cecum, colon, and rectum.

Larynx The cartilaginous voice box.

Leukocytes White blood cells. They attack invading microorganisms and help to combat injuries.

Ligament Fibrous tissue that connects bones.

Liver The largest organ in the body, it is involved in various metabolic processes.

Lungs The two organs of respiration, filling most of the chest cavity inside the rib cage and above the diaphragm.

Lymph A transparent fluid that leaks from blood vessels into tissue spaces.

Lymph gland See **Lymph node**.

Lymph node (or Lymph gland) One of the "knots" in the lymphatic system, which contain lymphocytes and macrophages that filter the lymph passing through the nodes.

Lymphatic system A network of lymph vessels and lymph nodes. Vessels collect lymph from body tissues and return it to the blood after harmful substances have been filtered out in the lymph nodes.

Mammary glands The milk-producing structures in the breast.

Medulla oblongata The lowest part of the brain stem, containing the vital centers that control heartbeat and respiration.

Meiosis A type of cell division that produces daughter cells (sperm and ova) each with half as many chromosomes as the parent cell.

Meninges Three protective membranes surrounding the brain and spinal cord.

Menopause When a woman ceases to have menstrual periods.

Menstruation Menstrual periods: the monthly flow of blood and uterine lining from the vagina of nonpregnant females of childbearing age.

Metabolism The array of continuous chemical changes that maintain life in the body.

Mitosis Ordinary cell division in which both daughter cells have as many chromosomes as the parent cell.

Mucous membranes The mucus-secreting linings of the

digestive, respiratory, reproductive, and urinary tracts.

Nasal Relating to the nose.

Nasal cavity The space inside the nose between the base of the skull and the roof of the mouth.

Nerve A bundle of nerve fibers (axons) that transmit impulses to (in the case of sensory nerves) or from (in the case of motor nerves) the central nervous system.

Nervous system The coordinated networks of neurons that control the body. It is divided into the central nervous system (brain and spinal cord), and the peripheral nervous system (the somatic and autonomic nervous systems).

Neuron (*or* Neurone) A nerve cell: the basic unit of the nervous system.

Neurone *See* **Neuron**.

Neurotransmitter A chemical released at nerve endings to transmit nerve impulses across synapses.

Nucleic acids Molecules that store genetic information.

Nucleus The control center of a cell, which contains coded genetic instructions.

Olfactory Relating to smell.

Optic Relating to the eye.

Organ A body part with different types of tissue that performs a particular task.

Organelles Tiny structures (miniorgans) in a cell's cytoplasm with particular tasks.

Ovaries Female sex organs that produce ova (eggs) and sex hormones.

Oviducts *See* **Fallopian tubes**.

Ovulation The release of a ripe egg from a female's ovary.

Ovum An egg; a female sex cell (plural: ova).

Palate The roof of the mouth.

Pancreas An abdominal organ that produces pancreatic juice and the hormones glucagon and insulin.

Parasympathetic nervous system The part of the autonomic nervous system that predominates when the body is at rest.

Parathyroid glands Four pea-sized endocrine glands on the thyroid gland. They produce parathyroid hormone, which controls blood calcium level.

Pelvis A bony basin formed by the two hip bones, the sacrum, and the coccyx.

Pericardium The double-layered membrane that encloses the heart and attaches it to the diaphragm and sternum.

Peristalsis Waves of muscular contraction that propel substances through passageways, such as the alimentary canal.

Phagocytes Types of leukocytes that engulf and destroy microorganisms and foreign bodies.

Pharynx The throat.

Pineal gland (or Epiphysis) An endocrine gland in the brain that secretes melatonin.

Pituitary gland (or Hypophysis) A three-lobed, pea-sized gland below the hypothalamus. It produces growth hormone, hormones that act on other endocrine glands, oxytocin, and ADH. It is often called the body's "master gland."

Plasma The fluid part of blood.

Pleura The membrane that covers the lungs (visceral pleura) and lines the chest wall (parietal pleura).

Plexus A network of nerves (or blood or lymph vessels).

Portal vein (or Hepatic portal vein) Drains blood from digestive organs to the liver.

Prostate gland A gland situated below the bladder in males. It produces a sperm-activating fluid that forms nearly a third of the semen's volume.

Pudendum See **Vulva**.

Pulmonary Relating to the lungs.

Receptor A structure, such as a sensory nerve ending, specialized to detect environmental stimuli.

Rectum The last part of the colon, where feces collects before leaving the body.

Reflex action The body's automatic response to a stimulus, such as blinking.

Renal Relating to the kidney.

Respiration 1) Breathing; 2) Taking in oxygen and giving out carbon dioxide; 3) Deriving energy from food with or without using oxygen.

Respiratory system In humans, the mouth, nose, pharynx, larynx, trachea, bronchi, bronchioles, alveoli, and lungs.

Ribonucleic acid (RNA) A nucleic acid concerned with protein synthesis.

Ribs Twelve pairs of bones that protect the chest cavity and assist breathing by moving up and out during inspiration and down and in during expiration.

Salivary glands The lingual, parotid, sublingual, and submandibular glands that produce saliva.

Serum Blood plasma that does not contain clotting factors but does contain antibodies.

Sinus A cavity, such as the channels draining venous blood from the brain.

Skeleton The bony framework that protects and supports the body's soft tissues.

Skin The body's waterproof covering; its largest organ, comprising two main layers: the epidermis and dermis.

Small intestine The alimentary canal between the stomach and large intestine, comprising the duodenum, jejunum, and ileum. Most digestion occurs here.

Smooth muscle (or Unstriated muscle or Involuntary muscle) Muscle without striped fibers that automatically operates internal organs such as the stomach, bladder, and blood vessels.

Sphincter A ring-shaped muscle that contracts to close an orifice.

Spinal cord The cable of nerve tissue running down inside the vertebral column (spine) and linking the brain with nerves supplying most of the body.

Spine See **Vertebral column**.

Sternum The breastbone.

Subcutaneous tissue The sheet of connective tissue below the dermis.

Suprarenal glands See **Adrenal glands**.

Suture An immovable fibrous joint between the skull bones.

Taste buds Tiny sensory organs of the tongue and palate, distinguishing salty, sweet, sour, and bitter tastes.

Teeth Bonelike structures in the jaws. Different types (incisors, canines, premolars, molars) are specialized to tear, crush, and/or grind food.

Tendons Bands of fibrous connective tissue joining muscles to bones.

Testis (*or* Testicle) One of a pair of primary male sex organs that manufacture sperm (plural: testes).

Thalamus A brain structure above the hypothalamus. It sends sensory impulses to the cerebral cortex, links sensations with emotions, and affects consciousness.

Thymus An endocrine gland located behind the sternum. It produces thymosin.

Thyroid An endocrine gland at the front of the neck, producing thyroid hormone.

Tissue A collection of similar cells that perform a particular task.

Trachea (*or* Windpipe) The tube between the larynx and the bronchi.

Tubule A tiny tube.

Tunica A tissue layer forming a coating. Blood vessels have three such layers (intima, media, adventitia).

Unstriated muscle *See* **Smooth muscle**.

Ureter The tube conveying urine from a kidney to the bladder.

Urethra The passage taking urine from the bladder to the body's exterior.

Urinary system The kidneys, ureters, bladder, and urethra.

Urine Liquid waste excreted by the kidneys.

Uterine tubes *See* **Fallopian tubes**.

Uterus (*or* Womb) A hollow muscular organ located above the bladder. Inside it, a fertilized ovum develops into a fetus.

Uvula A conical tag hanging from the back of the palate. It helps to keep food out of the nasal cavities.

Vagina The muscular passage between the vulva and cervix (neck of the uterus).

Vascular Relating to or richly supplied with vessels, especially blood vessels.

Vein A blood vessel that transports blood from capillaries back to the heart. Veins contain valves to prevent the backflow of blood.

Venous Relating to veins.

Ventricle A cavity: one of the two lower chambers of the heart.

Venule A small vein.

Vermiform appendix *See* **Appendix**.

Vertebra A bone of the vertebral column (plural: vertebrae).

Vertebral column (*or* Backbone *or* Spine) The column of vertebrae between the skull and the hip bones, supporting the body and shielding the spinal cord. It has five sections: cervical, thoracic, lumbar, sacral, and coccygeal.

Vestibule A space before a passage begins, as in the inner ear beyond the oval window, between the semicircular ducts and cochlea.

Vocal cords Two belts of tissue stretched across the larynx which produce sounds when air rushes past them.

Vulva (*or* Pudendum) The external female genitals.

White matter The paler tissue of the brain and spinal cord comprised mainly of myelin-sheathed nerve fibers.

Windpipe *See* **Trachea**.

Womb *See* **Uterus**.

There is a lot of useful information on the internet. There are also many sites that are fun to use. Remember that you may be able to get information on a particular topic by using a search engine such as Google (<http://www.google.com>). Some of the sites that are found in this way may be very useful, others not. Below is a selection of Web sites related to the material covered by this book. Most are illustrated, and they are mainly of the type that provides useful facts.

Facts On File, Inc. *takes no responsibility for the information contained within these Web sites. All the sites were accessible in January 2005.*

Access Excellence:

National Health Museum

Links to a range of resources in biology, biotechnology, and health issues.

<http://www.accessexcellence.org>

Ask a Biologist

Arizona State University staff answer email questions for students at grades K–12.

<http://askbiologist.asu.edu>

Biology Online

A source of biological information, suitable for homework, research projects, and general interest, with hundreds of biology Web site links.

<http://www.biology-online.org>

Cell and Molecular Biology Online

An information resource for cell and molecular biologists as well as geneticists.

<http://www.cellbio.com>

Health Sciences and Human Services Library

Provides links to selected Web sites about all aspects of life sciences that may be useful to both students and researchers.

[http://www.hshsl.umaryland.edu/
resources/lifesciences.html](http://www.hshsl.umaryland.edu/resources/lifesciences.html)

Human Genome Project

Education Resources

Identifies sequences of all the genes in human DNA, stores the information, and addresses ethical issues.

[http://www.ornl.gov/hgmis/education/
education.html](http://www.ornl.gov/hgmis/education/education.html)

Open Directory Project: Cell Biology

Comprehensive list of internet resources.

[http://dmoz.org/Science/Biology/
Cell_Biology/Education/](http://dmoz.org/Science/Biology/Cell_Biology/Education/)

Open Directory Project: Genetics

Comprehensive list of internet resources.

[http://dmoz.org/Science/Biology/
Genetics/](http://dmoz.org/Science/Biology/Genetics/)

The Biology Project

Structured tutorials on life sciences.

Particularly strong on cell biology, human biology, and molecular biology.

<http://www.biology.arizona.edu>

University of Texas: BioTech Life Sciences Resources and Reference Tools

The Dictionary and Science Resources are particularly useful.

<http://biotech.icmb.utexas.edu>

- A**
active transport 37, 40–41, 44
adenine 72, 75, 81
 DNA replication 78, 79
 protein synthesis 19, 46
adenosine triphosphate (ATP) 27, 37, 44, 45
 active transport 40, 41
 sodium-potassium pump 41, 42
adipocytes 12, 50, 51
alleles 66, 70–71
 genetic disorders 92
 inheritance 88–89
ameboid movement 15
amino acids 37
 active transport 40
 cell metabolism 36
 gene expression 77
 lysosomes 25
 mitochondria 27
 mutation 82
 protein synthesis 19, 46, 47, 74
anaphase 56, 57, 58, 59
apoptosis (cell death) 62–63
autolysis 24
- B**
base units 72
 DNA repair 80
 DNA replication 79
 gene expression 76, 77
 gene mapping 98
 mutation 83
 protein synthesis 19, 47, 75
basophil 23, 25
bone 34, 35, 50
bone marrow 60, 100
- C**
cancer 54, 64–65, 96–97
 gene therapy 100
 genetic disorders 93
 mutations 80, 82
cartilage 34, 50, 65
cell cycle 54, 55
cell death 62–63
cell division 52, 53, 54
 cancer 64, 96
 chromatin 22
 chromosomes 6, 67, 68
 DNA replication 78
 genetic disorders 94
 mitosis 56
 mutation 82, 84
 nucleus 23
 stem cells 60
cell (plasma) membrane 6, 10–11, 12, 36, 37
 active transport 40, 41
 ameboid movement 15
 cell structure 52
 centrioles 28
 cilia 32
 diffusion 38, 39
 endoplasmic reticulum 16, 17
 Golgi apparatus 20, 21
 lysosomes 25
 sodium-potassium pump 41, 42
 tight junctions 30
cellular respiration 27, 44–45
centrioles 6, 28, 52, 53, 56, 57, 58
centromeres 67, 68
cytoskeleton 14
 meiosis 58
 mitosis 56, 57
 mutation 84, 85
cholesterol 10, 36, 38, 41
 endoplasmic reticulum 17
 genetic disorders 93
chondrocytes 50
chromatids 56, 57, 58, 59, 67
chromosomes 6, 22, 66–69
 alleles 88
 cell death 62
 cell division 53, 55, 56–59
 gene mapping 98
 gene therapy 101
 genetic disorders 94, 95
 mutation 82, 83, 84, 85
 protein synthesis 19
 sex determination 90–91
cilia 28, 32–33
codons 19, 47, 76, 82, 83
collagen 34, 35, 51
connective tissue 50, 51
 cancer 65, 96
 extracellular matrix 34, crenation 39
cytokinesis 56, 57, 58, 59
cytoplasm 6, 12–13, 52
 cell death 62
 gene expression 76
 lysosome 24, 25
 mitochondria 26
 mitosis 57
 peroxisomes 29
 protein synthesis 36, 47
 ribosomes 18
cytosine 72, 75, 81
 DNA replication 78, 79
 protein synthesis 19, 46
cytoskeleton 12, 14–15, 52
 cell death 62
 cell membrane 31, 38
 mitosis 56

- D**
- diffusion 37, 38–39
 - active transport 40
 - cell communication 49
 - metabolism 37
 - osmosis 39
 - sodium-potassium pump 41, 42
 - digestive system 8, 11, 13, 51, 60
 - DNA 36, 37, 72–73
 - alleles 70
 - cancer 65
 - cell communication 49
 - cell division 53, 54, 55
 - cell structure 52
 - chromosomes 66, 68, 69
 - gene expression 76
 - gene mapping 98
 - gene therapy 100, 101
 - mitochondria 26, 69
 - mitosis 56
 - mutation 82
 - nucleus 6, 22
 - protein synthesis 19, 46, 74, 75
 - repair 80–81
 - replication 78–79, 80, 82
 - ribosomes 18
 - DNA fingerprinting 99
 - DNA polymerase 78, 79, 80, 81
 - dominance 70, 71, 88, 89
 - genetic disorders 92, 93
- E**
- ectoplasm 15
 - electrical potential 42–43
 - embryo 60, 61, 63
 - endocrine glands 48
 - endocytosis 24, 41
 - endoplasm 15
 - endoplasmic reticulum 6, 16–17, 36, 62
 - enzymes
 - cell death 62
 - cell division 54
 - cell membrane 38
 - cell metabolism 36, 37
 - chromosomes 66
 - DNA fingerprinting 99
 - DNA repair 80, 81
 - DNA replication 79
 - endoplasmic reticulum 17
 - gene expression 76
 - Golgi apparatus 20, 21
 - lysosomes 24, 25, 40
 - mitochondria 26
 - peroxisomes 29
 - protein synthesis 75
 - respiration 45
 - ribosomes 19
 - eosinophils 23, 24, 25, 60
 - epidermal cells 9
 - epithelial cells 9, 11, 50, 51
 - cancer 65, 96, 97
 - junctions 30, 31
 - erythrocytes 23, 50, 60
 - eukaryotes 36, 46
 - exocrine glands 13, 51
 - exocytosis 21, 25, 36, 37, 40
 - extracellular matrix 34, 38
- F**
- fertilization 58, 91
 - fibroblasts 35, 50, 51
 - flagella 28, 32–33
- G**
- gene expression 76–77
 - gene mapping 98
 - gene therapy 100–101
 - genes 52, 53
 - alleles 70, 71, 88
 - cell division 54
 - chromosomes 66, 68, 69
 - DNA repair 80, 81
 - genetic disorders 92, 93
 - inheritance 86
 - meiosis 58
 - mutation 82, 83
 - protein synthesis 74, 75
 - genetic disorders 84, 92–95, 96
 - genome 26, 98
 - genotype 71, 93
 - goblet cells 13, 33
 - Golgi apparatus 6, 20–21, 36, 37, 52
 - granulocytes 25
 - guanine 72, 75
 - DNA repair 81
 - DNA replication 78, 79
 - protein synthesis 19, 46
- H**
- heredity 86–89
 - hormones
 - active transport 40
 - cell communication 48, 49
 - cell metabolism 36
 - endocytosis 41
 - endoplasmic reticulum 17
 - extracellular matrix 34
- I**
- inclusions 12
 - inheritance 68, 86–89
 - alleles 70, 71
 - disorders 92, 100
 - mutation 82
 - interphase 52, 53

J

junctions 11, 30–31, 48

K

keratin 11, 31
Kreb's cycle 45

L

leukocytes 23, 50, 60
lipids (fats) 12, 17, 41
 cell membrane 10, 38
 Golgi apparatus 20
lymph nodes 35
lymph vessels 30, 65, 96
lymphocytes 23, 60
lysosomes 6, 24–25, 37
 cell metabolism 36, 37
 Golgi apparatus 20, 21
 phagocytosis 40

M

macrophages 60, 62
meiosis 53, 58–59, 94
messenger ribonucleic acid (mRNA) 18, 19, 36, 37
 gene expression 76, 77
 mutation 82
 protein synthesis 46, 47, 74, 75
 ribosomes 18
metabolism 36–37, 44
metaphase 56, 58, 59
metastasis 65, 96, 97
microfilaments 14, 15
microtubules 14, 28, 32, 56
microvilli 10
mitochondria 6, 26–27, 37, 45, 52, 69
mitosis 53, 54, 55, 56–57
monocytes 23
mucus 13, 32, 40, 93

muscle cells 6, 7, 9
 contraction 17, 43, 44
mutations 80, 82–84
 cancer 65, 96, 97
 chromosomes 82–85
 gene therapy 100
 genetic disorders 92–94
 inheritance 87
myofibrils 7, 27

N

nervous system 8, 63
neurons (nerve cells) 6, 50, 51
 action potential 43
 cell death 63
 connective tissue 35
 junctions 31
 life span 52
 sodium-potassium pump 41
neurotransmitters 34, 43, 48
neutrophils 23, 24, 25
nuclear envelope 22, 36
nuclear membrane 6, 52
 cell division 57, 58, 59
 endoplasmic reticulum 16
nucleic acids 18, 46, 76
nucleolus 22, 36, 37
nucleotides 72, 73
 cell division 55
 cell metabolism 36
 DNA repair 80
 DNA replication 79
 protein synthesis 46, 74, 75
nucleus 6, 22–23, 37
 cell death 62
 cell structure 52
 chromosomes 67, 68

cytoskeleton 14
DNA fingerprinting 99
gene expression 76
meiosis 58
mitosis 56
myofibrils 7
protein synthesis 19, 36, 46
stem cell transplants 61

O

oncogenes 97
organelles 6, 16–29
 cell structure 52
 centrioles 28
 cytoplasm 12
 endoplasmic reticulum 16
 eukaryotes 36
 Golgi apparatus 20
 mitochondria 26
 nucleus 23
 peroxisomes 29
 ribosomes 18
osmosis 39
osteocytes 50
ova (egg cells) 7
 cell division 53
 chromosomes 69
 genetic disorders 94
 meiosis 58
 mutation 82
 sex chromosomes 90, 91

P

passive transport 37
peroxisomes 29
phagocytes 24, 62
phagocytosis 24, 37, 40
phenotypes 71
pinocytosis 41

plasmodesmata 31
 platelets 60
 polypeptides 36, 37, 76, 77
 prokaryotes 12, 36
 prophase 56, 58
 protein synthesis 36, 46–47, 74–75
 cell division 54
 chromosomes 66
 endoplasmic reticulum 16, 17
 ribosomes 18, 19
 proteins 8
 active transport 40
 cell communication 49
 cell death 62
 cell division 54
 cell membrane 10, 11, 38
 cytoplasm 12
 cytoskeleton 14
 endocytosis 41
 extracellular matrix 34
 gene expression 77
 Golgi apparatus 20, 21
 junctions 30, 31
 mitochondria 27
 mutation 82, 83
 nucleus 22
 ribosomes 18
 pseudopodium 15

R

red blood cells 7, 23, 52
 reproduction 52, 58
 respiration 27, 44–45
 respiratory tract 13, 33
 ribonucleic acid (RNA),
 cell metabolism 36
 gene expression 76, 77
 nucleolus 22

protein synthesis 74, 75
 ribosomes 19
 ribosomal ribonucleic acid (rRNA) 18, 36, 77
 ribosomes 6, 18–19, 36, 37
 endoplasmic reticulum 16, 17
 gene expression 77
 mutation 82
 protein synthesis 46, 47, 75
 rough endoplasmic reticulum 16, 17, 37
 cell metabolism 36
 Golgi apparatus 20, 21
 protein synthesis 46
 ribosomes 18, 19

S

sex cells (gametes)
 cell division 52
 chromosomes 66, 91
 genetic disorders 94
 inheritance 87
 meiosis 58
 mutation 80, 82, 85
 sex chromosomes 69, 90–91, 94, 95
 skin 7, 9, 30, 35, 51
 cancer 65
 smooth endoplasmic reticulum 16, 17
 sodium-potassium pump 41, 42
 solute pump 40
 sperm 32
 cell division 53
 chromosomes 69
 genetic disorders 94
 meiosis 58
 mutation 82
 sex chromosomes 91

spindle (mitotic) 55, 56–59, 84
 squamous cells 51
 stem cells 60–61, 100
 stomach cells 7, 8
 synapses 31, 43

T

telophase 56, 57, 58, 59
 thymine 72, 75
 DNA repair 81
 DNA replication 78, 79
 gene expression 76
 protein synthesis 46
 tissues 8, 9, 34, 48, 51
 cancer 65, 96
 stem cells 60, 61
 transfer ribonucleic acid (tRNA) 19, 37
 cell metabolism 36
 gene expression 77
 mutation 82
 protein synthesis 47, 74

U

uracil 19, 46, 75, 76

V

vacuoles 6, 12
 vesicles 24, 25, 37
 active transport 40
 cell metabolism 36
 endoplasmic reticulum 17
 Golgi apparatus 20, 21

W

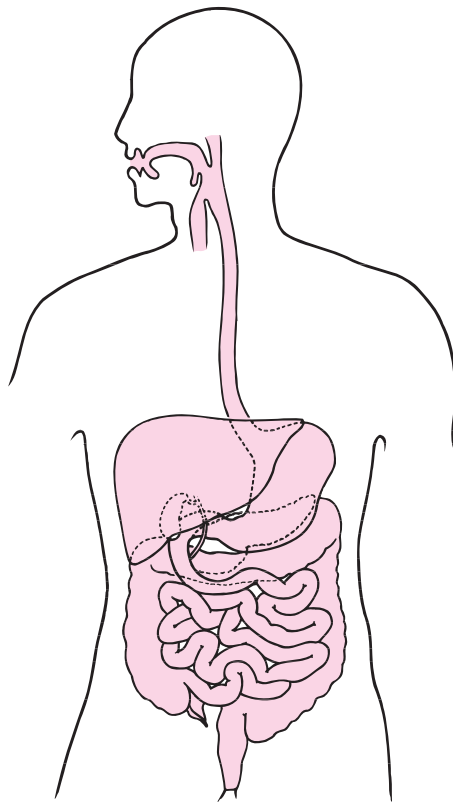
white blood cells 15, 23, 24, 40, 50, 100

Z

zygote 58, 85, 88, 91

THE FACTS ON FILE
ILLUSTRATED GUIDE TO
THE HUMAN BODY

DIGESTIVE SYSTEM



THE DIAGRAM GROUP

The Facts On File Illustrated Guide to the Human Body: Digestive System

Copyright © 2005 The Diagram Group

Editorial: Lionel Bender, David Harding, Denis Kennedy,
Gordon Lee, Jamie Stokes, Barbara Taylor

Scientific consultant: Stephen Rudd

Design: Anthony Atherton, Richard Hummerstone,
Lee Lawrence, Kim Richardson, Ben White

Illustration: Pavel Kostal, Kathleen McDougall

Picture research: Neil McKenna

Indexer: Jane Parker

All rights reserved. No part of this book may be reproduced or utilized in any form or by any means, electronic or mechanical, including photocopying, recording, or by any information storage or retrieval systems, without permission in writing from the publisher. For information contact:

Facts On File, Inc.
132 West 31st Street
New York NY 10001

Library of Congress Cataloging-in-Publication Data

The Facts On File illustrated guide to the human body. Digestive system / The Diagram Group.

p. cm.

Includes index.

ISBN 0-8160-5984-5 (hc : alk. paper)

1. Gastrointestinal system—Juvenile literature. I. Title: Digestive system. II. Diagram Group.

QP145.F23 2005

612.3—dc22

2004022926

Set ISBN: 0-8160-5979-9

Facts On File books are available at special discounts when purchased in bulk quantities for businesses, associations, institutions, or sales promotions. Please call our Special Sales Department in New York at 212/967-8800 or 800/322-8755.

You can find Facts On File on the World Wide Web at
<http://www.factsonfile.com>

Printed in the United States of America

EB Diagram 10 9 8 7 6 5 4 3 2 1

This book is printed on acid-free paper.

Note to the reader

This book is not intended to serve as a medical textbook for either physicians or patients. The information and advice it contains should not be used or relied upon without consulting the advice of a qualified physician. The publishers disclaim any responsibility for the accuracy of the information or advice that this book contains and any responsibility for any consequences that may result from any use or reliance thereon by the reader.

Contents

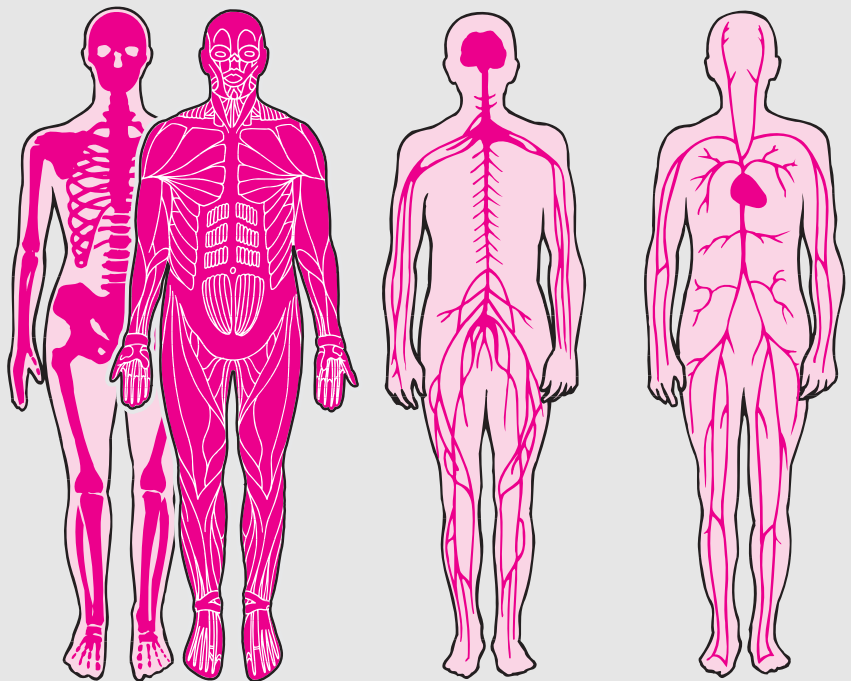
Introduction: About this book	4	Small intestine structure	58
		Small intestine function	60
		Small intestine absorption	62
		Appendix and membranes	64
SECTION 1			
DIGESTIVE SYSTEM			
Introduction	6	Large intestine	66
Digestive organs	8	Rectum and anus	68
Digestion key words and facts	10	Lower digestive tract disorders 1	70
Food's journey	12	Lower digestive tract disorders 2	72
How digestion works	14		
Movement of food	16	SECTION 5	
Alimentary canal wall	18	LIVER & PANCREAS	
Waste removal	20	Introduction	74
		Liver structure	76
SECTION 2		Liver function	78
NUTRIENTS & DIET		Gallbladder and bile	80
Introduction	22	Pancreas	82
Calories and diets	24	Pancreatic juices	84
Eating problems	26	Liver disorders	86
Reducing weight	28	Pancreas and gallbladder disorders	88
Malnutrition and special diets	30		
Digestive disorders	32	SECTION 6	
		URINARY SYSTEM	
SECTION 3		Introduction	90
MOUTH & GULLET		Kidney structure	92
Introduction	34	Nephrons	94
The tongue	36	Urine and urine flow	96
The teeth	38	Bladder and urethra	98
Dental hygiene	40	Urinary disorders	100
Salivary glands	42		
Pharynx and esophagus	44		
Swallowing	46	Glossary of the human body	102
Upper digestive tract disorders	48	Web sites to visit	108
		Index	109
SECTION 4			
STOMACH & GUT			
Introduction	50		
Stomach structure	52		
How the stomach works	54		
Stomach juices	56		

This book is a concise, illustrated guide to the anatomy, physiology, well-being, and disorders of the human digestive system. It has been written and illustrated specially for students and laypeople interested in medicine, health, fitness, and first aid. The subject is dealt with in clear steps, so that the reader can steadily acquire a good overall understanding. Explanatory texts, diagrams, illustrations, captions, and fact boxes are combined to help readers grasp important information at a glance. A glossary of scientific and jargon words defines medical terms in everyday language. A list of Web sites provides links to other relevant sources of information, and the index enables quick access to articles.

There are six sections within the book. The first section surveys the digestive system and outlines the process of digestion. The second section looks at food and the body's needs for nutrients. Sections 3 and 4 focus on the components of the digestive tract, and section 5 deals with organs linked with digestion. The last section describes the urinary system, which works in conjunction with the digestive system. Within each section, discussion and illustration of the structure and function of the anatomical parts are followed by principles of healthcare, fitness, and exercise. These are followed by a survey of the main disorders and diseases affecting the region. Information is presented as double-page topics arranged in subsections.

Human body systems

This book is one of eight titles in THE FACTS ON FILE ILLUSTRATED GUIDE TO THE HUMAN BODY series, which looks at each of the major body systems in turn. Some of the titles in the series include more than one system. The skeletal and muscular systems, and the blood and lymphatic systems, for example, work in conjunction and so are treated together. There is a separate title for human cells and genetics, which are the building blocks and underlying chemistry of all body systems.



**Skeletal and
Muscular Systems**

**Brain and
Nervous System** **Heart and
Circulatory System**

Section 1: DIGESTIVE SYSTEM follows the passage of food from the mouth to the anus, and shows how foodstuffs are broken down.

Section 2: NUTRIENTS & DIET analyzes the calorific and nutrient content of foods and gives guidelines on a balanced diet.

Section 3: MOUTH & GULLET focuses on the mechanical and early chemical breakdown of foods.

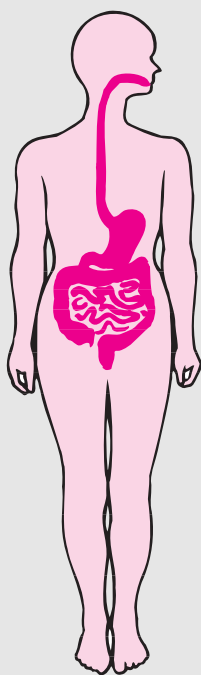
Section 4: STOMACH & GUT features the major chemical processes of digestion and the absorption of essential nutrients.

Section 5: LIVER & PANCREAS looks at how organs linked to the digestive tract aid digestion and how the products of digestion are processed and utilized.


Section 6: URINARY SYSTEM examines how the waste products of chemical processes in the body are filtered from the blood, collected, then eliminated.

This book has been written by anatomy, physiology, and health experts for non-specialists. It can be used:


- as a general guide to the way the human body functions
- as a reference resource of images and text for use in schools, libraries, or in the home
- as a basis for examination preparation for students of human biology, medicine, nursing, physiotherapy, and general healthcare.



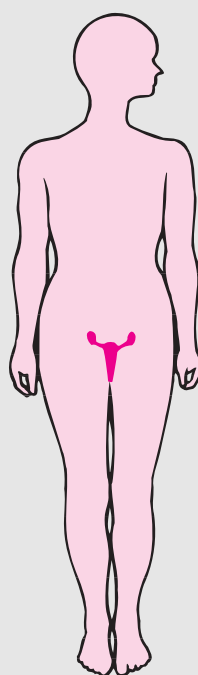
Digestive System



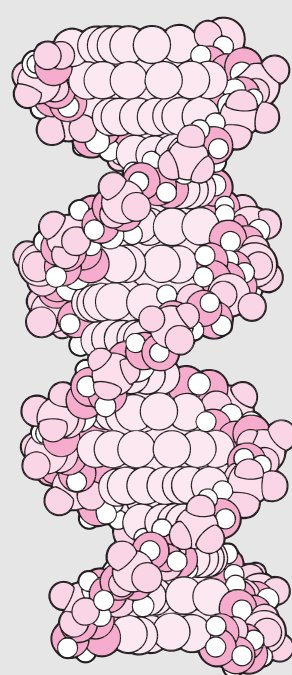
The Senses



Respiratory System



Reproductive System



Cells and Genetics

The digestive system is basically a long tube that breaks down food so it can be absorbed into the body. Its main feature is the alimentary canal, which measures about 30 feet (9 m) from mouth to anus and includes the esophagus, stomach, small and large intestines, and rectum. Also contributing to the digestive process are various accessory digestive organs: the teeth, tongue, salivary glands, liver, gallbladder, and pancreas.

Digestive system parts

Mouth cavity Here the teeth, tongue, and salivary glands process food for swallowing.

Esophagus This is the alimentary canal between the lower pharynx (throat) and the stomach. Swallowed food is moved through it by rhythmic muscular contractions known as peristalsis.

Stomach This enlarged section of the alimentary canal churns, disinfects, and starts digesting food, producing chyme, a semifluid mixture.

Sphincters These are rings of smooth muscle that contract to close an orifice. They include the pyloric sphincter (between the stomach and duodenum) and two anal sphincters.

Digestive juices Saliva and juices secreted in the stomach, small intestine, and pancreas contain enzymes for digesting specific food substances.

Small intestine This convoluted tube, about 21 feet (6.5 m) long, connects the stomach and the large intestine. It is subdivided into the duodenum, jejunum, and ileum. The small intestine is the part of the alimentary canal where most digestion occurs.

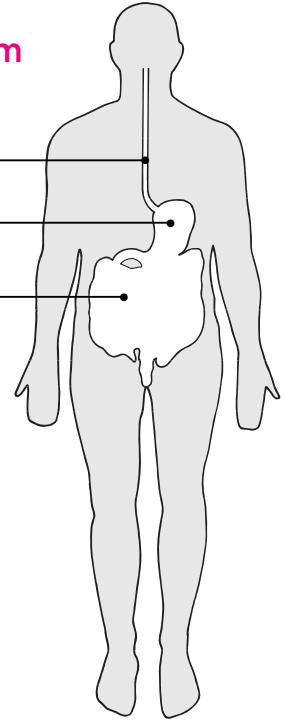
Large intestine Also called the colon, this is a broad tube about 5 feet (1.5 m) long,

Position of digestive system in the body

Esophagus

Stomach

Intestines



The digestive system forms the major part of the abdominal region, below the head and thorax.

extending from the ileum to the rectum. It is subdivided into the cecum (from which the appendix projects), and the ascending, transverse, descending, and sigmoid colons.

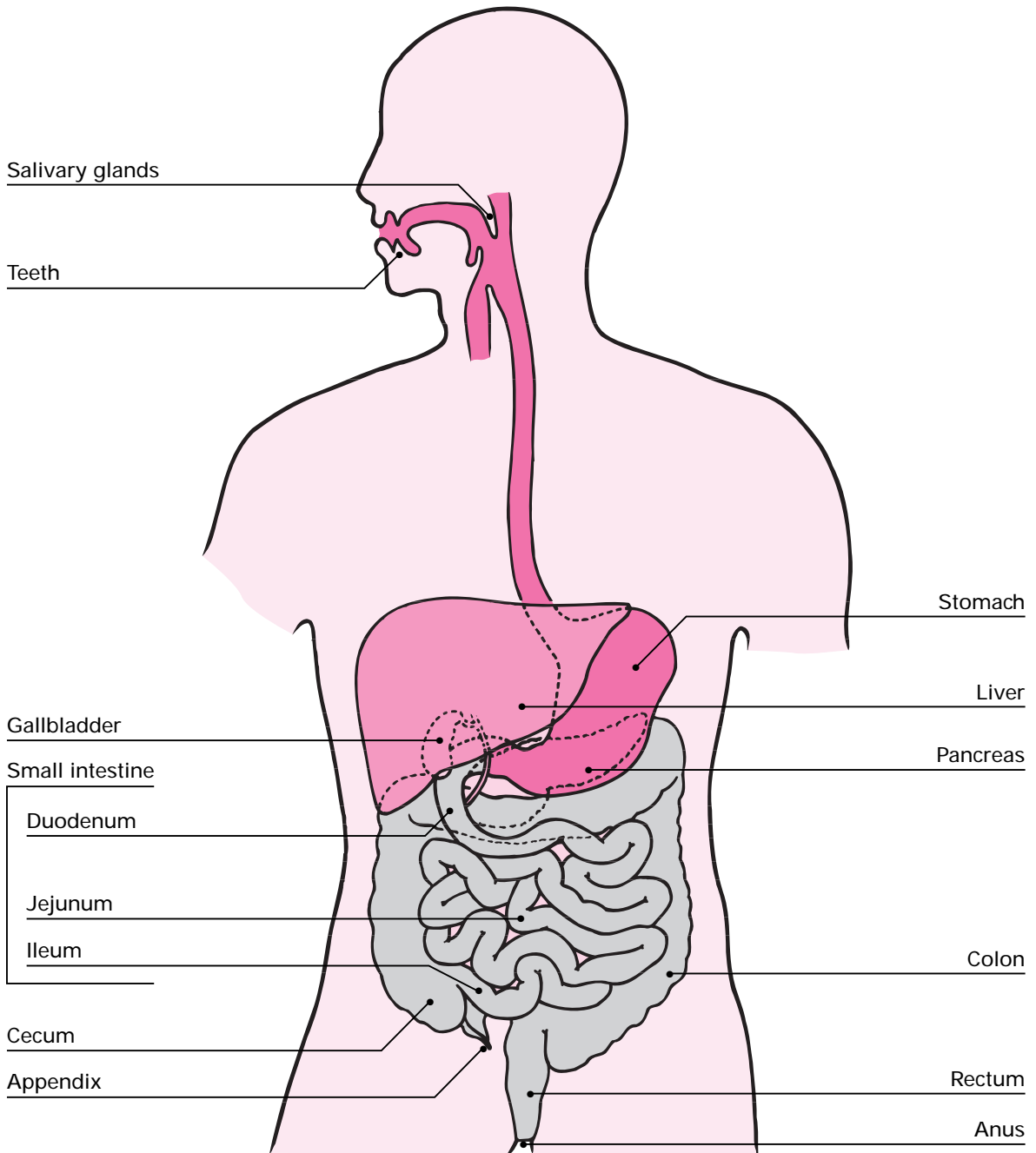
Rectum This tube extends from the sigmoid colon, and ends at a narrow orifice, the anus.

Liver The body's largest solid organ, the liver lies in the upper right part of the abdomen. Its complex chemical activities include secreting the emulsifying substance bile, and storing vitamins and glycogen (a carbohydrate produced from glucose).

Gallbladder This sac stores bile, releasing it via the cystic duct and common bile duct into the duodenum.

Pancreas This endocrine gland secretes insulin and pancreatic juice into the duodenum.

Digestive system



The digestive system

The digestive system consists of the group of organs involved in the processes by which food is digested (broken down into simpler substances) and absorbed (taken up by the blood

or lymph vessels). The digested and absorbed substances are then transported around the body to be used for energy and for rebuilding and repairing cells and tissues.

Alimentary canal organs

The alimentary canal—or gastrointestinal (GI) tract—consists of several organs.

Mouth

Here, food is chewed into smaller pieces, mixed with saliva, and formed into a rounded ball, or “bolus.”

Pharynx (throat)

Propels the bolus of food from the mouth to the esophagus.

Esophagus (gullet)

Pushes food down to the stomach by means of waves of muscular contraction.

Stomach

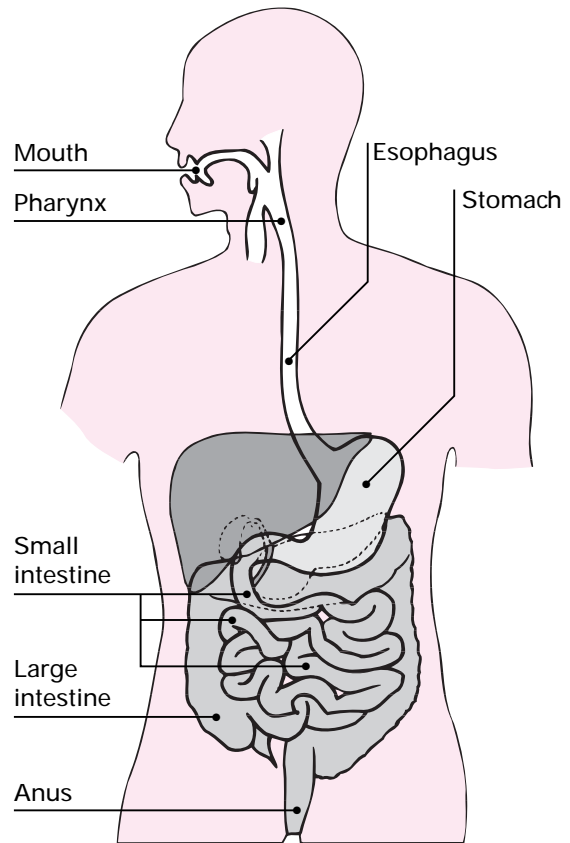
Churns food into even smaller pieces, mixes the food with gastric juices to digest food (especially protein), and regulates an even flow of food into the small intestine. Acid in the stomach kills bacteria.

Small intestine

Made up of the duodenum, jejunum, and ileum. Part of the system where most digestion takes place and water and nutrients are absorbed into the blood and lymph systems.

Large intestine

Removes salt and water from undigested food and turns the



remaining waste into a soft solid (feces), which is a mixture of indigestible remnants, unabsorbed water, and millions of bacteria.

Anus

Opening for feces to exit the body.

Accessory organs

The teeth and the tongue physically break the food up into smaller pieces. As food is chewed, it is mixed with saliva from the salivary glands. These make the digestive juice saliva. The liver,

the pancreas, and the gallbladder also produce digestive juices that chemically break down food. The liver is the largest gland in the body, and weighs 3–4 pounds (1.4–1.8 kg).

Accessory digestive organs

The accessory digestive organs aid digestion in various ways.

Teeth

These chop up food, making it easier to digest by exposing more surface area of the food for digestive enzymes to act on.

Tongue

Helps the teeth to chew food and shape it into the bolus, ready to be swallowed.

Salivary glands

Produce saliva, which lubricates food, making it easier to swallow. Saliva begins converting starch to sugar.

Liver

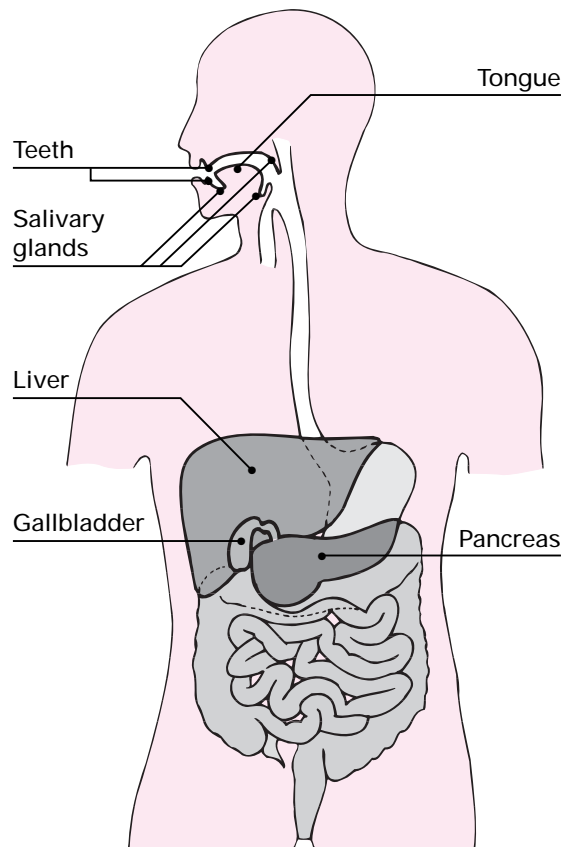
Converts nutrients from food into usable substances and stores them until they are needed.

Gallbladder

Stores and concentrates bile from the liver and releases it when needed to help with fat digestion.

Pancreas

Secretes many digestive enzymes into the small intestine and neutralizes stomach acid. Insulin, which helps the body to utilize sugar, is passed directly into the bloodstream from the pancreas.



Digestion fact

- The salivary glands produce up to 3 pints (1,600 ml) of saliva every day.

Digestive system: key words

Appendix (or Vermiform appendix) A short, wormlike tube opening into the cecum, which is closed at the other end. It contains tissues involved in immunity.

Bowel See Large intestine.

Cecum The first part of the large intestine, forming a blind pouch.

Colon The part of the large intestine between the cecum and rectum. It consists of the ascending, transverse, and descending colons, and the rectum.

Duodenum The upper part of the small intestine, where most chemical digestion takes place.

Esophagus (or Gullet) The muscular tube through which food travels between the pharynx and stomach.

Gallbladder A pear-shaped bag where bile is stored, below the liver.

Gastric Relating to the stomach.

Hepatic Relating to the liver.

Ileum The last part of the small intestine.

Jejunum The middle part of the small intestine.

Large intestine (or Bowel) The lower part of the alimentary canal,

comprising the cecum, colon, and rectum. It absorbs water, and expels wastes as feces.

Liver Divided into four lobes, its many functions include the manufacture of bile, a digestive juice.

Pancreas A tongue-shaped gland located in the abdomen that produces glucagon, insulin, and pancreatic juice.

Palate The roof of the mouth.

Pancreatic islets (or Islets of Langerhans) Scattered areas of the pancreas that produce glucagon and insulin.

Parotid glands See Salivary glands.

Peristalsis Waves of muscular contractions that force substances, such as food, through internal passageways.

Pharynx The throat.

Pylorus The narrow exit from the stomach into the duodenum, closed by a sphincter.

Rectum The last part of the colon, where feces collect before leaving the body.

Salivary glands The lingual, parotid, sublingual, and submandibular glands that produce saliva.

Sigmoid colon The S-shaped part of the colon.

Small intestine The alimentary canal between the stomach and large intestine, comprising the duodenum, jejunum, and ileum. Most digestion occurs here.

Sphincter A ring-shaped muscle that contracts to close an orifice, such as the pyloric sphincter and the anal sphincters.

Stomach A muscular, baglike part of the alimentary canal between the esophagus and small intestine. It stores, churns, and partially digests food.

Taste buds Tiny sensory organs (circumvallate papillae, filiform papillae, fungiform papillae) on the tongue and palate.

Teeth Bonelike structures in the jaws. Different types (incisors, canines, premolars, molars) are specialized to pierce, tear, crush, and/or grind food.

Tongue A muscular organ in the mouth, involved in tasting, chewing, swallowing, and speech.

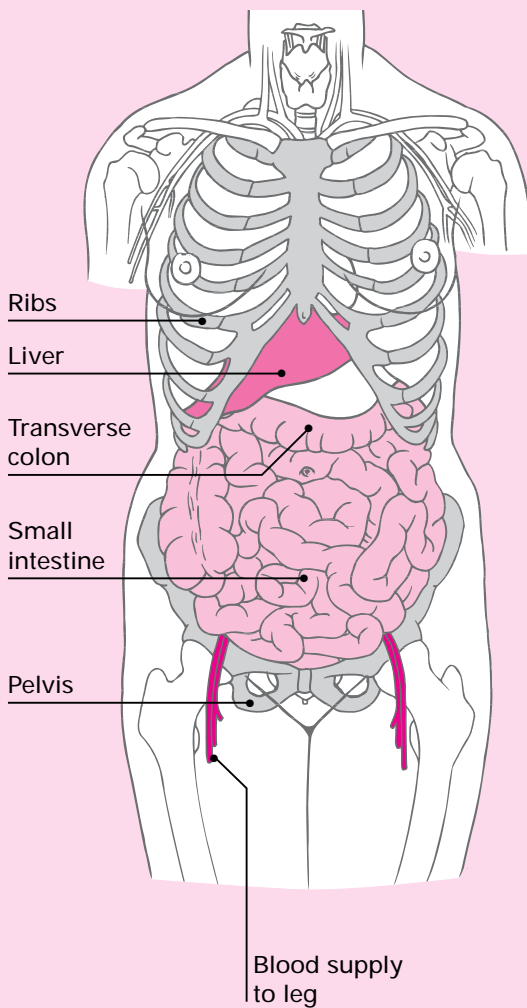
Villus A minute fingerlike projection. Huge numbers line the small intestine, increasing its surface area (plural: villi).

Location of organs

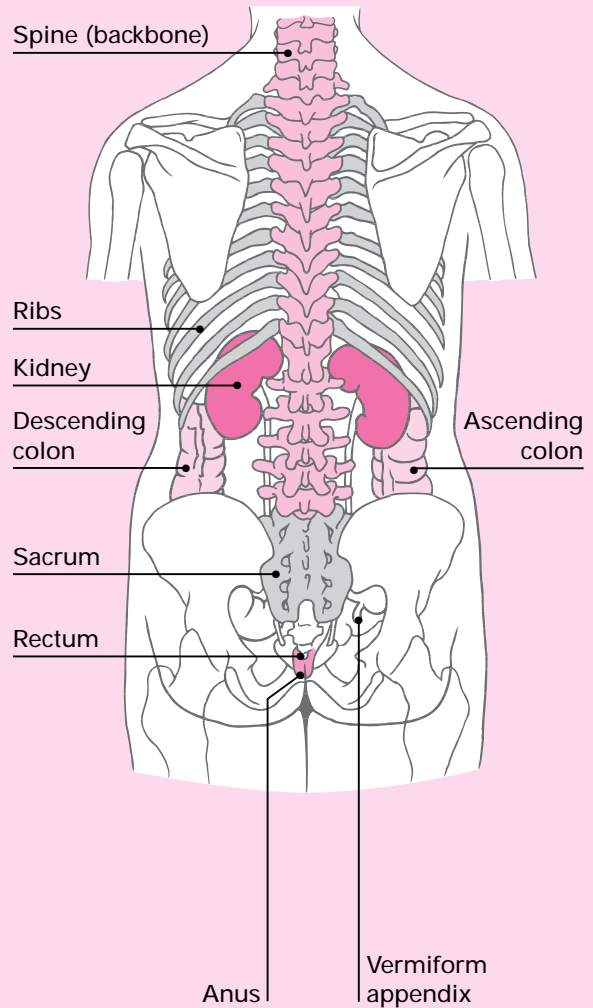
The two diagrams below show the location of the major digestive organs within the body. They take up most of the space within the abdomen, with the diaphragm above them and the pelvis

below. The liver is situated under the rib cage on the right side of the body, while the kidneys sit against the rear wall of the abdomen, just above the level of the waist.

Front view



Back view



The journey of food

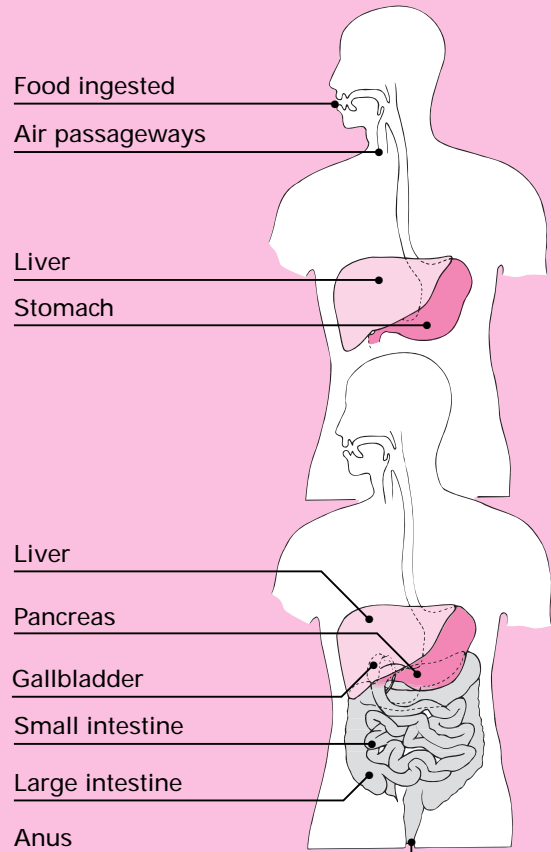
As food journeys through the body, it is first ingested, then digested, and finally absorbed into the blood or lymph.

Food is ingested and swallowed

Ingestion is the process of taking food into the body by way of the digestive system. The mouth is the doorway into this system. Teeth in the mouth break down the food by mastication (chewing). Taste buds on the tongue send nerve impulses to the brain to stimulate the release of saliva from the salivary glands. Saliva is mixed with the food by the actions of the teeth and the tongue. Saliva moistens the food, and begins the process of chemical breakdown. The tongue rolls the food into a chewed mass of food (bolus), ready to be swallowed. The throat (pharynx) automatically continues the swallowing process. While food is being swallowed, the air passageways are closed to prevent choking.

Food passes to the stomach

The opening to the esophagus widens, and waves of rhythmic muscular contractions called peristalsis force food into the stomach. The walls of the stomach distend as it fills up with food. The muscular walls of the stomach churn the food, breaking it down, and mixing it with gastric juices to produce chyme (a semifluid mixture). The gastric juices continue the process of chemical digestion that began in the mouth. Peristaltic movements eventually force chyme into the small intestine.

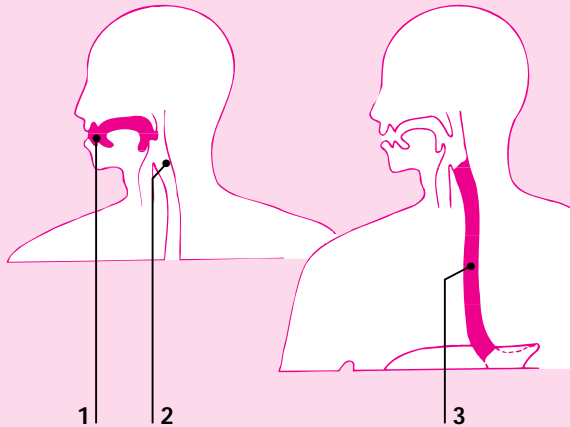


Food is digested and absorbed

In the small intestine, enzymes from the pancreas, and bile from the liver and gallbladder, almost complete the digestion of food. The products of digested food are absorbed through the lining of the small intestine into blood or lymph vessels. Remaining undigested food passes to the large intestine, where bacteria complete the digestion process, and water is absorbed. Feces (dead bacteria and cells, mucus, bile, and indigestible food) are excreted by muscular action via the rectum and anus.

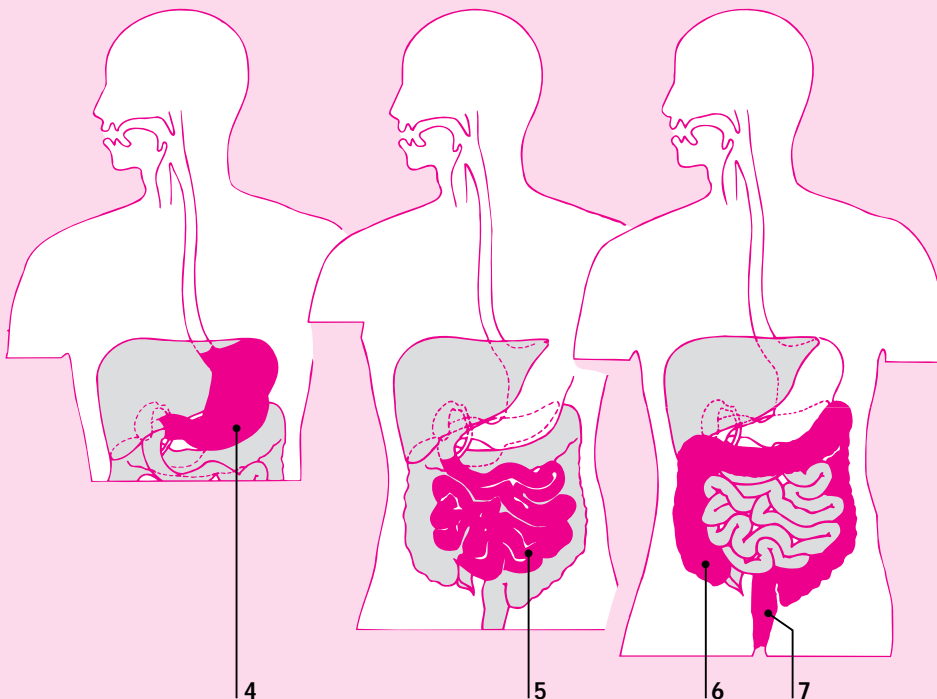
Journey time

It takes most food a total of about 24 hours to pass through the digestive system. Some foods, especially liquids, move faster, and others more slowly.



How long food takes to pass through the system

Organ	Time taken
1 Mouth	under voluntary control (usually minutes)
2 Pharynx	1–2 seconds
3 Esophagus	5–10 seconds (solids) 1 second (liquid)
4 Stomach	2–6 hours
5 Small intestine	1–6 hours
6 Large intestine	10–24 hours
7 Rectum	under voluntary control



Digestive processes

In order to digest and absorb food, the digestive system relies on six essential processes and mechanisms. These are:

ingestion, mechanical digestion, propulsion, chemical digestion, absorption, and elimination.

Activity

How it is achieved

Ingestion

Process of taking food into the alimentary canal.

Food is placed voluntarily into mouth.

Mechanical digestion

Physical breakdown of food into smaller fragments, enabling digestion.

Physical breakdown is achieved by:

- mastication (chewing);
- churning;
- mixing; and
- segmentation.

Propulsion

Process that moves food through the alimentary canal.

Food movement is achieved by:

- peristalsis (wavelike contractions of walls of alimentary canal);
- swallowing; and
- segmentation (rhythmic local constrictions of walls of alimentary canal).

Chemical digestion

Chemical breakdown of food into simpler substances, enabling digestion and absorption.

Chemical breakdown is achieved by:

- hydrolysis (using water to break down complex molecules);
- digestive enzymes (proteins that act as biological catalysts) breaking down food molecules; and
- bile (watery, alkaline solution), which breaks large fat globules down into smaller droplets.

Absorption

Passage of digested food products from alimentary canal to blood or lymph vessels.

- Simple molecules produced by food digestion are absorbed through the cell membranes of the alimentary canal lining into blood and lymph vessels.

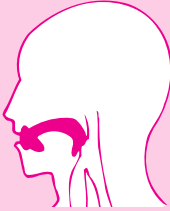Elimination

Process that expels indigestible substances from body.

- Defecation occurs; feces (dead bacteria and cells, mucus, bile, and indigestible food) are expelled by muscular action.

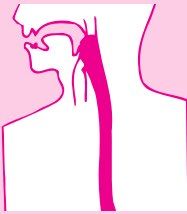The location of digestive processes

Organ



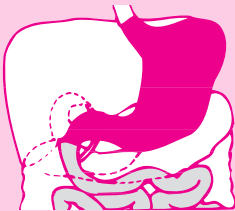The **mouth** is involved in:

- ingestion;
- propulsion;
- mechanical digestion (mastication and mixing); and
- chemical digestion (saliva).



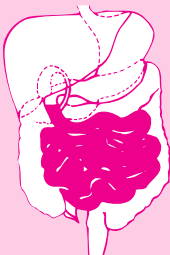
The **pharynx and esophagus** are involved in:

- propulsion (peristalsis).



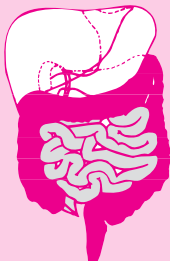
The **stomach** is involved in:

- propulsion (peristalsis);
- mechanical digestion (churning and mixing);
- chemical digestion (gastric juices); and
- absorption.



The **small intestine** is involved in:

- propulsion (peristalsis and segmentation);
- mechanical digestion (segmentation and mixing);
- chemical digestion (pancreatic juices, digestive enzymes, and bile); and
- absorption.



The **large intestine** is involved in:

- propulsion (peristalsis);
- mechanical digestion (mixing and segmentation);
- chemical digestion (bacterial);
- absorption (mainly water); and
- elimination (defecation).

Peristalsis

This is an involuntary process that propels food through the alimentary canal.

Adjacent muscle fibers contract and relax in sequence.

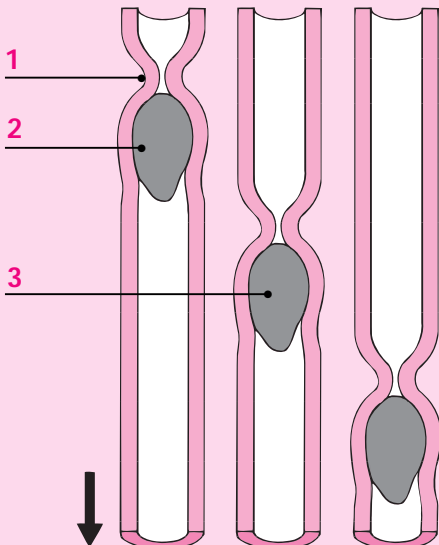
1 As a group of muscle fibers contracts, that part of the passage becomes narrower.

2 This action squeezes the food bolus into the next section, where the muscle fibers are relaxed.

3 This area then contracts, squeezing the bolus further down the length of the alimentary canal.

Within the digestive system peristaltic action occurs in the:

- pharynx and esophagus (as part of the swallowing process);
- stomach;
- small intestine; and
- large intestine.



Segmentation

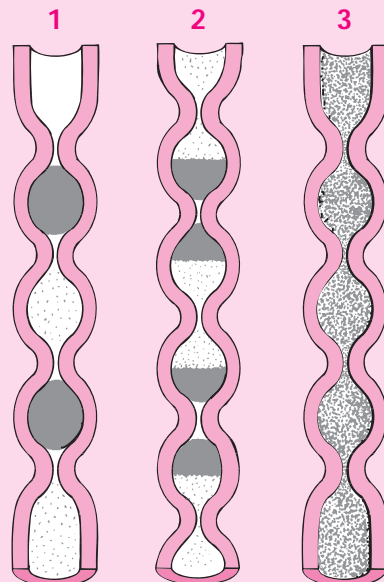
This is an involuntary process that occurs mainly in the small intestine, and has three functions:

- mixing food with digestive juices;
- increasing the absorption rate; and
- helping to propel food through the alimentary canal.

1 Nonadjacent sections of the intestinal wall alternately contract and relax.

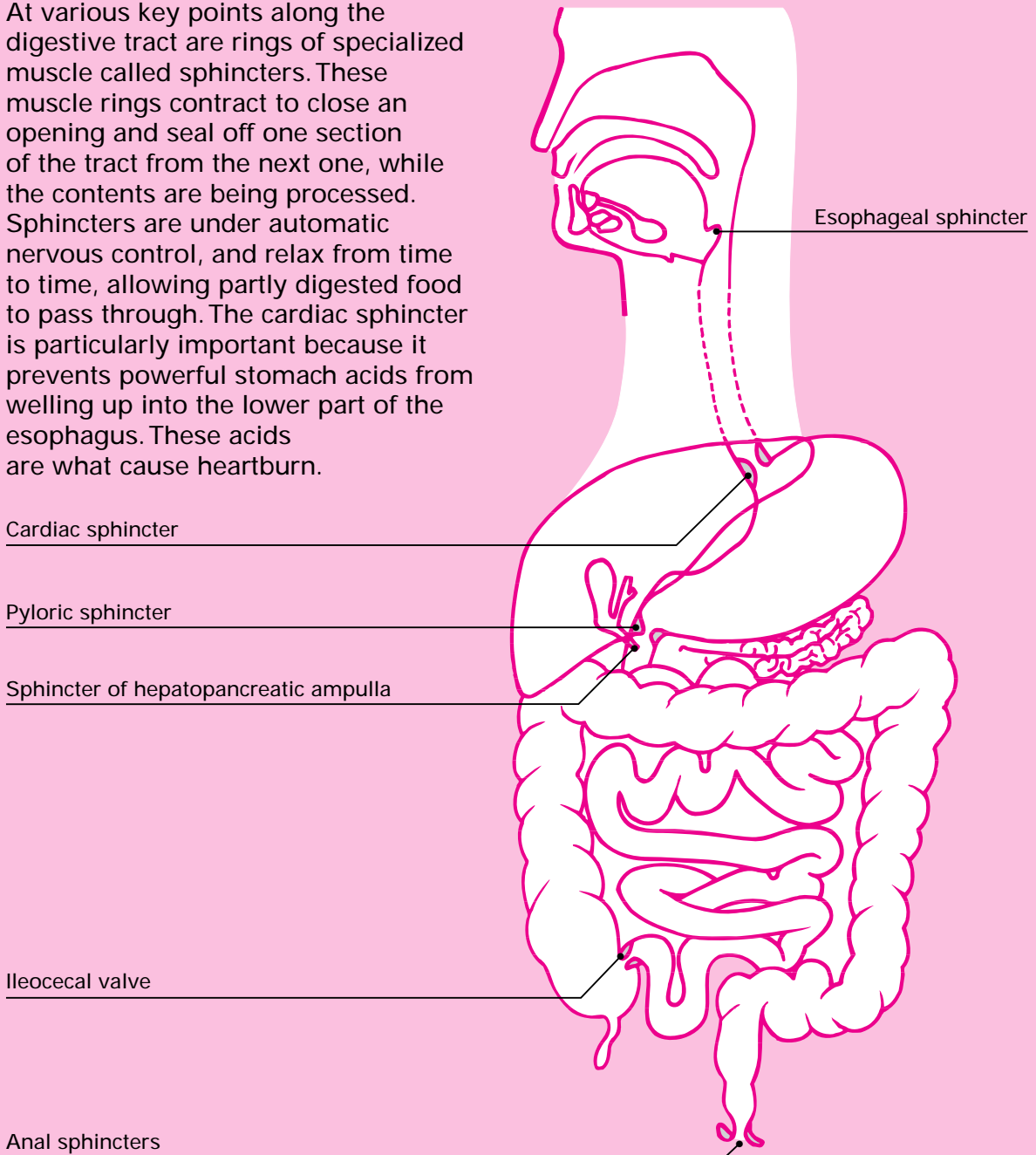
2 As inactive segments exist between the active ones, the food bolus is moved back and forth across the alimentary canal and mixed with digestive juices.

3 The digestive juices break down the bolus, and the contraction and relaxation of the intestinal wall help move the bolus down the canal.



Muscle sphincters

At various key points along the digestive tract are rings of specialized muscle called sphincters. These muscle rings contract to close an opening and seal off one section of the tract from the next one, while the contents are being processed. Sphincters are under automatic nervous control, and relax from time to time, allowing partly digested food to pass through. The cardiac sphincter is particularly important because it prevents powerful stomach acids from welling up into the lower part of the esophagus. These acids are what cause heartburn.



Structure of the alimentary canal

The walls of the alimentary canal, from esophagus to anus, are made up of four basic tunics (layers):

- mucosa;
- submucosa;
- muscularis externa; and
- serosa.

Mucosa

The mucosa, or mucous membrane, is the innermost layer that lines the lumen (cavities) of the alimentary canal. It is made up of surface epithelium, lamina propria (connective tissue), and a muscular layer. The mucosa contains goblet cells that secrete mucus (thick, slimy fluid which lines the gut), lymph nodules, and muscles.

Submucosa

This is a connective tissue layer of loose, spongy tissue, which cushions the layers on either side. It contains blood vessels, lymph vessels, and nerve endings.

Muscularis externa

This muscular layer thickens at certain points to form sphincters (rings

Muscular layer

Mucosa

Blood vessel

Submucosa

Muscularis externa

Inner circular muscle

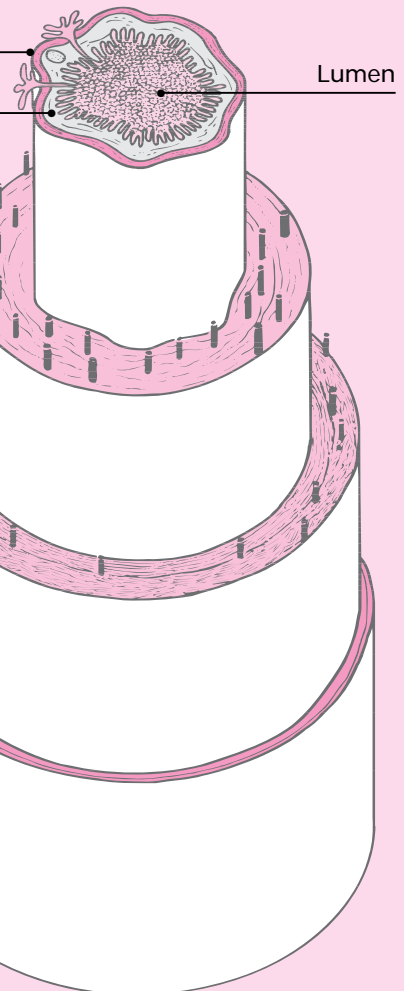
Outer longitudinal muscle

Serosa

of muscle). It normally has two sublayers, an inner circular muscle layer, and an outer longitudinal muscle layer.

Serosa

The serosa is connective tissue that covers the external surfaces of most



digestive organs. In the esophagus, the serosa is replaced by an adventitia (fibrous connective tissue).

Functions of the alimentary canal's layers

Each of the tunics (layers) of the alimentary canal lining has a distinct function. These include secretion and absorption on the inside, propulsion in the middle, and containment on the outside.

Mucosa

Secretes mucus to moisten food, and lubricate and protect the lining of the alimentary canal. The mucosa also secretes digestive enzymes and hormones, contains lymph nodules that protect against infectious diseases, and absorbs the end products of digestion into blood and lymph vessels.

Submucosa

Supplies surrounding tissues of alimentary canal wall with blood and lymph.

Muscularis externa

Performs peristalsis and segmentation, which mix and propel food through the canal, and has muscle sphincters that act as valves to regulate the passage of food from one section of the canal to the next.

Mucosa

Submucosa

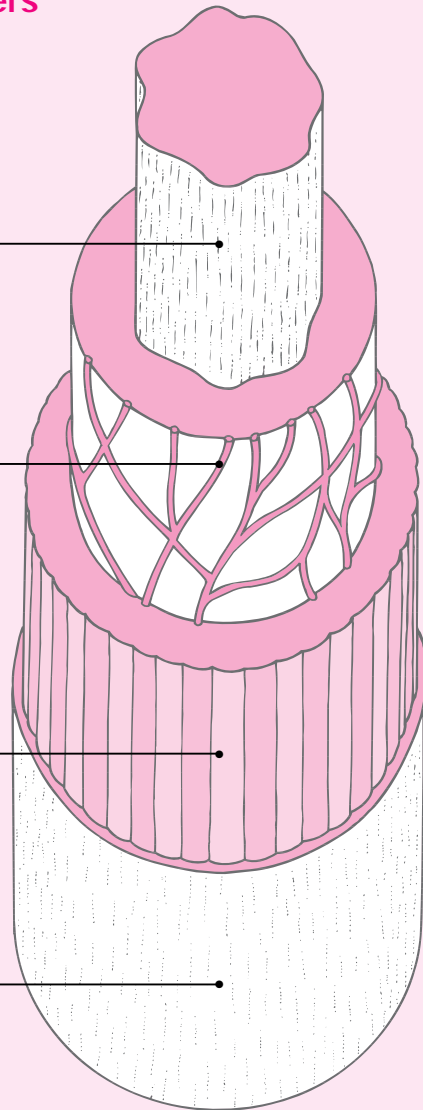
Muscularis externa

Serosa

Serosa

Secretes fluid that lubricates the peritoneal cavity (space between the membranes covering abdominal organs) allowing the organs to

glide across one another. It also stores fat, holds organs in place, and provides routes (the mesenteries) for blood, lymph, and nerves.



The urinary system

Although the intestines remove undigested leftovers from food, chemical reactions in the body produce many other waste products, which build up in the blood. These wastes are dealt with by the urinary system, which consists of the kidneys, ureters, bladder, and urethra. The kidneys remove waste products from the blood and also help to regulate the amount of water in the body. Wastes and excess water, in the form of urine, are excreted via the ureters, bladder, and urethra.

Kidneys

The kidneys are two bean-shaped organs located to the rear of the abdominal cavity, just above the waist, on either side of the spinal column. Each kidney is about 5 inches (12.5 cm) long and weighs about 6 ounces (170 g). Blood enters the kidney in the renal artery to pass through tiny filter units called nephrons. The cortex (outer part) of each kidney contains about one million nephrons, made up of a Bowman's capsule, a glomerulus (knot of capillaries), and a tubule. Filtered blood leaves the kidney in the renal vein. Urine leaves via the ureter.

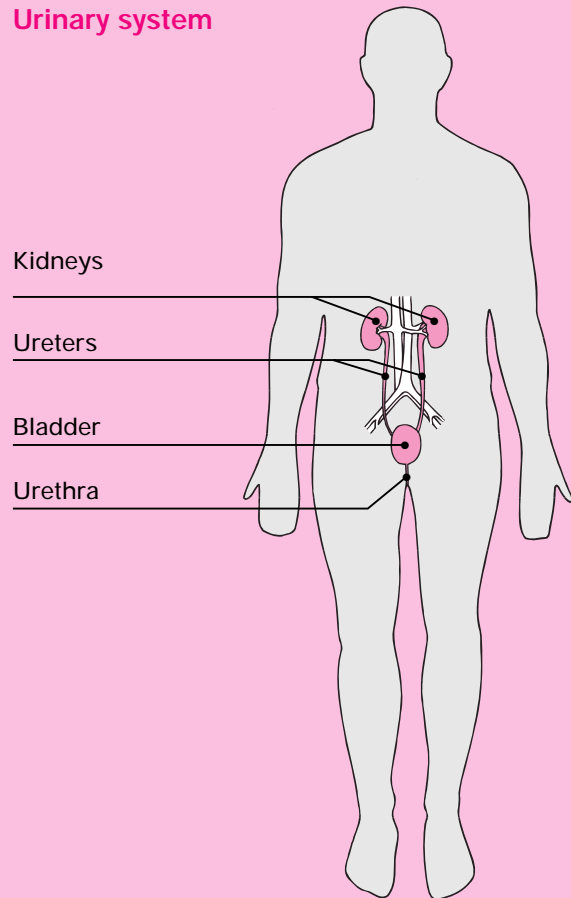
Ureters

These two tubes drain urine from the kidneys to the bladder. Each ureter is a muscular tube 10 inches (25 cm) long.

Bladder

Situated in the lower abdomen, this hollow, muscular organ acts as a reservoir for urine. It varies in size depending on the amount of urine it contains. The two ureters enter the

Urinary system



bladder from behind. The urethra leaves from the bladder's lowest point, known as the neck. A man's bladder may hold as much as 1.2 pints (56 cl) when full.

Urethra

This muscular tube connects the bladder with the outside of the body. It measures about 1.5 inches (3.8 cm) in a woman but up to 8 inches (20 cm) in a man. Micturition (urination) occurs when the sphincter (muscular ring) between the bladder and the urethra is relaxed. This sphincter is under voluntary control.

Kidney function

As blood flows through the kidneys, it is filtered, purified, cleaned, and adjusted. The kidneys keep the body balanced by adjusting their output of urine to equal the intake of substances into the body. They balance the fluid levels of the body as well as balancing its acid/alkaline nature (pH). The kidneys also balance concentrations of salts, minerals, and other substances, and eliminate foreign substances, such as drugs.

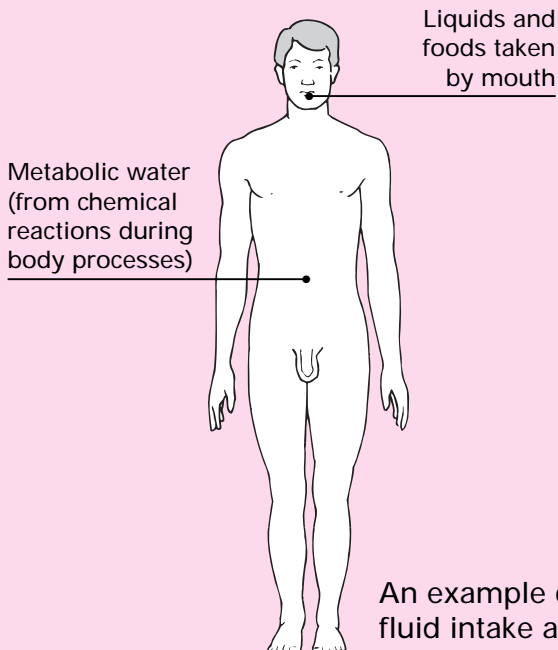
Fluid regulation

Most fluid is taken into the body in the form of drinks and food. Fluid intake is regulated by the feeling of thirst (a dry mouth and throat). Fluid is lost through urination, the lungs (as water vapor), the skin (as sweat), and the gut (in feces). Fluid output is adjusted by ADH (antidiuretic hormone), a hormone secreted from the pituitary gland, and by aldosterone, a hormone secreted by the adrenals (near the kidneys).

Fluid intake and output

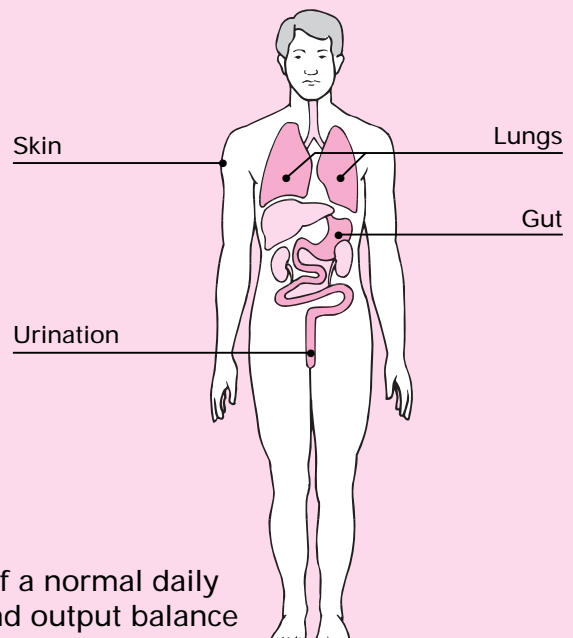
Daily input

- Mouth—54 fluid ounces (1600 ml)
- Foods—24 fluid ounces (700 ml)
- Body processes—7 fluid ounces (200 ml)



Daily output

- Urination—51 fluid ounces (1500 ml)
- Skin—17 fluid ounces (500 ml)
- Lungs—10 fluid ounces (300 ml)
- Gut—7 fluid ounces (200 ml)



The human body needs food to maintain life processes and promote healthy cell growth. The substances required by the body in the form of food are proteins, carbohydrates, fats, vitamins, and minerals. The body also requires about 84.5 fluid ounces (2500 ml) of water daily—some of which will be found in food—since roughly 75 percent of the body is water. The food is broken down and resynthesized in a form that the body can use. A wide variety of foods is more likely to provide all the essential nutrients than a limited diet. It is perfectly possible to be healthy on a balanced vegetarian diet, but some extreme diets can cause malnutrition because of nutrient deficiencies.

Proteins

Proteins are complex organic compounds containing nitrogen. Dietary protein is broken down by the body to liberate amino acids that pass into the blood and are used for building and repairing body tissues. Excess protein can be used for energy or turned into fat. The diet should contain about 15 percent protein. The need for protein varies with age, body weight, and amount of physical activity. Men usually need more protein than women because they are heavier. Young children need proportionately more protein than adults because they use a great deal of their protein for the rapid growth of body tissue.

Carbohydrates

Carbohydrates—chemical compounds of carbon, hydrogen, and oxygen—should ideally make up 50–60 percent of the diet. After digestion and absorption as glucose into the bloodstream, carbohydrates may be used

directly, temporarily stored in the muscles and liver as glycogen (the only carbohydrate the body makes), or converted into fat and deposited in the adipose tissues of the body. Carbohydrates provide the most readily available energy source for the body.

Fats

Fats are energy sources and should make up about 30–35 percent of the diet. They also help to prevent heat loss from the body, and to protect the body's structures. Fats are major contributors to obesity, and have been implicated in heart disease.

Vitamins

Vitamins act together with enzymes to increase the rate of chemical reactions that occur in the body. There are about 40 vitamins, of which 12 are essential in the diet. They can be divided into two groups: those that are soluble in fat (vitamins A, D, E, and K), and those that are soluble in water (vitamin C and the B complex). Fat-soluble vitamins are absorbed by the intestine, with fats, and are stored in fatty tissue. Overingestion of fat-soluble vitamins can cause dangerously high levels of these vitamins to accumulate within the body. A varied diet is necessary to provide the essential vitamins. Cooking vegetables in the minimum amount of water for only a short time will help to preserve the vitamins.

Minerals

Minerals play a vital role in the regulation of body fluids and the balance of chemicals. Some are needed in comparatively large amounts; these are calcium, phosphorus, potassium, sodium, chlorine, sulfur, and magnesium. Those that are needed in smaller quantities are iron, iodine, and fluorine. Deficiencies in these minerals can cause serious illnesses such as anemia and goiter (enlargement of the thyroid gland).

Food nutrients

The digestive system is designed to extract from food the nutrients (useful substances) that we need for growth,

repair, and energy. There are six groups of essential nutrients: proteins, vitamins, fats, minerals, carbohydrates, and water.

Nutrient	Major sources	Major functions
Proteins (large molecules made up of many amino acids)	<ul style="list-style-type: none">• Dairy products• Meat, fish, eggs• Legumes (peas and beans)• Bread and cereals	Provide structure for body tissues; are essential for growth and repair of cells; and as hormones, enzymes, and carrier molecules, help regulate body processes.
Carbohydrates (sugars, starches, and fiber—e.g. cellulose)	<ul style="list-style-type: none">• Bread and cereals• Vegetables• Fruit	Are a major energy source; fiber provides bulk and absorbs water from digested foods; make fats and amino acids.
Fats (lipids) (combinations of fatty acids and glycerol)	<ul style="list-style-type: none">• Dairy products• Meat and eggs• Vegetable oils	Are a major energy source; are the structural component of cells; transport and absorb fat-soluble vitamins; and when stored, provide energy reserves, protection for organs, and insulation.
Vitamins (chemicals the body needs for biochemical processes)	<ul style="list-style-type: none">• Dairy products• Meat, fish, eggs• Fruit• Vegetables• Bread and cereals	Regulate metabolism (chemical processes within cells); maintain healthy brain, nerves, muscles, skin, and bone; enable release of energy from food.
Minerals (chemicals needed to maintain health)	<ul style="list-style-type: none">• Vegetables• Legumes• Dairy products• Meat, fish, eggs	Control cell metabolism; prevent anemia (lack of iron); maintain fluid balance and healthy teeth and bones.
Water	<ul style="list-style-type: none">• All groups• Water	Maintains metabolism; is essential for normal bowel functioning; and determines volume of blood in circulation.

Counting calories

The measure used in talking about food and human energy needs is the kilocalorie (kcal), or calorie.

A typical number of calories for a woman to use up in a day is 2000. So this is the amount of energy her food must supply, unless she is to run down her stored reserves. Protein, fat, and carbohydrates are all sources of energy (though protein is more vital as a source of other things). One ounce (28 g) of protein or carbohydrate produces over 113 calories in the human body, and one ounce (28 g) of fat produces 225 calories. One ounce (28 g) of alcohol—rich in the carbohydrates we call sugars—produces 180 calories.

Western and Eastern diets

The West offers the most varied, cleanest, and most readily available supply of food in the history of the world. However, despite the opportunities for eating well, major nutritional problems including obesity, diabetes (associated in some cases with excessive carbohydrate intake), and digestive diseases associated with a lack of fiber, often occur. Also, food additives may be over-used in the West. Seventy-five percent of the world's people live on a diet based on just one food, usually a cereal (such as rice). Deficiency diseases and lack of food because of crop failure are common in the East. But in times of plenty, these diets often provide more nutrients than the average Western diet.

Vegetarian diets

Strict vegetarians eat only plant products—fruit, vegetables, and cereals. They do not eat any meat, poultry, fish, eggs, dairy produce, or, in some cases, honey. Their main sources of nutrients are nuts, wholewheat flour, legumes, pasta, brown rice, unrefined sugars, fruit, and vegetables (ideally eaten raw for maximum nutritional value), and unrefined vegetable oils. Soy-based milk can be substituted for cow's milk, and seaweed agar for gelatin. Strict vegetarians may need supplements of vitamin B₁₂, which can be taken in tablet form or added to food.

Lacto-ovo-vegetarian diets

Lacto-ovo-vegetarians are those who eat all foods that come from plants, and also dairy foods and eggs. This kind of diet is nutritionally sound as long as the ingredients are selected carefully. Eggs are an even better source of protein than meat, and also contain a complete protein rarely found in vegetables or fruit. Some people become vegetarians for their health. Other reasons are ethical (usually based on a belief in animal rights), religious (based on the sanctity of life), or economic (it is more economical to use land for growing crops than for feeding cattle).

Omnivorous diets

Omnivores eat food from all available sources, including meat, fish, poultry, eggs, vegetables, fruit, and cereals. Most people in the Western world are omnivores, and in theory this should be the most nutritious diet possible because all types of food are available. In practice, however, many omnivores do not plan a healthy diet because food is so readily available, and convenience foods are often easier to get than fresh foods.



Macrobiotic diets

Foods in a macrobiotic diet are labelled either yin or yang, based on their acid and alkali levels. For example, fruits and sugar are yin, meat and eggs are yang. The ratio in which these foods are eaten is supposed to be 5:1, yin to yang. Almost all foods may be eaten but there is a strong emphasis on grains, particularly brown rice.

Adolescents

The nutritional requirements of adolescents are decided mostly by the growth spurt at puberty. In boys, this is responsible for a gain in height of about 8 inches (20 cm), and in weight of about 40 pounds (18 kg). In girls, the gains are usually less. If the extra requirements are not provided at mealtimes, adolescents may have sweet snacks between meals. These may lead to obesity and dental problems, or an imbalance in the diet.

Adults

Childhood eating habits tend to continue in adult life. With freedom to choose, an adult may tend to eat what he or she finds satisfying (such as sweet things), rather than what is nutritionally worthwhile. Lifestyle may decide much of the daily food intake. People who are busy at work or in the home, may feel too rushed or tired to prepare or eat proper meals. Social events may encourage people to eat rich, fatty foods and drink alcohol.

Older people

Many elderly people remain active, and so their diet is similar to that of other adults. But as activity declines, the need for food is also less. If a person's intake is less than 2000 calories per day, the diet may be deficient in minerals and vitamins. They may need vitamin D if they do not get enough sunlight. The diet should include fresh fruit, vegetables, milk, eggs, and meat, but not too much bread or candy. Fiber is important to prevent constipation.

Overeating

Children who do not get enough affection or attention often turn to food for comfort, and this may lead to a dependence on food in all future times of stress. Parents should never feel that a child is rejecting them by rejecting their cooking, otherwise they can easily force the child into eating too much and suppress the body's signals of fullness.

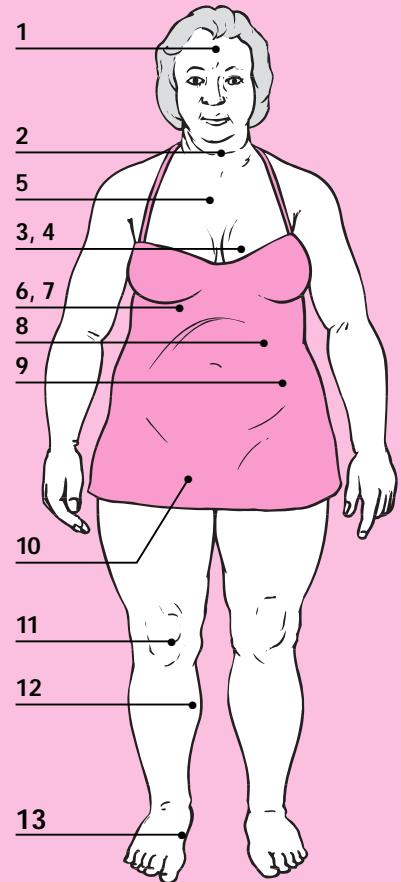
In adulthood, there are many dangerous situations likely to lead to overeating. Activity often declines during adulthood, but is not usually followed by a corresponding decrease in the amount of food eaten. Family difficulties, a death in the family, or work problems may all lead to the kind of stress that encourages overeating for comfort.

Effects of being overweight

Overweight people have a shorter life expectancy, and the greater their excess weight, the more their life expectancy decreases.

If the onset of obesity begins before the age of 35, life expectancy is even lower, and if it begins in childhood, the statistics are worse still. Overweight people are more accident-prone than those of normal weight, mainly because weight limits mobility so danger is more difficult to escape. Being overweight may disguise symptoms of serious diseases and make it difficult for a doctor to make a diagnosis. It also makes surgery more dangerous.

- 1** Strokes are more likely.
- 2** A double chin forms.
- 3** Hypertension, or high blood pressure, is more common.
- 4** Heart disease, heart palpitations, and poor circulation are more common.
- 5** Breathlessness and respiratory disease are more likely.
- 6** Gallbladder diseases occur more often.
- 7** Cirrhosis (scarring) of the liver is more common.
- 8** Diabetes is more common.
- 9** Kidney diseases of all types are more common.
- 10** Hernias are more frequent, especially among men.
- 11** Arthritis, especially of the hips and knee joints, is more common.
- 12** Varicose veins are more common.



Undereating

Occasionally the normal body cycle of hunger, eating, and fullness is changed, perhaps by physical disturbances, such as illness, or by psychological disturbances, for example stress or depression. The hunger pangs that the body produces may be ignored, in an overenthusiastic attempt to lose weight or because of a psychological disturbance, and

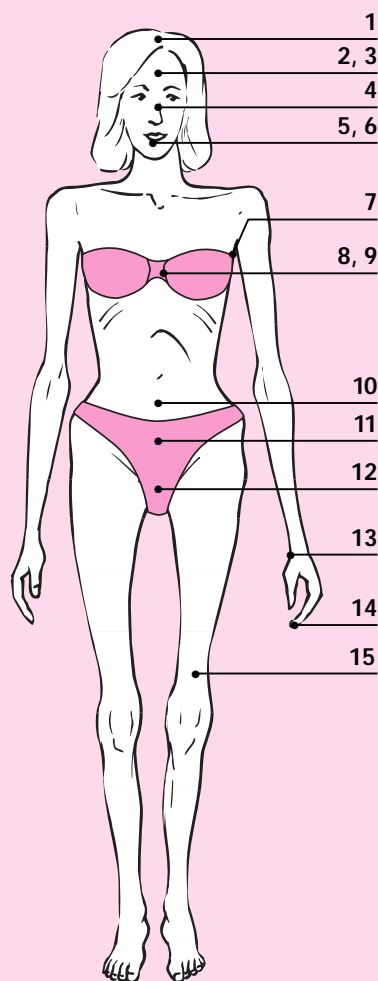
the condition known as anorexia nervosa may set in. This usually affects females between the ages of 14 and 18. Males are rarely affected. The sufferer either becomes physically incapable of eating, or vomits the food after meals (bulimia). Once anorexia is established, drastic and potentially fatal weight loss occurs. Medical help must always be sought.

Effects of anorexia

People who develop anorexia almost always say that there is nothing wrong with them; they may explain away their weight loss, or even fool themselves into thinking that they are fat. It may therefore be very hard to obtain successful treatment, since the cooperation of the anorexic is required. If left untreated, however, the condition can easily lead to death.

- 1** The hair changes texture, and sometimes color, because it lacks nourishment.
- 2** Dizziness and excessive fatigue may be felt as the muscles have no energy reserves.
- 3** Sleep disturbance often occurs.
- 4** Hormone imbalance arises.

- 5** Bad breath occurs because of the constantly empty stomach.
- 6** Decayed teeth occur if the tooth enamel is destroyed by stomach acids in vomit.
- 7** Hypothermia, or low body temperature, occurs as the body tries to conserve energy.
- 8** The electrolyte balance of the body is altered.
- 9** Respiration slows.
- 10** An excess of fine hair begins to grow on the body.
- 11** Chronic constipation may occur.
- 12** Menstrual periods often cease.
- 13** The pulse slows, and the blood pressure drops.
- 14** The fingernails become more brittle because they are not receiving nutrients.
- 15** Severe emaciation is one of the most obvious signs of the condition.



Reducing weight

Reducing weight requires commitment and planning. The only way to achieve a genuine weight loss is to use up more calories of energy than you take in by eating. A cut of about 3,500 calories is needed to lose one pound (0.45 kg) of body weight, so a person who would normally use 2,000 calories per

day should lose about two pounds (0.9 kg) per week on a 1,000 calorie diet. This is the ideal rate of weight loss; if you lose weight more slowly you may become discouraged, and if you try to lose weight more quickly, you will damage the body tissues by breaking them down instead of your body fat.

Optimum weight

Men

Height (ft:in/m)	Weight (lb/kg)
5:2/1.57	119–136/54–62
5:3/1.60	122–140/55–64
5:4/1.63	125–143/57–65
5:5/1.65	128–147/58–67
5:6/1.68	132–151/60–68
5:7/1.70	136–156/62–71
5:8/1.73	140–160/64–73
5:9/1.75	145–164/66–74
5:10/1.78	149–169/67–77
5:11/1.80	153–174/69–79
6:0/1.83	157–178/71–81
6:1/1.85	161–183/73–83
6:2/1.88	165–188/75–85

Women

Height (ft:in/m)	Weight (lb/kg)
4:10/1.47	100–117/45–53
4:11/1.50	103–120/47–54
5:0/1.52	106–123/48–56
5:1/1.54	109–126/49–57
5:2/1.57	112–130/51–59
5:3/1.60	115–134/52–61
5:4/1.62	119–138/54–63
5:5/1.65	123–142/56–64
5:6/1.68	127–146/58–66
5:7/1.70	131–150/59–68
5:8/1.73	135–154/61–70
5:9/1.75	139–159/63–72
5:10/1.78	143–164/65–74

Measuring weight

The chart above shows desirable weights for men and women by height. Always check with your doctor before going on a diet. Weigh yourself on the same scales, in the same room, at the same time of day, so that you have an accurate record of your weight loss. Measure your height

without shoes, and weigh yourself without clothes. During middle and old age people tend to put on about 10–20 pounds (4.5–9 kg) in weight, but this is not necessary; older people will find that they stay healthier if they maintain about the same weight as they had in their 20s.

Testing for obesity

Weight is not the only measure of whether you need to go on a reducing diet. Body shape and condition will tell you a lot too. If you examine yourself honestly, you may have to admit that you could do with losing some weight. If you stand relaxed, without pulling in your muscles, does your abdomen sag? Does your stomach bulge over a tight waistband? Can you pinch a roll of flesh on your midriff, upper arm, or thigh? Do you deliberately wear loose clothes so that your real shape is hidden? Are your body measurements larger than they used to be? If so, it is a good idea to think seriously about losing weight for the sake of your health and appearance.

Food groups

The no-counting method of dieting is basically a calorie-controlled diet, but one in which you do not need to weigh all your portions of food. The foods are divided into three groups, by high, medium, and low calorific value, and the aim is to eat as much as you please of the lower group, and to avoid the foods in the high group. Foods in the middle group should be eaten only in moderation.

a This is the group of forbidden foods, such as: cakes, cookies, candy, pastries, chocolate, nuts, cream, sugar, fried foods, sausages, salami and bologna, avocado, puddings, sauces, jellies, honey, mayonnaise, and oily salad dressings.

b This is the group of medium calorific value, with foods such as: lean meat, mackerel, herring, anchovies, bananas, crackers, bread, rice, pasta, whole milk, eggs, cheese, duck, and goose.

c This is the group of very low calorie foods, such as: onions, peppers, tomatoes, mushrooms,


a High calories



b Medium calories



c Low calories



lettuce and other salad greens, beets, apples, oranges, lemons, grapefruit, tangerines, melon, strawberries, raspberries, blackberries, peaches, nectarines, loganberries, sugar substitutes, diet soda, skim milk, black tea and coffee, unsweetened fruit juice, and water.

Attitude to eating

If you are trying to lose weight, and then to maintain that weight loss afterward, it will probably be necessary to alter the role that food plays in your life. Studies of overweight people show that they generally do not eat to satisfy hunger, but rather because they have uncontrolled urges for a particular food, or because food is too easily available. An overeater will not stop when his or her body has had enough, but will continue until the food is finished. Your body will need gradual re-education until you eat only when hungry, and stop eating when your hunger has been satisfied.

Eating patterns

Overweight people are open to temptation from snacks, candy stores, takeout foods, leftovers on plates, and eating while preparing food. One of the keys to successful dieting is to remove sources of temptation or to learn to overcome them. Help yourself to stop snacking by removing all tempting food from the kitchen; have only low-calorie foods available. Never buy food when you are hungry; go shopping after a meal so that your appetite will not be stimulated.

Nutritional needs

Malnutrition should not be a problem in the West, but ignorance of the body's nutritional needs may put some people at risk. Age, sex, body size, activity level, pregnancy, and illness are all factors that influence these needs.

Protein intake can be between 1–3 ounces (35–85 g) per day, fat no more than 2 ounces (65 g) per day, and carbohydrates between 9–20 ounces (250–560 g) per day. The average person will be able to get all the

nutrients they need from a daily diet that includes two servings (5–6 ounces/142–170 g) of meat, fish, poultry, eggs, beans, peas, or nuts; two to three cups of milk or the equivalent in cheese or yogurt (preferably fat-free or low fat); five to seven servings of fruit or vegetables (to include both); and six to nine servings of cereal, bread, pasta, or rice (a serving is a slice of bread or a cup of cereal). Foods high in fat or sugars are best avoided.

Pregnancy

During pregnancy, a well-balanced diet is essential for the development of the fetus. A pregnant woman needs about 15 percent more calories, and may need extra folic acid (the need doubles at this time), iron, and calcium. Weight gain should be about 20–25 pounds (9–11 kg).

Indigestion

Dyspepsia or indigestion is one of the most common digestive problems. Symptoms are nausea, heartburn, abdominal pain, discomfort or distension. Causes may be psychological, or be due to food intolerance or disease. A bland diet and regular meals may help.

Hypertension

Two dietary factors may predispose a person to high blood pressure (hypertension)—obesity and a diet high in salt. Weight loss and a low sodium diet are usually recommended to reduce blood pressure. Foods to be avoided include butter, bacon, and canned fish.

Illness and convalescence

People who are ill or recovering from illness may have little appetite and low food tolerance. Ample protein and energy foods are needed to repair the drain on the body's reserves and to restore the person's strength. Immobilization in bed may have caused demineralization of the bones. Milk is a good source of calcium to correct this.



Effects of inadequate nutrition

There are many theories and much research into the link between diet and disease. Here are some of the most commonly known effects of malnutrition.

1 The hair may become dull and brittle, or it may fall out or change color.

2 Headaches may be related to vitamin deficiency.

3 Nightblindness may arise from a lack of vitamin A.

4 The tongue may become inflamed as a result of a number of vitamin deficiencies.

5 Bleeding gums may be a sign of scurvy (vitamin C deficiency).

6 Enlargement of the thyroid gland (goiter) may be linked to iodine deficiency.

7 Rashes, itching, soreness, scaliness, and cracking of the skin may be the sign of a number of vitamin deficiencies.

8 Softening of the bones may be a sign of rickets (lack of vitamin D).

9 Loss of motor function in the legs may be sign of beriberi (lack of vitamin B₁, or thiamine).

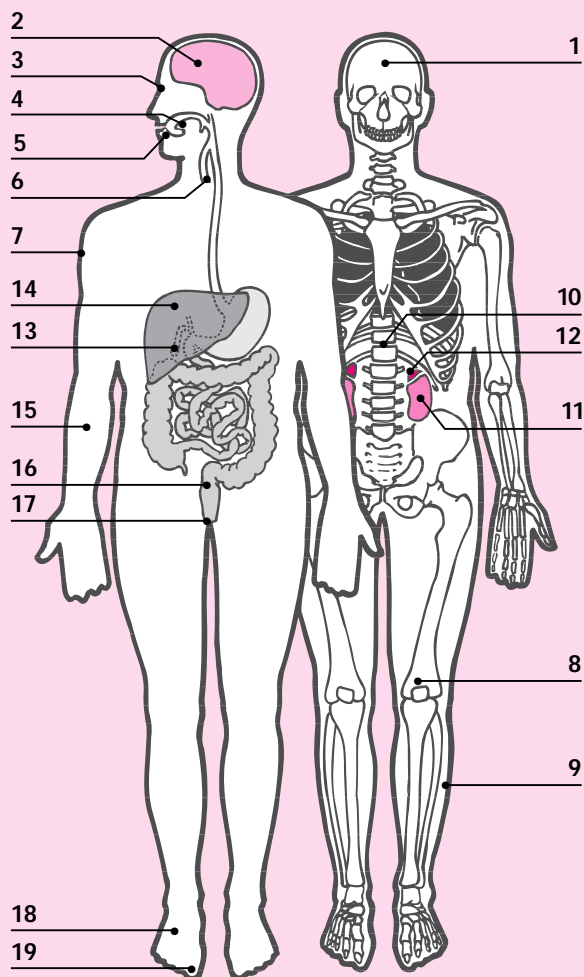
10 Lesions in the spinal cord may be a sign of vitamin B₁₂ deficiency.

11 Stones may form in the kidneys as a result of insufficient fluid; obese people may be prone to kidney failure.

12 Adrenal glands may enlarge as a result of salt deficiency (related to the B vitamins).

13 The formation of gallstones is associated with a fatty diet.

14 Too much alcohol may cause cirrhosis (scarring) of the liver.



15 Insufficient iron will cause anemia.

16 Constipation can be caused by lack of fiber in the diet.

17 Piles (hemorrhoids) may also be a result of lack of fiber.

18 Swelling and painful feet may be a sign of vitamin B₁₂ deficiency.

19 Numbness in the toes may be a sign of vitamin deficiency. Attacks of gout are connected with overindulgence in rich food and alcohol.

Digestive disorders

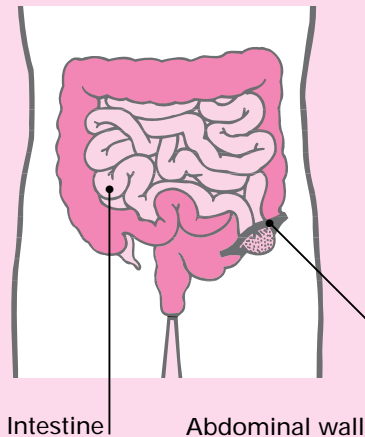
Almost all general digestive disorders, such as indigestion, gastroenteritis, and constipation, respond to self-help that can be given in your own home or workplace. For instance, drinking plenty of fluids is a commonsense way of restoring body fluids lost through vomiting or diarrhea, and by taking care about what, when, and how you eat, you may be able to heal a peptic ulcer. Modifying your daily pattern of activity also helps with the

pain and discomfort of some digestive ailments. People with esophagitis (inflammation of the esophagus) benefit from lying down after eating, while hiatus hernia sufferers are better if they stand after meals. Care with lifting heavy loads may prevent a hernia, and will certainly reduce the risk of worsening an existing one. Of course, medical help is needed to establish diagnosis and treatment of serious conditions.

Types of hernia

Hernias (ruptures) occur where part of the intestine pokes through a weak part of the abdominal wall. Inguinal hernia occurs in males of all ages where the thigh meets the abdomen. Femoral hernias (commonest in women) occur at the top of the thigh. Umbilical hernias (often seen in infants) protrude from the navel. Some hernias regress naturally, and others can be pushed back into place. But if a hernia gets nipped at its entrance, the resulting strangulated hernia causes pain and vomiting, and needs urgent medical aid. In hiatus hernia, the upper stomach bulges up where the esophagus passes through the diaphragm.

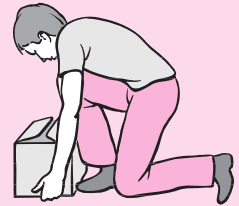Hernia



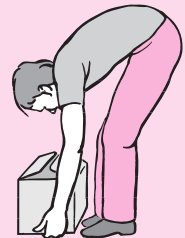Avoiding hernias

Some hernias occur because channels fail to close properly during pre-birth development, but most hernias develop when muscular exertion forces the abdomen through a weak part of the abdominal wall. To avoid this kind of hernia, do not exert unusually sudden

How to lift a load



How not to lift a load



muscular force that raises pressure within the abdomen. Do not cough violently or strain the bowels. Raise any heavy weight from a squatting position rather than bending and lifting from a standing position. Using the correct lifting posture helps to prevent back strain as well as hernias.

Digestive tract troubles

1 Dyspepsia, or indigestion, usually results from excess acid secreted in the stomach. Eating too quickly, or taking too much food in one meal, may also cause indigestion.

2 Gastroenteritis is inflammation of the stomach, and possibly the entire digestive tract. Food poisoning, allergy, irritant foods, or chemicals may be to blame.

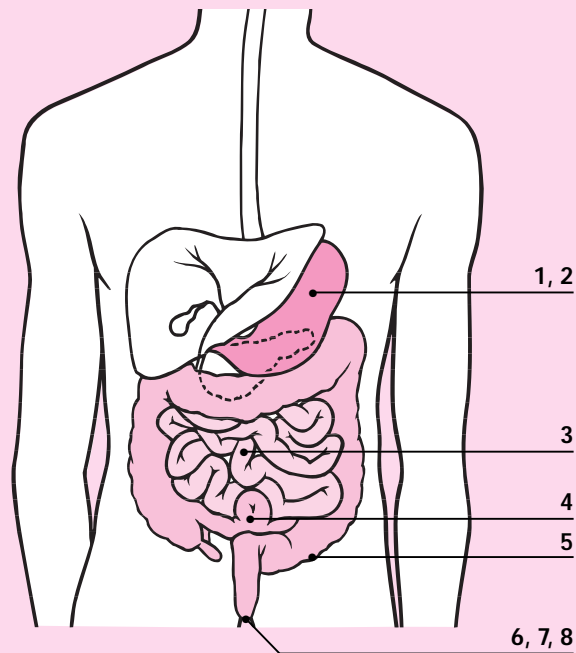
3 Umbilical hernia is a navel swollen by a protruding piece of intestine. Common in babies, this usually needs no treatment and regresses by age two.

4 Inguinal hernia of the groin may get pinched, causing acute pain, vomiting, and swelling in the groin. If left untreated, peritonitis (inflammation of abdominal membranes) may result.

5 Femoral hernia, occurring at the top of the thigh, may also get strangulated.

6 Diarrhea happens when the bowels try to purge themselves of some irritant or poison. The bowels respond to irritation by producing extra mucus and speeding up the rate at which waves of muscular contraction force feces through the bowel. This means there is less time than usual for the intestines to absorb water. This usually results in colicky pain, and an irresistible urge to open the bowels frequently, passing movements that are thin and watery. Seek medical advice if diarrhea is severe or persistent, or if it alternates with constipation.

7 Constipation is likely to happen to anyone who eats little food, takes little fluid, has a diet low in fiber, takes no exercise, or persistently ignores the



need to open the bowels. Habits such as hurrying to work straight after breakfast, or rising late in the morning, may be to blame. Other possible causes of constipation include depression, some medicines, and certain physical diseases. All basically healthy people can cure constipation by taking exercise, drinking plenty of fluid, and including sufficient fiber in the diet.

8 Food poisoning almost always occurs as a result of poor food hygiene. Symptoms typically include vomiting, diarrhea and abdominal pain; they may start up to 24 hours after eating food contaminated with bacteria, but within an hour if the poisoning is caused by bacterial toxins. Take plenty of fluids, and call a doctor if the symptoms are severe or last for over 24 hours.

The digestive journey begins in the mouth. The main process at this stage of the journey is mechanical digestion, which involves the physical breakdown of food by chewing with the teeth and tongue, and the passing of food to the stomach by muscular contractions called peristalsis. There is also some chemical digestion, which occurs as a result of saliva being mixed with the food in the mouth. Saliva contains enzymes that break down carbohydrates.

Digestive system key words

Adenoids Tonsils (lymphoid tissues that protect against bacteria) located at the back of the nose cavity.

Epiglottis A flap of cartilage behind the tongue that is closed during swallowing to help stop food from entering the larynx and windpipe.

Esophagus (or gullet) The muscular tube through which food travels between the pharynx and the stomach.

Larynx The voice box, located just below the pharynx.

Nasopharynx The part of the pharynx above the soft palate.

Palate The roof of the mouth, divided into the anterior hard palate at the front, and the posterior soft palate at the back.

Pharynx The throat.

Salivary glands The lingual, parotid, sublingual, and submandibular glands, which produce saliva.

Taste buds Tiny sensory organs (circumvallate papillae, filiform papillae, fungiform papillae) on the tongue and palate.

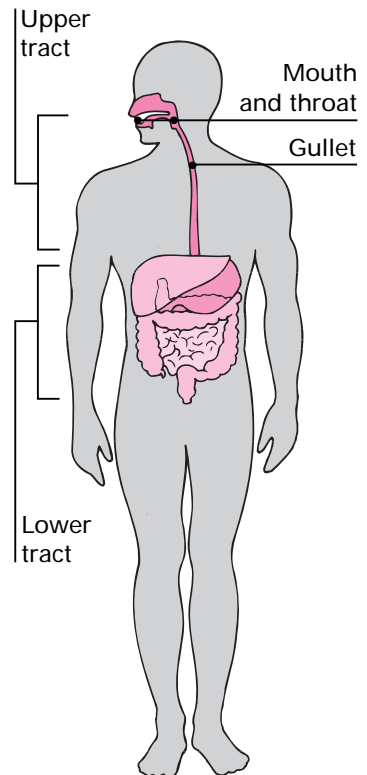
Teeth Bonelike structures in the jaws. Different types (incisors, canines, premolars, molars) are specialized to pierce, tear, crush, and/or grind food.

Tongue A mobile, muscular organ in the mouth, involved in tasting, chewing, swallowing, and speech.

Trachea (or windpipe) An air passage leading from the base of the larynx to the top of the lungs.

Uvula Conical flap of soft tissue hanging down from the soft palate, which helps to stop food and liquid from entering the nose.

Upper & lower tract



The upper digestive tract is the place where food first enters the digestive system. It consists of the mouth, throat, and gullet, or esophagus. The throat and esophagus connect the mouth with the stomach. Once food reaches the stomach, it enters the lower digestive tract (see Section 4).

Structure and functions of the mouth

The mouth, or oral cavity, is a mucosa-lined cavity housing the teeth and tongue (accessory digestive organs). It is made up of the lips, cheeks, and palate.

Lips

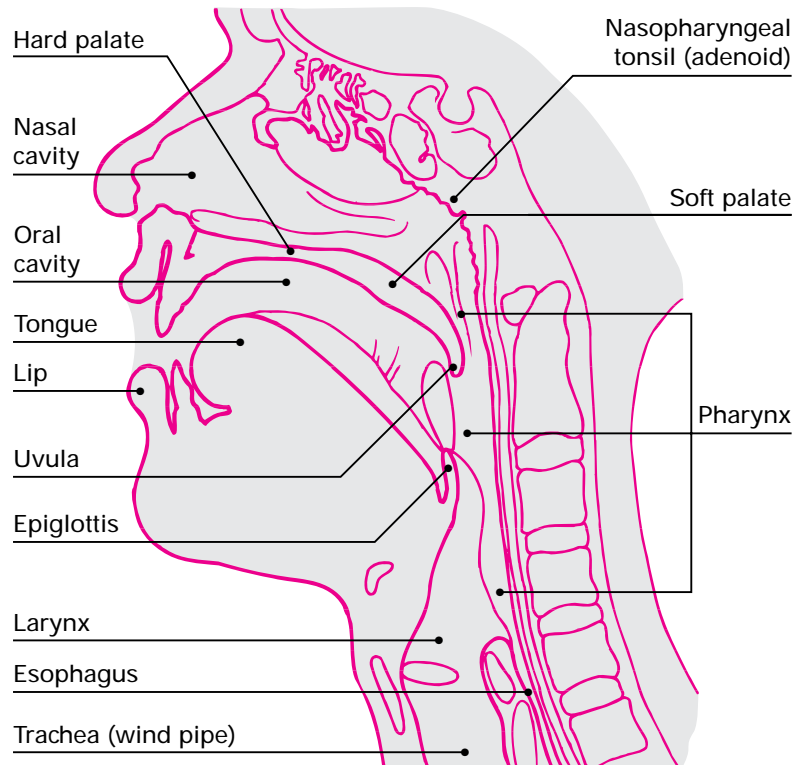
The lips, or labia, are folds of skeletal muscle with a thin covering of epithelium (layer of cellular lining tissue). The functions of the lips are:

- To hold food in the mouth and keep it in place for chewing;
- to protect the anterior (front) opening of the mouth; and
- to judge the texture and temperature of foods.

Cheeks

The main components of the cheeks are the buccinator (cheek) muscles. The cheeks are lined with cellular tissue, which protects against abrasion from food particles. The main function of the cheeks is to keep food between the teeth during chewing.

Section of the head



Palate

This is the roof of the oral cavity. The front part, the hard palate, is supported by bone. The rear part, the soft palate, is made up of skeletal muscle and connective tissue. The soft palate ends in a projection called the uvula. The main function of the palate is to prevent food from entering the nasal cavity

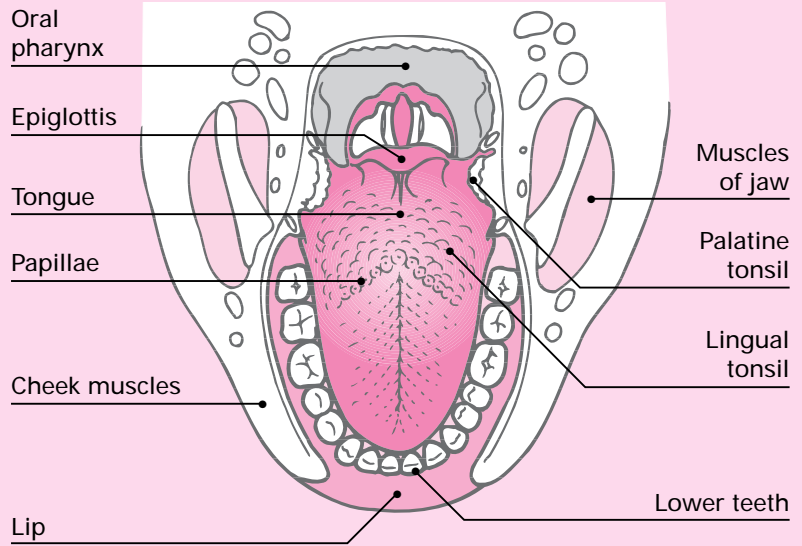
during swallowing. This is achieved by the soft palate and uvula rising to cover the nasopharynx (entrance to the nasal cavity). The palatine tonsils (paired masses of lymphoid tissue) are at the rear of the oral cavity. The tonsils have no digestive function but defend against bacteria that enter the mouth.

Tongue

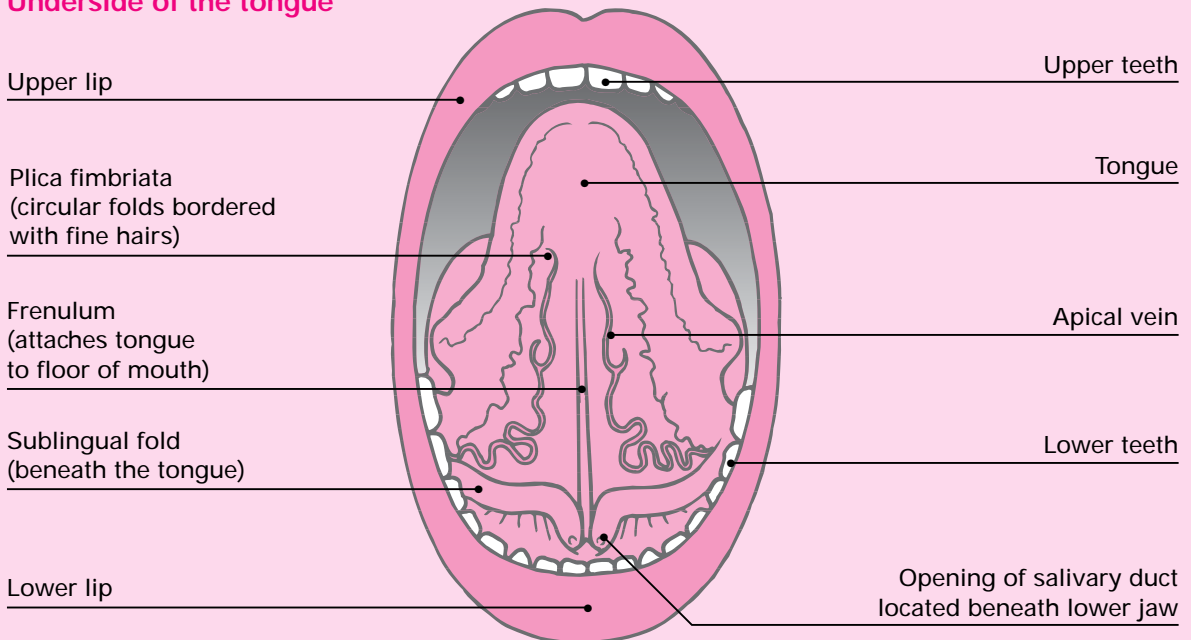
The tongue is made mainly of skeletal muscle covered with a mucous membrane. A thin membrane called the frenulum anchors the tongue to the floor of the mouth.

The top surface of the tongue contains papillae, taste buds, and other structures associated with sensing different tastes. The front of the tongue manipulates food during chewing, and the base helps in shaping the food for swallowing.

Cross section through the mouth



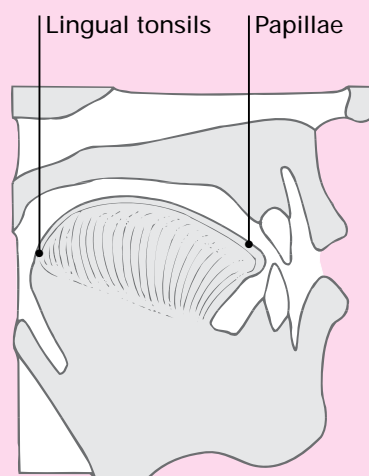
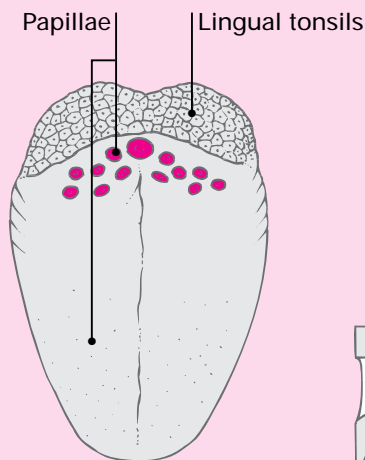
Underside of the tongue



Structure and functions of the tongue

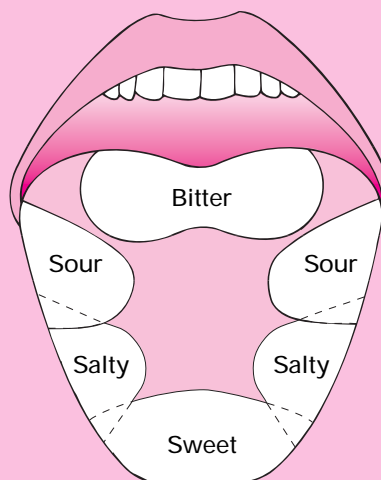
Intrinsic muscles within the tongue allow it to alter its shape. Extrinsic tongue muscles are attached to the skull bones and soft palate, and allow the tongue to alter its position. Various types of papillae (small bumps) project from the tongue's upper surface. Embedded in the rear surface of the tongue are the lingual tonsils. The main functions of the tongue are:

- manipulating food for chewing;
- mixing the food with saliva, shaping it into a bolus and directing it toward the pharynx for swallowing;
- stimulating saliva secretion;
- providing friction for manipulating foods via the papillae (which help the tongue to grip food); and
- defending against bacteria with the lingual tonsils.



Taste regions

In the skin around the base of the papillae (small bumps) are tiny sensory structures called taste buds, which are connected to a main nerve by a bundle of nerve fibers. Taste buds on different parts of the tongue are sensitive to different tastes—bitter at the back, sweet at the front, and sour or salty at the sides.

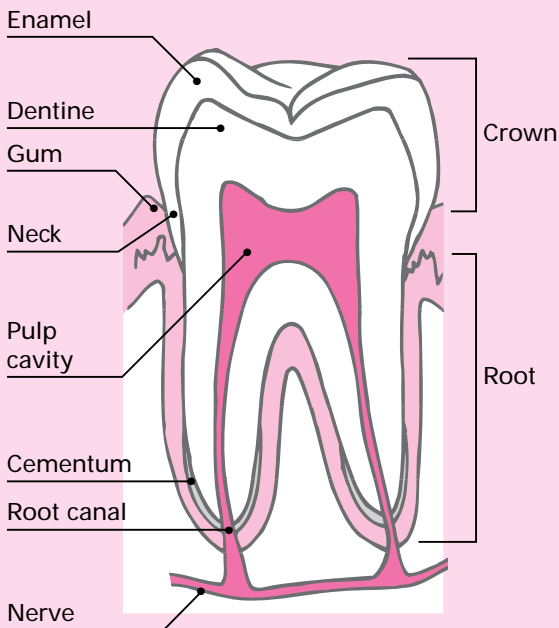


Structure of teeth

A typical tooth consists of three main parts: the crown, the neck, and the root. The crown is the part that projects upward from the gum. It is covered in enamel—the hardest substance in the body. The root fits into a socket in the upper or lower jaw. The neck joins the crown to the root.

It is a narrow part of the tooth, which is surrounded by the gum. In the center of a tooth is a pulp cavity, which is a soft core of connective tissue that contains nerves and blood vessels.

Structure of a permanent molar tooth



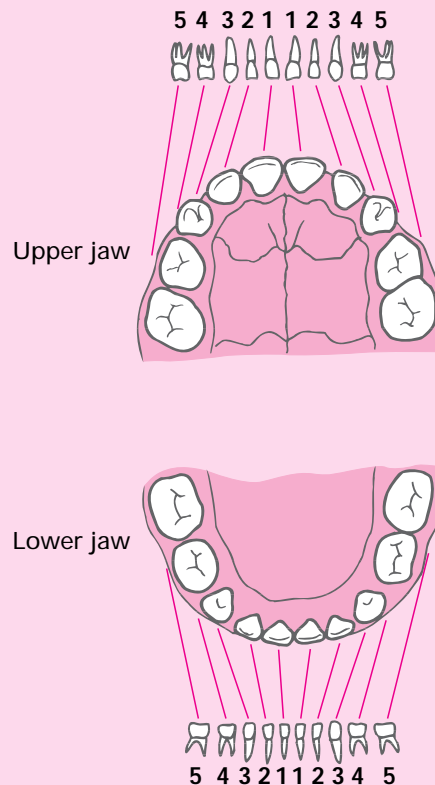
Deciduous dentition

Six months or so after birth, the first deciduous (milk or baby) teeth push through the gums. By the age of two, a child usually has 20 baby teeth.

At about six years of age, the first permanent teeth start to push out the baby teeth. By the age of 17–24 years, a full set of 32 adult teeth is usually present in the gums.

Teeth of a young jaw

- 1 Central incisor (6–8 months)
- 2 Lateral incisor (8–12 months)
- 3 Canine (15–20 months)
- 4 First molar (12–16 months)
- 5 Second molar (20–40 months)



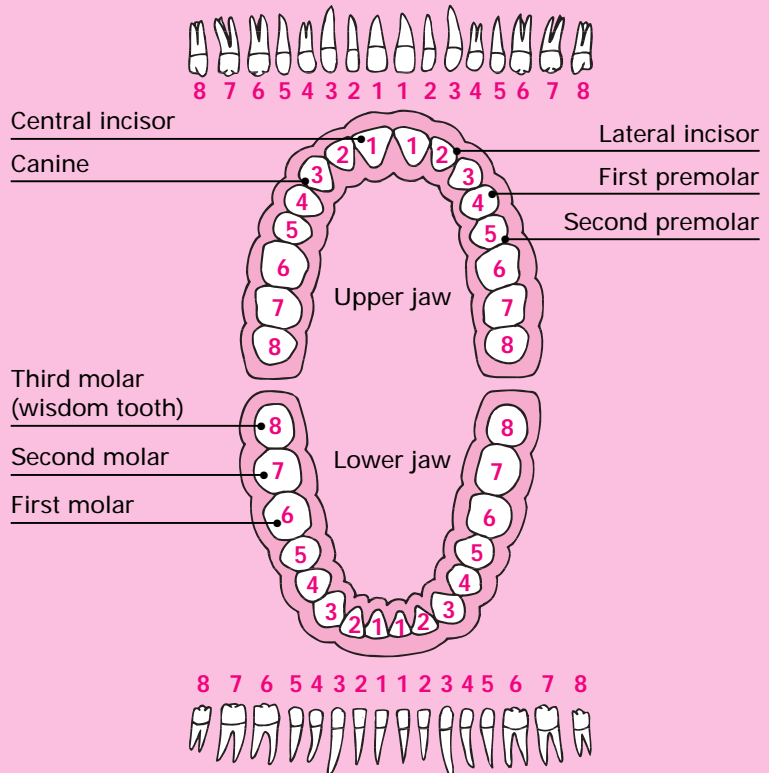
Function of teeth

Teeth are hard structures set in the jaw. There are four types, each with a different shape and function. All teeth are involved in the process of mastication (chewing). This is a form of mechanical digestion involving the mouth, the teeth, and the tongue. The purpose of mastication is to reduce the food to a soft, flexible mass that is easily swallowed.

Mastication occurs in two stages:

- 1 incisors and canines shear the food;
- 2 as the jaws open and close, the tongue pushes food between premolars and molars, which grind the food.

Individual teeth of the jaw



Tooth

Incisor

Shape

- chisel-shaped with sharp edges

Function

- biting into and cutting food

Canine
(cuspid or eyetooth)

- conical with cusps (points)

- grasping, shredding, and tearing food

Premolar
(bicuspid)

- flat surfaces with two distinct edges

- grinding food

Molar

- large with flat surfaces and rounded edges

- crushing and grinding food

Dental hygiene

Dental cavities are one of the most common medical problems in many Western countries. Cavities occur mainly because of the high sugar content of the Western diet, made worse by poor personal dental hygiene. Some people have a full set of dentures by middle age, but this can be avoided if the teeth and gums are adequately cared for through childhood and adulthood. Dental problems can be minimized by brushing and flossing the teeth regularly, visiting the dentist two or three times a year, and cutting down on sweet and starchy foods, especially between meals.

Teeth facts

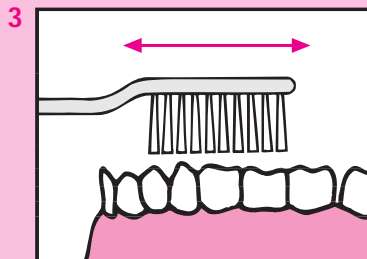
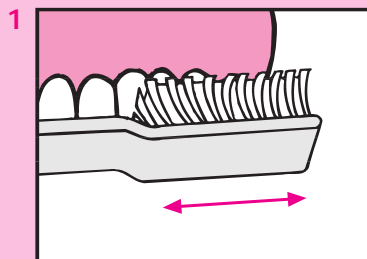
- Bacteria in the mouth feed on sweet or starchy food, producing acids, which cause cavities in the teeth.
- Dentists clean and fill tooth cavities to prevent further tooth decay.

Brushing the teeth

Brushing is one way to fight tooth decay, as it removes most of the plaque and bacteria from the surfaces of the teeth. Your toothbrush should have a small head, with medium-firm multitufted nylon bristles; it should be changed as soon as the bristles begin to spread. Teeth should be brushed after every meal, as acid begins to form immediately; plaque collects in a matter of hours. Even babies' and toddlers' teeth should be brushed.

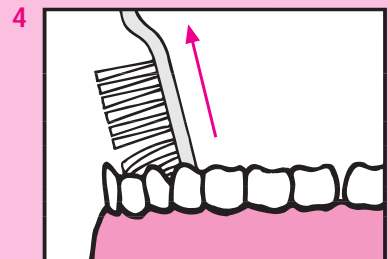
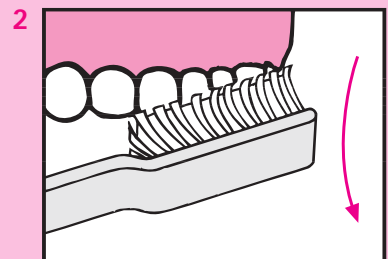
The illustrations show brushing techniques recommended for maximum efficiency in plaque removal.

1 Place the brush against the teeth as shown, and move it slightly from side



to side so that the bristles reach into the gap between the teeth and the gums.

2 When the bristles are well positioned, brush away from the gums with a slightly rocking action. Repeat steps 1 and 2 on the insides and outsides of the top and bottom teeth.



3 Brush back and forth across the top surfaces of the teeth.

4 Brush the insides of the front teeth by tilting the brush and brushing away from the gums. After brushing, use dental floss to remove any plaque remaining in the spaces between the teeth.

Tooth and gum problems

The illustration on the right shows some of the common problems that may arise as a result of poor dental hygiene.

1 Discoloration of the tooth; this may be a result of smoking, or excessive consumption of tea or coffee, or it may be an indication that the pulp at the center of the tooth is dead. Some drugs may cause the permanent discoloration of children's teeth.

2 Small cavity; this cavity, caused by tooth decay, is still confined to the enamel of the tooth and has not yet reached the sensitive dentine and pulp in the center of the tooth.

3 Large cavity; here the tooth has decayed right down to the central pulp where the nerves of the tooth are located. This causes pain and sensitivity at first, and eventually the death of the pulp.

4 Plaque, a sticky, bacteria-filled film that builds up on the tooth as a result of ineffective cleaning. If plaque is not

removed, it hardens into a substance known as calculus or tartar.

5 Periodontal pocket caused by the breakdown of the bone and fibrous attachments holding the tooth in the gum. As more of the periodontal attachments decay, the tooth loosens and finally drops out.

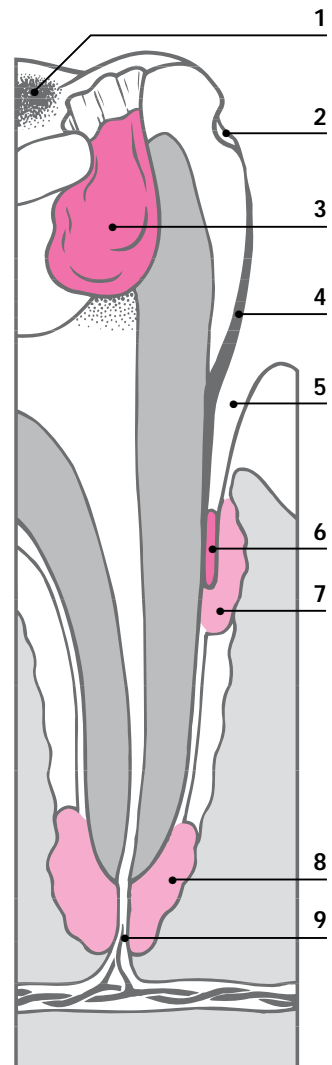
6 Debris, plaque, and tartar, collected in the periodontal pocket. Even meticulous cleaning cannot remove debris that is located so far under the gum, and once pockets are formed, debris and plaque build up rapidly, leading to foul breath and infection.

7 Gumboil or periodontal abscess caused by the decay of debris in the periodontal pocket and subsequent infection.

8 Abscess at the base of the tooth, caused by bacteria in the decaying tooth pulp. Since the infection has no escape route, great pain is caused.

9 Loss of blood supply to the tooth causes death of the pulp, which in a healthy tooth has its own blood supply.

Section through a diseased tooth



Salivary glands

Most saliva is produced by the three large pairs of extrinsic (lying outside the mouth) salivary glands. These are the parotid, sublingual, and submandibular glands. The small intrinsic (lying inside the mouth) salivary glands, or buccal glands, are located in the mucous membrane lining the mouth. They secrete small amounts of saliva.

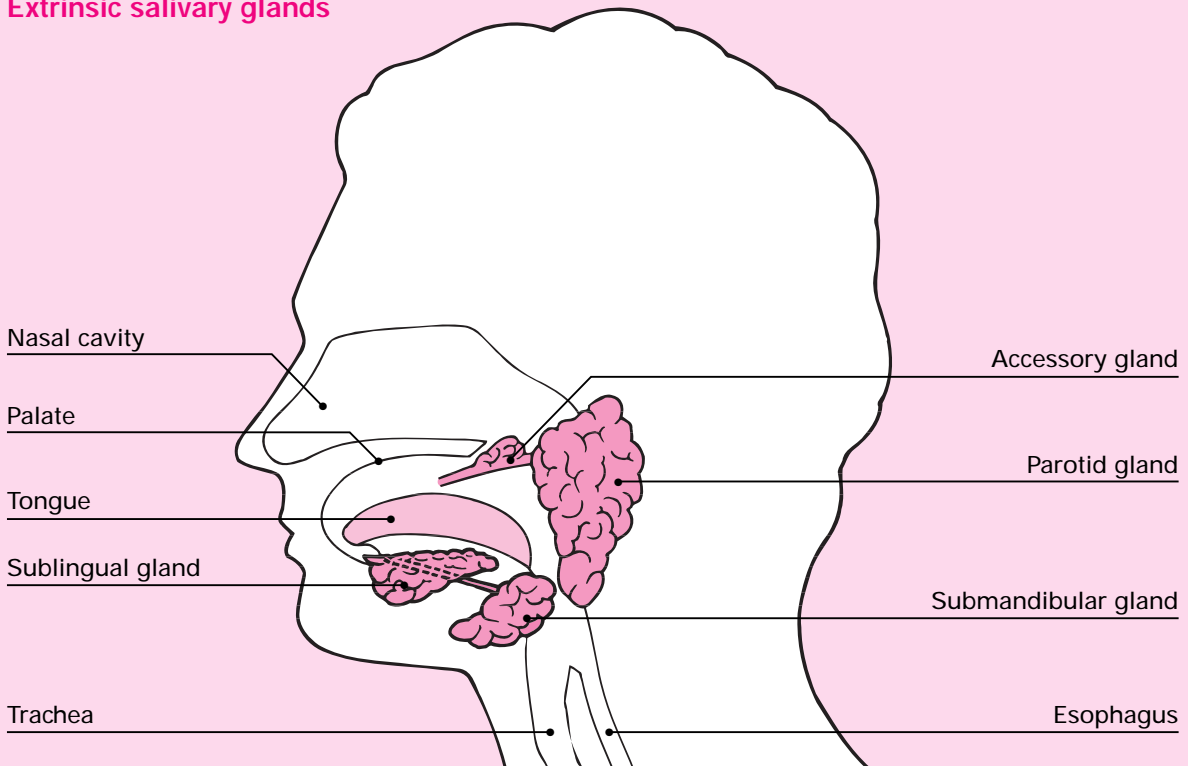
Digestive enzyme

Extrinsic salivary glands produce saliva from a mixture of cells secreting mucus and serous (thin, watery) fluid. Serous fluid contains the enzyme salivary amylase. This enzyme immediately begins the digestion of carbohydrates, breaking them down into maltose and dextrin.

Saliva facts

- The salivary glands secrete more than 36 fluid ounces (one liter) of saliva every day.
- Stomach acids inactivate salivary amylase minutes after it is secreted.
- Saliva is secreted upon smelling food and drink, before anything enters the mouth. A meal is said to be "mouthwatering" if it prompts this reaction.

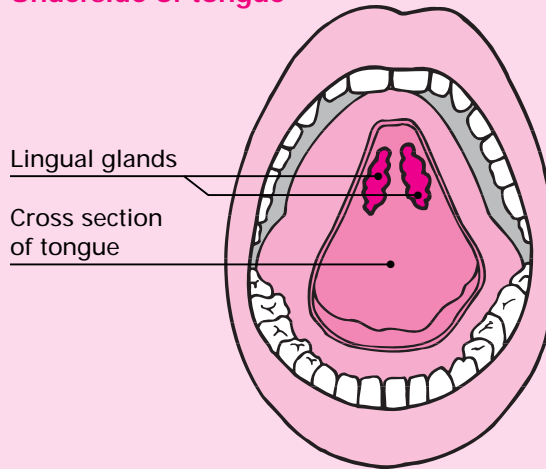
Extrinsic salivary glands



Sublingual glands

These are the smallest salivary glands, which are located at the front of the mouth just under the tongue. (Sublingual means “under the tongue.”) The secretion of the sublingual glands is high in mucus and low in salivary amylase. Tiny ducts leading from these glands carry their salivary secretions into the floor of the mouth.

Underside of tongue



Saliva

Saliva is more than 95 percent water. The rest is composed of various solutes (dissolved substances), chemicals, mucus (thick, slimy fluid), and waste materials.

In addition to starting the chemical breakdown of carbohydrates, saliva has a number of different functions. It moistens food with water, and lubricates it with mucus to help it slide easily

down the throat during swallowing. It also moistens and lubricates the mouth and the tongue, and dissolves solid substances, enabling food to be tasted with the taste buds. Saliva cleanses the mouth and the teeth, and inhibits the growth of bacteria. The high bicarbonate concentration of saliva helps to reduce tooth cavities by neutralizing the acidity of food in the mouth.

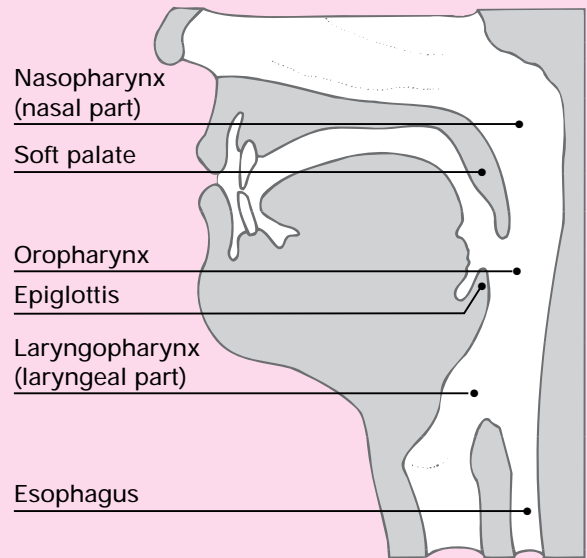
Salivation

The salivary glands are constantly secreting low levels of saliva to keep the mouth and throat moist. This process is known as salivation. The ingestion of food, however, stimulates the glands to secrete heavily. Increased secretion is activated both psychologically and

physiologically. In psychological activation, the smell, sight, and touch of food, or the sound of food preparation, can stimulate increased salivation. In physiological activation, the taste buds are stimulated by dissolved substances in ingested food.

Pharynx structure and function

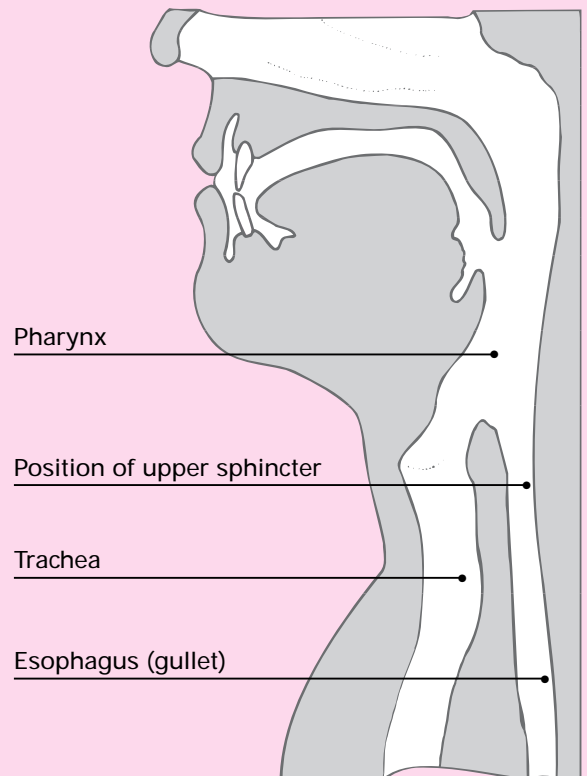
The pharynx (throat) is a tubelike structure made of muscle and lined with mucous membrane. It connects the back of the nose and mouth with the esophagus. The pharynx acts as an air passage during breathing and a food passage during swallowing. It propels food into the esophagus by means of peristalsis (wavelike contractions of its muscular walls). The pharynx can be divided into three parts: the nasopharynx (above the soft palate), the oropharynx (from the soft palate to the epiglottis), and the laryngopharynx (from the epiglottis to the esophagus).



Esophagus structure and function

The esophagus, or gullet, is a collapsible muscular tube through which food passes from the pharynx to the stomach. The passage of food in and out of the esophagus is controlled by upper and lower esophageal sphincters. These rings of muscle relax occasionally, allowing the contents of the digestive tract to pass through.

The upper sphincter links the pharynx to the esophagus. The cardiac (lower) sphincter links the esophagus to the stomach. The esophagus secretes mucus (thick, slimy fluid) to help the passage of food, and propels food along using peristalsis. Peristaltic waves are able to squeeze food from the throat down to the stomach in approximately one or two seconds.



Esophagus

The esophagus is about ten inches (25 cm) long. It is positioned just in front of the spine and behind the trachea, or windpipe. After passing through the lower neck and thorax, the esophagus passes through the diaphragm and joins the stomach in the abdominal cavity. The diaphragm is a sheet of muscle separating the chest cavity from the abdominal cavity.

Front view showing relative position

Cricoid cartilage in larynx

Sphincter

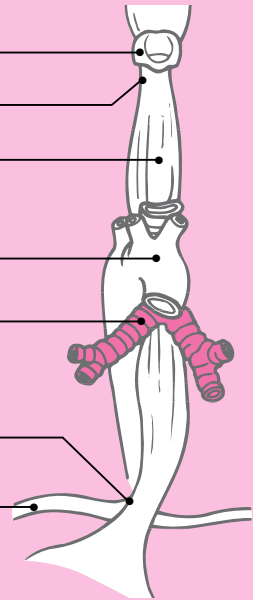
Esophagus

Aortic arch

Trachea

Diaphragmatic narrowing

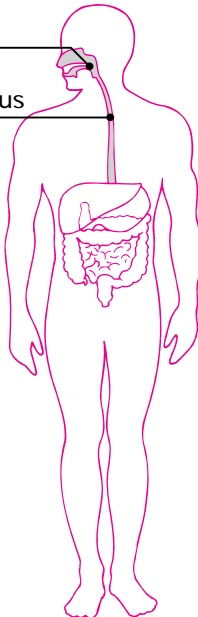
Diaphragm



Position guide

Pharynx

Esophagus



Side view

Spine

Sphincter

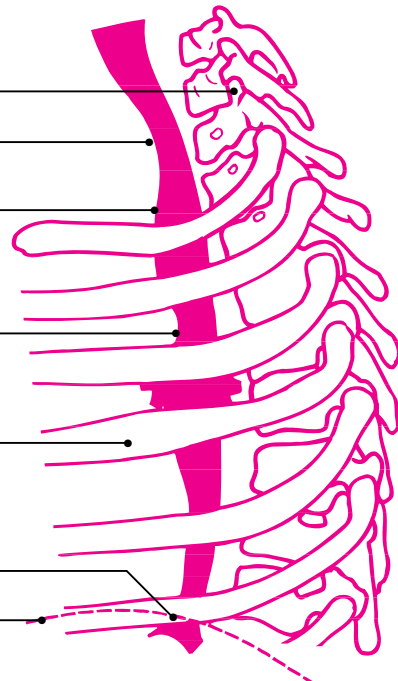
Esophagus

Aortic narrowing

Rib

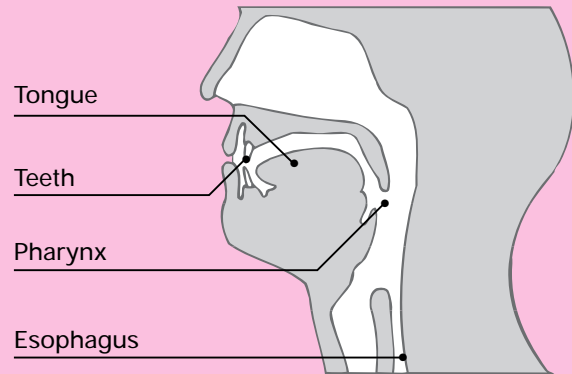
Diaphragmatic narrowing

Diaphragm



Swallowing

Swallowing, or deglutition, is the process that propels food from the mouth to the stomach. It involves the mouth, teeth, tongue, pharynx, and esophagus. The process involves two phases—the buccal phase and the pharyngeal-esophageal phase. Food does not normally enter the larynx during swallowing, but if food does go down the wrong way, the coughing reflex helps to prevent choking.



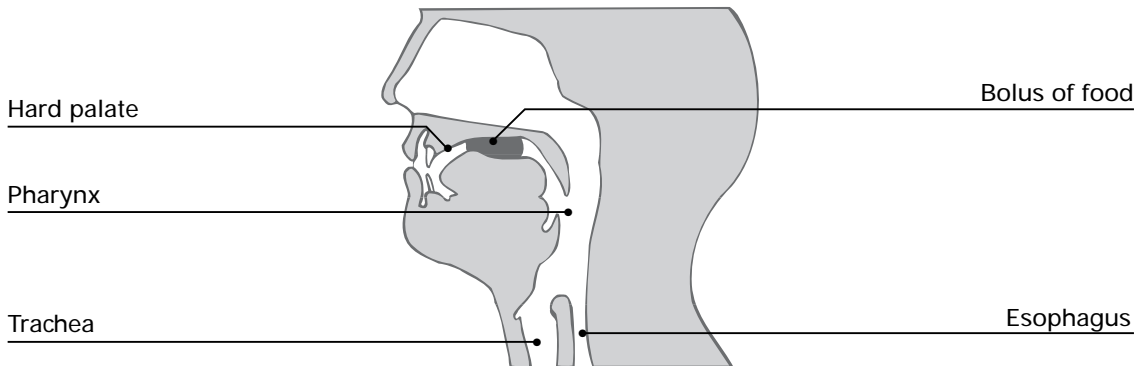
Buccal phase

Steps **1** through **2** are called the buccal (oral) phase. This stage is voluntary (under conscious control).

1 Food is prepared for swallowing in the mouth. This involves chewing the

food and mixing it with saliva to form a bolus (ball-like mass).

2 The tongue rises and presses against the hard palate. This forces the bolus of food into the pharynx.



Swallowing fact

- “Deglutition” comes from the Latin word *deglutire*, meaning “to swallow down.”

Choking fact

- A bolus of food entering the trachea, rather than the esophagus, causes choking.

Pharyngeal-esophageal phase

Steps 3 through 9 are known as the pharyngeal-esophageal phase. This stage is involuntary. It is a reflex (automatic) action triggered by food stimulating receptors in the pharynx.

3 The soft palate rises to cover the nasal cavity to stop food from entering.

4 The larynx (voice box) rises so that the epiglottis (flap of cartilage) covers its opening. This prevents food from entering the air passages to the lungs.

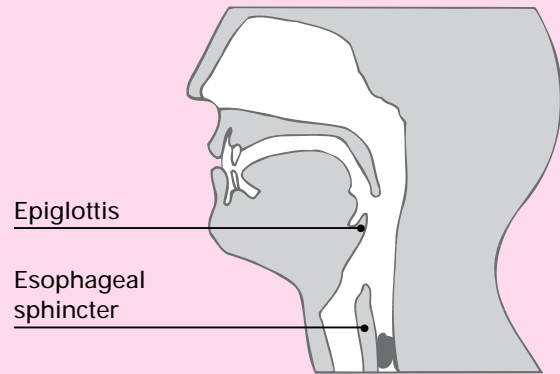
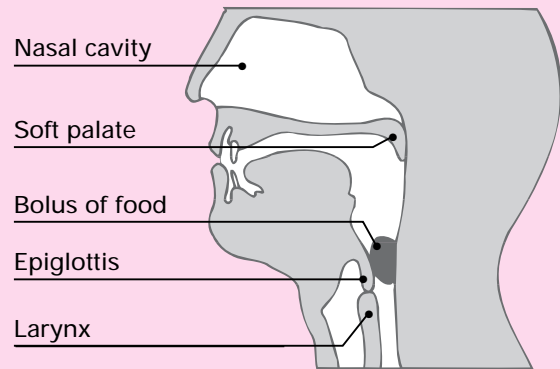
5 The upper esophageal sphincter relaxes.

6 Peristalsis (wavelike contractions of the muscular walls) force the bolus into the esophagus.

7 The upper esophageal sphincter contracts after food entry.

8 Peristalsis propels food down the esophagus.

9 The lower esophageal sphincter relaxes, allowing food into the stomach.



Choking and obstructions

Food, vomit, or other objects lodged in the windpipe may cause choking, unconsciousness, and death unless quick action is taken. Different techniques are applicable for children and adults. None should be attempted without training. If the person choking is an infant, grasp them by the legs and hold them upside down. Smack them sharply several times between the shoulder blades. If the child is very small, make sure the head is supported as you turn them upside down to avoid injury to the neck. Lay an older child across your knee, head hanging down, and use the same technique as for infants.

For adults, strike several sharp blows between the shoulder blades. If the smacking method is not effective with an adult, stand behind the person with your fists clasped against their upper abdomen, then push them up hard toward you. This is called the Heimlich maneuver. It is best not to try to remove an obstruction with a hooked finger or tweezers, since this almost always forces the obstruction farther down the windpipe.

If the victim fails to breathe after you have shifted the obstruction, give mouth-to-mouth or mouth-to-nose artificial respiration.

Detailed instructions for this can be found in first-aid manuals.

Upper digestive tract disorders

From the mouth to the esophagus, the upper digestive tract can be affected by a number of disorders that cause pain or discomfort, and prevent this part of the digestive system from working normally. Most of the disorders of the upper digestive tract are not serious, and will clear up with very simple treatment. Medical advice should be sought, however, if a condition persists for more than three weeks. Many symptoms are common to

different ailments, and medical help is also necessary to establish accurate diagnosis and treatment. Disorders that may occur in the mouth include bad breath, gum infections, salivary gland infections, and mouth ulcers. A mouth ulcer is a break in the lining of the mouth that uncovers sensitive tissue underneath. Good oral hygiene minimizes mouth disorders, which are often caused by bacterial infections.

Digestive tract troubles

Esophagitis (inflammation of the esophagus) occurs through irritation due to factors such as hot or abrasive foods, smoking, and infections.

Swallowing is difficult and there is burning chest pain. Bland foods, plenty of liquids, and lying down after meals may ease the condition.

Halitosis, or bad breath, is most often caused by neglecting dental hygiene. Sore throats, sinus problems, and digestive troubles can also lead to severe halitosis. A dentist will help to clear up any problems originating from the teeth or gums; other causes may require medical assistance.

Mouth ulcers can be caused by various

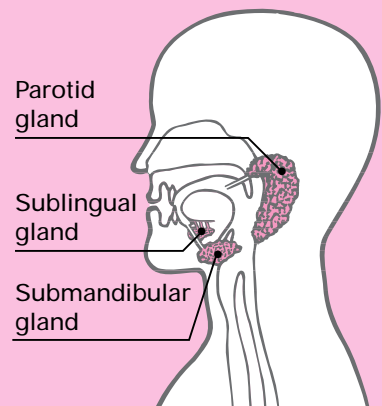
problems, such as stress, illness, or an injury to the mouth lining caused by a chipped tooth, a ragged filling, an illfitting denture, hot food, or biting the mouth or the tongue. Most ulcers heal up by themselves or with self-help, but persistent ulcers may be the first signs of cancer.

Gingivitis is an infection of the gums caused by their constant contact with plaque that has collected where the teeth meet the gums. Brushing the gums as well as the teeth will keep them healthy, and help to stimulate their blood supply.

Salivary gland infections may be caused by bacterial infections, while the parotid gland may become swollen and infected as a

result of mumps, which is the result of a viral infection.

Stones sometimes block the ducts of salivary glands (such as the submandibular glands) when chemicals in the saliva encrust minute particles. These stones can be removed, or an opening can be made near the duct to allow the saliva to bypass the duct.

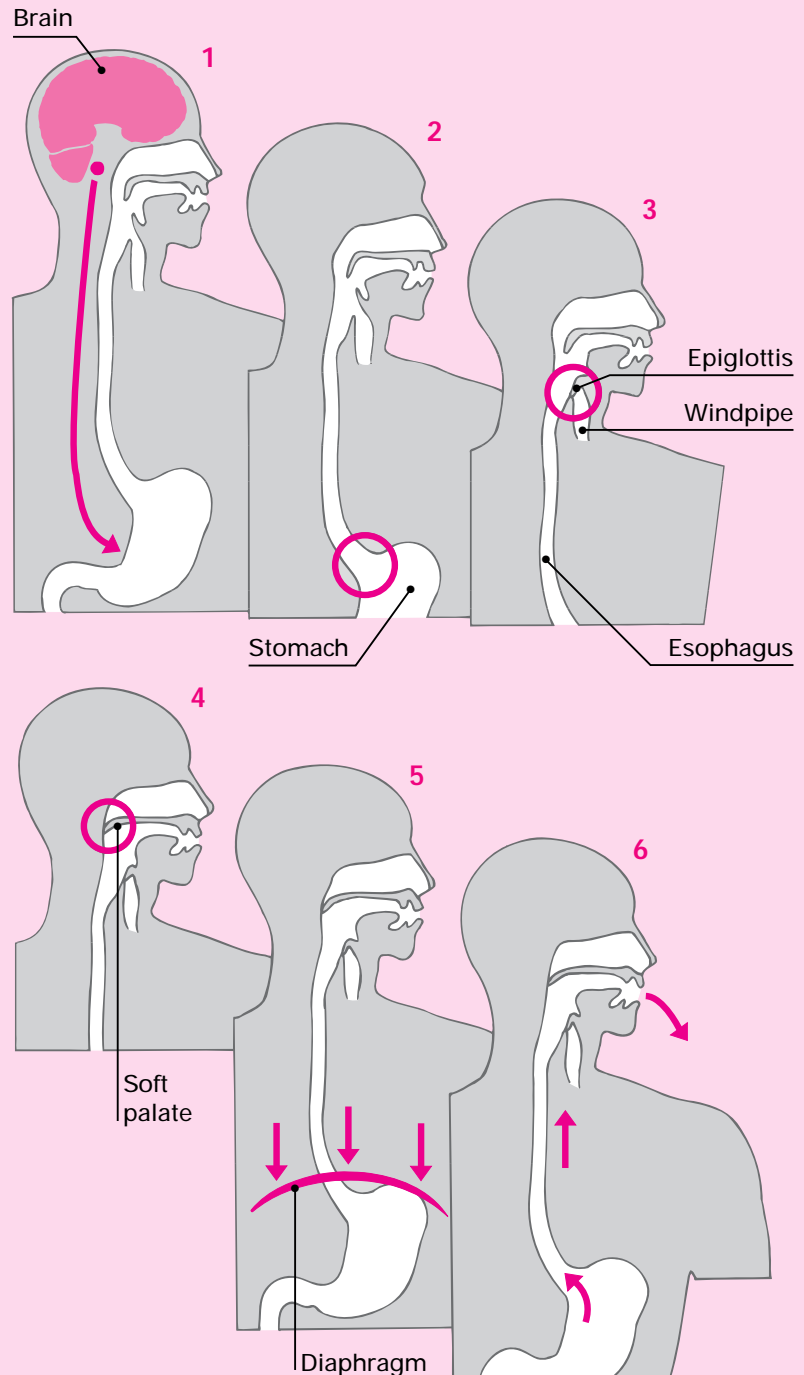


Vomiting

Vomiting, or emesis, is the involuntary expulsion of the stomach contents through the mouth. Many factors can trigger vomiting, such as: irritants in the stomach, high levels of some substances (such as alcohol) in the blood, pressure within the skull, disturbances of balance (such as motion sickness), overeating, or an emotional problem.

Emetic process

- 1** The emetic (vomiting) center in the brain is activated. Nerve messages sent to the abdomen trigger the vomiting reflex.
- 2** The lower esophageal sphincter relaxes.
- 3** The epiglottis closes the entrance to the larynx to prevent choking.
- 4** The nasal passages are sealed by the soft palate.
- 5** The diaphragm and abdominal wall muscles contract.
- 6** This contraction causes the contents of the stomach to be propelled upward by the pressure, through the esophagus, and out of the mouth.



As food journeys through the stomach and intestines, it is gradually broken down into a form that can be absorbed and used by body cells. The stomach stores food, and breaks it down with stomach acids and some enzymes. In the small intestine, enzymes complete the chemical breakdown of food, and nutrients are absorbed. The large intestine changes digested wastes into feces, which are excreted via the rectum and anus.

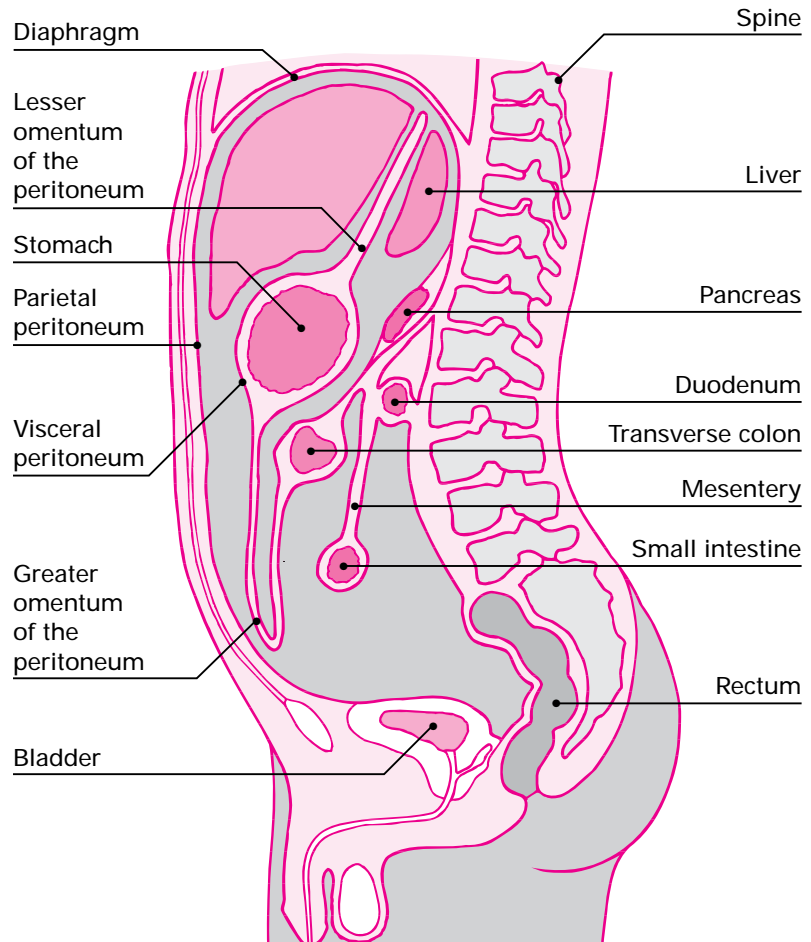
Digestion facts

- The stomach can hold about 54 fluid ounces (1.6 l) of fluid.
- *Omentum* is a Latin word meaning “fat skin.” The plural is *omenta*.

Peritoneum

A thin membrane of connective tissue—serous membrane—lines the closed abdominal cavity and covers the organs within it. This is called the peritoneum. The parietal peritoneum lines the abdominal cavity and the visceral peritoneum covers most of the organs. Between the parietal and visceral peritoneum is a space called the peritoneal cavity. Two extensions of the peritoneum are the mesentery and the greater omentum, which contains large amounts of fat. The greater omentum hangs down over the intestines like a large apron, protecting and insulating them. The lesser omentum extends from the liver to the stomach.

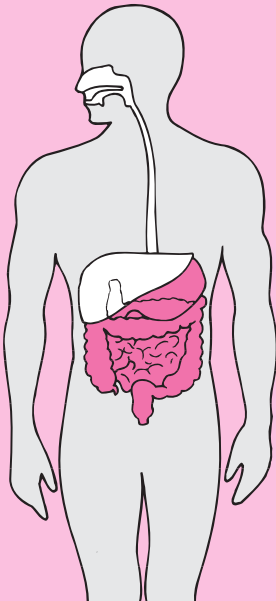
Side view of digestive organs in abdomen



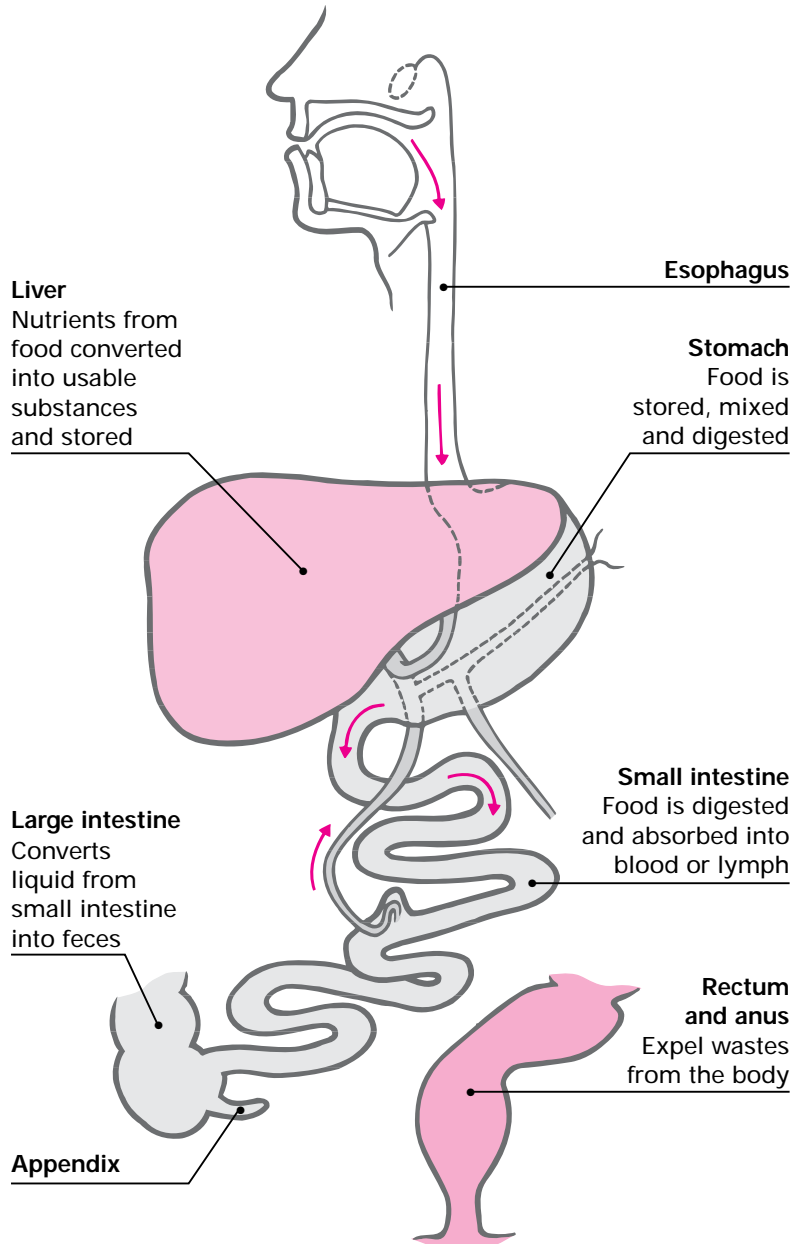
Lower tract

A bolus of food from the esophagus is propelled into the stomach, which is the widest and most expandable part of the digestive tract. When food reaches a muscular ring called the pyloric sphincter, it passes into the small intestine. This has a smaller diameter than the large intestine, even though it is four times longer. The large intestine is the final section of the digestive tract.

Locator



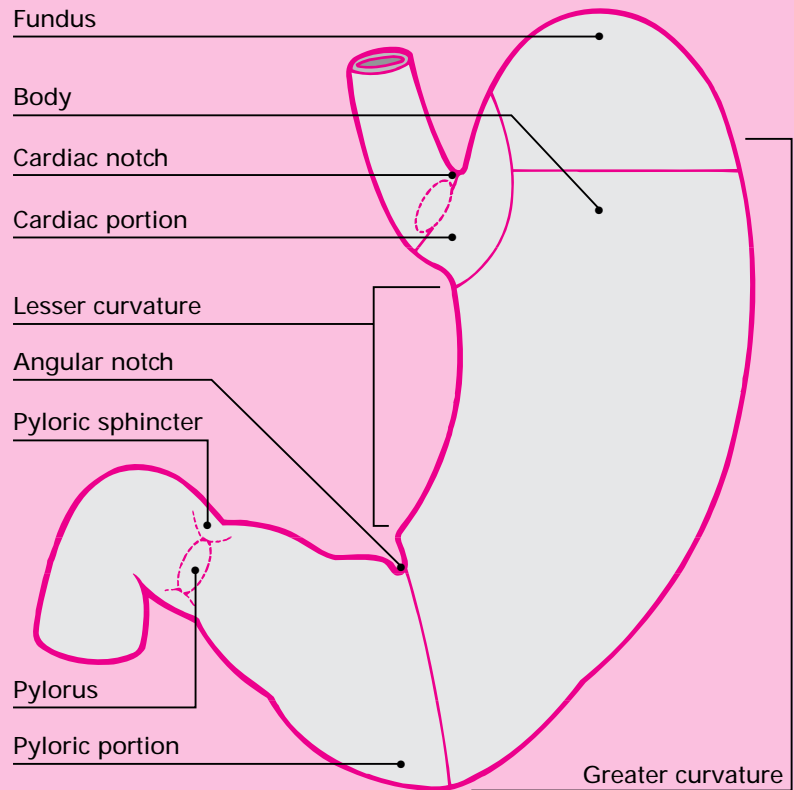
Route of food through lower tract



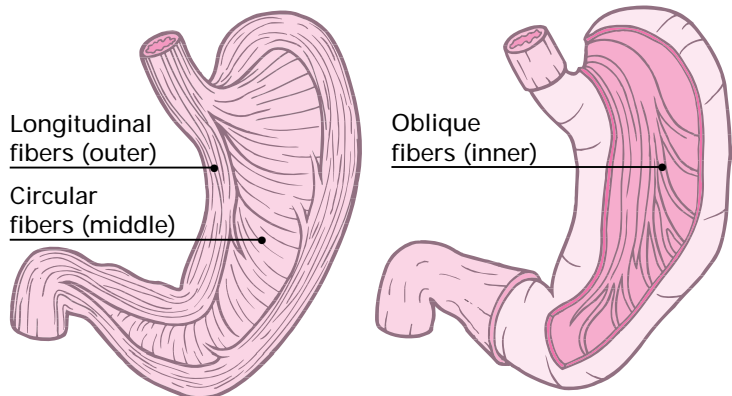
Parts of the stomach

The stomach is a hollow muscular organ that connects the esophagus with the duodenum (the uppermost part of the small intestine). It has a greater curvature toward the left side of the body and a lesser curvature on the right.

At the entrance to the stomach is the lower esophageal sphincter. At the exit to the stomach is the pyloric sphincter. The pyloric sphincter is more powerful than the lower esophageal sphincter, and surrounds an opening called the pyloric orifice, or pylorus. The stomach itself is divided into four major portions: the cardiac portion, the fundus, the body (large central area), and the pyloric portion. The fundus usually contains some swallowed air. The stomach wall is made up of three layers of smooth muscle—circular and longitudinal layers, and also an oblique (crosswise) layer. This makes the stomach strong and allows a great range of movements.



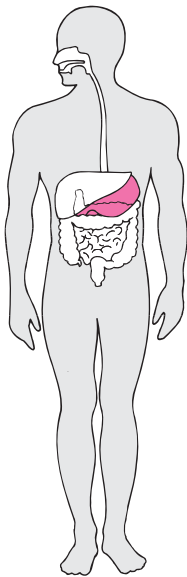
Muscles of the stomach wall



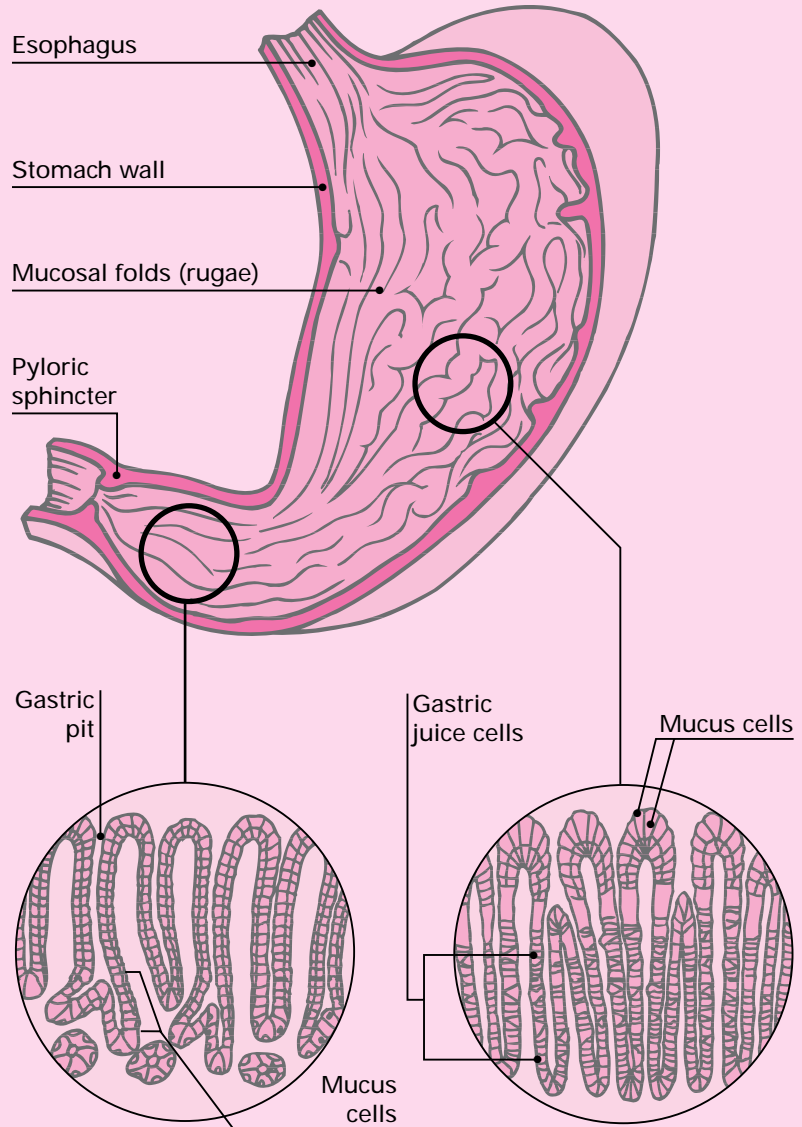
Stomach lining

The stomach is lined with glandular cells that secrete gastric juice (digestive fluid), and goblet cells that secrete mucus (thick, slimy fluid). Mucus lubricates and protects the stomach lining, and moistens food. Rugae (wrinkles and folds) in the stomach lining greatly increase its surface area. The rugae flatten as the stomach fills, allowing it to distend (expand).

Locator



Cross section of stomach



Magnified section of mucus membrane of pyloric region

Magnified section of mucus membrane of body of stomach

Functions of the stomach

The stomach has four main functions: digestion (both mechanical and chemical), absorption, propulsion, and storage. The muscular action of the stomach walls churns, mixes, and pummels the food. This physically breaks down the food (mechanical digestion) and mixes it with mucus and gastric juice to form chyme (semifluid mixture). Enzymes (proteins that act as biological catalysts) in the gastric juice

begin the breakdown of proteins (chemical digestion). Some water, salts, alcohol, and certain drugs (for example, aspirin) are absorbed in small quantities through the stomach lining into blood vessels. Peristalsis (wavelike contractions of stomach walls) propels food through the stomach and forces chyme through the pyloric sphincter. The stomach acts as a storage tank, reducing the need for frequent meals.

Muscular activity in the stomach

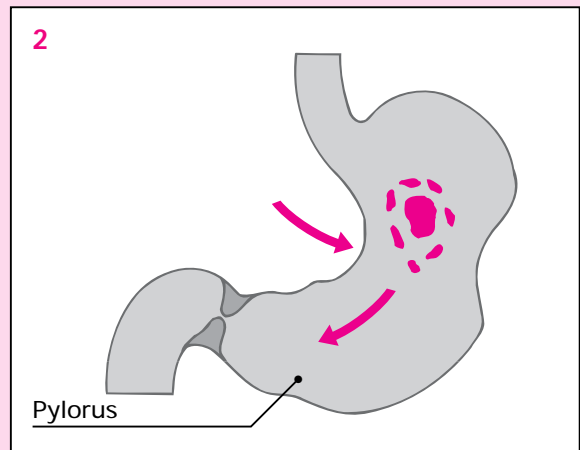
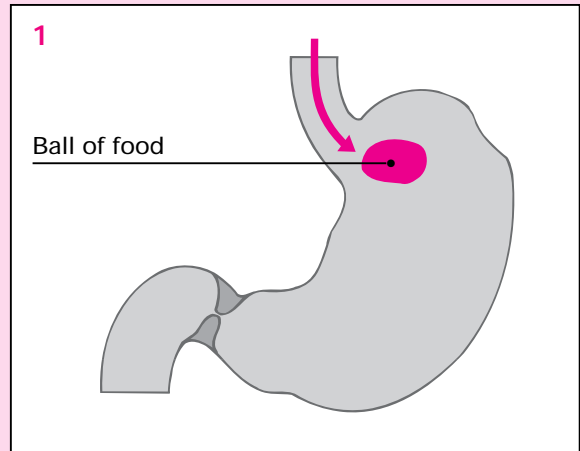
This is responsible for peristalsis, mixing actions, and the emptying of stomach contents. It is controlled by various mechanisms.

1 As the lower esophageal sphincter relaxes, food enters and distends the stomach. This expansion and gastric secretion (stimulated by contact with food) triggers gentle peristalsis.

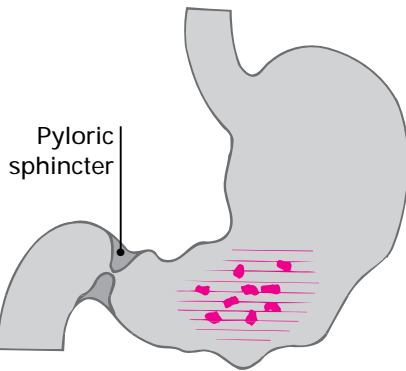
2 The food is mixed and moved toward the pylorus (lower region of the stomach). The pyloric sphincter remains closed throughout steps 1 and 2.

Stomach facts

- The lining of the stomach sheds about 500,000 cells per minute and is completely renewed every three days.
- The word "stomach" comes from the Greek word for "throat."

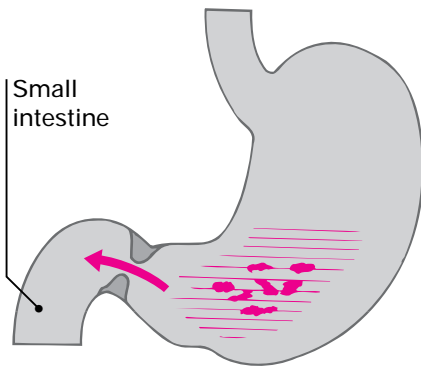


3



3 More vigorous peristalsis and mixing action take place near the pyloric sphincter, which relaxes. The lower esophageal sphincter remains closed (unless more food is traveling along the esophagus).

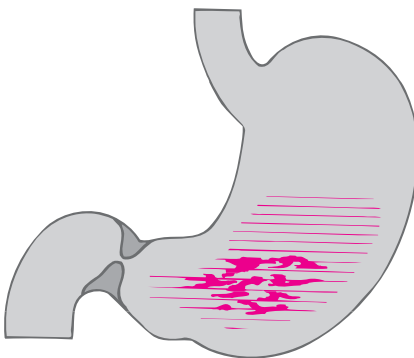
4



4 Peristalsis forces small amounts of chyme through the slightly open pyloric sphincter, and into the small intestine.

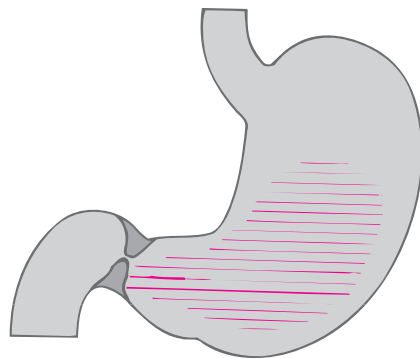
5 The presence of chyme stimulates receptors in the small intestine walls. These activate hormonal mechanisms to inhibit gastric secretion in the stomach. In turn, this reduces gastric activity, preventing further escape of chyme from the stomach.

5



6 Most material remains in the stomach for further mixing.

6



Gastric secretion

Gastric juice is a clear, colorless fluid secreted by the stomach in response to food. There are three phases that control this secretion.

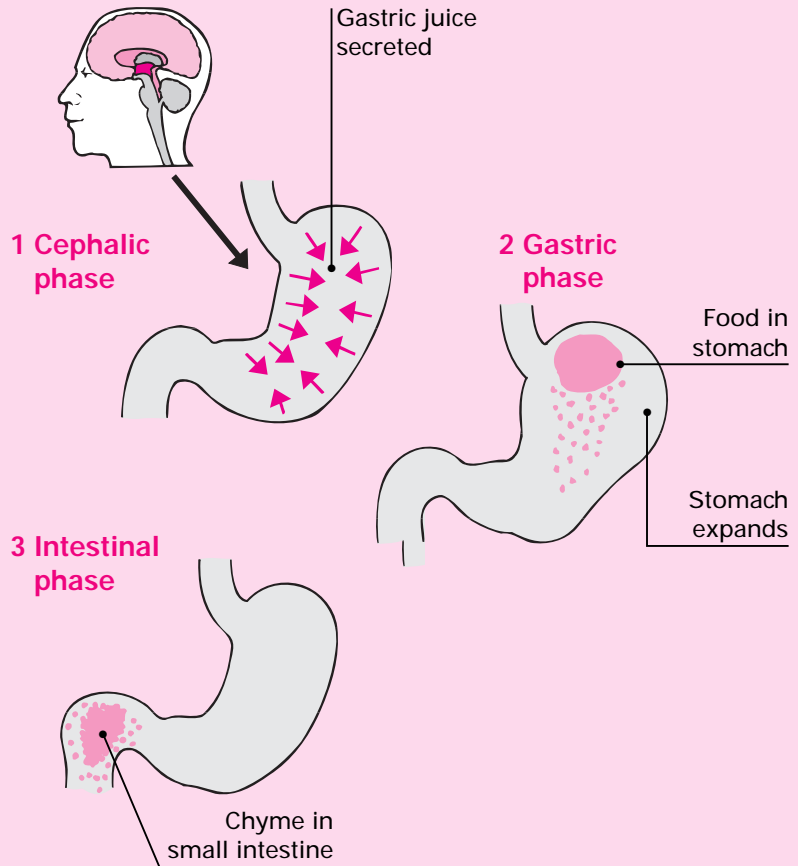
1 Cephalic phase

This begins before food reaches the stomach, and prepares the stomach for digestion. Seeing, smelling, thinking about, and tasting food stimulates the secretion of the hormone gastrin from specialized cells in the stomach. This enters the blood system, which returns it to the stomach, to trigger the secretion of more gastric juice.

2 Gastric phase

This begins when food reaches the stomach. Secretion of gastric juice is triggered by the presence of food and the expansion of the stomach, and by the low acidity this causes.

Controlling gastric secretion



Stomach facts

- The stomach processes about 1100 pounds (500 kg) of food in a year.
- In 24 hours, the stomach makes 40–60 fluid ounces (1.7 l) of gastric juices.

3 Intestinal phase

After one to three hours, food leaves the stomach and enters the small intestine. At this point, the intestinal phase begins. Chyme (a semifluid mixture of food and digestive juices) in the small intestine triggers the secretion of hormones that stimulate gastric secretion. Hormones are released that inhibit (slow or prevent) gastric secretion, preventing more acidic chyme from entering the small intestine.

Gastric juice composition

Gastric juice (digestive fluid) contains hormones, enzymes (proteins that act as biological catalysts), hydrochloric acid, mucus (thick, slimy fluid), and the protein intrinsic factor.

Ingredient	Function
Gastrin (hormone)	<ul style="list-style-type: none">• Stimulates the secretion of more gastric juice—it has a positive feedback effect• Stimulates the contraction of stomach muscles
Serotonin (neurotransmitter)	<ul style="list-style-type: none">• Stimulates the contraction of stomach muscles
Rennin (enzyme only present in infants)	<ul style="list-style-type: none">• Chemically breaks down milk protein
Lipase (enzyme)	<ul style="list-style-type: none">• Splits fat molecules
Pepsinogen (inactive form of pepsin)	<ul style="list-style-type: none">• Is activated by hydrochloric acid to form pepsin (an enzyme), which chemically breaks down proteins
Hydrochloric acid	<ul style="list-style-type: none">• Activates pepsinogen into pepsin• Kills bacteria
Intrinsic factor	<ul style="list-style-type: none">• Is essential for the absorption of vitamin B₁₂ by the small intestine
Mucus	<ul style="list-style-type: none">• Protects the stomach• Lubricates the stomach• Mixes with food to create a fluid medium for chemical reactions

Protecting the stomach

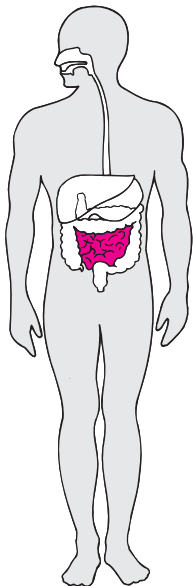
The enzymes and hydrochloric acid in gastric juice begin the digestion of large protein molecules into smaller protein molecules of peptides, proteose, and amino acids. Although the stomach walls are made mainly of protein, they are not normally digested by gastric

juice. This is because they are covered with a protective coating of mucus that is secreted by the stomach lining. The enzyme pepsin is also secreted in an inactive form (pepsinogen), so it cannot digest the stomach cells that produce it.

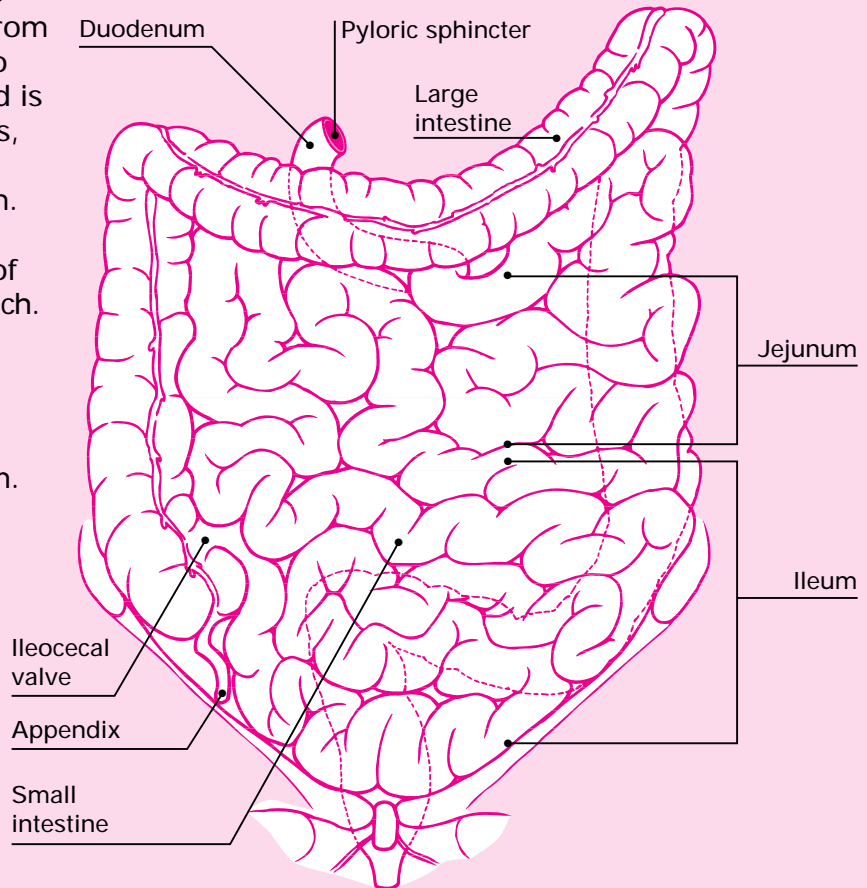
Parts of the small intestine

The small intestine is a long, coiled, muscular tube connecting the stomach with the large intestine. It stretches from the pyloric sphincter to the ileocecal valve, and is divided into three parts, the duodenum, the jejunum, and the ileum. The pyloric sphincter controls the entrance of chyme from the stomach. The ileocecal valve regulates the flow of chyme into the large intestine and stops backflow into the ileum.

Locator



Front of the intestines



Intestine facts

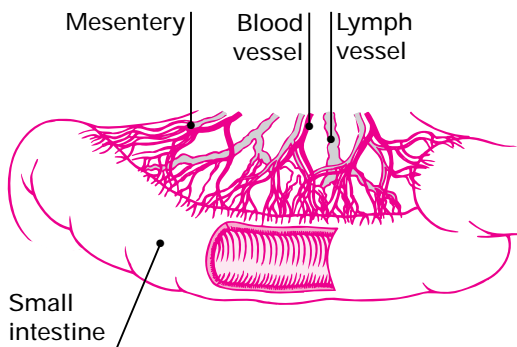
- The small intestine is about 20 feet (6 m) long and 1.6 inches (4 cm) in diameter. The large intestine is about 5 feet (1.5 m) long and 2.4 inches (6 cm) in diameter.

Area for absorption

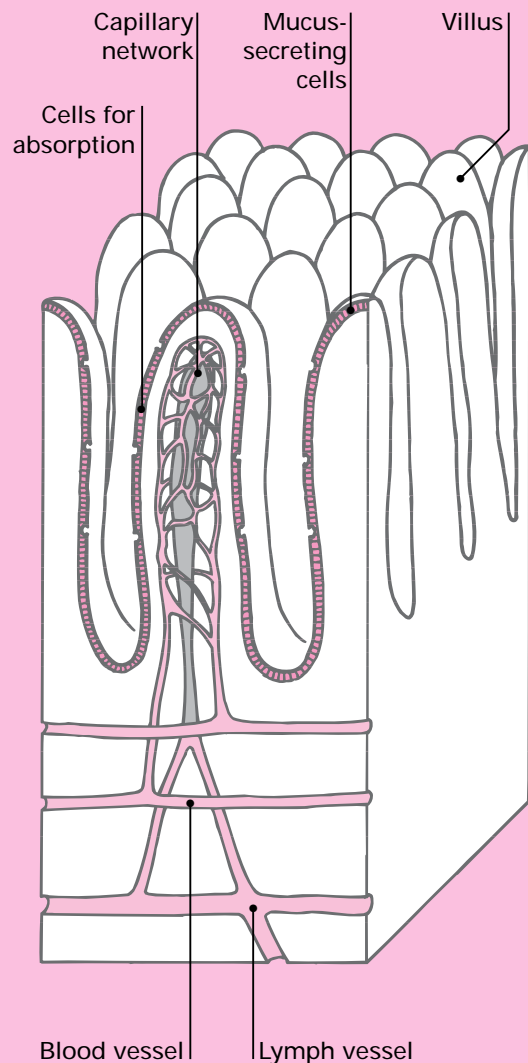
The small intestine is adapted in several ways for the absorption of nutrients from digested food. It is the longest section of the whole alimentary canal, and also has a gigantic internal surface area of about 300 square yards (250 sq m)—an area larger than a doubles tennis court. This huge surface area is achieved by means of numerous folds, which are covered with minute, fingerlike bulges called villi (singular villus). The villi are themselves covered with extensions called microvilli (or brush border), which further increases the total surface area. The folds, villi and microvilli, make the small intestine 600 times more absorptive than an intestine would be if it had a smooth lining.

Mesentery

The small intestine is anchored to the rear wall of the abdomen by a tissue structure called the mesentery. This thin, membranous sheet also carries blood to the intestine, and transports nutrients away in blood and lymph.



Section through intestine wall

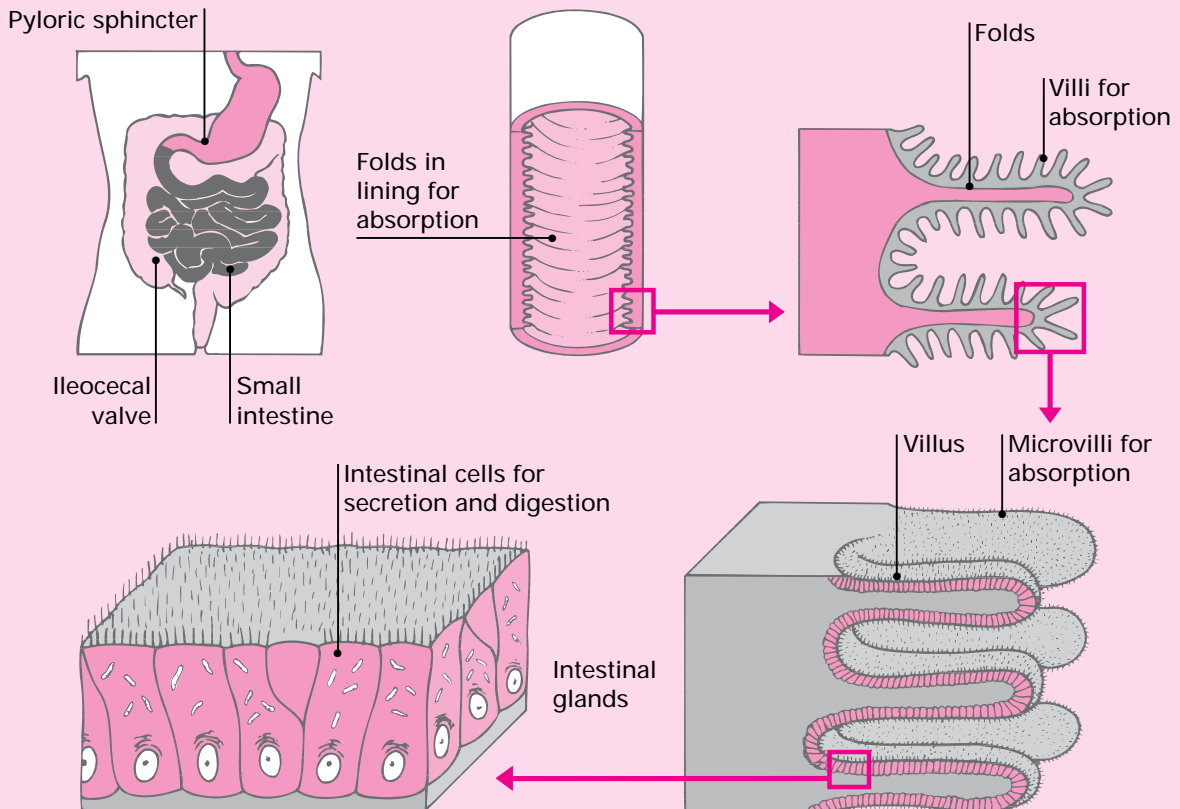


Role of the small intestine

The major functions of the small intestine are digestion and absorption, which occur as a result of movements of the intestinal muscles and the chemical action of enzymes. These enzymes are secreted by the small intestine itself, and also by the liver and pancreas. They complete the digestion of proteins and carbohydrates in the food, and break down most of the fats. Segmentation (rhythmic constrictions of the muscular walls of the intestine) and pendular movements (lengthening and

shortening motions caused by muscle contractions) mix stomach chyme with digestive juices and bring it into contact with villi in the intestinal walls for absorption. Waves of peristalsis (rhythmic muscular contractions) move chyme forward. It takes from one to six hours for chyme to move through the small intestine. Intestinal juice provides lubrication and a fluid medium for absorption and chemical digestion, neutralizes acidic chyme, and protects the intestine wall from being digested.

Small intestine



Chemical digestion in the small intestine

Most of the chemical digestion carried out by the digestive system occurs in the small intestine. The production and release of digestive enzymes and hormones (which control processes and

mechanisms) is stimulated by ingestion of food, distension of the small intestine walls (caused by the entrance of chyme), the acidity of chyme, and the presence of partially digested foods in chyme.

Agent	Source	Functions
Peptidases (enzymes)	Small intestine/pancreas	• Break down peptides (protein segments) into amino acids
Maltase (enzyme)	Small intestine	• Converts disaccharide (double sugar) maltose into monosaccharide (single sugar) glucose
Sucrase (enzyme)	Small intestine	• Converts disaccharide sucrose into the monosaccharides glucose and fructose
Lactase (enzyme)	Small intestine	• Converts the disaccharide lactose into the monosaccharides glucose and galactose
Lipase (enzyme)	Small intestine/pancreas	• Breaks down fat into its components—monoglycerides and fatty acids
Enterokinase (enzyme)	Small intestine	• Activates a protein-splitting enzyme (trypsin) from the pancreas
Secretin (hormone)	Small intestine	• Stimulates the pancreas to produce juice with high bicarbonate content
Cholecystikinin (hormone)	Small intestine	• Increases the bile output of the liver • Stimulates the release of bile stored in the gallbladder
Pancreatic juice (enzymatic fluid)	Pancreas	• Breaks up protein, starch, and fats; its high bicarbonate content neutralizes acidic chyme
Bile (bile salts and cholesterol)	Liver	• Emulsifies (breaks down) fats into smaller droplets

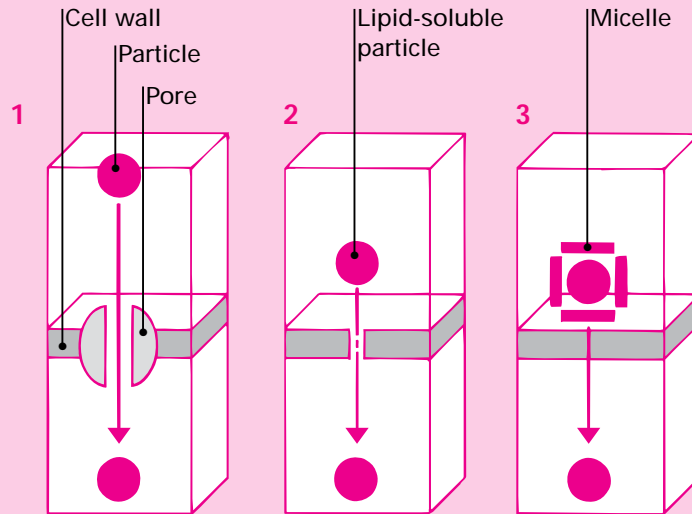
Methods of absorption

The simple substances produced by digestion are small enough to be absorbed across the cell walls of the intestinal lining. This happens by means of passive or active transport. Passive transport (such as diffusion) does not require the cell to use any energy. For active transport (such as solute pumping or endocytosis), a cell needs to use energy to transport a particle across its wall.

Simple diffusion

1 A particle is small enough to pass through the pores of the cell wall.

2 A particle is lipid soluble (can be dissolved



in fat), and so will pass directly through the lipid layer of the cell wall.

3 A particle is coated with bile salts (secreted by the liver) to form micelles. These do not float and so sink to the cell's wall, through which they are easily diffused.

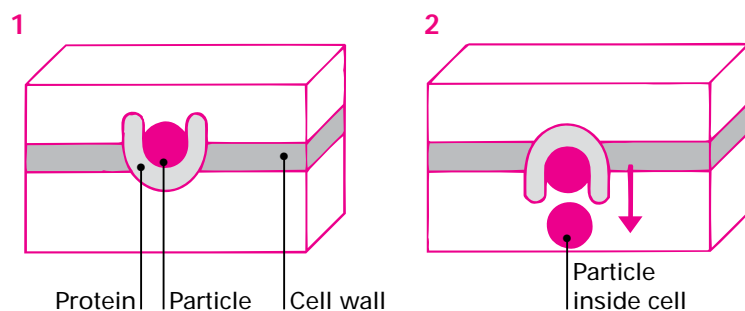
Digested substances absorbed by simple diffusion include the end products of fat digestion (glycerol, monoglycerides and fatty acids), water-soluble vitamins (B and C) and water. (The diffusion of water across the cell wall is called osmosis.)

Facilitated diffusion

If a particle is not lipid soluble, and is too large to pass through the pores of the cell wall, then it needs the help of a carrier protein.

1 The particle binds to the protein, which straddles the cell wall.

2 The particle enters the cell through the protein.

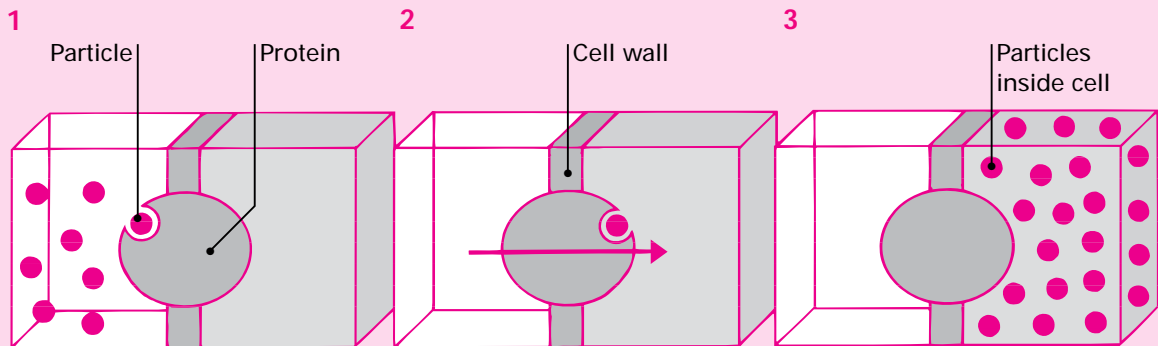


Digested substances absorbed by facilitated diffusion include fructose (a sugar).

Solute pumping

- 1 A carrier protein combines with a particle.
- 2 The protein transports the particle across the cell wall.
- 3 The particle is released into the cell. The carrier is powered by ATP

(adenosine triphosphate), and is called a solute pump. Substances absorbed by solute pumping include amino acids (the building blocks of proteins) and glucose/galactose (sugar).



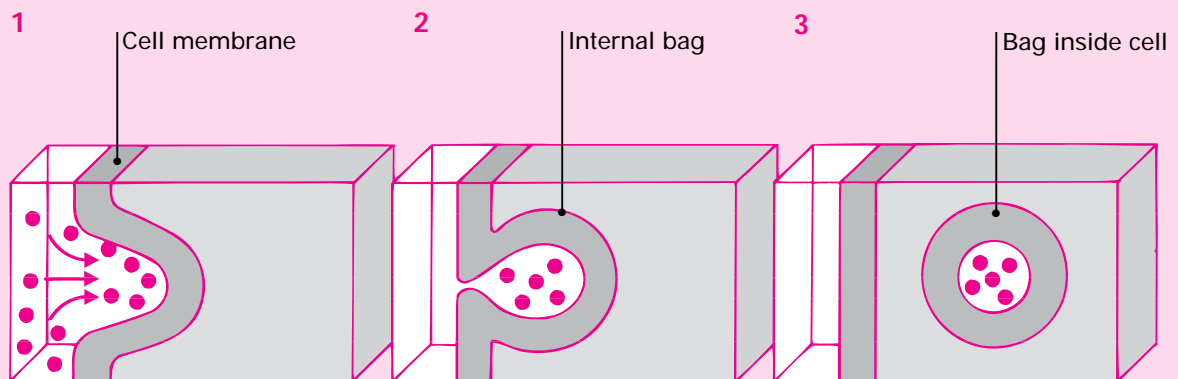
Endocytosis

This is the process by which cells "engulf" substances.

- 1 The cell membrane folds inward.
- 2 It then closes over the gathered particles or liquid, forming an internal bag on the inside of the membrane.

- 3 The bag breaks away from the membrane. Its contents may be digested by cellular enzymes.

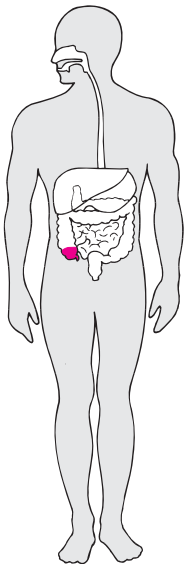
Substances absorbed by endocytosis include proteins.



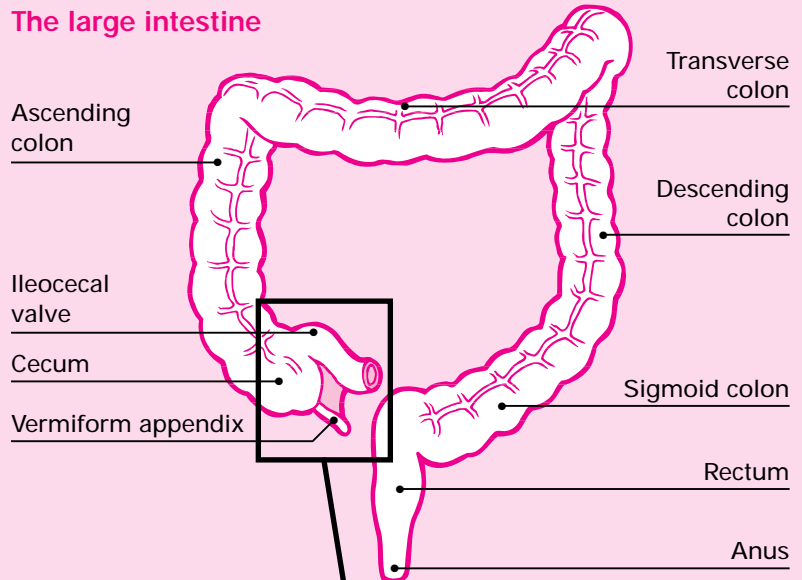
Appendix

Attached to the first part of the large intestine, just below the ileocecal valve, is a wormlike, tubular structure called the vermiform (“worm-shaped”) appendix. It is made of muscle fibers sheathing a layer of lymphatic tissue, and may play a minor role in the immune system. The appendix does not seem to have a digestive function in humans. Inflammation of the appendix lining causes appendicitis.

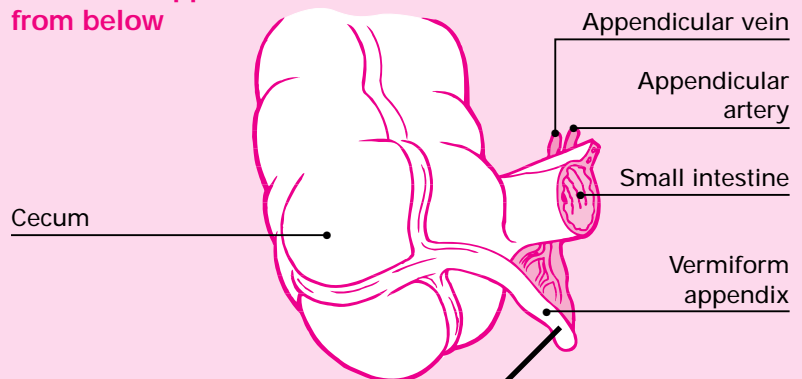
Locator



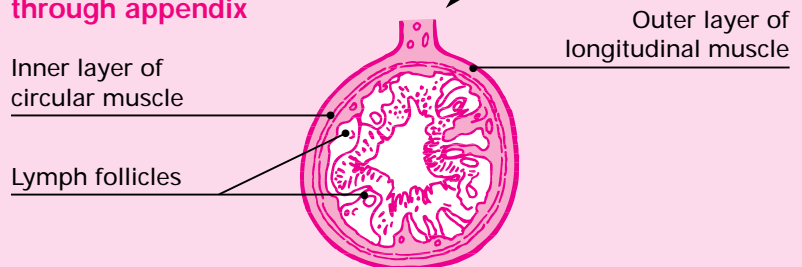
The large intestine



Cecum and vermiform appendix from below



Cross section through appendix

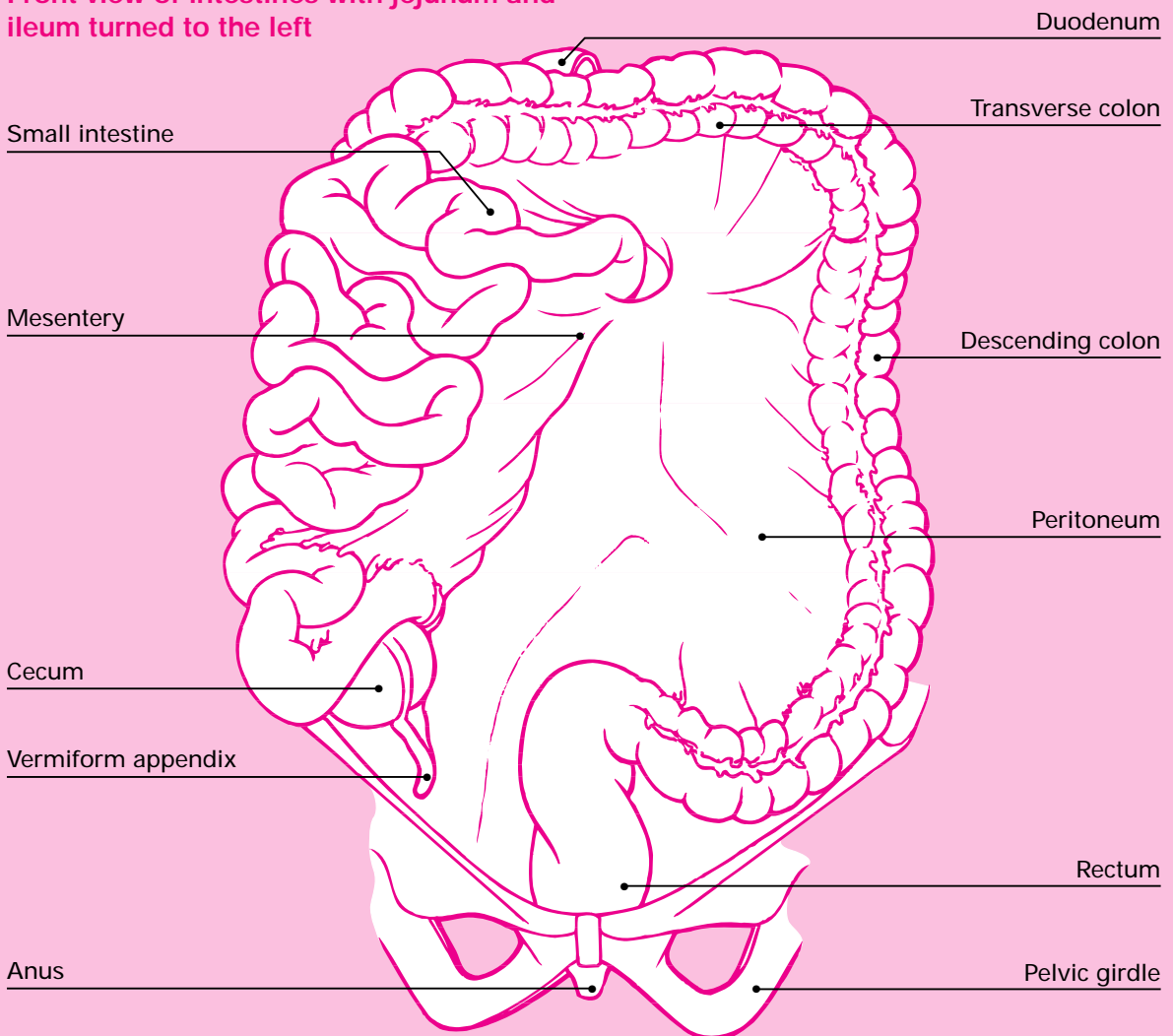


Intestines and membranes

The two-layered abdominal membrane called the peritoneum produces a fluid that reduces friction between organs in the abdomen. Most of the duodenum, and the ascending and descending colons of the large intestine, lie behind

the peritoneum, and are covered but not surrounded by it. Most of the small intestine, and the transverse colon of the large intestine, are suspended from the back wall of the abdomen by two fused layers of peritoneum, the

Front view of intestines with jejunum and ileum turned to the left



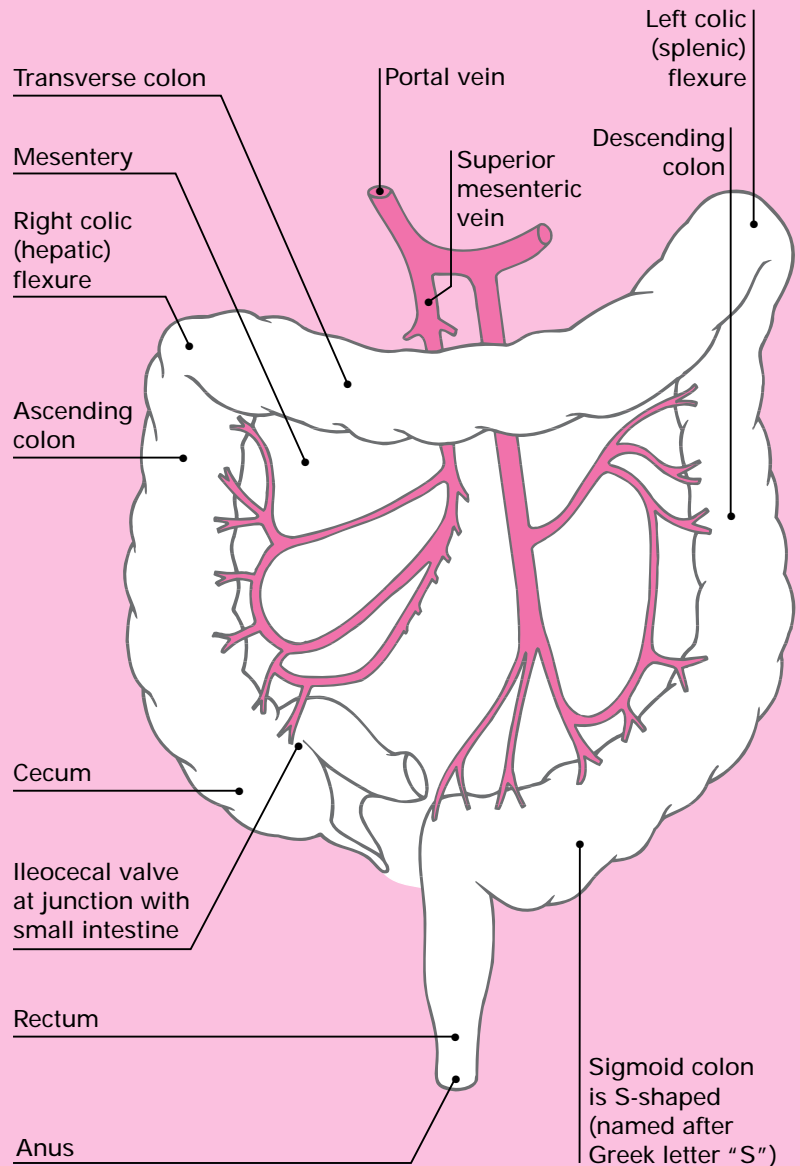
Parts of the large intestine

The large intestine is the section of the digestive system between the ileocecal valve (at the junction with the small intestine), and the anus. It starts at the cecum, ascends to the liver as the ascending colon, then crosses the abdomen, as the transverse colon, to the spleen before descending to the pelvis as the descending colon. It then narrows to become the sigmoid colon, and finally the rectum, before ending at the anus.

Functions

Material takes between about six and 18 hours to pass through the large intestine. During this time, material that escaped digestion in the small intestine is acted on by bacteria, and some water, salts, and minerals are absorbed. This converts liquid wastes into feces. Mucus secreted by the large intestine provides lubrication and holds the feces together. It also helps to neutralize acids produced by bacteria.

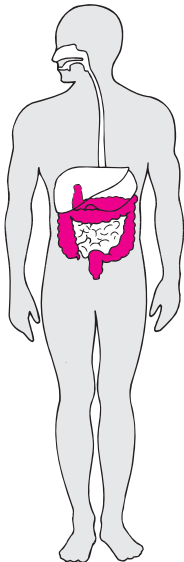
Large intestine



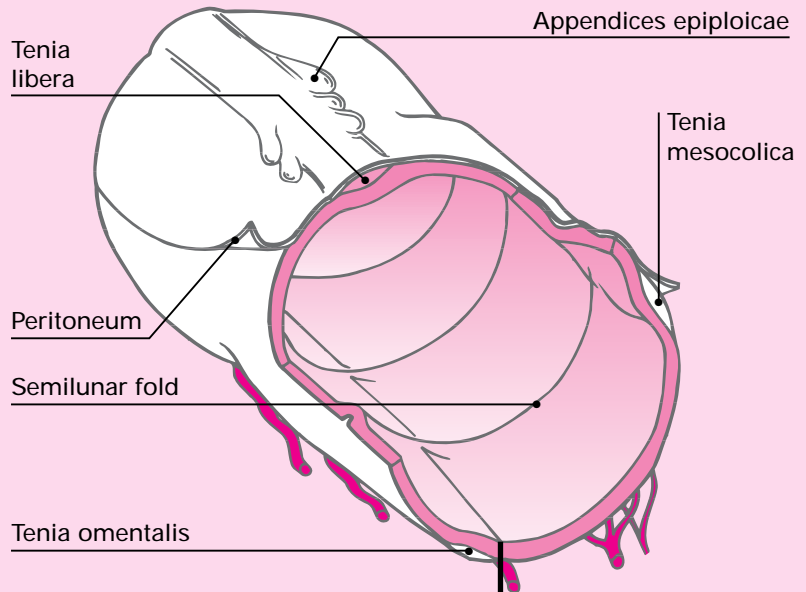
Outside and inside

The large intestine has three separate bands of longitudinal muscle running along its outer surface. These muscle bands are called "teniae," from the Latin word for ribbons. Since the teniae are not as long as the large intestine itself, the wall is puckered with bulges called haustra. The internal surface of the large intestine is smooth and has no villi because absorption is not its main function.

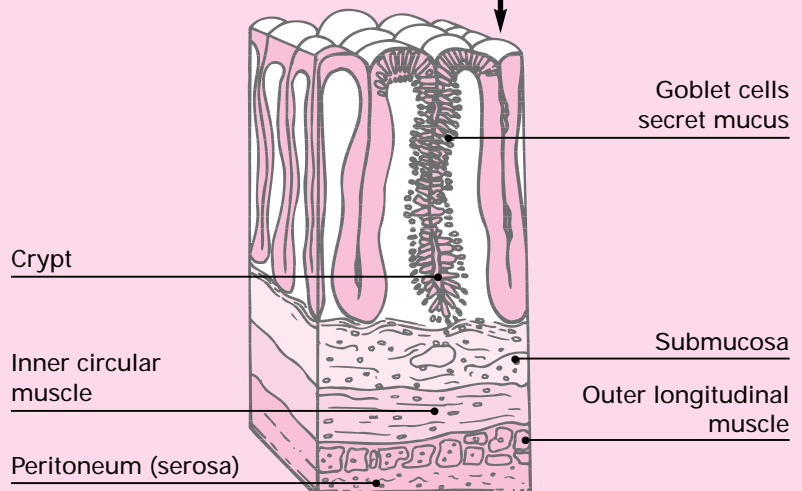
Locator



Ascending colon, partly cut away



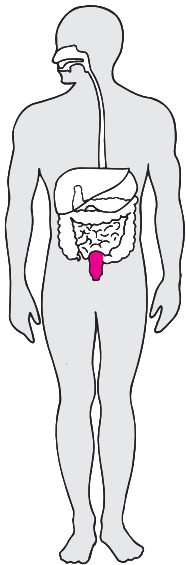
Cross section of colon wall



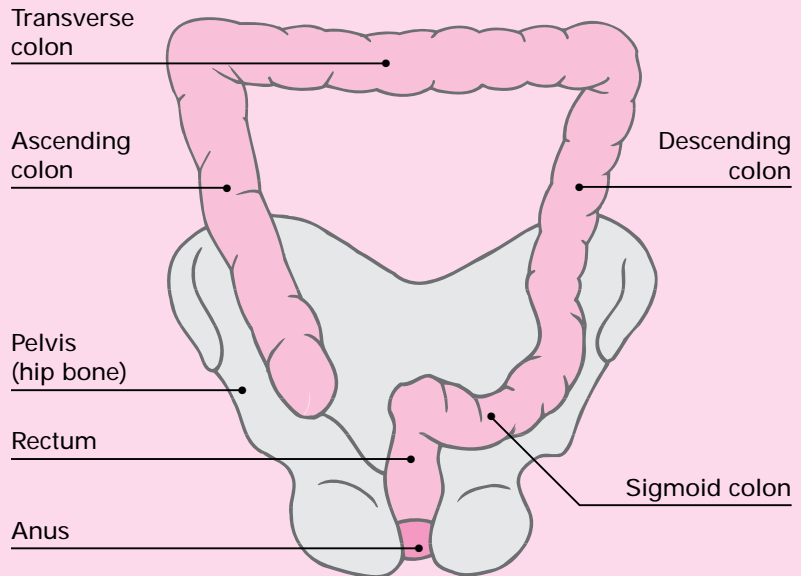
Journey's end

At the end of the large intestine is the rectum, leading to the anal canal, and the anus. The rectum extends about six inches (15 cm) from the sigmoid colon to the anus. The opening and closing of the anus is controlled by internal and external anal sphincters (rings of muscle that act as valves). The internal anal sphincter is not under voluntary (conscious) control. The external anal sphincter is under voluntary control.

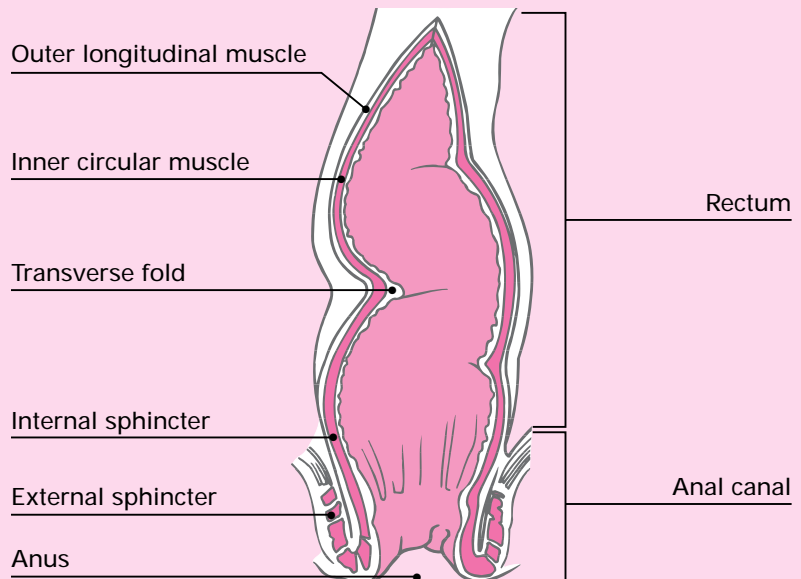
Locator



Rectum and pelvis



Section through the rectum



Defecation

The expulsion of feces (dead bacteria and cells, mucus, bile, and indigestible food) through the anus by muscular action is called defecation.

The decision to defecate, or open, the external anal sphincter, is under voluntary control (except in babies). The presence of feces in the rectum sends a nerve impulse to the brain. The decision whether or not to defecate is taken, and the sphincter is either opened or remains closed. The defecation reflex will be triggered again the next time the large intestine forces feces into the rectum.

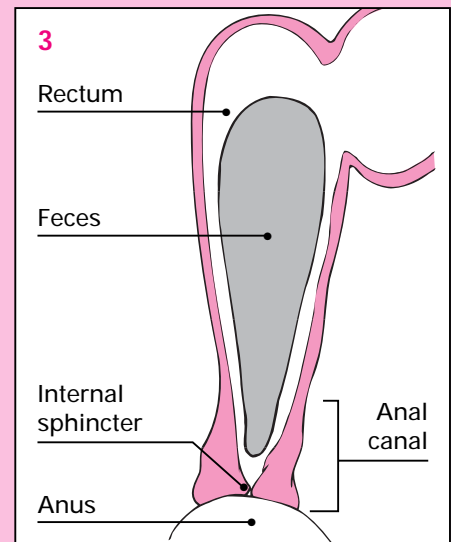
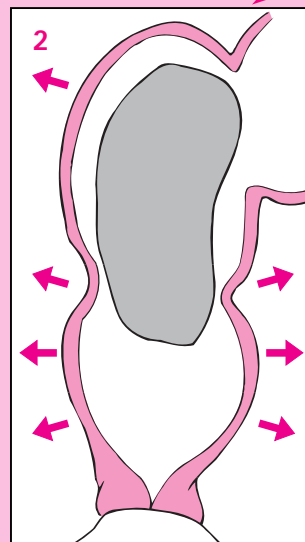
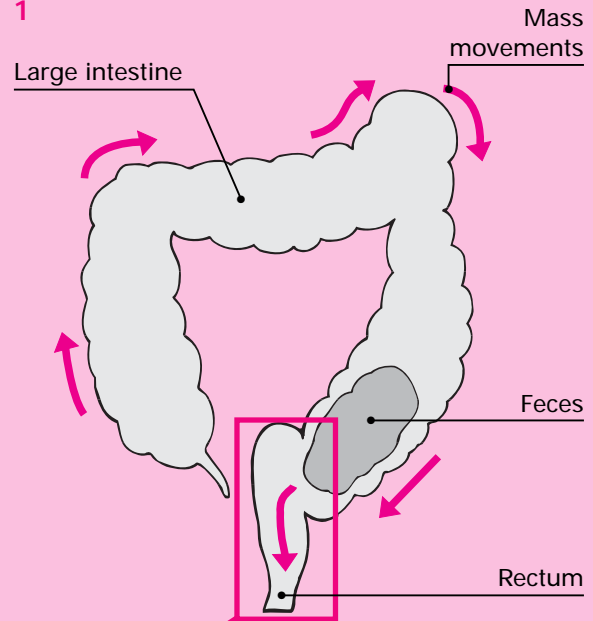
1 Mass movements (long, slow, contractile waves of muscular walls) force the contents of the large intestine toward the rectum. These movements occur only three or four times daily, generally following meals.

2 When the contents of the large intestine enter the rectum, the walls stretch, and the defecation reflex is triggered.

3 This reflex causes the walls to contract and the internal anal sphincter to relax. The feces then enter the anal canal, and may be expelled by contractions of the intestines, abdominal muscles, and diaphragm.

The defecation reflex

1



Lower digestive tract disorders

Many aspects of modern life force our intestines to cope with unnatural habits, such as rushed, irregularly-spaced meals, and an excess of processed foods. In order for the intestines to work correctly, they should be treated well, particularly by following good dietary principles. The effort needed to keep the intestines healthy is minimal compared with the trouble that they can otherwise cause—especially as our bodies age. Old people are more prone to certain complaints as the large intestine deteriorates and eating habits change. Pouches called diverticula occur where the large intestine bulges through weak parts of its muscular wall.

Infected pouches give rise to diverticulitis. As muscles generally lose tone, straining at stool becomes more likely to cause a hernia. If overstraining collapses the rectum wall, a fecal mass may become trapped inside the rectum and keep overflowing. Eating enough dietary fiber helps to stop this situation from developing. The human digestive system cannot digest fiber, but uses it to help retain toxic substances that would otherwise pass into the bloodstream. Fiber produces soft, bulky and easily evacuated stools, and speeds up their elimination. A fiber-rich diet can help to protect the body against disorders such as diverticulitis, colitis, and hemorrhoids.

Self-help

Many common digestive ailments respond to changes in diet or the introduction of an exercise regime. Make sure to include enough fiber in your diet by eating some raw cereals, fruits, and vegetables rich in fiber or roughage (indigestible cellulose). Cooking tends to break down cellulose cell walls, so most of the food taken for its fiber value should be eaten raw; cereal fiber is best. Wholewheat bread has a higher fiber content than brown or white bread, and brown rice contains more fiber than white rice.

Constipation can be prevented by eating enough fiber, together with exercising, drinking plenty of liquids, and forming regular bowel habits. This should also help to prevent straining at stool, which is very likely to produce hemorrhoids. Short term constipation and diarrhea are often linked with travel and a sudden change of diet, but do not ignore a change in bowel habit that persists for more than two or three days. See your doctor about continuing diarrhea, constipation, or alternation of the two.

Hemorrhoids (piles)

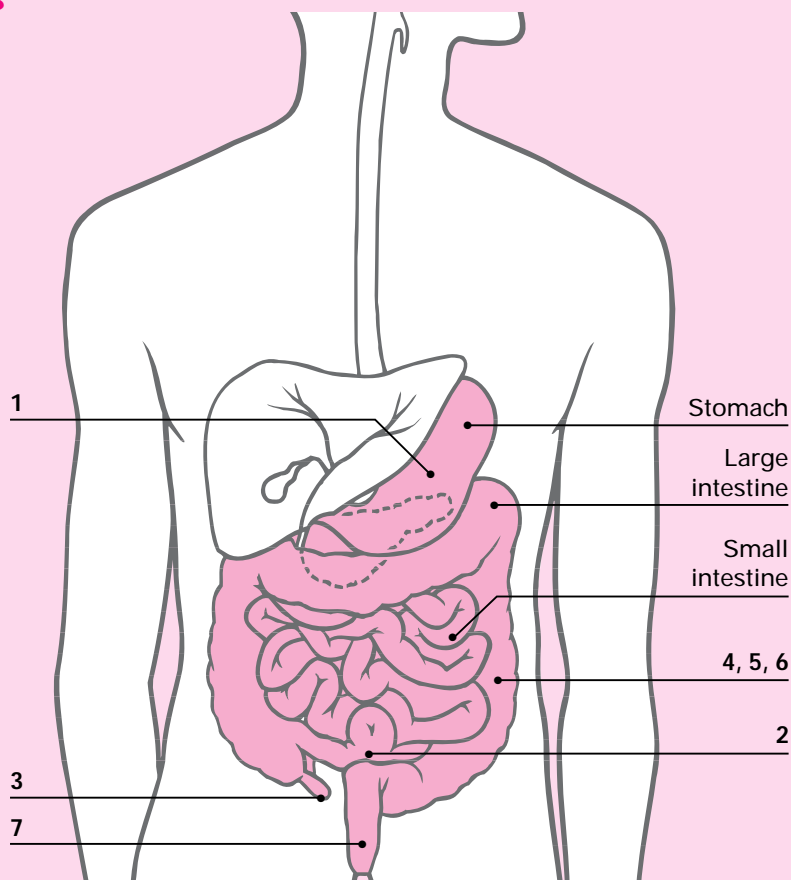
Internal hemorrhoids can occur high in the anal canal; external hemorrhoids protrude from the rectum. A greased finger can sometimes push external hemorrhoids back into place. Itching may be relieved by sitting in warm water. Various local anesthetic preparations deaden pain and relieve itching. Hemorrhoids that continue to give trouble should be seen by a doctor; if necessary the enlarged veins can be treated by injection or removed by a simple, safe operation.

Digestive tract troubles

1 Gastritis is a general term for inflammation of the stomach due to irritation from causes such as infection, stress, alcohol, spicy food, or aspirin. Often the best treatment is to rest the stomach by eating nothing and drinking plenty of bland liquids.

2 Ileitis (Crohn's disease) is inflammation of the lower small intestine producing weight loss, anemia, perhaps diarrhea, and other symptoms. Bed rest, a bland diet, vitamin-mineral supplements, and plenty of liquids help to treat it, but medical advice should be sought.

3 Appendicitis, inflammation of the appendix, can be triggered by blockage of the appendix or by ulceration of its lining. Symptoms include loss of appetite and severe pain in the lower right part of the abdomen. There may also be nausea and vomiting. The usual treatment is surgical removal of the appendix, called appendectomy. If not removed, an inflamed



appendix can burst, causing peritonitis (inflammation of the abdominal lining), with potentially fatal results.

4 Colitis is inflammation of the colon, due often to mild infection producing diarrhea.

5 Irritable bowel syndrome (IBS) can involve alternate constipation and diarrhea, with bloated abdomen and

discomfort. A bland, fibrous diet and bed rest help acute attacks.

6 Diverticulitis is the inflammation of pouches that may form in the colon, giving left-sided abdominal pain and fever.

7 Piles (hemorrhoids) are varicose veins of the rectum, which can be internal or external.

Lower digestive tract disorders

Further examples of lower digestive tract disorders are covered on these two pages. These disorders include ulcers, which form when the protective lining of the stomach or small intestine is eroded by irritants. The main symptom is upper abdominal pain. About 10 percent of people in developed countries may suffer from ulcers; the problem can occur at any age. If the sphincters at the

entrance and exit to the stomach are not working properly, this can disrupt the passage of food through the lower digestive tract, causing disorders such as heartburn and pyloric stenosis. Other problems with the lower tract are caused by the invasion of parasitic worms rather than with the tract itself. Invasion may occur through contaminated food or through the feet.

Ulcers

Ulcers are craterlike lesions that form when the walls of the digestive tract are eroded by digestive juices. The most common locations for ulcers are the walls of the stomach (gastric ulcer) and duodenum (duodenal ulcer). Most gastric and duodenal ulcers are caused by infection with the bacterium

Helicobacter pylori. The bacterium causes inflammation and ulceration by increasing stomach acid. Other contributory factors include certain drugs (such as aspirin or ibuprofen), smoking, alcohol, coffee, diet, or stress. Some individuals have a genetic predisposition to ulcer

development. Various drugs can help to treat ulcers. Antibiotics eradicate the bacteria, while other drugs block or reduce stomach acid secretion. In spite of improved drug therapy, surgery is sometimes necessary for treating hemorrhage, perforation, scarring, or other more serious complications.

Food for ulcer sufferers

Modern drugs help to make strict diets unnecessary, but small, light, frequent meals are better than large, heavy ones. Foods to avoid are those that stimulate digestive juices or irritate the inflamed lining of the

stomach or duodenum.

Eat: milk, eggs, fish.

Limit: sugar, candies, chocolate.

Avoid: fatty foods, fried foods, spicy foods, pastry, strong coffee or tea, cola drinks, alcohol, pickles, fruit juices, fibrous meats, whole grain cereals.



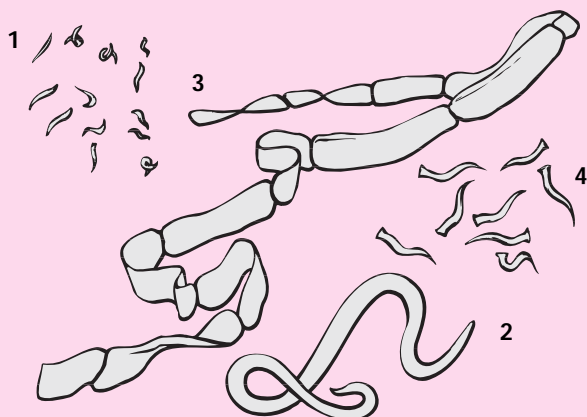
Worms

1 Threadworms or pinworms are common in children. Resembling tiny white threads $\frac{1}{4}$ inch (6 mm) long, they live in the colon, emerging at night to lay eggs around the anus. This produces itching that causes scratching, leading to reinfection via the mouth. Meanwhile, worms show up in feces. One dose of piperazine will clear an infestation; all the family should be treated.

2 Common roundworms resemble white earthworms and are up to 4 inches (10 cm) long. They invade the small intestine, and are spread via contaminated food. Treatment is the same as for threadworms.

3 Tapeworms comprise up to 30 feet (9 m) of flat, white segments. They live in the intestine and break off to leave it via the feces. Tapeworm infestation results from eating undercooked pork, beef or fish; treatment is by drugs.

4 Hookworms are about 1 inch (2.5 cm) long, and cause anemia by sucking blood from the intestine. They occur in warm climates; eggs exit via the feces, hatching into larvae that invade the skin of the feet. Patients need drugs, iron supplements, and a high protein diet. Wearing shoes, together with good sanitation and foot hygiene, prevents infestation.



Disorders

Hiatus hernia is a condition in which the top of the stomach protrudes through the diaphragm. It causes heartburn, since control is lost over the sphincter linking the esophagus to the stomach. Backward flow of stomach acids up into the esophagus causes burning, and pressure behind the breastbone.

Peritonitis is caused by inflammation of the peritoneum (the membrane lining the abdomen). It results from bacterial infection within the abdomen, caused by perforation of the stomach or intestine. It causes severe pain, muscle spasms, fever, vomiting, and sometimes shock.

Pyloric stenosis occurs when the pylorus (valve between the stomach and the small intestine) is narrowed, obstructing the passage of food. It can be caused by thickening of the muscle at the pylorus (in infants especially), by scarring, or the presence of a tumor.

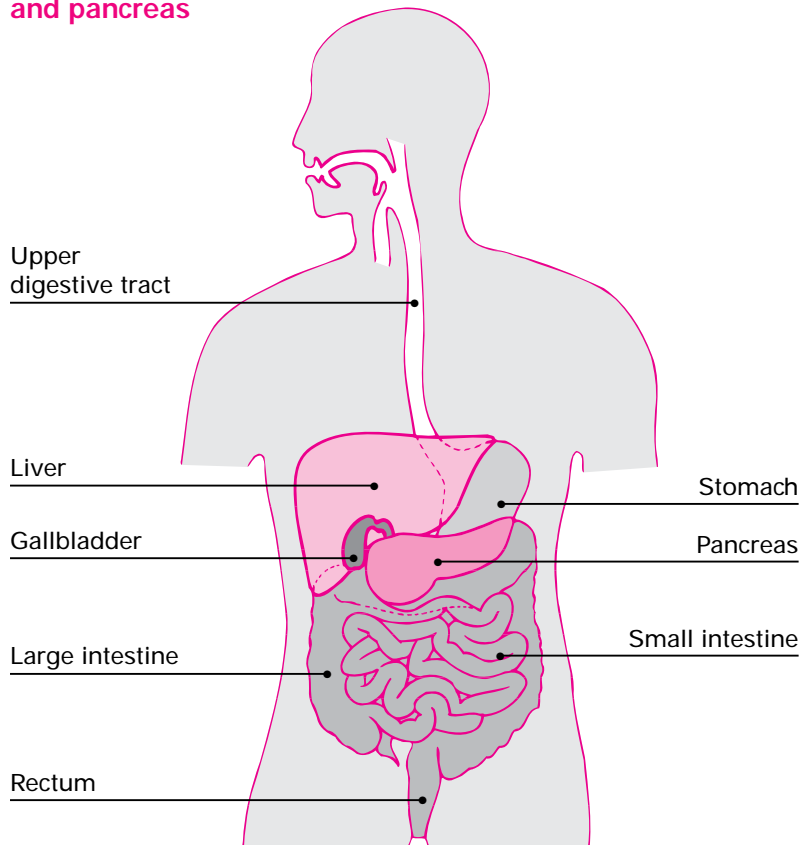
The liver and pancreas are closely connected with the digestive tract, and secrete digestive juices into the small intestine. The liver produces bile, which is stored and concentrated in the gallbladder. Bile helps with the digestion of fats. The pancreas secretes pancreatic enzymes that break down fats, proteins, and carbohydrates. It also makes two hormones, called insulin and glucagon, which control carbohydrate metabolism (the way the body uses energy).

Liver and pancreas facts

- The liver weighs about 3.3 pounds (1.5 kg).
- The pancreas makes more than 36 fluid ounces (1 l) of digestive juices daily.
- The liver makes 36 fluid ounces (1 l) of bile daily.

In the abdomen

The liver is a wedge-shaped organ located mainly on the right side of the upper abdomen under the diaphragm and ribs. The underside faces the stomach, the first part of the duodenum, and the right side of the large intestine. In a hollow under the right lobe of the liver is the pear-shaped gallbladder. It is about 4 inches (10 cm) long. The pancreas is a long, soft organ, tucked behind the stomach on the left side of the body. The wider head and body portions of the pancreas (on the right side) fit into the loop of the duodenum; the tail stretches across to the spleen.

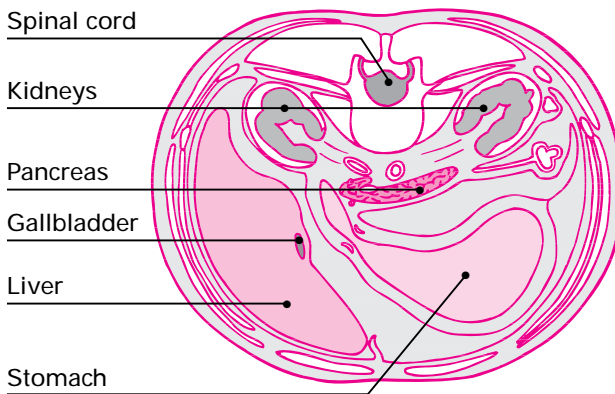
Position of liver and pancreas

Body organs

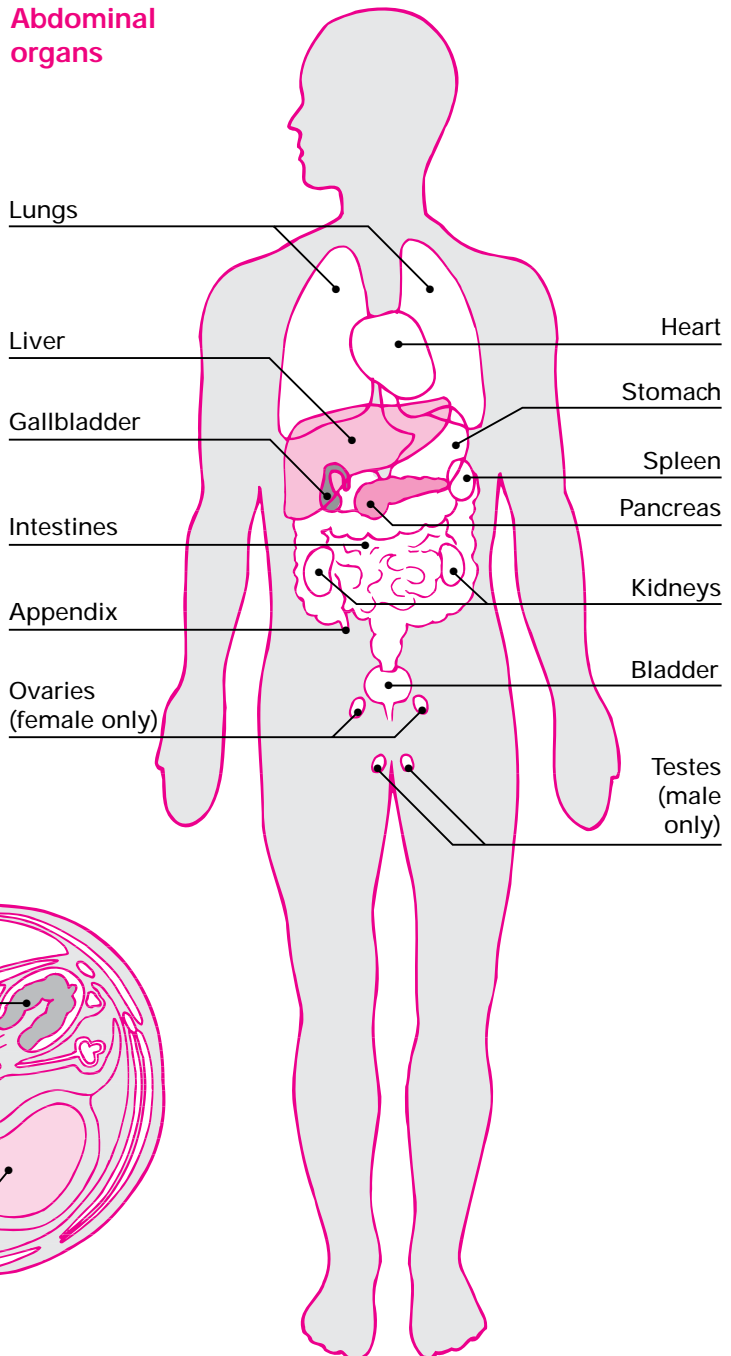
The diagram to the right shows the relationship of the liver and pancreas to other organs in the body. They are below the heart and lungs in the thorax, but at the top of the abdomen, above the intestines and reproductive organs. The stomach lies close to the same level in the body as the liver and pancreas.

Digestive juices from the liver and pancreas pour into ducts that merge as they enter the first part of the small intestine, the duodenum. The liver, pancreas and gallbladder are not actually part of the digestive tract, but are considered to be accessory digestive organs. The liver is the body's largest internal organ.

Cross section through the abdomen



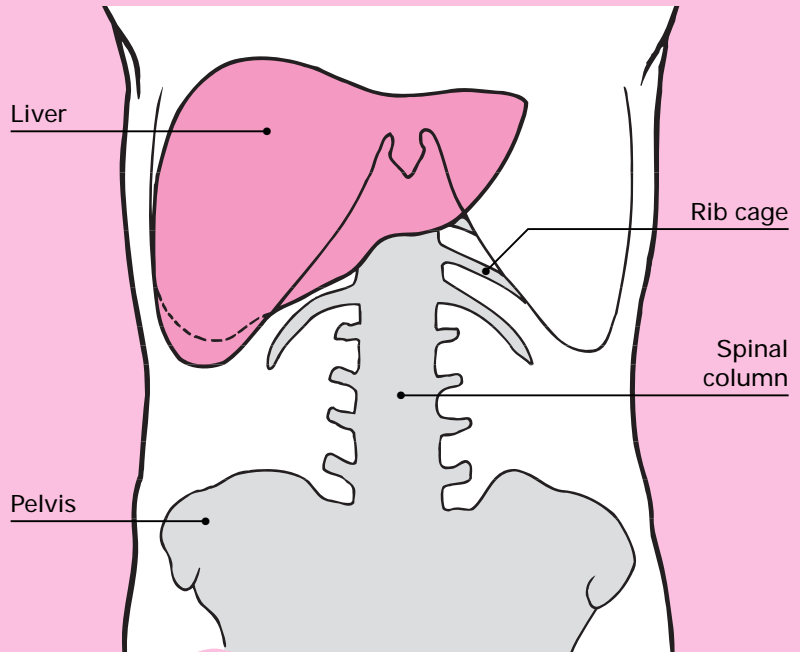
Abdominal organs



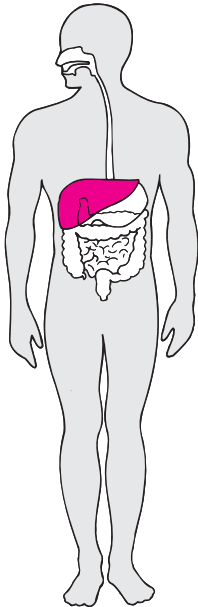
Lobes of the liver

The liver is divided into two main lobes, a right lobe and a smaller left lobe, which lies over the stomach. The right lobe is about six times larger than the left lobe. It is further subdivided into a quadrate lobe and a caudate lobe on its underside. The quadrate lobe partially surrounds and cushions the gallbladder. The caudate lobe is next to the inferior vena cava, which is the largest vein in the body.

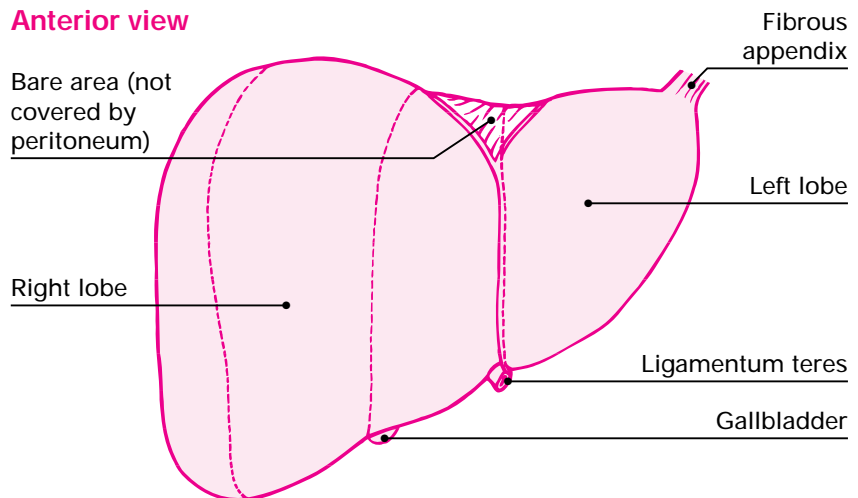
Position of liver



Locator



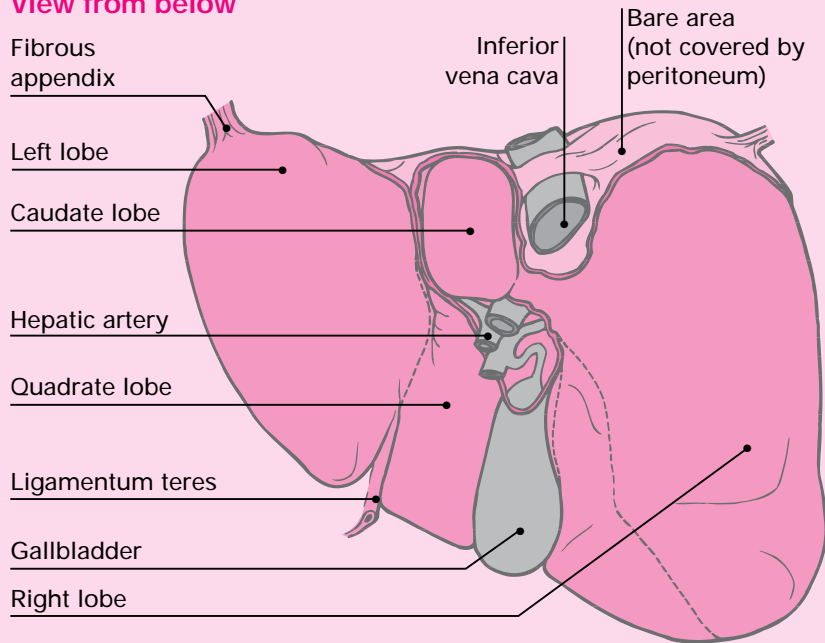
Anterior view



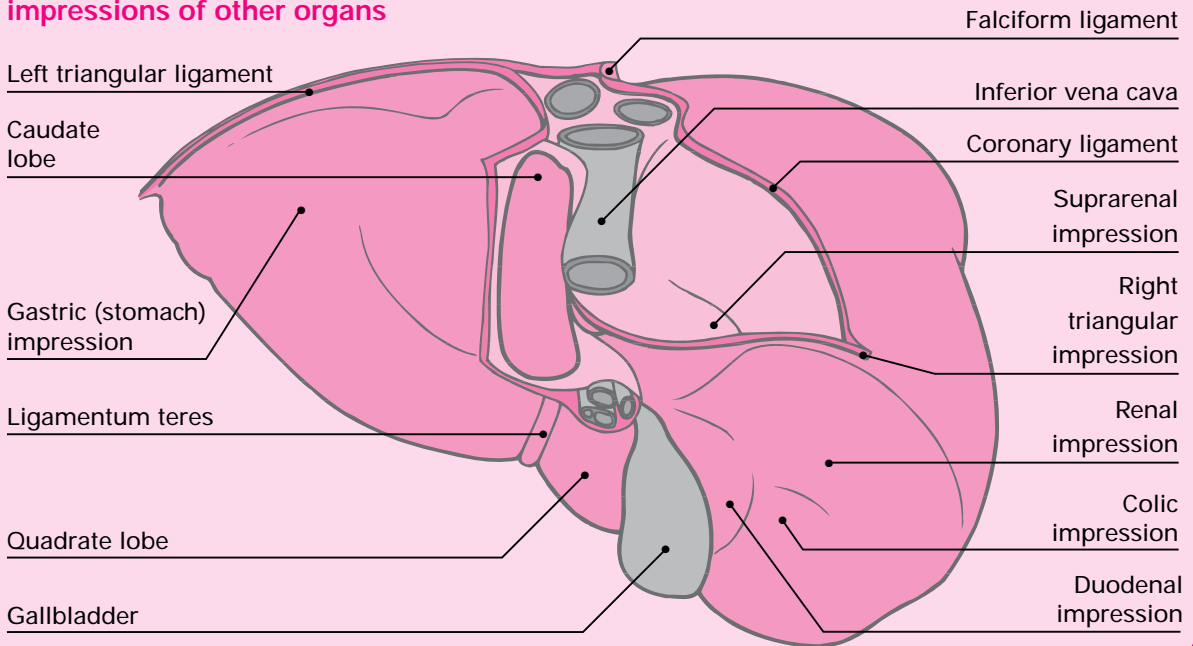
Ligaments

A mesentery attached to the front of the abdominal wall, the falciform ligament, divides the liver into its two main lobes. In the free border of the falciform ligament is the ligamentum teres (round ligament), which is a remnant of the left fetal umbilical vein. The ligamentum teres extends from the liver to the umbilicus.

View from below



Visceral surface, showing ligaments and impressions of other organs



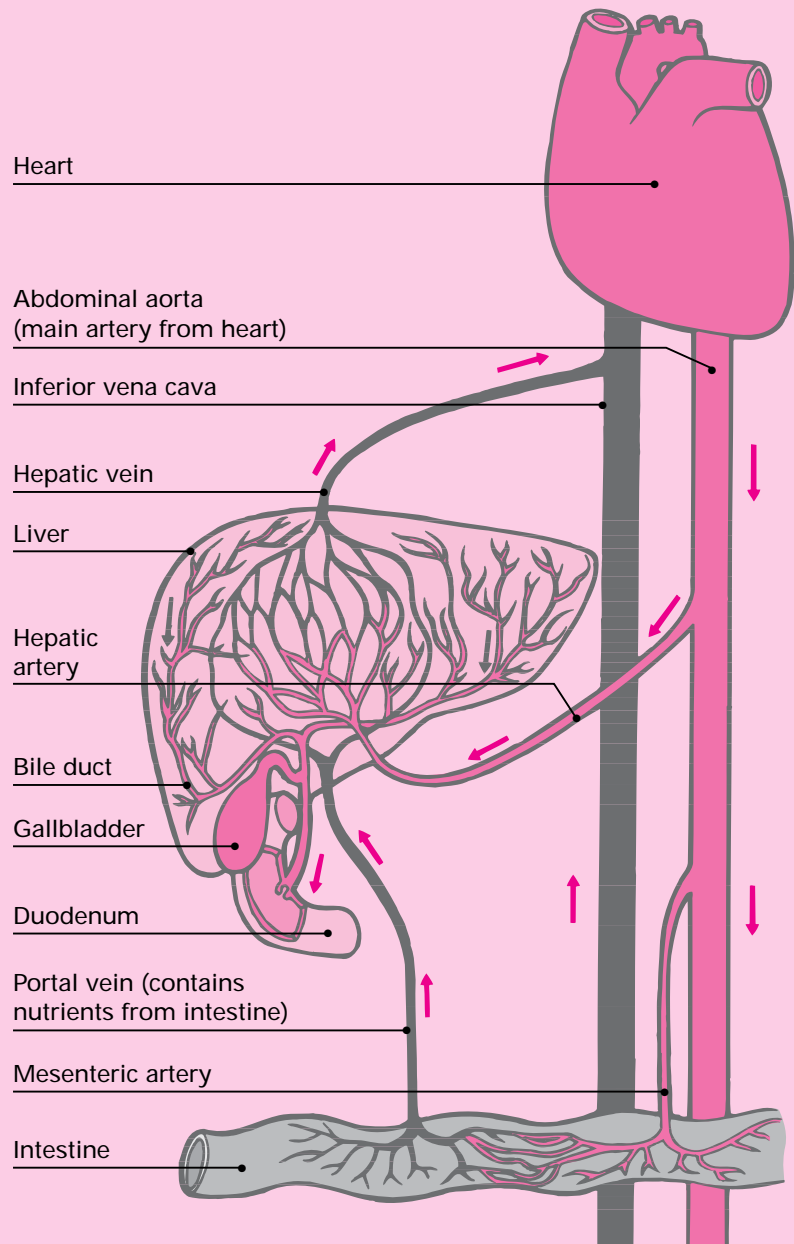
Roles of the liver

The liver is the largest gland in the body, and performs many functions. It converts the nutrients from food into usable substances, and stores them until they are needed. The liver is the body's main storage center. It stores vitamins and minerals, and glucose in the form of glycogen. Another important role of the liver is detoxification, turning dangerous chemicals into harmless substances. Within the digestive system, the liver is important for the production of bile (a greenish-yellow fluid). This trickles into the small intestine, or is stored in the gallbladder.

Liver facts

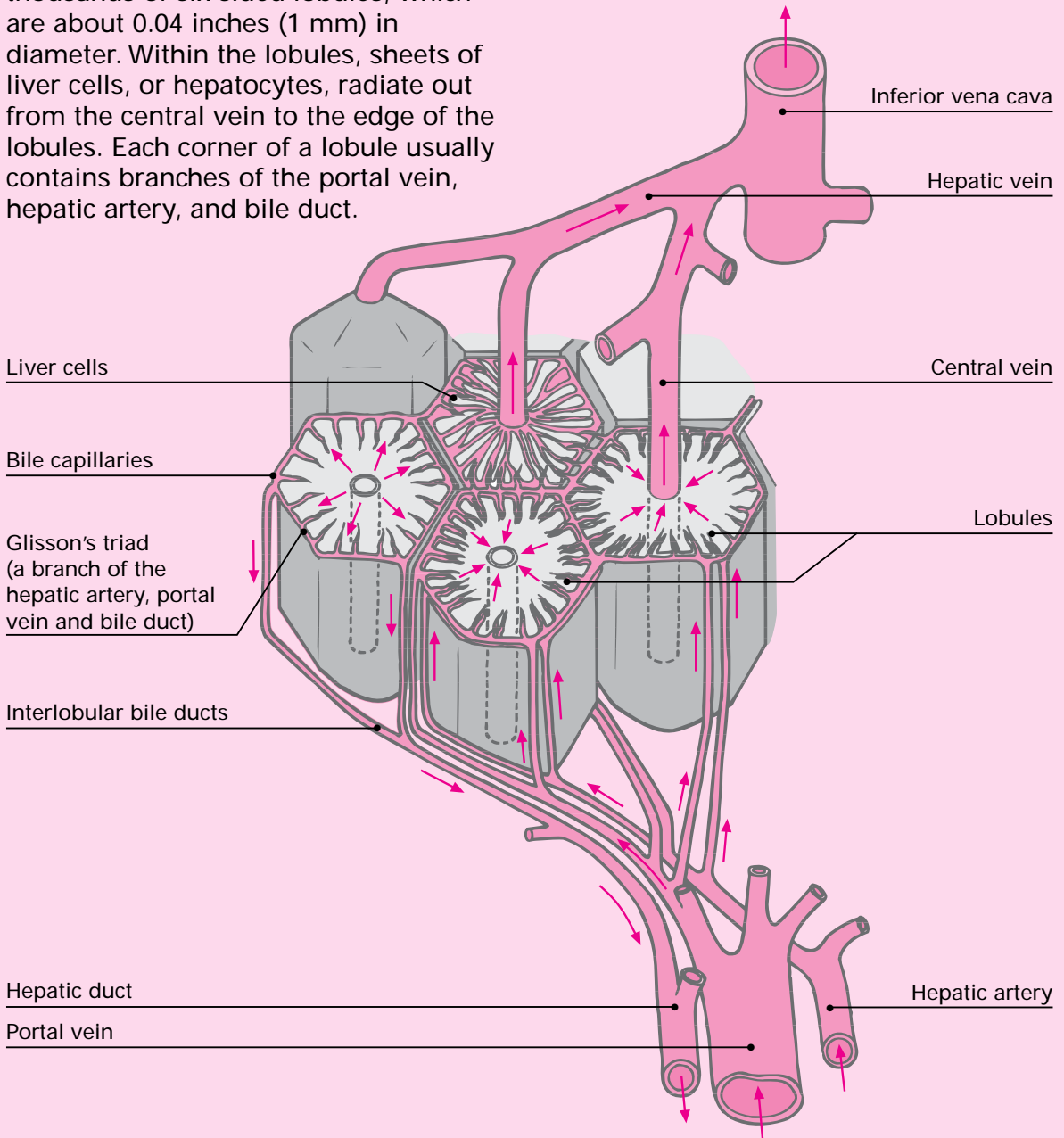
- The liver contains 50,000–100,000 lobules.
- Over 36 fluid ounces (1 l) of blood passes through the liver every minute.
- "Hepatic" comes from the Greek word for liver.

Hepatic circulation and bile ducts



Liver lobules

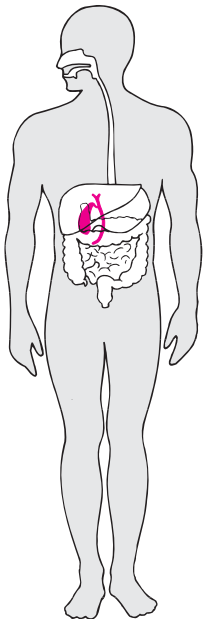
The lobes of the liver are made up of thousands of six-sided lobules, which are about 0.04 inches (1 mm) in diameter. Within the lobules, sheets of liver cells, or hepatocytes, radiate out from the central vein to the edge of the lobules. Each corner of a lobule usually contains branches of the portal vein, hepatic artery, and bile duct.



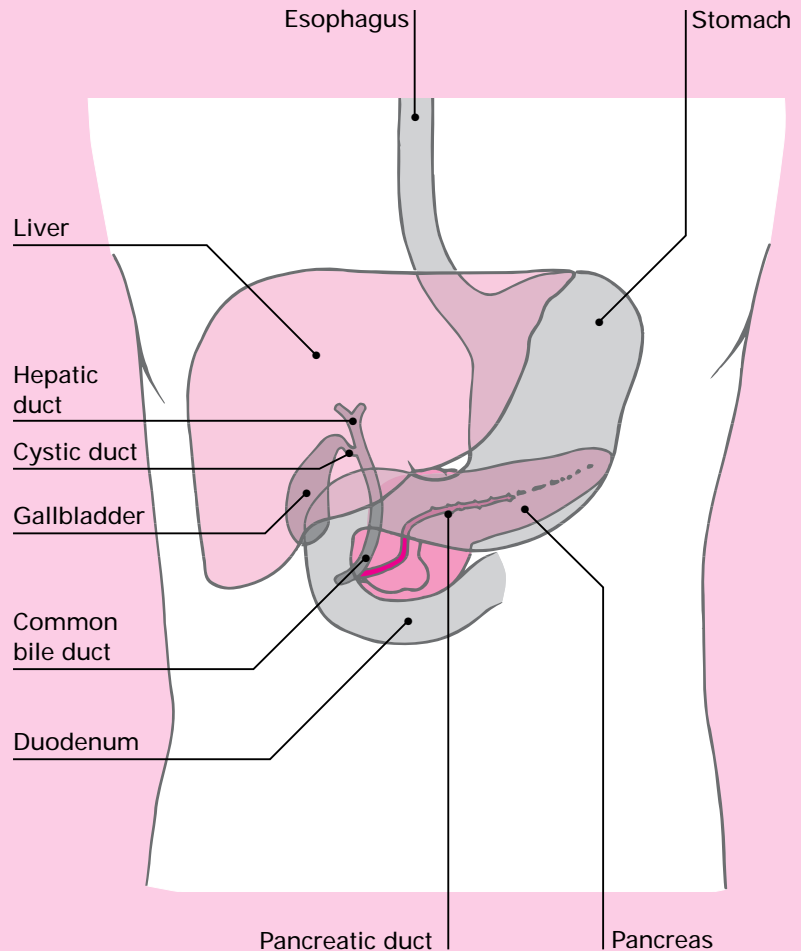
Functions

The functions of the gallbladder are to store bile, concentrate bile (by absorbing its water), and release bile into the small intestine. Bile helps to break down, or emulsify, large fat globules into smaller fat droplets. This increases the surface area for digestion. Loss of bile in the feces also serves to excrete cholesterol, bile pigments, hormones, and drugs from the body.

Locator



Upper abdominal digestive organs



Bile

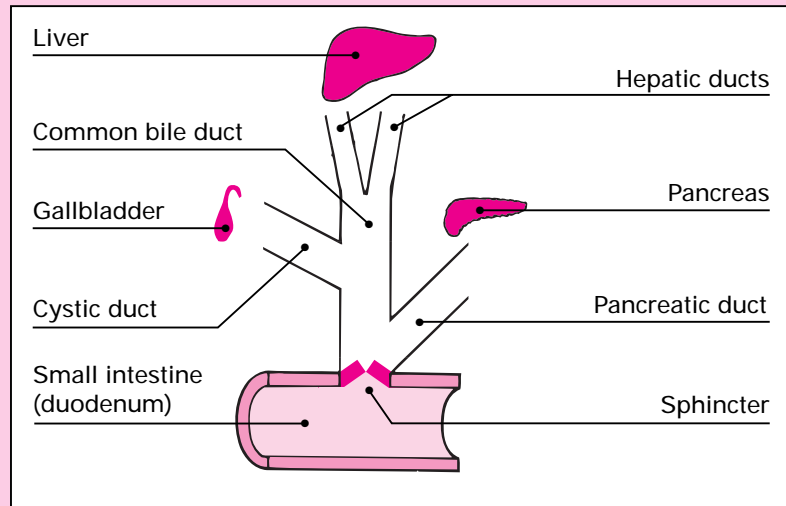
Bile is mainly made up of water. The other two major ingredients are bile salts (formed by the liver from cholesterol), and bile pigments (waste products from the destruction of red blood cells).

Gallbladder facts

- The gallbladder has a capacity of 1.5 fluid ounces (44 ml).
- The common bile duct is 3 inches (7.6 cm) long.

Bile ducts

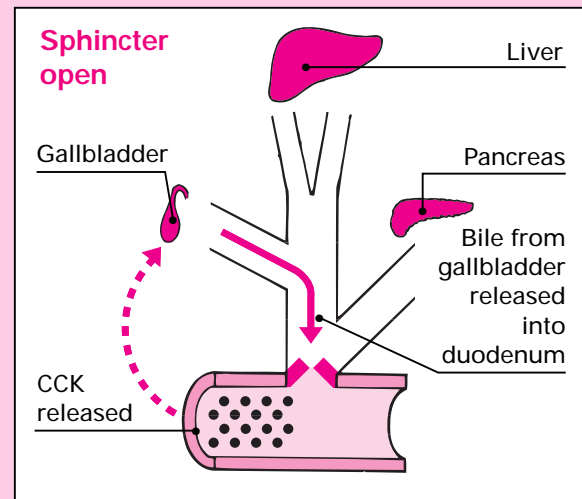
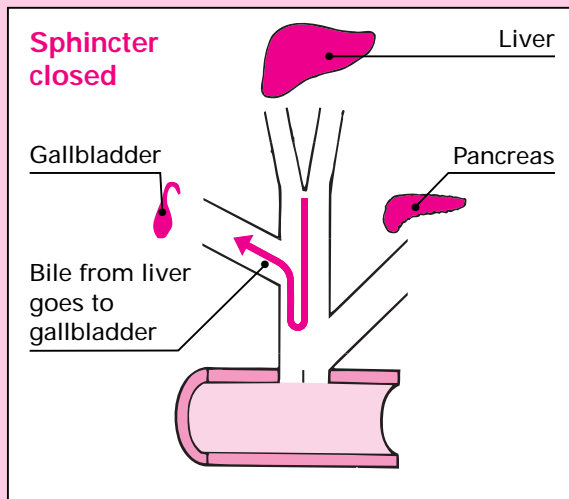
The liver continuously secretes bile, which drains out of the liver through the hepatic ducts. These join to form the common bile duct, which is linked to the gallbladder by the cystic duct. Just before it enters the duodenum, the common bile duct is joined by the pancreatic duct carrying pancreatic juices from the pancreas.



Bile storage and secretion

Where the common bile duct joins the duodenum, a sphincter controls the flow of bile and pancreatic juices into the duodenum. When the sphincter is closed, bile goes back up the ducts and is stored and concentrated by the

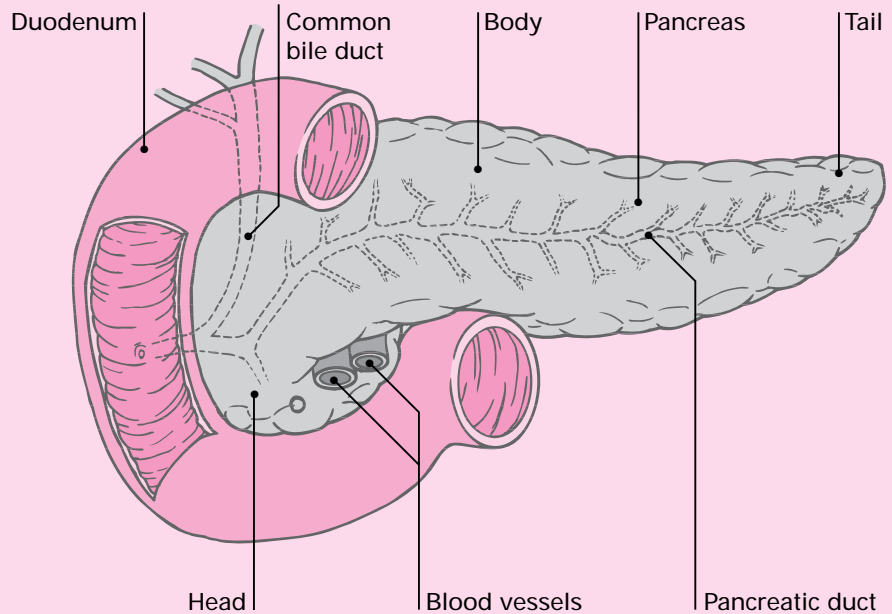
gallbladder. The presence of fat in the small intestine triggers the release of the hormone cholecystokinin (CCK), which causes the gallbladder to contract and the sphincter to relax and open. Bile is then squirted into the duodenum.



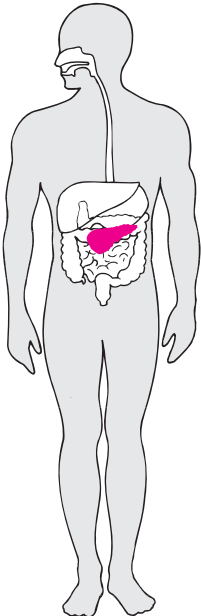
Functions

The pancreas is both an exocrine (ducted) gland that secretes digestive enzymes (pancreatic juice) into the pancreatic duct, and an endocrine (ductless) gland that secretes hormones. The hormones insulin and glycogen regulate the body's blood sugar level.

Anatomy of the pancreas



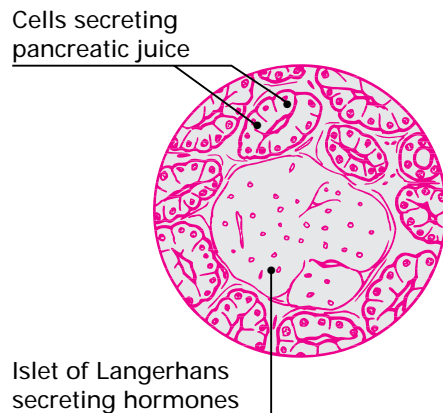
Locator



Islets of Langerhans

The hormones of the pancreas are secreted by clusters of cells, called islets (of Langerhans). These islets have no contact with any ducts, and their hormones pass straight into the blood flowing through the pancreas.

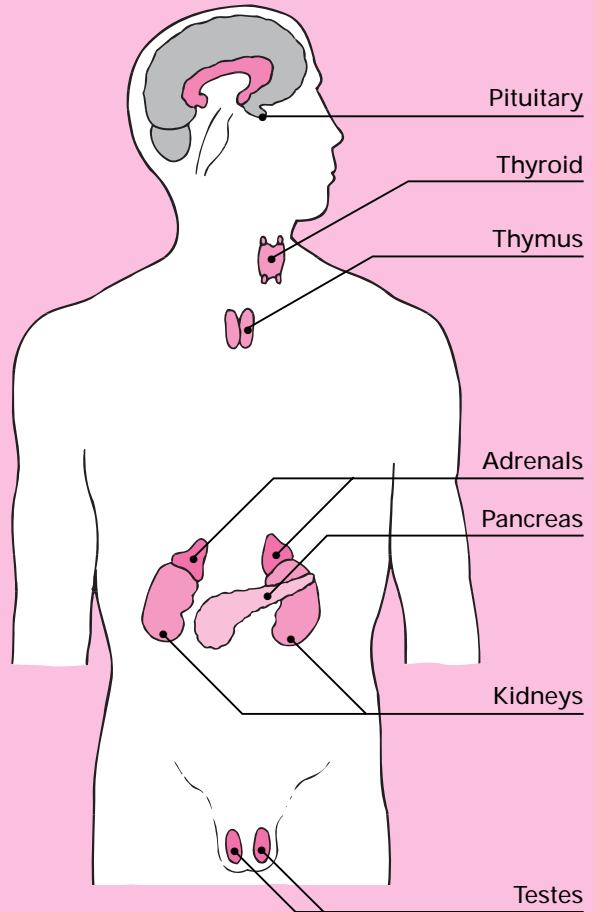
Section of the pancreas



Hormones of the pancreas

The islets of Langerhans consist of more than a million clusters of cells, but make up less than one hundredth of the pancreas by weight. They secrete two hormones, which are chemical messengers that travel in the blood. There are two types of cells in the islets: alpha cells, which secrete glucagon, and beta cells, which secrete insulin. Glucagon results in an increased blood glucose level. This is achieved by moving glucose and fatty acids from where they are stored in the body. Glucagon also stimulates the liver to release glucose and to manufacture glucose from proteins and fats. Insulin is secreted when there is a high level of glucose in the blood. It works in the opposite way to glucagon, and has the overall effect of decreasing blood sugar levels. Insulin stimulates the liver and muscles to remove glucose from the blood. When the liver has stored as much glucose as it can, excess glucose is converted into fat. Insulin also inhibits the manufacture of glucose from proteins and fats.

Glands that secrete hormones



Hormones

Glucagon

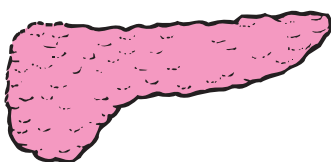
Target tissues

Liver

Effects

- increases the level of glucose in the blood

Insulin



Liver, skeletal muscles, adipose (fat tissue)

- decreases the level of glucose in the blood
- promotes the storage of glucose
- decreases the level of potassium in the blood

Pancreatic secretion

The secretion of pancreatic juice by the pancreas is stimulated by hormones from the small intestine.

1 Chyme (semifluid mixture of food and digestive juices) enters the small intestine.

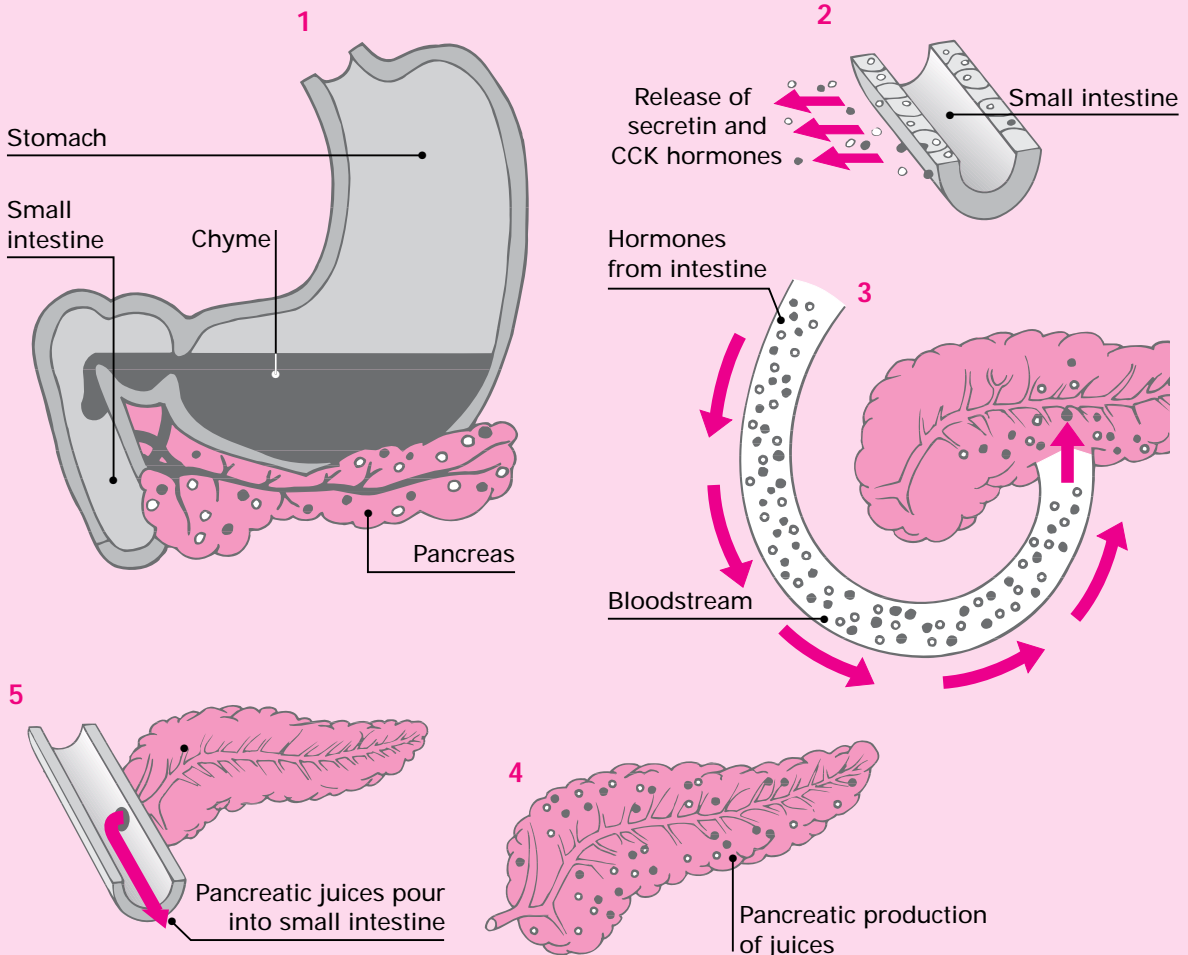
2 Release of the hormones secretin and cholecystokinin (CCK) is triggered.

3 These enter the bloodstream and travel to the pancreas.

4 Secretin stimulates the production of juice with a high bicarbonate content.

5 Cholecystokinin stimulates the production of juice with a rich enzyme content.

The secretion of pancreatic juices



Pancreatic juice

The main ingredient of pancreatic juice is water. It also contains digestive enzymes (proteins that act as biological catalysts) and bicarbonate (a salt). Pancreatic juice is the main agent of chemical digestion. This occurs, however, in the small intestine. In order

to protect the pancreas, most of the enzymes are secreted in an inactive form and then activated by other enzymes, or the presence of bile, when they reach the small intestine. The chart below shows the functions of each of the agents in pancreatic juice.

Agent	Function
Trypsinogen (inactive enzyme)	• inactive form of trypsin activated by the intestinal enzyme enterokinase
Chymotrypsinogen (inactive enzyme)	• inactive form of chymotrypsin activated by trypsin
Peptidases (inactive enzymes)	• inactive enzymes activated by trypsin
Trypsin (active enzyme)	<ul style="list-style-type: none"> • reduces proteins into shorter chains of amino acids called peptides • activates chymotrypsinogens and peptidases
Chymotrypsin (active enzyme)	• reduces proteins into peptides
Peptidases (active enzymes)	• reduce segments of proteins called peptides into their building blocks: amino acids*
Lipase (active enzyme)	• breaks down fats into their components: monoglycerides* and fatty acids*
Pancreatic amylase (active enzyme)	• reduces complex carbohydrates (for example, starch) into disaccharides (double sugars)
Bicarbonate (salt)	<ul style="list-style-type: none"> • neutralizes acidic chyme • provides correct environment for chemical digestion

* substances ready for absorption

Liver disorders

Causes of liver disorders, such as hepatitis, include drinking too much alcohol, viral infections of the liver, and drug abuse. Long-term damage from any of these causes can lead to cirrhosis (scarring) of the liver. Hepatitis causes the liver to swell up and stop working well. It is often caused by a viral infection, particularly with hepatitis A, B, or C viruses. There are vaccines for hepatitis A and B, but not for C. Viral hepatitis is usually an acute, short-lived illness. Most people get over the acute inflammation in a few days or weeks. Sometimes the inflammation does not go away, and develops into chronic hepatitis, which can cause liver failure and death.

Viral hepatitis

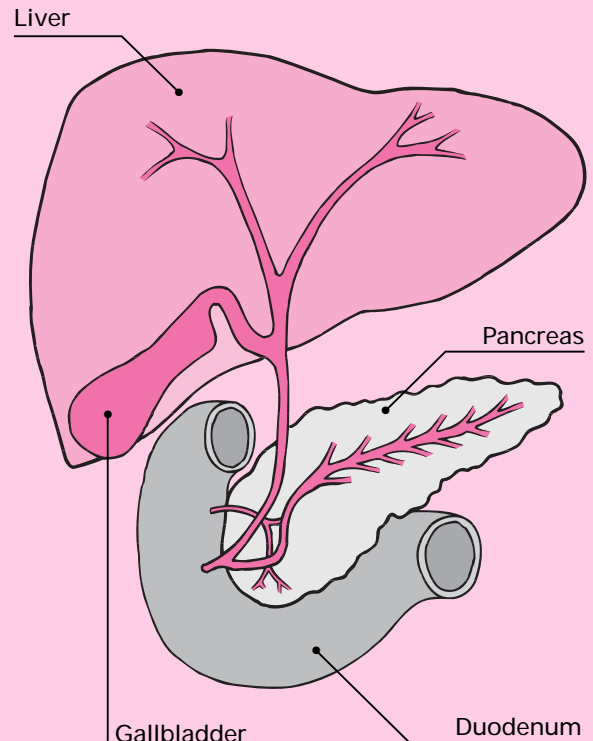
Several viruses can infect the liver. Each one is named with a letter of the alphabet. People usually get hepatitis A or E by drinking water infected with the virus. Hepatitis B is spread through infected blood or syringes, while hepatitis C is usually spread through contact with infected blood, e.g. by sharing syringes. Hepatitis D is a defective virus that needs hepatitis B to exist. People can only get hepatitis D if they already have hepatitis B.

Sites of liver problems

In alcoholic hepatitis, the liver becomes inflamed, and damage allows yellow bile pigment to enter the bloodstream, causing jaundice. The spleen is enlarged, fluid collects in the abdominal cavity, and there is usually fever.

Hepatitis A, B, C, D, and E also feature an inflamed liver but are due to viral infection. Abdominal discomfort and fever occur, and jaundice develops. In rare cases the liver is destroyed and the patient dies.

Cirrhosis is a chronic liver disease that destroys liver cells, replacing them with fibrous material; the liver may enlarge and harden. As it stops working properly, there may be internal bleeding, or blocked blood flow. Accumulating fluid may stretch the abdomen, and jaundice and kidney failure are likely.



Signs and symptoms

This illustration locates the sites of some of the signs and symptoms that are produced by certain ailments affecting the liver. Some of these conditions plainly show disease that needs urgent medical aid, whereas others hint at trouble less dramatically. Many of the symptoms are common to various ailments, some slight and some serious, and a doctor's diagnosis of liver disease will often depend on the presence of several or many of these signs and symptoms. See a doctor immediately if you experience any of these severe symptoms, or if you exhibit several of the slighter ones at the same time.

1 Fever occurs in hepatitis.

2 Yellowing of the whites of the eyes and the skin indicates jaundice, which is a common symptom of hepatitis. This is caused by a waste product, bilirubin, which builds up in the blood and tissues when the liver is not working properly.

Bilirubin and other waste products may also cause itching, nausea, fever, and body aches.

3 Nausea and loss of appetite, perhaps with vomiting, also occur in hepatitis and cirrhosis.

4 Thin, spider-shaped blood vessels suddenly showing up on the face, upper trunk and arms are often caused by cirrhosis of the liver.

5 A swollen and tender liver often indicates early cirrhosis; the liver may become shrunken as the condition progresses.

6 White nails are a common sign of cirrhosis, and the ends of the fingers may become clubbed in shape.

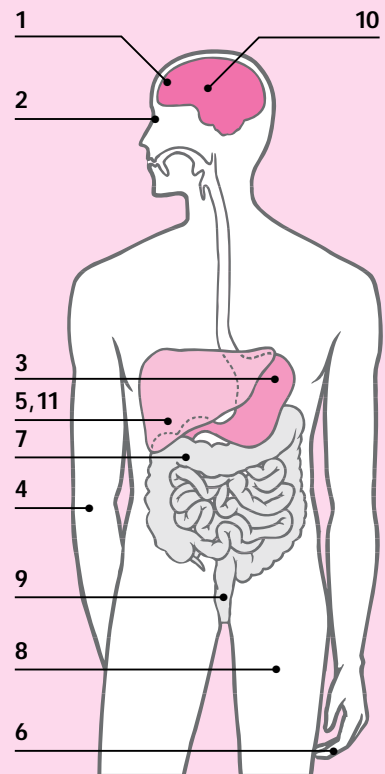
7 Severe pain in the upper right part of the abdomen may be caused by hepatitis.

8 Weight loss is often associated with cirrhosis and hepatitis.

9 Dark-colored urine and pale stools can be a sign of advanced hepatitis.

10 Muscle aches, headaches, and tiredness can be common early signs of hepatitis.

11 Liver abscesses can cause fever, nausea, weight loss, liver enlargement, and chest pain. They can be caused by infection with bacteria or amoebas. Bacteria may spread from another part of the body, such as the appendix. Diarrhea may precede amoebic liver abscesses, which are common in the tropics.



Inflammation of the pancreas may be due to viral infections, gallstones, or alcohol abuse. If the pancreas does not produce enough insulin, the amount of glucose builds up in the blood and diabetes will develop. Insulin-dependent diabetes, also called juvenile onset diabetes, usually affects people under 40 years of age. Non-insulin dependent diabetes, or late onset diabetes, usually affects older people. Most disorders of the gallbladder are due to the presence of gallstones.

People at risk

Pancreatitis often occurs in alcoholics, and individuals with bile tract disease. Overweight white women aged over 40 seem most liable to gallstones, although the reasons for gallstone formation are still unclear. Diabetes among adults may be linked with excessive carbohydrate intake.

Pancreas and gallbladder problems

Pancreatitis is inflammation of the pancreas, when pancreatic enzymes build up inside it, for instance if a gallstone blocks its outlet. It may occur in association with disease of the gallbladder. Steady, severe upper abdominal pain and vomiting after excessive alcohol intake may signal an acute attack. In chronic pancreatitis, people suffer recurrent but milder attacks. Swift medical aid is essential; treatment includes bed rest, and at first only intravenous nourishment. **Diabetes** occurs when the pancreas fails to make any or enough of the hormone insulin

which the body needs for using sugar and starches. Juvenile onset diabetes usually involves the complete failure of the parts of the pancreas that make insulin (the islets of Langerhans); in these cases insulin injections are needed at regular intervals. In late onset diabetes, the islet failure is often only partial, and if this is the case, the patient can be treated with diet regulation and tablets. Regular meals help to keep the sugar and insulin in balance—too much or too little sugar can cause coma. Complications of diabetes may include arterial degeneration, heart disease, kidney disease, gangrene of the feet, and

retinopathy (retinal hemorrhages). Untreated severe diabetes can produce coma and death. **Gallstones** are small lumps, usually of cholesterol, forming in people who tend to overconcentrate cholesterol in the bile. They may occur in the gallbladder without causing discomfort, but can also lodge in the bile duct, causing pain and jaundice.

Cholecystitis is inflammation of the gallbladder. An acute form may be due to bacterial infection of the gallbladder. Chronic cholecystitis is usually due to gallstones. If they block the bile duct, there may be liver damage.

Signs and symptoms

This illustration locates the sites of some of the signs and symptoms produced by certain ailments affecting the pancreas and gallbladder.

1 Excessive fatigue and lethargy are common signs of juvenile onset diabetes. Coma may result if the condition is left untreated.

2 Insatiable thirst strongly suggests diabetes.

3 Breath that smells fruity and sweet is another common sign of diabetes.

4 Diabetes may affect the eyesight because blood vessels in the retina can be damaged.

5 Fever occurs in pancreatitis.

6 Sweating and shock may be caused by pancreatitis.

7 Belching associated with severe right-sided upper abdominal pain may occur in gallstone troubles. The pain may spread to the right shoulder blade. This usually happens within an hour of eating, and lasts several hours. Where symptoms occur

only after eating fats, a low-fat weight-reducing regime, supplemented with vitamins, may suffice. Doctors sometimes remove the gallbladder to avoid possible fatal bile blockage.

8 Nausea and loss of appetite, perhaps with vomiting, occur in pancreatitis.

9 A painful sensation of fullness in the stomach is another sign of pancreatitis.

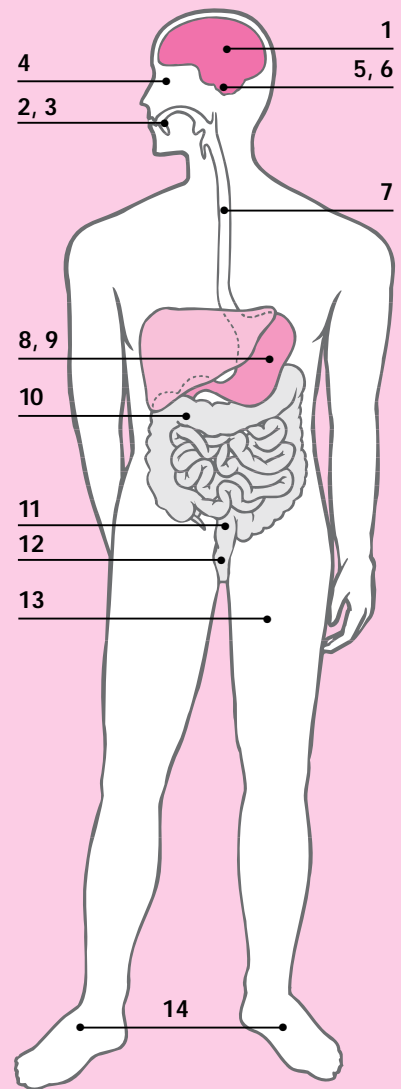
10 Severe pain in the upper right part of the abdomen may be caused by gallbladder inflammation.

11 Clay-colored stools are one symptom of gallbladder inflammation and indicate that the bile duct has been blocked; an emergency operation is necessary.

12 Heavy urine output may well indicate diabetes; in women, intense itching of the vulva may also occur. Dark brown or yellow urine may be indicative of gallbladder disease.

13 Weight loss is often associated with diabetes.

14 Long-term diabetes may damage the nerves and



cause numbness in the feet. If this happens, a diabetic person may injure or burn their feet. Keeping the feet clean and dry and wearing shoes that fit well is very important for diabetics.

The urinary system is one of the methods by which the body eliminates toxins and wastes produced during chemical reactions inside body cells. It produces a fluid waste called urine. The system consists of two bean-shaped kidneys, a muscular bladder, two tubes called ureters linking the kidneys to the bladder, and one tube called a urethra, through which the urine from the bladder leaves the body.

Urinary system facts

- The right kidney is usually 0.4–0.8 inches (1–2 cm) lower than the left one.
- Each ureter is about 12 inches (30 cm) long.
- The bladder holds about two pints (1 l) of urine.

Functions

The urinary system filters the blood, removes wastes, and flushes wastes out through the urine. Other functions of the system include maintaining the balance of water and salts in the body, and regulating the acid-base balance of the blood.

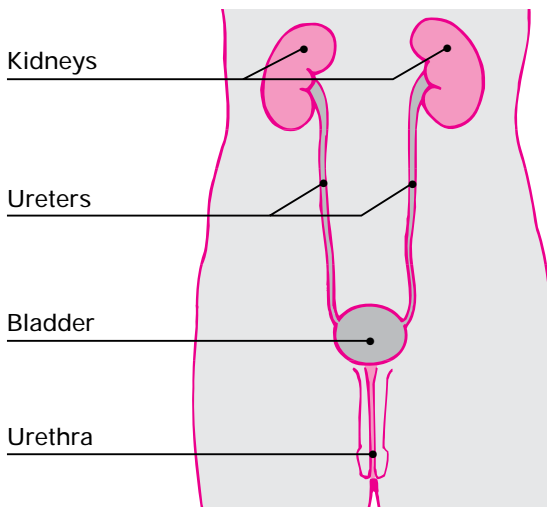
The kidneys remove wastes, excess water, and salts from the blood, and form urine, which is a pale yellow, slightly acid fluid. They also secrete the

hormones renin and erythropoietin, and activate vitamin D. The ureters take urine from the kidneys to the bladder.

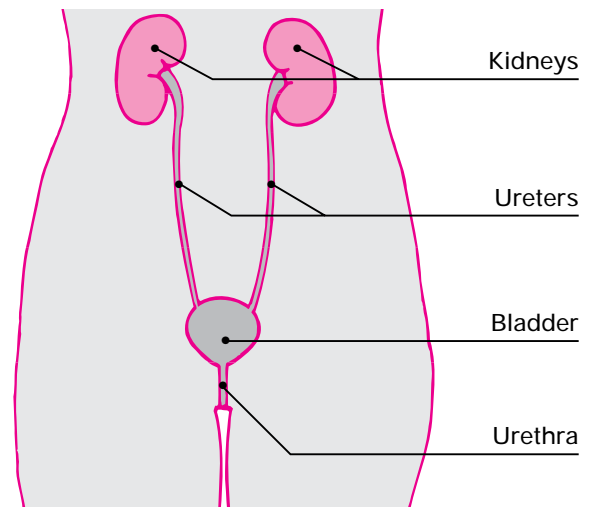
The bladder is a stretchable bag near the base of the abdomen, which collects and stores urine.

The urethra is the duct through which urine from the bladder flows to the outside of the body during urination. In men, it also carries sperm during ejaculation.

Male



Female



Urinary system: key words**Adrenal glands** (or Suprarenal glands)

Two endocrine glands, situated one above each kidney. The adrenal glands secrete adrenaline and noradrenaline, as well as various hormones.

Bladder A sac, especially the muscular bag inside the pelvis where urine collects before being expelled from the body.

Bowman's capsule (or Glomerular capsule)

The dilated end of a kidney tubule: a little cup surrounding a glomerulus.

Calyx A cup-shaped part. *See also***Renal calyx.****Capsule** *See* Renal capsule.**Cortex** *See* Renal cortex.

Epithelium The cell layer covering the outer surface of the body and lining the urinary, gastrointestinal and respiratory tracts.

Glomerular capsule *See* Bowman's capsule.

Glomerulus A convoluted mass of blood-filtering capillaries in a nephron.

Kidney A bean-shaped organ that filters wastes from blood to form urine. The two kidneys lie in the upper rear of the abdomen, one on each side of the vertebral column.

Loop of Henle The U-shaped turn in the medullary portion of a renal tubule.

Medulla The inner part of any organ that is distinguishable from the outer part or cortex. *See also* Renal medulla.

Mucous membranes The mucus-secreting linings of the urinary, digestive, respiratory, and reproductive tracts.

Nephron The basic filtration unit in a kidney. *See also* Glomerulus; Renal tubule.

Pelvis *See* Renal pelvis.**Renal** Relating to the kidney.**Renal artery** The large artery supplying

a kidney. It arises from the abdominal aorta and divides into an anterior and a posterior branch.

Renal calyx A recess enclosing a pyramid within the renal pelvis.

Renal capsule The tough, fibrous sheath in which a kidney is enclosed.

Renal cortex The outer layer of a kidney, situated immediately beneath its fibrous capsule, and containing the nephrons.

Renal medulla The inner part of a kidney, composed mostly of collecting elements and loops of Henle organized into pyramids.

Renal pelvis The core of a kidney, containing the broad upper end of a ureter.

Renal pyramid One of the conical masses that constitute the renal medulla.

Renal tubule (or Uriniferous tubule) A tiny, convoluted tube within a kidney, forming part of a nephron.

Renal vein The large vein taking blood from the kidney, usually to the inferior vena cava.

Sphincter A ring of muscle around an opening. *See also* Urinary sphincter.

Suprarenal glands *See* Adrenal glands.**Tubule** A tiny tube. *See also* Renal tubule.

Ureter The tube conveying urine from a kidney to the bladder.

Urethra The passage taking urine from the bladder to the body's exterior. The male urethra stretches along the penis to its tip.

Urinary sphincter The ring of muscle between the bladder and the urethra.

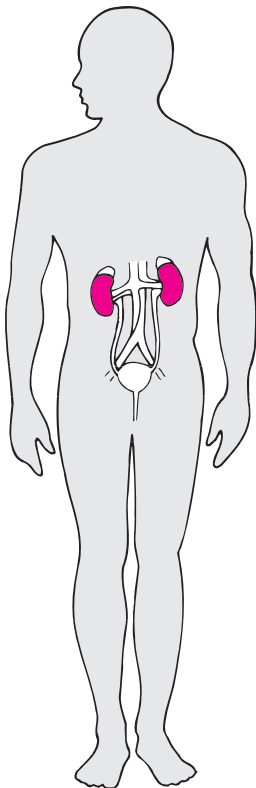
Urinary system The kidneys, ureters, bladder, and urethra.

Urine Liquid waste excreted by the kidneys.**Uriniferous tubule** *See* Renal tubule.

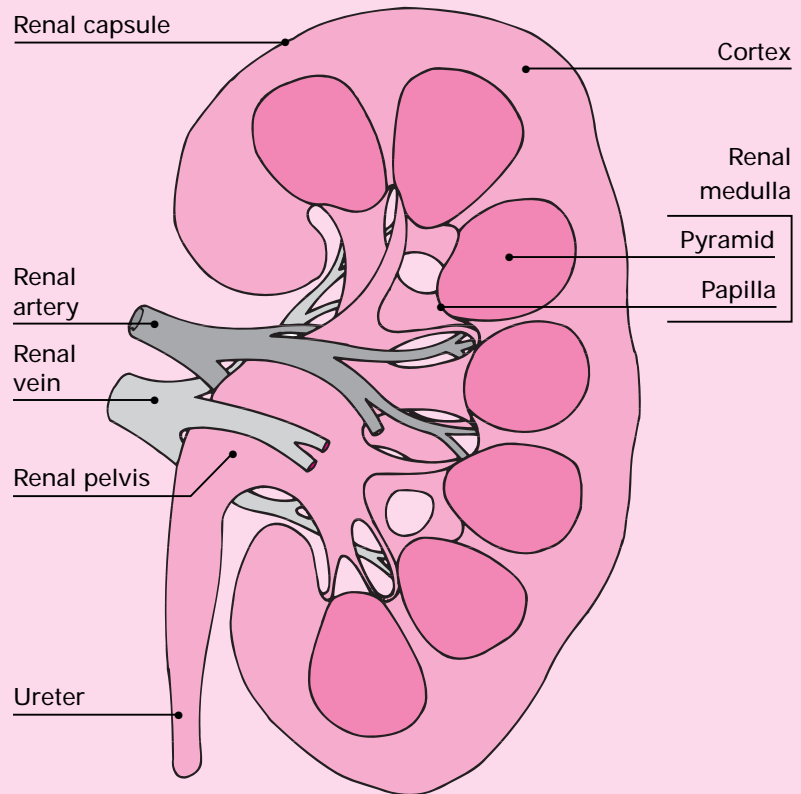
Macro structure

Each kidney is covered by a layer of connective tissue called a renal capsule. It has three distinct regions—the renal cortex on the outside, the renal medulla in the middle, and the renal pelvis on the inside. The renal pelvis is an expansion of the upper end of a ureter.

Locator



Section through a kidney



Renal medulla

The middle of the kidney, the renal medulla, is divided into triangular sections called renal pyramids. The narrow, innermost end of a pyramid is called a papilla. Renal pyramids consist of tubules and collecting ducts of the nephrons that form urine.

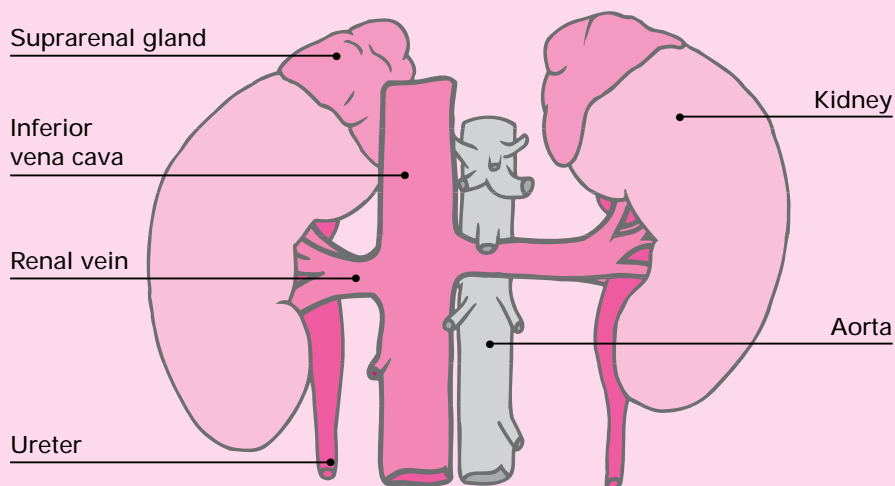
Kidney facts

- Each kidney is about 4.7 inches (12 cm) long, and 2.7 inches (7 cm) wide. It weighs about 4.8 ounces (135 g).
- About a third of a gallon (1.2 l) of blood passes through the kidneys every minute.

Blood supply

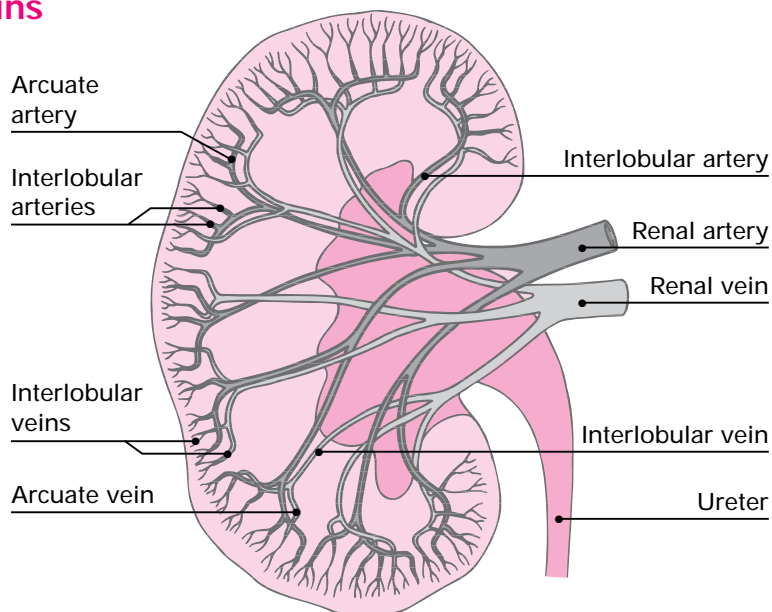
Oxygenated blood comes to each kidney from the abdominal aorta through the renal artery, which delivers 20 percent of the blood pumped by the heart each minute. Deoxygenated blood leaves the kidneys through the renal vein, which carries blood to the inferior vena cava.

Front view of kidneys and blood vessels



Renal arteries and veins

Inside the kidney, the renal artery branches into the interlobular arteries, which pass through the renal columns (cortical tissue between the renal pyramids). When the arteries reach the cortex, they form arcuate arteries, which run parallel to the bases of the renal pyramids. The arcuate arteries branch into interlobular arteries, which stretch up into the cortex. The arcuate veins branch into interlobular veins, which stretch up into the cortex.



Cleaning the blood

Nephrons are the microscopic filtration units within a kidney. More than a million nephrons make up the medulla and cortex of each kidney. Different parts of the nephron are responsible for different functions. These include filtration (the process by which substances are filtered out of blood), reabsorption (the process by which substances are taken out of urine and put back into blood), and secretion (the process by which substances are taken out of blood and put into urine).

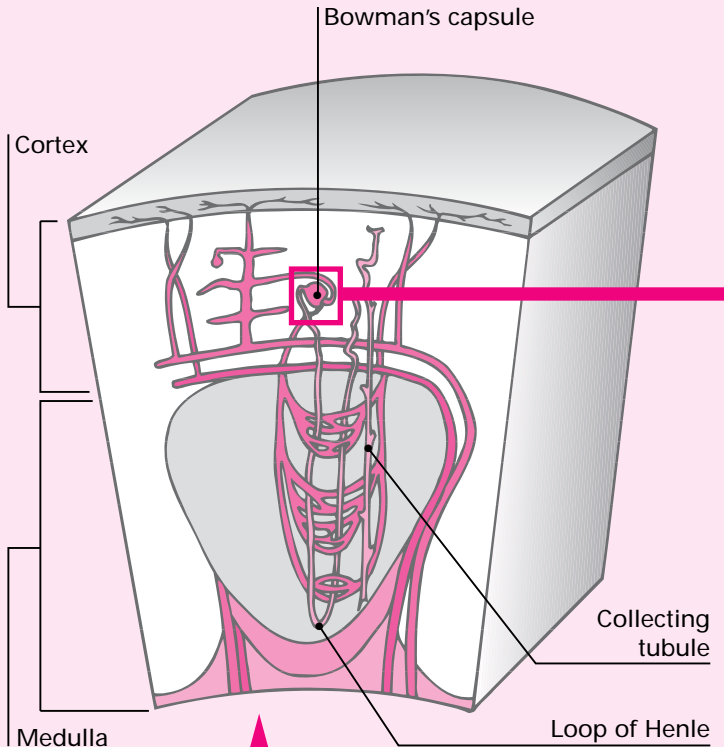
Nephron structure

Nephrons look like tiny funnels with very long, and convoluted, stems. Each nephron consists of several parts. Blood is filtered through a tiny knot of blood capillaries called a glomerulus housed within a structure called the Bowman's capsule.

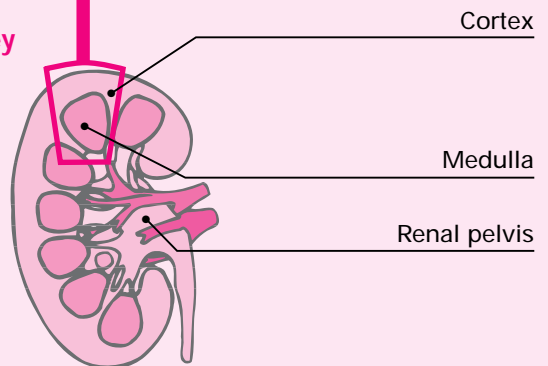
Each Bowman's capsule is the expanded beginning of a long, thin renal tubule (small tube) with many bends, which winds away from the glomerulus and capsule, and joins with other tubules to form a larger collecting tubule. The kidney medulla contains the looped ends of the renal tubules, while the kidney cortex contains many thousands of glomeruli. The length of the kidney tubules are entwined with blood capillaries, facilitating filtration, reabsorption, and secretion.

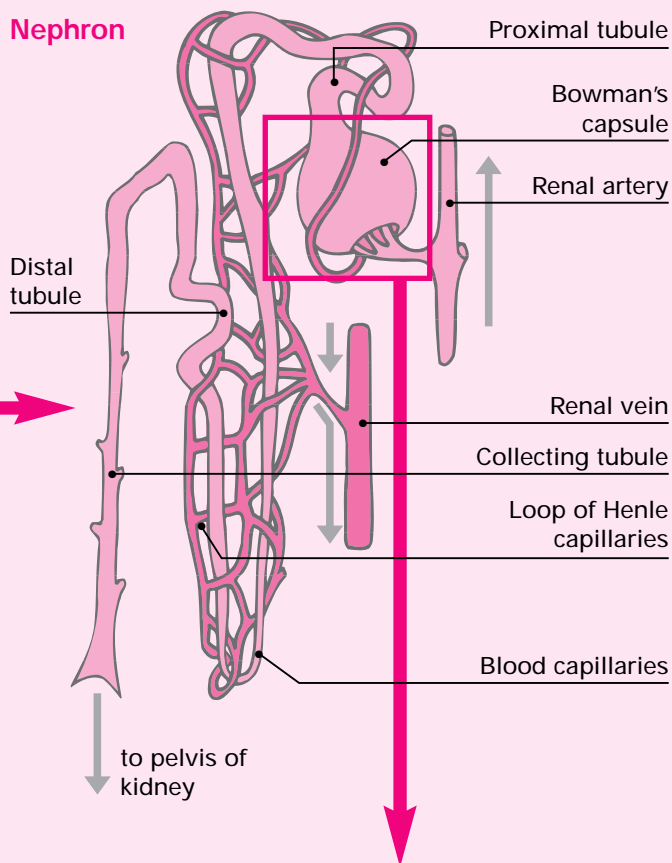
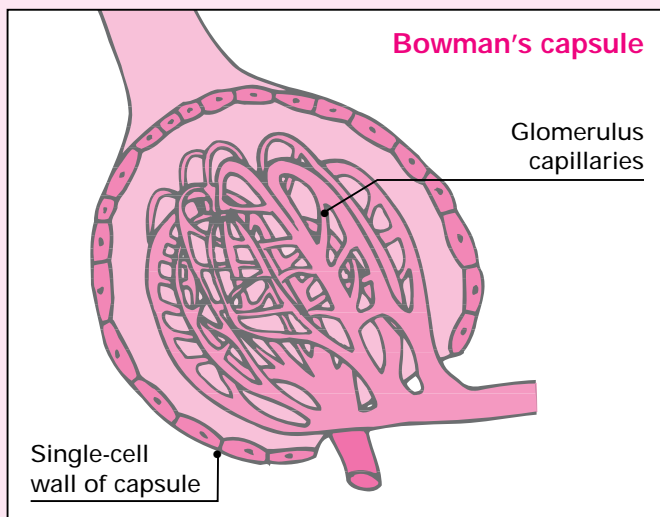
Structure and function

Inside a kidney



Whole kidney



Nephron**Bowman's capsule****Nephron function**

Blood from the renal artery is forced into the glomerulus capillaries inside the Bowman's capsule. Large molecules and blood cells do not pass through the capillaries, but water and wastes filter through into the Bowman's capsule.

The fluid that has been filtered then passes along the coiled renal tubules, which run in great U-shaped loops through the medulla of the kidney. Each tubule consists of a proximal tubule, a loop of Henle, and a distal tubule. Water and solutes (dissolved substances) are reabsorbed back into the blood in the proximal tubule.

In the loop of Henle, sodium and chloride ions are reabsorbed from the filtered fluid back into the blood. This process continues in the distal tubule, where water is also reabsorbed. Here, certain substances (ammonia, potassium ions, hydrogen ions, and some drugs) are secreted from the blood into the urine solution.

Collecting urine

The distal tubules from different nephrons unite to form a collecting tubule which runs down toward the renal pelvis. This tube drains urine into the bladder. The kidneys can vary the amount of a substance that is reabsorbed or secreted, which changes the volume and composition of urine.

Formation of urine

About 44 gallons (200 l) of filtered water and wastes are produced by the glomeruli each day. But most of the water, glucose, other nutrients, and sodium and other ions are reabsorbed into the blood as the filtrate trickles round the tubules of the nephrons. This brings the actual volume of urine produced down to one third of a gallon (1.2 l) a day.

Ureters

The passage of urine down the ureters occurs as they contract and relax their muscular walls (by peristalsis). Jets of urine are squirted from the ureters into the bladder at a rate of one to four times per minute.

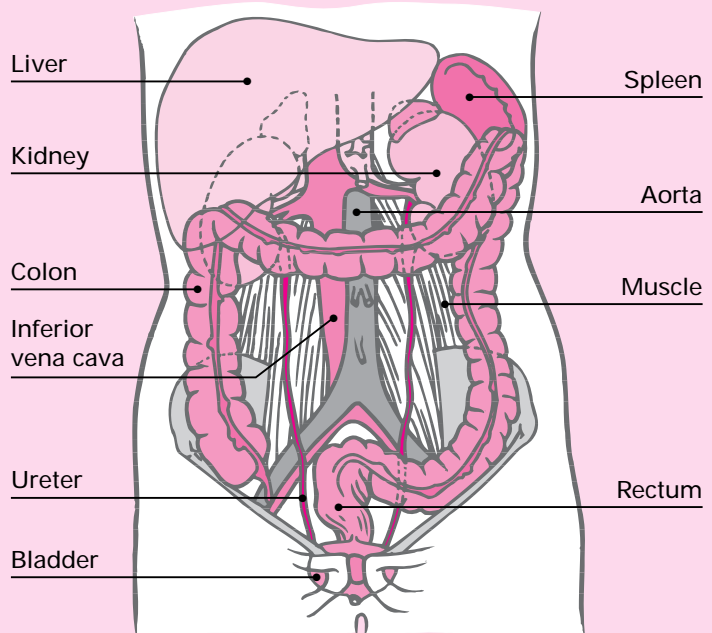
Bladder

The bladder is a temporary storage for urine. Generally the bladder is emptied when about 1 pint (500 ml) of urine is present. Pressure in the bladder begins to be felt once about half a pint (300 ml) has collected.

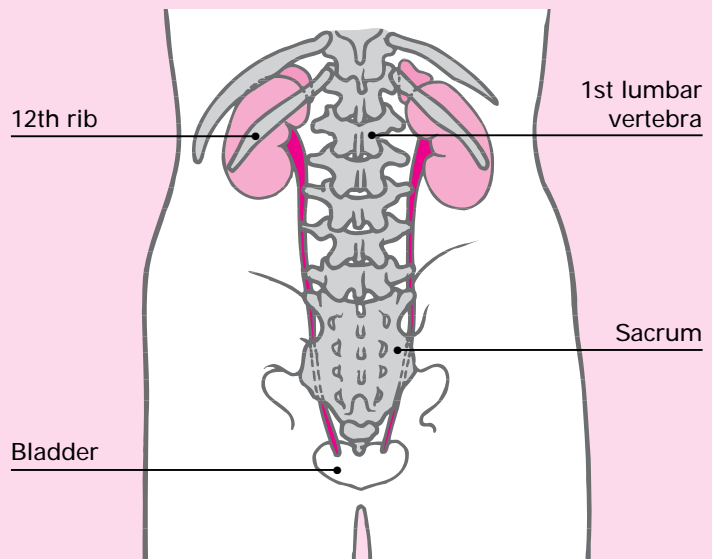
Urethra

The urethra has an internal sphincter, which keeps it closed when urine is not being passed, and an external sphincter. Both must relax for urination to take place; the internal sphincter is not under voluntary (conscious) control, but the external sphincter is.

Urinary tract and abdominal organs



Urinary tract and spine



Composition and properties

Urine is a slightly acidic, usually clear or yellowish fluid produced by the body as a means of expelling waste products. The volume of urine produced and its composition vary according to how much a person eats and drinks, physical activity, general state of health, temperature, and other factors. It is generally about 95 percent water and 5 percent metabolic waste products (although the proportion varies depending on the concentration of the urine). It may also contain drugs that have not been produced by the body but which need to be expelled.

Color

The yellow color of urine is due to a pigment called urobilinogen/urobilin, derived from the body's destruction of hemoglobin. Certain foods, drugs, and infections alter urine color and clearness; also, it is darker when concentrated.

Specific gravity

When comparing the weight of a substance with the weight of distilled

water, the term specific gravity is used. The specific gravity of distilled water is 1.000. The specific gravity of urine ranges from 1.001 to 1.035, meaning that it is slightly heavier than water.

Constituents

Urine is made up of, in addition to water, urea (derived from the breakdown of protein), sodium, potassium, phosphates, sulfates, creatinine (derived from the breakdown of body tissues), and uric acid (a waste product of metabolism). Certain diseases alter this composition.

Acidity

The term pH is used to describe the acidity or alkalinity of substances. Urine has a pH range of 4.5 to 8.0, so it tends to be acidic. Diets high in protein make urine more acidic; vegetarian diets make it more alkaline.

Odor

Fresh urine has little smell, but if allowed to stand, it smells of ammonia. Certain vegetables, drugs, and diseases alter its usual odor.

Properties of urine

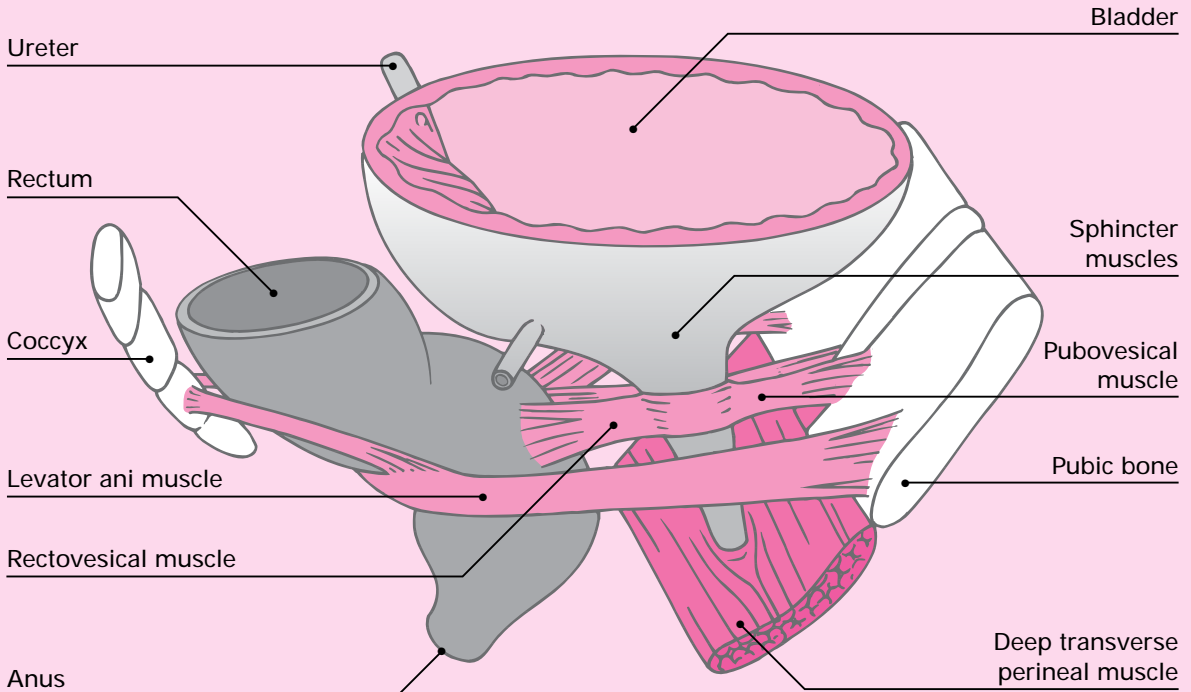
Volume	1–2 liters over 24 hours
Constituents	95 percent water, 5 percent solutes (but can vary)
Color	yellow (but can vary)
Odor	smells of ammonia if left to stand
Turbidity	transparent; becomes cloudy if left to stand
pH	between 4.5 and 8.0
Specific gravity	between 1.001 and 1.035

Urinary bladder

The empty urinary bladder sits in the pelvis, but when full of urine, it projects upward into the lower part of the abdominal cavity. The bladder is a hollow, muscular organ that can distend considerably. This means that its size and shape vary. The wall of the bladder has three layers: a tough outer serosa, a thick middle layer of meshed muscle fibers, and an inner layer of mucosa, which prevents acidic urine from damaging the cells. The inner lining is loosely attached to the deeper muscle layer so it is very wrinkled and covered

in folds called rugae when the bladder is empty. When the bladder is full, the inner surface is smooth. At the base of the bladder is the trigone, a triangular area extending between the openings of the two ureters above, and the urethra below. The trigone membrane is always smooth because the lining membrane at this point is tightly fixed to the deeper muscle coat. At the urethral opening is a muscle that forms the internal urethral sphincter. Another sphincter, the external urethral sphincter, is located just below, outside the bladder.

Bladder and pelvic floor muscles

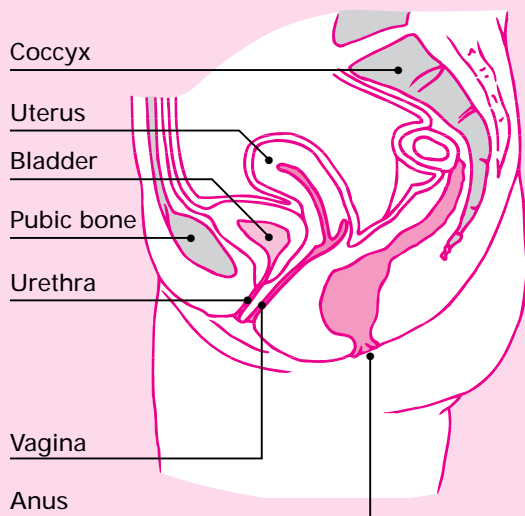


Urethra

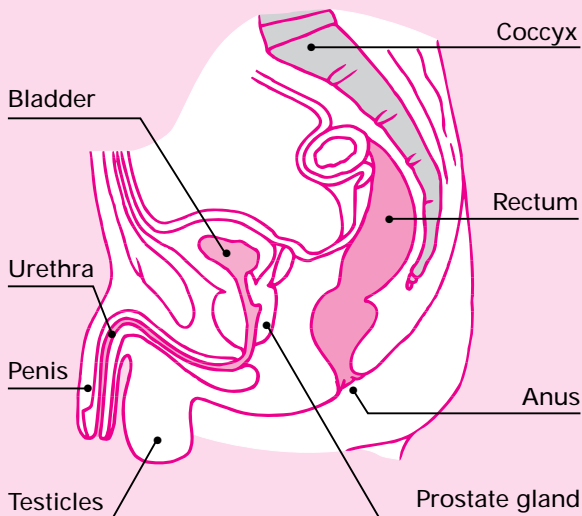
The urethra is the narrow tube through which urine leaves the body, and so it is the lowest part of the urinary system. In women, the urethra is about 1.5 inches (4 cm) long. In men, the urethra is about 7–8 inches (18–20 cm) long, and stretches from the bladder, through the

prostate gland, and along the penis. It serves as a passageway for both urine and semen. In women, the urethra is a part only of the urinary tract and is not part of the reproductive system. The shorter urethra in women makes them more prone to urinary infections.

Female



Male



Micturition

Micturition is another term for urination or voiding. It is partly under voluntary and partly under involuntary (unconscious) control.

When there is about 10 fluid ounces (300 ml) of urine in the bladder, stretch receptors in the bladder wall trigger the involuntary micturition reflex. The reflex transmits an impulse to the spinal cord, then to the bladder, and the urethra's

internal sphincter. In adults, urination occurs when a voluntary impulse is sent to the urethra's external sphincter, relaxing it and allowing the urine to pass through and out of the body. For this reason, it is possible to control urination. Urination can occur without this conscious reflex, as is the case in infancy or with a condition called incontinence.

Urinary tract problems

1 In diabetes insipidus, a faulty hypothalamus stops the secretion of vasopressin (a hormone), so the kidneys reabsorb too little water. The result is high urine output and intense thirst. Treatment involves replacing vasopressin by injection or nasal spray.

2 An ectopic kidney is a kidney in an abnormal position (such as two kidneys on one side of the body). Ectopic kidneys are liable to kidney stones, infection, and blocked urine flow.

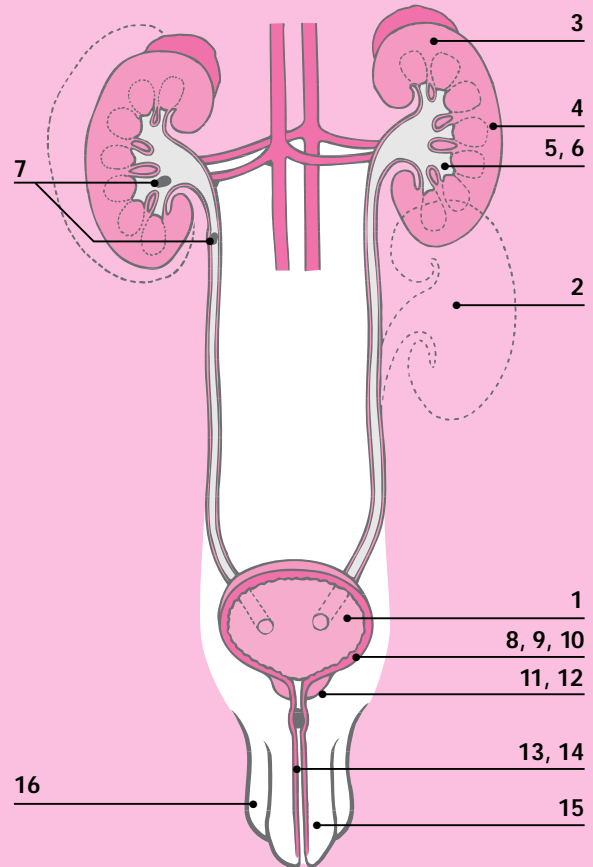
3 Some people are born with only one kidney, or have one removed, but one kidney can do the work of two.

4 Glomerulonephritis involves inflammation of the glomeruli, filtering capillaries within the kidney's nephrons. Water accumulates in body tissues and there may be kidney damage and heart failure.

5 Pyelonephritis (kidney infection) may produce kidney damage and toxins in the blood.

6 Sudden kidney failure can be due to burns, injury, shock, heart attack, drugs, or certain other factors. Acute kidney failure can cause loss of kidney function, pulmonary edema (build-up of watery fluid in the lungs), hemorrhage, and uremia (poisoning by toxins accumulating in the body). Severely ill patients may need to use an artificial kidney machine until their own kidneys can restart.

7 Stones may form in the kidneys from dissolved substances that have precipitated out from urine and grown around bacteria or other tiny nuclei.



Small, smooth stones escape in the urine. Large stones stuck in the kidney or ureter can cause bleeding, extreme pain, and kidney damage. Such stones need to be removed by surgery or destroyed by ultrasound. If a stone blocks a ureter, urine accumulates above the stone, distending the ureter and enlarging the space inside the kidney. Kidney tissue grows thinner and may be destroyed.

8 Cystitis is caused by inflammation of the bladder, often with urethritis, and is especially prevalent in women. Symptoms include a frequent urge to urinate (even though this causes burning pain), lower abdominal pain, and blood in the urine. The cause is often infection by bacteria from the bowel invading via the urethral opening, but sometimes via the kidneys.

9 Extroverted bladder is a congenitally incomplete bladder, causing urine leakage, and requiring surgery.

10 Some physical and psychological problems can cause lack of bladder control, giving rise to incontinence.

11 An enlarged prostate can lead to urine retention, which in turn can lead to infection. If an enlarged prostate gland blocks the bladder mouth, the bladder wall thickens. Accumulating urine dilates the ureters, and enlarges the space inside the kidneys. This causes the substance of the kidneys to grow

thinner and may be destroyed.

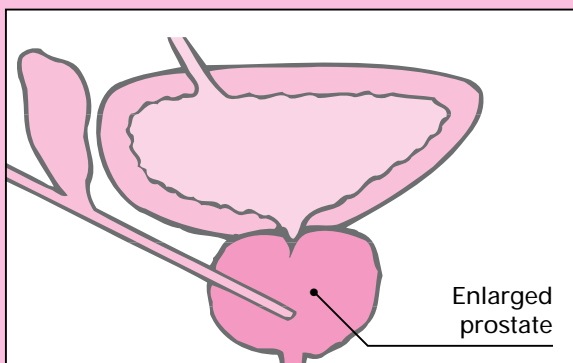
12 Prostatitis is caused by inflammation of the prostate and requires antibiotic treatment. Symptoms include tenderness in the rectum, with fever, harsh pain, and difficulty passing water.

13 Urethritis is inflammation of the urethra. Symptoms may include watery or thick greenish-yellow discharge from the penis, pain or a burning sensation on passing water, and an urgent need to urinate often.

14 Urethral stricture can be caused by infection, especially gonorrhea, or injury.

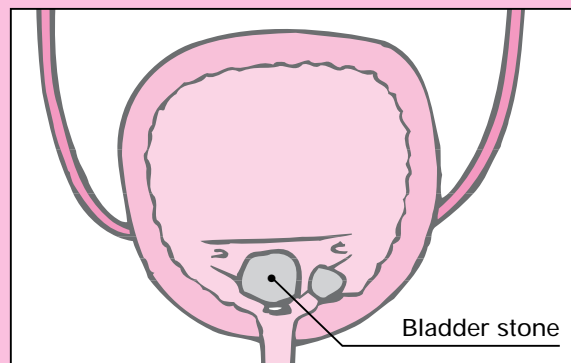
15 Hypospadias and epispadias are conditions where the urethral opening in males is on the top or bottom of the penis shaft rather than in the correct place at the tip of the penis.

16 Diaper rash occurs on skin soaked with urine, especially in babies. Incontinent adults may also suffer skin problems.



Enlarged prostate

The prostate gland in men can become enlarged due to infection, multiplication of cells within the gland, or cancer.



Stones

Stones, or calculi, form from substances precipitated out of urine. They can form in the kidneys, ureters, or bladder.

Adipose tissue Connective tissue containing numerous fat cells.

Adrenal glands (*or* Suprarenal glands) Endocrine glands located on each kidney. The cortex and medulla produce a range of hormones.

Afferent Directed toward a central organ or part of the body.

Alimentary canal (*or* Gastrointestinal tract *or* Gut) The digestive tract: a tube starting at the mouth and ending at the anus.

Anus The lower end of the rectum, forming the outlet of the alimentary canal.

Aorta The largest artery, arising from the left ventricle of the heart.

Appendix (*or* Vermiform appendix) A short, wormlike tube opening into the cecum but closed at the other end. It contains lymphoid tissue, which is involved in immunity.

Arteriole A small artery supplying blood from a main artery to a capillary.

Artery A blood vessel transporting blood from the heart to elsewhere in the body.

Atrioventricular valve (*or* AV valve) A valve between a ventricle and an atrium. The right atrioventricular valve (*or* tricuspid valve) has three cusps. The left atrioventricular

valve (mitral valve or bicuspid valve) has two cusps.

Auditory Relating to hearing.

Axillary Relating to the armpit.

Backbone See **Vertebral column**.

Basal ganglia Paired structures deep in the forebrain: they help coordinate and control willed muscle movements.

Basophil A type of white blood cell that is readily stained by basic dyes.

Biceps A muscle with two heads: biceps brachii in the upper arm and biceps femoris in the thigh.

Bile ducts Tiny tubes that carry bile (a liver secretion) from the liver to the duodenum.

Bladder A sac, especially the muscular bag inside the pelvis where urine collects before being expelled from the body.

Blood A sticky red fluid consisting of colorless plasma, red blood cells (Erythrocytes), white blood cells (Leukocytes), and platelets (thrombocytes).

Blood pressure The pressure of blood against blood-vessel walls, especially artery walls.

Bone The hard, dense connective tissue that forms the skeleton's components.

Bone marrow Soft red and yellow substances that fill cavities in bone.

Bowel See **Large intestine**.

Brain The body's chief control center, consisting of billions of interconnected nerve cells.

Brainstem A stalklike part of the brain, between the cerebrum and spinal cord. It contains the midbrain, pons, and medulla oblongata.

Breast A female breast consists mainly of a mammary (milk-secreting) gland embedded in fatty tissue.

Breastbone See **Sternum**.

Bronchiole A small subdivision of a bronchus, ending in tiny air sacs called alveoli.

Bronchus The main tubes branching from the lower end of the trachea and forming the main airways to and from the lungs (plural: bronchi).

Capillary The tiniest type of blood vessel, connecting an arteriole and a venule.

Cardiac Relating to the heart.

Cardiovascular Relating to the heart and blood circulatory system.

Cartilage Gristle: dense, white connective tissue cushioning bones.

Cecum The first part of the large intestine, forming a blind pouch.

Cell The basic unit of the body, usually comprising an outer membrane, cytoplasm, a nucleus, and organelles.

Central nervous system

(CNS) The brain and spinal cord.

Cerebellum The largest part of the hindbrain. It helps coordinate muscular movements.

Cerebral cortex The cerebrum's thin outer layer of gray matter.

Cerebral hemisphere Either of the two halves of the cerebrum.

Cerebrospinal fluid A clear fluid filling the brain's ventricles and surrounding the brain and spinal cord to protect them from injury.

Cerebrum The upper, major part of the brain, comprising cerebral hemispheres and diencephalon.

Cervix A neck, especially the neck of the uterus (womb) where it opens into the vagina.

Clavicle Either of the two collarbones.

Clitoris An erectile, pea-sized organ above the opening of the vagina; it is highly sensitive and is involved in female sexual response.

CNS See **Central nervous system**.

Coccyx Four fused vertebrae forming the "tail" of the backbone.

Collagen A fibrous protein that is a major constituent of connective tissue.

Colon The part of the large intestine between the cecum and rectum.

Connective tissue Tissue that supports, binds, or separates more specialized body tissues or acts as packing.

Corium See **Dermis**.

Cornea The transparent circular area at the front of the eye, which acts as a lens.

Coronary arteries Supply the heart muscle.

Corpuscles A term often used for red and white blood cells.

Cortex The outer layer of the brain.

Cranial nerves Twelve pairs of nerves linking the underside of the brain with parts of the head, neck, and thorax.

Cranium The part of the skull that contains the brain.

Cutaneous Relating to the skin.

Cuticle See **Epidermis**.

Deoxyribonucleic acid (DNA) A nucleic acid in the cell's chromosomes containing the cell's coded genetic instructions.

Dermis (or **Corium**) The layer of skin below the epidermis, containing nerves, blood vessels, glands, and hair follicles.

Diaphragm A muscular sheet used in breathing. It separates the thorax (chest) and abdomen (belly).

Digestion The chemical and mechanical breakdown of foods into substances that can be absorbed by the body.

DNA See **Deoxyribonucleic acid**.

Duodenum The upper part of the small intestine, where most chemical digestion takes place.

Ejaculation The discharging of semen from the penis.

Endocardium The membrane that lines the heart and the heart valves.

Endothelium The cell layer that lines the inside of the heart, blood vessels, and lymph vessels.

Enzymes Biological catalysts: proteins that speed up chemical reactions without undergoing change themselves.

Epidermis (or **Cuticle**) The skin's outer layer.

Epiglottis A cartilage flap behind the tongue that is closed during swallowing to stop food from entering the larynx.

Epiphysis See **Pineal gland**.

Epithelium The cell layer covering the body, and lining the alimentary canal and respiratory and urinary tracts.

Erythrocytes Red blood cells.

Esophagus (or **Gullet**) The muscular tube through which food travels between the pharynx and the stomach.

Fallopian tubes (or Uterine tubes or Oviducts) The tubes through which ova (eggs) travel from the ovaries to the uterus.

Femur The thigh bone: the long bone between the hip and the knee.

Follicle A small secreting cavity or sac. Ova (egg cells) develop in follicles in the female ovaries.

Forebrain The front part of the brain comprising diencephalon and telencephalon.

Gallbladder A pear-shaped bag where bile is stored, below the liver.

Gametes Sex cells: sperm in males; ova in females.

Gastric Of the stomach.

Gastrointestinal tract See **Alimentary canal**.

Genes Basic biological hereditary units, consisting of DNA, located on chromosomes.

Genitalia Sex organs.

Gland A structure that synthesizes and secretes a fluid.

Gonads Primary reproductive organs: the ovaries and testes.

Granulocytes White blood cells with cytoplasm that contains granules: basophils, eosinophils, and monocytes.

Gray matter The darker tissue of the brain and spinal cord mainly consisting of neurons' cell bodies and dendrites.

Gullet See **Esophagus**.

Gut See **Alimentary canal**.

Heart The hollow, muscular, fist-sized organ that pumps blood around the body.

Hemoglobin The iron-rich, oxygen-transporting pigment in red blood cells that gives them their color.

Hepatic Relating to the liver.

Hepatic portal vein See **Portal vein**.

Hindbrain Brain structures below the midbrain, comprising the pons, medulla oblongata, and cerebellum.

Hormones Chemical substances released into the blood by endocrine glands to influence organs or tissues in other parts of the body.

Hypophysis See **Pituitary gland**.

Hypothalamus A part of the brain with endocrine functions.

Ileum The last part of the small intestine.

Immune system The body's defense system against infective organisms or other foreign bodies. It includes the lymphatic system.

Involuntary muscle Muscle that is not under conscious control. See also **Smooth muscle**.

Jejunum The middle part of the small intestine.

Joint The junction between bones.

Karyotype The chromosome complement of a person or species: the genome.

Kidney A bean-shaped organ that filters wastes from blood to form urine.

Lactation Milk production by the mammary glands.

Large intestine (or Bowel) The lower part of the alimentary canal, comprising the cecum, colon, and rectum.

Larynx The cartilaginous voice box.

Leukocytes White blood cells. They attack invading microorganisms and help to combat injuries.

Ligament Fibrous tissue that connects bones.

Liver The largest organ in the body, it is involved in various metabolic processes.

Lungs The two organs of respiration, filling most of the chest cavity inside the rib cage and above the diaphragm.

Lymph A transparent fluid that leaks from blood vessels into tissue spaces.

Lymph gland See **Lymph node**.

Lymph node (or Lymph gland) One of the "knots" in the lymphatic system, which contain lymphocytes and macrophages that filter the lymph passing through the nodes.

Lymphatic system A network of lymph vessels and lymph nodes. Vessels collect lymph from body tissues and return it to the blood after harmful substances have been filtered out in the lymph nodes.

Mammary glands The milk-producing structures in the breast.

Medulla oblongata The lowest part of the brain stem, containing the vital centers that control heartbeat and respiration.

Meiosis A type of cell division that produces daughter cells (sperm and ova) each with half as many chromosomes as the parent cell.

Meninges Three protective membranes surrounding the brain and spinal cord.

Menopause When a woman ceases to have menstrual periods.

Menstruation Menstrual periods: the monthly flow of blood and uterine lining from the vagina of nonpregnant females of childbearing age.

Metabolism The array of continuous chemical changes that maintain life in the body.

Mitosis Ordinary cell division in which both daughter cells have as many chromosomes as the parent cell.

Mucous membranes The mucus-secreting linings of the

digestive, respiratory, reproductive, and urinary tracts.

Nasal Relating to the nose.

Nasal cavity The space inside the nose between the base of the skull and the roof of the mouth.

Nerve A bundle of nerve fibers (axons) that transmit impulses to (in the case of sensory nerves) or from (in the case of motor nerves) the central nervous system.

Nervous system The coordinated networks of neurons that control the body. It is divided into the central nervous system (brain and spinal cord), and the peripheral nervous system (the somatic and autonomic nervous systems).

Neuron (*or* Neurone) A nerve cell: the basic unit of the nervous system.

Neurone *See* **Neuron**.

Neurotransmitter A chemical released at nerve endings to transmit nerve impulses across synapses.

Nucleic acids Molecules that store genetic information.

Nucleus The control center of a cell, which contains coded genetic instructions.

Olfactory Relating to smell.

Optic Relating to the eye.

Organ A body part with different types of tissue that performs a particular task.

Organelles Tiny structures (miniorgans) in a cell's cytoplasm with particular tasks.

Ovaries Female sex organs that produce ova (eggs) and sex hormones.

Oviducts *See* **Fallopian tubes**.

Ovulation The release of a ripe egg from a female's ovary.

Ovum An egg; a female sex cell (plural: ova).

Palate The roof of the mouth.

Pancreas An abdominal organ that produces pancreatic juice and the hormones glucagon and insulin.

Parasympathetic nervous system The part of the autonomic nervous system that predominates when the body is at rest.

Parathyroid glands Four pea-sized endocrine glands on the thyroid gland. They produce parathyroid hormone, which controls blood calcium level.

Pelvis A bony basin formed by the two hip bones, the sacrum, and the coccyx.

Pericardium The double-layered membrane that encloses the heart and attaches it to the diaphragm and sternum.

Peristalsis Waves of muscular contraction that propel substances through passageways, such as the alimentary canal.

Phagocytes Types of leukocytes that engulf and destroy microorganisms and foreign bodies.

Pharynx The throat.

Pineal gland (or Epiphysis) An endocrine gland in the brain that secretes melatonin.

Pituitary gland (or Hypophysis) A three-lobed, pea-sized gland below the hypothalamus. It produces growth hormone, hormones that act on other endocrine glands, oxytocin, and ADH. It is often called the body's "master gland."

Plasma The fluid part of blood.

Pleura The membrane that covers the lungs (visceral pleura) and lines the chest wall (parietal pleura).

Plexus A network of nerves (or blood or lymph vessels).

Portal vein (or Hepatic portal vein) Drains blood from digestive organs to the liver.

Prostate gland A gland situated below the bladder in males. It produces a sperm-activating fluid that forms nearly a third of the semen's volume.

Pudendum See **Vulva**.

Pulmonary Relating to the lungs.

Receptor A structure, such as a sensory nerve ending, specialized to detect environmental stimuli.

Rectum The last part of the colon, where feces collects before leaving the body.

Reflex action The body's automatic response to a stimulus, such as blinking.

Renal Relating to the kidney.

Respiration 1) Breathing; 2) Taking in oxygen and giving out carbon dioxide; 3) Deriving energy from food with or without using oxygen.

Respiratory system In humans, the mouth, nose, pharynx, larynx, trachea, bronchi, bronchioles, alveoli, and lungs.

Ribonucleic acid (RNA) A nucleic acid concerned with protein synthesis.

Ribs Twelve pairs of bones that protect the chest cavity and assist breathing by moving up and out during inspiration and down and in during expiration.

Salivary glands The lingual, parotid, sublingual, and submandibular glands that produce saliva.

Serum Blood plasma that does not contain clotting factors but does contain antibodies.

Sinus A cavity, such as the channels draining venous blood from the brain.

Skeleton The bony framework that protects and supports the body's soft tissues.

Skin The body's waterproof covering; its largest organ, comprising two main layers: the epidermis and dermis.

Small intestine The alimentary canal between the stomach and large intestine, comprising the duodenum, jejunum, and ileum. Most digestion occurs here.

Smooth muscle (or Unstriated muscle or Involuntary muscle) Muscle without striped fibers that automatically operates internal organs such as the stomach, bladder, and blood vessels.

Sphincter A ring-shaped muscle that contracts to close an orifice.

Spinal cord The cable of nerve tissue running down inside the vertebral column (spine) and linking the brain with nerves supplying most of the body.

Spine See **Vertebral column**.

Sternum The breastbone.

Subcutaneous tissue The sheet of connective tissue below the dermis.

Suprarenal glands See **Adrenal glands**.

Suture An immovable fibrous joint between the skull bones.

Taste buds Tiny sensory organs of the tongue and palate, distinguishing salty, sweet, sour, and bitter tastes.

Teeth Bonelike structures in the jaws. Different types (incisors, canines, premolars, molars) are specialized to tear, crush, and/or grind food.

Tendons Bands of fibrous connective tissue joining muscles to bones.

Testis (*or* Testicle) One of a pair of primary male sex organs that manufacture sperm (plural: testes).

Thalamus A brain structure above the hypothalamus. It sends sensory impulses to the cerebral cortex, links sensations with emotions, and affects consciousness.

Thymus An endocrine gland located behind the sternum. It produces thymosin.

Thyroid An endocrine gland at the front of the neck, producing thyroid hormone.

Tissue A collection of similar cells that perform a particular task.

Trachea (*or* Windpipe) The tube between the larynx and the bronchi.

Tubule A tiny tube.

Tunica A tissue layer forming a coating. Blood vessels have three such layers (intima, media, adventitia).

Unstriated muscle *See* **Smooth muscle**.

Ureter The tube conveying urine from a kidney to the bladder.

Urethra The passage taking urine from the bladder to the body's exterior.

Urinary system The kidneys, ureters, bladder, and urethra.

Urine Liquid waste excreted by the kidneys.

Uterine tubes *See* **Fallopian tubes**.

Uterus (*or* Womb) A hollow muscular organ located above the bladder. Inside it, a fertilized ovum develops into a fetus.

Uvula A conical tag hanging from the back of the palate. It helps to keep food out of the nasal cavities.

Vagina The muscular passage between the vulva and cervix (neck of the uterus).

Vascular Relating to or richly supplied with vessels, especially blood vessels.

Vein A blood vessel that transports blood from capillaries back to the heart. Veins contain valves to prevent the backflow of blood.

Venous Relating to veins.

Ventricle A cavity: one of the two lower chambers of the heart.

Venule A small vein.

Vermiform appendix *See* **Appendix**.

Vertebra A bone of the vertebral column (plural: vertebrae).

Vertebral column (*or* Backbone *or* Spine) The column of vertebrae between the skull and the hip bones, supporting the body and shielding the spinal cord. It has five sections: cervical, thoracic, lumbar, sacral, and coccygeal.

Vestibule A space before a passage begins, as in the inner ear beyond the oval window, between the semicircular ducts and cochlea.

Vocal cords Two belts of tissue stretched across the larynx which produce sounds when air rushes past them.

Vulva (*or* Pudendum) The external female genitals.

White matter The paler tissue of the brain and spinal cord comprised mainly of myelin-sheathed nerve fibers.

Windpipe *See* **Trachea**.

Womb *See* **Uterus**.

There is a lot of useful information on the internet. There are also many sites that are fun to use. Remember that you may be able to get information on a particular topic by using a search engine such as Google (<http://www.google.com>). Some of the sites that are found in this way may be very useful, others not. Below is a selection of Web sites related to the material covered by this book. Most are illustrated, and they are mainly of the type that provides useful facts.

Facts On File, Inc. *takes no responsibility for the information contained within these Web sites. All the sites were accessible in January 2005.*

Anatomy of the Human Body: Gray's Anatomy

Online version of the classic *Gray's Anatomy of the Human Body*, containing over 13,000 entries and over 1,200 images.
<http://www.bartleby.com/107/>

Biology Online

A source for biological information, suitable for homework, research projects, and general interest, with hundreds of biology Web site links.

<http://www.biology-online.org>

BIOME

A guide to selected, quality-checked internet resources in the health and life sciences.

<http://biome.ac.uk>

Health Sciences & Human Services Library

Provides links to selected Web sites that may be useful to both students and researchers.

<http://www.hshsl.umaryland.edu/resources/lifesciences.html>

Human Anatomy Online

Interactive resource, with visual keys to text on the human body

<http://www.innerbody.com>

North Harris College Biology Department

Tutorials and graphics on biology, human anatomy, human physiology, microbiology, and nutrition.

<http://science.nhmccd.edu/biol/>

Open Directory Project: Digestive Disorders

Comprehensive list of internet resources.

http://dmoz.org/Health/Conditions_and_Diseases/Digestive_Disorders/

Open Directory Project: Gastroenterology

Comprehensive list of internet resources.

http://dmoz.org/Health/Medicine/Medical_Specialties/Gastroenterology/

The Biology Project

Structured tutorials on life sciences.

Particularly strong on cell biology, human biology, and molecular biology.

<http://www.biology.arizona.edu>

University of Texas: BioTech Life Sciences Resources and Reference Tools

Enriching knowledge of biology and chemistry, for everyone from high school students to professional researchers. The Dictionary and Science Resources are particularly useful.

<http://biotech.icmb.utexas.edu>

- A**
abdomen
 large intestine 66
 liver 6, 74
 membranes 65
 organs 11
 pancreas 74
 urinary system 20
absorption 8, 12, 14, 16, 50, 51
 large intestine 15, 66
 mucosa 19
 small intestine 15, 59, 60, 62–63
acid 8, 9, 17, 57
alcohol 25
 calories 24
 intestinal disorders 71, 72
 liver disorders 86
 nutrition 31
 pancreas disorders 88
 stomach 54
 vomiting 49
alimentary canal 6, 8–9, 17
allergy 33
amino acids 22, 23
 pancreas 85
 small intestine 61, 63
 stomach 57
amylase 42, 43, 85
anemia 31, 71
anorexia nervosa 27
anus 8, 12, 50, 51, 64, 65, 68
 alimentary canal 6, 7
 defecation 69
 intestinal disorders 70
 large intestine 66
 worms 73
appendicitis 32, 64, 71
appendix 6, 7, 10, 51, 58, 64
 autonomic nervous control 17
B
bacteria 8
 defecation 69
 dental hygiene 40, 41
 digestion 12, 14
 intestinal disorders 72, 73
 large intestine 66
 liver disorders 87
 mouth disorders 48
 saliva 43
 stomach juices 57
 urinary tract disorders 101
beriberi 31
bile 6, 9, 10, 14, 74, 78, 80–81, 86
 defecation 69
 digestion 12, 15
 pancreas 74
 small intestine 61
bile duct 6, 78, 79, 80, 81
bile salts 61, 62
bladder 20, 90, 91, 98
 urethra 99
 urinary tract disorders 101
 urine 96
blood
 absorption 8, 12, 14
 liver 78
 mucosa 19
 nephron 94, 95
 small intestine 59
 urinary system 20, 21, 90, 93
blood sugar 82, 83, 88
bolus 8, 9
 ingestion 12
 peristalsis 16
 stomach 51
 swallowing 46, 47
 tongue 37
Bowman's capsule 20, 91, 94, 95
C
calories 24, 28
carbohydrates 6, 22, 23
 calories 24
 malnutrition 30
 pancreas 74
 saliva 34, 42, 43
 small intestine 60
cecum 6, 7, 10, 64, 65, 66
cheeks 35, 36
chewing (mastication) 14
 mouth 8, 12, 15, 35
 teeth 9, 12, 39
 tongue 9, 10, 12, 34, 36, 37
 swallowing 46, 47
cholesterol 80, 88
chyme 6, 54, 55, 56
 ingestion 12
 pancreas 84, 85
 small intestine 58, 60, 61
cirrhosis 86, 87
colon 6, 7, 10
 ascending 6, 10, 11, 64, 66, 67
 descending 6, 10, 11, 64, 65, 66
 irritable 71
 membranes 65
 sigmoid 6, 10, 66, 68
 transverse 6, 10, 11, 50, 64, 65, 66
constipation 25, 27, 31, 32, 33, 70, 71
Crohn's disease (ileitis) 71
cystitis 101

D

defecation 14, 15, 69
 dental hygiene 40–41, 48
 dentine 38, 41
 diabetes 24, 26, 88, 89,, 100
 diaphragm 45, 49, 50, 73
 diarrhea 32, 33, 70, 71
 diet 22–33, 70, 72
 digestive disorders 32–33
 diverticulitis 70, 71
 duodenum 7, 8, 10, 50, 58
 bile duct 81
 liver and pancreas 75
 membranes 65
 sphincters 6
 ulcer 72
 dyspepsia (indigestion) 30, 32, 33

E

emaciation 27
 enamel 27, 38, 41
 endocrine glands 6, 82, 91
 enzymes 6, 9, 14, 19, 22, 23
 digestion 12, 15
 pancreas 74, 84, 85, 88
 saliva 34, 42
 small intestine 60, 61
 stomach 54, 57
 epiglottis 34, 36, 47, 49
 esophagus (gullet) 6, 8, 34–49, 51
 alimentary canal 6
 digestion processes 14, 15, 16
 disorders 32, 48, 73
 ingestion 12, 13
 structure & function 44–45
 swallowing 46, 47

F

fat digestion 9
 bile 14, 80
 liver 74
 pancreas 74, 85
 small intestine 60, 61
 stomach 57
 fats (lipids) 22, 23, 24, 30, 62
 fatty acids 23, 61, 62, 83, 85
 feces 8, 10, 12, 50, 51
 bile 80
 digestive disorders 33
 elimination 14, 69
 large intestine 66
 fiber 23, 24, 25, 31, 70
 food poisoning 33

G

gallbladder 6, 7, 9, 10, 76, 78, 80–81
 digestion 12
 disorders 88–89
 liver and pancreas 74, 75
 overweight effects 26
 small intestine 61
 gallstones 31, 88, 89
 gastric juice 8, 12, 15, 53, 54, 56–57
 gastroenteritis 32, 33
 glomerulus 20, 91, 94, 95, 96, 100
 glucagon 10, 74, 83
 glucose 6, 22
 liver 78
 pancreas 83, 88
 small intestine 61, 63
 urine 96
 glycogen 6, 22, 78, 82, 83

H

halitosis (bad breath) 27, 48

heart disease 22, 26
 heartburn 17, 72
 hemorrhoids (piles) 70, 71
 hepatic vessels 77, 78, 79
 hepatitis 86, 87
 hernias 32, 33, 70, 73
 hormones 19, 23
 anorexia 27
 pancreas 74, 82, 83, 84
 stomach 55, 56, 57
 urinary system 21, 90, 91
 hypertension (high blood pressure) 26, 30

I

ileum 6, 7, 8, 10, 58
 incontinence 99, 101
 insulin 6, 9, 10, 74, 82, 83
 pancreas disorders 88
 islets of Langerhans 10, 82, 83

J

jaundice 86, 87
 jejunum 6, 7, 8, 10, 58

K

kidneys 92–93
 nephrons 94, 95
 nutrition 31, 51
 problems 100
 urinary system 20–21, 90, 91

L

large intestine 6, 8, 10, 50, 51, 64, 66–67
 defecation 69
 digestion 12, 13, 15, 16
 membranes 65
 rectum 68
 larynx (voice box) 34, 46, 47, 49

lipase 57, 61, 85
 liver 6, 7, 9, 11, 50,
 74–89
 bile 80, 81
 digestion 12
 disorders 86–87
 function 78
 glycogen 22
 lobes 76
 lobules 78, 79
 mesentery 77
 nutrition 31, 51
 overweight effects 26
 position 75, 76
 small intestine 60, 61
 lymph vessels 8, 12, 14
 18, 19, 59

M

malnutrition 22, 30–31
 maltase 61
 mesentery 19, 50, 65
 large intestine 66
 liver 77
 small intestine 59
 minerals 22, 23, 25
 convalescence 30
 large intestine 66
 liver 78
 mouth (oral cavity) 8,
 34–49
 alimentary canal 6, 8
 digestion processes 15
 disorders 48
 ingestion 12, 13, 14
 palate 10
 swallowing 46
 vomiting 49
 worms 73
 mucous membranes 36,
 42, 44, 53
 mucus 18, 19, 43
 defecation 69

digestive disorders 33
 esophagus 44
 large intestine 66
 stomach 53, 54, 57
 muscles
 alimentary canal 18
 appendix 64
 bladder 98
 esophagus 44
 intestinal disorders 70
 large intestine 67
 mouth 36
 peristalsis 16
 small intestine 60
 sphincters 17
 stomach 52
 tongue 37

N

nephrons 20, 91, 92, 94–95,
 96
 urinary tract disorders
 100
 nutrients 22–33
 absorption 8, 50, 59
 liver 9, 51, 78
 urine 96

O

obesity 22, 24, 25, 26
 hypertension 30
 kidneys 31
 weight loss 28

P

palate 10, 34, 35, 44
 swallowing 46
 tongue 37
 vomiting 49
 pancreas 6, 7, 9, 10, 50,
 82–85
 digestion 12
 disorders 88–89

enzymes 60
 position 74, 75
 small intestine 15, 61
 parasitic worms 72, 73
 peptidase 61, 85
 pepsin 57
 peristalsis 6, 10, 14, 15,
 16, 34, 96
 esophagus 44, 47
 gut 19
 ingestion 12
 pharynx 44
 small intestine 60
 stomach 54, 55
 peritoneum 50, 65, 67, 73
 peritonitis 33, 71, 73
 pharynx (throat) 6, 8, 10,
 34, 36, 44
 digestion 15, 16
 ingestion 12, 13
 swallowing 46, 47
 tongue 37
 portal vein 66, 78, 79
 prostate gland 99, 101
 proteins 22, 23
 absorption 62, 63
 calories 24
 convalescence 30
 digestion 8, 54, 60, 61,
 74, 85
 malnutrition 30
 pyloric sphincter 6, 10, 17,
 51
 small intestine 58, 60
 stomach 54, 55
 intestinal disorders 72,
 73

R

rectum 10, 11, 13, 51, 68
 alimentary canal 6, 7
 feces 12, 50, 69
 intestinal disorders 70

renal tubule 91, 92, 94,, 95, 96
 renal vessels 20, 91, 92, 93, 95
 rennin 57
 rickets 31

S

saliva 9, 10, 12, 34, 42–43
 mouth 8, 15
 swallowing 46
 tongue 36, 37
 salivary glands 9, 10, 34, 42–43
 digestive organs 6, 7
 infections 48
 ingestion 12
 salt
 absorption 8, 54, 66
 nutrition 30, 31
 urinary system 90, 95
 scurvy 31
 small intestine 8, 10, 11, 50, 58–59
 alimentary canal 6, 7
 bile 78
 digestion 12, 13, 15, 16
 disorders 71, 73
 function 60–61
 liver 74, 75
 membranes 65
 pancreas 74, 75, 84, 85
 pyloric sphincter 51
 stomach 55, 56
 smooth muscle 52
 sphincters 6, 10, 17, 18, 19
 anus 68

bile duct 81
 bladder 98
 defecation 69
 disorders 72, 73
 esophagus 44, 45, 47
 stomach 51, 52
 urinary system 20, 96
 vomiting 49
 starch 9, 23
 stomach 8, 10, 50, 51, 52–53
 alimentary canal 6, 7
 disorders 33, 71, 72, 73
 function 15, 16, 54–55
 ingestion 12, 13
 vomiting 49
 stress 26, 27, 72
 strokes 26
 sugar 9, 23, 24, 40, 61
 swallowing (deglutition) 9, 10, 14, 34, 46–47
 mouth 6, 12
 pharynx 12, 16, 44
 saliva 12, 43
 tongue 12, 36, 37

T

taste 10, 12, 34, 36, 37, 43
 teeth 9, 34, 35, 36, 38–39
 chewing 12, 34, 46
 dental hygiene 40, 41
 digestive organs 6, 7
 malnutrition 31
 tongue 6, 9, 35, 36, 37
 chewing 12, 34, 46
 malnutrition 31

tonsils 34, 35, 36, 37
 trypsin 61, 85

U

ulcers 72
 ureters 20, 90, 91, 92, 96
 bladder 98
 urinary disorders 100
 urethra 20, 90, 91, 96, 99
 bladder 98
 urinary disorders 101
 urinary system 20–21, 90–101
 disorders 100–101
 urination (micturition) 20, 21, 96, 99
 urine 96–97, 98, 99
 urinary system 20, 21, 90, 91, 95
 uvula 34, 35

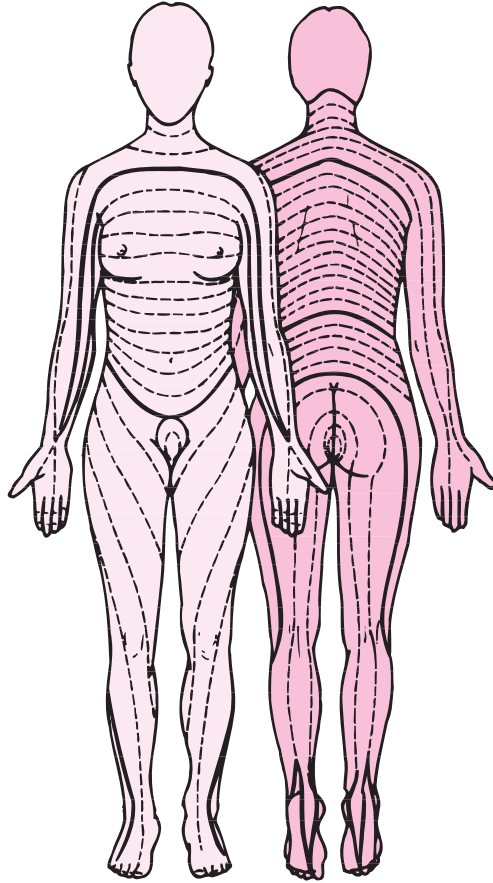
V

villus 10, 59, 60
 vitamins 6, 22, 23, 25
 liver 78
 malnutrition 31
 small intestine 62
 urinary system 90
 vomiting 32, 33, 49, 73, 89

W

water 22, 23
 absorption 8, 10, 12, 54, 62, 66
 balance 20, 21, 90, 95
 urine 96, 97
 worms 73

THE FACTS ON FILE
ILLUSTRATED GUIDE TO
THE HUMAN BODY
THE SENSES



THE DIAGRAM GROUP

The Facts On File Illustrated Guide to the Human Body: The Senses

Copyright © 2005 The Diagram Group

Editorial: Lionel Bender, David Harding, Denis Kennedy,
Gordon Lee, Steve Parker, Jamie Stokes

Scientific consultant: Stephen Rudd

Design: Anthony Atherton, Richard Hummerstone,
Lee Lawrence, Kim Richardson, Ben White

Illustration: Pavel Kostal, Kathleen McDougall

Picture research: Neil McKenna

Indexer: Jane Parker

All rights reserved. No part of this book may be reproduced or utilized in any form or by any means, electronic or mechanical, including photocopying, recording, or by any information storage or retrieval systems, without permission in writing from the publisher. For information contact:

Facts On File, Inc.
132 West 31st Street
New York NY 10001

Library of Congress Cataloging-in-Publication Data

The Facts on File illustrated guide to the human body. The senses / the Diagram Group.

p. cm.

Includes index.

ISBN 0-8160-5987-X

1. Senses and sensation—Juvenile literature. I. Title: Illustrated guide to the human body. The senses. II. Title: Senses. III. Diagram Group.

QP434.F32 2005

612.8—dc22

2004026428

Set ISBN: 0-8160-5979-9

Facts On File books are available at special discounts when purchased in bulk quantities for businesses, associations, institutions, or sales promotions. Please call our Special Sales Department in New York at 212/967-8800 or 800/322-8755.

You can find Facts On File on the World Wide Web at <http://www.factsonfile.com>

Printed in the United States of America

EB Diagram 10 9 8 7 6 5 4 3 2 1

This book is printed on acid-free paper.

Note to the reader

This book is not intended to serve as a medical textbook for either physicians or patients. The information and advice it contains should not be used or relied upon without consulting the advice of a qualified physician. The publishers disclaim any responsibility for the accuracy of the information or advice that this book contains and any responsibility for any consequences that may result from any use or reliance thereon by the reader.

Contents

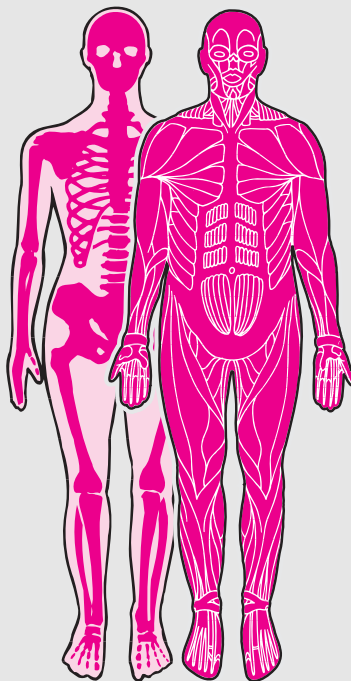
Introduction: About this book	4		
SECTION 1			
SENSORY SYSTEMS			
Introduction	6	Ear problems	56
Senses key words	8	Ear problems and ear care	58
Senses and the nervous system	10	Vestibular apparatus and balance	60
Senses and the brain	12	Mechanism of balance	62
Sensory pathways	14	 	
Receptors and sensations	16	SECTION 4	
Senses and reflexes	18	SMELL AND TASTE	
 		Introduction	64
SECTION 2		Nose and nasal chamber	66
EYES AND VISION		Olfactory areas	68
Introduction	20	Smell perception	70
Around the eye	22	Mouth and oral chamber	72
Eye muscles and movements	24	Tongue and taste buds	74
Cornea, pupil, and lens	26	Taste perception	76
Front of the eye	28	Smell and taste disorders	78
The retina	30	 	
Nerve pathways for vision	32	SECTION 5	
Eye care	34	SKIN AND TOUCH	
Eye tests and corrective aids	36	Introduction	80
Eye problems 1	38	Epidermis	82
Eye problems 2	40	Dermis	84
Defects of vision	42	Touch sensors	86
 		Nonsensory skin functions	88
SECTION 3		Hair	90
EARS AND HEARING		Nails	92
Introduction	44	General skin disorders 1	94
Outer, middle, and inner ear	46	General skin disorders 2	96
Middle ear	48	Facial skin disorders	98
Inner ear	50	Hair and nail disorders	100
Stages in hearing 1	52	 	
Stages in hearing 2	54	Glossary of the human body	102
		Web sites to visit	108
		Index	109

This book is a concise, illustrated guide to the anatomy, physiology, well-being, and disorders of the human senses. It has been written and illustrated specially for students and laypeople interested in medicine, health, fitness, and first aid. The subject is dealt with in clear steps, so that the reader can steadily acquire a good overall understanding. Explanatory texts, diagrams, illustrations, captions, and fact boxes are combined to help readers grasp important information at a glance. A glossary of scientific and jargon words defines medical terms in everyday language. A list of Web sites provides links to other relevant sources of information, and the index enables quick access to articles.

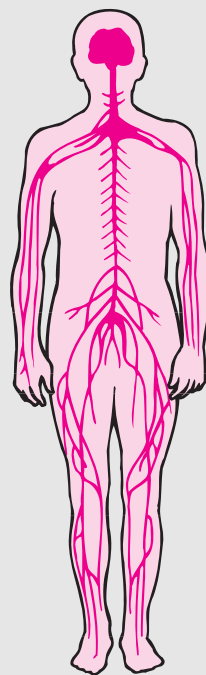
There are five sections within the book. The first section surveys the sensory system and outlines how sensory cells respond to stimuli, or changes, and pass signals to the brain for interpretation. Sections 2, 3, and 4 focus on the major sense organs—eyes, ears, nose, and tongue—and the senses they provide—vision, hearing, balance, smell, and taste. Section 5 deals with the skin: both the senses of touch, temperature, and pain, and its nonsensory structures and functions. Within each section, normal structure and function are followed by principles of healthcare and hygiene. These are followed by a survey of the main disorders and diseases affecting the region. Information is presented as double-page topics arranged in subsections.

Human body systems

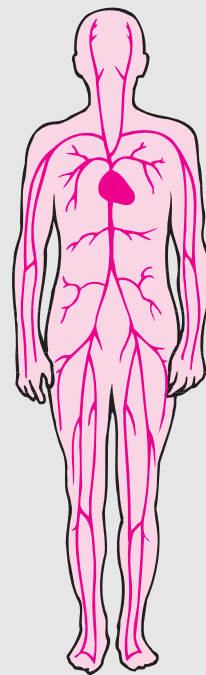
This book is one of eight titles in THE FACTS ON FILE ILLUSTRATED GUIDE TO THE HUMAN BODY series, which looks at each of the major body systems in turn. Some of the titles in the series include more than one system. The skeletal and muscular systems, and the blood and lymphatic systems, for example, work in conjunction and so are treated together. There is a separate title for human cells and genetics, which are the building blocks and underlying chemistry of all body systems.



**Skeletal and
Muscular Systems**



**Brain and
Nervous System**



**Heart and
Circulatory System**

Section 1: SENSORY SYSTEMS looks at the principles of sensory stimulation, how sensory signals are transmitted to the brain, and how reflex actions work.

Section 2: EYES AND VISION investigates how light enters the eyes, stimulates sensory cells in the retina, and how visual messages are interpreted.

Section 3: EARS AND HEARING focuses on how sounds are transmitted to the inner ear and how the sense of hearing works. It also describes the sense of balance.

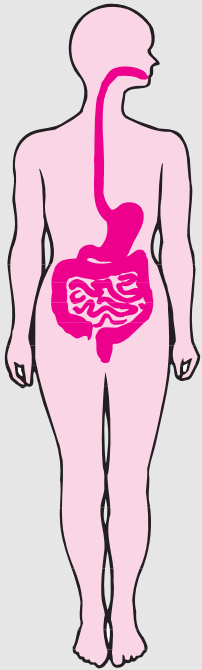
Section 4: SMELL AND TASTE features the nose and tongue, and the senses stimulated by chemical messages.

Section 5: SKIN AND TOUCH looks at how special cells in the skin provide additional


senses. It also describes the skin in relation to the control of body temperature, and the structure and function of hair and nails.

This book has been written by anatomy, physiology, and health experts for non-specialists. It can be used:

- as a general guide to the way the human body functions
- as a reference resource of images and text for use in schools, libraries, or in the home
- as a basis for examination preparation for students of human biology, medicine, nursing, physiotherapy, and general hygiene and healthcare.



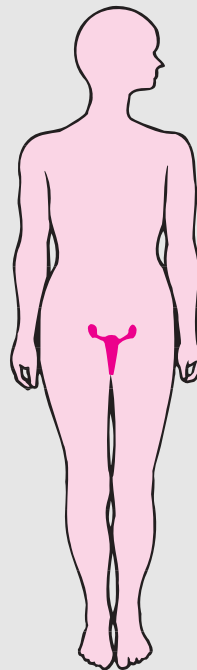
Digestive System



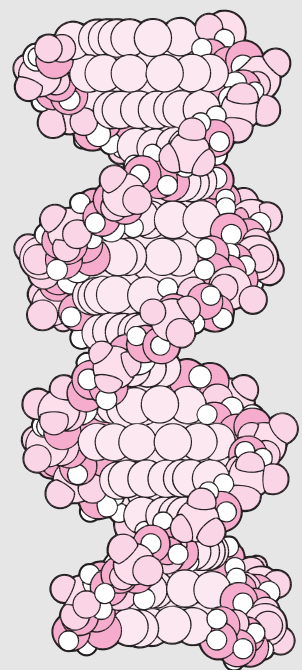
The Senses



Respiratory System



Reproductive System



Cells and Genetics

We know about the outside world and our surroundings through our senses. The body parts receiving the information are known as sensory receptors—nerve endings specialized to register specific stimuli. The stimuli include light rays, sound waves, substances in foods and drinks, and various types of physical contact. They are detected by exteroceptors, concentrated in the eyes, ears, nose, tongue, and skin. The body monitors its “inside world” too—changes such as the movements of joints or a rise in body temperature—through internal senses, known as proprioceptors and interoceptors.

The five main senses encompass seven sensory parts or exteroceptor organs.

Skin

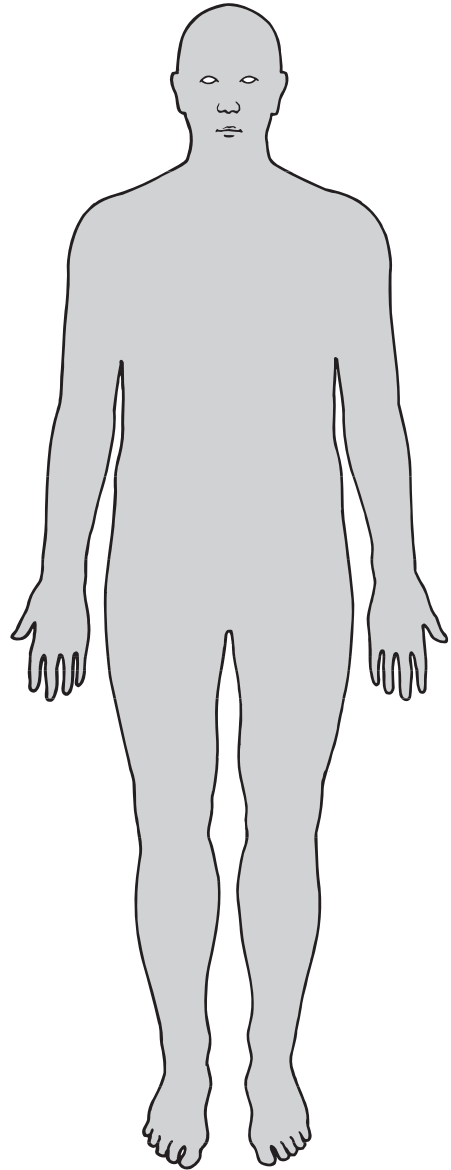
This body covering has a thin outer layer (epidermis) and a thicker, deeper layer (dermis or corium) overlying subcutaneous fat. Skin contains mechanoreceptors sensitive to various kinds of touch, including light contact, steady pressure, and vibrations, and also thermoreceptors sensitive to temperature. Nails, hairs, sweat glands, and sebaceous glands are appendages of the skin.

Eyes

Each eyeball is positioned in an orbit (eye socket) at the front of the skull. Light rays enter the eye through the cornea (a transparent area at the front of the sclera), which carries out the main focusing, or bringing together of the light rays to form an image. The rays then pass through the eye's anterior chamber and the pupil (central

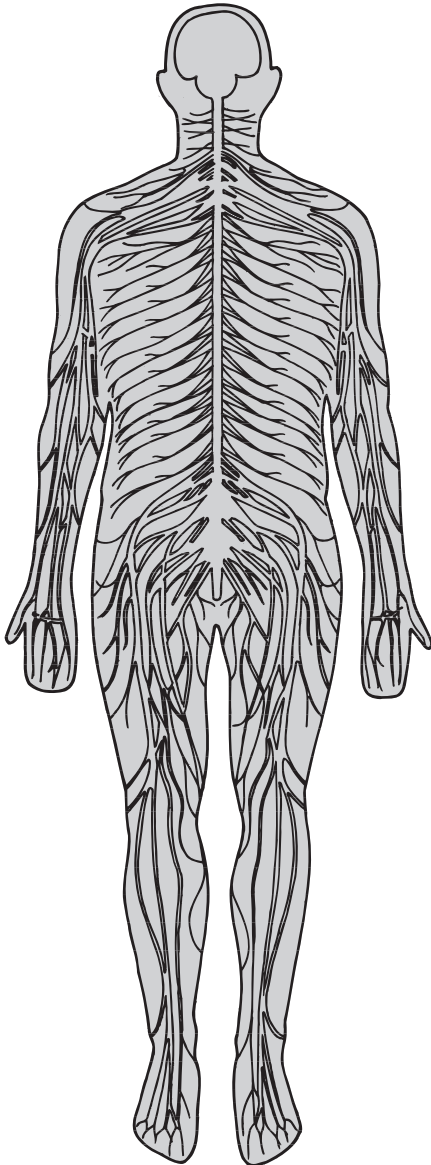
Skin—the largest organ

The body's outer covering is by far the largest sensory organ. In fact it is the biggest of all organs, with an average area of 20 square feet (1.8 m²).



Senses and nerves

The sense organs can be regarded as appendages of the nervous system, which conducts their nerve impulses to the spinal cord and brain.



opening in the iris) before being further adjusted and fine-focused by the lens (sometimes called the crystalline lens). Focused rays produce an image on the retina at the back of the eye, where they are converted into electrical impulses by photoreceptor cells (rods and cones). Impulses are then transmitted via the optic nerve to the cortex at the rear of the brain's cerebral hemispheres to be processed.

Nose

Chemoreceptors in two olfactory membranes—one in the upper part or roof of each nasal cavity—register scent molecules. These trigger nerve signals sent to olfactory bulbs linked with the brain's limbic system.

Tongue

Chemoreceptors sited on papillae on the tongue (and also on the palate, throat, and nostrils) register combinations of tastes, probably in a similar way to the detection of smells. Nerves transmit these taste signals to the brain's thalamus and cerebral cortex.

Ears

Sound waves reaching an ear pass from its fleshy auricle, or outer ear flap, through the external auditory canal (ear canal) to the middle ear. The waves vibrate in sequence the tympanic membrane (eardrum) and tiny ear bones known as ossicles (malleus, incus, and stapes). These bones agitate fluid in the inner ear where the oscillating basilar membrane vibrates the spiral-shaped organ of Corti. From there, nerve impulses go to the cortex of the temporal lobes on the sides of the brain. The inner ear's vestibular system (featuring semicircular ducts, saccule, and utricle) registers the head's position and so helps to control balance and posture.

Key terms relating to the senses

Acoustic Relating to sound or hearing.

Afferent Directed toward a central organ or part of the body. The afferent (or sensory) nerves of the peripheral nervous system send impulses to the central nervous system.

Auditory Relating to hearing.

Auditory tube See Eustachian tube.

Auricle The external ear flap or pinna.

Blind spot See Optic disk.

Brain The body's chief control center, containing billions of interconnected nerve cells. It receives, collects, processes, and stores information, and controls the body's responses.

Central nervous system (CNS) The brain and spinal cord.

Choroid The eyeball's dark middle layer.

Cochlea Part of the inner ear concerned with hearing: a canal coiled like a snail's shell and linked to the auditory nerve.

Cones Photoreceptor cells in the retina that distinguish colors and fine detail, and work best in bright light.

Cornea The transparent domed area at the front of the eye, which partly focuses light.

Cranial nerves Twelve pairs of nerves linking the underside of the brain with parts of the head, neck, and thorax. Some feed sensory nerve messages from the eyes, nose, and ears to the brain.

Cutaneous Relating to the skin.

Cuticle The epidermis. Also the strip of thickened skin at the base of a nail.

Dermatome The area of skin supplied by an individual spinal nerve.

Dermis (or Corium) The layer of skin below the epidermis, containing nerves, blood vessels, glands, and hair follicles.

Ear The organ of hearing and balance.

Eardrum See Tympanic membrane.

Efferent Directed away from a central organ or part of the body. Efferent (or motor) nerve fibers carry signals away from the central nervous system.

Epidermis (or Cuticle) The skin's outer layer.

Eustachian tube (or Auditory tube) A tube between the middle ear and the throat. It helps equalize air pressure in the middle ear.

External ear The ear's auricle (pinna) and external auditory canal between the auricle and the tympanic membrane (eardrum).

Eye The sense organ that converts light into electrical signals to be interpreted as visual images by the brain.

Fovea A small pit, especially that in the retina where vision is clearest.

Hair follicle The tiny sheath in which a hair grows up through the skin.

Inner ear The cochlea and vestibular system, dealing with hearing and balance.

Integument An outer covering; the skin.

Iris The circular colored part of the eye. Its muscle fibers adjust pupil size.

Lens A biconvex transparent structure in the eye, behind the iris. It works with the cornea to focus light rays on the retina.

Macula The site on the retina with the greatest concentration of cones.

Nasal Relating to the nose.

Nerve A bundle of nerve fibers (axons) that transmit impulses to (in the case of sensory nerves) or from (in the case of motor nerves) the central nervous system. Mixed nerves contain both sensory and motor fibers.

Nervous system The coordinated networks of neurons (nerve cells) that control the body. It is divided into the central nervous system (brain and spinal cord), and the

peripheral nervous system (the somatic and autonomic systems or divisions).

Neuron A nerve cell: the basic unit of the nervous system, conveying electrochemical nerve impulses around the body.

Olfactory Relating to the nose and smell.

Optic Relating to the eye and vision.

Optic disk (or Blind spot) Where the optic nerve exits the eyeball.

Ossicles Tiny bones, especially the auditory ossicles: the malleus, incus, and stapes in the middle ear.

Outer ear The ear's auricle (pinna) and external auditory canal.

Oval window A membrane-covered opening between the middle ear and the inner ear.

Papillae Small nipple-like projections. The vallate, fungiform, and filiform papillae on the tongue bear the taste buds.

Peripheral nervous system A network of nerves linking the brain and spinal cord to other parts of the body. It is divided into the autonomic nervous system (which is not under conscious control) and the somatic nervous system.

Photoreceptors Light-sensitive cells in the eye's retina. *See also* Cones; Rods.

Pupil The hole in the center of the iris, through which light enters the eye.

Reflex action The body's automatic, involuntary response to a stimulus.

Retina The back of the eyeball where photoreceptors convert light into electrical impulses that are passed to the brain.

Rods Photoreceptor cells in the retina that sense dim light.

Round window A membrane-covered opening between the middle and inner ear.

Sclera The white outer coat of the eye.

Sebaceous glands Glands in the epidermis that produce sebum (an oily secretion).

Sensory neurons (or Afferent neurons)

Nerve cells that send signals to the central nervous system.

Skin The body's waterproof covering; its largest organ, comprising two main layers: the epidermis and dermis.

Spinal cord The "multi-cable" of nerve tissue running down inside the vertebral column and linking the brain with nerves supplying most of the body.

Spinal nerves Thirty pairs of nerves and one single nerve (which soon divides) that branch directly from the spinal cord. They are named, in order from the top, cervical (C1–C8), thoracic (T1–T12), lumbar (L1–L5), sacral (S1–S5), and coccygeal nerves.

Subcutaneous tissue The sheet of connective tissue below the dermis of the skin.

Sweat glands Glands in the epidermis that produce perspiration.

Taste buds Tiny sensory organs of the tongue and palate, distinguishing salt, sweet, sour, and bitter tastes.

Tongue A mobile, muscular organ in the mouth, involved in tasting, chewing, swallowing, and speech.

Tympanic membrane The eardrum, a thin membrane between the external ear and middle ear.

Vestibular system The part of the inner ear dealing with balance. It includes two sacs (saccul and utricle) containing gravity-sensitive otoliths, and three fluid-filled semicircular ducts which register movement.

Vestibule An interconnecting chamber in the inner ear beyond the oval window, between the semicircular ducts and cochlea.

Sensory neurons

Sensory nerve cells, or neurons, also called receptor cells, convey information from receptors in the body to the central nervous system (spinal cord and brain).

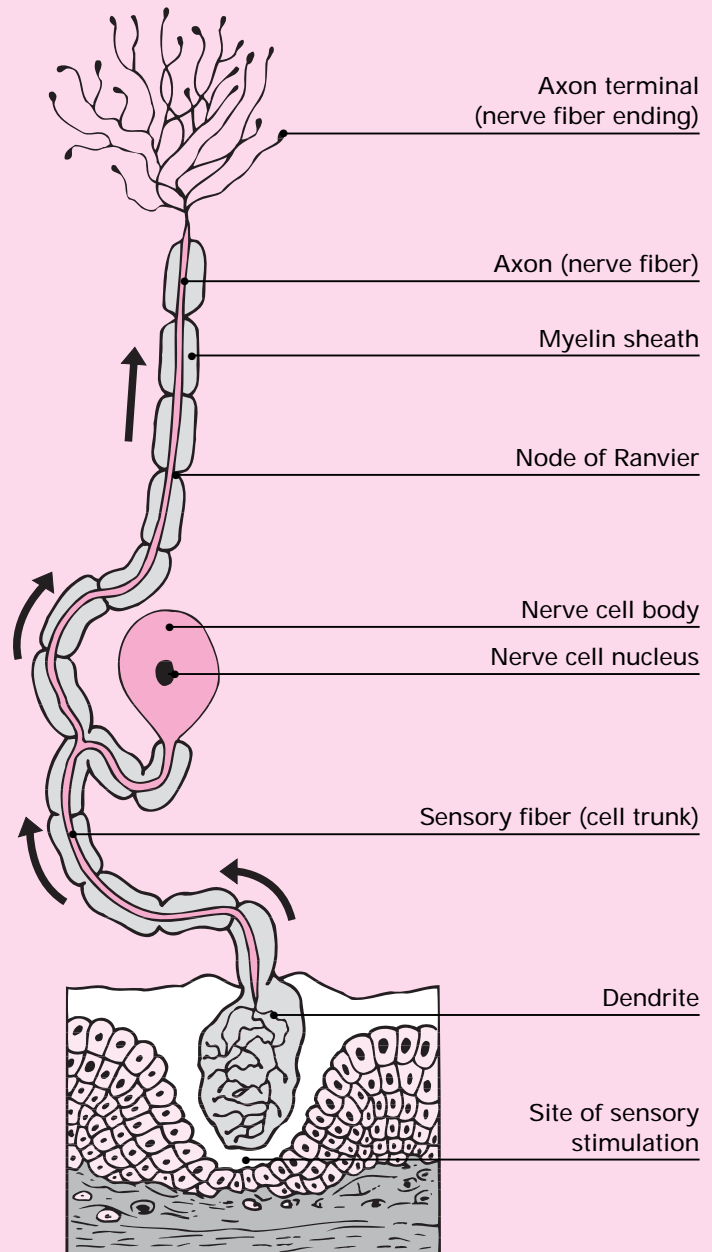
The information is in the form of tiny pulses of electricity known as nerve signals or neuronal impulses. These begin at dendrites, which are short projections of the nerve cell in the skin, eye, nose, or other sense organ.

The dendrites pick up the signals and transmit them along the sensory fiber or cell "trunk" to the nerve cell body. Another fiber, the axon, conveys the impulses to nerve endings known as axon terminals. Here the signals are passed to other nerve cells, in the brain or spinal cord.

Very long cells

- Most cells in the body are typically 1/1000th of an inch (0.025 mm) across.
- The microscopically thin but very elongated fibers (axons) of nerve cells make them the longest cells in the body.
- Some nerve cells in the legs have fibers more than 2 feet (60 cm) in length.

A sensory neuron



CNS and PNS

The Central Nervous System, CNS, consists of the brain within the skull, the major nerves leading from it, and the spinal cord. The spinal cord extends from the base of the brain, through a hole called the foramen magnum in the bottom part of the skull, and then down through the spinal canal. This canal is a long passageway formed by a series of holes in the vertebrae, or backbones, of the spine.

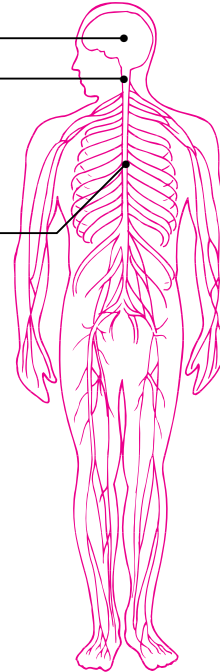
The bodywide network of nerves linking to the brain and the spinal cord is known as the Peripheral Nervous System, PNS. Most sensory nerve signals passing along nerves of the PNS in the chest, abdomen, and limbs arrive at the spinal cord via connections on its rear (dorsal) surface. These are known as dorsal nerve roots. Nerve signals known as motor impulses, sent out from the cord to body parts, leave along the cord's front (ventral) nerve roots.

Central and peripheral nerves

Brain

Spinal cord

Site of transverse section in diagram below



Transverse section through thoracic level of spinal cord

White matter (nerve fibers)

Gray matter (nerve cells)

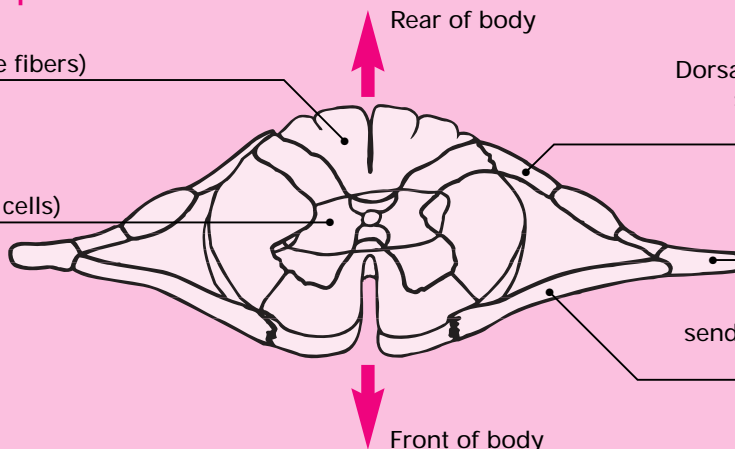
Rear of body

Dorsal nerve root brings sensory (incoming) nerve signals

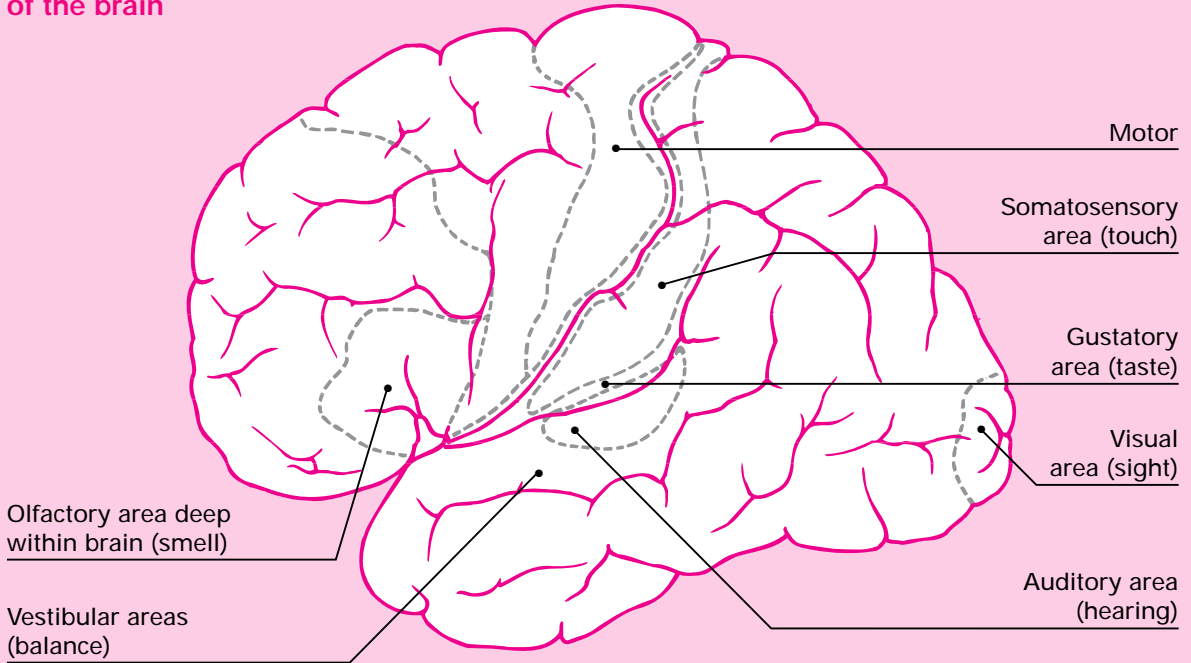
Peripheral spinal nerve

Ventral nerve root sends motor (outgoing) nerve signals

Front of body



Side view of left hemisphere of the brain



Sensory areas of the brain

The two large, wrinkled, dome-shaped structures that dominate the brain are known as cerebral hemispheres.

The surface of each of the hemispheres is covered by a thin layer of gray matter known as the cerebral cortex. Nerve signals from different sensory organs arrive at different areas or centers of the cortex for analysis.

The gray matter of the cortex is formed by billions of interconnected neurons (nerve cells) with their many-branched dendrites. Beneath the cortex is a layer of white matter, composed of nerve fibers (axons). These carry sensory signals to the cortex, and motor signals away from the cortex to other brain parts and to muscles and glands.

Lots of links

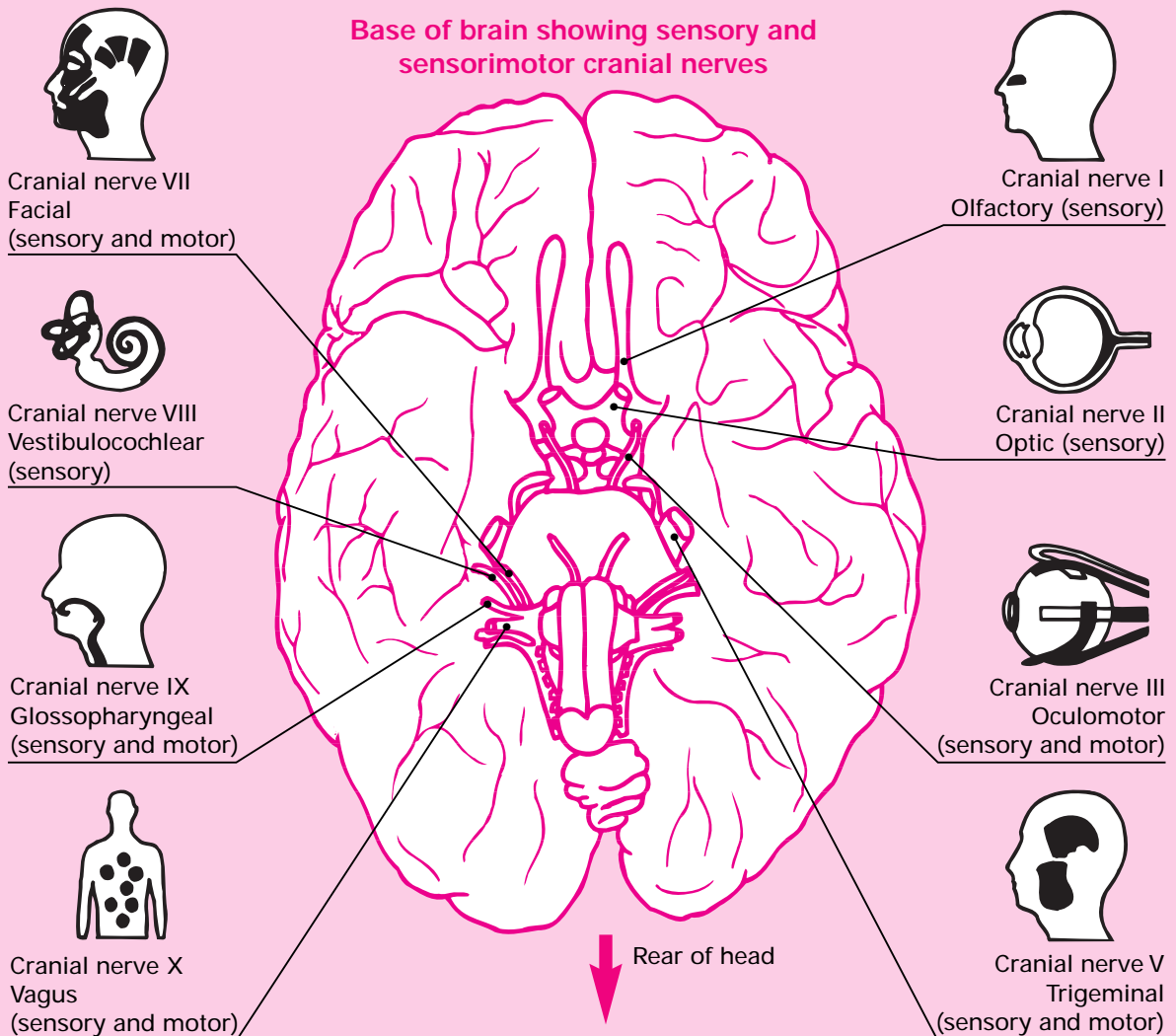
- Nerve cells in the cortex have many branching connections, or dendrites—in some cases more than 100,000.
- So each nerve cell is in communication with thousands of others.

Cranial nerves

Twelve pairs of peripheral nerves branch directly from the brain, rather than from the spinal cord. They are called cranial nerves and are numbered in pairs from I to XII. Three nerves (I, II, VIII) carry only sensory signals to the brain. Four (IV, VI, XI, XII—not labelled below) convey motor messages away from the brain.

Five (III, V, VII, IX, X) are mixed or sensorimotor. The sensory and sensorimotor cranial nerves and the sites they supply are shown below. For example, cranial nerve I brings sensory signals concerning smell from the olfactory regions of the nose.

Base of brain showing sensory and sensorimotor cranial nerves



Nerve pathways

Different nerves transmit information via specific routes (nerve pathways). The pathways taken by nerves relaying information about pain and temperature, for example, are different from each other, and from those taken by nerves relaying information received from the sense organs, such as the eyes.

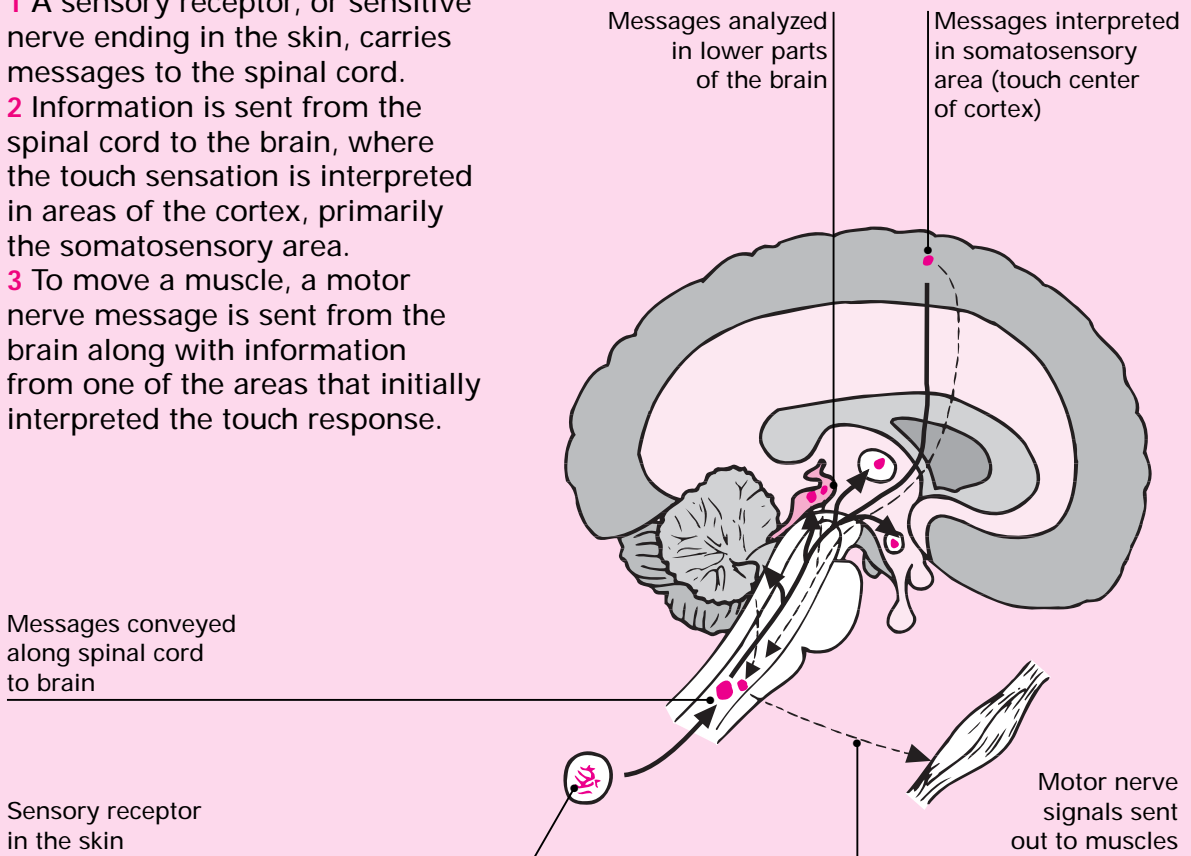
Pathway of a nerve message relating to touch

- 1** A sensory receptor, or sensitive nerve ending in the skin, carries messages to the spinal cord.
- 2** Information is sent from the spinal cord to the brain, where the touch sensation is interpreted in areas of the cortex, primarily the somatosensory area.
- 3** To move a muscle, a motor nerve message is sent from the brain along with information from one of the areas that initially interpreted the touch response.

Speed of nerve signals

- Some peripheral nerves carry sensory messages at speeds of more than 165 feet per second (50 m/s).
- Certain pain signals may travel more slowly: less than 6 feet per second (2 m/s).

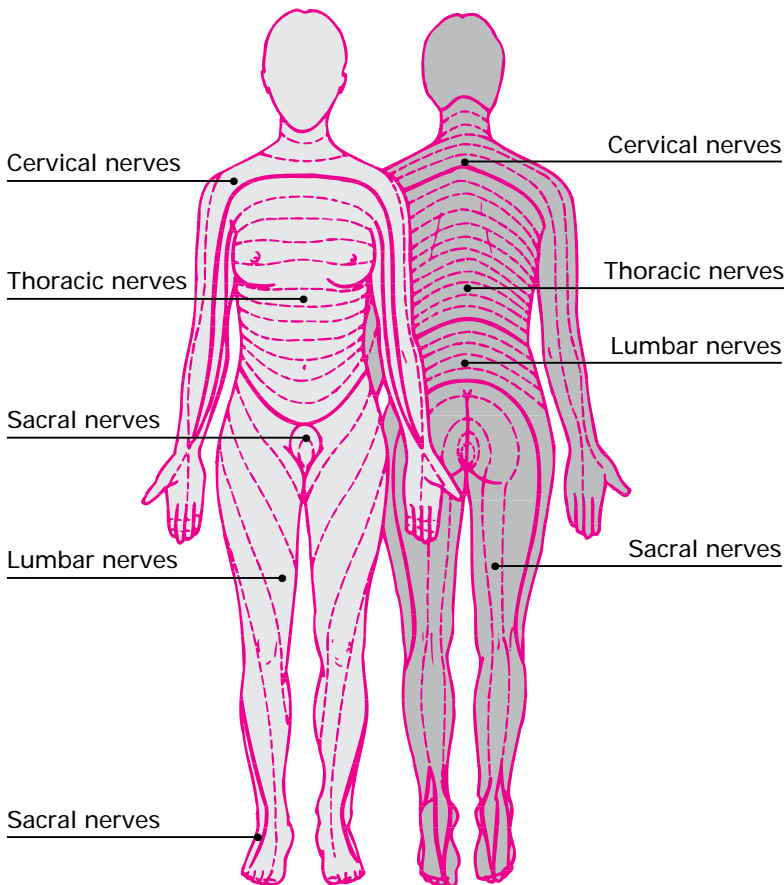
Nerve signals to and from the brain



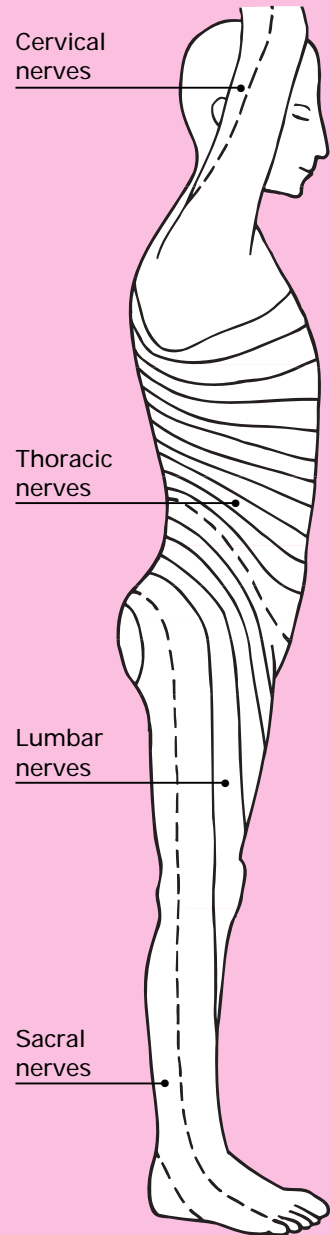
Dermatomes

Dermatomes (represented here by dotted lines) are areas of the skin identified by the nerves that supply them and convey their sensory messages about touch to the brain. Pain in a dermatome may result from a problem with an internal organ that is supplied by the same nerve. The pain caused by a heart attack, for example, can often be felt in the left arm—as both the heart and left arm are served by thoracic nerves. Solid lines represent the boundaries between groups of dermatomes supplied by different nerves.

Front and back views of dermatomes



Side view of dermatomes



Sensory receptors

These are nerve endings sensitive to various stimuli—such as light, sound, touch, pressure, temperature, hunger, thirst, and pain. There are three types of sensory receptor: exteroceptors, interoceptors, and proprioceptors.

Exteroceptors These handle information due to contact outside of the body. There are hundreds of thousands of them on the body's surface layers, especially in the lips, the tip of the

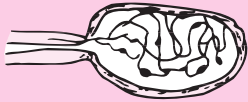tongue, and the fingertips. They include mechanoreceptors (sensitive to touch and pressure), and thermoreceptors (sensitive to heat and cold), which are found in the skin.

Interoceptors These report changes deep inside the body.

Proprioceptors These give information about joint and muscle movements. They are located mainly in the muscles, ligaments, and tendons (see opposite).

Receptors

Meissner's corpuscles



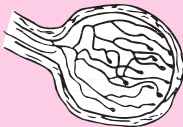Locations

- skin, especially lips, nipples, fingertips, and eyelids

Stimuli

- exteroception
- touch
- vibration

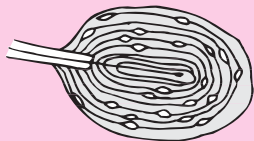
Krause's end bulbs



- mouth
- lips
- conjunctiva (front surface covering) of eye

- exteroception
- touch
- possibly temperature

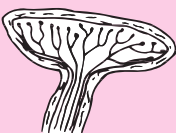Pacinian corpuscles



- skin
- joints
- soles of feet
- tendons and ligaments
- fingers

- exteroception
- interoception
- proprioception
- pressure
- vibration
- stretch

Ruffini's corpuscles



- skin
- joints

- exteroception
- proprioception
- pressure
- stretch
- touch

Receptors

Muscle spindles



Locations

- skeletal muscles

Stimuli

- proprioception
- stretch

Golgi tendon organs



- tendons

- proprioception
- stretch

Proprioception

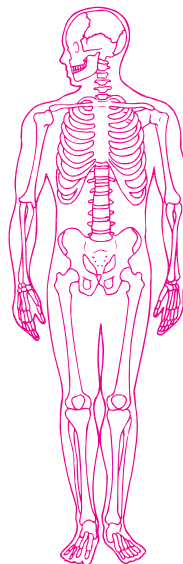
The sense of proprioception, also known as the kinesthetic sense, allows us to know and monitor the positions of body parts, and how they move, without other sensory input such as sight or touch.

It relies on many kinds of internal sensors and receptors which feed information to the brain so that a person can, for example, tie shoelaces or play guitar without looking at their fingers.

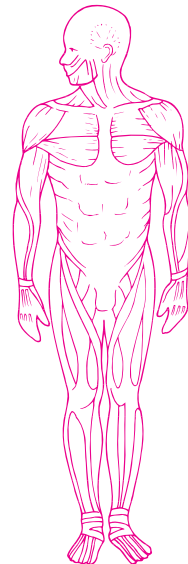
Senses and other body systems

All body systems have their own specialized types of sensors. The muscular system contains muscle spindles, and the digestive system has stretch sensors in the walls of the gullet, stomach, and intestines. Pain sensors (mainly of the type known as free nerve endings) occur throughout the body, even in the bones of the skeletal system. They register pain, for instance, due to pressure inside the bone from a tumor.

Skeletal system



Muscular system



Reflex arcs

Reflex arcs are nerve pathways that allow the one-way flow of messages. They are “pre-programmed” and involuntary, that is, they are not under the conscious control of the brain and do not respond to will.

Structure

Reflex arcs have five main parts: receptor, sensory neuron (nerve cell), integration center, motor neuron, and effector.

Receptors These are located at the site of the stimulus, such as touch sensors in the skin. They respond to a change in the internal or external environment.

Sensory neurons These transmit nerve impulses from the receptors to the central nervous system (CNS).

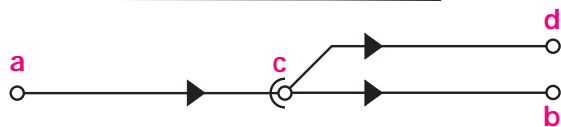
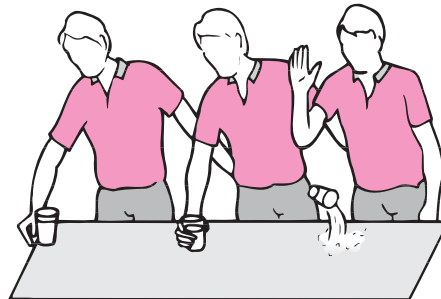
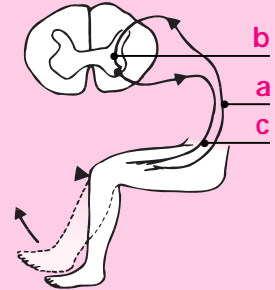
Integration centers These process incoming messages and generate outgoing messages.

Motor neurons These transmit impulses from the integration centers in the CNS to the effector organ (for example, a muscle or gland) which is outside the CNS.

Effectors These respond to impulses from the motor neurons and produce the appropriate action—such as contraction of a muscle or secretion from a gland.

Simple reflex arc

A simple reflex arc occurs when the knee is tapped with a knee hammer. The tendon beneath the knee is stretched and a sensory neuron (a) relays this information to the spinal cord (b). This relays it to a motor neuron (c), which contracts the thigh muscle, and the lower leg swings upward.



Complex reflex arc

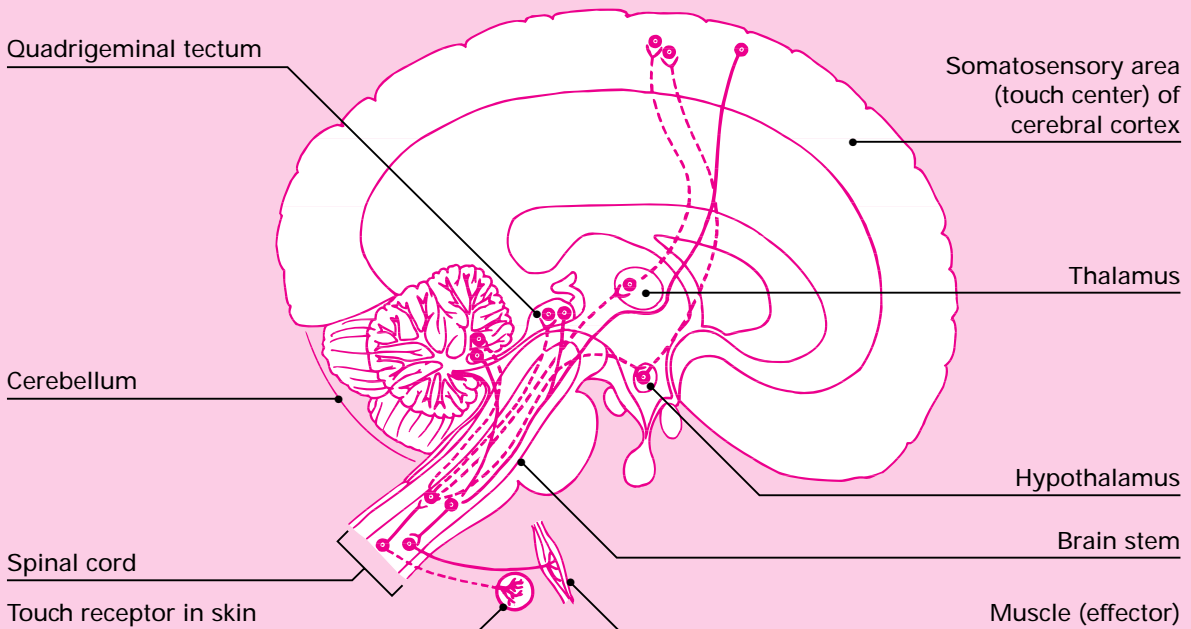
A slightly more complex reflex arc occurs when a hot cup is picked up. Heat is registered by a sensory nerve (a) in the skin and this information is relayed to a motor nerve (b) in the arm via interneurons in the spinal cord (c). The motor nerve causes muscles to contract, which draws the hand away. Pain messages are sent to the brain (d), but the reflex occurs before the brain has registered the sensation of pain.

Reflex nerve pathways

In addition to the brain, the spinal cord carries out the coordination and relaying of nerve messages, and acts as an integration center for many reflexes. In a simple stimulus-response reflex, sensory nerve messages travel from the receptor to the cord, and then motor signals travel back out to the effector,

usually a muscle, in a fraction of a second. Interneurons (those placed between the sensory and motor neurons) convey the signals to sensory and coordinating areas of the brain, but these usually arrive a split second after the response part of the reflex reaction has been initiated.

Reflex routes within the spinal cord and brain



The brain and reflexes

Brain sites involved in reflex messages include the cerebellum, which automatically coordinates muscles for complex and skilled movements; the quadrigeminal tectum, which relays messages concerning eyeball movement, vision, and hearing in reflex

reactions; the hypothalamus, involved in basic motivational drives such as fear and avoidance of pain; the thalamus, a "filter" of information destined for consciousness; and the somatosensory area of the cortex, where conscious awareness of touch occurs.

In most people, vision is the primary sense for gathering information about the world around us. It is estimated that some two-thirds of the knowledge and data within the brain, existing as memories, comes in through the eyes—in the form of words, pictures, diagrams, and similar images. Vision, or eyesight, is also vital for safety. We watch for and avoid hazards and dangers all around, from part-open doors to flashing warning lights and fast-moving vehicles. Two eyes facing forward but spaced apart allow perception of depth and judgement of distance by stereoscopic vision.

The primary sense

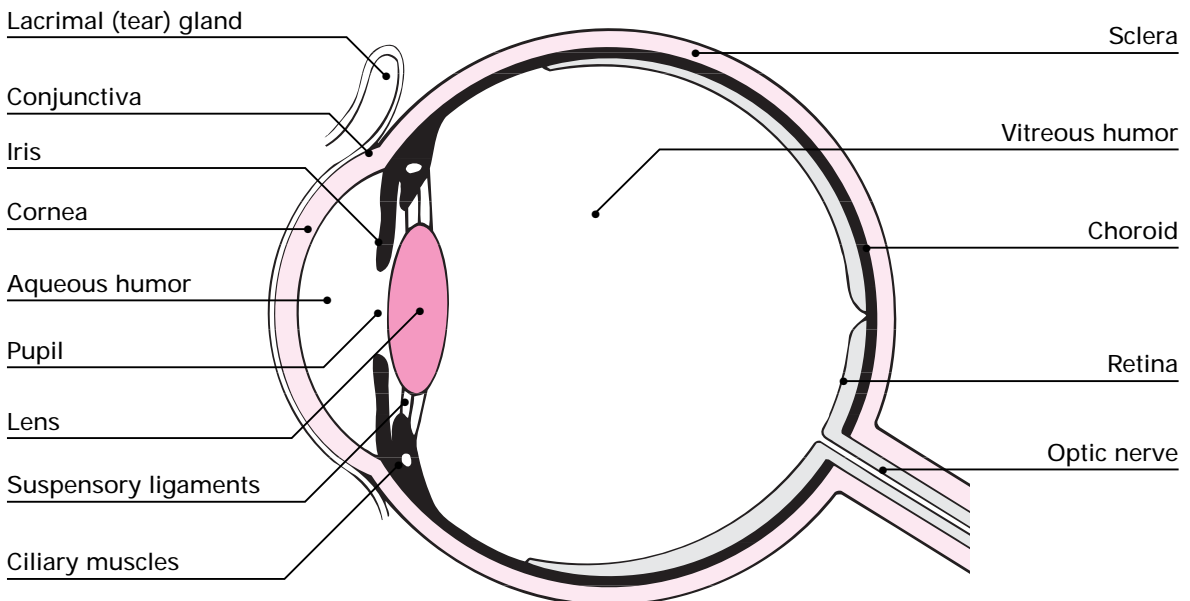
- The numbers of nerve fibers carrying messages from eyes to brain exceed the numbers of fibers from all other sense organs combined.
- Eyes have been called “outgrowths of the brain.”

Inside the eye

The eyes are sense organs that receive visual information. They contain special cells known as photoreceptors, called cones and rods. These are stimulated by light energy to send information to the

brain, in the form of patterns of nerve signals or neuronal impulses traveling along the optic nerve. Each eyeball is an approximate sphere, with an outside diameter of about 1 inch (25 mm).

Vertical section through the eyeball



Structure and function

The eye is often likened to a camera, and this comparison helps to clarify the functions of the eye's various parts. In both, the lens is adjusted to bring light rays from different distances to a focus,

forming a clear image. However, a camera lens usually focuses by moving forward or backward, while the eye's lens fulfils this function by changing shape, becoming thicker or thinner.

Structure

Lacrimal (tear) gland

Functions

- A gland producing tears that clean the eye and keep it moist.
- Tears also contain chemicals that protect against infection.

Conjunctiva

- A thin membrane that secretes mucus (thick, slimy fluid), which protects the cornea and keeps it moist and clean.

Aqueous humor

- A watery liquid that helps maintain pressure in the eye and supplies nutrients to the lens and cornea.

Cornea

- A transparent "window" through which light enters the eye.

Iris

- A colored disk that adjusts the size of the pupil.

Pupil

- A hole in the iris through which light passes.

Lens

- A soft, transparent structure that focuses light onto the retina.

Suspensory ligaments

- Cords that hold the lens in place.

Ciliary muscles

- Muscles that alter the shape of the lens.

Vitreous humor

- A transparent, gel-like substance that helps give the bulk of the eyeball its firmness and shape.

Sclera

- A tough, outer layer that protects the eye from damage.

Choroid

- A dark layer that stops light being reflected around the eye.

Retina

- A light-sensitive area containing photoreceptors (rod and cone cells) that transform light energy into nerve messages.


Optic nerve

- A nerve that sends visual information to the brain.

External appearance

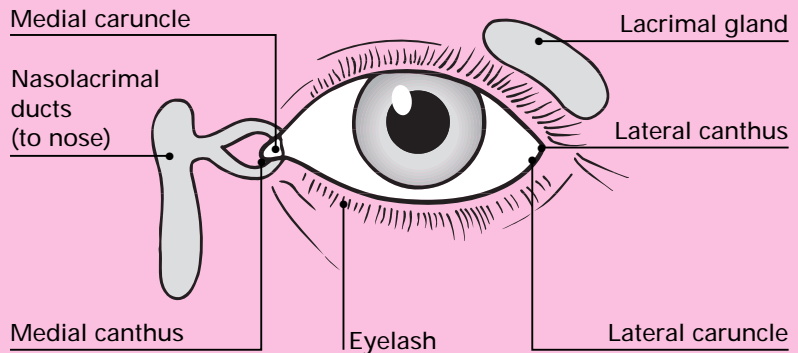
Viewed from the front, the eye's main features are the "white" or sclera, which is the eyeball's tough outer sheath; the pigmented muscular ring of the iris, which gives the eye its color, such as blue, brown, or hazel; and the dark hole or pupil at the center of the iris.

Frontal view of the eye



Healthy eyes

Healthy eyes shine or "sparkle" with a thin film of lacrimal or tear fluid. They are free from discoloration and swelling. They can focus clearly, are not tender, do not tire easily, and do not itch or "water" with excessive fluid. However, any tenderness or pain in the eye, disturbance in sight, or loss of vision may be serious. A doctor or ophthalmologist (eye specialist) should be consulted urgently. Most such cases have trivial causes and leave no lasting damage. But a few eye problems may have long-term consequences for vision.



Parts of the eye

The two eyelids, known as palpebrae, come together at each side to form V-shaped angles. These are called the medial canthus on the side nearer the nose, and lateral canthus on the side nearer the ear. In each angle is a small fleshy part, the caruncle. The lacrimal or

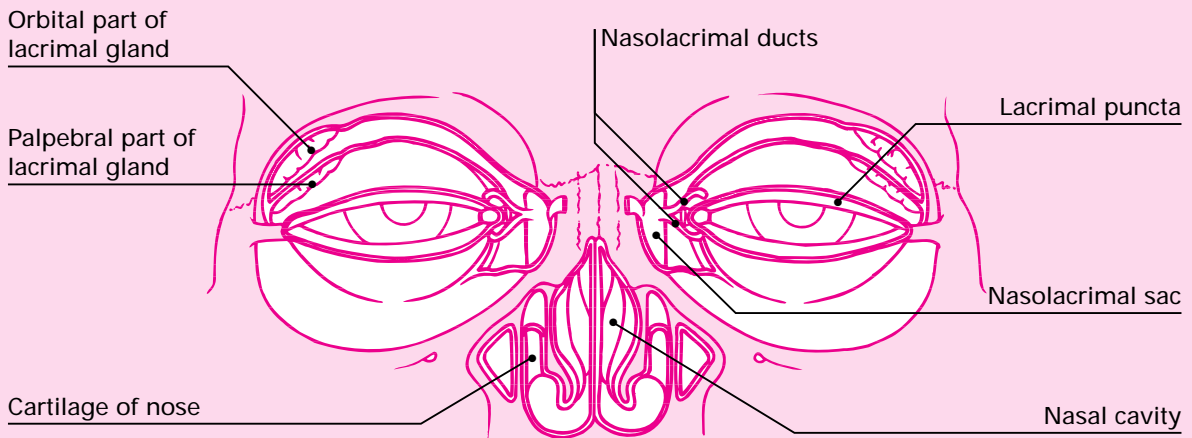
tear gland is behind the outer or lateral part of the upper eyelid. Tear fluid drains away through the nasolacrimal ducts into the nose (see opposite). The hairs of the eyebrows help prevent perspiration from the forehead from dripping into the eyes.

The lacrimal apparatus

The parts in and around the eye concerned with production and drainage of tear fluid are known as the lacrimal apparatus. The fluid is made in the two lacrimal glands, one behind the outer portion of each upper eyelid. The fluid oozes continuously along several tiny channels, the lacrimal ducts, to emerge on the rear surface of each upper lid. Blinking wipes the fluid across the eye,

where it washes away dust, germs, and other unwanted substances. The fluid drains away through two tiny openings, the upper and lower lacrimal puncta, near the inner angle of the eye. Each opening leads into a narrow tube, the nasolacrimal duct. These join as a wider tube, the nasolacrimal sac, which carries the tear fluid down into the nasal chamber for disposal.

Skin and cartilage removed to show lacrimal apparatus



Blinking

- In normal conditions a blink occurs every 2–5 seconds.
- Each blink lasts 0.3–0.4 seconds.
- Total time in a typical day with eyes closed when blinking—1.5 hours.

Tear fluid functions

- Moistens the delicate conjunctiva.
- Washes away foreign particles.
- Contains a mild anti-bacterial substance.
- Supplies nutrients to the cornea.

Eyeball muscles

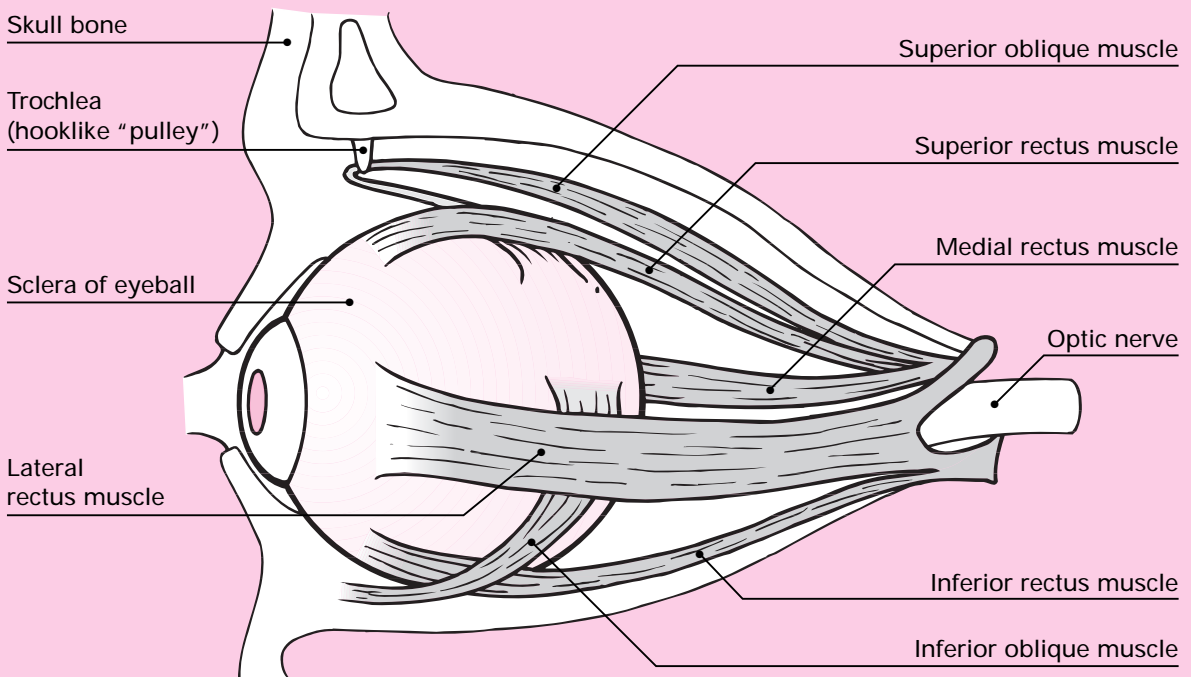
Around each eyeball is a set of six small, elongated, strap-shaped muscles. These are known as the extraocular or extrinsic muscles of the eyeball, to distinguish them from the intraocular or intrinsic muscles, such as the ciliary muscles that focus the lens. Around and between the extraocular muscles, sandwiched between the sclera (outer white sheath) of the

eyeball and the lining of the bony orbit (eye socket), are fatty pads and fluids. These act as cushions to make eye movements smooth and well-lubricated. Each of the four rectus muscles is anchored at its rear end to a ring of tendinous material around the optic nerve, at the back of the orbit. The front of each muscle joins to the sclera.

Small but fast

- The extraocular muscles are among the fastest-reacting muscles in the human body.
- They are primarily responsible for moving or swivelling the eyeball within its socket, the orbit.
- They also work with the eyelid muscles to hold the eyeball steady during violent head movements, such as sudden sneezing.

Schematized section through the orbit



Layout of the eye muscles

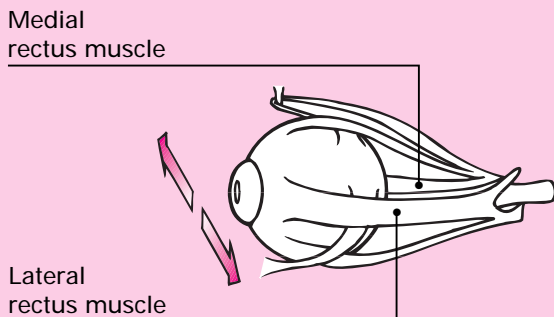
The two oblique ("angled") muscles of each eyeball have a different layout compared to the four rectus ("upright") muscles. The superior oblique muscle is anchored to the sphenoid bone of the skull, which forms part of the orbit, while the inferior oblique muscle attaches to the lacrimal bone. Each of these muscles attaches to the sclera behind the mid-point of the eyeball when viewed from the side.

In comparison the rectus muscles attach toward the front of the sclera. All six muscles act in a closely coordinated fashion and can also rotate or "spin" the eyeball.

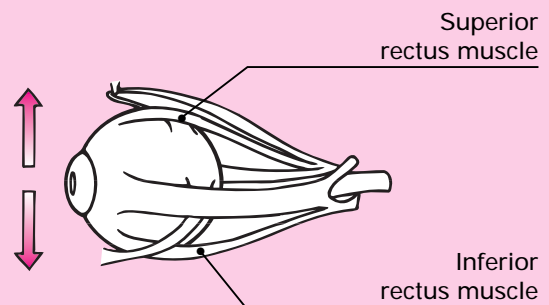
Movements of the eye

Each of the eyeball's six extraocular muscles has a main line of pull. For instance, the superior rectus muscle attached to the top of the eyeball at the "12 o'clock" position contracts to elevate or roll the eye upward and direct the gaze above. The inferior rectus muscle below the eyeball, at "6 o'clock," opposes this motion and depresses or rolls the eyeball downward. Likewise the lateral rectus muscle abducts, or swivels the eyeball to look to the outer side (toward the ear), while the medial rectus muscle opposes this action and adducts or swivels the eyeball inward (toward the nose).

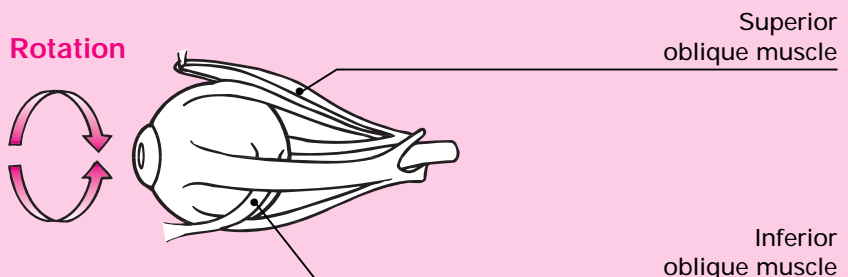
Abduction and adduction (sideways movement)



Elevation and depression (up and down movement)



Rotation



Inside the front of the eyeball

The human eye is very similar to the eyes of other mammals, and also of other vertebrates (backboned creatures) such as birds, reptiles, and fish.

The parts inside the front of the eyeball are concerned with allowing in a suitable amount of light, adjusted according to external conditions, and bending or refracting the light rays to focus a clear image onto the rear of the eye.

Cornea provides four-fifths of refracting power

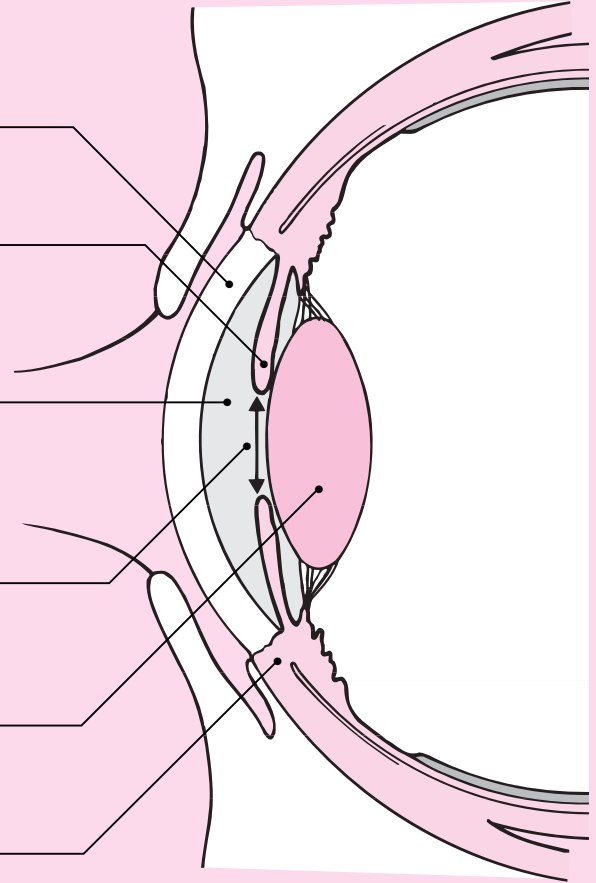
Iris muscle fibers contract or relax to alter pupil

Aqueous humor in front chamber behind cornea

Pupil constricts in bright light to prevent glare

Lens changes shape to adjust refracting power

Ciliary muscle ring alters shape of lens

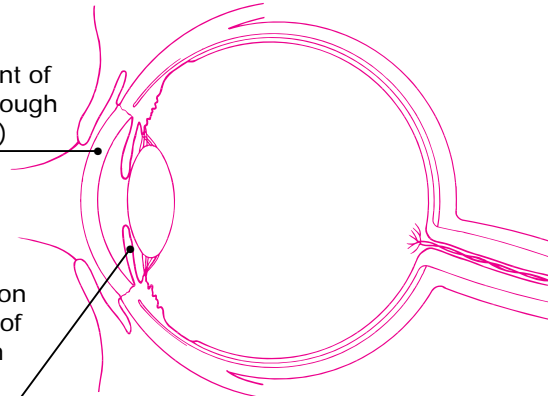


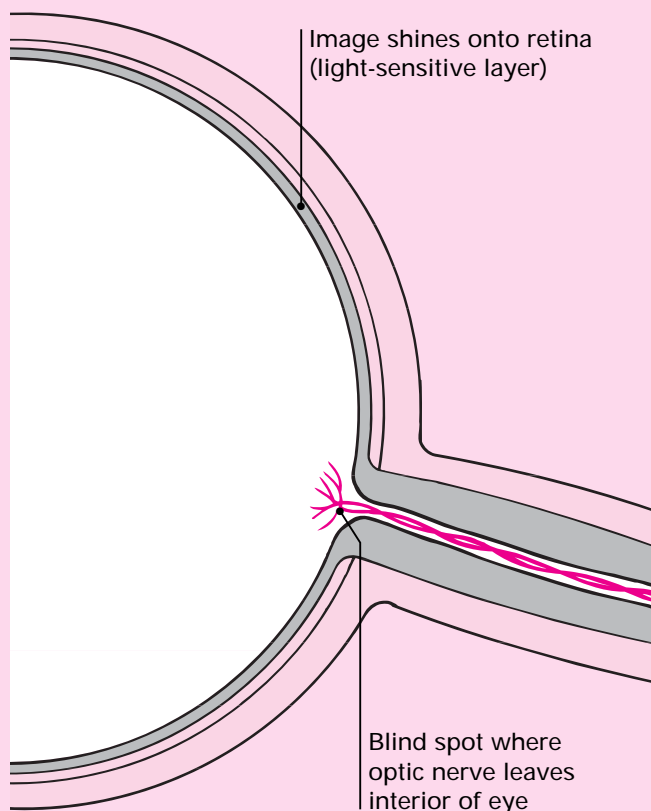
Eyeball shape

The eyeball is almost a perfect sphere, slightly "squashed" from front to back. The extra curvature of the clear, domed cornea at the front provides most of the refracting or focusing power, with fine adjustments made by the lens.

The cornea is a continuation at the front of the eye of the sclera (tough sheath-like outer layer)

The iris is a continuation at the front of the eye of the choroid (blood-rich middle layer)





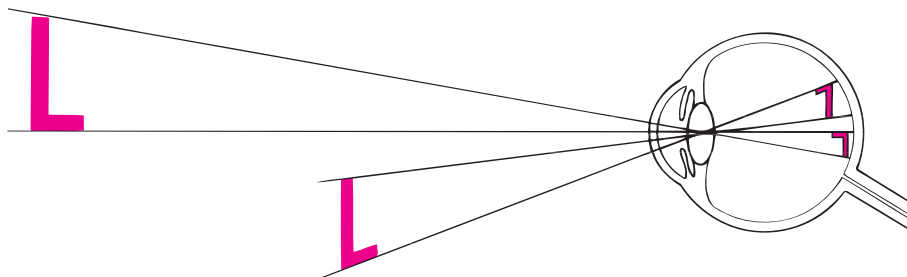
The lens and focusing

The flexible lens is suspended within a circular ring of muscle fibers, the ciliary muscle. When the eye looks at a distant object, the ciliary muscle relaxes and its circle enlarges. The lens slung in its middle is stretched in diameter and becomes flatter. This thinner lens is then suited to bending or refracting light rays less. To view a nearer object, the ciliary muscle contracts and its circle diminishes. This allows the lens to bulge and become fatter, so that it bends or refracts light rays more (see also page 36).

Optic nerve carries
nerve signals to brain

Because of the way light enters the eye, images are formed upside down and left to right on the retina. Impulses are

sent to the brain, which early in life learns, in effect, to turn them right way up and right-to-left.



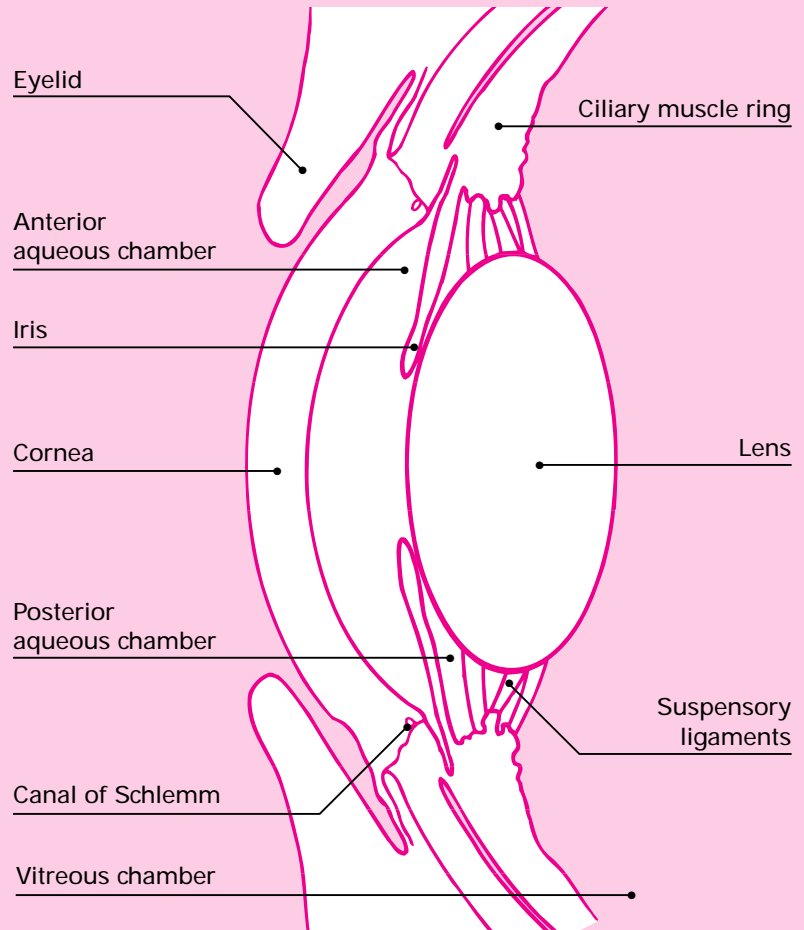
Fluids within the eye

The eyeball contains two major fluid-filled compartments. These are the aqueous chamber between the cornea and the lens, and the vitreous chamber between the lens and the retina.

In turn the aqueous chamber has two compartments—the anterior chamber between the cornea and iris, and the posterior chamber between the iris and the lens. These compartments are filled with aqueous humor, a thin, watery fluid. The humor contains nutrients to supply the lens and cornea, which are among the few parts of the body lacking their own blood supply.

The vitreous humor behind the lens is thicker and more jelly-like and makes up about four-fifths of the eyeball's total volume.

Cross-section through the front of the eye



Fluid problems

- The flow of aqueous humor through its chamber is important in maintaining the correct pressure inside the eyeball.
- If the flow is disrupted and pressure builds, the result may be glaucoma (see page 40).

Flow of eye fluid

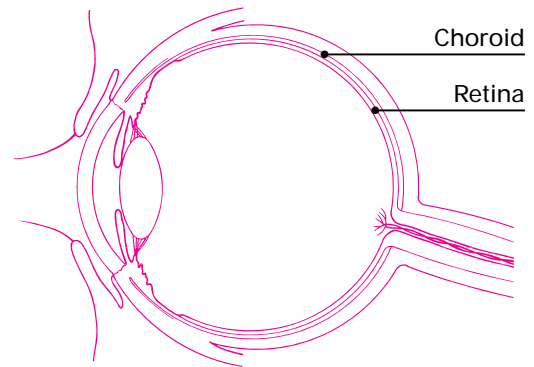
Both humors are formed by the ciliary body around the ciliary muscle. Aqueous humor passes from the posterior chamber, around the iris to the anterior chamber. It is absorbed into the canal of Schlemm at the cornea's edge.

Looking into the eye

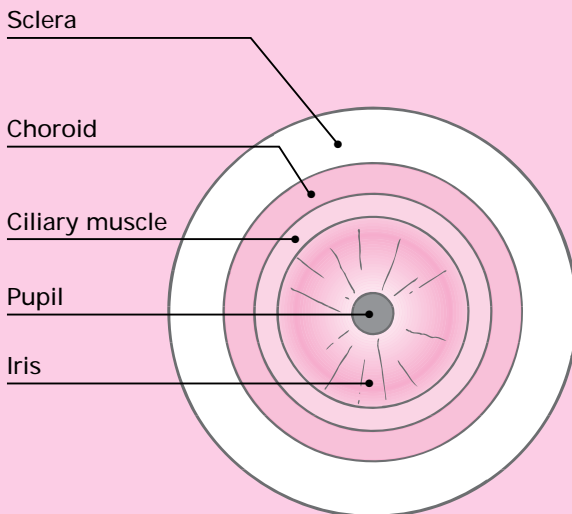
Viewing the front of the eye, the most prominent feature is the pigmented iris, visible through the transparent cornea. Around this is the blood-rich layer of the choroid. Through the central dark hole of the pupil the retina is visible lining the inner rear of the eyeball. Blood vessels snake and branch across its inner surface. The macula lutea or yellow spot (with a yellower color than the rest of the retina) is an area of great concentration of cone cells, which detect detailed features of an image in color. At its center is the slightly bowl-shaped fovea centralis, with cones only. When we study a scene, the central portion of the image falls here for maximum clarity (see page 30).

Choroid

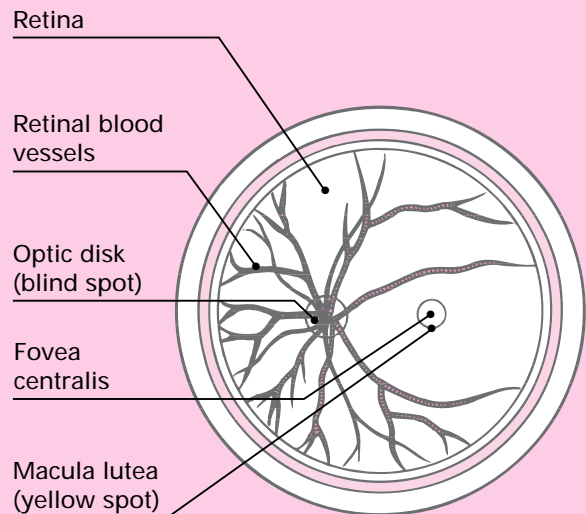
The choroid keeps both the sclera and the retina supplied with oxygen and nutrients. Its dark color helps to absorb stray reflections.



Anterior view of the iris and lens



Anterior view of the retina

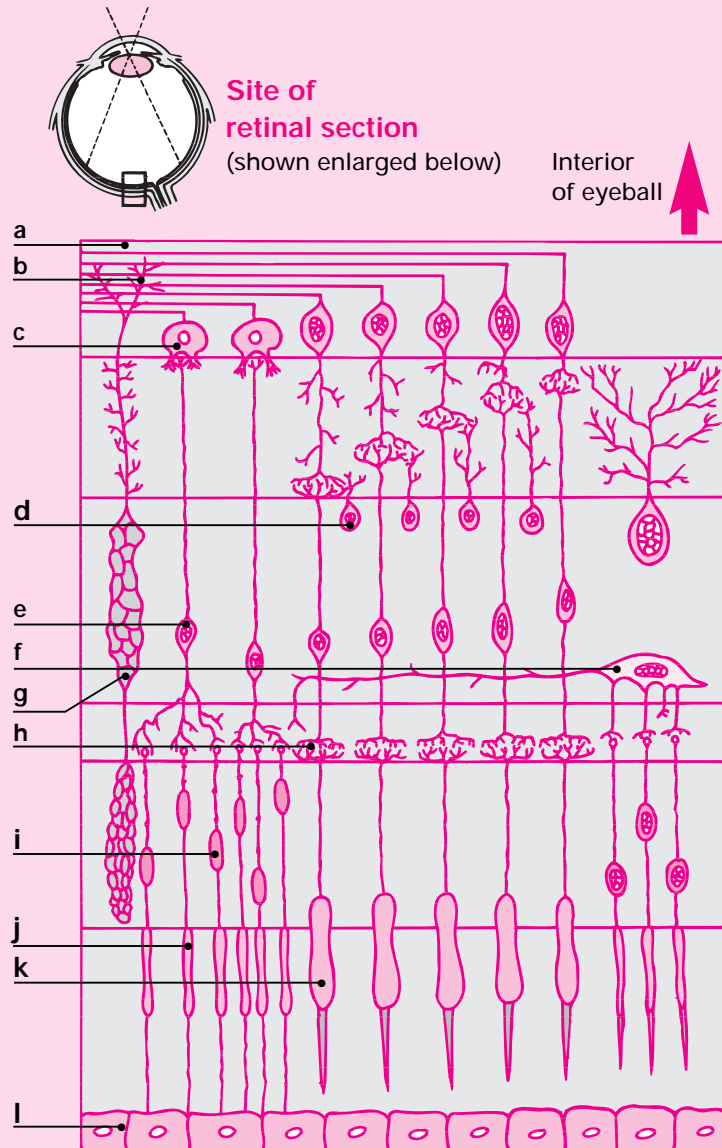


Rods and cones

The retina contains light-sensitive photoreceptor cells called cones and rods. These are not distributed evenly. The area directly behind the center of the cornea is called the fovea centralis (see page 29) and contains only cone cells. This is where vision is sharpest. Around the fovea, cone cells become scarcer and rod cells more common.

Function of the retina

Light enters the eye and passes through several layers of nerve fibers and cells before reaching the rod and cone cells. When light reaches one of these cells, it triggers a nerve impulse. The impulses are relayed and part-processed by the overlying nerve cells including horizontal, bipolar, amacrine, and ganglion cells, before leaving along fibers.



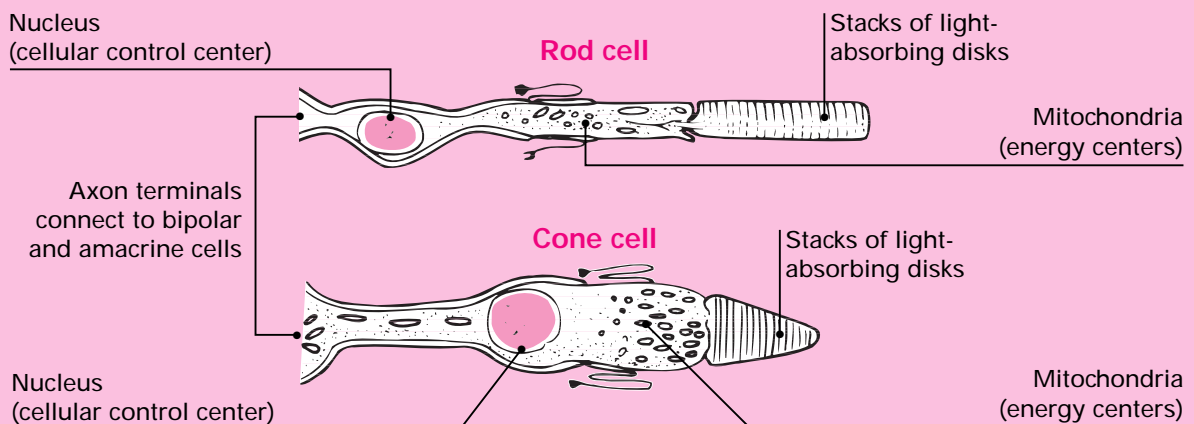
Schematized section through the retina

- | | | |
|--|---|-----------------------------------|
| a Internal boundary | e Bipolar cells (each with two long axons) | i Rod cells (cell bodies) |
| b Nerve fibers (axons) to optic nerve | f Outer horizontal cell | j Rod cells (rod sections) |
| c Retinal ganglion cells | g Glial (support) cell | k Cone cells |
| d Amacrine cells | h Plexiform layer | l Pigmented layer |

How rod and cone cells work

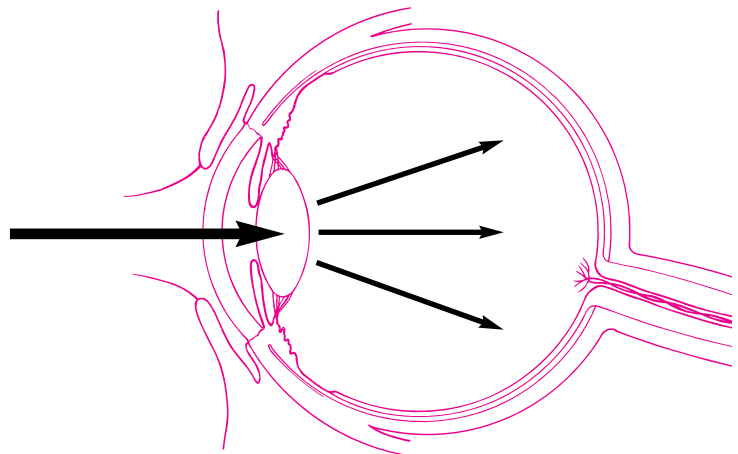
The 125 million rod cells in each retina are sensitive to dim light but they cannot discriminate between colors. They are situated mainly around the sides of the retina. The six million cone cells are stimulated only by bright light, but distinguish colors and fine detail. There are three kinds of cones, each responsive to one color: red, green, or

blue. When light strikes a rod or cone cell, it causes a photochemical reaction involving the substance rhodopsin. This stimulates a nerve signal to be sent from the cell's axon terminal to the dendrites of other retinal cells. After sending an impulse the cell is temporarily "bleached" and must recover before sending another.



The route of light

Before light rays reach rod and cone cells, they pass through several layers of nerve fibers and other cells, which block out some of them. The pigmented layer (see opposite) stops stray light reflecting around inside the eye, which could confuse the clarity of the image.



View from below of brain and visual cortex

Left optic nerve

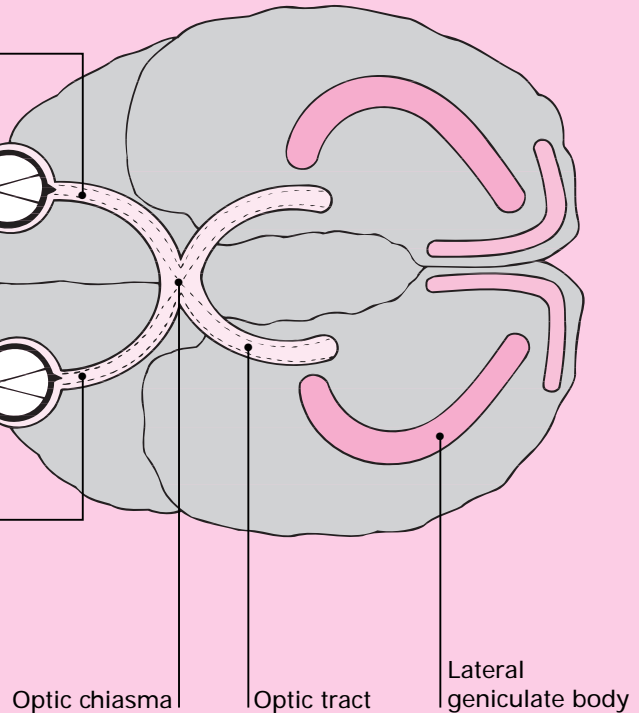
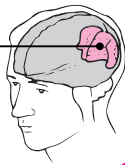Field of view

Eye

Right optic nerve

Position of the visual cortex in the brain

Visual cortex



Visual pathways to the brain

- 1** Light rays fall on the retinas of both eyes, which produce nerve signals.
- 2** The optic nerve from each eye carries the nerve signals toward the brain. The nerves meet at a crossover junction known as the optic chiasma at the lower front of the brain (see opposite).
- 3** From this point, each optic nerve becomes known as an optic tract. It continues to pass rearward through the lower center of the brain.
- 4** Each optic tract contains a relay area

known as the lateral geniculate body.

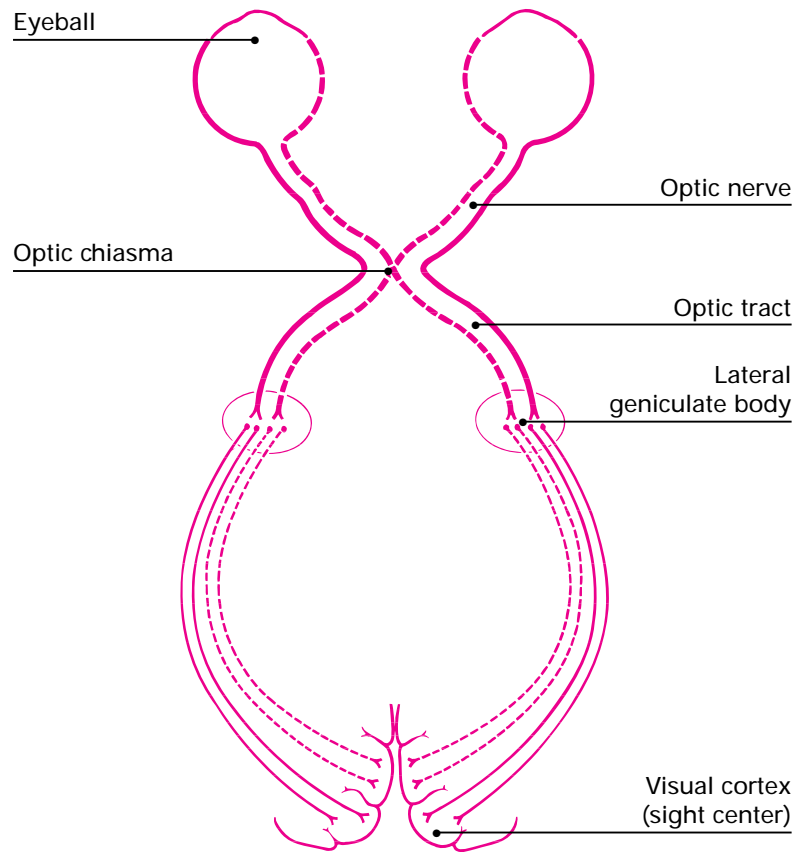
5 Nerve signals about vision are sent from here to other brain parts, such as the thalamus, which coordinates awareness and levels of arousal.

6 Finally, optic signals enter the visual cortex. Here they are registered and analyzed and also passed to other parts of the brain. In this way, information is organized and recognized so that we can grasp the sizes, shapes, and positions of the objects we see.

Swapping visual pathways

At the optic chiasma, the left and right fields of vision from both eyes are recombined. The result is that one optic tract carries information about the right-hand fields of vision from both eyes, while the other optic tract carries information about the left-hand fields of vision from both eyes. This helps comparison of the views (see below). The more different the views from, say, the left fields of vision of each eye, then the closer the object is to the eyes. This is one feature used to judge distance or depth of objects and scenes.

Schematized diagram showing crossover at optic chiasma



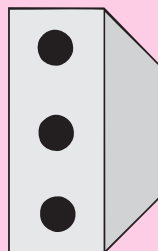
Composite image

The same object is seen differently by the left eye and the right eye. The brain combines these images to produce a composite image.


Left eye



Right eye




Composite



Eye strain

Eye strain is caused by too frequent use of the eyes in unfavorable conditions, such as poor light, a smoky atmosphere, or late at night when the eyes are already tired. Excessive reading can also produce eye strain, because it causes the eyes to remain focused at the same short distance for an unnaturally long time. All reading should be done in good light, and you should look up every few minutes to refocus your eyes on a distant object before returning to your reading. All other detailed work should also be done in good light, and if your eyes start to tire, you should rest them briefly before resuming the work.



Allergies affecting the eye

Many common allergens cause symptoms in the eyes of sensitized people, usually taking the form of red, sore eyelids. Itching is also a frequent reaction. Common culprits include make-up, dust, and chemicals. Avoid these as much as possible by using hypoallergenic

Eye care


- Treat your eyes gently at all times, remembering that any damage to the eyes may be irreversible.
- Rest your eyes when they are tired or sore.
- Avoid substances to which you know you are allergic.
- Use a good light when reading.
- Look up to change the focus of your eyes regularly when reading.
- Do all detailed work in good light.
- Make sure that you have sufficient sleep each night.
- Make sure that any foreign body that becomes trapped in your eye is removed before it can damage the eyeball.
- Consult your doctor if your eyeball is accidentally scratched.
- Use hypoallergenic cosmetics if your eyes become irritated when wearing make-up.
- Remove all make-up, especially mascara, from your eyes before you go to bed.
- Burn or boil all handkerchiefs, wash clothes, etc. that have been used by someone with sties or conjunctivitis, as both these conditions are very contagious.

cosmetics and by avoiding touching the eyes and their surroundings if your hands are dirty. If you do develop an allergic reaction, bathe your eyelids carefully with warm water and dry with clean cotton or paper tissues. (See also page 39.)


Protection against glare

Strong sunlight can cause eyesight problems ranging from discomfort and glare to permanent blindness if the bright sun is viewed directly. The glare caused by the sun is heightened when it is reflected off snow, light sand, pale-colored rocks, or water, so special care should be taken, for example, when sailing or skiing. The most common way of protecting the eyes from glare is to use dark glass or plastic, worn either as a one-piece shade or visor, on a headband, or as a pair of sunglasses. Less expensive sunglasses have lenses that are merely colored; more

sophisticated versions include those with polarized lenses that reduce glare and those with photochromatic lenses that increase their tint automatically as you move into stronger sunlight. For those who wear ordinary glasses it is possible to have prescribed lenses tinted or to buy dark lenses that clip onto the glasses frame over the usual lenses. Even the strongest sunglasses, however, are not sufficient protection for looking directly at the sun, even when watching an eclipse. Special viewers or filters, made to special standards, are available for such purposes.



Eyeshade or visor



Sunglasses ("shades")

Beware of the sun

- NEVER look at the sun with unprotected eyes.
- Even more importantly, NEVER view the sun through a telescope or binoculars.

One-eyed viewing

- Viewing a scene through one eye, as with a monocular telescope, can be awkward.
- It may help to change the eye being used regularly, or to wear an eye patch.

Corrective aids

Lenses of various kinds are the most common aids for defects that arise from focusing problems (see also page 42). Lenses are made from polished glass or plastic, and are shaped or treated so that they correct the defect by changing the direction of the light waves that pass through them. Corrective lenses may be prescribed for only one eye if the vision in the other is normal; in this case the person may wear a pair of eyeglasses in which one lens is plain glass, or may use only one contact lens. (For care of such items, see opposite)

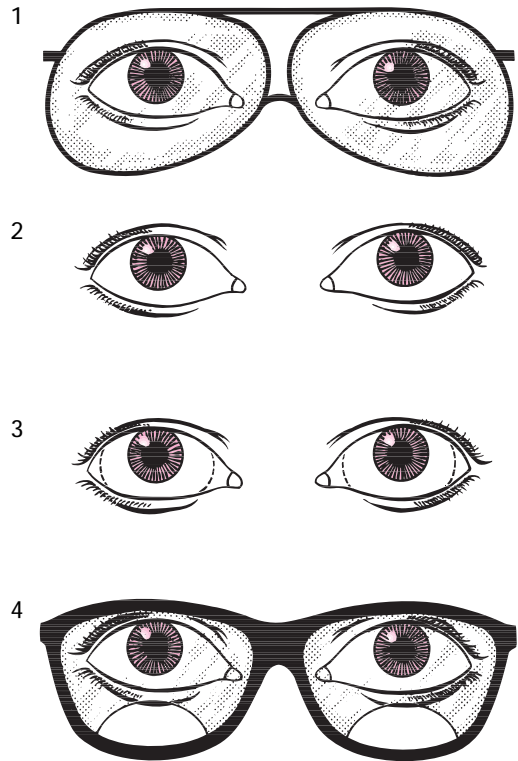
1 Eyeglasses or spectacles consist of a pair of lenses, prescribed individually for each eye, connected by a frame that goes over the bridge of the nose.

2 Rigid contact lenses are small lenses of glass or plastic that “float” on the front of the eyeball, held there by the suction of the eye’s natural fluids. The lens usually covers only the center of the eyeball.

3 Soft contact lenses are larger than most of their rigid counterparts, and are gelatinous in form. Many people find them easier to wear than the rigid lenses, and some do not need to be taken out at night. Some are now disposable daily.

4 Bifocals are glasses for people who need a weak lens for ordinary vision and a stronger lens for reading or detailed work. The bottoms of the lenses contain arcs of a more powerful refraction, and as the eyes look downward the beams of light they receive are those that have passed through the stronger lenses. It is

Spectacles and lenses



important to remember that the very old and the very young frequently will not complain about eye problems, so those who are caring for them must be extra vigilant in noticing anything unusual which may be a result of vision problems. Warning signs include frequently rubbing the eyes (this may happen if the vision has become blurred), or tripping over, bumping into, or mishandling objects.

Professional eye care

It is important to have your eyes checked regularly so that you can be sure that they are in good health. If you have any overt defects in vision, the correct lenses will be prescribed for you or surgery arranged, and the specialist will also be able to spot many signs of latent eye trouble such as the warning symptoms of glaucoma or detached retina. You should also make an extra visit to the ophthalmologist if you suffer from persistent unexplained headaches, especially after reading, or if you have sustained an eye injury.

Glasses (spectacles)

Glasses should be chosen for fit, comfort, and appearance; if they are unsatisfactory in any of these respects you will soon become reluctant to wear them regularly. Glasses are readily available and easy to fit, and tend to be cheaper than contact lenses; they are also easier to clean and maintain, and are not so easily lost. You will usually be able to choose from many frame styles; the frame should rest on the bridge of your nose and not slip down, and the earpieces should not chafe. Wear your glasses as often as your ophthalmologist recommends.

Contact lenses

Contact lenses are of two basic types: rigid gas permeable (RGP) and soft (see opposite). Soft lenses are easier to adjust to, and can generally be worn for longer periods than the rigid type, but they are generally more expensive and have a shorter life. Rigid lenses are easier to keep clean, and easier to alter to suit changing eye needs, but many people experience difficulty in accustoming the eyes to wearing them. Contact lenses are more difficult to fit than glasses, and may require several visits to the ophthalmologist. They are not suitable for everyone, and can cause harm if they are not used correctly.

Eye "don'ts"

- Don't wear glasses that slip down the bridge of your nose or rest on your cheekbones.
- Don't fiddle with glasses when you are not wearing them; this may loosen the screws and affect the fit.
- Don't insert contact lenses if your hands are dirty; thoroughly wash and dry your hands before handling them.
- Don't continue to wear a contact lens that has dirt or dust lodged behind it; take it out, clean the lens and bathe your eye before reinserting the lens.
- Don't leave contact lenses in position if your eyes become sore.
- Don't borrow someone else's glasses, except in an emergency; you should only wear lenses that have been specifically prescribed for your eyes.
- Don't use glasses or contact lenses that have been scratched or damaged; take them to your ophthalmologist and have them repolished or replaced.
- Don't wear glasses that will break easily when taking part in sports activities; extra-durable protective types can be bought for this purpose.

Laser surgery

- Lasers have revolutionized eye care and ophthalmic surgery in the past few decades.
- Laser beams are used to re-fix detached retinas, burn away opaque patches, and sculpt the front of the eye (cornea) so that contact lenses or spectacles are no longer needed.

Common eye problems

The diagram below illustrates some of the common problems that manifest themselves in or around the eyes. Most of these problems can be treated at home, but if any eye problem or infection persists then you should consult your doctor.

1 Foreign body in the eye. Removal of specks of dirt, dust, etc. that have become lodged under the eyelid is very important (see opposite). If they remain they may scratch the eyeball. Generally it is better to wash the object out of the eye than to try

to remove it manually. If the object is not removed easily, or if any soreness persists after removal, see a doctor.

2 Black eye is usually caused by a blow to the eye area. The bruising may be eased by several applications of a cold, wet, sterile compress. If vision is disturbed, consult a doctor urgently. Take a child with a black eye to a doctor as she or he may not report any vision disturbance.

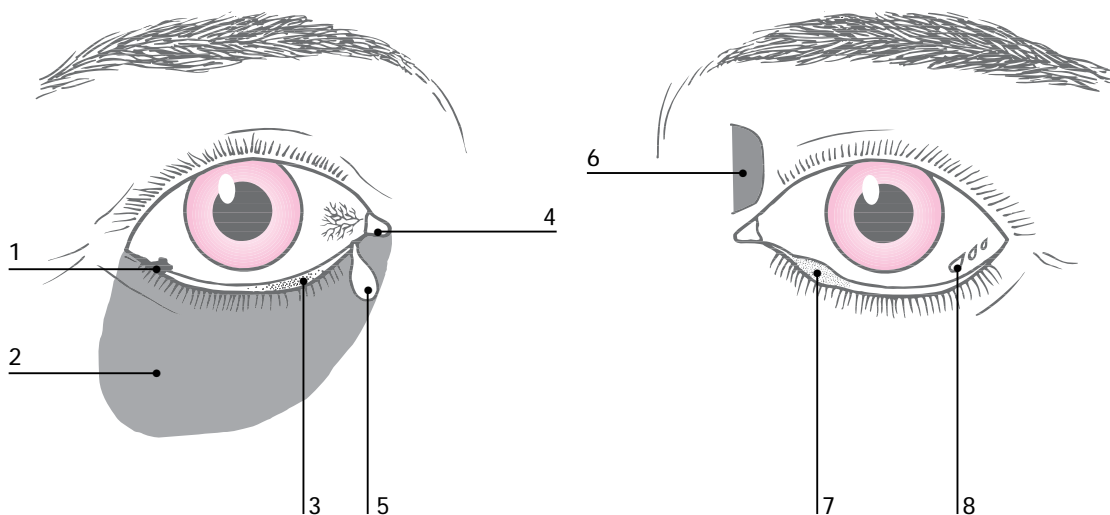
3 Inflamed eyelids are often the result of allergies (see page 34), but if yellow crusts are present, the

cause is probably an infection.

4 Conjunctivitis, or pinkeye, is reddening of the inner eyelids and the conjunctiva (see also page 40).

5 Watering of the eyes is common in young babies, and almost always disappears as the baby grows. It is often noticeable also in older people, caused by loose skin around the eyes. Ask your doctor for advice if you have troublesome watering or any discomfort or discharge.

6 Benign cysts often



occur around the eyes. They usually disappear of their own accord eventually, but will require medical attention if they become infected.

7 A sty is a boil that generally has formed in one of the hair follicles of the eyelashes. The sty usually reaches a head after several days and will then burst. When this has occurred the eyelid

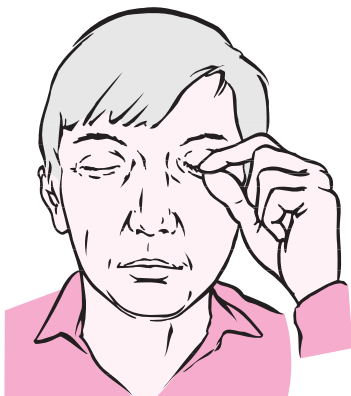should be wiped frequently with cotton swabs dipped in clean warm water; this will prevent the infection from spreading to other follicles. If sties are recurrent see your doctor, as other follicles may be harboring infection, which could then require antibiotic treatment.

8 Splashes of chemicals. Most chemicals can irritate

the eye if they come into direct contact. Wash the eye at once with plenty of water, and see a doctor quickly with a note of the chemical that caused the problem. Always wear protective goggles or a visor when handling strong chemicals that may splash.

Removing a foreign body

It is quite common for dirt, fibers, eyelashes, or small insects to become trapped under the eyelid. Because the eye is so sensitive they usually cause great discomfort. To remedy the problem, first rinse the eye in an eyebath or a cupful of water. If this doesn't dislodge the source of the trouble, lift your upper eyelid by the edge and pull it out and down over the lower lid, as shown. If this measure also fails, it is probably best to see a doctor: never try to use tweezers, cotton tips, or similar items as these might easily damage the eye.



Risks to eyes

People working in dusty environments are urged to wear protective eyewear such as goggles, a mask, a helmet, or a visor. In particular, there are great risks from the fast-moving sparks, shards, and specks thrown out by drills, grinders, sanders, and similar machinery. Continued exposure of the delicate eye surface to such particles can cause increasing irritation and sensitization. There are also risks from very bright sources of light, especially arc-welding and halogen-type spotlights. In many cases eye protection is a required condition in workplaces such as factories and machine shops.

The eyes and pollen

For people who suffer from hay fever and similar allergic conditions, pollen landing on the conjunctiva can set off an episode of swelling, redness, watering, and itching. Again, protective eyewear such as wrap-around sunglasses can help to reduce the irritation. Rubbing the eyes, or exposing them to fast-moving airstreams or wind usually worsens this problem.

Disorders of the eye

Blindness The inability to see. It can be total or partial and has a number of causes, including injury, and such diseases as various degenerative nervous disorders.

Cataract Condition in which the lens of the eye becomes cloudy due to overexposure to sunlight, disease, certain drugs, or aging.

Colorblindness An hereditary defect possibly caused by the lack of certain color-receptive cells (cones) in the retina (see opposite).

Conjunctivitis Inflammation of the membrane (conjunctiva) that lines the insides of the eyelids and covers the cornea.

Glaucoma Pressure within the eye increases (see page 28), compressing the retina and the optic nerve, and causing pain and possibly increasing blindness.

Nyctalopia (night blindness) The inability to see well in dim light.

Retinal detachment

A condition in which the light-sensitive inner layer, the retina, lining the back of the eyeball becomes detached from the outer layers around it.

Retinal hemorrhage

Bleeding into the retina which may be caused by diabetes mellitus, hypertension, or by blockage of the vein that drains blood from the retina.

Retinal tear A tear in the retina caused by injury or general degeneration.

Retinal vein or artery occlusion Blockage of the central vein or artery of the retina that sometimes results in blindness.

Retinitis Inflammation of the retina inside the eye.

Retinitis pigmentosa Degeneration of the light-sensitive cells of the retina.

Retinoblastoma One type of cancer of the retina.

Strabismus (squint, see below) Condition in which one eye does not look



“straight,” but turns in (convergent) or out (divergent). It is caused by a lack of balance between the muscles that control the eyes or a failure of the nervous system to control these muscles.

Toxocariasis The infestation of humans by the worm *Toxocara canis*, which lives in the intestines of dogs. It is spread by contact with dog feces or areas where they are left, and can infect and destroy the retina, causing blindness.

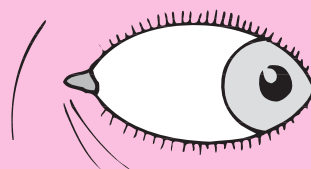

Toxoplasmosis Infection by a parasite that can affect the retina.

Trachoma Chronic and contagious conjunctivitis caused by a specific microorganism.

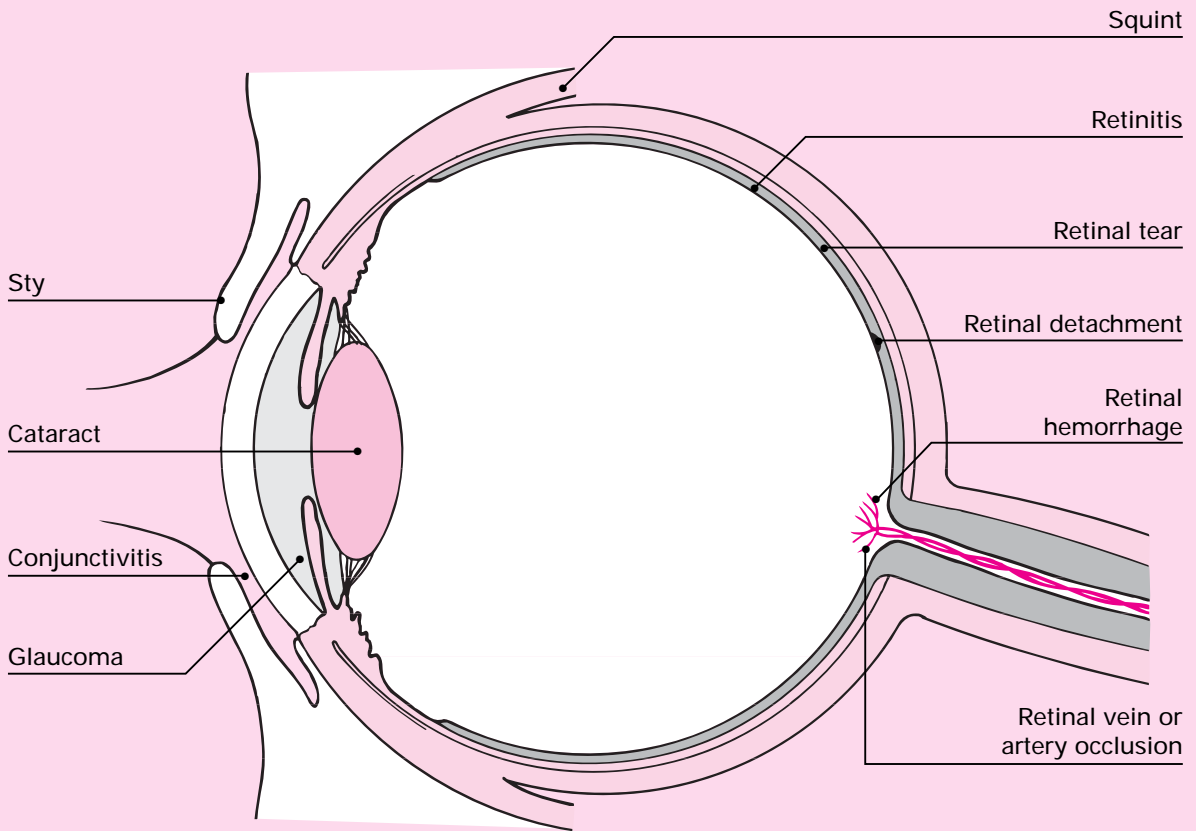
Convergent squint



Divergent squint



Sites of eye disorders

**Examining the retina**

- Examination of the interior of the eye, and especially the retina, gives much valuable information.
- This includes not only information about vision and the condition of the eye itself, but also about general health.
- The doctor views the eye's interior through the

pupil and lens, shining a light into the pupil to illuminate the interior.

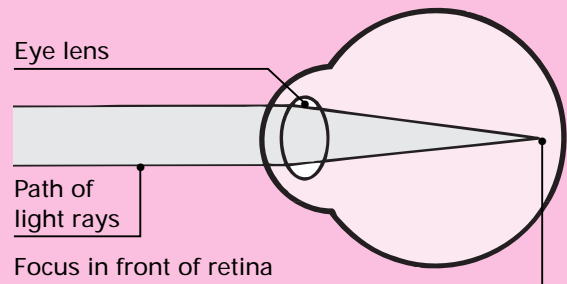
- The arteries and veins branching across the inner surface of the retina are the only place on the body where exposed blood vessels can be conveniently viewed.
- The state of the vessels can indicate several health problems, including diabetes.

How corrective lenses work

(see also page 36)

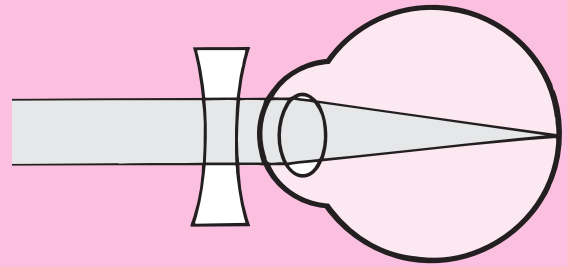
Focusing in a myopic eye

In short sight, or myopia, the eyeball is too big for the focusing power of the lens. Light rays are brought to a focus in front of the retina and so images from more distant objects are blurred.



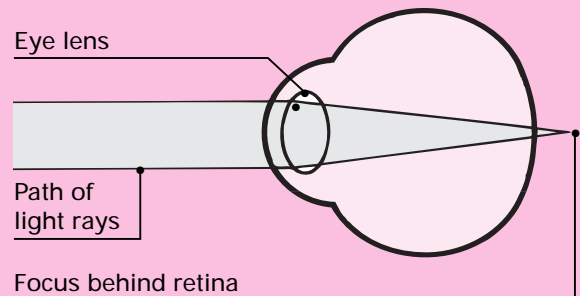
Myopia corrected by a concave lens

A concave lens is thinner in the center than around the edges. It makes light rays diverge or bend apart before they pass through the eye's lens. This brings them to an accurate focus on the retina.



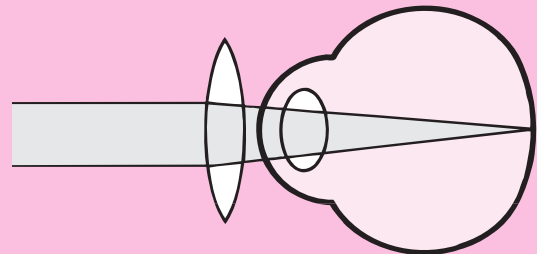
Focusing in a hypermetropic eye

In far sight or hypermetropia, the eyeball is too small relative to the focusing power of the lens. Light rays would be brought to a focus behind the retina so when they reach the retina images from nearer objects are blurred.



Hypermetropia corrected by a convex lens

A convex lens is thicker in the center than around the edges. It makes light rays converge or come together slightly, before passing through the eye's lens. This focuses them at the correct distance, on the retina.

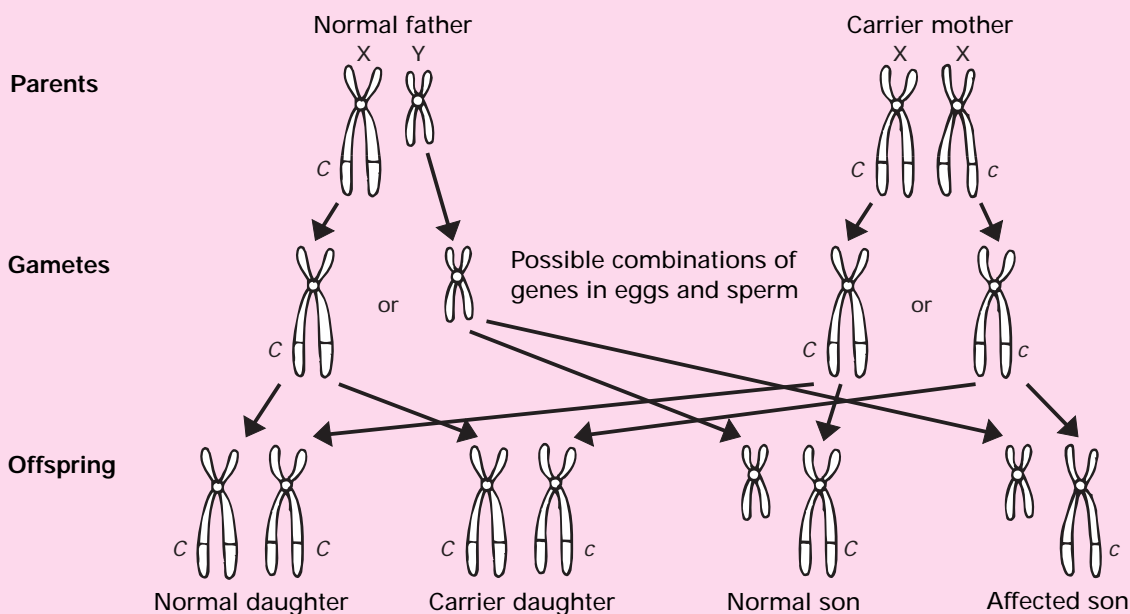


Inheritance of colorblindness

Red-green colorblindness, or defective color vision, is a relatively common condition in men. It is caused by a change in the genes and so it can be inherited, or passed from parents to offspring. In the genetic make-up of each individual there are two or more variations of most genes, called alleles. These alleles are contained in packages of genetic material known as chromosomes. In the case of defective color vision the alleles are

carried on the X chromosome, which is one of the two sex chromosomes. A female has two X chromosomes, XX, while a male has one X and one smaller Y chromosome, XY. In a female, if one X chromosome has the normal allele for color vision, C, and the other X has the defective allele, c, then the normal allele predominates and so vision is normal. But the female is a “carrier” and may pass the defective allele to offspring.

Color vision inheritance



Affected males

In the male, XY, there is only one allele for color vision, on the X chromosome. The Y chromosome has a different structure and does not carry a color vision allele. In a male, if the color vision allele is normal, C, then vision is normal. But if this allele is abnormal, c, then color vision will be

defective. This is because there is no “partner” X chromosome with a normal allele, C, to predominate over it. The diagram shows the possible combinations resulting in the children of a normally sighted male and a “carrier” female (with one allele for defective color vision).

In most people, hearing is the second most important sense (after vision) for gathering information about the world around us. Hearing allows us to detect hazards and dangers, such as the wail of a warning siren, the screech of vehicle brakes, or the scream of an injured person. Like eyesight, hearing changes throughout a lifetime. It is most sensitive in youth and becomes less so with age. Having two ears, one on each side of the head, enables us to perceive the direction from which a sound comes, by stereophonic or binaural hearing.

High and low sounds

- Sound waves occur in many frequencies (pitches).
- Human ears detect a range from the deep rumble of thunder, at 25–30 Hz (vibrations per second), to the shrillest of birdsongs at 20,000 Hz.

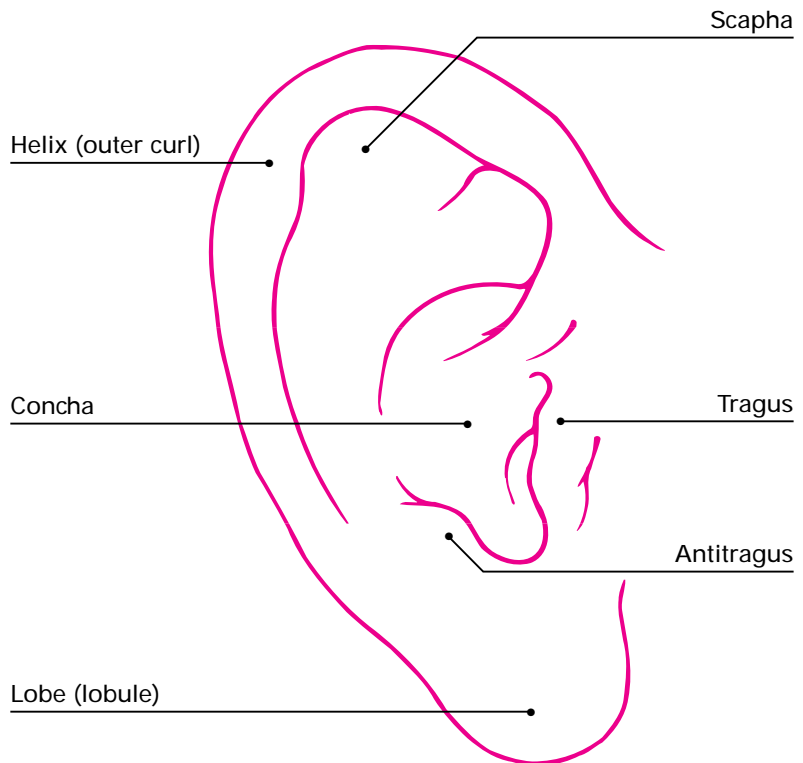
External ear

The ear flap on the side of the head is also called the auricle or pinna. It is the largest, but by far the simplest in structure, of all the parts involved in the auditory sense. It is basically a funnel made of curved pieces of bendy, springy cartilage, covered with skin. Each curl and prominence of the ear flap has a name.

The overall shape, and especially the size of the ear lobe or lobule relative to the rest of the flap, is under the influence of genes inherited from parents.

The concha is the narrowing entrance or hole into the ear canal (see opposite), which passes into the temporal bone of the skull.

Side view of the right ear flap (auricle or pinna)

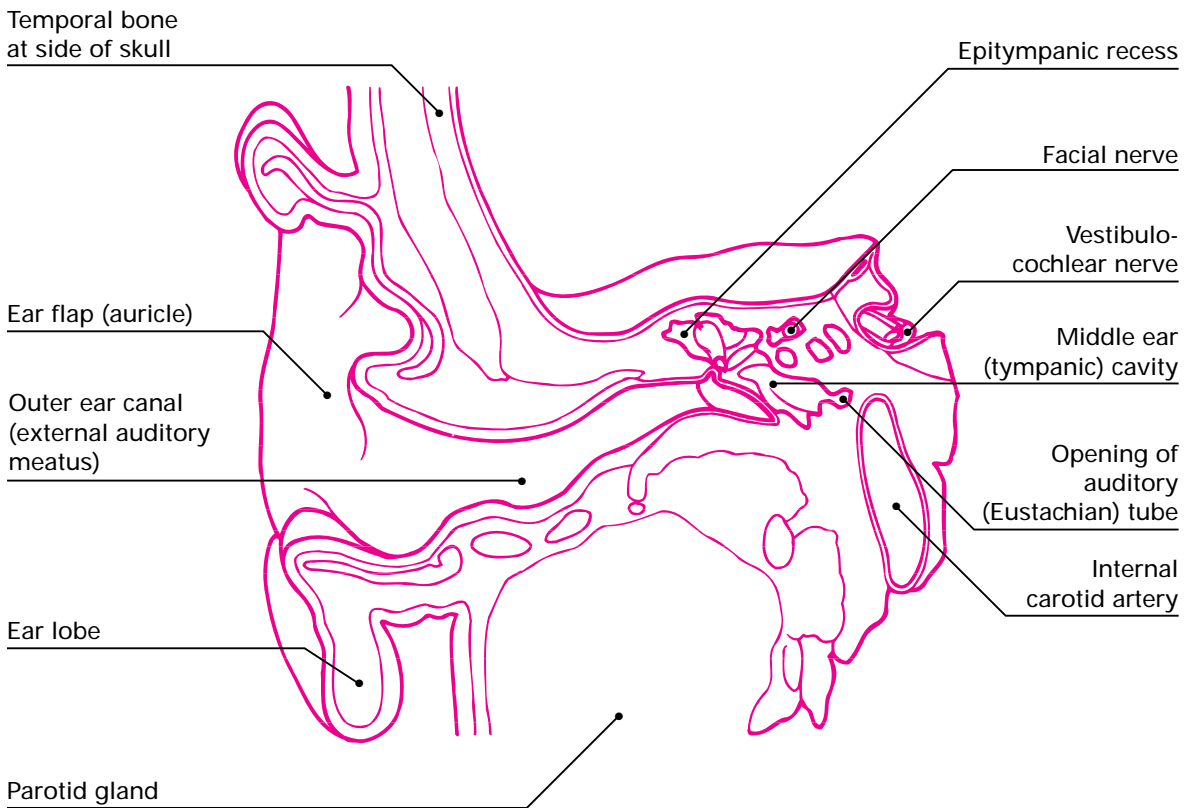


Parts around the ear

The parts of the ear extend at right angles from the ear flap, inward to the center of the head. The innermost parts of the ear are almost behind the eyeball. The image below shows the relationships of various cavities, nerves,

and blood vessels in and around the ear. The parotid gland produces saliva; the internal carotid artery supplies parts of the brain with blood; and the vestibulo-cochlear nerve carries information about both hearing and balance to the brain.

Coronal section through the ear (viewed from front)



Main parts of the ear

The ear is usually divided into three parts. The outer ear ends and the middle ear begins at the eardrum or tympanic membrane. The inner ear is set into the

skull bone and changes patterns of sound waves into corresponding patterns of nerve signals. It also deals with position and balance.

Structure

Outer ear

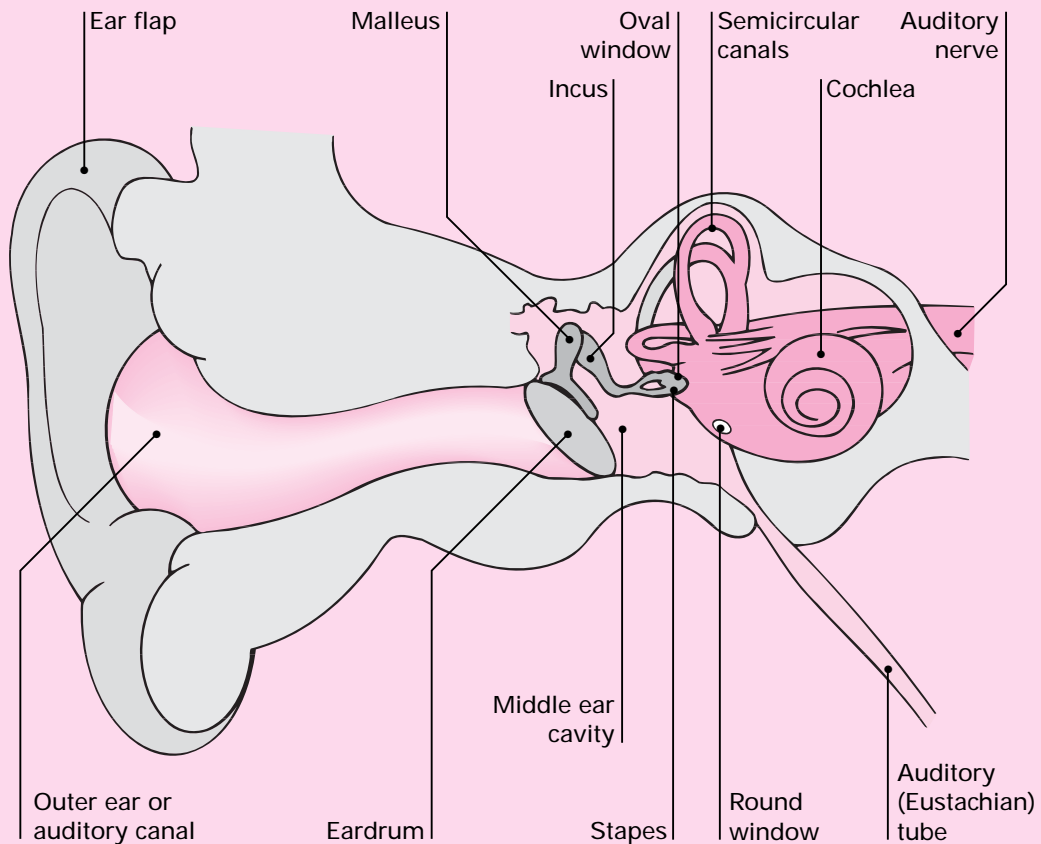
Ear flap (auricle or pinna)

Outer ear canal

Functions

- Gathers sound waves and directs them to the middle ear.
- Conveys sounds to the eardrum.

Section through the ear (viewed from front)



Structure

Middle ear

Eardrum (tympanic membrane)

Ossicles (ear bones):

Malleus (hammer);

Incus (anvil); and

Stapes (stirrup)

Middle ear (tympanic) cavity

Auditory (Eustachian) tube

Functions

- Vibrates, sending sound waves to the ossicles.

- Together, they act as tiny levers that transmit sound waves from the tympanic membrane in the middle ear to the oval window in the inner ear.

- An air-filled hollow through which sound waves pass.

- Regulates air pressure within the middle ear cavity.

Inner ear

Oval window

Semicircular canals or ducts

Cochlea

Round window

Auditory (acoustic) nerve

- Causes vibrations in the fluid of the inner ear.

- Help the body to balance.

- Contains the organ of Corti, which converts sound vibrations into nerve signals.

- Compensates for vibrations in the cochlea fluid.

- Sends nerve signals about hearing to the brain.

Ear "don'ts"

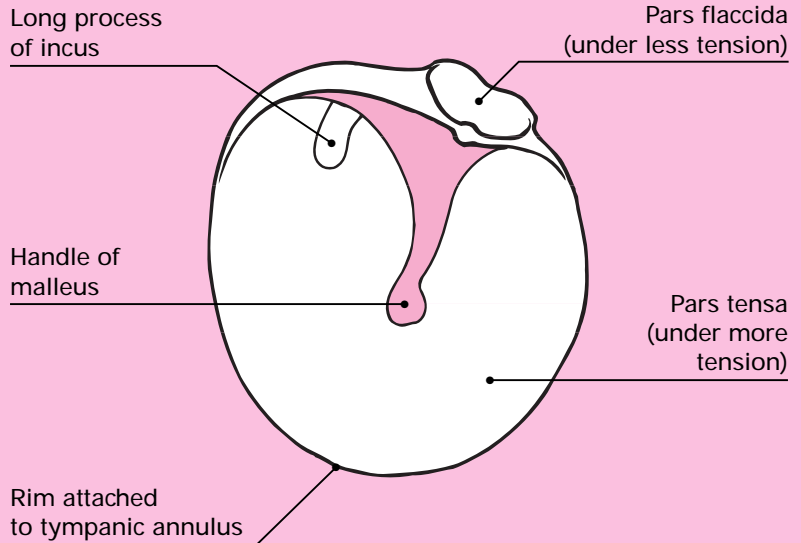
- Don't poke dirty fingers, pencils, hairpins, or any other objects into the ear canal.
- Don't clean your ears by forcing cotton tips or a washcloth into the ear canal.
- Don't try to swab out a discharging or infected ear.
- Don't syringe impacted wax at home.
- Don't allow water to remain in your ear canals after swimming.
- Don't put your head underwater if you have a blocked nose; the changes in pressure may cause considerable pain.
- Don't dive deeply into water from the surface.
- Don't neglect de-pressurizing routines when scuba diving.

- Don't expose yourself to loud music too frequently.
- Don't work without ear protection in an environment where you find the noise level uncomfortable.
- Don't turn up the volume of music beyond the normal level when listening through headphones.
- Don't neglect ear infection or earache.
- Don't blow your nose vigorously; anything other than gentle blowing may force bacteria up the auditory (Eustachian) tubes.
- Don't resist being fitted with a hearing aid from reasons of vanity or because you think it will age you; it is far more aging to appear deaf.

Eardrum

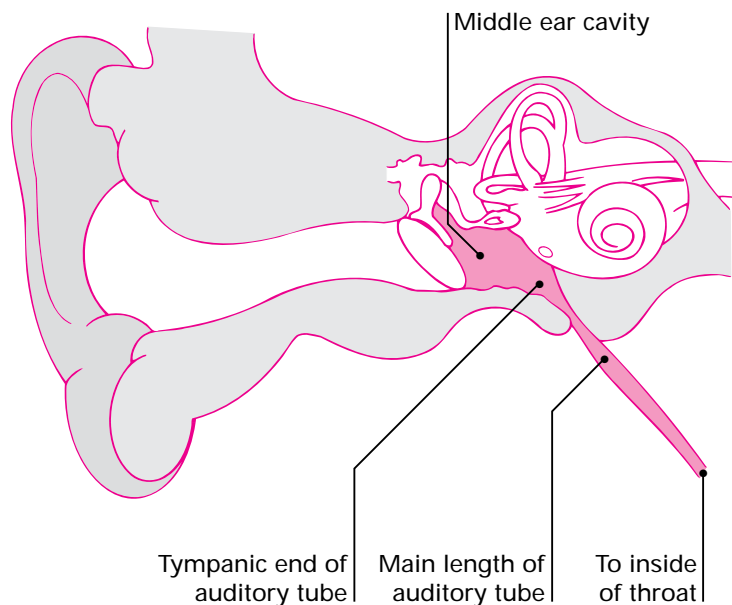
When viewed by looking into the outer ear canal, the eardrum appears as a thin, taut, hazy sheet of skin, approximately the area of the nail on the little finger. It has a plentiful blood and nerve supply and its main feature is the long, slim “handle” of the malleus or hammer bone—the ossicle on the other side of the eardrum. It shows up as a shadowy dark area. Around the eardrum is a ring of bone, the tympanic annulus.

External view of the tympanic membrane



Auditory (Eustachian) tube

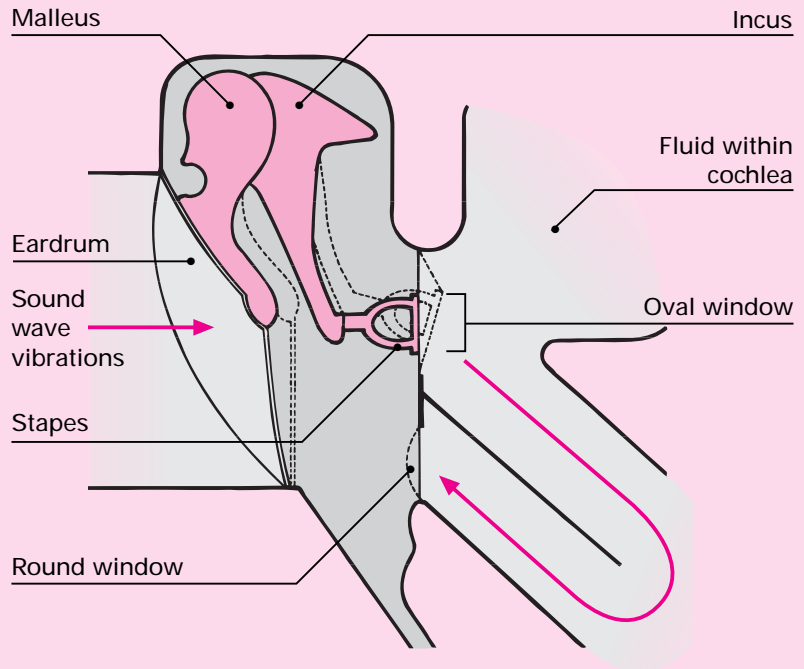
If the middle ear cavity were a sealed chamber, then as air (barometric) pressure altered outside with changes in weather, the eardrum would bend in or out. The auditory tube connects the middle ear cavity to the throat and so to the outside air. This allows air in and out, so that pressure can equalize on either side of the eardrum.



Ossicles and vibrations

The three tiny ear ossicles (bones) work as magnifying levers to transmit vibrations from the eardrum to the cochlea of the inner ear. As the vibrations pass via the thin flexible membrane of the oval window, into the fluid sealed within the cochlea, they try to compress and then expand the fluid. Another thin membrane, the round window, flexes to compensate for these vibrational waves and so keeps the pressure changes inside the cochlea to a minimum.

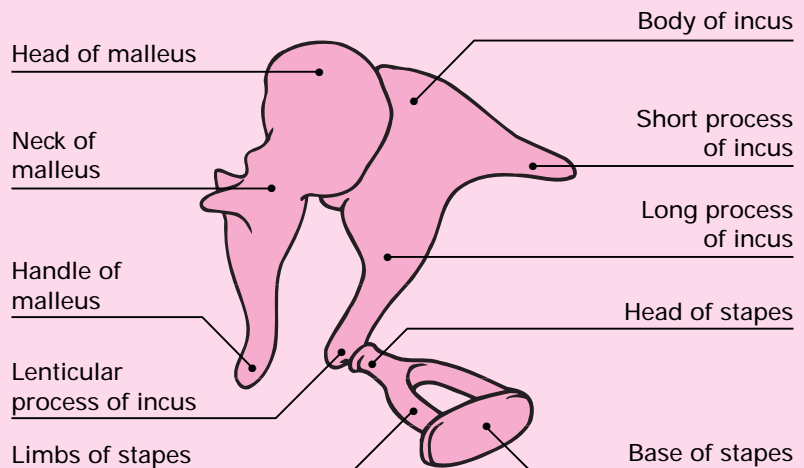
How vibrations are conducted and dissipated within the inner ear



Auditory ossicles

These are the smallest bones in the body. However they have the same detailed structure as larger bones, including blood and nerve supplies. The handle of the malleus joins to the eardrum, while the base of the stapes touches the oval window. The malleus-incus and incus-stapes joints also have the same structure as larger joints.

Auditory ossicles in position

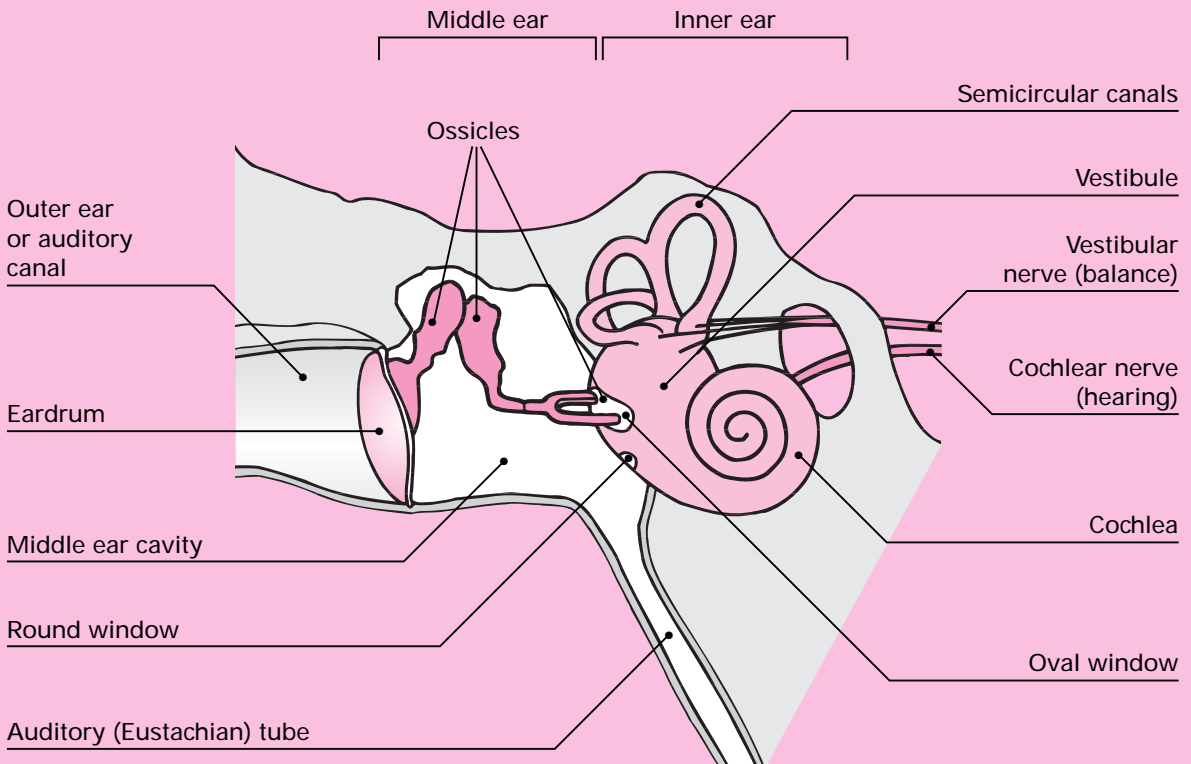


Parts of the inner ear

The main component of the inner ear is the cochlea, a snail-shaped tube about the size of a sugar cube. It is set within a similarly shaped cavity inside the temporal bone. It is continuous with a wider chamber, the vestibule, which consists of the utricle and saccule. In turn the utricle connects to the three C-shaped semicircular canals or ducts.

The utricle, saccule, and semicircular canals form part of the sense of position and balance. They send their nerve signals to the brain along the vestibular nerve. The cochlea is concerned with hearing and its nerve signals travel to the brain along the cochlear nerve. These two nerves join to form the vestibular-cochlear or auditory nerve.

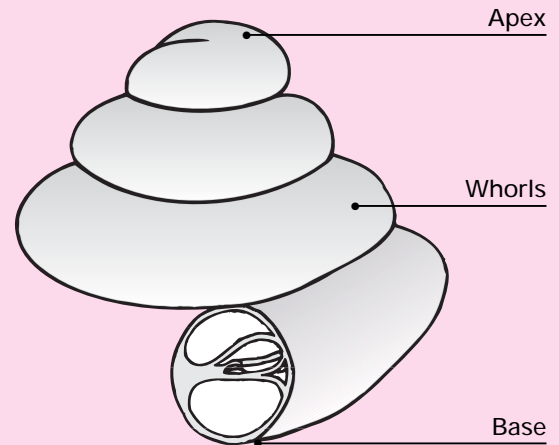
Schematized coronal section through the ear



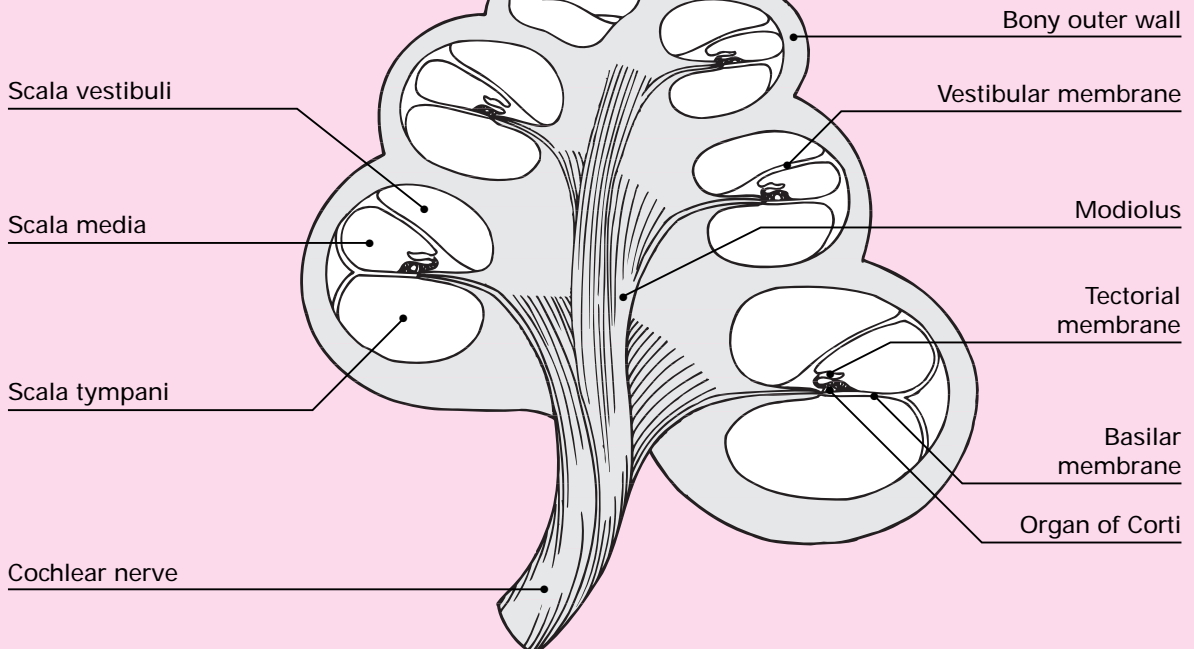
Features of the cochlea

The cochlea has about two-and-three-quarters turns from its wide base to its narrow point or apex. Inside are three chambers filled with fluid. The two outer chambers, scala vestibuli and scala tympani, contain perilymph. The central chamber, scala media or cochlear duct, contains endolymph. The floor of the scala media contains the organ of Corti, where sound vibrations are converted into nerve signals. The central "hub" of the spiral, around which these ducts twine, is the modiolus. The stages in hearing are shown on the following pages.

View of cochlea from below



Section through the cochlea



Receiving sound waves in the outer ear

Sounds arrive at the ear as “waves” of alternating high and low air pressure. The faster the vibrations, measured in Hertz—frequency Hz, or numbers of waves per second—the higher the pitch of the sound. The “taller” the waves, in terms of high and low air pressure, the louder the volume of the sound.

Outer ear flap

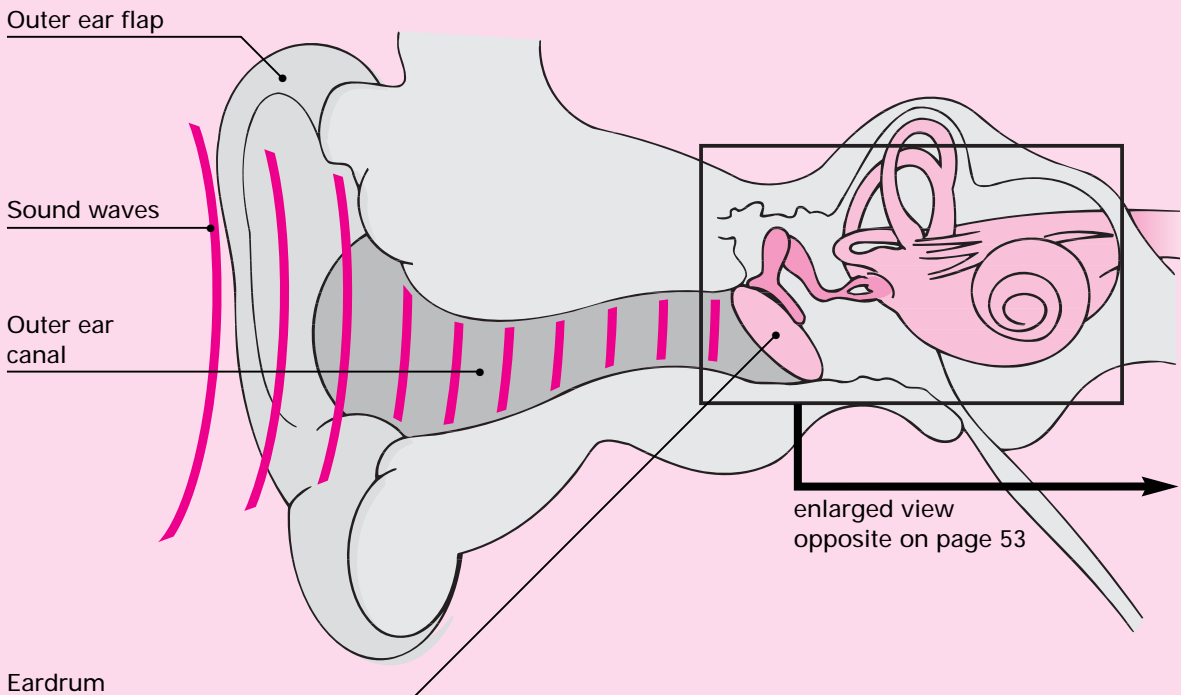
The sound waves are gathered by the funnel-shaped ear flap (auricle or pinna).

They are concentrated into the concha or opening of the outer ear canal (external auditory meatus).

Ear canal

The outer ear canal is slightly S-shaped and about one inch (25 mm) in length. It is lined with skin and hairs, and small glands that produce a waxy substance. The hairs and wax help to trap particles of dust, dirt, and encroaching insects. The wax regularly flakes away and works itself out of the canal with movements of the jaw just below.

Path of sound vibrations



Sound in the middle ear

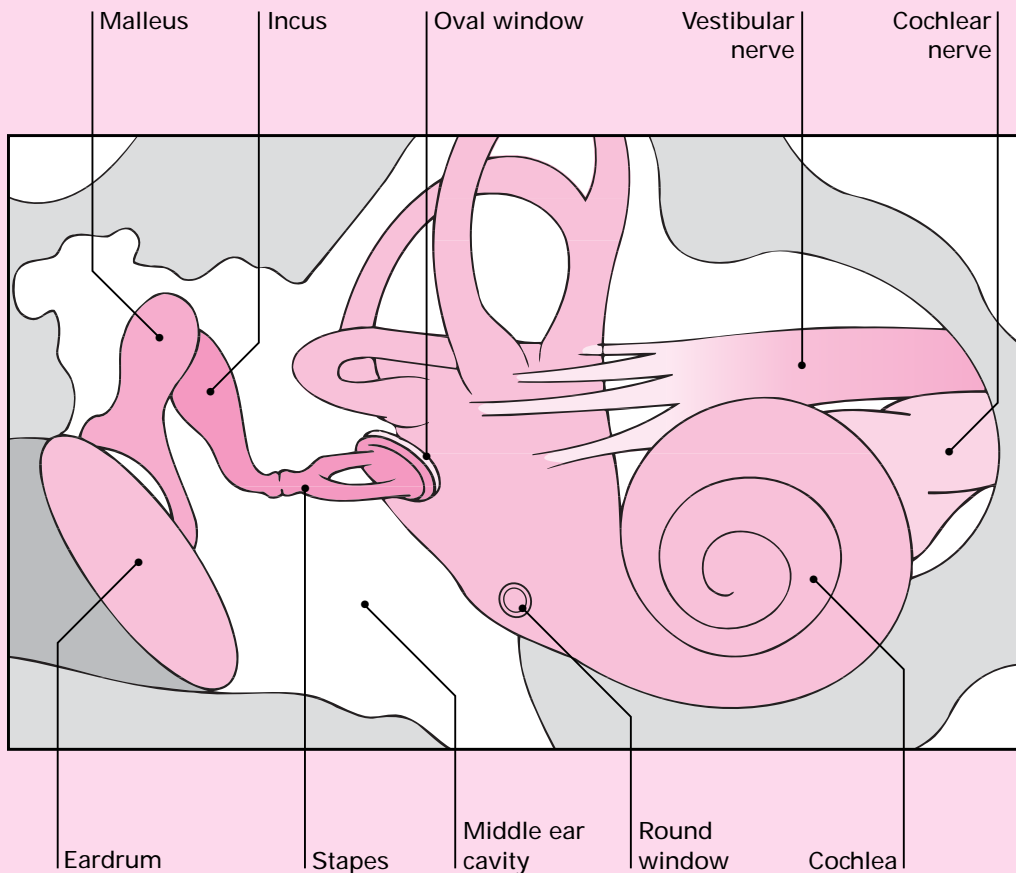
Eardrum

Sound waves are converted from vibrations (changes in pressure) in air, in the outer ear, to vibrations in solids, in the middle ear. The taut and flexible eardrum vibrates as the pressure waves bounce off it, and sets in motion vibrations along the chain of ossicles.

Ossicles

Transfer of vibrations along the three ear ossicles is extremely efficient, at more than 90 percent. The last ossicle, the stapes, vibrates the oval window of the cochlea, and from here the vibrations change into pressure changes within liquid, as described overleaf.

Enlarged view of the middle and inner ear



Pressure inside the cochlea

1 The oval window moves in and out as the ossicles (tiny bones) transfer sound waves from the eardrum.

2 As the oval window bulges outward, it pushes the perilymph (fluid) of the vestibular canal up into the cochlea.

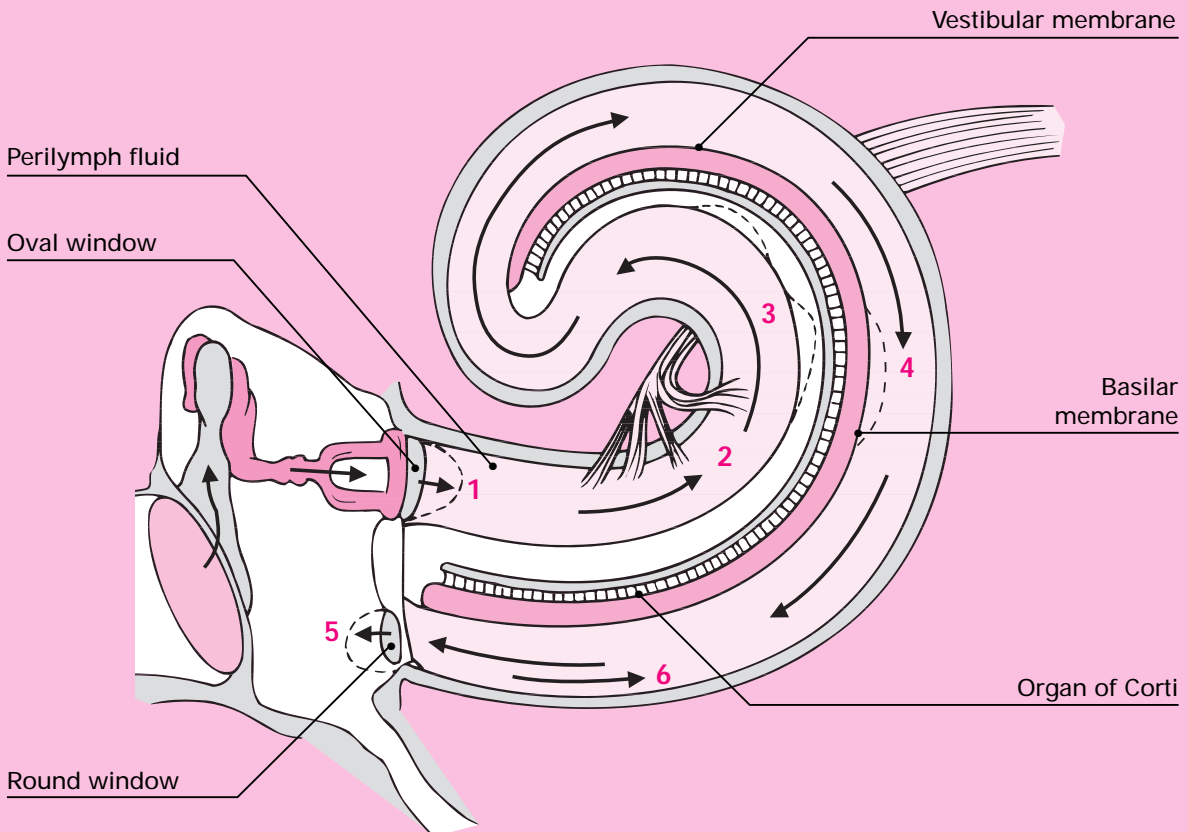
3 Increased pressure pushes the vestibular membrane inward. This increases pressure inside the middle chamber of endolymph fluid, the scala media or cochlear duct.

4 This causes the basilar membrane to bulge out further along the cochlear duct.

5 This pushes the perilymph toward the round window so that it bulges back into the middle ear cavity.

6 When the sound waves subside, the flow of fluid is reversed, and it travels back toward the oval window. (Arrows show the direction of the waves.)

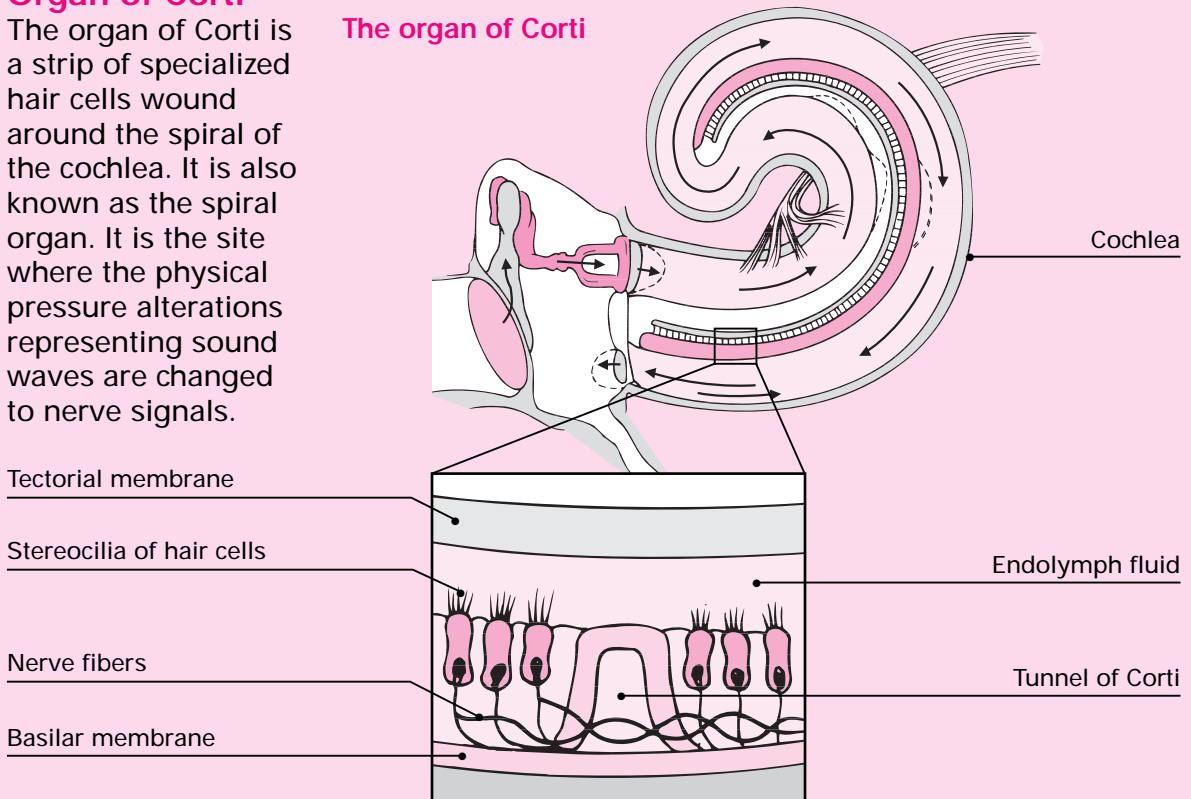
Pressure changes inside the cochlea



Organ of Corti

The organ of Corti is a strip of specialized hair cells wound around the spiral of the cochlea. It is also known as the spiral organ. It is the site where the physical pressure alterations representing sound waves are changed to nerve signals.

The organ of Corti



How the organ of Corti works

Vibrations pass from the stapes bone into the fluids within the cochlea, where they travel as ripples of pressure. These ripples cause the cochlear membranes to vibrate and undulate. The hair cells have numerous tiny hairs, stereocilia,

projecting from their tips into the tectorial membrane above. As the basilar and tectorial membranes undulate the stereocilia of the hair cells are bent and rocked, and the cells are stimulated to generate nerve impulses.

Inner hair cells

- There are about 3,500 inner hair cells.
- They are arranged in a row, nearest the modiolus (central axis of the cochlea).
- Each inner hair cell has about 50 to 60 stereocilia at its tip.

Outer hair cells

- There are about 15,000 outer hair cells.
- They are arranged in three to five rows, farther from the modiolus than inner hair cells.
- Each outer hair cell has up to 100 stereocilia at its tip.

Common ear problems

The illustration on the right shows some of the common problems that may develop in the ear (see also page 58).

1 Hairy ears; these occur particularly in men, and a tendency toward them may be hereditary. If you are worried about the condition, visit your doctor.

2 Discharging ear; this is always a sign that something is wrong with the ear. The only material that the ear naturally secretes is wax. If the ear has a watery, bloody, or infected discharge, see your doctor. Never plug a discharging ear as this may drive the infection deeper.

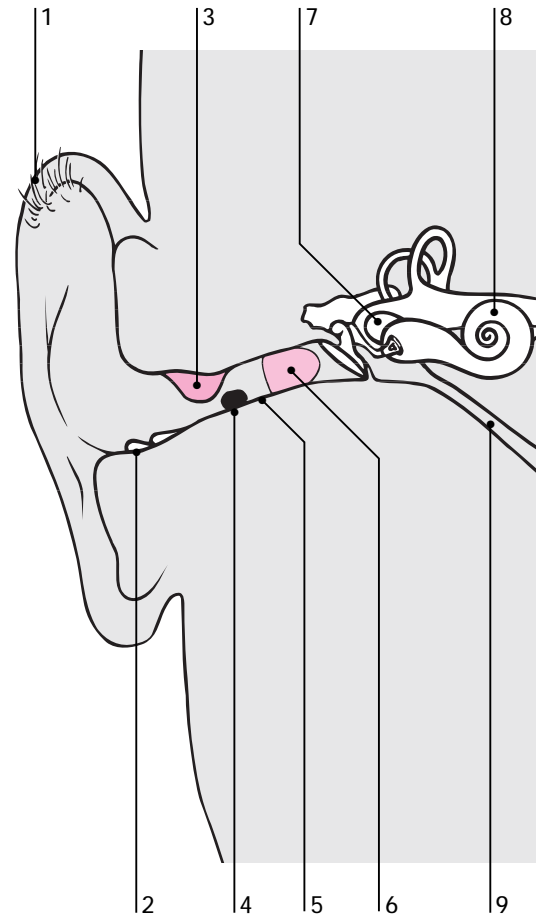
3 Boil inside the ear; this condition is often the result of scratching the ear with a dirty fingernail, hairpin, or similar item, and can be very painful. A warm compress may ease the pain, but you should seek a doctor's advice so that the infection does not spread.

4 Foreign body inside the ear; children are especially prone to pushing peanuts, beads, and other small objects into the ear, which become lodged. Take the child to a doctor; attempts to remove the object yourself may force it further into the ear.

5 Otitis externa; this is an infection of the outer ear. Ear infections that develop after swimming, perhaps as a result of inadequate drying, are usually otitis externa.

6 Impacted wax; the ear usually cleans itself of its natural wax through the movements of chewing and talking, but occasionally wax becomes impacted. Contributing factors in this problem may

Front view of section through the ear



include dust, dry air, and probing in the ears with the fingers. The ear needs to be syringed with warm water to dislodge the obstruction, but this should only be done by a nurse or doctor rather than at home.

7 Otitis media; an infection of the middle ear. This condition is very painful, and requires a doctor's attention as there is a severe risk of the eardrum being perforated if the infection continues unchecked.

8 Inner ear infection; this may also be an excruciatingly painful and potentially serious condition. When the inner ear cavity, or labyrinth, is inflamed, deafness, disturbance of balance, and

vomiting occur. Hearing impairment and balance disturbance may become permanent if the condition is not properly treated.

9 Auditory (Eustachian) tube infection; bacteria or other microbes found here may have traveled down from the ear or up from the throat. In either case the ear will be affected and pain will result as the pressure behind the sensitive eardrum is altered (see below).

More common ear problems

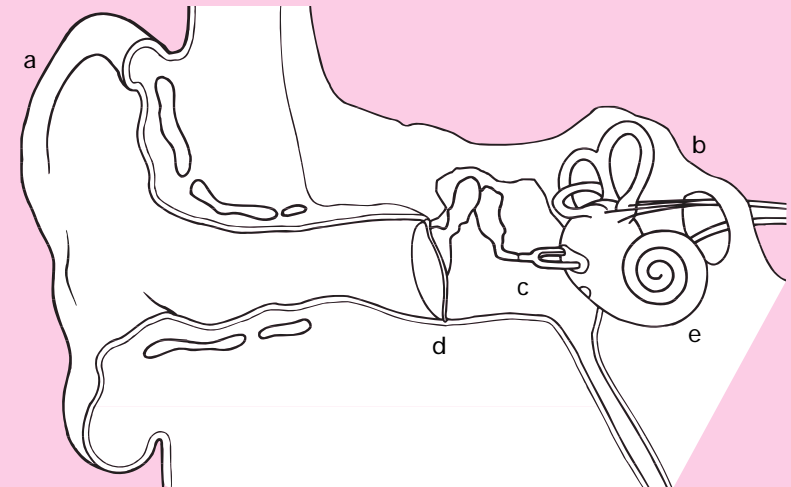
Deafness is the inability to hear. It can be total or partial and can be caused by a variety of factors including diseases such as otosclerosis; blockage of the ear canal by wax; damage to the eardrum; damage to the bones of the middle ear; and damage to nerves that take messages from the ear to the brain. Otalgia is the general term for any form of earache (see next page). Tinnitus is a ringing or buzzing sound in the ears, which has numerous causes.

a Cauliflower ear

Condition in which the tissues of the ear flap (pinna) are misshapen due to damage.

b Menière's disease

Fluid accumulates in the inner ear, causing deafness,



vertigo, and tinnitus. The cause of the fluid increase is not usually known.

c Otosclerosis

The immobilization of the stapes bone in the middle ear, usually caused by the excess bone tissue forming around the oval window. Untreated, otosclerosis may result in

progressive levels of deafness.

d Perforated eardrum

A tear or erosion of the eardrum, often resulting from middle ear infection.

e Presbycusis

Loss of hearing with age, caused by deterioration of the hair cells in the cochlea.

Earache

Earache often arises from an infection. The infection may be the result of a scratch or boil in the external canal of the ear, or a bacterial invasion of the middle ear, the drum, or the auditory (Eustachian) tubes (see previous pages). Infected adenoids, a head cold, allergies, and even toothache may also cause earache. A pain-relieving medication and a warm pad or compress may ease the pain, but if the ache persists see a doctor. Neglect may result in perforation of the eardrum and possible permanent deafness.

Pressure

The ears are very sensitive to changes in pressure, such as those experienced when going up or down in an elevator or airplane. The discomfort caused in these circumstances, which makes the ears feel as though they are blocked, can often be relieved by yawning, swallowing, or chewing. Pressure on the ears underwater can sometimes be painful. If you are diving in from the surface you should avoid going too deep. Scuba divers should follow the correct drills for slowly adjusting the pressure in the ears.


Noise

Noise is a widespread but little recognized hazard, and can cause permanent loss of hearing. Industrial noise is controlled by law, but if you feel that these laws are not being enforced where you work, or that your hearing is being impaired at work, ask to have the noise level assessed. Industrial ear-plugs should be provided and worn if the noise level is higher than recommended. Music is often an unexpected source of ear damage; avoid too-frequent exposure to loud music at concert, club, and dance venues.

Swimming

One of the most common ear problems associated with swimming is "swimmer's ear," an infection of the outer ear that relies on a moist surface to develop. If you are prone to swimmer's ear, wear earplugs made of waxed lambswool or a similar material while in the water. Dry your ears thoroughly with a soft towel after swimming. If water is trapped in your ear, lie on your side until the water

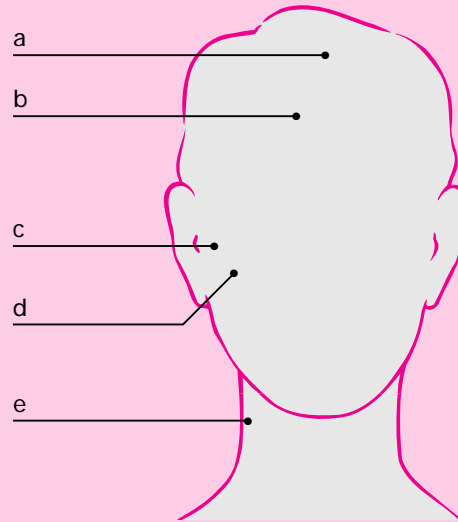
runs out. Other common ear problems for swimmers are usually related to changes in pressure when underwater (see above).



Complications of ear problems

The diagram shows the sites of some of the common complications of ear problems.

- a** Headache; this may occur during infection because of bacterial poisons and subsequent inflammation.
- b** Vertigo is caused by a disturbance of the balance center in the inner ear.
- c** Temporary or permanent deafness may result from ear infection or its consequent damage.
- d** Blocked auditory (Eustachian) tubes; these occur when an infection reaches the tubes linking the ear to the throat.
- e** Swollen lymph nodes; these may occur in the neck when the ear is infected.



Ear care

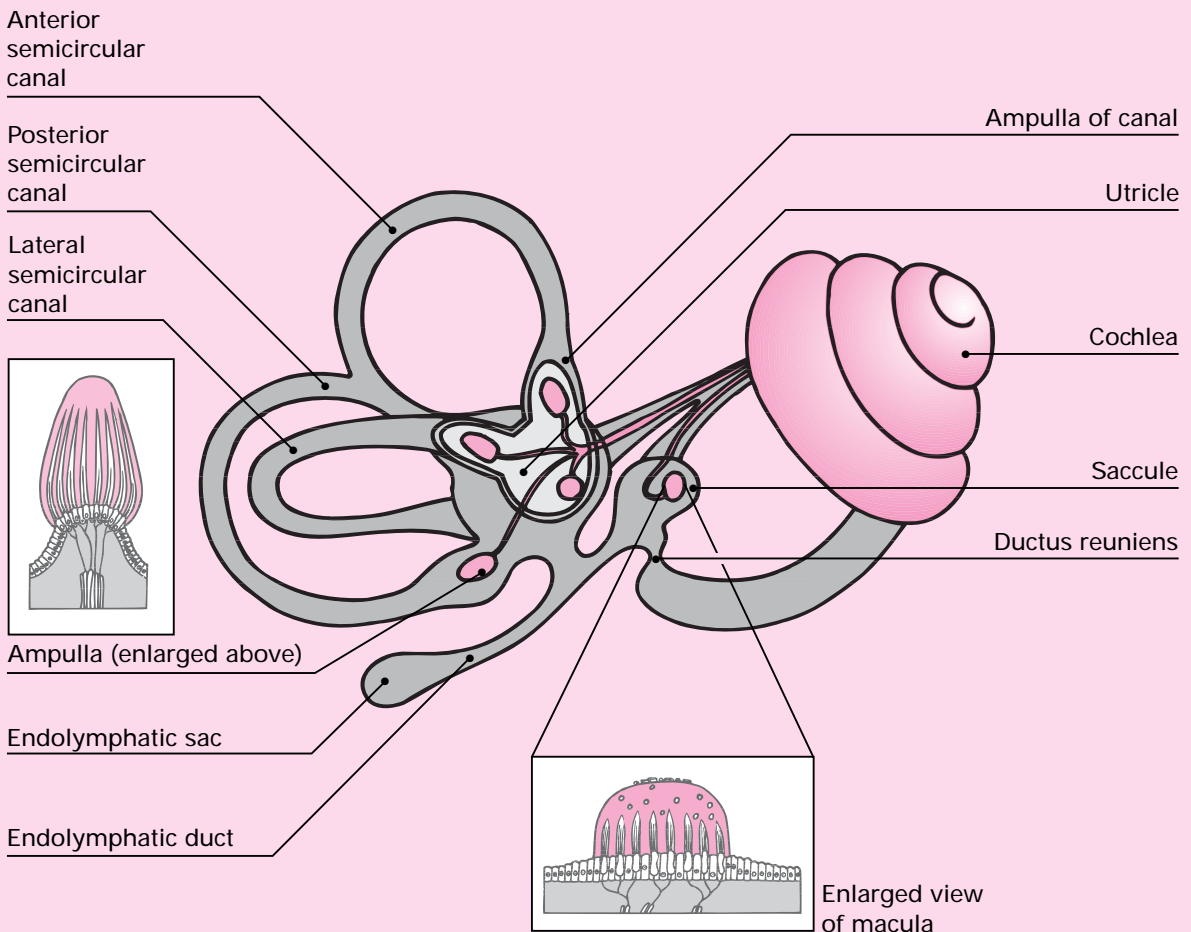
- Clean your ears gently with a clean, warm washcloth daily.
- Visit your doctor if you have a discharge of any kind from your ear, or if you have an object lodged in your ear canal.
- Wear specially-made earplugs while swimming if you suffer from ear problems. Remove the plugs when you leave the water so that the skin lining the ear canal can start to dry out. If it remains moist and unventilated then bacteria can thrive.
- Dry your ears thoroughly after swimming, and drain out any water lodged deeper in the ear.
- Have your hearing tested regularly.
- Visit your doctor as soon as possible if you feel that your hearing is impaired in any way—for example, if you strain to hear the radio, television, or music system compared to others in the room.
- Wear industrial earmuffs if you work in a place with a high noise level or in dusty surroundings with floating particles in the air.
- See your doctor if you have a severe earache or one that has persisted for more than a few hours.
- Watch for warning signs of ear trouble if you have sinusitis, a head cold, or severe allergy symptoms.
- Have your ear professionally fitted with a hearing aid if you suffer from partial deafness.

The vestibular apparatus

The ear contains not only the sensory parts for hearing, but also the parts that sense equilibrium, head position, and head movements—thereby contributing to the process of balance (see pages 61–63). The vestibular apparatus is concerned with sensing head position and motion. Its chief components are

two chambers, the utricle and saccule, and the three semicircular canals or ducts. All of these contain fluid and are surrounded by bone. The saccule links to the base of the cochlea on one side and the utricle on the other; the utricle links to the three semicircular canals.

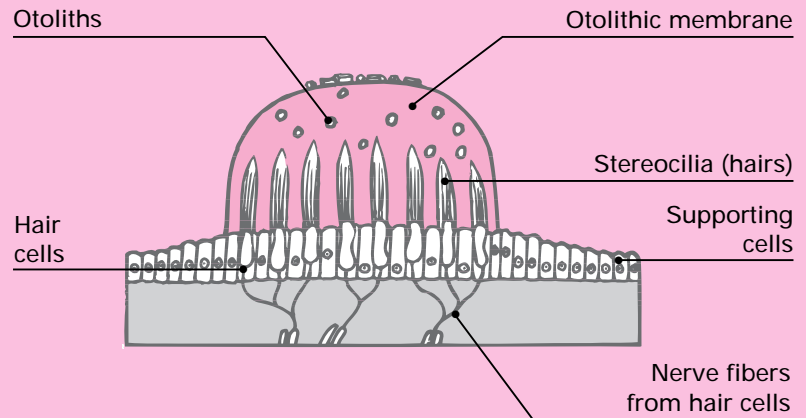
Schematized cutaway section through the vestibular apparatus



Macula

The utricle and saccule each contain a sensory region called the macula. This has a patch of hair cells, similar to those in the cochlea, covered by a jelly-like otolithic membrane, on which are scattered tiny mineral crystals, otoliths (otoconia). When the otoliths roll, as a result of changes in the pull of gravity, the hairs bend, and their cells produce nerve messages (see page 62).

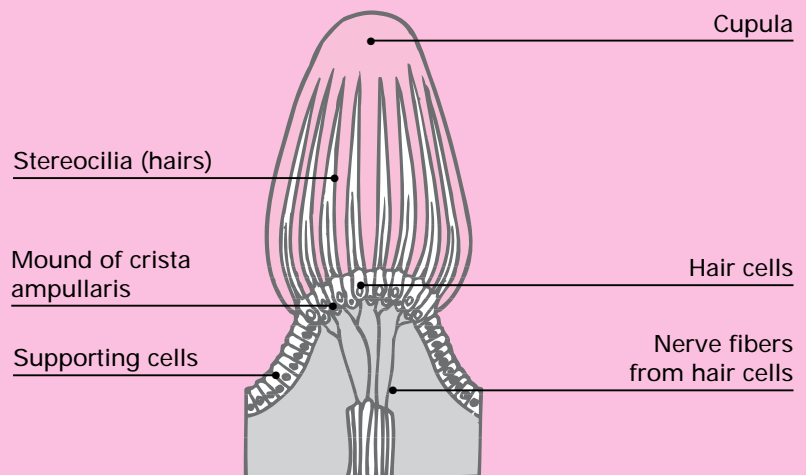
Schematized section through macula of saccule



Crista ampullaris

Each semicircular canal has a bulge at one end, the ampulla. This bears a patch of sensory hair cells (see above) situated on a mound, the crista ampullaris. The tiny hairs of the hair cells project into a jelly-like, dome-shaped mass, the cupula. The sides and tip of the cupula brush against the walls of the ampulla, so that together, crista and cupula almost block the passage. However they can flex to allow fluid past (see page 62).

Schematized section through crista ampullaris




What is balance?

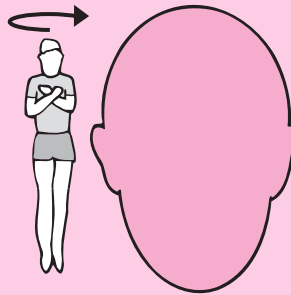
Balance is sometimes regarded as one of the main senses. In fact, it is an ongoing process or mechanism, using sensory information from several sources including the skin, the eyes, proprioceptors in muscles and joints, and the vestibular apparatus. The three semicircular canals are set at right angles to each other and filled with fluid, endolymph. As the head moves, the fluid in at least one of the canals

gradually starts to flow, like water in a tumbler when the tumbler is turned. In this way the three canals detect head movements, or dynamic equilibrium. (Details of this process are shown below and opposite.) The maculae of the utricle and saccule, shown on page 60, are gravity sensors and involved in static equilibrium. They sense the position of the head relative to the pull of gravity.

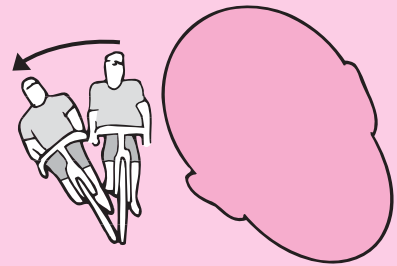
Forward movement



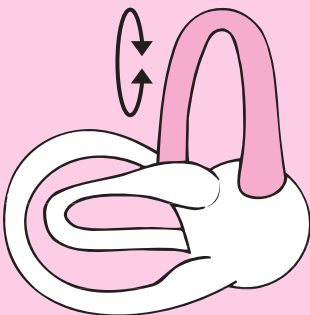
Sideways movement



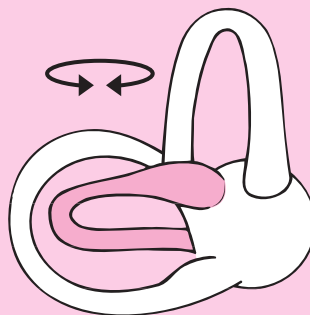
Tilting movement



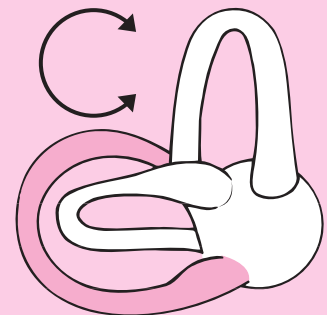
Superior semicircular canal



Lateral semicircular canal



Posterior semicircular canal



Semicircular canals and movement

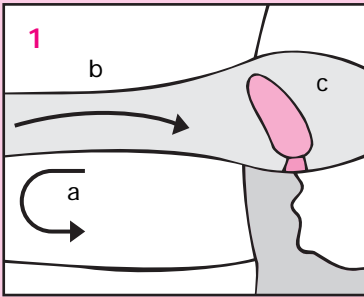
Different movements of the body affect different semicircular canals. The semicircular duct that lies at right angles

to the axis of rotation sends messages to the brain that inform it about the direction of movement of the head.

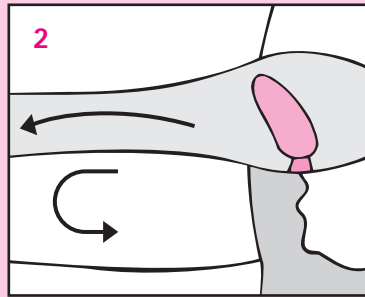
How the cristae and cupulas work

The semicircular canals are C-shaped, each with a bulge or wide chamber at one end, called the ampulla (see pages 60–61). Almost filling the ampulla is the jelly-like cupula, sitting on its mound of the crista ampullaris. Together these two parts, in effect, work like a flap or swing door. They almost block the flow of fluid past them, but can also bend to allow this flow, as the head moves and the fluid moves too. Nerve signals from the

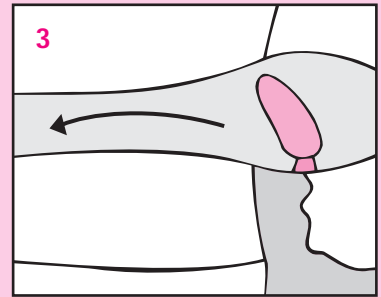
hair cells in the three ampullae and the two maculae pass along the vestibular nerve. This contains about 19,000 nerve fibers. It joins to the cochlear nerve, which carries nerve signals relating to hearing. The two nerves together are known as the vestibulocochlear or auditory nerve (cranial nerve VIII, see page 13). This conveys the nerve signals about hearing and balance to many parts of the brain.



1 The head starts to rotate—for example, to the left (a). Endolymph fluid (b) in the affected semicircular canal lags slightly behind the movement of the canal itself. This displaces the cupula (c). The hair cells are stimulated by bending. Nerve fibers leading from them send the information to the brain, which interprets it as the head rotating to the left.



2 When the initial inertia is overcome, the endolymph moves with the head and the cupula is no longer displaced. This occurs if the head moves at a steady rate, so the hair cells are not bent, and therefore no longer stimulated to produce nerve signals. Any change in the rate of head movement, such as faster rotation, causes the cupula to bend again and so produces signals.



3 When prolonged movement of the head ceases, the endolymph continues moving, in the same way that water in a spinning cup continues to rotate when the cup stops. This displaces the cupula in the opposite direction. Hair cells are bent and send messages to the brain, telling it that the head is moving. This results in the temporary feeling of movement in the opposite direction.

Smell and taste are often referred to as the chemosenses. They detect chemical substances, whether floating in air, or in foods, drinks, and other items and materials taken into the mouth. There are many parallels between the ways that these two senses function. At their basic level both smell and taste rely on millions of microscopic hair cells. The cells are stimulated to produce nerve signals when the hairs or cilia projecting from them come into physical contact with specific chemicals.

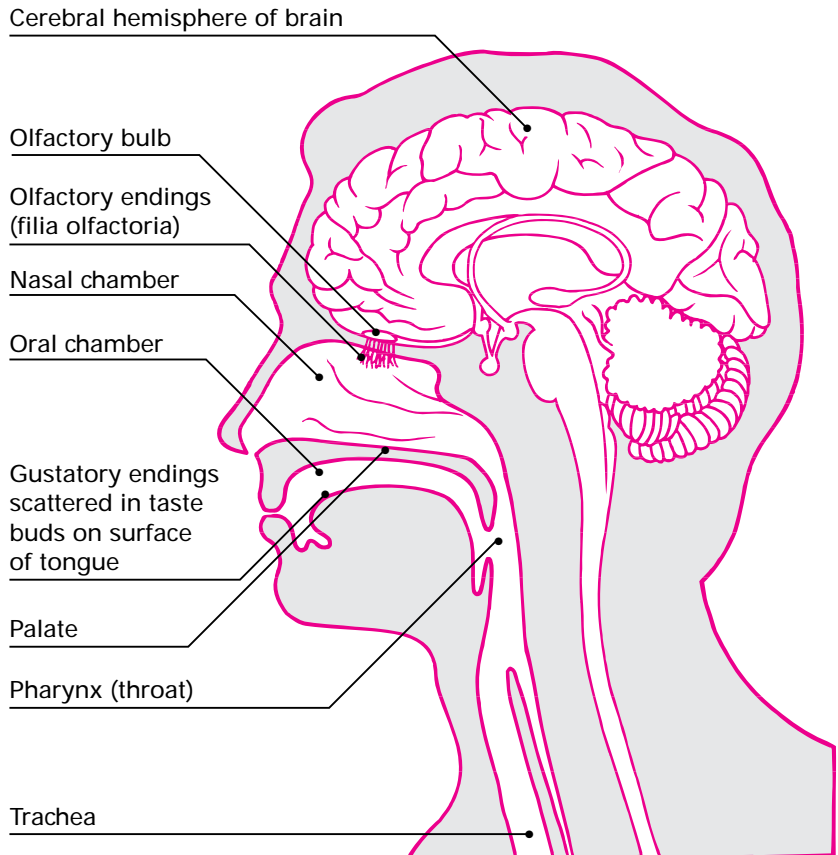
More and less sensitive

- Smell is usually regarded as more sensitive and delicate than taste.
- Estimates vary, but some authorities regard smell as 20,000 times more sensitive than taste, especially in concentrations detected.

Inside the nose and mouth

Smell and taste each have their own air-filled compartments within the head. The nasal chamber or cavity behind the external nose bears the sensory equipment for smell, or olfaction, in its upper surface or roof. The oral cavity or chamber contains the primary organ of taste, or gustation—the tongue—on its floor. Some taste sensations also come from the gums, insides of the cheeks, mouth lining, and upper throat.

Section through the head showing nasal and oral chambers



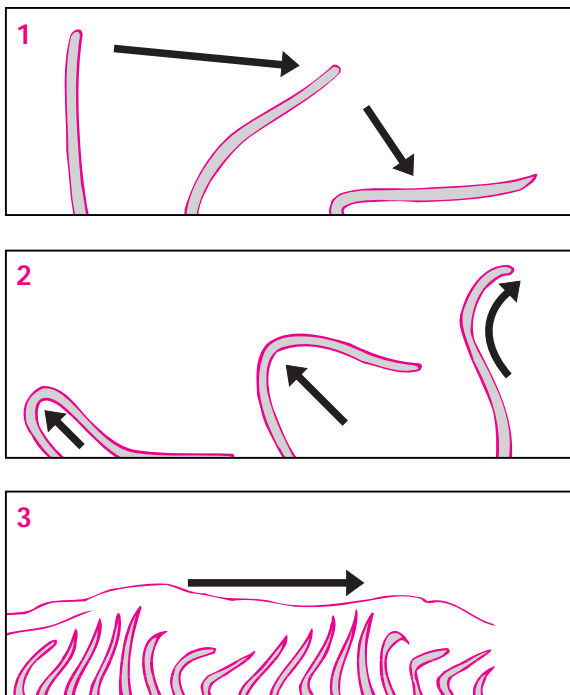
Sensory cilia

Cilia appear as tiny, hairlike fronds on the hair cell's exposed surface. Sensory cells for smell and taste have varying numbers of hairs or cilia, from five to more than 100 per cell, depending on the cell's position.

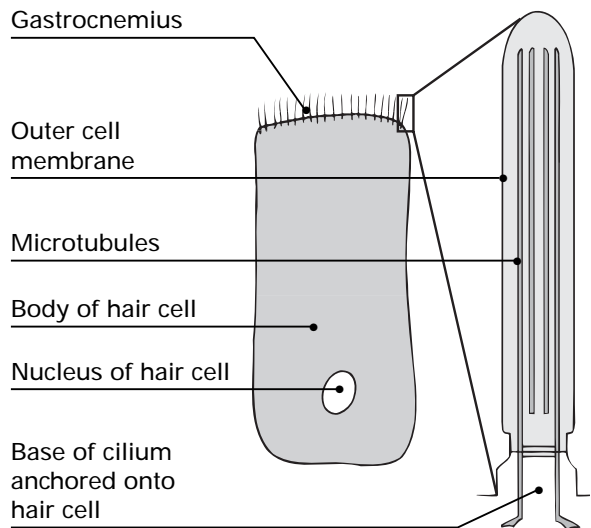
Functions

The sensory hair (cilia) of smell and taste cells may have large numbers of different-shaped, molecule-sized receptor sites on their surfaces. Different chemical substances slot into these, like keys in locks, and stimulate the cell to make nerve signals. (For further theories on this process see page 71.)

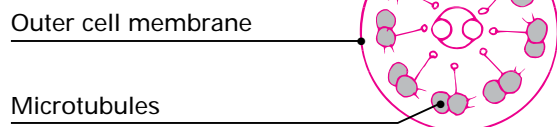
Ciliary motion



Cilia structure



Cross section through cilium



Ciliary structure and motion

Each cilium is made of bundles of microtubules (tiny tubes) covered by the cell's outer cell membrane. Each cilium can flex at various points along its length, with a power stroke to drive material along, followed by a weaker recovery stroke.

1 Power stroke.

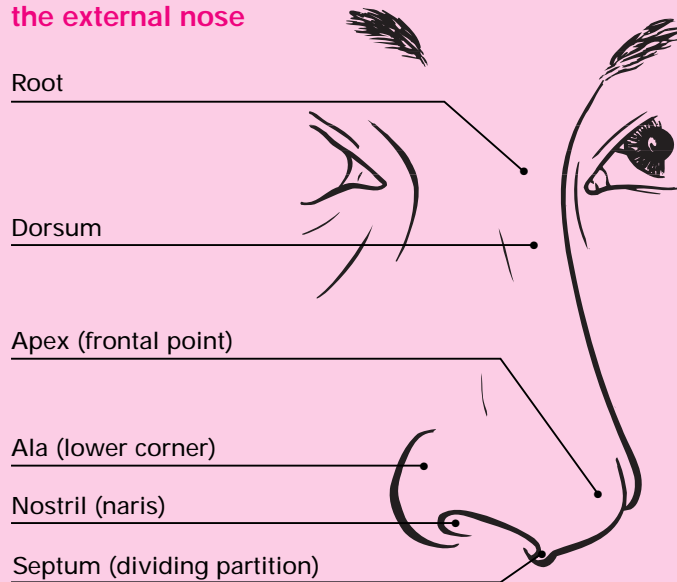
2 Recovery stroke.

3 Direction of propulsion of substance (for example, mucus in the nose) by wavelike ciliary motion.

External appearance of the nose

The nose is a pyramidal projection of cartilages, ringed by bones of the skull, and covered with fatty layers and skin. The gaps through which respired air passes in and out of the nasal chamber are known as nostrils or nares. Muscular tissues around the nose can widen or flare the nostrils to allow extra air intake, when the body is very active or when sniffing the scent of a substance.

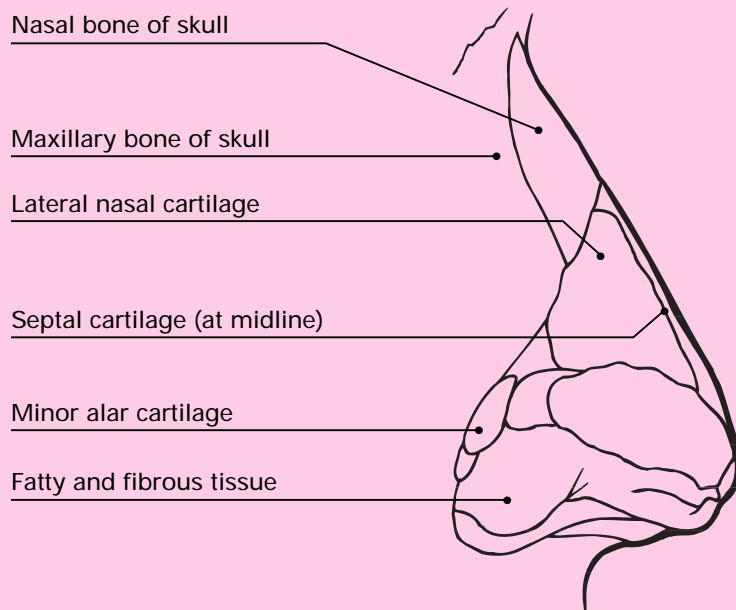
Anterolateral view of the external nose



Nasal cartilages

The nasal cartilages usually number about nine, although they vary in size and shape between individual people. The septal cartilage is the largest and extends from the dorsum or midline, rearward into the nasal chamber, partitioning it into two halves. On either side of the septal cartilage are main lateral cartilages above, and major alar cartilages below. Behind each major alar cartilage are one or two minor alar cartilages.

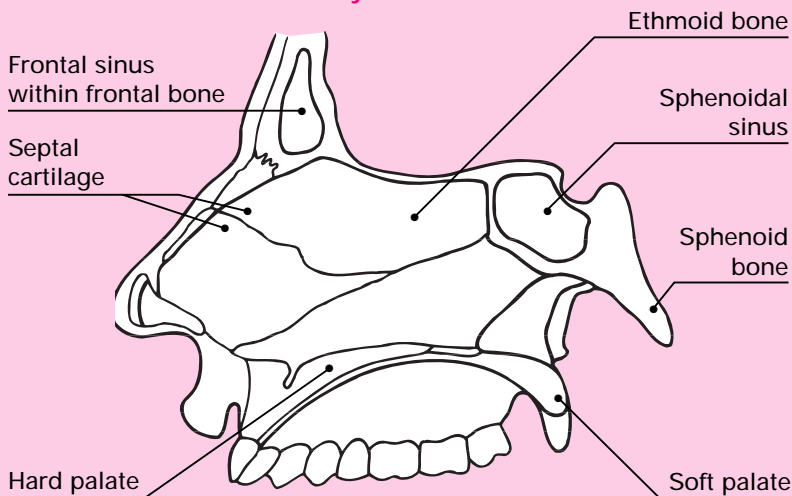
Lateral view of nasal cartilages



Inside the nose: associated air spaces

Sets of air spaces known as paranasal sinuses branch to the left and right, off the main nasal chamber. The opening to each sinus widens into the sinus proper, which is set within the thickness of a skull bone. The four main pairs of sinuses are the frontal sinuses above the brows, ethmoidal and sphenoidal sinuses on either side of the nose, and maxillary sinuses in the cheek region.

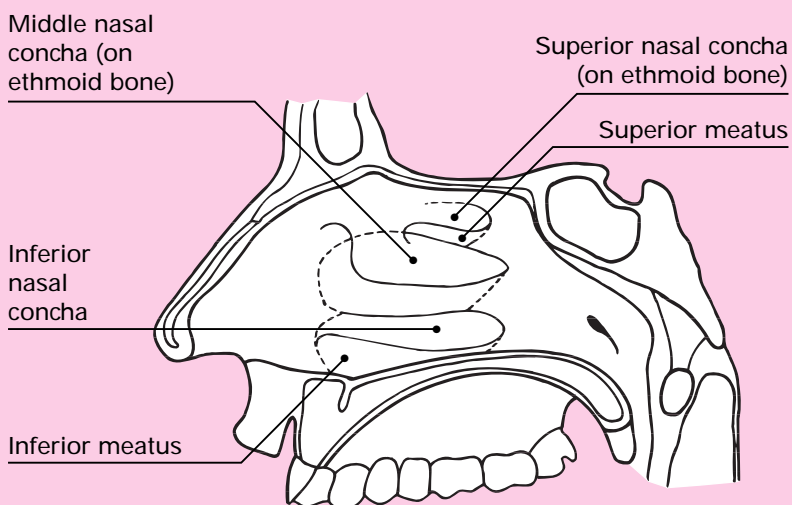
Lateral wall of nasal cavity



The nasal cavity

The cavity is divided in two by the large septal cartilage, which forms the medial or inner wall of each side. Each lateral or outer wall consists of two skull bones, the ethmoid above and the inferior nasal concha below. The ethmoid bone has two curved shelflike projections, turbinates or conchae, while the inferior nasal concha has one. These projections are covered with blood-rich nasal lining which warms and humidifies incoming air.

Lateral wall of nasal cavity: nasal conchae partially removed

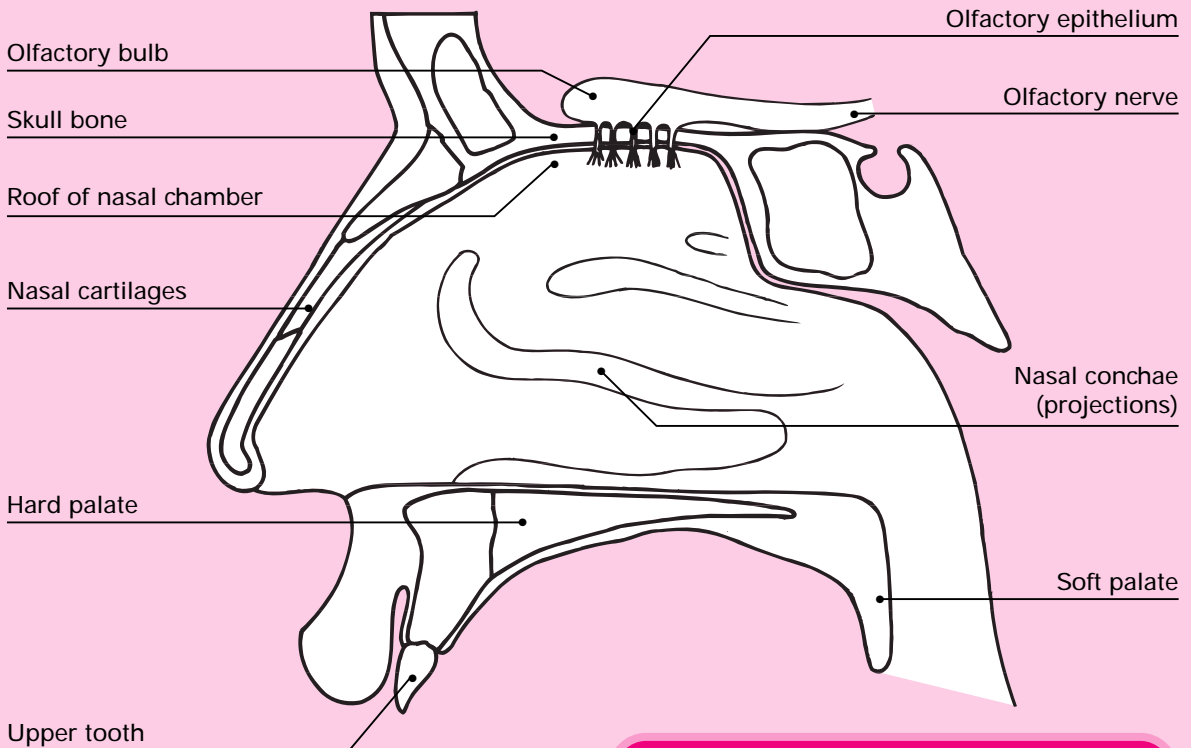


Olfactory epithelia

In the roof of each side of the nasal chamber is a patch of velvet-like lining about the size of a thumbnail, called the olfactory epithelium. The fuzzy surface is composed of millions of hair cells with their micro-hairs (see Sensory cilia on page 65). Each patch of olfactory hair cells, left and right, connects via many

nerve fibers to a rounded enlargement of nerve tissue just above, termed the olfactory bulb. This is, in turn, the expanded ending to one of the two olfactory nerves. These are short major nerves that convey nerve signals concerning smell to the brain just behind.

Sagittal section through the nasal cavity



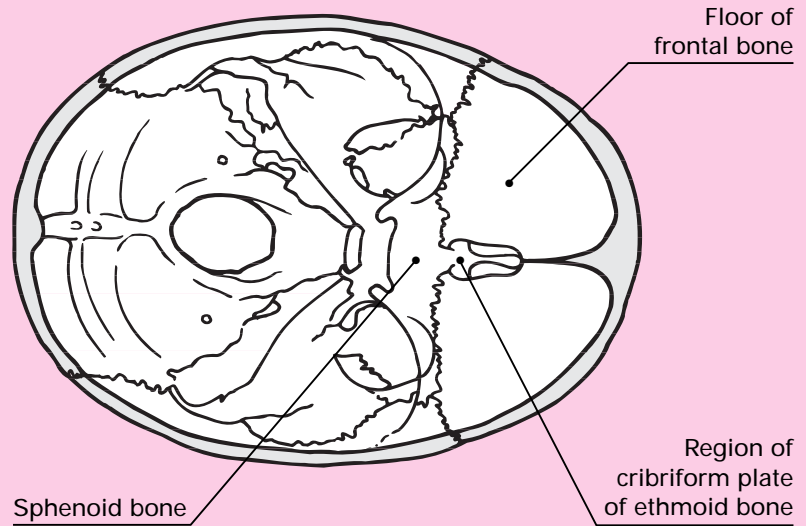
Millions of olfactory cells

- In a human each of the two olfactory patches, left and right, has more than 10 million receptor (or hair) cells.
- In some dogs this number is 250 million.

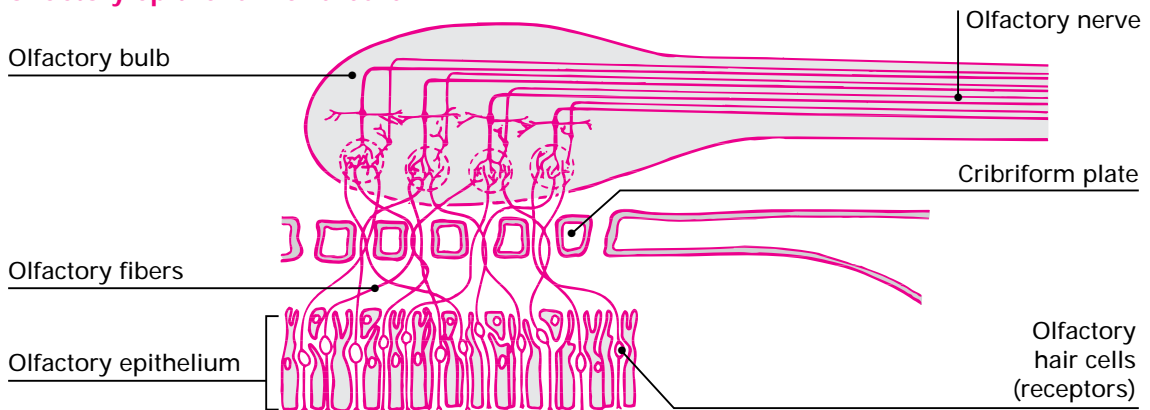
Cribriform plate

The cribriform plate is a small, thin patch of bone that separates the olfactory epithelium below, with its millions of smell-detecting olfactory hair cells, from the olfactory bulb above. The plate is pierced by many small holes or foramina, through which pass the nerve fibers (axons) of the hair cells. These olfactory fibers are among the shortest nerve fibers of the major senses, and also conduct nerve signals very slowly.

Internal view of skull from above



Schematized connections between olfactory epithelium and bulb



Nerve connections

Nerve signals from the olfactory hair cells, or receptors, pass directly into the olfactory bulb. Here numerous

interconnections, or synapses, "pre-sort" the signals before sending them to the brain (see next page).

How smells are detected

1 Scent particles, known as odorants, enter the nose in inspired air and pass into the nasal chamber.

2 Some of the particles land on the smell receptor sites of the micro-hairs projecting from the olfactory hair cells.

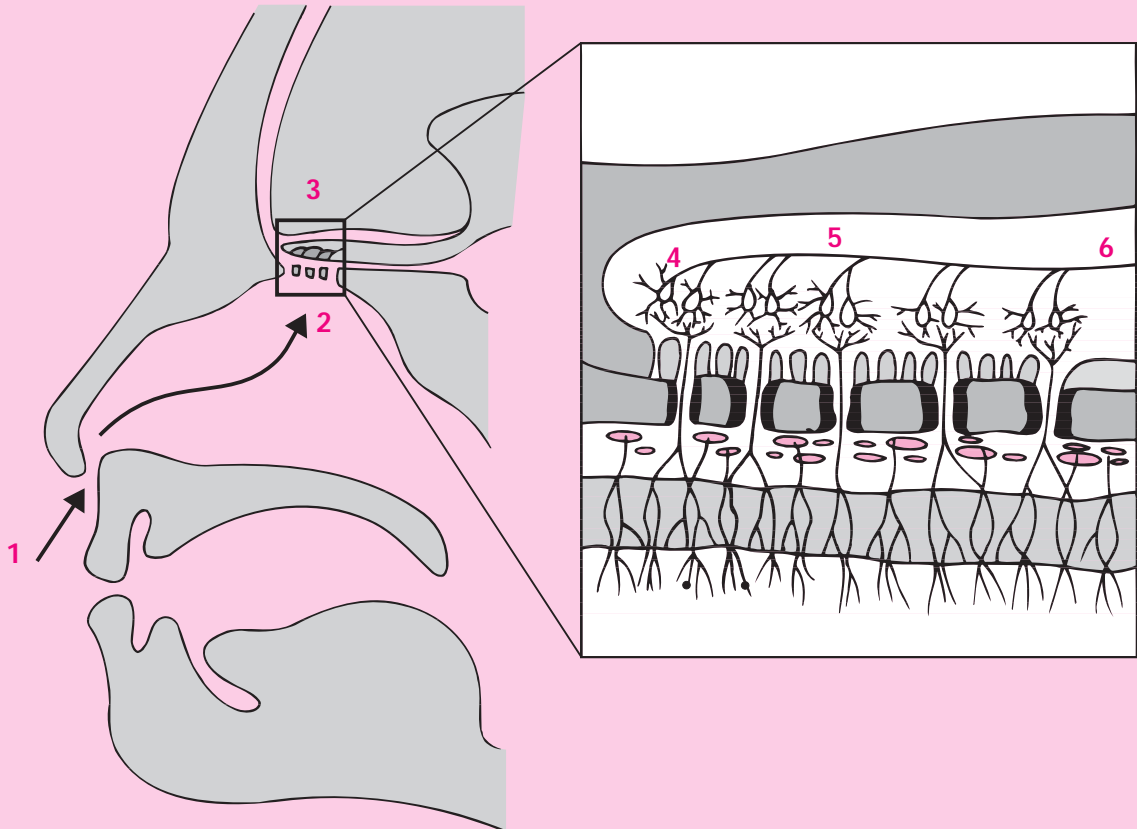
3 If the odorant particles fit into the receptor sites, the hair cells are stimulated to produce nerve signals.

4 The signals travel along nerve fibers through the cribriform plate to the olfactory bulb.

5 Some pre-sorting and pre-processing of signals occurs in the olfactory bulb.

6 The partially processed nerve signals travel the short distance along the olfactory nerve to the brain.

Flow of information concerning the sense of smell



Conversion of odors to nerve impulses

It is not certain how the physical presence of a smell particle, or odorant molecule, is converted to a nerve impulse. There are several theories concerning this process:

- Substances that emit odors also emit gases. These dissolve in the membranes of the nasal cavity into a fluid that stimulates the olfactory hair to produce the nerve impulse.
- Some form of energy given off by the molecules of a stimulating substance,

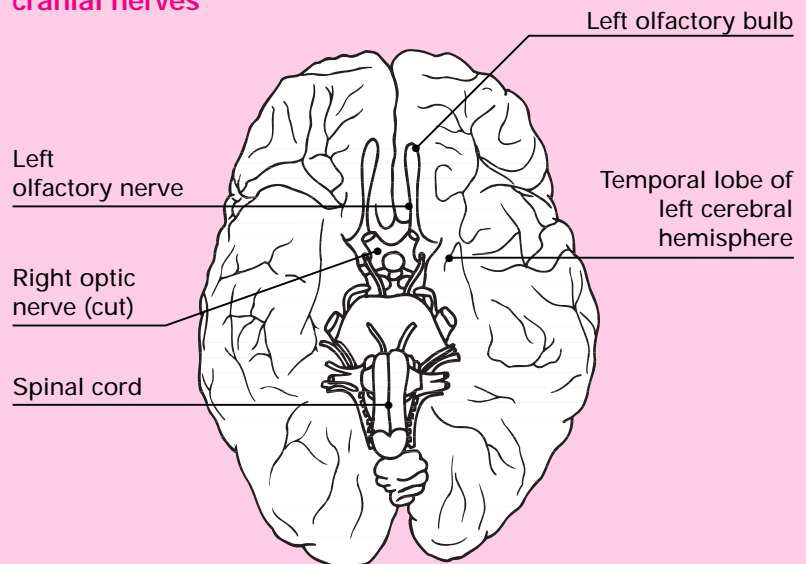
rather than the substance itself, creates the nerve impulse.

- The identity of the odor is coded as the shape of the odorant molecule. This slots into a same-shaped receptor site on the micro-hair of an olfactory hair cell, like a key fitting into a lock. It is this chemical bonding in the outer membrane that covers the micro-hair which triggers an electrochemical process that eventually generates the nerve signal.

Olfactory nerves and olfactory centers of the brain

Each olfactory nerve is also called cranial nerve I, because it is one of the twelve pairs of major nerves that connect directly to the brain, rather than linking via the peripheral nervous system. Each olfactory nerve conveys signals to a region of the cortex on the inner temporal (side) lobe of the cerebral hemisphere, known as the uncus. This is one of the primary sites where scents and odors are perceived in conscious awareness. However, little is known about the details of this process.

Underside of brain showing cranial nerves



Inside the mouth

The mouth fulfills various functions. It is one route in and out for air during breathing (respiration). It is the point of intake for food and drink. As part of this function, it is the site of taste detection, so that foods and drinks can be

monitored for unpleasant flavors. And along with the paranasal sinuses, described earlier, the mouth is a resonating chamber for the sounds of speech, which are modified by the tongue, cheeks, lips, and teeth as words.

Lips, teeth, and tongue

The lips are fleshy edges to the oral chamber entrance. They contain the elliptically shaped orbicularis oris

muscle. This works as a sphincter to vary the size of the oral opening and close it during chewing.

Transverse section through oral cavity

Vocal folds (cords)
in larynx

Epiglottis

Mandible (lower jaw bone)

Tongue

Papillae of tongue

Buccinator muscle

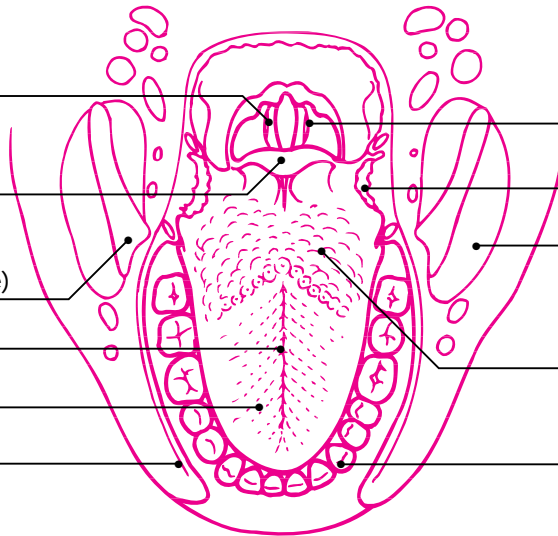
Oral pharynx (throat)

Palatine tonsil

Masseter muscle

Lingual tonsil

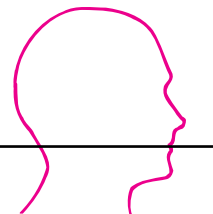
Teeth



Wear and tear

- The oral lining is one of the body's fastest-replaced parts, renewed every few hours.

Level of transverse section



Tongue and oral landmarks

The tongue is the body's most flexible muscle. It contains about a dozen muscle elements (see next page) that allow it to curl and tilt in almost any direction. The tongue is rooted in the upper front of the neck and on the hyoid bone. The roof of the mouth is formed at the front by the hard palate—the horizontal plates of the maxilla and palatine bones—and to the rear by the soft palate, a fleshy flap of cartilage, muscle, and connective tissue.

Anterior view of the underside of the tongue

Lip

Apex (tip)

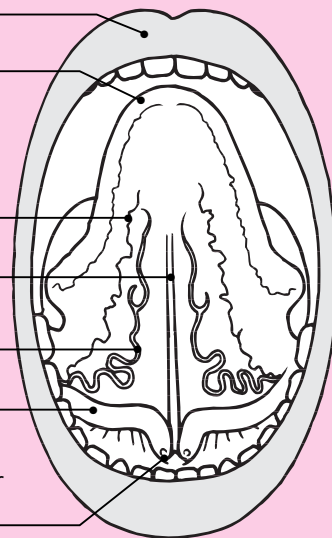
Plica fimbriata

Frenulum

Apical vein

Sublingual fold

Opening of duct from submandibular salivary gland



Median sagittal section of the front of the head

Nasal chamber

Hard palate

Oral chamber

Teeth

Tongue

Epiglottis

Hyoid bone

Laryngeal part of pharynx

Trachea

Soft palate

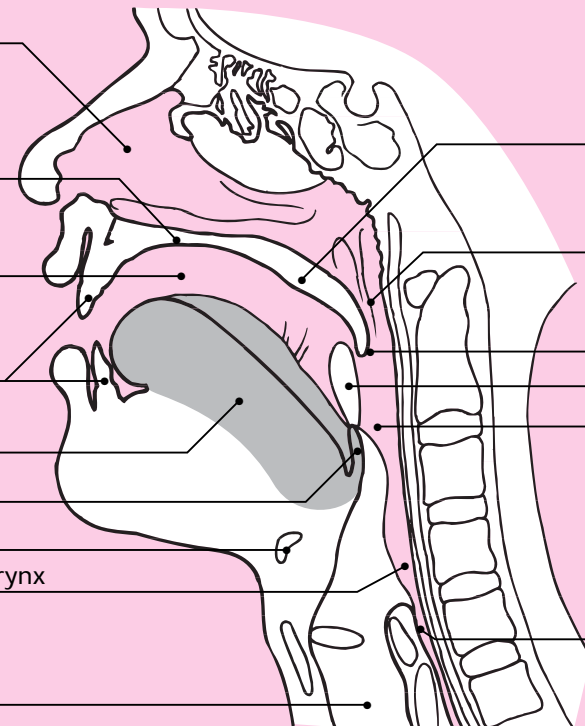
Nasal part of pharynx

Uvula

Tonsil

Oral part of pharynx

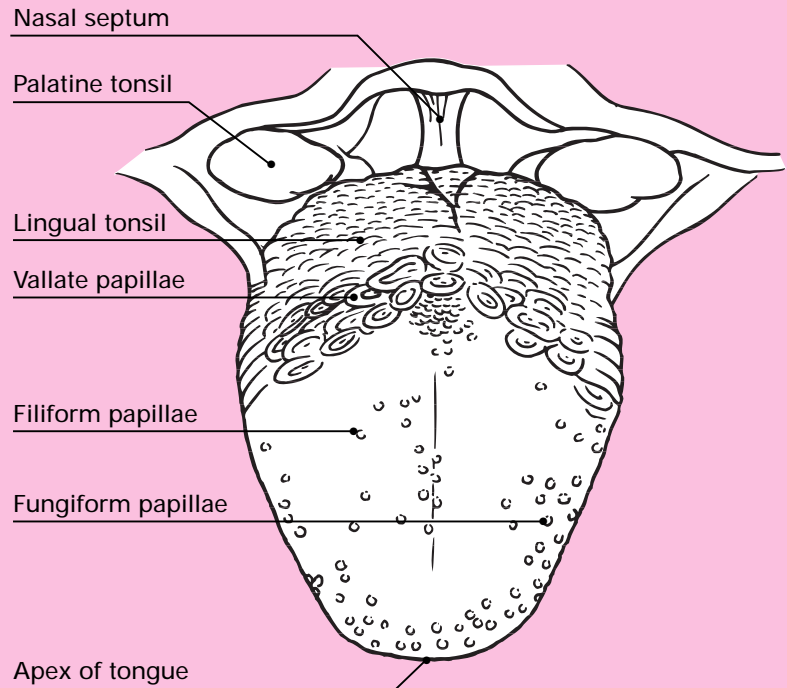
Esophagus



Surface of the tongue

The upper surface of the tongue is marked by three main kinds of small projections called papillae (see also opposite). The papillae help to grip food as it is moved around the mouth during chewing. They are distributed mainly at the front, sides, and rear of the tongue. The central upper surface of the tongue, known as the oral part, is free of papillae. Since the microscopic taste buds which provide the sense of taste are associated with papillae, the oral part of the tongue cannot detect tastes or flavors.

The tongue from the front



Musculature of the tongue

The muscles of the tongue are known as the lingual muscles. There are two main sets: the intrinsic lingual muscles entirely within the tongue itself, and the extrinsic lingual muscles which connect the tongue to other parts of the mouth, head, and neck. Examples and actions include:

Genioglossus Projects the tongue forward so the tip can protrude from the mouth; curves the sides of the tongue upward; helps to move the tongue from side to side.

Hyoglossus Presses the tongue down onto the floor of the mouth.

Styloglossus Raises the tongue up to touch the roof of the mouth, and also pulls it rearward toward the throat.

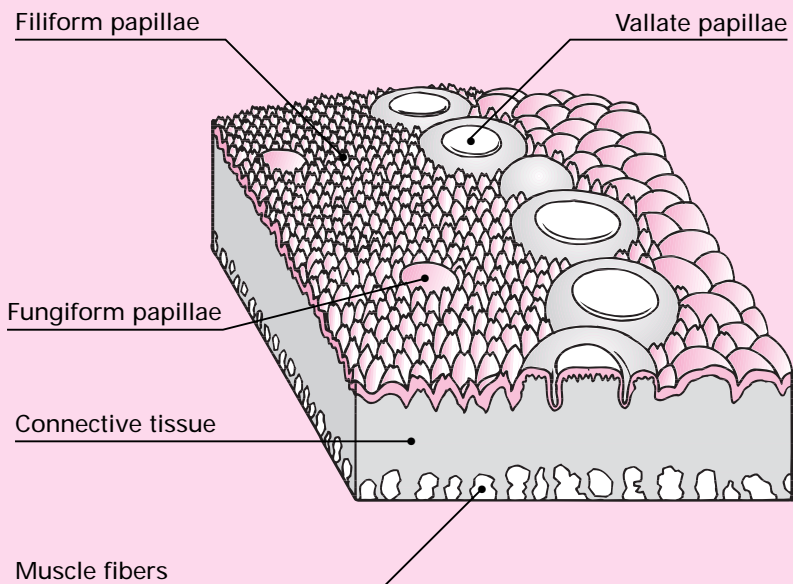
Transversus Makes the tongue longer and thinner in overall shape.

Verticalis Opposes the action of the transversus and makes the whole tongue wider and flatter.

Structure of papillae

Largest of the tongue's three types of papillae or "pimples" are the vallate papillae, which are low and rounded. They form two V-shaped rows across the rear of the tongue. Smaller are fungiform papillae, which are shaped like miniature mushrooms and are scattered singly, especially near the tongue's tip. Smallest are filiform papillae which are like tiny pointed hairs. Microscopic taste buds are arranged around the sides of the papillae, as shown below and on the next page.

Section through the surface of the tongue



Section through a vallate papilla

Mound of papilla

Taste buds in lower side of papilla

Enlargement of a taste bud

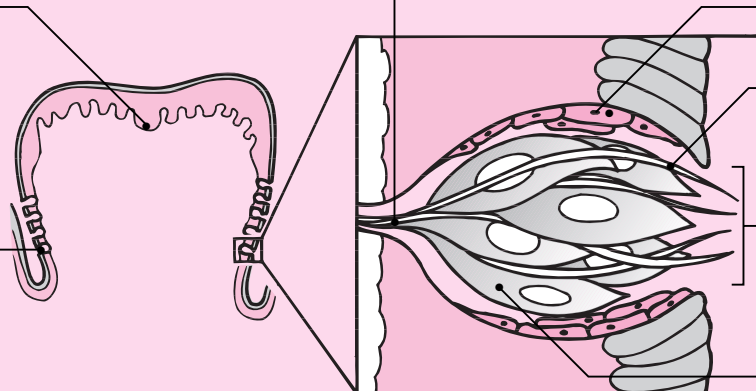
Nerve fibers

Supporting cells

Microvilli

Taste pore

Gustatory hair cells (receptor cells)



Taste buds

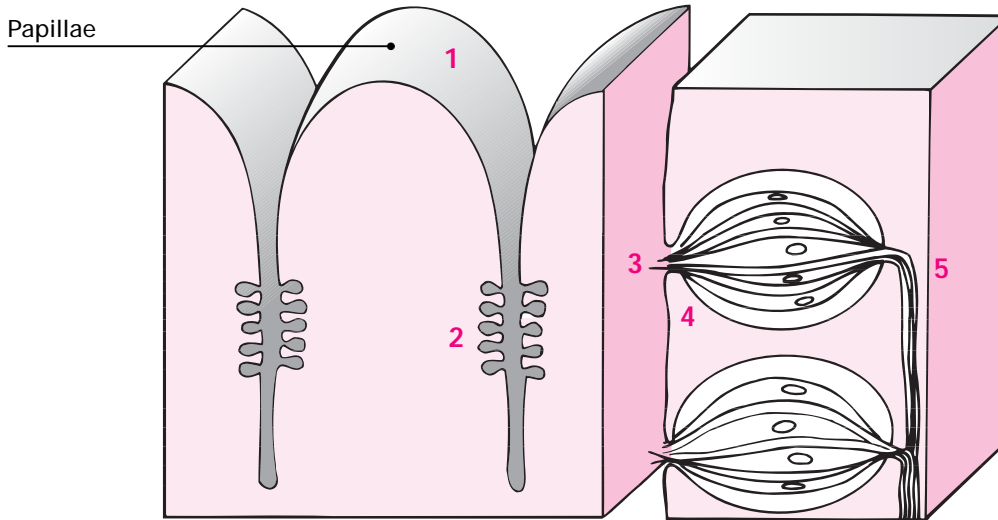
Taste receptor cells, or gustatory hair cells, are found in groups known as taste buds. In each taste bud, which is far too small to see with the unaided eye, the cells are clustered together like segments of an orange. The taste buds are found on the tongue, soft palate (rear part of the mouth roof), and in the

upper throat, with a few scattered on the cheek linings, gums, and inner lips. Each taste bud is made up of two main types of cell: supporting cells and gustatory hair cells. The 10–30 gustatory hair cells of a taste bud have micro-hairs which project from the taste bud through an opening called the taste pore.

How the taste buds work

- 1 Flavor substances coat papillae on surface of tongue.
- 2 Flavor substances touch taste microhairs.

- 3 Micro-receptors are stimulated.
- 4 Gustatory cell generates nerve signal.
- 5 Nerve fibers convey signals to brain.



Taste buds

- A young person has about 10,000 taste buds in total.
- This falls to around 5,000 in later years.

Short-lived cells

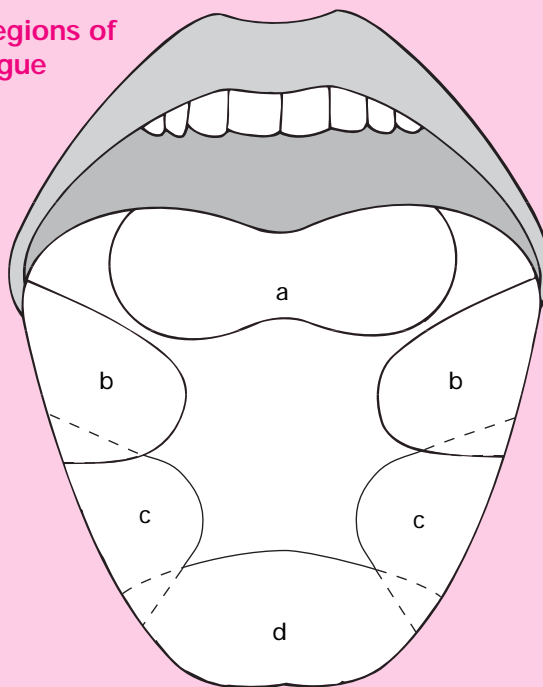
- The gustatory hair cells (receptor cells) that actually detect flavors each have a life of only 10 days.

Taste regions

Tastes and flavors are not detected equally all over the tongue. The middle or oral part of the upper surface has no taste buds and so cannot detect any flavors. Most taste buds are sited at the tip, along the sides, and across the back of the tongue. These regions detect four different basic components that are thought to make up all tastes and flavors:

- a** Rear—bitter;
- b** Rear sides—sour;
- c** Front sides—salty; and
- d** Tip—sweet.

Taste regions of the tongue



Nerve links to the brain

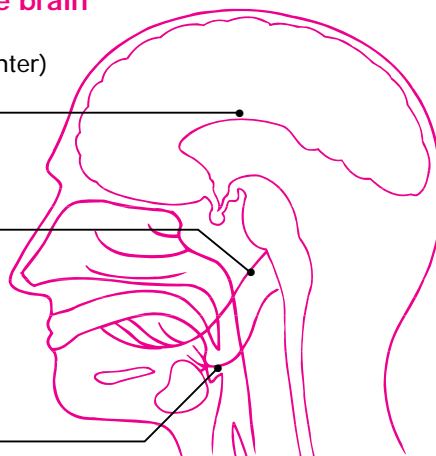
Two major nerves convey most of the signals concerning taste to the brain. Information from the front two-thirds of the tongue travels via branches of the facial nerve (cranial nerve VII). Signals from the rear third of the tongue are carried by branches of the glossopharyngeal nerve (cranial nerve IX).

Sagittal section showing nerves conveying taste sensations to the brain

Gustatory cortex (taste center) on lower side of brain

Facial nerve

Glossopharyngeal nerve



The nose and mouth tend to be particularly susceptible to viral and bacterial infections. Airborne and food- or drink-borne infectious organisms have easy access, and the warm, moist mucous membranes lining the nose and mouth encourage the growth of these organisms. Bacterial infections such as tonsillitis and strep-throat (streptococcal infection) can usually be cured with

antibiotics; viral infections, such as colds, cannot be cured by drugs although the troublesome symptoms may be relieved. These pages show some of the infections and other problems that affect the nasal and oral areas, and describe ways in which you can help yourself toward better health by preventing such problems or minimizing their symptoms and effects.

Common nose and mouth problems

1 Sinusitis; this condition often occurs when bacteria from a nose infection spread into the sinuses. It may produce a purulent discharge from the nose and is relieved by medication and applying warmth.

2 Inflamed nasal membranes; this condition is frequently a result of an allergic reaction (see opposite).

3 Foreign body in the nose; if a child has a blockage and discharge in only one nostril, suspect a small object lodged there and consult a doctor or nurse.

4 Nosebleed; this condition is caused by the rupture of one of the many tiny blood vessels that line the nose.

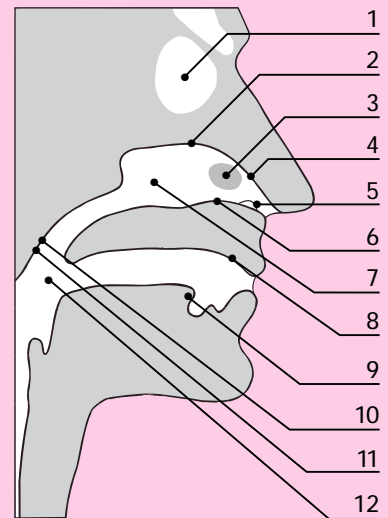
5 Boil in the nose; this very painful condition is often caused by scratching the lining of the nostril with a dirty fingernail, pencil, etc. It is wise to seek a doctor's advice.

6 Dry mucous membranes; this condition may be caused by a lack of humidity in a centrally heated home, or by an infection and fever.

7 Common cold in the nose; this is one of the most enigmatic and bothersome of all infections, with no cure yet discovered.

8 Thrush; this condition is an infection of the mouth by *Candida albicans* fungus, causing curdy patches.

9 Virus blisters (cold sores); these occur on the cheeks and tongue, but



generally disappear of their own accord.

10 Tonsillitis; this is the infection and inflammation of the tonsils.

11 Quinsy; this very painful condition is caused by an abscess around the tonsils.

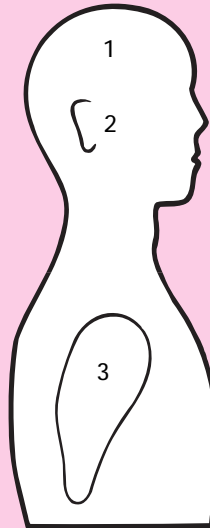
12 Sore throat; this is often a complication of many bacterial or viral infections.

Side-effects

The diagram here shows some of the other parts of the body that may be affected by nose and mouth problems.

1 Head Infections of the nose and sinuses may lead to headaches, especially in the forehead region (site of the frontal sinuses). Inflammation of the nerves passing around the face can also produce headaches.

2 Ears Temporary deafness is a frequent side-effect of many nose and throat infections. The causative organisms tend to




spread up the Eustachian tube from the throat to the middle ear, and multiply there. This produces infected mucus and pus that press on the eardrum and tiny ear ossicles (bones), damping their movements so they cannot convey sound vibrations to the inner ear.

3 Lungs Mucus and phlegm from nose and throat infections may be breathed in as an aerosol after coughing or sneezing, and travel down into the lungs. This can set up a lung infection such as bronchitis or pneumonia.

Nose and mouth allergies

Very common substances can cause distressing allergic reactions in sensitized people, especially in the lining of the nose and the sensitive lining of the mouth. The symptoms often include an itchy, runny, or blocked nose with soreness, and frequent sniffing and sneezing; and itchy inflammation, soreness, and swelling in the mouth and throat. Causes of allergies may include plant pollen, house dust,



animal fur, chemicals, certain foods, or the sap and hairs from particular plants. The main control of allergies consists of identifying the source of the reaction and avoiding

it as much as possible. When this is not possible, medication such as antihistamines or steroids, as tablets or sprays, may help to alleviate the symptoms.

The skin forms the body's outer covering. Skin and its appendages or outgrowths, hair and nails, form the integumentary system. This is multi-functional. Its foremost role is protection—to shield the body against harm and damage from the outside. But it is also the sense organ of touch, and plays roles in regulation of body temperature and waste excretion.

Protection of the skin

Skin protects the body—but also needs protection itself from harmful influences. One of the most damaging influences is sunshine, especially its ultra-violet (UV) rays. Sunshine has good and bad effects. It helps our bodies to make vitamin D, and benefits acne sufferers. But in the short term, unaccustomed strong sunshine—especially on pale skin—is liable to produce sunburn. First-degree burns show as red, tender areas of skin that subsequently peel. Nose, neck, shoulders, chest, and back are often danger areas. Severe sunburn so inflames the skin that it stops helping to keep the body cool and victims grow dangerously overheated and may even die.

Called sunstroke, this is a form of heatstroke if it involves malfunction of the temperature control center at the base of the brain. Keeping the head and neck covered during long exposure to strong sunlight helps to protect the brain from heat damage. This is especially important in young children. Pale sunworshippers can avoid sunburn if at first they start by exposing skin to strong sunshine for only 10 minutes a day, and guard the skin with high-factor protective sunscreen oil or cream. Prolonged exposure to the sun over years ages skin, increasing its lines and wrinkles, and may result in cancers.

Skin, hair, and nails

The integumentary system forms the entire body covering apart from over the eyes.

Scalp hair

Thin skin
on eyelids

Sensitive
skin on lips

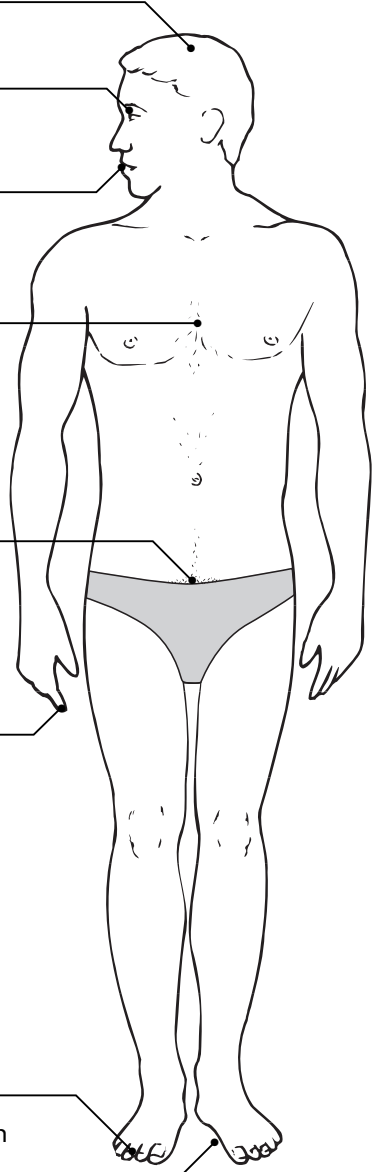
Body hair

Pubic hair

Fingernails

Toenails

Thickened skin
on soles



Structure of skin

The skin, or cutaneous membrane, has two basic layers:

1 the epidermis; and

2 the dermis.

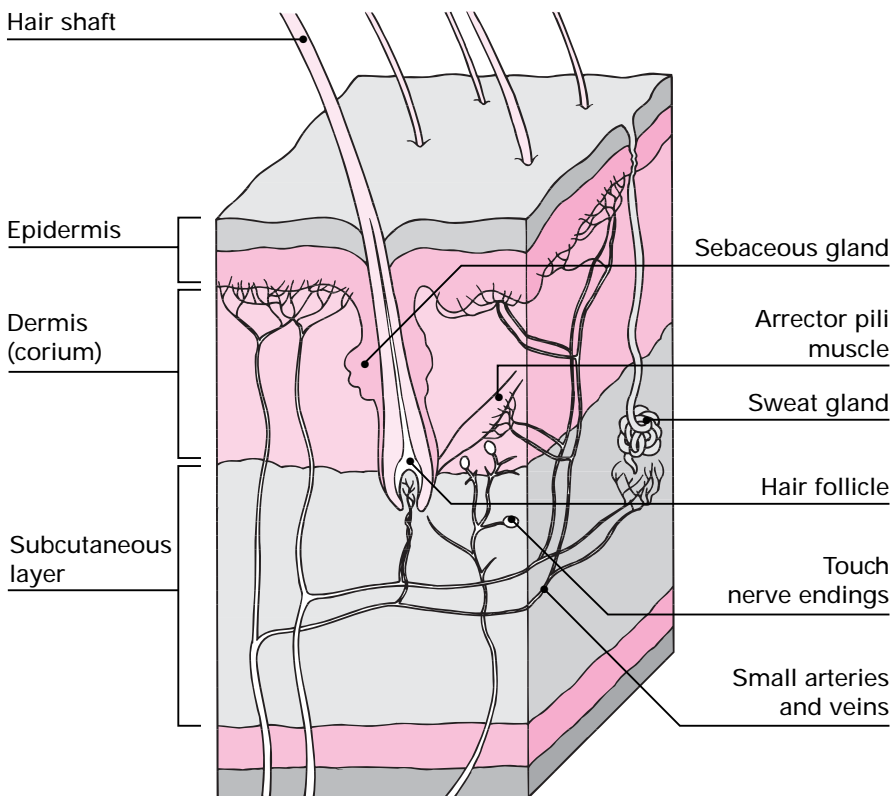
3 A third layer, the subcutaneous layer, is not actually part of the skin, being below it. But it is important to skin structurally, and also it aids in physical protection of the body, being able to absorb some of the impact of knocks and bumps.

Functions of skin


The skin:

- helps to control body temperature;
- provides a defense against the invasion of the body by harmful substances;
- protects internal organs and structures from injury;
- is involved in waste product removal;
- is an important, and the largest, sense organ; and
- allows identification by fingerprints, no two of which are identical.

Section through hairy skin

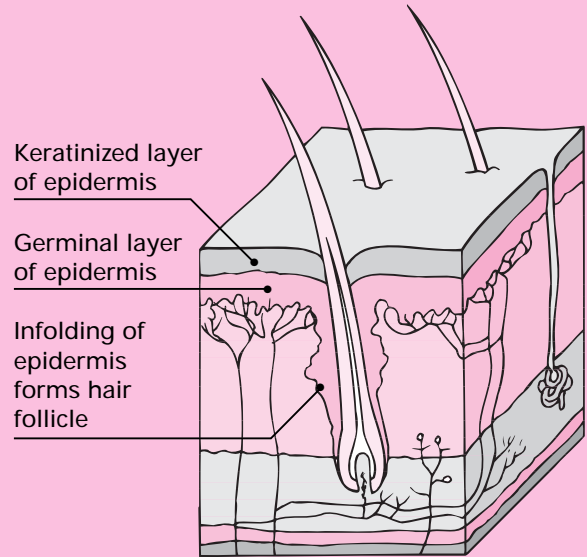


Fingerprints



Epidermis: structure

The upper part of the epidermis, the keratinized layer, is made up of thin, flat, dead cells. In some places (such as the soles of the feet), this layer is thicker than elsewhere. Cells in the lower epidermal layer, the germinal layer, continually multiply to produce new cells. These are pushed toward and into the keratinized layer by the production of more cells below. This means the skin is constantly being renewed. As the cells leave the germinal layer a tough, fibrous protein called keratin is deposited inside them, making them harder and flatter, and eventually dead.



Epidermis: functions

The components of the epidermis serve several purposes.

- The renewal of cells gives skin its ability to repair itself if damaged.
- Keratin makes skin tough and waterproof. This is important for keeping rainwater and other liquids out of the body, and retaining bodily fluids.
- Melanin shields the skin from UV rays (see opposite).
- Cholesterol molecules in the epidermal cells are converted into vitamin D by the action of sunlight on the skin. This vitamin is important for healthy bones.

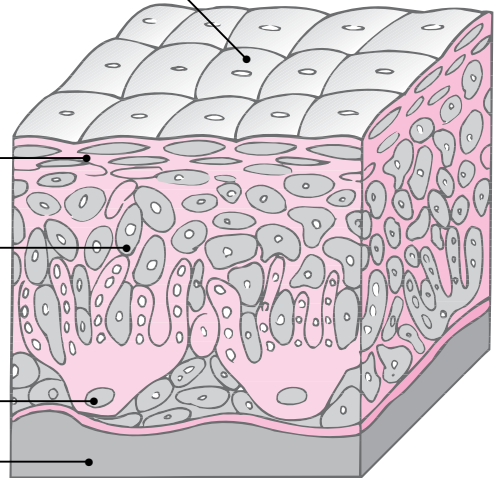
Keratinized cells at surface

Keratinized layer

Upper germinal layer

Multiplying cells at base of germinal layer

Dermis



Micro-structure of epidermis and melanin formation

The epidermis can be divided into five sublayers according to the stage of keratinization of its cells. The basal layer contains specialized melanocyte cells that produce the yellow, brown, or black pigment melanin. The level of melanin production is partly under genetic control, which is why skin color is inherited.

New each month

- On average, skin cells in the epidermis take one month to move outward, fill with keratin, die, and be rubbed off the surface.
- This means the body's entire outer skin is renewed monthly.

Cross section through epidermis and upper dermis

Horny sublayer of keratinized layer

Clear sublayer of keratinized layer

Granular sublayer of keratinized layer


Spinous sublayer of germinal layer

Scattered melanocytes

Dermal papillae (mounds)

Basal sublayer of germinal layer

Fibrous upper dermis

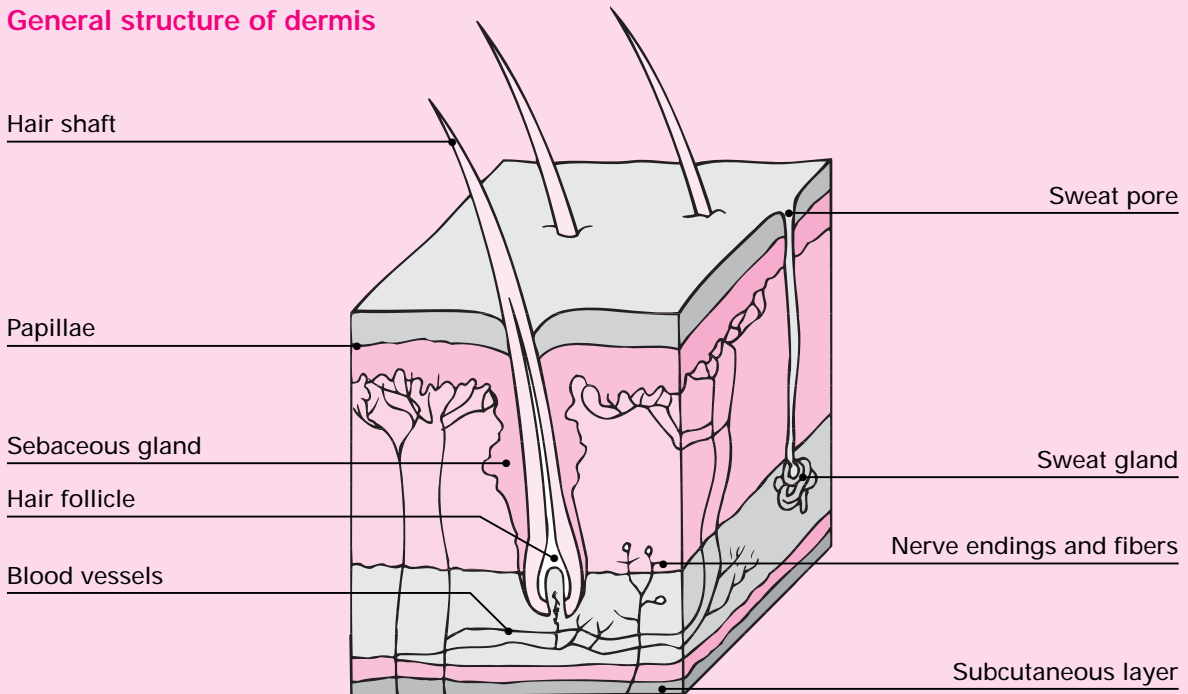


Dermis: structure

This is the thicker, inner layer of skin. It is mainly fibrous connective tissue that contains a number of specialized microstructures. These include hair follicles and nail beds; the coiled tubes of sweat glands; and sebaceous (oil-producing) glands, usually each associated with a hair. There are also small nerves; thinner single nerve fibers; and sensory nerve endings or sensory

receptors which detect the many types of touch (see following pages). Small arteries and veins supply blood to all these structures. Papillae (nipple-like projections) indent the upper surface and join firmly to the epidermis. On the palms of the hands and soles of the feet, the papillae form ridges and grooves that help to provide friction and improved grip.

General structure of dermis



Thick skin

- Typical thickness is $\frac{1}{25}$ to $\frac{1}{12}$ of an inch (1–2 mm). Unprotected skin on the sole of the feet may be ten times thicker.

Thin skin

- Some of the thinnest areas of skin are on the eyelids, with a thickness of $\frac{1}{50}$ of an inch (0.5 mm).

Dermis: functions

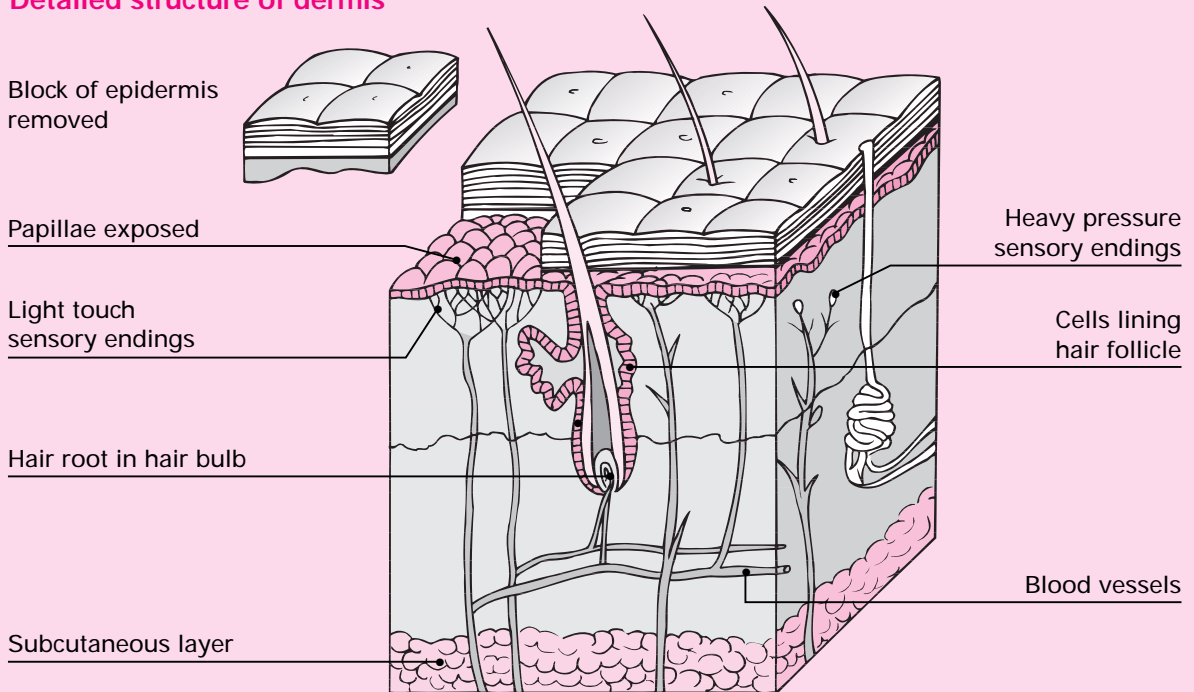
The components of the dermis all have important roles to play.

- Collagen (fibrous protein) and elastic fibers that form the connective tissue give the skin its strength and elasticity.
- Sensory receptors receive information about pain, pressure, touch, and temperature.
- Sebaceous glands lubricate the skin with sebum (oily secretion). Sebum

also contains chemicals that help to disable or kill bacteria.

- Sweat glands are important for the control of body temperature. They also help in the excretion of waste materials such as urea and uric acid. The acidity of sweat and chemicals contained in it provide protection against bacteria.
- Blood vessels supply nutrients to both the dermis itself and the epidermis.

Detailed structure of dermis



Subcutaneous layer

This layer lies underneath the skin. It is mainly composed of loose connective tissue and fatty material called adipose tissue. In certain places the adipose tissue is thicker and forms fatty "pads" that round the body's outline.

Functions of the layer include:

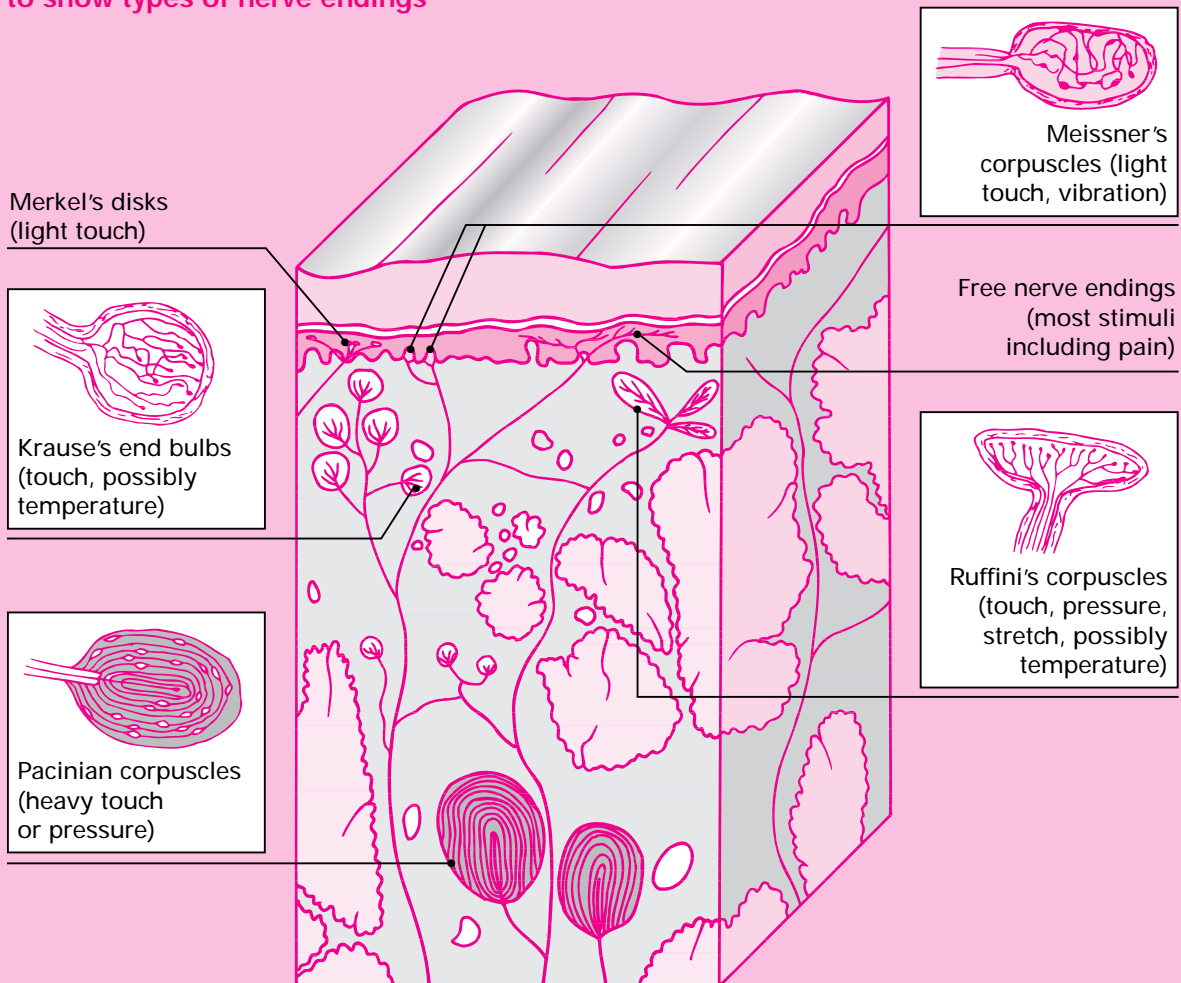
- anchoring the skin to underlying structures;
- providing protection for inner organs;
- insulating the body; and
- storing energy as body fat.

Arrays of touch sensors

Touch sensors or receptors are specialized endings of nerve fibers. There are several distinct types and shapes. Most are distributed at specific depths within the dermis, and are more common in some areas of the body than in others. Most are named after the

anatomists who discovered them, generally during the eighteenth and nineteenth centuries. Some types of endings seem to detect specific stimuli, such as reduction in temperature or very light touch. Others respond to several stimuli.

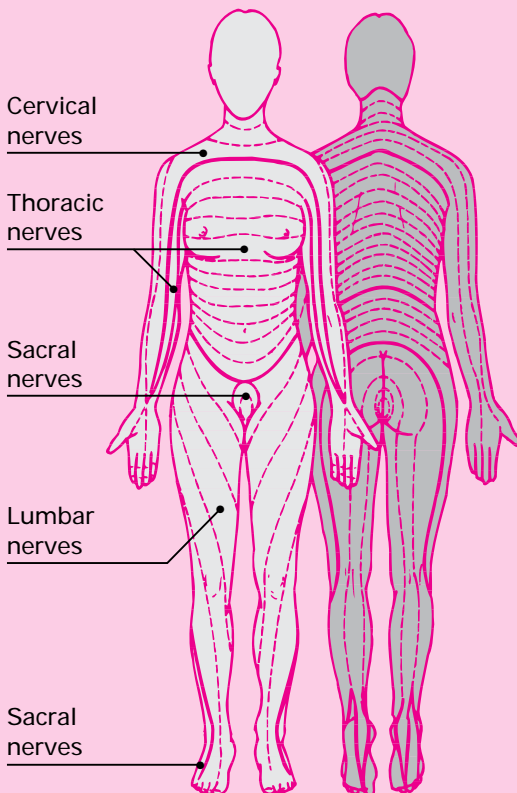
Section through glabrous (hairless) skin to show types of nerve endings



Dermatomes

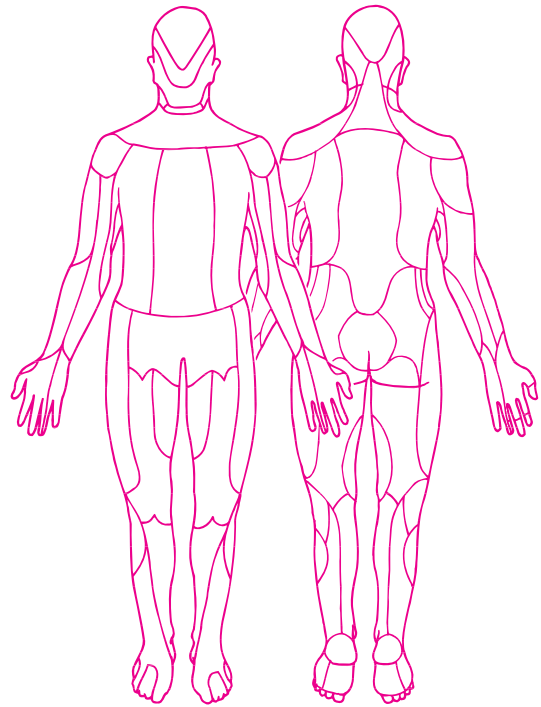
Dermatomes are areas of skin identified by the nerves that supply them. Pain in a dermatome may result from damage to the skin in that dermatome, or occasionally, from a problem with an internal organ linked by the same nerve. This is why damage to one area of skin may cause aches or pains deeper in the tissues of a nearby area. The solid lines below represent the boundaries between groups of dermatomes supplied by different nerves.

Major dermatomes



Nerves to the skin

Very few main nerves supply the skin alone. Most major nerves have branches both to the skin and to tissues and organs beneath.

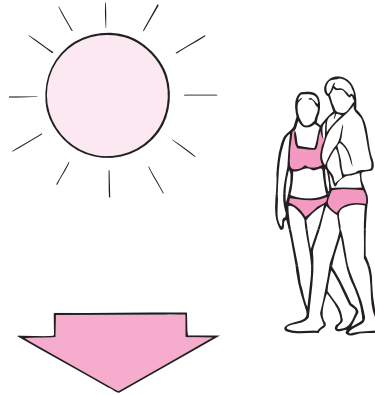


Pattern analysis

- Nerve signals concerning touch are routed to the somatosensory cortex or touch center, a strip on the side of the brain's surface, in the region above the ear.
- The brain probably analyzes the signals for overall patterns to determine the nature of the contact, from cold, hard, and dry to warm, soft, and moist.

Skin and temperature regulation

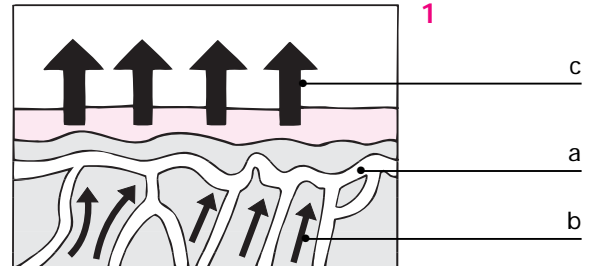
The normal temperature of the human body is about 98°F (37°C). The body has the ability to keep this temperature constant even as the temperature of the environment changes. This ensures that the chemical reactions vital to life can still be carried out. The skin plays an important part in regulating body temperature.



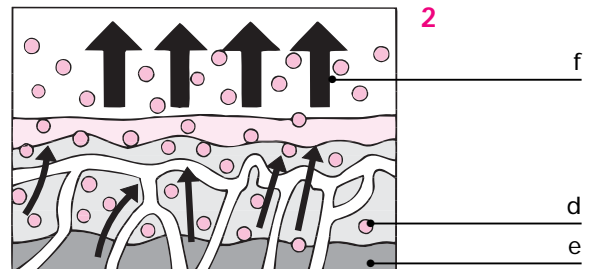
Losing heat

If the body becomes hotter than normal (on a hot day or during physical exercise, for example), the body makes the following adjustments in order to stop overheating.

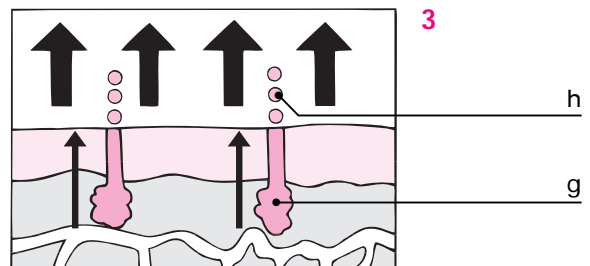
1 The blood vessels (a) of the skin dilate. This increases the flow of warm blood (b) to the skin. More heat (c) than usual is lost because the blood cools as it passes near the surface of the body.



2 Water (d) seeps from underlying tissues (e) and evaporates (f) from the surface. In doing so, it carries away heat with it. This is called insensible water loss. It happens constantly but will vary with the temperature of the air.



3 The sweat glands (g) secrete more sweat (h) and, as this evaporates from the skin, it carries more heat away from the body.



Perspiration

- In hot, humid conditions when the body is very active, water loss through sweating can exceed one gallon (4 l).

Retaining heat

If the body becomes colder than normal (on a cold day, for example), it makes the following adjustments in order to stop overcooling.

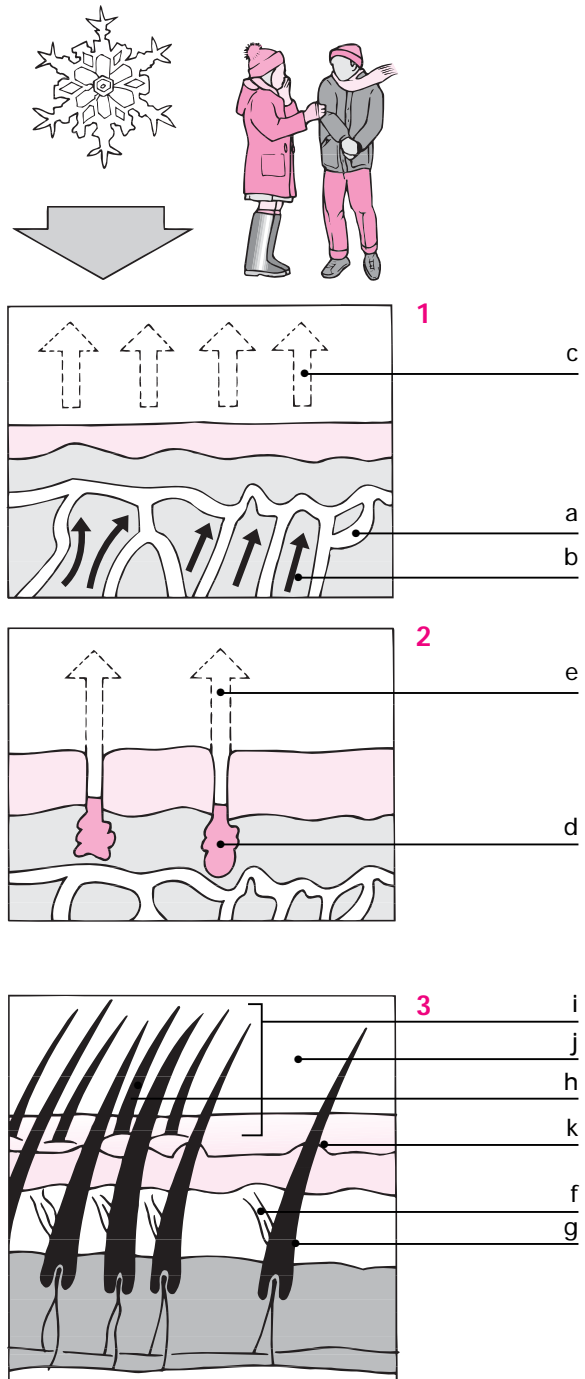
1 The small arterial blood vessels (**a**) of the skin become narrower or constricted, under the control of nerve signals from the autonomic nervous system (the part that works automatically, without the need for conscious intervention). This decreases the flow of warm blood (**b**) near the surface of the body. This in turn reduces heat loss from the surface (**c**) and keeps internal structures warm.

2 If blood temperature is below normal, the activity of sweat glands (**d**) is decreased. This ensures that only very small amounts of body heat are lost through evaporation (**e**).

3 The tiny arrector pili muscles (**f**) attached to body hairs (**g**) contract, making the hairs stand more upright. In areas of thicker hair growth over the body (**h**), this has a small insulating effect as it increases the layer of trapped air (**i**) just above the skin surface. In turn, this reduces the loss of heat from the skin. In areas of thinner hair growth (**j**), the effect is visible as small puckered skin mounds called goosebumps (**k**).

Heat output

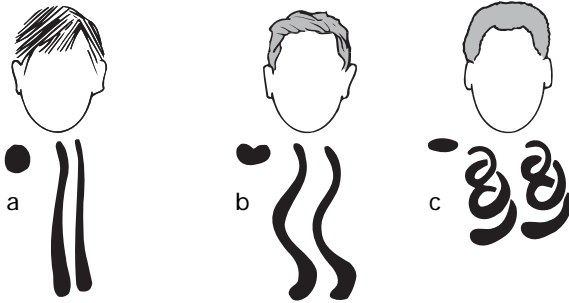
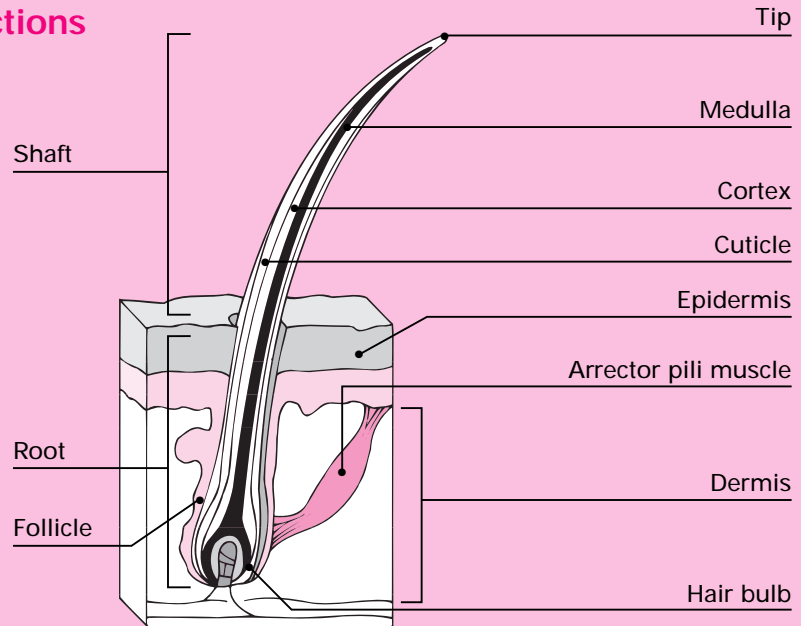
- A human body gives off approximately 500–1,000 watts of heat energy depending on its level of activity.



Hair structure and functions

Structure

Hairs are mostly made of dead cells containing keratin, the same tough, fibrous protein found in the epidermis. The hair root is embedded in the dermis, with the shaft above. The pit-like follicle widens at its base to form the hair bulb, where hair growth takes place. The hair itself is made of a spongy medulla surrounded by the fibrous cortex. The outer layer, cuticle, is made of overlapped cells.



Hair growth and cross sections

The shape of the hair follicle determines whether a hair will be straight, wavy, or curly. This follicle shape is inherited, and is under genetic control.


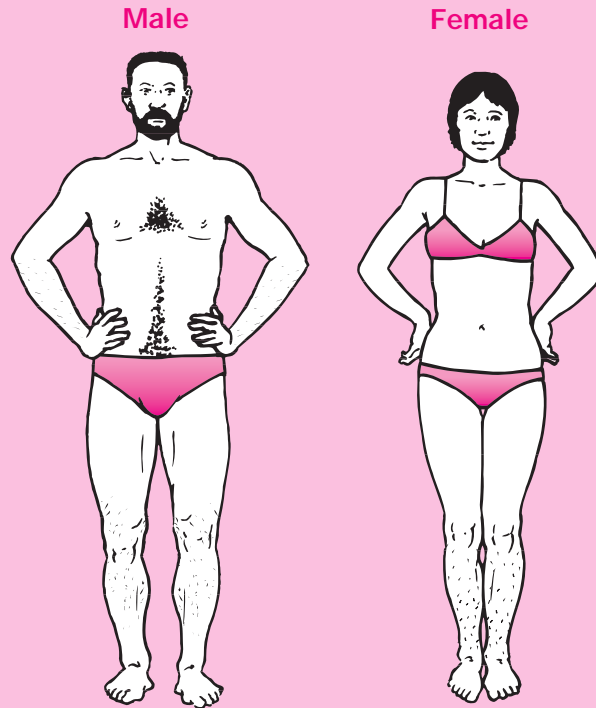
- Straight hair (a) is round in cross-section and comes from a round follicle.
- Wavy hair (b) is kidney-shaped in cross-section and comes from a curved follicle.
- Curly hair (c) is flat, from a flat follicle.

Functions


- Unless cut very short, hair gives physical protection and helps to guard the head from bumps and knocks.
- Long head hair insulates the head from cold and great heat such as sun glare, and retains body warmth. Body hairs also have an insulating function.
- Eyelashes shield the eyes from glare, airborne dust, and other foreign bodies.
- Nasal hairs help to trap and retain foreign particles, to protect the respiratory system.

Hair cover and types

Except for the lips, parts of the genitals, the soles of the feet, and the palms of the hands, most of the body is covered in hair. There are, however, differences between men and women in hair cover. Men tend to have thicker, coarser body hair, especially on the chest and arms, than women. Most men also have areas of thick, coarse facial hair that forms beards and moustaches. Both sexes have thicker hair under the arms and around the genitals; again, this tends to be more extensive in males.



a




b



c



d



e

Different types of hair

Each person has more than one type of hair on his or her body:

a body hairs are thin and short;

b head hairs on the scalp tend to grow denser and longer;

c eyebrows are thick hairs and also grow densely but shorter;

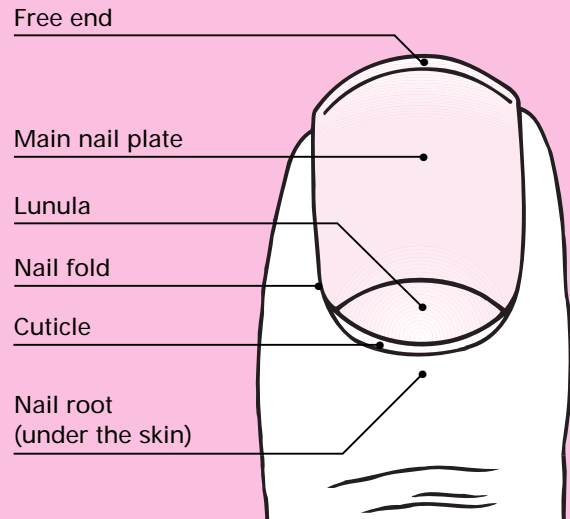
d pubic hairs tend to be more coarse and curly; and

e eyelashes are short and regular.

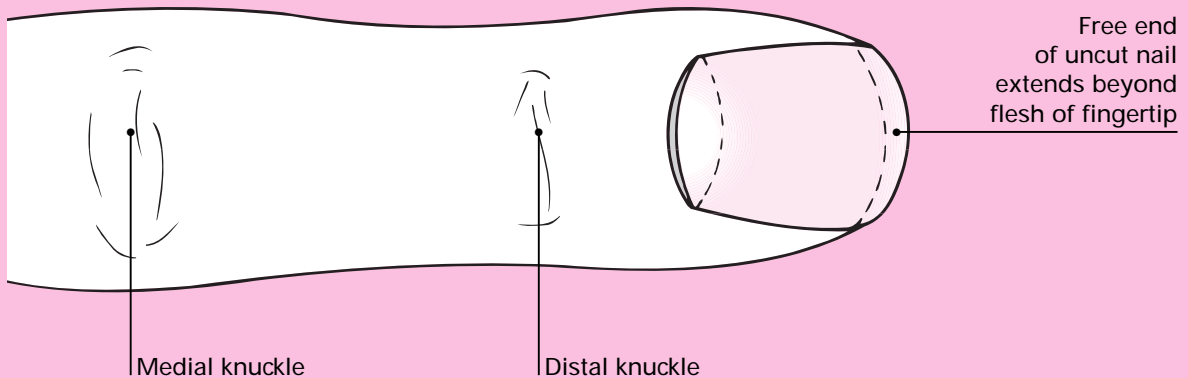
Nail structure

Nails are hard surfaces on the ends of fingers and toes. They are produced by epidermal cells and are made up of keratin, the tough, fibrous protein which is also found in the epidermis. Like the cells on the epidermal surface of skin, the nail itself is dead and cannot feel touch or pain. Sensations come from the surrounding skin. The nail plate lies on the nail bed. It has a root, which is attached under the skin, and a free end. The flap of skin that covers the root is called the cuticle. The skin around the nail is called the nail fold. The pale half-moon shape at the base of the nail plate is called the lunula.

Anterior view of fingertip



Anterior view of finger



Nail functions

Nails protect the very sensitive ends of the fingers and toes, preventing them from being squashed. Each nail forms a type of rigid backplate to the fleshy end of the digit. This acts as a firm surface for the fleshy part to press against,

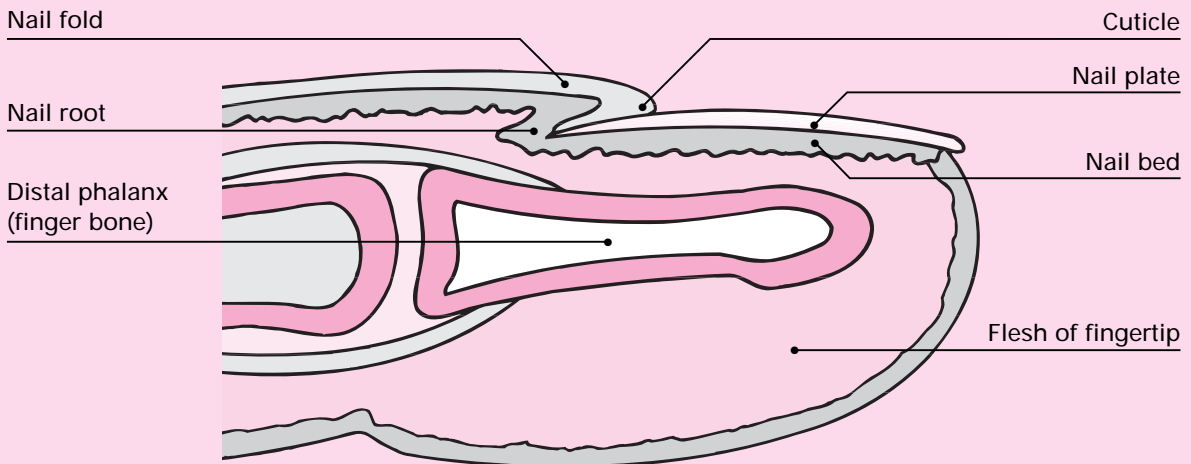
when picking up and gripping objects, especially when picking up small items with the fingertips. Nails are also useful for scratching and removing bits of skin debris or tiny objects that occasionally get embedded in skin, like splinters.

Nail growth

The nail plate grows out from the root. Here, new cells are produced which push the older, dying ones toward the end of the toe or finger. It takes a fingernail about six months to grow

from base to tip. A toenail takes at least twice as long. The nail root appears white; the rest of the nail plate appears pink because of capillaries in the dermis below the nail.

Longitudinal section through a fingertip



Nail care

A home manicure will help to keep nails in good condition.

1 Cut your nails with a shortbladed pair of scissors. Nailclippers may not give a good shape to the nail. The nails should be cut in a gently sloping curve; do not cut them down at the sides.

2 File the nails into the exact shape required

with an emery board or a nail file coated with diamond slivers. Most metal nail files are usually too coarse and tend to split the layers of the nail.

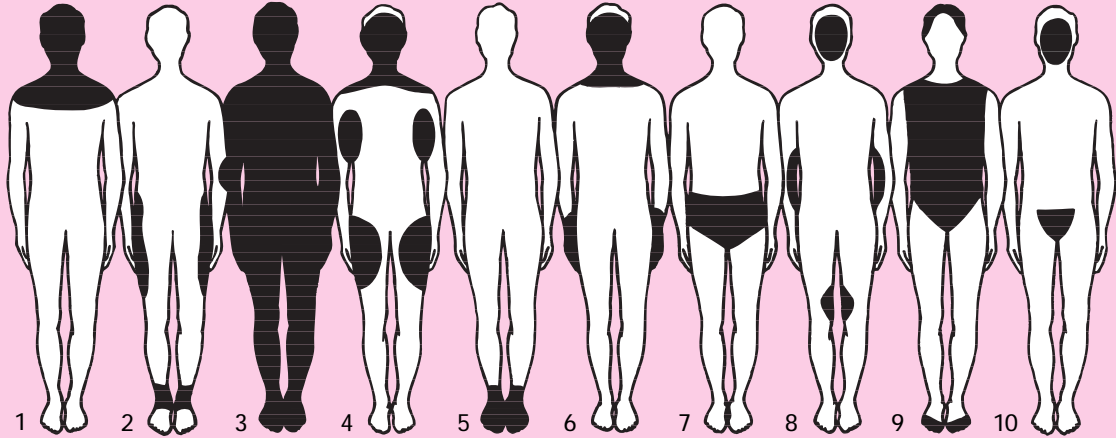
3 File each nail from the sides toward the center, holding the file toward the underside of the nail rather than the top.

4 Trim any ragged cuticles close to the nail. Soak the hands in warm soapy

water for a few minutes, and then gently push down the cuticles with an orange stick to expose the half moon area at the nail base.

5 Keep the free end clean of dirt and debris using the curved end of a nail file (but not a sharp point). This both improves appearance and lowers the risk of infection.

Sites of common skin problems



1 Acne, blackheads, and sebaceous cysts all tend to be triggered by overproductive sebaceous glands, a condition that often occurs for hormonal reasons in adolescence (see next page). Affected areas are the face, neck, shoulders, and back.

2 Bedsores, or pressure sores, may develop on the elbows, hips, buttocks, ankles, and heels of bedridden people. Areas of skin become red and ulcerate. Shifting the patient's position hourly helps to prevent pressure sores.

3 Birthmarks occur on any part (see page 96).

4 Boils generally occur on the face, neck, back,

armpits, and buttocks; they are highly infectious.

5 Corns and calluses are hardened patches of skin that occur on the toes, heels, or balls of the feet as a result of pressure.

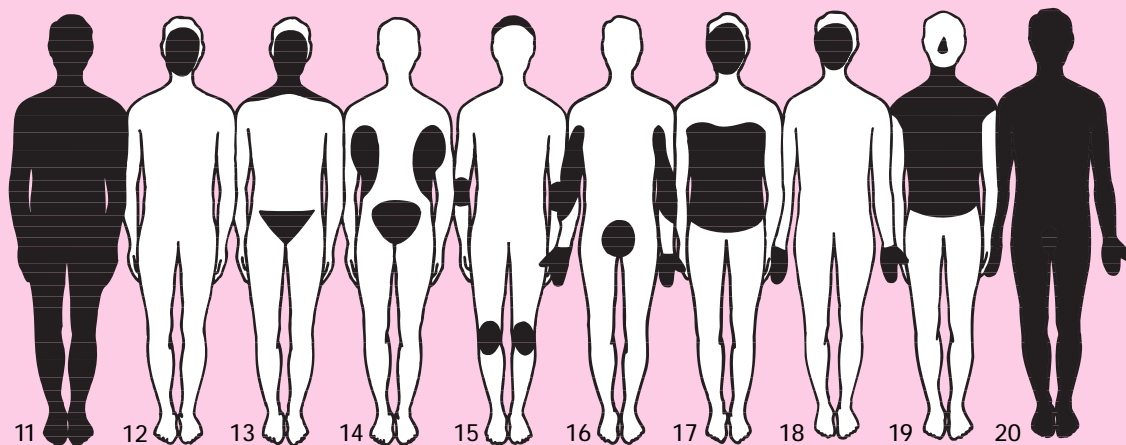
6 Contact dermatitis is a skin inflammation and rash where skin is in contact with irritants. Some people react allergically to cosmetics, dyes, or other substances that leave most of us unaffected; the skin burns, stings, and itches, and it may ooze clear fluid. Areas affected are the face (from cosmetics or soaps), neck (from jewelry) and hands. Avoid contact with the irritant.

7 Incontinence in later life can cause rashes similar to diaper rash in babies.

8 Eczema, or atopic dermatitis, produces red, raised patches often on the face or the knee and elbow creases. It usually appears in infancy; it may clear up at ages 2–3, but recur later in life.

9 The fungal infection of ringworm produces expanding scaly rings on the trunk and elsewhere; it can be intensely itchy.

10 Herpes viruses produce cold sores (painful, irritating patches on the lips and nearby areas); these often break out due to a trigger such as a febrile illness, minor injury, or strong sunlight. Genital herpes affects the genital region and is generally transmitted sexually.



11 Hives (urticaria, or nettle rash) is a skin inflammation causing itchy weals that suddenly appear on any part of the body, and come and go for a week or more. Hives is often caused by allergic reaction to certain drugs, foods, infections, or even sunlight or stress.

12 Impetigo is an infectious disease that begins with small blisters; within hours these burst and produce a discharge which forms a golden crust on the skin. Impetigo occurs mainly on the face.

13 Molluscum contagiosum is a virus infection that produces painless pink or yellowish pimples in the genital

area or sometimes on the face and shoulders. It may be transmitted sexually or by communal bathing.

14 Prickly heat, or heat rash, occurs on damp parts of the body that are usually covered by clothing, particularly the groin and armpits.

15 Psoriasis features bright red patches covered with loose silvery scales, particularly on the scalp, elbows, knees, and lower back. The condition is sometimes itchy, but is not contagious.

16 Scabies, also aptly called the itch, features intense itching, especially at night. The cause is infestation by tiny mites, spread by close contact.

17 Shingles, or herpes

zoster, is a virus disease that produces blisters along the line of a nerve on the face or trunk. Pain in the affected area may be severe; the blisters burst and dry into crusts. Herpes zoster may cause scarring, and can be debilitating.

18 Skin cancers may occur on many parts of the body, but the most usual sites are the face and the backs of the hands. (See also next page.)

19 Sunburn chiefly affects the nose, neck, shoulders, chest, and back (see also page 80).

20 Warts may appear anywhere on the body (see next page).

Warts

These are benign skin growths. Different types may appear on hands, soles of feet, face, and in the anal-genital region, but all are probably due to one kind of virus. Warts may remain invisible for long periods, become prominent, then regress, only to reappear years later. Anyone can get warts, but young skin, being thin, is especially prone. Folklore recipes for charming away warts sometimes seem to work, but coincidence or psychology may play a part in this. Doctors can attack stubborn warts with freezing or cautery, especially if they are painful or cosmetically awkward.

Birthmarks, moles, and scars

Many people have disfiguring nevi (birthmarks) or scars. Nevii result from enlarged blood vessels in skin or an area of dark pigmentation. Moles are brown; strawberry nevi dark red; portwine stains pink to purple. Such marks are most noticeable when on the face. Strawberry nevi and the paler birthmarks tend to fade in early childhood. Portwine stains, moles, and scars persist. Most can be concealed by special cosmetics that match skin color. Other treatments include camouflage tattooing and dermabrasion.

Cysts

Cysts are sacs containing liquid or semisolid matter. Sebaceous cysts, which develop when sebaceous glands become blocked, are a type often found in the skin, especially on the back, head, and scrotum. They are firm, round, movable lumps that grow slowly but can grow as large as a walnut. Unless they are obvious and unsightly they may need no treatment. But a sebaceous cyst may become infected and inflamed. A doctor can drain the contents of the cyst and treat the area with antibiotic ointment. Large sebaceous cysts can be removed.

Skin cancers

Skin cancers occur mainly in light-skinned people long exposed to strong sunlight, or in anyone who has suffered from considerable exposure to X-rays or substances that include toxic chemicals. Different

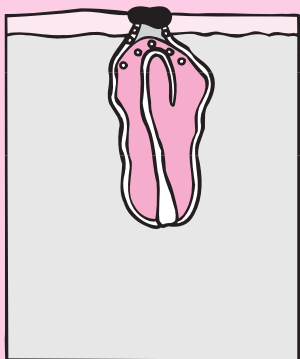
signs include: scaly, crusted, wartlike lesions on freckled skin in solar keratosis (a precancerous condition); an ulcer on the face (rodent ulcer); a fast-growing lump that may break down and bleed (epithelioma); and changes in a mole, such as

itching, darkening, inflammation, or ulceration (melanoma). Many skin cancers have rolled edges. Most types of skin cancer are treatable, especially if they are diagnosed early and action is taken very promptly.

Blackheads

A blackhead forms when a hard, waxy plug of sebum derived from a sebaceous gland in the skin blocks the gland opening. The plug may blacken, in contact with air and dust, producing a blackhead. (If the plug does not darken it is known as a whitehead.) To remove unsightly blackheads, try soaking the skin in warm water. This helps to open pores in the skin and so tends to loosen any sebum plugs present. A trained person may be able to gently squeeze or wipe out the blackheads. This is most effective when the plugs are recently formed.

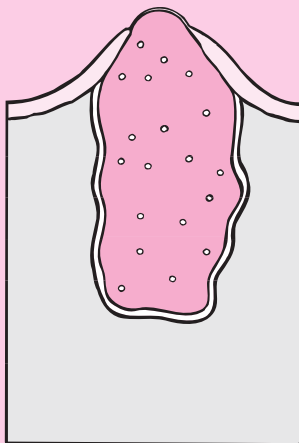
Cross-section of blackhead



Boils

These painful, pus-filled lumps may develop if bacteria deeply invade a hair follicle and nearby tissue. Early on, a boil is round and red, and nearby skin is swollen and tender. Later it produces a conical pus-filled head (carbuncles are multiheaded boils). Repeated soaking in warm water speeds this process and the boil usually bursts. Absorb the pus on a piece of gauze, wash the area, dab dry, add antibiotic cream, and cover with a sterile gauze pad. If healing takes more than a few days see a doctor. Never squeeze a boil.

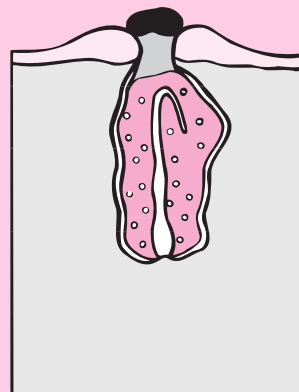
Cross-section of boil



Acne

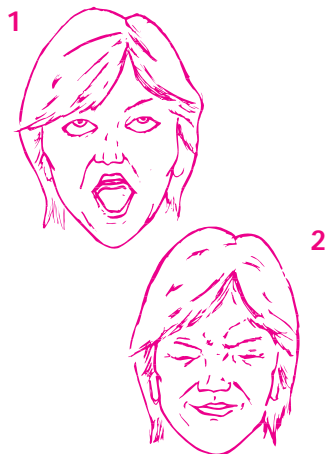
This involves small, inflamed swellings that develop into pustules. Acne tends to occur in skin where blackheads have blocked sebaceous glands and these have become infected. Acne mostly affects the face, neck, shoulders, and back. It occurs mainly in adolescence and before menstruation—times when hormonal activity narrows the necks of sebaceous glands. Minimize acne by washing the skin twice a day with antiseptic soap and exposing it to sunlight. Various proprietary anti-acne creams and lotions are available at pharmacies.

Cross-section of acne pustule



Since marks on the face are so easily seen by others, and often difficult to disguise effectively, problems with facial skin can cause severe distress. The troubles may range from birthmarks or infections to disorders that arise from poor hygiene or lack of proper skin care. The state of the skin, particularly that on the face, often reflects the state of health in the rest of the body. So a poor diet, inadequate

exercise, insufficient sleep, stress, and overwork can all have adverse effects on the condition and appearance of the face. Many problems affecting facial skin can be prevented, alleviated, or cured by careful attention to whole body health and to facial hygiene in particular (see previous pages for further information on blackheads, sunburn, acne, viral infections, and birthmarks).



Exercises for the face

Isometric exercises help to keep the muscles of the face supple and in good condition. They are quite strenuous for the muscles concerned, so only do each exercise once a day and maintain each position for a maximum of five or six seconds.

- 1** Open your mouth and eyes wide so that your facial muscles are as fully stretched as possible.
- 2** Screw up your eyes and mouth and wrinkle your nose so that your facial muscles are contracted.

Care of facial skin

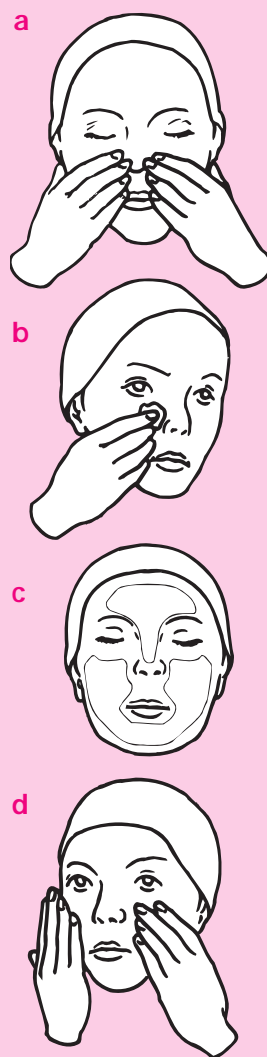
A facial is a complete cleansing program for your face. Facials are equally beneficial to men and women, to maintain a clean and healthy facial appearance.

a Wash your face thoroughly in mild soap and water, and then pat it dry with a soft towel so that the surface is not abraded.

b Cleanse your face with pads of cotton dipped in cleansing lotion; this will remove any stubborn traces of make-up and dirt, and will also clean dirt from deep down in the pores.

c Apply a face mask suited to your skin type. The mask may be in the form of liquid, cream, or gel, but any type will dry out excess oil, moisturize and soften the skin, and clean out impurities from the pores. The mask should be removed after the specified time, either by splashing the face with water or by peeling off the mask that has formed.

d Apply a gentle astringent lotion to your face to close and condition the pores.



Common facial problems

The illustration shows some of the face and skin problems that are, to a certain extent, under your own control. If you have a severe infection, see your doctor.

1 Wrinkles; these occur as an inevitable part of the aging process. But if you keep your skin moisturized and clean, and avoid too much exposure to bright sun if pale-skinned, they may not appear so early.

2 Dandruff of the eyebrows; this can be minimized by washing the eyebrows with a medicated soap.

3 Bags under the eyes; these are frequently the result of insufficient sleep, and are also an intrinsic part of aging.

4 Blackheads and open pores; thorough cleansing and the use of an astringent lotion will help to prevent this condition.

5 Sunburn; the nose is especially susceptible to sunburn, but all of the face (if your skin is light) should be protected with a sun cream before exposure to hot sun.

6 Dry skin; this often occurs naturally but is alleviated by the use of a moisturizer.

7 Acne; this condition often occurs on oily skin, and can be alleviated to some extent by thorough cleansing of the face several times a day and by anti-acne cream or lotion.

8 Unwanted hair; this can be removed temporarily by shaving or plucking, or permanently by laser treatment or electrolysis.

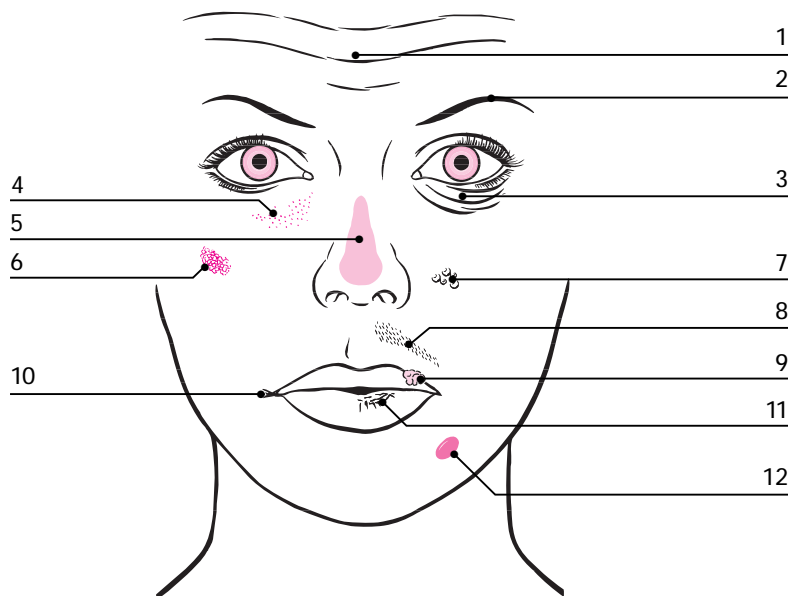9 Viral infections, such as herpes and dermatitis of the lips; these conditions may be relieved by the use of antihistamine

creams, but the advised action is to consult a doctor.

10 Corner cracks on the lips; these may be caused by illfitting dentures, by fungal infection, or by vitamin deficiency. The lips should be kept dry to enable the cracks to heal.

11 Chapped lips; these are often the result of exposure to wind, and can be alleviated by using a lip salve.

12 Birthmarks; even very severe birthmarks can be camouflaged by carefully applied cosmetics. Beauty therapists often specialize in this problem.



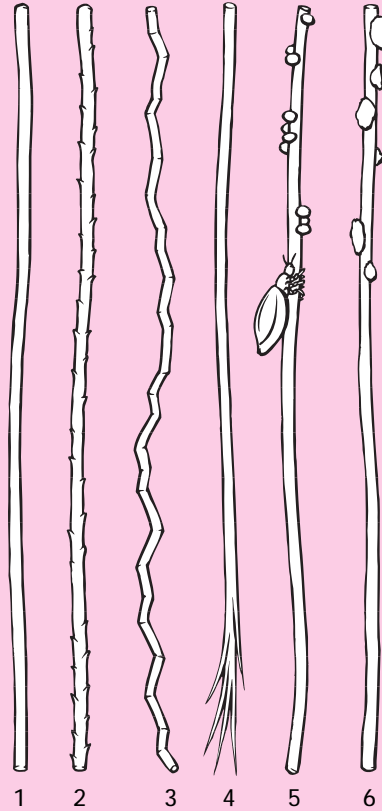
Common hair problems

This illustration shows some of the common problems that may affect your hair.

1 Healthy hair: the coating of the hair is smooth, giving it a shiny appearance, and there are no kinks or broken portions in the hair. Healthy hair is either slightly pointed at the end, or blunt if it has recently been cut or trimmed.

2 Dry, brittle hair with a ruffled appearance is caused by the disturbance of the tiny scales that coat the shaft of the hair. This kind of damage may be caused by overheating with dryers or heated rollers, or by frequent bleaching or lightening of the hair. This dries out the natural oils on it, which derive from the skin.

3 Damaged and frizzy hair. The hair can be damaged in this way by too-frequent use of permanent waves or by careless combing. Backcombing ruffles the scales of the hair; vigorous brushing while the hair is wet damages



and stretches it. Hair should be combed gently toward the tips, beginning near them and slowly working further up the hair with each stroke as the tangles are removed.

4 Split ends are caused by the use of rubber bands, careless combing, or lack of cutting. The best treatment is a trim. Lotions which purport to re-seal split ends may be ineffective, and usually so are attempts to burn them off.

5 Hair with lice and nits (louse eggs). Once these are contracted they can be very difficult to remove, so if there is an epidemic, for instance at a child's school, keep all the family's hair short and inspect it regularly.

6 Dandruff (see below).

Dandruff

Dandruff, or scurf, is the flaking of dead skin from the scalp, which causes an unsightly white dust on the scalp and hair. Dandruff is a very common complaint; most people are likely to experience this problem at some time. Most cases of dandruff can be controlled by washing the hair frequently using a reliable, medicated, anti-dandruff shampoo.

Nail problems

This illustration shows some of the common problems that affect fingernails (and toenails), and which can usually be prevented or alleviated by good nail care (see page 93) and general hygiene.

1 Ridges on the fingernails can occur as a result of injury or damage, for example, if the fingers have been crushed in an accident or through heavy manual work. Ridges can also occur due to damage by overenthusiastic shaping of the cuticles, especially if this is done with a metal instrument.

2 Damaged cuticles (see above) may be caused by attempts to shape them with a sharp instrument such as a scissor blade.

3 Cloudy nail; this may occur if nail polish is left on the fingernails for too long, or if an alcohol-based polish remover is frequently used. The condition can be alleviated by massaging the nails with one of the over-the-counter nail preparations—these usually contain lanolin

and protein—and then polishing them with a soft buffer-type cloth.

4 Hangnail is a sliver of nail or hard skin that projects beyond the rest of the nail and causes snagging. It can be removed by clipping carefully with scissors.

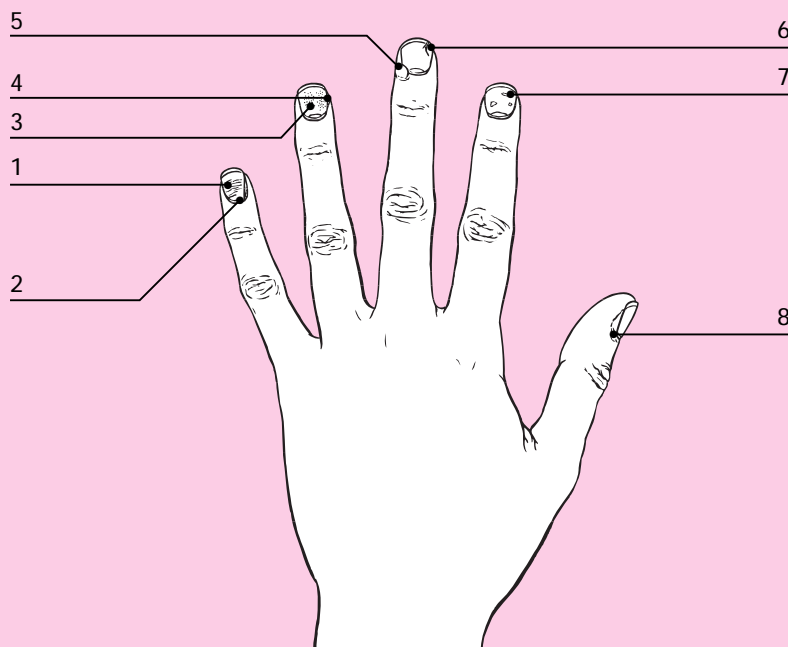
5 Whitlow is an extremely painful boil-like infection that grows under or near the fingernail. Whitlows can be bathed and poulticed to soften them but will generally require lancing by a doctor.

6 Broken nails should ideally be filed down

immediately. If the break is very close to the skin a special liquid can be painted over the break, strengthening the nail at that point.

7 White spots can appear on the nails as a result of damage to the nail root and bed. Like ridges and other marks, they move toward the free end as the nail grows, and are eventually trimmed off.

8 Sore skin around the nails is often caused by picking at rough edges of the nails or at uneven cuticles. Keep the nails well trimmed.



Adipose tissue Connective tissue containing numerous fat cells.

Adrenal glands (*or* Suprarenal glands) Endocrine glands located on each kidney. The cortex and medulla produce a range of hormones.

Afferent Directed toward a central organ or part of the body.

Alimentary canal (*or* Gastrointestinal tract *or* Gut) The digestive tract: a tube starting at the mouth and ending at the anus.

Anus The lower end of the rectum, forming the outlet of the alimentary canal.

Aorta The largest artery, arising from the left ventricle of the heart.

Appendix (*or* Vermiform appendix) A short, wormlike tube opening into the cecum but closed at the other end. It contains lymphoid tissue, which is involved in immunity.

Arteriole A small artery supplying blood from a main artery to a capillary.

Artery A blood vessel transporting blood from the heart to elsewhere in the body.

Atrioventricular valve (*or* AV valve) A valve between a ventricle and an atrium. The right atrioventricular valve (*or* tricuspid valve) has three cusps. The left atrioventricular

valve (mitral valve or bicuspid valve) has two cusps.

Auditory Relating to hearing.

Axillary Relating to the armpit.

Backbone See **Vertebral column**.

Basal ganglia Paired structures deep in the forebrain: they help coordinate and control willed muscle movements.

Basophil A type of white blood cell that is readily stained by basic dyes.

Biceps A muscle with two heads: biceps brachii in the upper arm and biceps femoris in the thigh.

Bile ducts Tiny tubes that carry bile (a liver secretion) from the liver to the duodenum.

Bladder A sac, especially the muscular bag inside the pelvis where urine collects before being expelled from the body.

Blood A sticky red fluid consisting of colorless plasma, red blood cells (Erythrocytes), white blood cells (Leukocytes), and platelets (thrombocytes).

Blood pressure The pressure of blood against blood-vessel walls, especially artery walls.

Bone The hard, dense connective tissue that forms the skeleton's components.

Bone marrow Soft red and yellow substances that fill cavities in bone.

Bowel See **Large intestine**.

Brain The body's chief control center, consisting of billions of interconnected nerve cells.

Brainstem A stalklike part of the brain, between the cerebrum and spinal cord. It contains the midbrain, pons, and medulla oblongata.

Breast A female breast consists mainly of a mammary (milk-secreting) gland embedded in fatty tissue.

Breastbone See **Sternum**.

Bronchiole A small subdivision of a bronchus, ending in tiny air sacs called alveoli.

Bronchus The main tubes branching from the lower end of the trachea and forming the main airways to and from the lungs (plural: bronchi).

Capillary The tiniest type of blood vessel, connecting an arteriole and a venule.

Cardiac Relating to the heart.

Cardiovascular Relating to the heart and blood circulatory system.

Cartilage Gristle: dense, white connective tissue cushioning bones.

Cecum The first part of the large intestine, forming a blind pouch.

Cell The basic unit of the body, usually comprising an outer membrane, cytoplasm, a nucleus, and organelles.

Central nervous system

(CNS) The brain and spinal cord.

Cerebellum The largest part of the hindbrain. It helps coordinate muscular movements.

Cerebral cortex The cerebrum's thin outer layer of gray matter.

Cerebral hemisphere Either of the two halves of the cerebrum.

Cerebrospinal fluid A clear fluid filling the brain's ventricles and surrounding the brain and spinal cord to protect them from injury.

Cerebrum The upper, major part of the brain, comprising cerebral hemispheres and diencephalon.

Cervix A neck, especially the neck of the uterus (womb) where it opens into the vagina.

Clavicle Either of the two collarbones.

Clitoris An erectile, pea-sized organ above the opening of the vagina; it is highly sensitive and is involved in female sexual response.

CNS See **Central nervous system**.

Coccyx Four fused vertebrae forming the "tail" of the backbone.

Collagen A fibrous protein that is a major constituent of connective tissue.

Colon The part of the large intestine between the cecum and rectum.

Connective tissue Tissue that supports, binds, or separates more specialized body tissues or acts as packing.

Corium See **Dermis**.

Cornea The transparent circular area at the front of the eye, which acts as a lens.

Coronary arteries Supply the heart muscle.

Corpuscles A term often used for red and white blood cells.

Cortex The outer layer of the brain.

Cranial nerves Twelve pairs of nerves linking the underside of the brain with parts of the head, neck, and thorax.

Cranium The part of the skull that contains the brain.

Cutaneous Relating to the skin.

Cuticle See **Epidermis**.

Deoxyribonucleic acid (DNA) A nucleic acid in the cell's chromosomes containing the cell's coded genetic instructions.

Dermis (*or* Corium) The layer of skin below the epidermis, containing nerves, blood vessels, glands, and hair follicles.

Diaphragm A muscular sheet used in breathing. It separates the thorax (chest) and abdomen (belly).

Digestion The chemical and mechanical breakdown of foods into substances that can be absorbed by the body.

DNA See **Deoxyribonucleic acid**.

Duodenum The upper part of the small intestine, where most chemical digestion takes place.

Ejaculation The discharging of semen from the penis.

Endocardium The membrane that lines the heart and the heart valves.

Endothelium The cell layer that lines the inside of the heart, blood vessels, and lymph vessels.

Enzymes Biological catalysts: proteins that speed up chemical reactions without undergoing change themselves.

Epidermis (*or* Cuticle) The skin's outer layer.

Epiglottis A cartilage flap behind the tongue that is closed during swallowing to stop food from entering the larynx.

Epiphysis See **Pineal gland**.

Epithelium The cell layer covering the body, and lining the alimentary canal and respiratory and urinary tracts.

Erythrocytes Red blood cells.

Esophagus (*or* Gullet) The muscular tube through which food travels between the pharynx and the stomach.

Fallopian tubes (or Uterine tubes or Oviducts) The tubes through which ova (eggs) travel from the ovaries to the uterus.

Femur The thigh bone: the long bone between the hip and the knee.

Follicle A small secreting cavity or sac. Ova (egg cells) develop in follicles in the female ovaries.

Forebrain The front part of the brain comprising diencephalon and telencephalon.

Gallbladder A pear-shaped bag where bile is stored, below the liver.

Gametes Sex cells: sperm in males; ova in females.

Gastric Of the stomach.

Gastrointestinal tract See **Alimentary canal**.

Genes Basic biological hereditary units, consisting of DNA, located on chromosomes.

Genitalia Sex organs.

Gland A structure that synthesizes and secretes a fluid.

Gonads Primary reproductive organs: the ovaries and testes.

Granulocytes White blood cells with cytoplasm that contains granules: basophils, eosinophils, and monocytes.

Gray matter The darker tissue of the brain and spinal cord mainly consisting of neurons' cell bodies and dendrites.

Gullet See **Esophagus**.

Gut See **Alimentary canal**.

Heart The hollow, muscular, fist-sized organ that pumps blood around the body.

Hemoglobin The iron-rich, oxygen-transporting pigment in red blood cells that gives them their color.

Hepatic Relating to the liver.

Hepatic portal vein See **Portal vein**.

Hindbrain Brain structures below the midbrain, comprising the pons, medulla oblongata, and cerebellum.

Hormones Chemical substances released into the blood by endocrine glands to influence organs or tissues in other parts of the body.

Hypophysis See **Pituitary gland**.

Hypothalamus A part of the brain with endocrine functions.

Ileum The last part of the small intestine.

Immune system The body's defense system against infective organisms or other foreign bodies. It includes the lymphatic system.

Involuntary muscle Muscle that is not under conscious control. See also **Smooth muscle**.

Jejunum The middle part of the small intestine.

Joint The junction between bones.

Karyotype The chromosome complement of a person or species: the genome.

Kidney A bean-shaped organ that filters wastes from blood to form urine.

Lactation Milk production by the mammary glands.

Large intestine (or Bowel) The lower part of the alimentary canal, comprising the cecum, colon, and rectum.

Larynx The cartilaginous voice box.

Leukocytes White blood cells. They attack invading microorganisms and help to combat injuries.

Ligament Fibrous tissue that connects bones.

Liver The largest organ in the body, it is involved in various metabolic processes.

Lungs The two organs of respiration, filling most of the chest cavity inside the rib cage and above the diaphragm.

Lymph A transparent fluid that leaks from blood vessels into tissue spaces.

Lymph gland See **Lymph node**.

Lymph node (or Lymph gland) One of the "knots" in the lymphatic system, which contain lymphocytes and macrophages that filter the lymph passing through the nodes.

Lymphatic system A network of lymph vessels and lymph nodes. Vessels collect lymph from body tissues and return it to the blood after harmful substances have been filtered out in the lymph nodes.

Mammary glands The milk-producing structures in the breast.

Medulla oblongata The lowest part of the brain stem, containing the vital centers that control heartbeat and respiration.

Meiosis A type of cell division that produces daughter cells (sperm and ova) each with half as many chromosomes as the parent cell.

Meninges Three protective membranes surrounding the brain and spinal cord.

Menopause When a woman ceases to have menstrual periods.

Menstruation Menstrual periods: the monthly flow of blood and uterine lining from the vagina of nonpregnant females of childbearing age.

Metabolism The array of continuous chemical changes that maintain life in the body.

Mitosis Ordinary cell division in which both daughter cells have as many chromosomes as the parent cell.

Mucous membranes The mucus-secreting linings of the

digestive, respiratory, reproductive, and urinary tracts.

Nasal Relating to the nose.

Nasal cavity The space inside the nose between the base of the skull and the roof of the mouth.

Nerve A bundle of nerve fibers (axons) that transmit impulses to (in the case of sensory nerves) or from (in the case of motor nerves) the central nervous system.

Nervous system The coordinated networks of neurons that control the body. It is divided into the central nervous system (brain and spinal cord), and the peripheral nervous system (the somatic and autonomic nervous systems).

Neuron (*or* Neurone) A nerve cell: the basic unit of the nervous system.

Neurone *See* **Neuron**.

Neurotransmitter A chemical released at nerve endings to transmit nerve impulses across synapses.

Nucleic acids Molecules that store genetic information.

Nucleus The control center of a cell, which contains coded genetic instructions.

Olfactory Relating to smell.

Optic Relating to the eye.

Organ A body part with different types of tissue that performs a particular task.

Organelles Tiny structures (miniorgans) in a cell's cytoplasm with particular tasks.

Ovaries Female sex organs that produce ova (eggs) and sex hormones.

Oviducts *See* **Fallopian tubes**.

Ovulation The release of a ripe egg from a female's ovary.

Ovum An egg; a female sex cell (plural: ova).

Palate The roof of the mouth.

Pancreas An abdominal organ that produces pancreatic juice and the hormones glucagon and insulin.

Parasympathetic nervous system The part of the autonomic nervous system that predominates when the body is at rest.

Parathyroid glands Four pea-sized endocrine glands on the thyroid gland. They produce parathyroid hormone, which controls blood calcium level.

Pelvis A bony basin formed by the two hip bones, the sacrum, and the coccyx.

Pericardium The double-layered membrane that encloses the heart and attaches it to the diaphragm and sternum.

Peristalsis Waves of muscular contraction that propel substances through passageways, such as the alimentary canal.

Phagocytes Types of leukocytes that engulf and destroy microorganisms and foreign bodies.

Pharynx The throat.

Pineal gland (or Epiphysis) An endocrine gland in the brain that secretes melatonin.

Pituitary gland (or Hypophysis) A three-lobed, pea-sized gland below the hypothalamus. It produces growth hormone, hormones that act on other endocrine glands, oxytocin, and ADH. It is often called the body's "master gland."

Plasma The fluid part of blood.

Pleura The membrane that covers the lungs (visceral pleura) and lines the chest wall (parietal pleura).

Plexus A network of nerves (or blood or lymph vessels).

Portal vein (or Hepatic portal vein) Drains blood from digestive organs to the liver.

Prostate gland A gland situated below the bladder in males. It produces a sperm-activating fluid that forms nearly a third of the semen's volume.

Pudendum See **Vulva**.

Pulmonary Relating to the lungs.

Receptor A structure, such as a sensory nerve ending, specialized to detect environmental stimuli.

Rectum The last part of the colon, where feces collects before leaving the body.

Reflex action The body's automatic response to a stimulus, such as blinking.

Renal Relating to the kidney.

Respiration 1) Breathing; 2) Taking in oxygen and giving out carbon dioxide; 3) Deriving energy from food with or without using oxygen.

Respiratory system In humans, the mouth, nose, pharynx, larynx, trachea, bronchi, bronchioles, alveoli, and lungs.

Ribonucleic acid (RNA) A nucleic acid concerned with protein synthesis.

Ribs Twelve pairs of bones that protect the chest cavity and assist breathing by moving up and out during inspiration and down and in during expiration.

Salivary glands The lingual, parotid, sublingual, and submandibular glands that produce saliva.

Serum Blood plasma that does not contain clotting factors but does contain antibodies.

Sinus A cavity, such as the channels draining venous blood from the brain.

Skeleton The bony framework that protects and supports the body's soft tissues.

Skin The body's waterproof covering; its largest organ, comprising two main layers: the epidermis and dermis.

Small intestine The alimentary canal between the stomach and large intestine, comprising the duodenum, jejunum, and ileum. Most digestion occurs here.

Smooth muscle (or Unstriated muscle or Involuntary muscle) Muscle without striped fibers that automatically operates internal organs such as the stomach, bladder, and blood vessels.

Sphincter A ring-shaped muscle that contracts to close an orifice.

Spinal cord The cable of nerve tissue running down inside the vertebral column (spine) and linking the brain with nerves supplying most of the body.

Spine See **Vertebral column**.

Sternum The breastbone.

Subcutaneous tissue The sheet of connective tissue below the dermis.

Suprarenal glands See **Adrenal glands**.

Suture An immovable fibrous joint between the skull bones.

Taste buds Tiny sensory organs of the tongue and palate, distinguishing salty, sweet, sour, and bitter tastes.

Teeth Bonelike structures in the jaws. Different types (incisors, canines, premolars, molars) are specialized to tear, crush, and/or grind food.

Tendons Bands of fibrous connective tissue joining muscles to bones.

Testis (*or* Testicle) One of a pair of primary male sex organs that manufacture sperm (plural: testes).

Thalamus A brain structure above the hypothalamus. It sends sensory impulses to the cerebral cortex, links sensations with emotions, and affects consciousness.

Thymus An endocrine gland located behind the sternum. It produces thymosin.

Thyroid An endocrine gland at the front of the neck, producing thyroid hormone.

Tissue A collection of similar cells that perform a particular task.

Trachea (*or* Windpipe) The tube between the larynx and the bronchi.

Tubule A tiny tube.

Tunica A tissue layer forming a coating. Blood vessels have three such layers (intima, media, adventitia).

Unstriated muscle *See* **Smooth muscle**.

Ureter The tube conveying urine from a kidney to the bladder.

Urethra The passage taking urine from the bladder to the body's exterior.

Urinary system The kidneys, ureters, bladder, and urethra.

Urine Liquid waste excreted by the kidneys.

Uterine tubes *See* **Fallopian tubes**.

Uterus (*or* Womb) A hollow muscular organ located above the bladder. Inside it, a fertilized ovum develops into a fetus.

Uvula A conical tag hanging from the back of the palate. It helps to keep food out of the nasal cavities.

Vagina The muscular passage between the vulva and cervix (neck of the uterus).

Vascular Relating to or richly supplied with vessels, especially blood vessels.

Vein A blood vessel that transports blood from capillaries back to the heart. Veins contain valves to prevent the backflow of blood.

Venous Relating to veins.

Ventricle A cavity: one of the two lower chambers of the heart.

Venule A small vein.

Vermiform appendix *See* **Appendix**.

Vertebra A bone of the vertebral column (plural: vertebrae).

Vertebral column (*or* Backbone *or* Spine) The column of vertebrae between the skull and the hip bones, supporting the body and shielding the spinal cord. It has five sections: cervical, thoracic, lumbar, sacral, and coccygeal.

Vestibule A space before a passage begins, as in the inner ear beyond the oval window, between the semicircular ducts and cochlea.

Vocal cords Two belts of tissue stretched across the larynx which produce sounds when air rushes past them.

Vulva (*or* Pudendum) The external female genitals.

White matter The paler tissue of the brain and spinal cord comprised mainly of myelin-sheathed nerve fibers.

Windpipe *See* **Trachea**.

Womb *See* **Uterus**.

There is a lot of useful information on the internet. There are also many sites that are fun to use. Remember that you may be able to get information on a particular topic by using a search engine such as Google (<http://www.google.com>). Some of the sites that are found in this way may be very useful, others not. Below is a selection of Web sites related to the material covered by this book. Most are illustrated, and they are mainly of the type that provides useful facts.

Facts On File, Inc. *takes no responsibility for the information contained within these Web sites. All the sites were accessible in January 2005.*

Access Excellence

National Health Museum
Links to a range of resources in biology, biotechnology, and health issues.
<http://www.accessexcellence.org>

Anatomy of the Human Body: Gray's Anatomy

Online version of the classic *Gray's Anatomy of the Human Body*, containing over 13,000 entries and 1,200 images.
<http://www.bartleby.com/107/>

Ask a Biologist

Arizona State University, Life Sciences Visualization Group answers email questions for students grades K–12.
<http://askbiologist.asu.edu>

BIOME

A guide to quality-checked internet resources in health and life sciences.
<http://biome.ac.uk>

Health Sciences and Human Services Library

Provides links to selected Web sites about all aspects of Life Sciences that may be useful to both students and researchers.
<http://www.hshsl.umaryland.edu/resources/lifesciences.html>

Human Anatomy Online

Interactive resource, with visual keys to text on the human body; also visual images and animations.
<http://www.innerbody.com>

Open Directory Project: Anatomy

Comprehensive list of internet resources.
http://dmoz.org/Health/Medicine/Basic_Sciences/Anatomy/

Open Directory Project: Conditions and diseases

Comprehensive list of internet resources.
http://dmoz.org/Health/Conditions_and_Diseases/

Open Directory Project: The Senses

Comprehensive list of internet resources.
<http://dmoz.org/Health/Senses/>

University of Texas: BioTech Life Sciences Resources and Reference Tools

Enriching knowledge of biology and chemistry, for everyone from high school students to professional researchers. The Dictionary and Science Resources are particularly useful.
<http://biotech.icmb.utexas.edu>

A

acne 94, 97, 99
afferent (sensory) nerves 8, 9
allergies,
 ear problems 58, 59
 eye problems 34, 39
 nose and mouth problems 78, 79
 skin problems 94, 95
ampulla 61, 63
aqueous humor 20, 21, 26, 28
auditory area of brain 12
auditory (Eustachian) tube 8, 45, 46, 47, 48, 50
 problems 57, 58, 59, 79
auditory nerve 8, 46, 47
auricle (ear flap, pinna) 7, 8, 9, 44, 46, 52, 57
autonomic nervous system 9, 89

B

balance 7, 8, 9, 60, 62
 brain 12
 ear structure 45, 46, 47, 50
 problems 57, 59
basilar membrane 7, 51, 54, 55
birthmarks 94, 96, 98, 99
blindness 40
blinking 23
body hair 91
boils 94, 97
brain 7, 8, 9
 balance 62, 63
 CNS 11
 cranial nerves 13
 dermatomes 15, 87
 eyes 20

nerve pathways 14
olfactory areas 68
reflex arcs 19
sensory areas 12
sensory neurons 10
smell 64, 70, 71
taste 64, 76, 77
vestibulocochlear nerve 45
vision 27, 32

C

cancers, skin 80, 95, 96
cartilages, nose 66, 67, 68
cataract 40, 41
cells,
 hair 90
 nails 92, 93
 skin 82, 83, 85
central nervous system (CNS) 8, 10, 11, 18
cerebral hemispheres 7, 12, 64
chemoreceptors 7
chemosenses 64
choroid 8, 20, 21, 26, 29
ciliary muscles 20, 21, 24, 29
 focusing 26, 27
cochlea 8, 51
 ear structure 46, 47, 49, 50
 hearing process 53, 54
 organ of Corti 55
colorblindness 40, 43
color vision 8, 31
cones 7, 8, 20, 30, 31
 colorblindness 40
 yellow spot 29
conjunctiva 20, 21
 eye problems 39, 40
conjunctivitis 34, 38, 40, 41

cornea 6, 8, 29
 aqueous humor 28
 eye structure 20, 21
 focusing 26
cortex 7, 12
 nerve pathways 14
 reflex arcs 19
 smell perception 71
 taste 77
 visual nerve pathways 32
cranial nerves 8, 13
crista ampullaris 61, 63

D

dandruff 100
deafness 47, 57, 58, 59, 79
dermatomes 8, 15, 87
dermis (corium) 6, 8, 9, 81, 84
 hair 90
 touch 86
dorsal nerve roots 11

E

ear canal 7, 8, 9, 44
 ear problems 58
 ear structure 45, 46, 47
 hearing 52
earache 47, 57, 58, 59
ears 7, 8, 44–63
 exteroceptors 6
 problems 56–59, 79
 structure 44, 45, 46, 48, 50, 53
eczema 94
effectors 18, 19
epidermis (cuticle) 6, 8, 9, 81
 nails 92
 structure 82–83
exteroceptors 6, 16

eyeball 6, 8, 9
 movements 19, 25
 muscles 24-25
 parts 26
 structure 20, 21
 vitreous humor 28
 eyelids 22, 23
 eye problems 34, 38, 39
 skin 80, 84
 eyes 7, 8, 9, 20-43
 balance 62
 care 34, 37
 color 22
 exteroceptors 6
 injury 37
 nerve pathways 14
 problems 34, 35, 36-41
 structure 21

F
 far sight (hypermetropia) 42
 fingerprints 81
 focusing 6-7, 21, 26-27
 eye problems 36, 42
 fovea centralis 8, 29, 30

G
 ganglion cells 30
 genes 43, 44, 90
 glaucoma 28, 37, 40, 41
 Golgi tendon organs 17
 goosebumps 89

H
 hair 6, 80, 81, 90-91
 body 91
 facial skin disorders 99
 problems 100
 temperature regulation 89

hair cells,
 balance 61, 63
 hearing loss 57
 olfactory areas 68, 69
 organ of Corti 55
 smell and taste 64, 65
 smell perception 70, 71
 tongue 75, 76
 hair follicle 8, 81, 90
 dermis 84
 epidermis 82
 eyelid 39
 headaches 79
 hearing 8, 44-63
 impairment 57, 58, 59
 process 52-55
 hormones 94, 97
 hyoid bone 73
 hypothalamus 19

I
 incus 7, 9, 46, 47, 48, 49, 53
 infections,
 ears 56, 57, 58, 59
 nails 101
 nose and mouth 78, 79
 skin 94, 95, 98, 99
 inflammation 94, 95
 inheritance
 colorblindness 43
 ear flaps 44
 hair 90
 inner ear 7, 8, 9, 49, 50, 53
 ear problems 57, 59, 79
 ear structure 46, 47
 integumentary system 80
 interoceptors 6, 16
 iris 7, 8, 9, 22, 29
 aqueous humor 28
 eye structure 20, 21
 focusing 26

J
 joints 16, 62
K
 keratin,
 epidermis 82, 83
 hair 90
 nails 92
 Krause's end bulbs 16, 86

L
 lens 7, 8, 24, 28
 eye structure 20, 21
 focusing 26, 27
 lenses, corrective 36, 37, 42
 limbic system 7

M
 macula 8, 29, 60, 61, 62, 63
 malleus 7, 9, 49
 ear structure 46, 47, 48
 hearing 53
 mechanoreceptors 6, 16
 Meissner's corpuscles 16, 86
 melanin 82, 83
 Menière's disease 57
 middle ear 7, 8, 9, 48, 53
 ear structure 45, 46, 47
 hearing 53
 problems 58, 79
 mouth 72
 infections 78, 79
 smell and taste 64
 taste buds 76
 tongue 73
 movements
 balance 60, 62, 63
 eyeball muscles 25
 sensory receptors 16
 mucous membranes 78

muscles
 eyeball 24-25, 40
 hair 90
 reflex arcs 18, 19
 sensory receptors 16, 17
 skin 81, 89
 tongue 73, 74

N

nails 6, 80, 84, 92-93, 101
 nasal cavity 7, 64, 67, 66, 68, 70, 73
 nerve endings 6, 10, 16
 touch 81, 84, 86
 nerve fibers
 olfactory areas 69, 70
 organ of Corti 55
 tongue 75
 nerve pathways 14
 reflex arcs 18, 19
 vision 32-33
 nerve signals (impulses) 7, 8, 9
 balance 50, 61, 63
 ear 51
 eyes 20
 hearing 46, 47
 olfactory areas 68, 69
 organ of Corti 55
 photoreceptors 30, 31
 sensory neurons 10
 smell 64, 65, 70, 71
 taste 64, 65, 76, 77
 visual pathways 32
 nerves 8
 dermatomes 87
 dermis 84
 nervous system 7
 neurons (nerve cells) 8, 9, 12
 motor 8, 11, 14, 18, 19
 sensory 10, 11, 18, 19

nose 7, 9, 66
 cranial nerves 13
 exteroceptors 6
 problems 78, 79
 smell 64, 70
 structure 66-67
 tear duct 22, 23
 nyctalopia (night blindness) 40

O

olfactory area of brain 12, 68, 69
 olfactory bulb 7, 64, 68, 69, 70
 olfactory membranes 7
 olfactory nerves 13, 68, 70, 71
 optic chiasma 32, 33
 optic disc (blind spot) 8, 9, 27, 29
 optic nerves 7, 13, 20, 21
 eyeball muscles 24
 focusing 27
 nerve pathways 32, 33
 orbit (eye socket) 6, 24, 25
 organ of Corti 7, 47, 51, 54, 55
 ossicles 7, 9, 49, 50, 79
 ear structure 47, 48, 50
 hearing process 53, 54
 nose and mouth
 otoliths 9, 61
 oval window 9, 46, 47, 50
 hearing process 53, 54
 ossicles 49

P

Pacinian corpuscles 16, 86
 pain
 dermatomes 15, 87
 ear problems 58

nerve endings 86
 nerve pathways 14
 reflex arcs 18
 pain receptors 16, 17, 85
 palate 7, 9
 nose 67, 68
 smell and taste 64
 taste buds 76
 tongue 73
 papillae 7, 9, 72, 74, 75, 76
 peripheral nervous system (PNS) 8, 9, 11, 13, 71
 photoreceptors 7, 8, 9, 20, 30
 position sense 46, 50, 60
 pressure receptors 6, 16, 85, 86
 proprioceptors (kinesthetic) 6, 16, 17, 62
 puncta 23
 pupil 6, 8, 9, 22, 29
 eye structure 20, 21
 focusing 26

R

receptor cells,
 olfactory areas 69
 tongue 75, 76
 reflex action 9, 18-19
 retina 7, 8, 9, 20, 21, 29, 30-31
 colorblindness 40
 focusing 27
 photoreceptors 30, 31
 problems 37, 40, 41
 visual nerve pathways 32
 vitreous humor 28
 rods 7, 9, 20, 30, 31
 round window 9, 46, 49, 50, 53, 54
 Ruffini's corpuscles 16, 86

S

sacculle 7, 9, 50, 60, 61, 62
 salivary glands 45, 73
 scent molecules 7, 70, 71
 Schlemm, canal of 28
 sclera 6, 9, 20, 21, 22, 26, 29
 eyeball muscles 24, 25
 sebaceous glands 6, 9, 81, 84
 skin problems 94, 96, 97
 semicircular canals 7, 9, 50
 balance 60, 61, 62, 63
 ear structure 46, 47
 sensory receptors 6, 16
 dermis 84, 85
 nerve pathways 14
 reflex arcs 18
 short sight (myopia) 42
 sinuses 67, 72, 78, 79
 skin (integument) 8, 9, 80–101
 balance 62
 dermatomes 87
 dermis 84–85
 epidermis 82–83
 exteroceptors 6
 hair 90–91
 nails 92–93
 nerve pathways 14
 pigmentation 83
 problems 94–99
 reflex arcs 18
 sensory receptors 16
 structure 81
 temperature 88–89
 touch 86–87
 smell 9, 13, 64–79
 perception 70–71
 sound waves 6, 7, 44, 46, 47, 51
 hearing 52–53, 54
 ossicles 49
 sensory receptors 16
 spinal cord 7, 8, 9
 CNS 11
 nerve pathways 14
 reflex arcs 18, 19
 sensory neurons 10
 stapes 7, 9, 46, 47, 49, 53
 organ of Corti 55
 subcutaneous layer 6, 9, 81, 85
 sunburn 80, 95, 99
 suspensory ligaments 20, 21
 sweat glands 6, 9, 81
 dermis 84, 85
 temperature control 88, 89

T

taste buds 9, 64, 74, 75, 76, 77
 taste (gustatory) sense 7, 9, 64–79
 brain 12
 tongue regions 77
 tear (lacrimal) glands 20, 21, 22, 23
 temperature control 6
 nerve pathways 14
 sensory receptors 16, 86
 skin 80, 81, 85, 88–89
 thalamus 7
 thermoreceptors 6, 16
 tinnitus 57
 tongue 7, 9, 72, 73, 74, 75
 exteroceptors 6
 smell and taste 64
 taste buds 76
 taste regions 77
 tonsils 72, 74

touch 6

 dermatomes 15, 87
 dermis 84
 nerve pathways 14
 skin 80
 touch (somatosensory)
 cortex 12, 14, 19, 87
 touch receptors 16, 81, 85, 86
 reflex arcs 18
 tympanic membrane (eardrum) 7, 8, 9, 46, 47, 48, 49, 50
 hearing 52, 53
 problems 57, 58, 79

U

utricle 7, 9, 50, 60, 61, 62

V

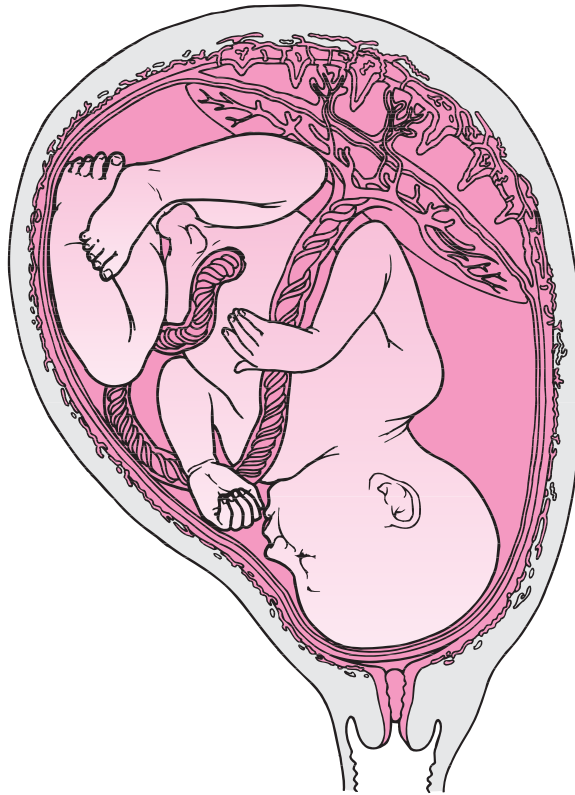
vertigo 57, 59
 vestibular system 7, 8, 9, 54, 60, 62
 brain 12
 vestibulocochlear nerve 13, 45, 63
 vibration detection,
 ear 7, 47, 49, 52, 53
 organ of Corti 55
 skin 6, 16, 86
 vision 9, 20–43
 problems 22, 36, 37
 visual cortex 12, 32, 33
 vitamin D 80, 82
 vitreous humor 20, 21, 28
 vocal cords 72

W

warts 95, 96
 waste excretion 80, 81, 85

THE FACTS ON FILE
ILLUSTRATED GUIDE TO
THE HUMAN BODY

REPRODUCTIVE SYSTEM



THE DIAGRAM GROUP

The Facts On File Illustrated Guide to the Human Body: Reproductive System

Copyright © 2005 The Diagram Group

Editorial: Lionel Bender, David Harding, Tom Jackson
Denis Kennedy, Gordon Lee, Jamie Stokes

Scientific consultant: Stephen Rudd

Design: Anthony Atherton, Richard Hummerstone,
Lee Lawrence, Kim Richardson, Ben White

Illustration: Pavel Kostal, Kathleen McDougall

Picture research: Neil McKenna

Indexer: Jane Parker

All rights reserved. No part of this book may be reproduced or utilized in any form or by any means, electronic or mechanical, including photocopying, recording, or by any information storage or retrieval systems, without permission in writing from the publisher. For information contact:

Facts On File, Inc.
132 West 31st Street
New York NY 10001

For Library of Congress Cataloging-in-Publication Data, please contact Facts On File, Inc.

ISBN: 0-8160-5985-3

Set ISBN: 0-8160-5979-9

Facts On File books are available at special discounts when purchased in bulk quantities for businesses, associations, institutions, or sales promotions. Please call our Special Sales Department in New York at 212/967-8800 or 800/322-8755.

You can find Facts On File on the World Wide Web at
<http://www.factsonfile.com>

Printed in the United States of America

EB Diagram 10 9 8 7 6 5 4 3 2 1

This book is printed on acid-free paper.

Note to the reader

This book is not intended to serve as a medical textbook for either physicians or patients. The information and advice it contains should not be used or relied upon without consulting the advice of a qualified physician. The publishers disclaim any responsibility for the accuracy of the information or advice that this book contains and any responsibility for any consequences that may result from any use or reliance thereon by the reader.

Contents

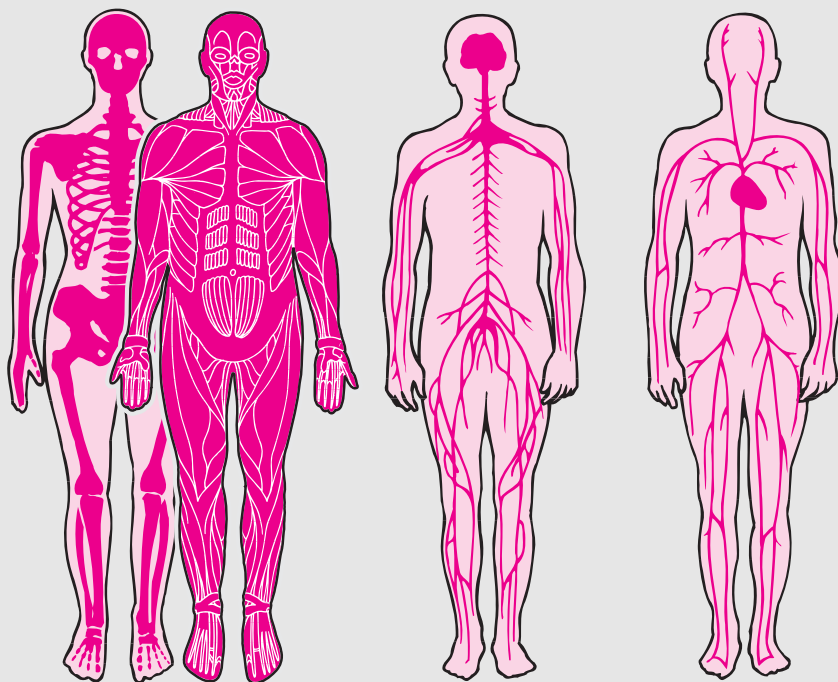
Introduction: About this book	4		
SECTION 1		SECTION 4	
REPRODUCTION		PREGNANCY	
Introduction	6	Introduction	58
Overview of reproduction	8	Overview of pregnancy	60
Reproductive system, female	10	Fertilization	62
Reproductive system, male	12	Development of the fertilized egg	64
Fertilization to birth	14	Early embryo	66
Reproductive hormones	16	Late embryo	68
Sexual development	18	Early fetus	70
Problems of puberty	20	Mid-term fetus	72
SECTION 2		Placenta	74
FEMALE SYSTEM		Full-term fetus	76
Introduction	22	Multiple pregnancies	78
Female reproductive organs	24	Changes in pregnancy	80
Production of eggs	26	Prenatal care	82
Ovary and follicles	28	Activity during pregnancy	84
Fallopian tubes and uterus	30	Contraception	86
Menstrual cycle	32	Sexual problems	88
Breasts	34	Sexual infections	90
Female sexual health	36	SECTION 5	
Menstrual problems 1	38	BIRTH AND GROWTH	
Menstrual problems 2	40	Introduction	92
Female system disorders	42	Delivery	94
SECTION 3		Birth problems	96
MALE SYSTEM		The newborn child	98
Introduction	44	Child development	100
Male reproductive organs	46	Glossary of the human body	102
Production of sperm	48	Web sites to visit	108
Testes	50	Index	109
Penis	52		
Male sexual health	54		
Male system disorders	56		

This book is a concise, illustrated guide to the anatomy, physiology, well-being, and disorders of the human reproductive system. It has been written and illustrated specially for students and laypeople interested in medicine, health, fitness, and first aid. The subject is dealt with in clear steps, so that the reader can steadily acquire a good overall understanding. Explanatory texts, diagrams, illustrations, captions, and fact boxes are combined to help readers grasp important information at a glance. A glossary of scientific and jargon words defines medical terms in everyday language. A list of Web sites provides links to other relevant sources of information, and the index enables quick access to articles.

There are five sections within the book. The first section gives an overview of reproduction and the parts of the body associated with sex and reproduction in males and females. Section 2 focuses on the female reproductive system, and section 3 on the male reproductive system. Section 4 deals with fertilization and growth of the fetus inside the mother's womb. The last section looks at the newborn baby itself. Within each section, normal structure and function are followed by principles of healthcare and hygiene. These are followed by a survey of the main disorders and diseases affecting the female or male reproductive system. Information is presented as double-page topics arranged in subsections.

Human body systems

This book is one of eight titles in THE FACTS ON FILE ILLUSTRATED GUIDE TO THE HUMAN BODY series, which looks at each of the major body systems in turn. Some of the titles in the series include more than one system. The skeletal and muscular systems, and the blood and lymphatic systems, for example, work in conjunction and so are treated together. There is a separate title for human cells and genetics, which are the building blocks and underlying chemistry of all body systems.



**Skeletal and
Muscular Systems**

**Brain and
Nervous System** **Heart and
Circulatory System**

Section 1: REPRODUCTION compares the male and female reproductive system, defines related key words, and looks at the hormones concerned with sexual characteristics and reproduction.

Section 2: FEMALE SYSTEM investigates the structure and function of organs of the female reproductive system and details the mechanism, function, and effects of the menstrual cycle.

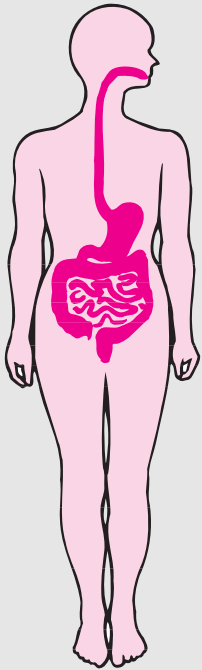
Section 3: MALE SYSTEM focuses on the structure and function of organs of the male reproductive system.

Section 4: PREGNANCY features the fusion of sperm and egg, development of the embryo and fetus, and the stages of pregnancy.


Section 5: BIRTH AND GROWTH looks at the process of birth and the gradual development of the newborn baby's physical and mental abilities during its first few years.

This book has been written by anatomy, physiology, and health experts for non-specialists. It can be used:


- as a general guide to the way the human body functions
- as a reference resource of images and text for use in schools, libraries, or in the home
- as a basis for examination preparation for students of human biology, medicine, nursing, child growth and development, family counseling and general hygiene and healthcare.



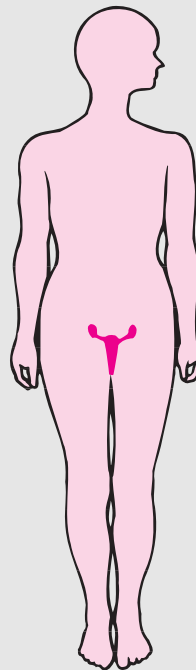
Digestive System



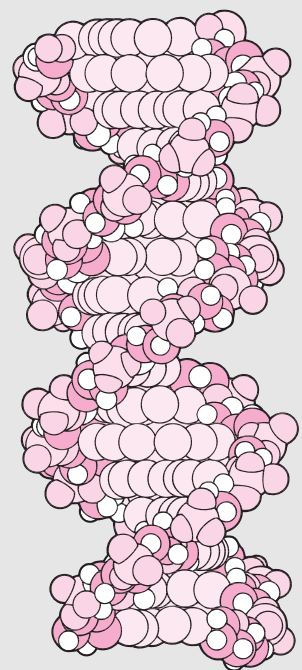
The Senses



Respiratory System



Reproductive System



Cells and Genetics

Often considered as part of the urogenital system, the reproductive system includes: male sex organs producing and emitting sperm; female sex organs producing ova for fertilization that then develop into embryos and fetuses; and mammary glands that produce milk for nourishing newborn babies.

Male genitals

These include two sperm-producing testes suspended in a sac (the scrotum) outside the main body cavity. Spermatozoa (sperm cells) produced by a special type of cell division in tubules inside the testes mature in ducts (the epididymides) and travel through two tubes (the vas deferentia) into the pelvic cavity. There, seminal fluid from the seminal vesicles and prostate gland mixes with spermatozoa before these are ejaculated as semen through the penis via the urethra.

External female genitals

Located below and in front of the pubic arch, the external female genitals include the mons pubis (a rounded pad of fatty tissue); labia majora and labia minora (liplike skin folds around the cleft into which the urethra and vagina open); clitoris (an erectile tissue that is similar in structure to the penis); vestibule of the vagina; bulb of the vestibule; and greater vestibular glands. These collectively make up the vulva or pudendum.

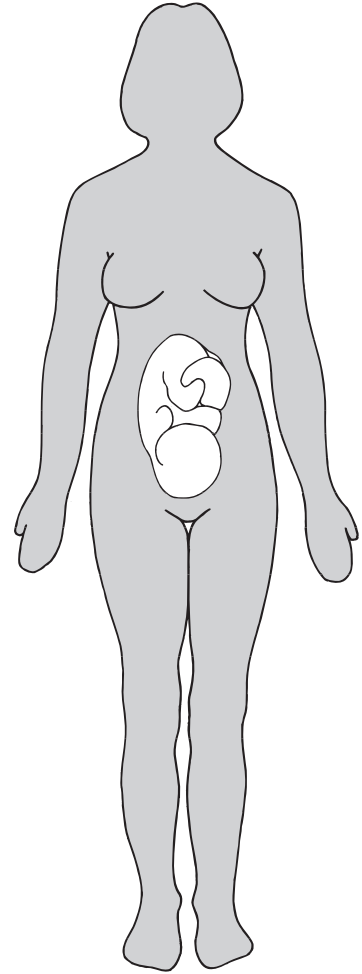
Internal female genitals

These lie inside the pelvis and are connected to external genitals via the birth canal or vagina. The vagina connects to the uterus (womb) via the cervix, a muscular opening at the base of the uterus. Two fallopian tubes or oviducts connect to each side of the upper uterus, each leading to an ovary. Ova (eggs) produced in the ovaries travel through the tubes to the uterus. A fertilized ovum implanted in the wall of the uterus develops into an embryo and then a fetus nourished by a placenta. Sperm enters the uterus via the vagina, which then also serves as a birth canal.

Breasts

These comprise mammary glands, fibrous tissue, and fatty tissue. After a woman has given birth, milk is produced by the mammary glands to be sucked from her nipples.

Reproduction



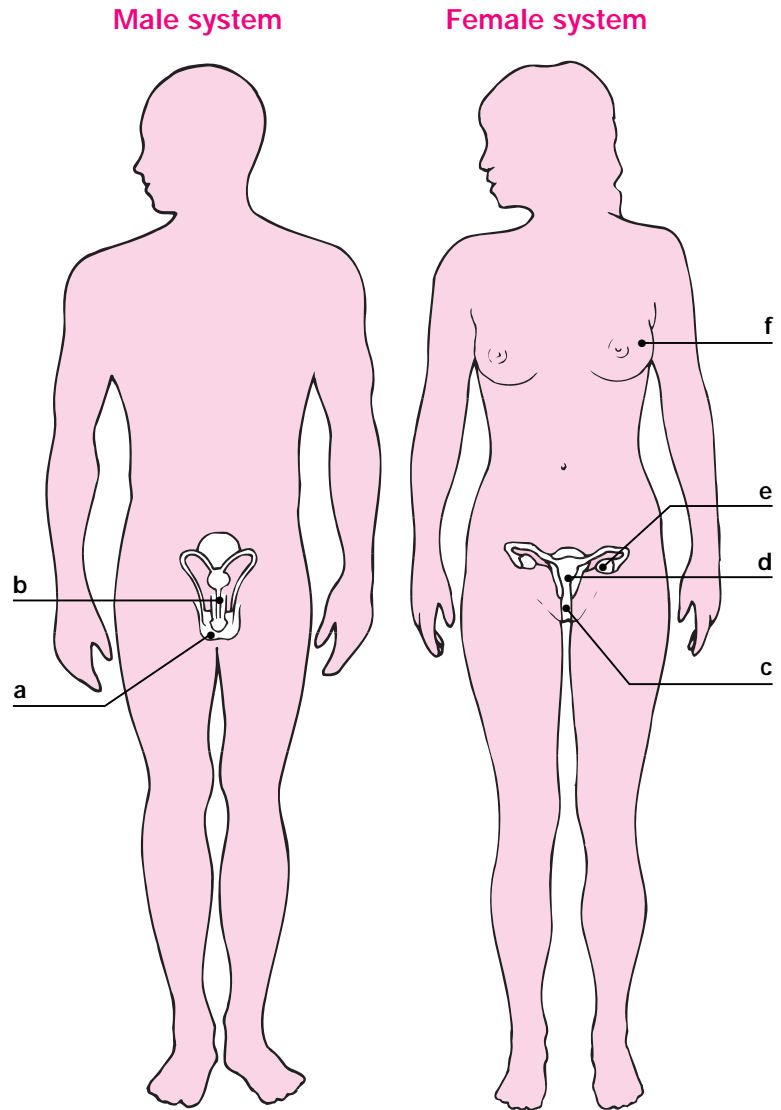
Humans, like nearly all other mammals, are viviparous. This means that developing young are nurtured inside the female's body, before being born at a relatively advanced stage of development.

Male and female reproductive system

The difference between the two sexes is based on how much an individual invests in each offspring. Male individuals invest nothing but genetic material in the next generation. They produce mobile sperm cells in their testes (**a**). These are released through the penis (**b**) into the female's vagina (**c**).

The sperm then carries its genetic material into the uterus (**d**) and fuses with a female sex cell or ovum. The ovum, produced in an ovary (**e**), contains the rest of the required genetic material and the nutrients needed for a new individual to begin to develop. In humans and most other mammals, this development takes place inside the uterus.

A temporary organ, called the placenta, connects the fetus to its mother's blood supply, which provides food and oxygen. Once the child is born, the female continues to supply food to the newborn by suckling it with milk-producing mammary glands inside the breasts (**f**).



Female reproductive system

These organs are devoted to producing female sex cells and to nurturing the developing embryo and fetus.

Primary organs

The female gonad is the ovary. Normally there are two ovaries, one on each side of the body. Ovaries produce gametes (sex cells). Female sex cells are called ova, or eggs.

Sex cells

Ova (singular: ovum) are large cells released by the ovaries during ovulation. An ovum contains many mitochondria (cellular power plants) and is coated in proteins, forming the pellucid area.

Hormones produced

The main female sex hormones are estrogens and progesterone. There are several estrogens of which estradiol is the most potent. Both types of hormone are produced by the ovaries.

Accessory organs

Ova travel from the ovaries along the fallopian tubes to the uterus. The uterus is connected to the external genitals via the vagina.

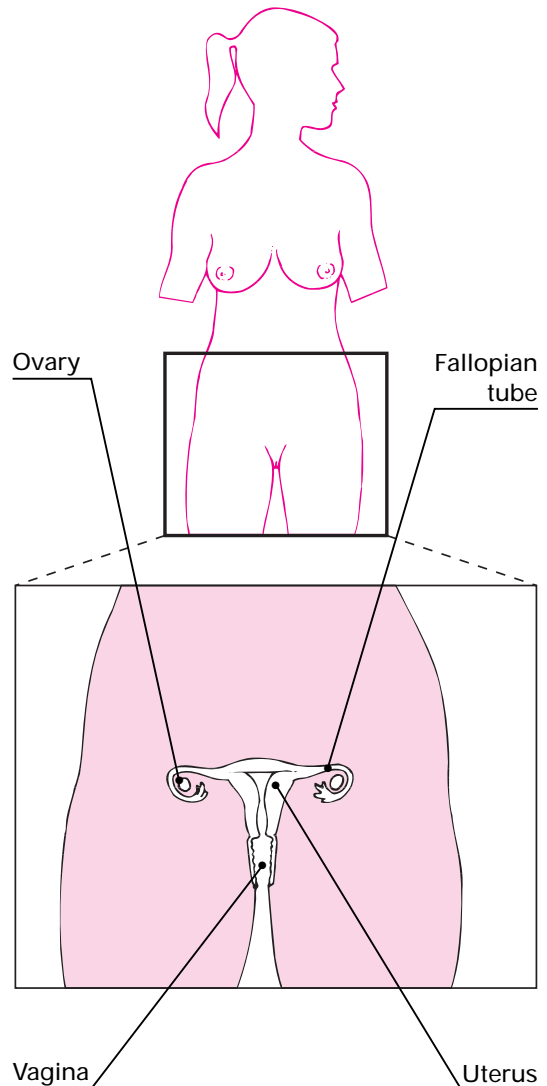
External genitalia

These comprise the vulva, which is made up of the labia, the clitoris, mons pubis, and the opening to the vagina.

Female reproduction

- Once fertilized the ovum becomes a zygote. This single cell develops into the embryo and placenta.
- Progesterone is produced by the placenta during pregnancy.

Female overview



Male reproductive system

These organs produce male gametes and deliver them to the female uterus.

Primary organs

The male gonad is the testis. Normally there are two testes contained in the scrotum, which hangs outside the body.

Sex cells

Male gametes are called spermatozoa. This is often shortened to sperm. The word sperm is also used to mean the ejaculated semen that contains the cells.

Hormones produced

The main male hormone is testosterone. It is produced by the testes.

Accessory organs

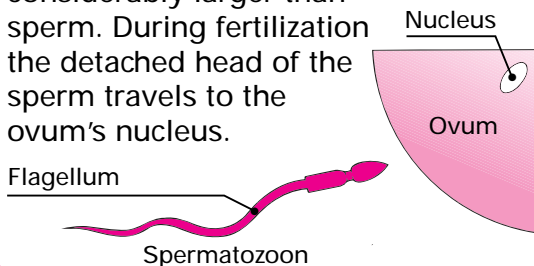
The sperm cells are stored in the epididymides. They travel along the vas deferentia to the seminal vesicles where they are mixed with liquid to form semen.

External genitalia

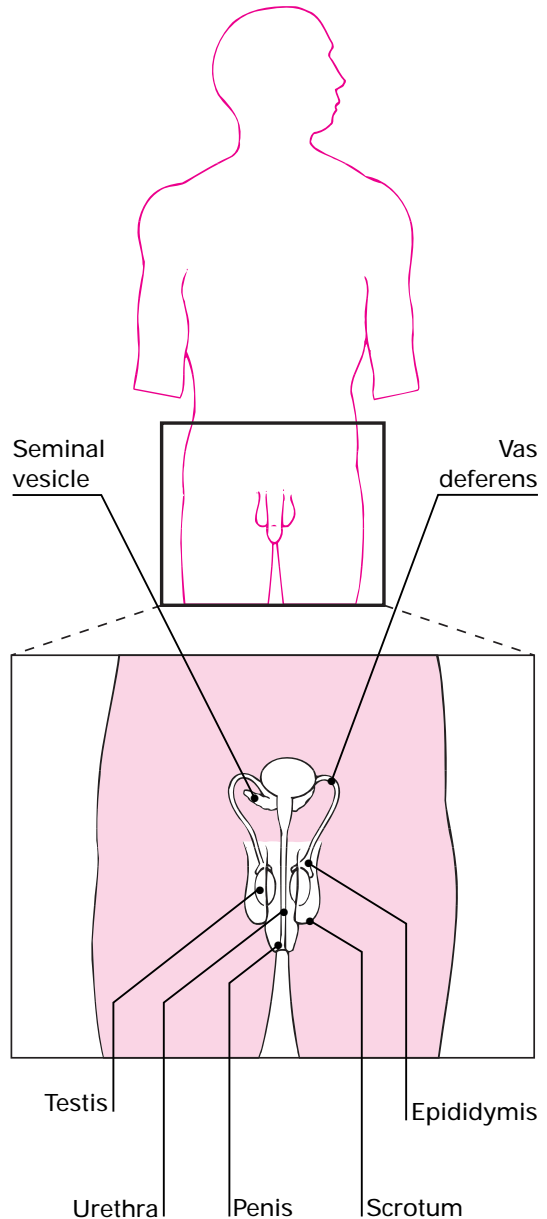
The semen is ejaculated through the urethra and out of the penis.

Sperm and ovum

Sperm cells are one of the few independently mobile body cell types. They are propelled by a tail-like flagellum. Ova are considerably larger than sperm. During fertilization the detached head of the sperm travels to the ovum's nucleus.



Male overview



Female reproductive system key words

Alveolus A small sac or cavity, occurring in the breasts.

Areola The pigmented ring around a nipple.

Bartholin's glands A pair of glands flanking the outlet of the vagina. They produce a lubricating fluid.

Breast A female breast consists mainly of a mammary (milk-secreting) gland embedded in fatty tissue. Each gland comprises many lobules linked by ducts leading to a nipple.

Cervix A muscular neck, especially the neck of the uterus (womb) where it opens into the vagina, or birth canal.

Clitoris An erectile, pea-sized organ above the opening of the vagina; it is highly sensitive to touch and is involved in the female sexual response.

Corpus albicans Scar tissue in the ovary formed after a corpus luteus has ceased its excretory activity.

Corpus luteum Yellow endocrine (hormone-producing) tissue formed in the ovary from a ruptured Graafian follicle.

Endometrium The mucous membrane that lines the uterus and is shed with blood during menstruation.

Estrogen A collective name for female sex hormones made in the ovaries, which produce female secondary sexual characteristics and stimulate growth of the lining of the uterus.

Fallopian tubes (or Uterine tubes or Oviducts) The tubes through which ova (eggs) travel from the ovaries to the uterus.

Follicle A small secreting cavity or sac. Ova (egg cells) develop in Graafian follicles in the female ovaries.

Follicle-stimulating hormone (FSH) A hormone produced in the pituitary gland under the brain. It stimulates the maturation of ovarian follicles in females (and sperm production in males).

Frenulum A fold of mucous membrane, as occurs, for example, in the labia minora.

Gametes Sex cells: in females, ova (eggs).

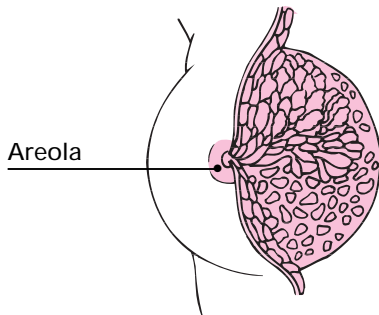
Genitalia Sex organs.

Gonadotrophins Gonad-stimulating hormones made by the pituitary gland.

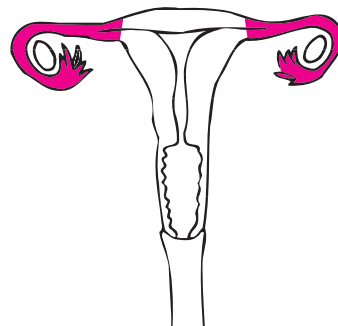
Gonads The primary reproductive organs. In females these are the ovaries.

Graafian follicle (or Vesicular follicle) A tiny vesicle (small fluid-containing sac) in

Breast



Fallopian tubes



the ovary that encloses a developing ova. The follicle becomes a corpus luteum (a hormone-producing body) after ovulation.

Hymen A perforated membrane that may cover or partly cover the opening of the vagina.

Labia Meaning “lips” in Latin, the labia majora and labia minora are respectively the outer and inner liplike skin folds of the vulva surrounding the vagina.

Lactation Milk production by the mammary glands.

Lactiferous ducts The tubes that transport milk to the nipple.

Luteinizing hormone (LH) A pituitary hormone that in females helps to make ova mature and triggers ovulation. It acts with follicle-stimulating hormone (FSH) to regulate the ovarian cycle.

Mammary glands The milk-producing structures in the breast.

Menarche When a girl first starts to have menstrual periods.

Menopause When a woman ceases to have menstrual periods.

Menstruation Menstrual periods: the regular flow of blood and shedding of the uterine

lining from the vagina of nonpregnant females between menarche and menopause.

Mons pubis A fatty pad over the point where the pubic bones meet.

Nipple The conical projection on a breast, which contains the outlets of the lactiferous (milk) ducts.

Oocyte An immature ovum (egg).

Ovarian cycle The monthly cycle by which eggs develop and are released from the ovary in females between menarche and menopause.

Ovary A walnut-sized sex organ that produces ova (eggs). The ovaries are located one on each side of the uterus.

Oviducts See Fallopian tubes.

Ovulation The release of a ripe egg from a female’s ovary.

Ovum An egg; a female sex cell (plural: ova).

Perineum The part of the body between the anus and the genitals.

Progesterone A female sex hormone that helps prepare the uterus to receive a fertilized egg. It is also produced by the placenta during pregnancy.

Pudendum See Vulva.

Uterine tubes See Fallopian tubes.

Uterus (or Womb) Commonly known as the womb. The uterus is a hollow muscular organ located above the bladder. Inside it, a fertilized ovum develops into a fetus, and eventually becomes a baby.

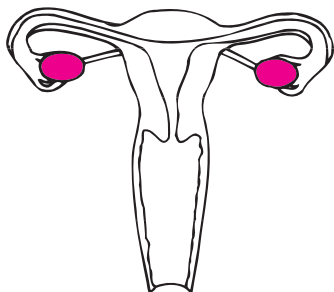
Vagina The muscular passage between the vulva and cervix (neck of the uterus). Babies travel down the vagina during birth.

Vesicular follicle See Graafian follicle.

Vulva (or Pudendum) The external female genitals, comprising the labia, clitoris, and mons pubis.

Womb See Uterus.

Ovaries



Male reproductive system key words

Corpus cavernosum One of the two cylindrical channels forming part of the erectile tissue of the penis (plural: corpora cavernosa).

Corpus spongiosum A single channel surrounding the urethra that is part of the erectile tissue of the penis.

Cowper's glands A pair of small glands opening into the urethra at the base of the penis. Their secretions form a small part of seminal fluid.

Cremaster muscle A thin layer of muscle looping over the spermatic cord. It pulls up the testis when it contracts.

Dartos muscle A thin layer of muscle under the skin of the scrotum. It tightens in the cold, causing the skin to wrinkle and the testes to rise.

Ductus deferens See Vas deferens.

Ejaculation The discharging of semen from the penis at orgasm.

Ejaculatory ducts The tubes that connect the seminal vesicles and urethra.

Epididymis A coiled tubule on each testis where sperm are stored and mature (plural: epididymides).

Erectile tissue The corpora cavernosa and corpus spongiosum. They expand when filled with blood, causing the penis to become erect.

Foreskin (or Prepuce) Loose skin that covers the glans of the penis.

Frenulum A fold of mucous membrane, as on the prepuce.

Gametes Sex cells: in males, sperm.

Genitalia Sex organs.

Glans (or Glans penis) The bulbous end of the shaft of the penis.

Gonads Primary reproductive organs: the ovaries and testes.

Inguinal Relating to the groin (the external depression at the junction between a thigh and the abdomen).

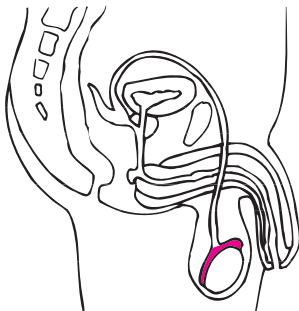
Interstitial cells Cells in the testes that produce testosterone.

Penis The male organ of urination and copulation.

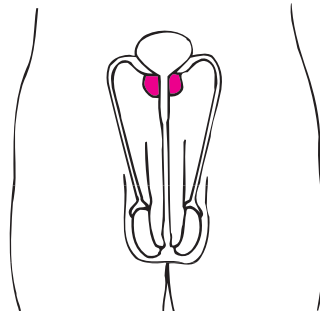
Perineum The part of the body between the anus and the genitals.

Prepuce See Foreskin.

Epididymis



Prostate gland



Prostate gland A gland situated below the bladder in males. It produces a sperm-activating fluid that forms nearly a third of the semen's volume.

Scrotum The sac that contains the two testes and the epididymides, hanging below the abdomen.

Semen Fluid containing sperm and seminal fluid. It is ejaculated from the penis at orgasm.

Seminal fluid The secretions from the prostate gland, seminal vesicles, and Cowper's glands that together form the largest component of semen.

Seminal vesicles Two accessory glands situated on the prostate and opening into the vas deferens, which produce most of the seminal fluid.

Seminiferous tubules The hundreds of coiled tubes in the testes where sperm is produced.

Sperm The common name (singular and plural) for male sex cells and seminal fluid.

Spermatozoon The formal name of the male sex cell (plural: spermatazoa).

Spermatic cord The cord consisting of the vas deferens, nerves, and blood vessels that runs between a testis and the abdominal cavity.

Testicle *See* Testis.

Testis (*or* Testicle) One of a pair of primary male sex organs that manufactures sperm (plural: testes).

Testosterone A sex hormone made mainly in the testes. It stimulates the development of male sexual characteristics.

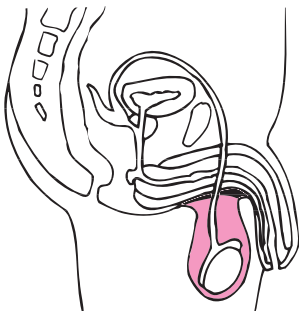
Tunica albuginea A fibrous membrane that is part of the tissue covering the penis.

Urethra The passage that transports urine and, in males, semen outside the body.

Vas deferens (*or* Ductus deferens) One of a pair of muscular tubes that take sperm from an epididymis to a seminal vesicle (plural: vasa deferentia).

Vesicle A small sac or bladder that contains liquid, as in seminal vesicles.

Scrotum



Male genitals

- The skin covering the penis is hairless.
- The erectile tissue of the penis contains several cavities that fill with blood to produce an erection.
- The foreskin is sometimes removed from the penis in a procedure called circumcision. This is thought to make it easier to keep the penis clean. Circumcised men suffer less from urinary tract infections.

From fertilization to birth key words

Amnion (or Amniotic sac) The inner of the two membranes surrounding an embryo or fetus.

Amniotic cavity The fluid-filled space between the embryo and the amnion.

Amniotic fluid The fluid within the amniotic cavity.

Amniotic sac See **Amnion**.

Blastocyst (or Blastula) A hollow ball of cells formed from a morula about five days after fertilization.

Blastomere Any of the cells produced by division of a zygote before a blastocyst is formed.

Blastula See **Blastocyst**.

Breech presentation When a fetus is bottom down ready for birth.

Chorion The outer of the two membranes around an embryo or fetus.

Chorionic villi Multiple folds of the chorion from which the fetal part of the placenta is formed.

Conception See **Fertilization**.

Dilation The opening up of the cervix during the first stage of labor.

Ectoderm An embryo's outer germ layer, which develops into structures including the brain and skin.

Effacement The thinning and shortening of the cervix during the first stage of labor.

Embryo A young animal in an early phase of development. In humans the phase lasts from the third through the eighth week after fertilization.

Embryoblast An embryo's inner cell mass.

Endoderm An embryo's inner germ layer, developing into some internal organs and the linings of the digestive and respiratory systems.

Fertilization (or Conception) The joining of a sperm with an ovum.

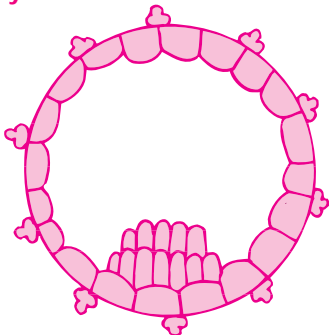
Fetus An unborn mammal from when its adult features become recognizable. In humans this occurs in the ninth week of development.

Full term At the end of the normal gestation period.

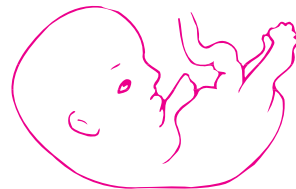Gametes Sex cells: ova and sperm.

Germ layers An early embryo's three cellular layers (ectoderm, endoderm, and mesoderm), giving rise to all body tissues.

Blastocyst



Embryo



Gestation (or Pregnancy) The period from conception to birth, which in humans lasts about 280 days.

Implantation The process by which a blastocyst attaches itself to the lining of the uterus.

Labor The process by which a baby is born, divided into three stages.

Meiosis The process of two successive cell divisions that halve the number of chromosomes in the resulting cells, which are sex cells (ova or sperm).

Mesoderm An embryo's middle germ layer, which develops into the bones and muscles.

Mitosis Ordinary cell division resulting in the formation of two identical daughter cells, each with the same number of chromosomes as the parent cell.

Morula The ball of cells produced from a fertilized cell after three days.

Navel See **Umbilicus**.

Neural tube Embryonic tissue that gives rise to the brain and spinal cord.

Oocyte An immature ovum (egg).

Ovum An egg; a female sex cell (plural: ova).

Placenta An organ formed in the uterus during pregnancy to nourish the fetus and remove its waste products.

Polar body See **Polar cell**.

Polar cell (or Polar body) One of the cells produced during the formation of an ovum from an oocyte that does not itself develop into an ovum.

Pregnancy See **Gestation**.

Sperm The common name (singular and plural) for male sex cells and the seminal fluid in which the cells are ejaculated.

Spermatozoon The formal name of the male sex cell (plural: spermatozoa).

Transverse presentation When a fetus is lying across the cervix.

Trophoblast The tissue that forms the wall of a blastocyst.

Umbilical cord The cord that joins a fetus to a placenta.

Umbilicus (or Navel) An abdominal scar left by removal of the umbilical cord after birth.

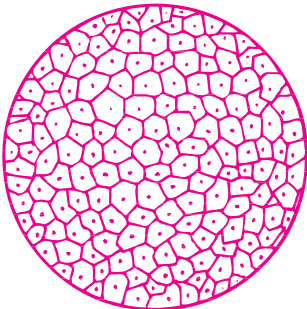
Vertex presentation When a fetus is head down ready for birth.

Villi See **Chorionic villi**.

Zona pellucida The membrane that surrounds an ovum.

Zygote A fertilized egg, formed by the union of a sperm cell with an ovum. All body cells grow from this initial zygote.

Morula



Gestation facts

- The placenta grows from the blastocyst, from which the embryo also grows.
- During childbirth the pelvis widens and the uterus contracts to push the baby down the short birth canal.

Testes

The testes (testis) are the primary male reproductive organs, or gonads, located within the scrotum.

Functions

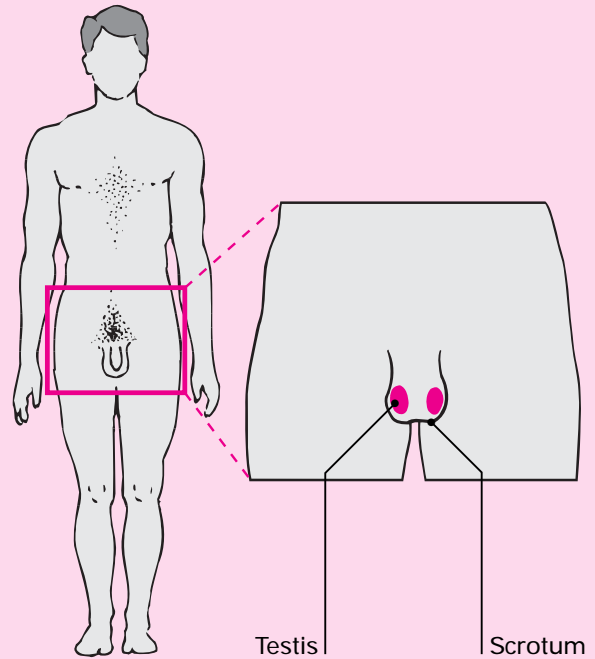
The testes are responsible for producing sperm cells, but they also have specialized cells with an endocrine (glandular) function. These secrete male sex hormones called androgens, the principal androgen being testosterone.

Testosterone

Testosterone is responsible for:

- the growth and development of male reproductive organs and maintenance of their adult size;
- the growth and distribution of male pattern body hair;
- the enlargement of the larynx (causing the voice to deepen);
- increased skeletal and muscular growth; and
- the male sexual drive.

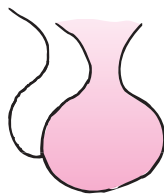Testosterone is secreted in response to hormones released by the



hypothalamus and anterior pituitary. The level of testosterone is regulated by negative feedback.

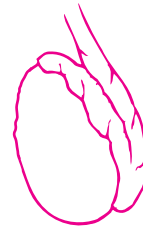Pituitary anterior lobe

The pituitary gland is attached to the underside of the hypothalamus, a part of the midbrain. The gland has three lobes: anterior, intermediary, and posterior. Only the anterior lobe has an affect on the testes, regulating testosterone production.



Testes

Most of the testosterone produced by males is produced by the testes. Some is also produced by the adrenal glands (in both males and females) above the kidneys. Testosterone is a growth hormone and controls the development of male features.



Ovaries

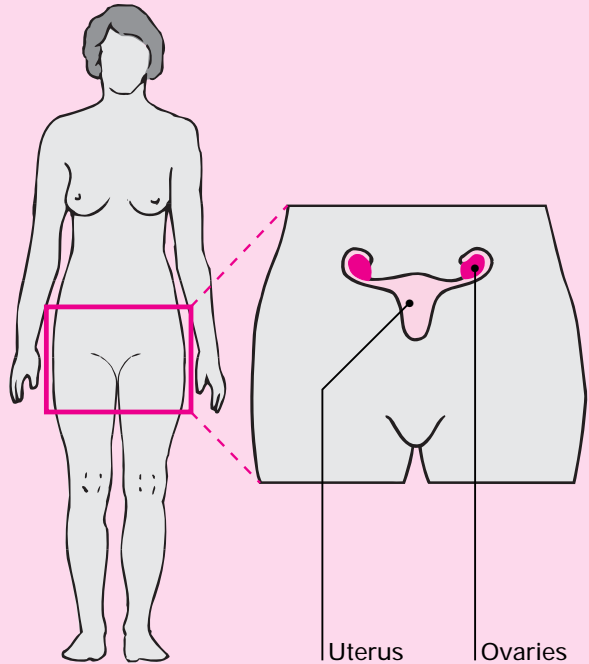
The ovaries are the primary female reproductive organs, located in the lower abdomen on either side of the uterus. They produce the ova for reproduction, and also produce hormones through the ovarian follicles and corpora lutea.

Functions

The ovarian follicles secrete estrogen, which at puberty promotes:

- maturation of the female reproductive organs, such as the uterus and vagina;
- development of breasts;
- distribution of body hair; and
- distribution of body fat.

The corpus luteum is formed from the Graafian follicle after ovulation. It secretes some estrogen, but mainly produces progesterone, which causes the lining of the uterus to thicken in preparation for pregnancy. Both estrogen and progesterone are responsible for changes that occur during the menstrual cycle.



Estrogen and progesterone

Like testosterone, estrogen and progesterone are secreted in response to hormones released by the hypothalamus and anterior pituitary.

Pituitary anterior and posterior lobe

The pituitary gland plays a major role in controlling the ovaries. The anterior lobe triggers ovulation, prepares the uterus for pregnancy, stimulates the production of female hormones, and controls milk production. The posterior lobe controls labor contractions.



Ovaries

These organs produce estrogens and progesterone. Estrogen promotes the development of secondary sexual features and the menstrual cycle. Progesterone prepares the uterus for implantation and develops the breasts.



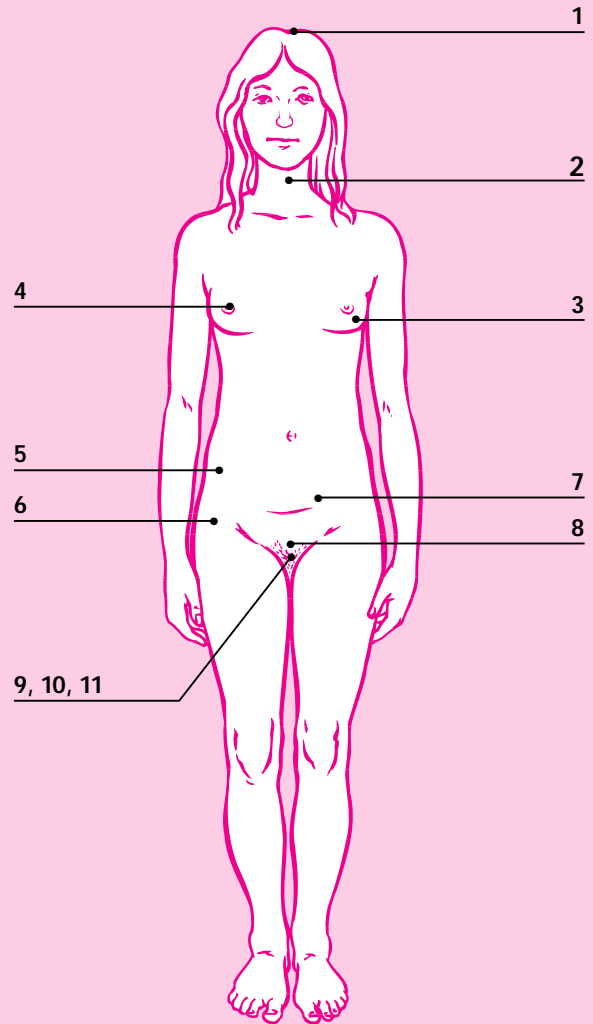
Puberty is the time of life that marks the end of childhood and the beginning of adolescence. At this time adult hormones begin to be produced in young teenagers, causing the characteristic growth spurts, bodily changes, and altered attitudes that are part of the preparations for adulthood. Puberty usually begins at a certain body weight, so boys and girls who are tall or

heavy for their age are likely to begin the changes of puberty before their smaller or slighter contemporaries. Puberty takes place over several years, and is well established by the time a boy has his first ejaculation or a girl her first menstrual period. Adolescent changes in height and body shape may continue as late as age 18 in girls, and the early 20s in males.

Changes in girls

The diagram on the right shows the sites of major physical changes in girls at puberty.

- 1** Body height increases, although not as markedly as in boys.
- 2** The voice deepens slightly.
- 3** The breasts enlarge.
- 4** The nipples stand out from the surrounding skin.
- 5** Fat pads form on the hips and thighs.
- 6** The pelvic girdle widens to prepare the girl for childbearing.
- 7** The ovaries begin to release eggs in a monthly cycle.
- 8** The vaginal walls thicken.
- 9** Pubic hair grows around the vulva and over the pubic bone.
- 10** Menstruation occurs monthly as the uterus sheds its lining.
- 11** The genitals increase in size.



Growing up

- Adolescents become more capable of abstract thought. They can develop interests in relationships, politics, and morality.
- From puberty, children begin to engage in more adult social behavior.

Changes in both sexes

The hair and skin become greasier as a result of hormonal action. Body temperature falls slightly. Underarm hair grows. Sweat glands under the arms and in the groin produce more perspiration than before.

Blood pressure and blood volume increase. Heart rate slows. Breathing rate slows. Bones harden and change their proportions.

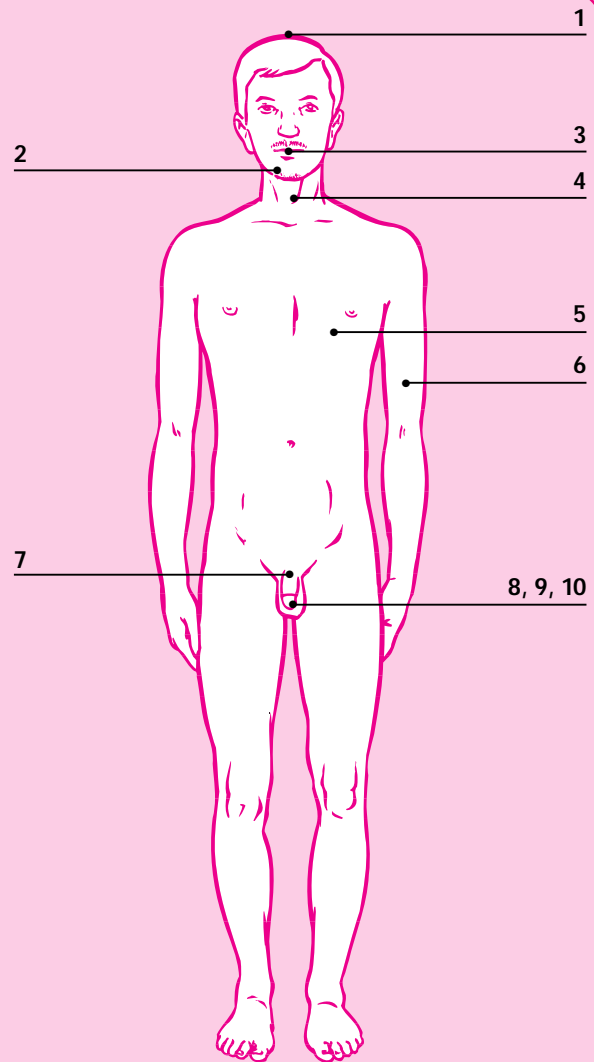
Transition period

Puberty and adolescence can be difficult times, because the boy or girl is caught between two phases of life. Childhood has the benefits of security; adulthood has the benefits of independence and sexual relationships. The adolescent exhibits behavior from both categories, and is also disturbed by physical changes.

Changes in boys

The diagram on the right shows the sites of major, physical changes in boys at puberty.

- 1 Body height increases considerably.
- 2 Hair begins to grow on the chin, cheeks, and upper lip.
- 3 The voice deepens as the larynx grows.
- 4 The Adam's apple enlarges.
- 5 Muscles over the whole body develop and become more noticeable.
- 6 Bodily strength increases greatly.
- 7 Pubic hair grows around the base of the penis.
- 8 The prostate gland enlarges.
- 9 The genitals increase in size.
- 10 Ejaculation often occurs during sleep.



Changing behavior

- Adolescents think about why they behave the way they do.
- Self-esteem may fluctuate throughout puberty, but it generally increases with age as the teenager becomes more confident.
- During puberty children experiment with adult social behavior while they are still safely in the care of their parents.

Problems in adolescence

The illustration (right) shows the sites of some of the health problems that are common during adolescence.

1 Fatigue and lethargy often occur during adolescence, partly from physical causes, such as hormone activity, and partly for psychological reasons.

2 Sleep disturbance may occur, especially if the person is anxious or fearful.

3 Mood changes are caused by hormonal action, and are often confusing for the individual and those around him/her alike.

4 Acne is a frequent result of the increased greasiness of the skin; the pores become clogged and then form infected pimples.

5 The appetite may increase or decrease during adolescence, and may lead to overeating or undereating.

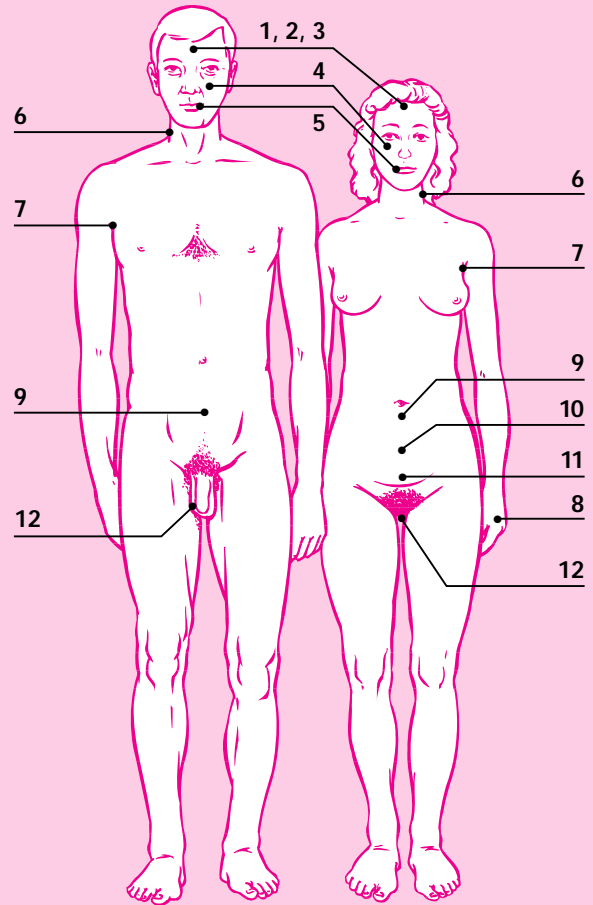
6 Mononucleosis (glandular fever) is common among adolescents, and its effects may last for a month or more.

7 Body odor from the armpits and groin can occur when insufficient attention is paid to personal hygiene.

8 Clumsiness is a phase often passed through by adolescents who do not yet feel at home in their taller, heavier, and more powerful bodies.

9 Weight problems in early adolescence may be a sign of rapid puberty, in which case the problem will disappear as the body's height catches up with its weight; or the increase in weight may be a result of greatly increased appetite.

10 Stretch marks occur when the increase in weight during puberty has



been very rapid; they begin as red lines and eventually fade to a permanent silvery-gray.

11 Menstrual pain may begin to occur in later adolescence. The possible reasons for menstrual pain are many, and if the girl is being greatly inconvenienced by monthly pain she should be seen by a gynecologist.

12 Genital problems such as vaginal discharge or "jock itch" may develop if the adolescent does not appreciate the need for genital hygiene.

Rebelliousness

The challenging of authority is an inevitable part of the life of a healthy adolescent. By tackling the values held by parents, teachers etc., the adolescent both discovers whether those values are worthwhile, and also affirms his or her own newly acquired independence. In most cases, this rebelliousness covers fairly minor offenses such as truancy, indolence at work, rudeness, or staying out late. In these cases, parents can be reassured that the phase will eventually pass. More severe rebellion, such as criminal activity, usually requires analysis of the emotional disturbances underlying the actions.

A sense of values

As the growth toward full physical, emotional, and mental maturity progresses, adolescents are either consciously or subconsciously establishing the values, attitudes, and tastes that they will probably hold for the rest of their lives. In childhood the standards of the parents have usually been accepted unquestioningly; adolescence gives the individual the opportunity and the motive to examine prevailing standards and decide whether to uphold or replace them. Political awareness usually develops during this time, and the adolescent adopts his own moral and social code of values.

Relationships

After puberty the full sexual nature of the individual develops, and the adolescent becomes very sensitive and responsive to sexual stimuli. Hero-worship of an older person of the same sex is often based on admiration of that person's sexuality, and is later replaced in many cases by an attraction to a particular film star or other cult figure of the opposite sex. The objects of these affections are unattainable and therefore very safe. This kind of fantasy heterosexual interest usually moderates into attraction to friends of the opposite sex, and dating begins. Adolescence is often the time of the first full sexual experiences.

Conformity

Being regarded as the "odd one out" can cause an enormous amount of suffering for a teenager during a period when he or she is perhaps deeply disturbed by the relentless changes in physique and mood. The teenager, especially in the years between 12 and 16, usually satisfies his or her need for security at a time of emotional turmoil by conforming to the habits, dress, appearance, and tastes of the peer group. Later in adolescence the mature teenager will develop enough security in his or her personal views to take a stand that may be completely independent from the massed views of his or her friends.

The female human reproductive system is set up to receive semen from the male through the vagina and then bring it together with a female sex cell for conception (fertilization) to take place. Once conception has occurred producing a zygote, the menstrual cycle is interrupted to allow the fetus to develop inside the uterus. The human fetus takes about 280 days to develop fully before leaving the confines of the uterus and being born through the vagina, the same passage through which the sperm originally arrived.

Ovaries

- At birth, a human ovary contains about 400,000 immature ova.
- About 400 fertile eggs are released during a woman's childbearing years.

External genitalia

Known collectively as the vulva, the external female genitalia are comprised of several features. The opening to the vagina is protected by two sets of fleshy lips, or labia, and a fatty pad, called the mons pubis.

The clitoris is located inside the labia majora and below the mons pubis. This organ is homologous to the male glans and extremely sensitive to touch. During

intercourse the stimulated clitoris is involved in producing an orgasm. Just inside the vaginal opening, the Bartholin's (or major vestibular) glands secrete mucus into the vagina to lubricate it for intercourse.

As well as surrounding the genital opening, the vulva also contains the female urethral opening, through which urine is released from the bladder.

Female external sex organs

Mons pubis

Clitoris

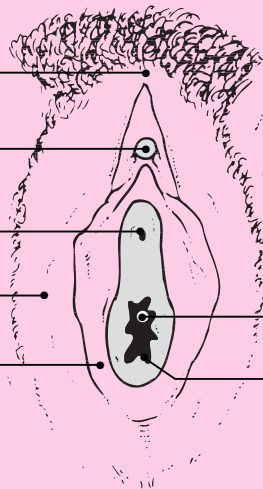
Urethral opening

Labia majora

Labia minora

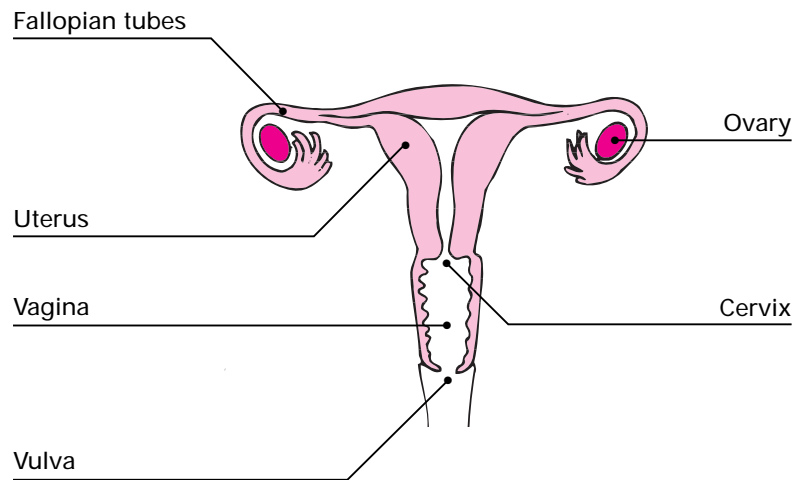
Vaginal opening and hymen

Bartholin's glands



Internal genitalia

The internal female sex organs serve to link the ovaries with the external vaginal opening, through which sperm is deposited. An ovum released by an ovary is captured by the fallopian tube and travels toward the uterus. If it meets a sperm cell and is fertilized, the resulting zygote develops into a blastocyst, which becomes implanted in the lining of the uterus.



Structure

Fallopian tubes

Functions

- Serve as a passage through which eggs pass on their way from the ovaries to the uterus.

Ovaries

- Produce ova (eggs); and
- Produce the female sex hormones estrogen and progesterone.

Uterus

- Nourishes a developing fetus.

Cervix

- Neck (entrance) of the uterus which widens during childbirth to allow passage of a baby.

Vagina

- Serves as passage for a baby in childbirth;
- Serves as passage for menstrual flow from the uterus outside the body; and receives the penis during sexual intercourse.

Vulva

- Elements of external genitalia have different functions. For example, the labia majora (outer labia) and labia minora (inner labia) are protective folds. The clitoris is highly sensitive and is involved in female sexual response. Bartholin's glands secrete lubricating mucus into the opening of the vagina during sexual excitement.

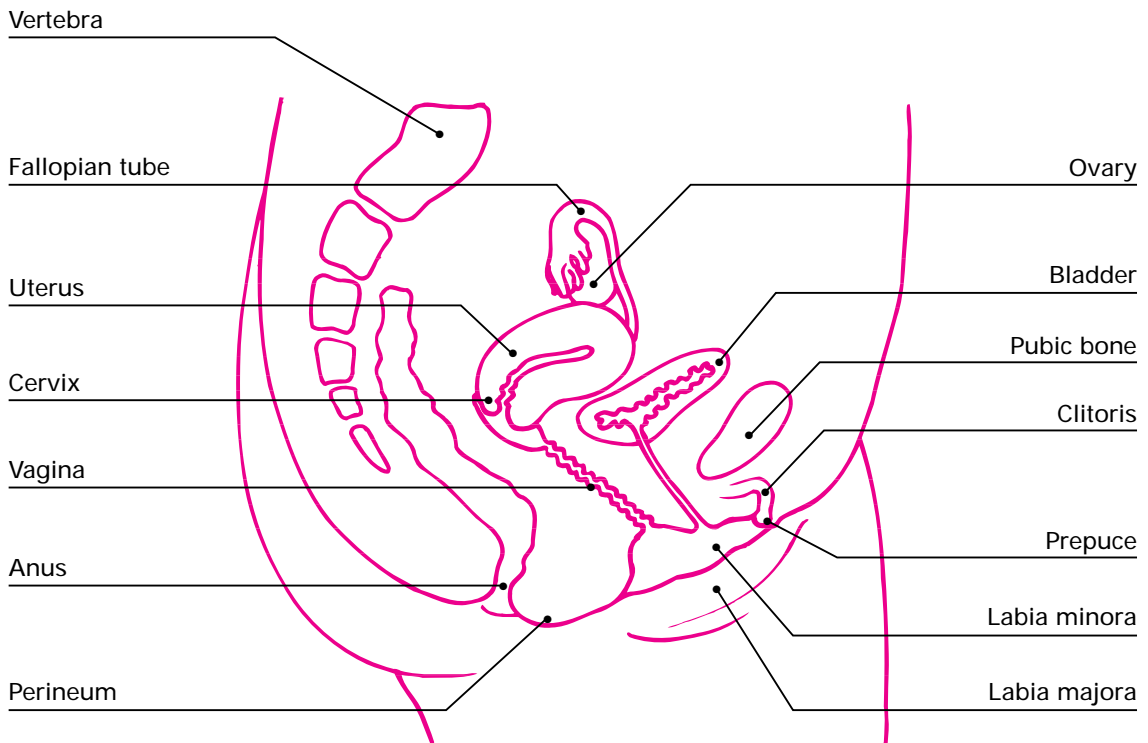
Cross section of female genitals

The ovaries are located in the pelvic cavity situated halfway between the belly button and the pubic bone (pubic symphysis). The gonads flank the uterus and are surrounded by the trumpet-shaped upper end of the fallopian tube. The tubes are extensions of the uterus or womb. This is a muscular sac that links to the vagina through the cervix. The clitoris is a forked structure of

erectile tissue that extends around the lower end of the vagina. Its exposed tip is covered by a hood, or prepuce, which is the homolog of the male foreskin.

The genitals are closely associated with the excretory system. The bladder sits between the pubic bone and the uterus and drains through the vulva. The vaginal opening is separated from the anus by the perineum.

Median section through the female pelvis

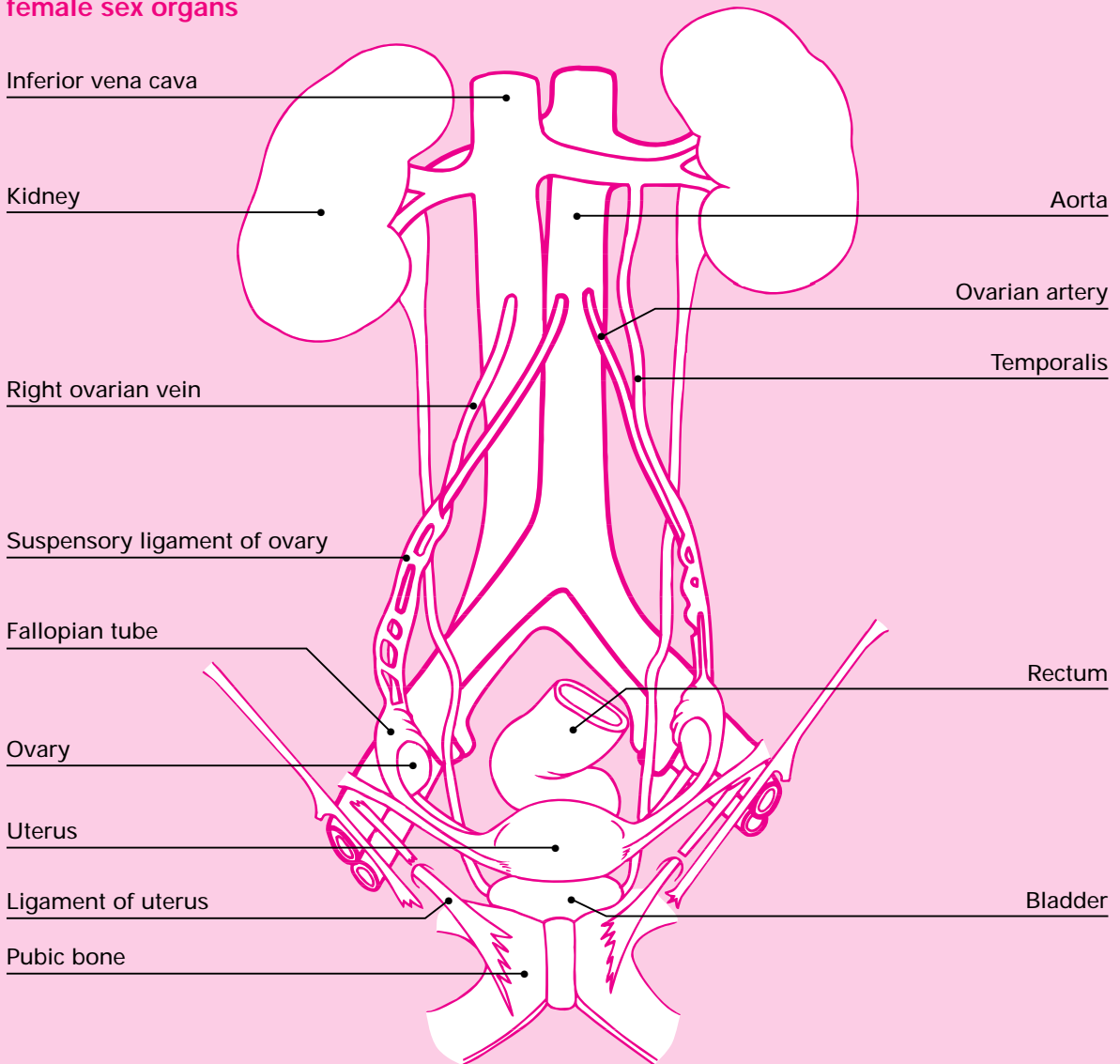


Urinogenital blood supply

Each ovary is supplied with blood through an artery that connects directly to the aorta, the body's main artery. The ovarian veins carry blood away

from the ovaries, draining into the inferior vena cava (the largest vein) via the kidney. Ligaments support the ovaries, fallopian tubes, and uterus.

Front view of kidneys and female sex organs



Oogenesis

Oogenesis is the formation of an ovum (female sex cell, or egg). It starts before birth and, unlike the production of sperm (male sex cells), becomes a cyclical process by puberty. Each cycle (steps 3 to 5) lasts about 28 days and is repeated throughout a woman's reproductive years.

Before birth

1 During fetal development, certain cells within the ovaries change to become what are known as oogonia.

2 Oogonia rapidly divide by mitosis (ordinary cell division) to make thousands of other cells. Each of these cells has 46 chromosomes. The cells become primary oocytes. By birth, every female has a lifetime's supply of primary oocytes in her ovaries.

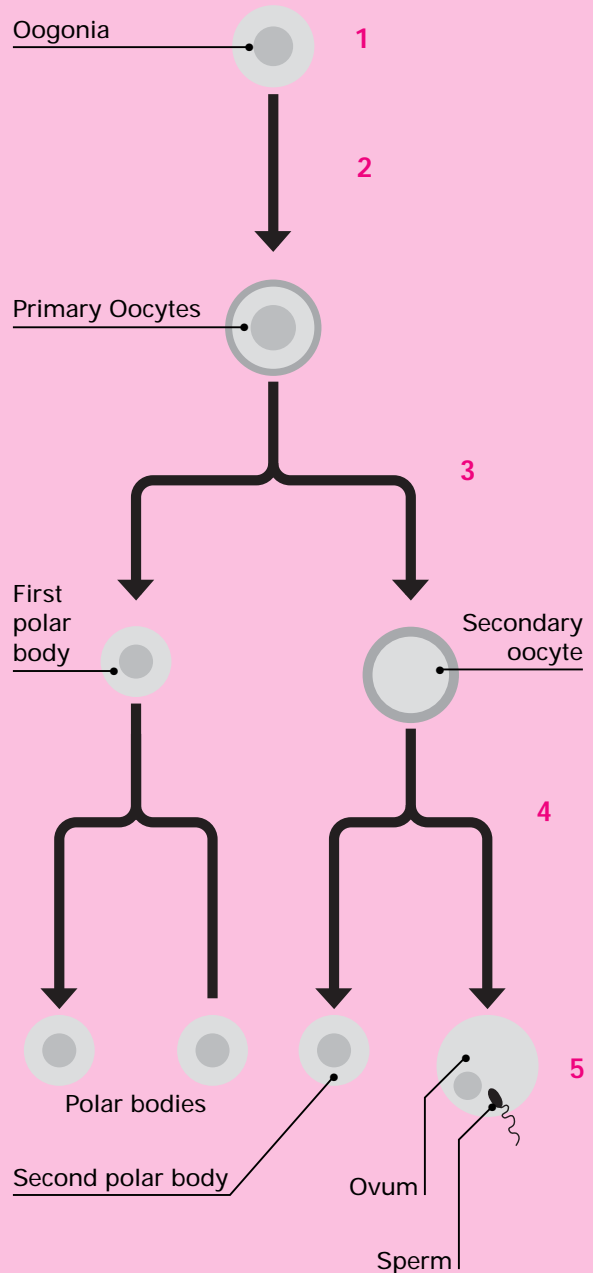
At puberty

3 Each month, some primary oocytes start to grow and one dominates. The dominating oocyte begins meiosis (sex cell division) and produces one cell called a secondary oocyte and another smaller cell called the first polar body. Both cells have only 23 chromosomes each (half the normal number).

4 The secondary oocyte begins to divide as it is released from the ovary.

5 If fertilization takes place, the meiotic division completes, producing a small second polar body and another larger cell called the ovum. The ovum has been fertilized by the sperm. The first polar body may also divide to produce two smaller cells, but only one fertile cell (ovum) develops from the primary oocyte. All the polar bodies degenerate.

Stages of oogenesis



Male and female meiosis

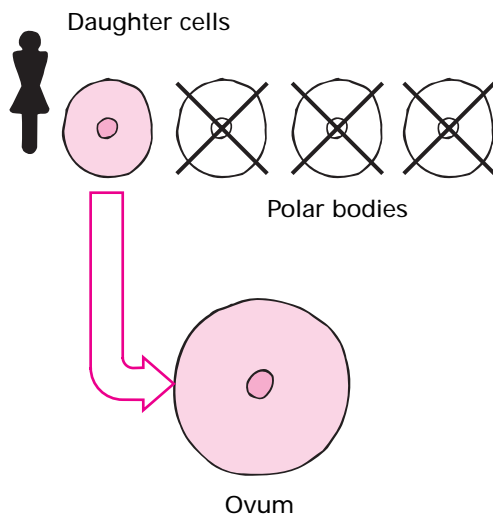
Oogenesis is the process by which ova (female gametes) are produced by meiotic cell division. Meiosis is a special type of cell division which produces four daughter cells, each containing half a full set of chromosomes. During oogenesis three out of the final four cells die and only one develops into a mature ovum.

Sperm production also involves meiosis, but all four cells produced by the cell division become sperm, and they are all capable of producing viable offspring. This difference goes to the heart of the difference between the two sexes. The one fertile ovum produced in oogenesis is a very large cell that is well

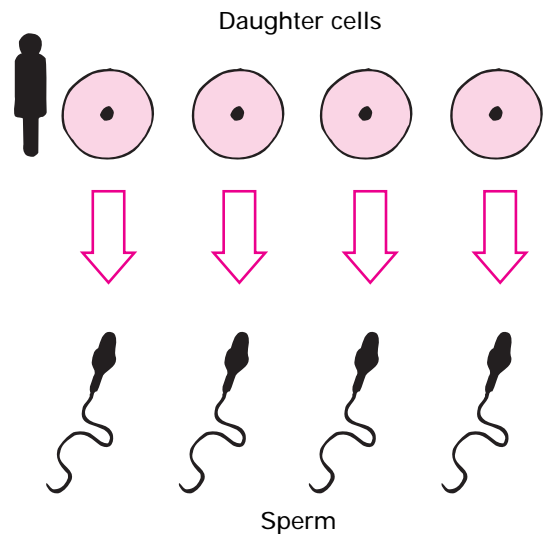
prepared for fertilization. It contains most of the nongenetic material from the other daughter cells, or polar bodies, which are all consequently very small. Sperm cells contain just genetic material and therefore are small cells.

In addition, since all female reproductive cells are laid down before birth, members of that sex must guard their reproductive opportunities against unsuitable partners. However, males do not have the same concerns, since they do not have to undergo pregnancy and nurse their young. Therefore it is in a male's interest to produce as many sperm cells—and distribute them among as many females—as possible.

Female meiosis



Male meiosis



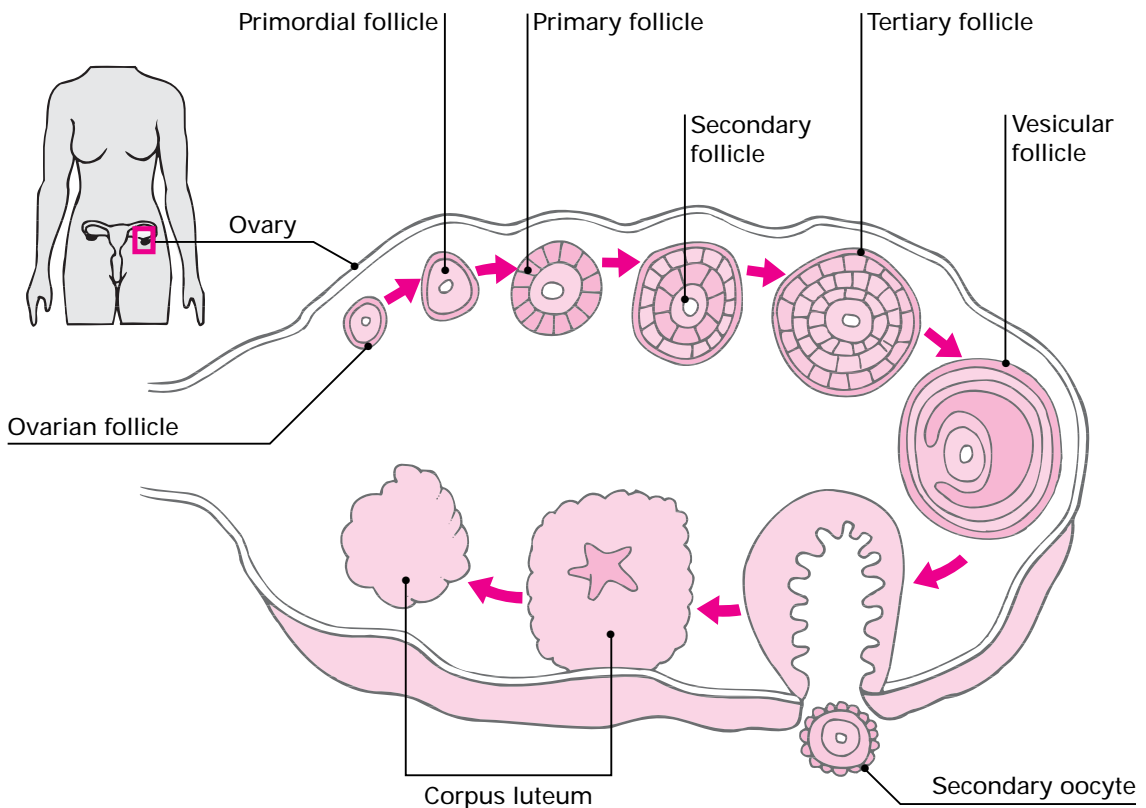
Ovary structure and function

The outer region of the ovary is called the stroma. The inner zone is known as the cortex. Inside the cortex of both ovaries are many saclike structures called ovarian follicles. Each follicle contains an immature egg, called an oocyte. Follicle-stimulating hormone (FSH) from the pituitary gland causes the oocytes to develop. The structure of follicles changes as they develop.

A primordial follicle has one layer of cells surrounding the oocyte, whereas a primary follicle has two or more layers. Vesicular follicles are the most mature type of follicle.

- The function of ovaries is the regular maturation and release of ova (eggs). This is achieved by the ovarian cycle.
- The ovaries also produce the hormones estrogen and progesterone.

Maturation of follicles



The ovarian cycle

The ovarian cycle involves two consecutive phases: the follicular phase and the luteal phase. Ovulation—the release of an egg—occurs in the middle of the cycle. A normal cycle lasts between 28 and 35 days. At any one time, the many follicles inside an ovary will be at different stages, and not all the stages will necessarily be present. The ovarian cycle is regulated by FSH (follicle-stimulating hormone) produced by the pituitary gland.

Follicular phase: days 1–14

Primordial follicles (a) develop into primary and then secondary (b) follicles. These secrete the hormone estrogen. They then develop into tertiary follicles (c) and finally become mature vesicular follicles (d).

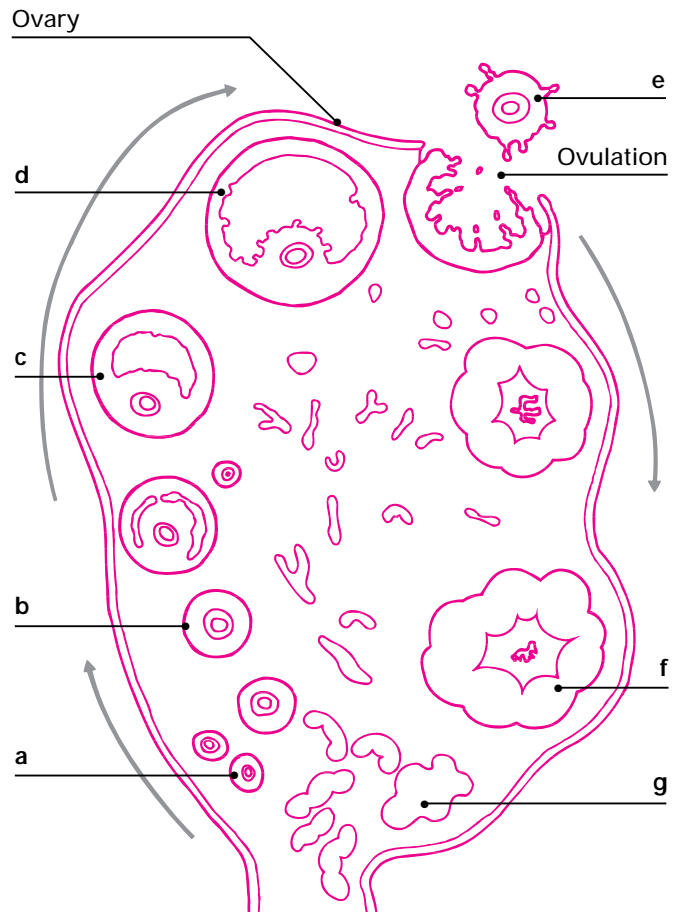
Ovulation

The follicle ruptures and the secondary oocyte (e) is released.

Luteal phase: days 14–28

The corpus luteum (f) is formed from the ruptured follicle. This “yellow body” is an endocrine gland; it produces both the hormones progesterone and estrogen. Eventually, the corpus luteum shrinks and becomes a white scar called a corpus albicans (g).

Cross section of an ovary showing the development of a follicle



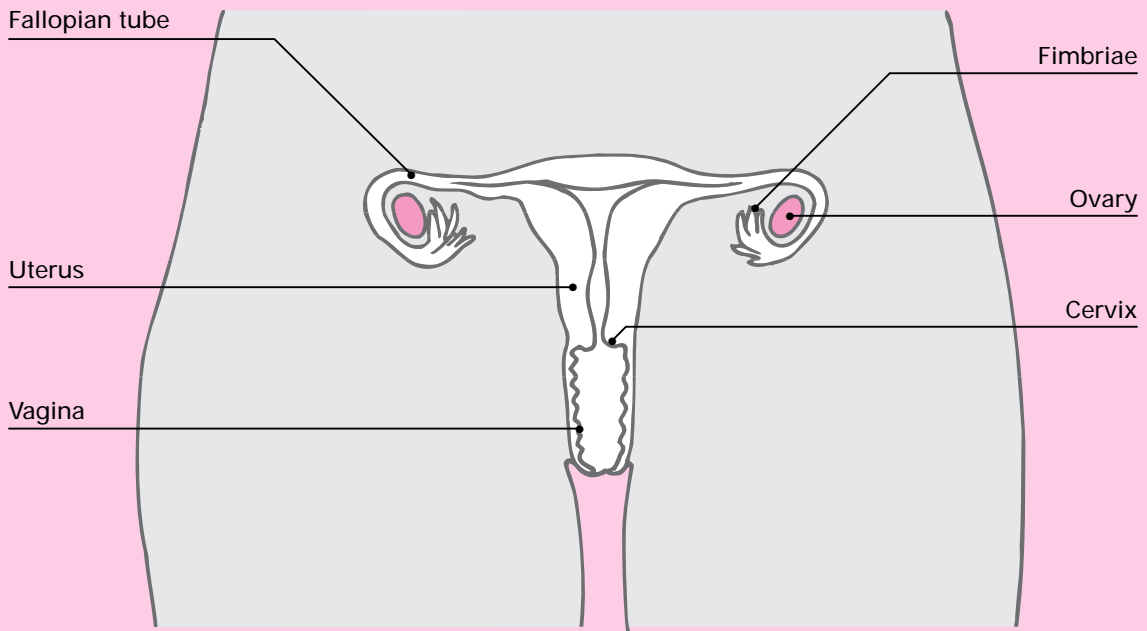
Due to hormonal imbalances, more than one follicle may begin to mature in the ovary, preventing a single follicle from dominating and being released during ovulation. Instead the follicles form ovarian cysts. Women with polycystic ovaries often have other health problems.

Accessory female sex organs

The ovaries are connected to several internal sexual structures that serve to receive sperm and to provide a nurturing environment for developing young. After ovulation, the released egg is captured by the trumpet-shaped upper end of the fallopian tubes. At this end the tubes are fringed with petal-like fimbriae. The egg passes through the

tube into the uterus. It may meet sperm cells swimming in the opposite direction and be fertilized. The uterus is a muscular sac that is lined with a thick layer called the endometrium. This layer thickens as it prepares to receive a fertilized egg. After several days of development, the embryo becomes implanted in the mucosa to continue its development.

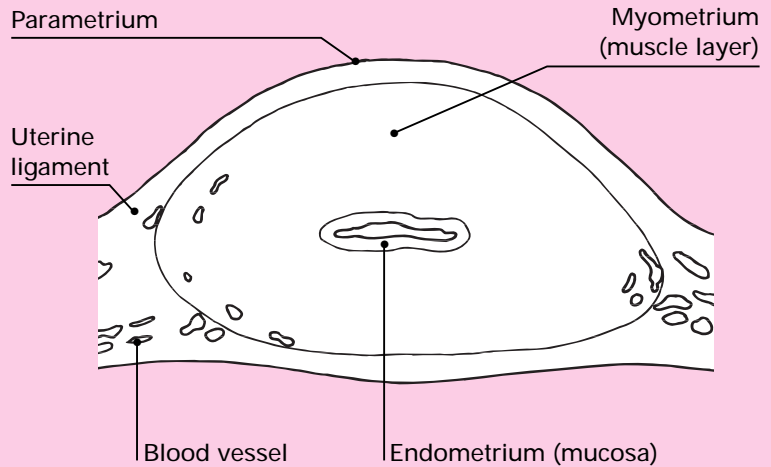
Front view of female reproductive tract



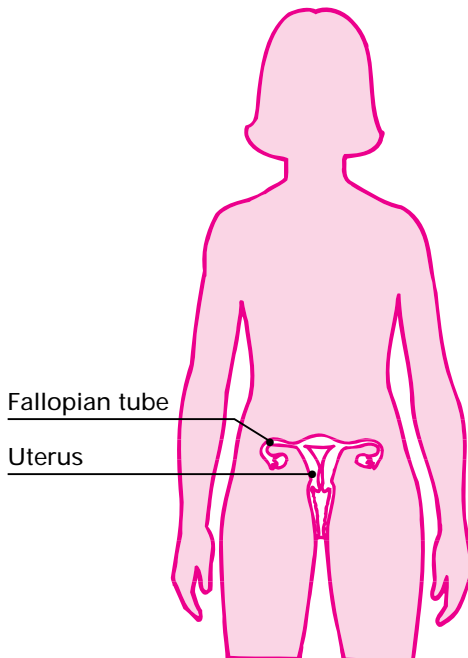
Uterus and fallopian tubes

The insides of the uterus and fallopian tubes are lined with a layer of cells called the endometrium. The lining of the fallopian tubes is heavily folded, while the endometrium in the uterus thickens during each menstrual cycle, before being shed again during menstruation. The uterus is also heavily muscled to help push a full-term baby down the birth canal during labor.

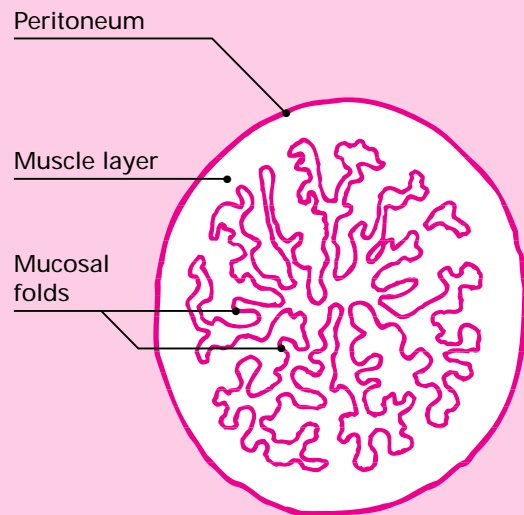
Cross section through the body of the uterus



Levels of section



Cross section through a fallopian tube



The menstrual cycle

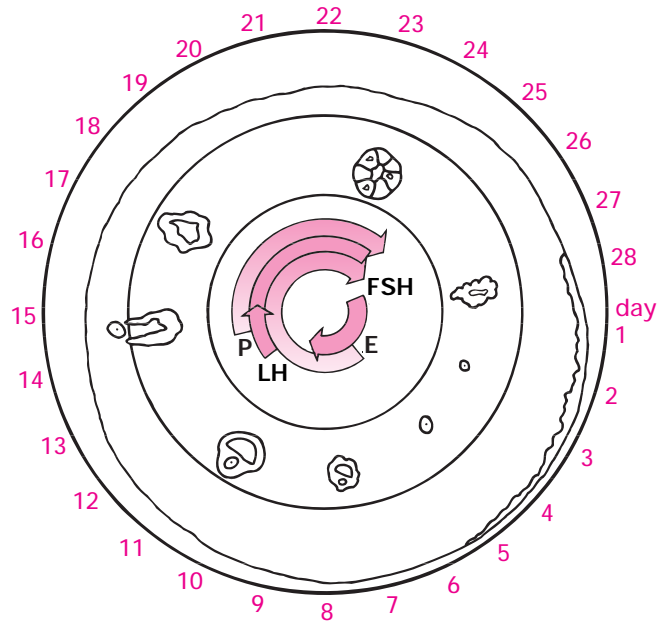
Each month, the uterus is receptive to the implantation of a fertilized egg for only a short period of time—about seven days after ovulation (release of an egg from an ovary). The menstrual cycle represents the changes that occur in the endometrium (uterine lining) that allow or prohibit this implantation.

The menstrual cycle is closely linked to the ovarian cycle, which controls ovulation. Both last about 28 days, although this can vary between women, and even from month to month in the same woman. There are three phases of the menstrual cycle: menstrual, proliferative, and secretory phases.

Hormones

Menstrual and ovarian cycles are regulated by hormones (regulatory chemicals). These include LH (luteinizing hormone), FSH (follicle-stimulating hormone), estrogen, and progesterone. FSH and LH are produced by the pituitary gland through stimulation by the hypothalamus in the brain. Estrogen is produced by developing follicles, while progesterone is secreted by the corpus luteum (resulting from the follicle ruptured by ovulation) after ovulation. Progesterone is also produced by the placenta after a fertilized egg has been successfully implanted.

Scheme of the menstrual cycle



The innermost circle shows secretion of hormones by the pituitary gland and ovarian follicle. The middle circle shows the ovarian follicle ripening from day 1 to

ovulation on day 14 and formation of the corpus luteum. The outer circle shows the build-up of the endometrium and then menstruation from day 28 to 5.

Phases of the menstrual cycle

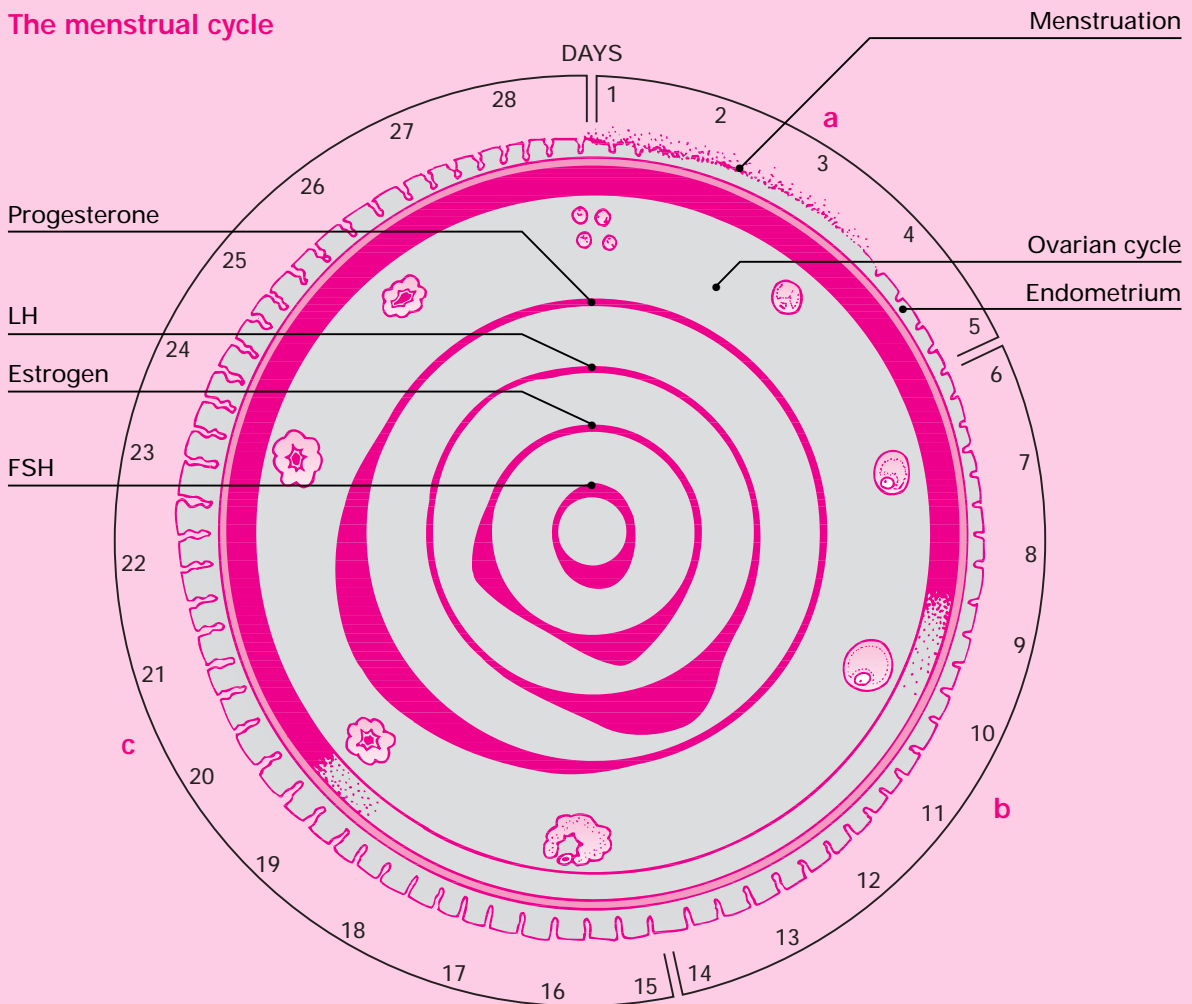
a Menstrual phase: days 1–5
The uterus sheds most of the endometrium. The detached tissue and blood pass out through the vagina over about three to five days.

b Proliferative phase: days 6–14
The endometrium begins to rebuild

itself, gradually thickening under the influence of estrogen during this period.

c Secretory phase: days 15–28
The endometrium prepares for the implantation of a fertilized egg. Nutrients are secreted by the lining to sustain any implanted egg.

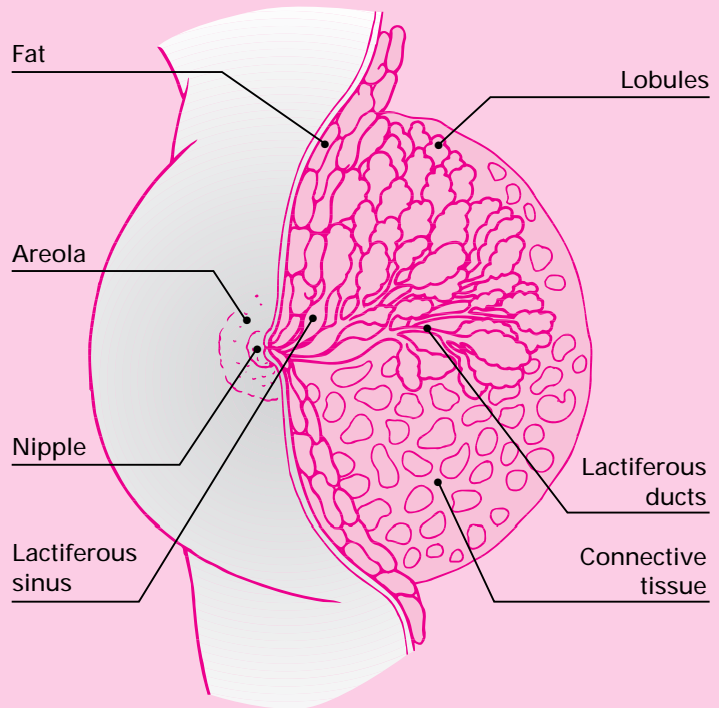
The menstrual cycle



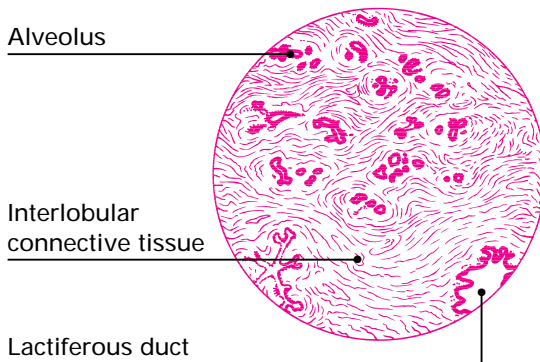
Breasts

The mature female breast is a milk-producing organ formed of many lobes, each with a tree-like system of milk ducts. Clustered nodules feed into small ducts that lead into a main milk duct opening into the nipple. Each lobe is embedded in fat and separated from neighboring lobes by fibrous tissue. On these pages we look at some common breast problems. Sometimes one breast develops before the other, giving grounds for needless worry. Variations in fat content (which gives a breast its bulk) can cause cosmetic problems. Breast infections, cysts, and tumors can threaten health and so always deserve attention.

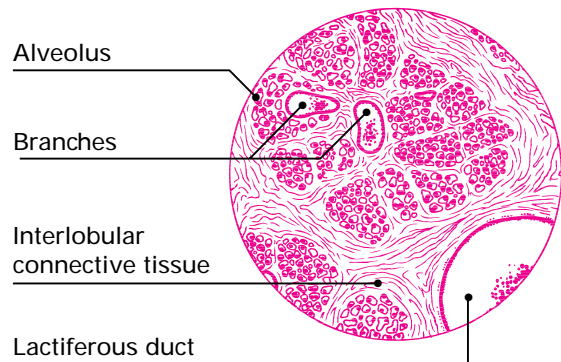
Section through a female breast



Section from an inactive breast

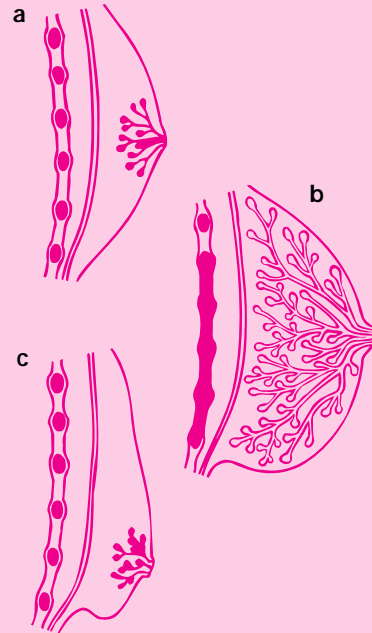


Section from a lactating breast



Changes in breasts

Breasts remain undeveloped before puberty. About the age of 11 (**a**), breasts start to grow: grape-sized nodules beneath the nipples make the surrounding pigmented areas (the areolae) bulge outward. Often one breast starts to grow before the other. By the age of 16, growth of milk ducts and fat makes breasts prominent and firm. In pregnancy (**b**) the milk ducts grow until the breasts are one third larger than usual. After childbirth, breasts may remain larger than they were. About the time of the menopause (**c**) the breasts shrink and may begin to droop, although some women's breasts gain increased fat deposits.



Breast cancer

Cancers may show themselves in a change in nipple size, shape, or color; bloodstained nipple discharge; a painless lump in the breast with dimpled skin above; or a hard lump in the armpit. Detecting the cancer within a month of its onset may help to boost survival chances enormously, so monthly self-examination is advisable. Some women tend to be more at risk than others. They include those with a relative who has had the disease; those with benign breast tumors; those who have had no children, one child, or a first child when they were over 35; and women experiencing menopause in their 50s.

Cysts and benign tumors

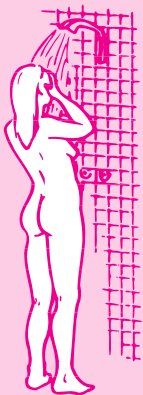
Most lumps in the breast are harmless cysts or tumors. Cysts are small sacs comprising blocked milk ducts filled with fluid made by breast cells. All women's breasts contain scores of cysts too tiny to be noticed. Doctors can sometimes collapse a large cyst by inserting a hollow needle and drawing off the fluid. Benign tumors are growths that develop in a slow, orderly way (unlike malignant tumors). But if a benign lump in the breast keeps growing it may press hard enough on nearby nerves and other tissues to cause pain (a painful lump in the breast is usually benign). A surgeon will then remove the lump.

Women can do much to prevent problems with simple hygiene. This includes: wearing clean cotton panties daily (not nylon ones, as these promote fungal infections); washing the vulva daily with mild soap; wiping the genitals from front to back after a bowel movement; remembering to remove tampons after a period; avoiding chemicals that irritate

the vagina; and ensuring that a sexual partner is clean and disease-free. Ideally a woman should learn to use a speculum, an instrument that enables her to see her internal genitals clearly; she will then be able to notice any unexplained change. Abdominal pain or swelling, or pain during or after intercourse, should always be investigated medically.

Washing

Skin in and around the genital area produces natural oils and discharge that protect against most infections. Chemicals and perfume in soaps and tampons can break down this protection. Wash the area gently, in the morning and evening, with mild soaps and warm, not hot, water. Washing in a bidet, shower, or bath is preferable to using a flannel or medical wipe.



Sanitary pads

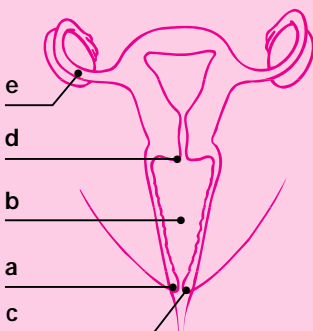
These are thin absorbent pads that are used to soak up blood discharged during a period to prevent it reaching and staining clothing. They are placed inside panties in front of the genital area. Sanitary pads are made of a disposable, soft, cotton-like material, often with a waterproof outer layer to prevent leaks and one or more adhesive strips to hold them in place. They come in different sizes and thicknesses. The pads should be used and removed every few hours, but it is safe to use one to last through the night. Used sanitary pads should be placed in a bag and disposed of in a garbage bin. They should not be discarded down the toilet.

Tampons

Tampons are used like sanitary towels but are rolled-up absorbent pads that are inserted gently into the vagina. They can be inserted by hand or with the help of an applicator. They are available in different sizes and absorbencies to suit the heaviness of bleeding. They have threads attached that are used to pull them out. Tampons, too, should be used and removed every few hours. Women should wash their hands before and after using them. It is sensible to remove a tampon before taking a shower or bath and insert a fresh one afterward. If tampons or sanitary towels are not changed regularly, there is more chance of vaginal infection.

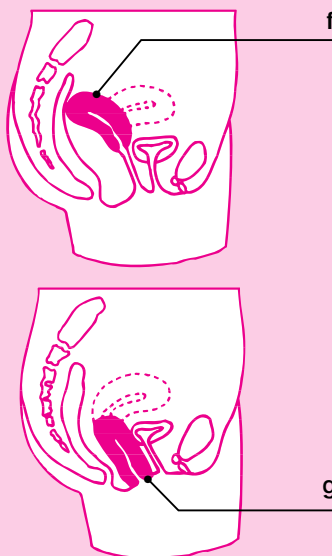
Irritation and infection

Irritation of the genital tract may be due to infection, or have chemical or mechanical causes. If the irritation persists for more than a day or two, consult a doctor. Illness, injury, overdouching, or sexual intercourse with an infected partner may cause trouble externally or internally. Infection of the vulva (**a**) and vagina (**b**) can cause irritation and discharge. Cuts or abrasions (**c**) may give rise to infection of the cervix, the neck of the womb (**d**), or the Fallopian tubes (**e**). If you suspect you may have an infection of the genital tract consult your doctor.



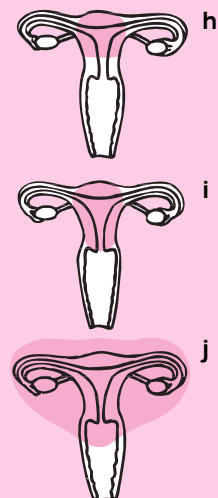
Displaced uterus

Some women suffer retroversion or prolapse of the uterus. In retroversion (**f**) the uterus is always tilted backward, causing urine retention in pregnancy, sometimes with cystitis or even a miscarriage. Doctors treat it by manually repositioning the uterus, though surgery is sometimes needed. In prolapse (**g**), weakened muscles let the uterus sag down into or even beyond the vagina, causing discomfort, discharge, backache, and urination problems. Surgery is generally required.



Hysterectomy

This is an operation to remove the uterus. It may be subtotal, involving just the uterus (**h**); total, involving uterus and cervix (**i**); or radical, involving uterus, cervix, part of the vagina, local lymphatic ducts, ovaries and Fallopian tubes (**j**). Conditions that may require hysterectomy include fibroids, endometriosis, menstrual problems, and cancer. If the ovaries have to be removed, hormone treatment prevents menopause and most women continue to have a normal sex life.

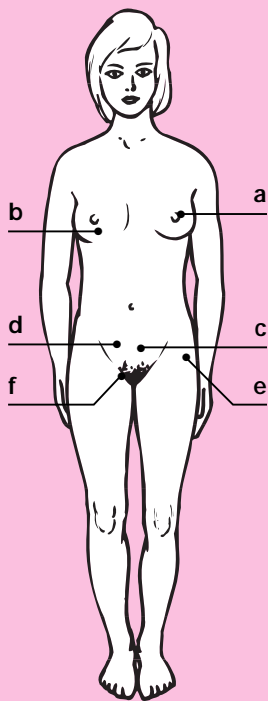


Women between the ages of approximately 12 and 47 experience a flow of blood and mucus from the vagina about once every 28 days. This regular flow indicates that several things have happened. First, hormones have helped thicken the womb lining to receive a fertilized egg. Next, an ovary has released an egg. If this has remained unfertilized, hormone action has helped to break up the

lining of the womb, which has leaked out with some blood—the process called menstruation. Women wear pads or insert tampons in the vagina to absorb the menstrual flow. But many have to cope with other problems, ranging from premenstrual tension to period pains and abnormal periods. Here we look at problems commonly associated with menstruation.

Onset of puberty

This can start as early as nine years old or as late as 15, but in the Western world usually begins at about 11. Thus girls tend to reach puberty ahead of boys. The age of onset has grown earlier this century as diets and living standards have improved. By 11 nipples (a) are becoming prominent and breasts (b), uterus (c), and ovaries (d) are growing. The pelvis broadens and pads of fat develop on the hips (e). Body hair (f) increases. Menstruation may begin between the ages of 11 and 13. Ovulation usually starts at about 14. Later, genitals mature and menstruation becomes more regular.



Chronic problems

Premenstrual problems

The body's overreaction to the hormonal changes triggered by the menstrual cycle produces premenstrual problems—notably premenstrual tension—in about half of all women. Discomfort sets in about a week before the menstrual flow starts, and stops when the flow begins.

On the left half of the illustration on the right common sites of problems, which are both physical and psychological, are shown.

- 1 Headaches (migraine sufferers report that they get their very worst headaches at this time).
- 2 Psychological tension, increasing feelings of nervousness and irritability.
- 3 Fatigue and depression.
- 4 Low backache.
- 5 Nausea.
- 6 Painful, tender, and swollen breasts.
- 7 Swollen feet and ankles produced by fluid collecting in the tissues. Thumb pressure drives it out, leaving the skin temporarily pitted.
- 8 Bloating abdomen (generally due to fluid retention).

The symptoms of premenstrual problems may be alleviated in several ways. Doctors may prescribe progesterone that modifies the hormonal changes of the menstrual cycle. A mild analgesic should help to stop discomfort, and limiting salt intake some days before menstruation helps to reduce tension. Drinking more water and hot herbal teas raises urine output and reduces fluid retention.

Menstrual problems

The right half of the illustration shows sites of major menstrual problems.

Lack of menstruation may be caused by:

- 9** Abnormality of the uterus.
- 10** Failure of the ovaries to stimulate the adolescent uterus, perhaps through malfunction of the hypothalamus gland.
- 11** The eating disorder called anorexia nervosa.
- 12** Malfunction of the pituitary gland: overproduction of prolactin, interfering with another hormone in the ovaries.

Irregular periods may be caused by:

- 13** A malfunction of the hypothalamus.

Painful periods may indicate:

- 14** Normal hormonal changes that affect the uterine muscle.
- 15** Pelvic damage caused by inflammation of the ovaries, fallopian tubes, and uterus, sometimes following abortion or childbirth. These internal organs may become “glued” to bowel or pelvic walls.

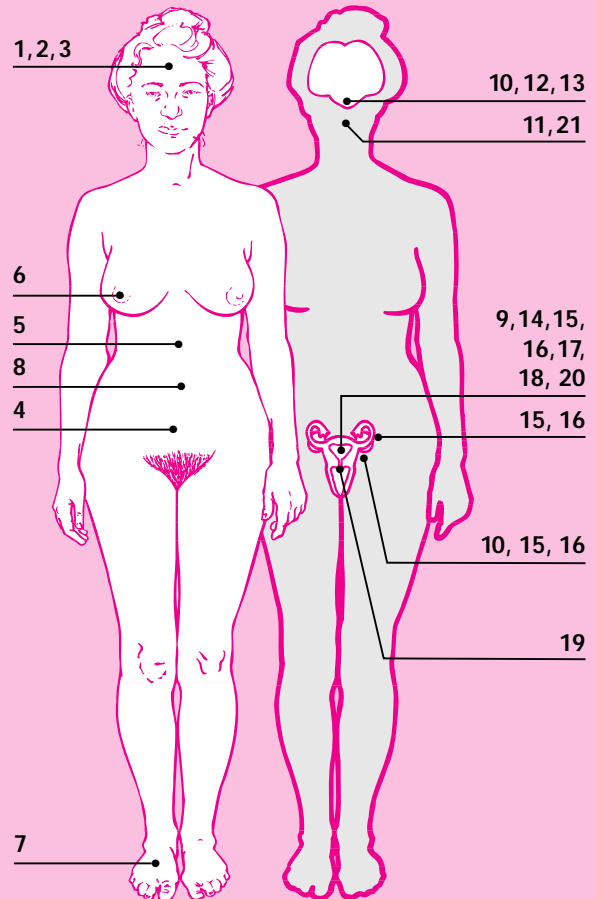
- 16** Similar damage caused by endometriosis, gonorrhea, or syphilis.

Heavy periods may suggest:

- 17** A troublesome intrauterine contraceptive device.
- 18** Some type of tumor, most notably (benign) uterine fibroids.

Postmenopausal bleeding has many possible causes. The most common are:

- 19** Cervical cancer.
- 20** Endometrial cancer.
- 21** Estrogen medication.



Menstruation guidance

Do

- Prepare girls for the onset of menstruation—otherwise their first flow of blood can be frightening.
- See a doctor if menstruation has not started by the age of 16.
- Try a mild analgesic painkiller for acute premenstrual discomfort.
- Cut down the intake of salt or try a salt substitute for some days before menstruation starts.
- Exercise: this helps to reduce the discomfort that many women feel while menstruating.
- Seek medical help if you suffer severe period pains, especially one-sided, lower abdominal pain.
- Take extra iron in your diet if menstruation makes you anemic.
- Avoid constipation (exercise and bran in the diet help); it may worsen period pains.
- Get plenty of sleep and nourishing food to help to minimize period pains.
- See your doctor if you bleed very heavily, or bleed between periods or after menopause.

Don't

- Ignore severe premenstrual symptoms.
- Drink more liquids than usual in the few days before each period begins.
- Automatically cope with period pains by “giving up” (i.e. just taking time off work or going to bed).
- Become dependent on analgesics or tranquilizers to help you cope with premenstrual tension and period pains.
- Lead a life that lacks any regular vigorous exercise.
- Allow yourself to become constipated.
- Ignore heavy, irregular, or postmenopausal bleeding episodes, or more than a few months of missed periods. The longer you leave it the more difficult it may become to treat the underlying cause.

Absence of periods

Absence of menstruation is called amenorrhea. Girls who have never menstruated by 16 may have uterus or ovary problems requiring medical help. Women who stop having periods before menopause (average onset: 48) may be pregnant or breastfeeding a young baby.

But amenorrhea is also linked with poor health, drug abuse, traveling, and emotional stress including fear, shock, depression, or tension, especially when there is loss of appetite and weight. Amenorrhea is often treatable with drugs that rebalance hormones.

Irregular periods

At certain times in life it is quite common for menstruation to be irregular. In the first months after menarche a girl may miss one or two periods (but if she has had intercourse she should test for pregnancy).

Even adult women may find that their menstrual cycle may be as short as 21 days or as long as 35. However, disorders of the hypothalamus in the base of the brain can cause periods to become irregular.

Heavy and light periods

Most women shed between two and four tablespoons of blood during each period. Some lose more, some less. At menarche, the discharge may redden only gradually. Women using contraceptive pills have light periods, and periods change as menopause approaches. Prolonged bleeding may occur at menarche, or with intrauterine contraceptive devices. Heavy bleeding may also occur for psychological reasons.

Painful periods

Dysmenorrhea (painful periods) may be primary or acquired. Primary dysmenorrhea is due to hormonal changes; it may cause a day's discomfort or cramping pain in the lower abdomen with nausea and headaches. It is often worst in tense people. Taking exercise helps, and doctors may prescribe analgesics, iron supplements, and contraceptive pills. Acquired dysmenorrhea is due to disease and features one-sided pain. Surgery may be needed.

Exercising

Doctors believe there is a close link between exercise and lack of period pains. They point out that healthy, active women and girls suffer least, and some athletes claim they feel fittest while menstruating. On the other hand many women suffering period pains perform sedentary work. This encourages constipation, which is a factor that helps to promote dysmenorrhea. Leaving school to take up a sedentary job often coincides with the onset of painful periods, at least partly because the individual may stop sports activities. Instead of taking to your bed with hot

blankets and analgesics to relieve mild pains, many doctors suggest eating an iron-enriched diet (to combat loss of iron in menstruation) and exercise. The following types of exercise are among those considered suitable. Walking: this should be brisk and done for a fairly extended period. It provides rhythmic exercise yet does not strain individual joints. Swimming: this is a fine all-around activity, exercising the heart, lungs, and muscles, and helping to keep joints flexible. Cycling: riding provides useful exercise, although some people complain it accentuates back problems. Dancing: this is helpful if it is vigorous.

Inside the female reproductive system, ovaries produce eggs and the female sex hormones estrogen and progesterone. A ripe egg from an ovary passes through a fallopian tube to the uterus. Meanwhile a penis inserted into the vagina will ejaculate sperm-containing semen. The sperm cells travel up through the cervix, and then through the uterus, to fertilize the egg. The fertilized egg travels down the fallopian tube and becomes implanted in the

uterine wall until it has grown into a full-term baby, and is forced by contractions through the vagina and out of the mother's body. Sexual (or other types of) infection can affect all parts of the female genital tract, and some parts are liable to damage or displacement. Some ailments are merely irritating, but others can cause infertility or chronic illness, and occasionally even death if not diagnosed and treated promptly enough.

Female reproductive problems

1 Ovarian cysts are sacs of mucus or fluid that grow in the egg-shaped ovaries, and which may be tiny or large enough to cause visible swelling. Some cysts become twisted, producing sudden severe pain, nausea, and even life-threatening shock reactions; troublesome or large cysts need to be drained or removed surgically.

2 Solid ovarian tumors may be benign or malignant. Some tumors produce female hormones, causing precocious sexual development in young girls or postmenopausal bleeding. A few tumors produce male hormones, which deepen the voice, shrink the breasts, and produce facial hair.

3 Salpingitis is inflammation of the fallopian tubes caused by bacterial infection, most frequently gonorrhea. Pain often occurs in the lower abdomen with cervical discharge; infertility and peritonitis (an infection of the lining of the body cavity) may be complications if the condition is left untreated.

4 The uterus in a non-pregnant woman is a small, pear-shaped organ; during pregnancy the fertilized egg embeds

itself in the endometrium (the blood-rich lining of the uterus), and the uterus enlarges to make room for the developing fetus.

5 Endometriosis is the abnormal growth of endometrial cells outside the uterus, lining the fallopian tubes, ovaries, and nonsexual organs in the pelvic region. This causes backache and abdominal pain, particularly at menstruation.

6 Fibroids are benign tumors of the uterus. They are present in 20 percent of women aged 35 to 40 and range from the size of a pinhead to the size of an unborn baby. Large fibroids disturb normal menstruation and bladder action, and require surgical removal.

7 The uterus is generally folded forward when a woman is not pregnant. Occasionally it becomes tilted backward or drops downward in some women. This causes discomfort, increases the likelihood of infections and problems with urination.

8 Cervicitis is the inflammation of the cervix—the neck of the uterus. Cervicitis is caused by bacterial or fungal infection and produces thin,

clear mucus, perhaps streaked with blood or pus.

9 Cervical erosion is a rough, reddened area lining the os (cervical opening) that requires electric cauterization if it causes persistent trouble.

10 Cervical polyps are benign tumors in the cervix linked to warts; sometimes producing bleeding, discharge, pain, and infertility. They should be removed surgically.

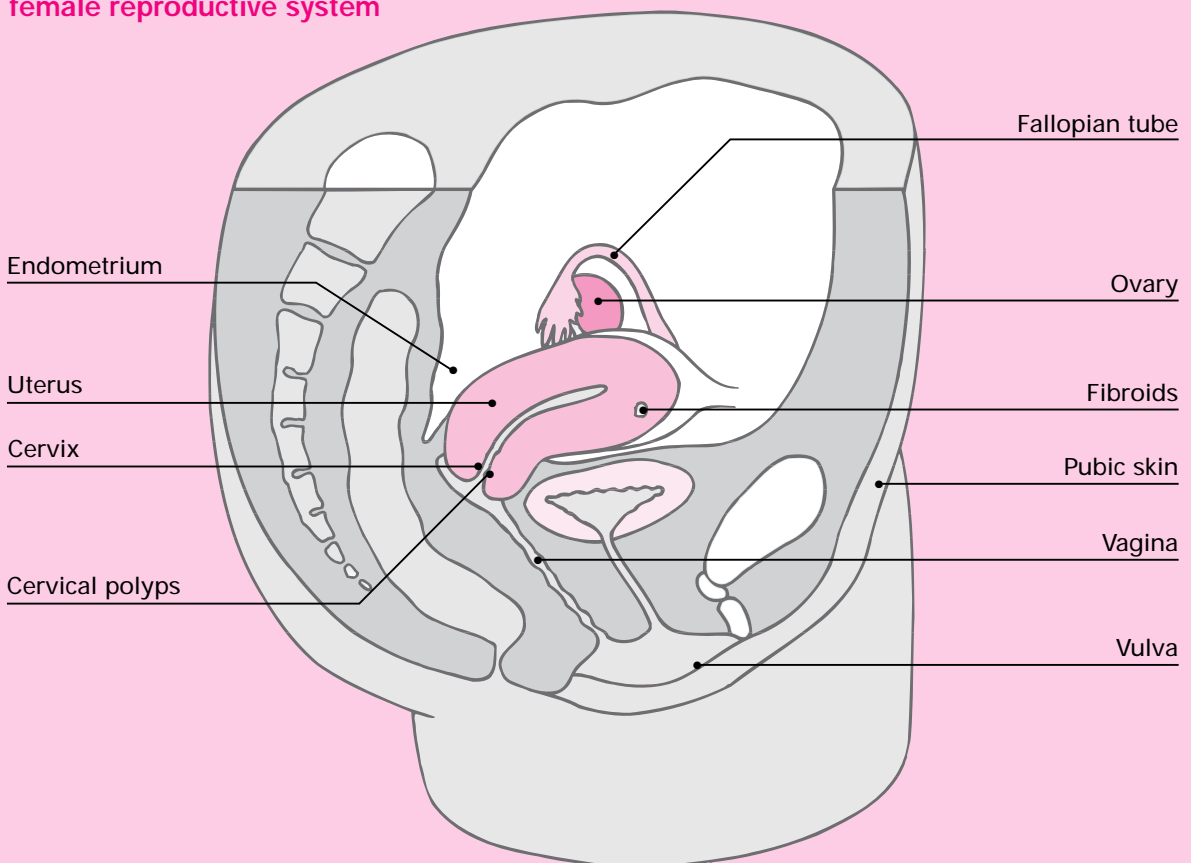
11 Vaginitis is inflammation of the vagina, the muscular passage between the cervix and the external genitals.

12 Vulvitis is inflammation of the vulva, the external female genitals.

13 Syphilitic sores and other venereal lesions may show up on the vulva.

14 Pubic skin troubles include sores, ulcers, warts, and mite and louse infestations—all resulting from sexual contact.

Cross section of female reproductive system

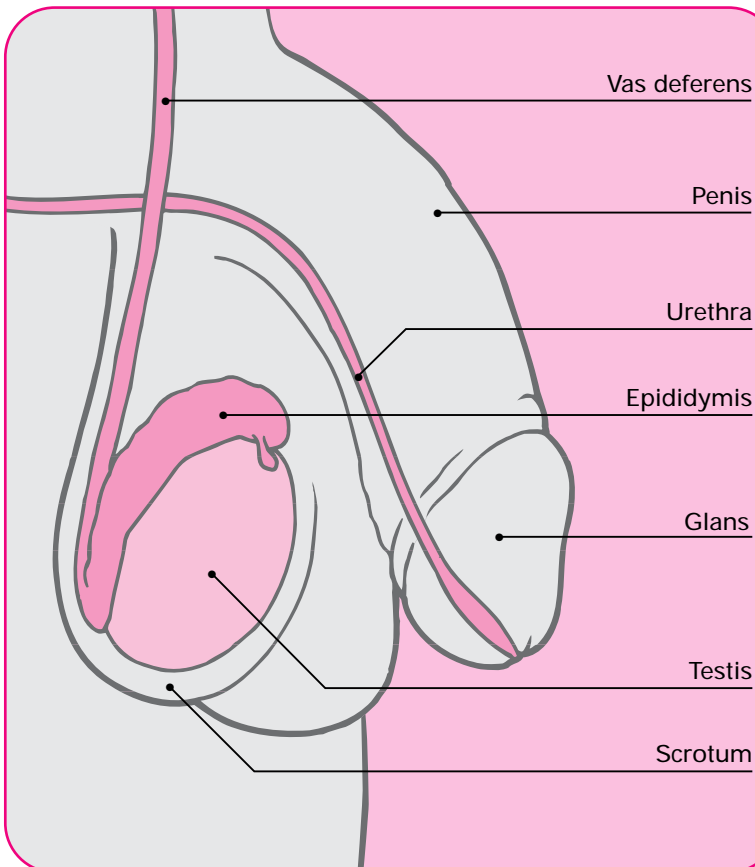


The male reproductive system produces spermatozoa, or sperm cells, in the testes. These cells are then mixed with a nutrient-rich liquid to form semen. The semen is then ejaculated at high speed through the penis while it is inserted into a woman's vagina. The penis is mainly made of erectile tissue, like a female clitoris. It becomes erect when a man is sexually aroused. The erection makes it easier for the penis to enter the vagina and also helps to stimulate the woman sexually.

Temperature-sensitive

- The exposed location of the testes means that they are at a temperature about 3°F (1.3°C) lower than normal body temperature. This is essential for sperm survival.

Male genital organs



External genitals

The male genitals differ from the female because most of them are outside the pelvic cavity. There are a few potential reasons for this. Sperm are produced most efficiently at a slightly lower temperature than the average body temperature. Therefore the testes (male gonads) are kept outside the body in the scrotum to keep them cooler.

The penis contains erectile tissue. It contains several chambers that can be filled with blood. This makes the penis rigid and erect. An erection is produced by a localized increase in blood pressure. The tip of the erectile tissue is the glans, which is highly sensitive to touch.

Male reproductive system

Structure

Seminal vesicles

Prostate gland

Vas deferens

Cowper's gland

Urethra

Penis

Epididymis

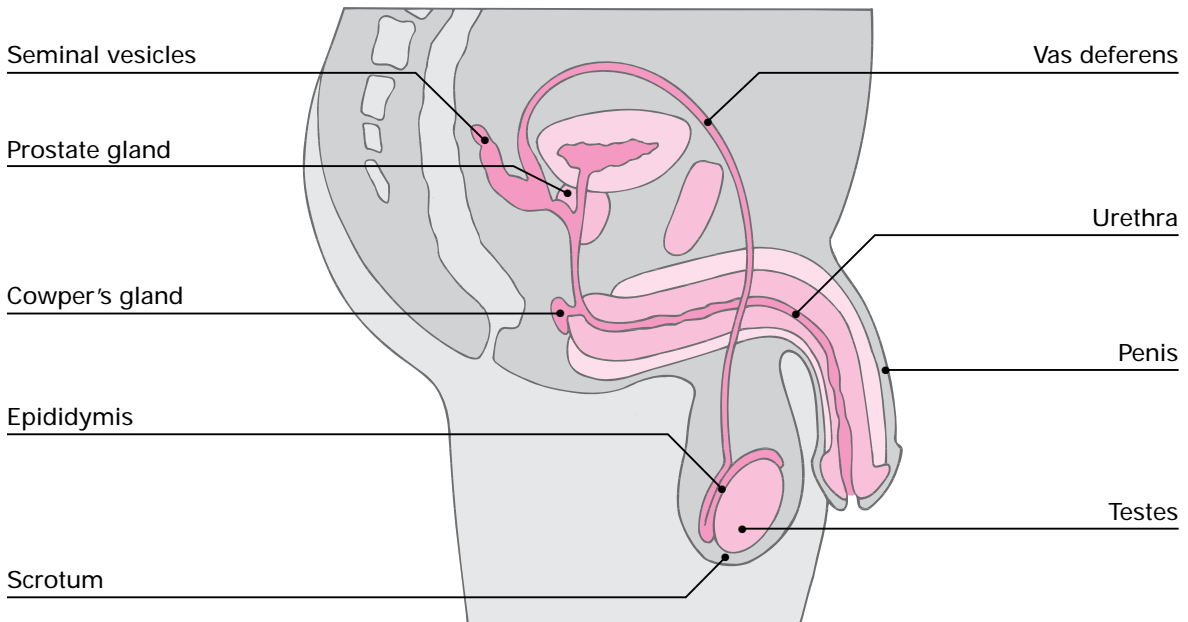
Testes

Scrotum

Functions

- Produce the semen (or seminal fluid) in which sperm (male sex cells) leave the body.
- Secretes fluid that helps activate sperm during ejaculation.
- Moves sperm from epididymis to urethra using muscular wave movements.
- Secretions form part of seminal fluid.
- Carries sperm and seminal fluid to the penis tip during ejaculation; and
- carries urine from the bladder during urination.
- Delivers sperm outside the body (in particular, to the female reproductive organs during sexual intercourse); and
- is involved in male sexual response.
- Stores sperm cells while they mature.
- Produce sperm cells and male sex hormones (regulatory chemicals) including testosterone.
- Contains the testes and keeps them cooler than the rest of the body, which is necessary for efficient sperm production.

Median section through male pelvis



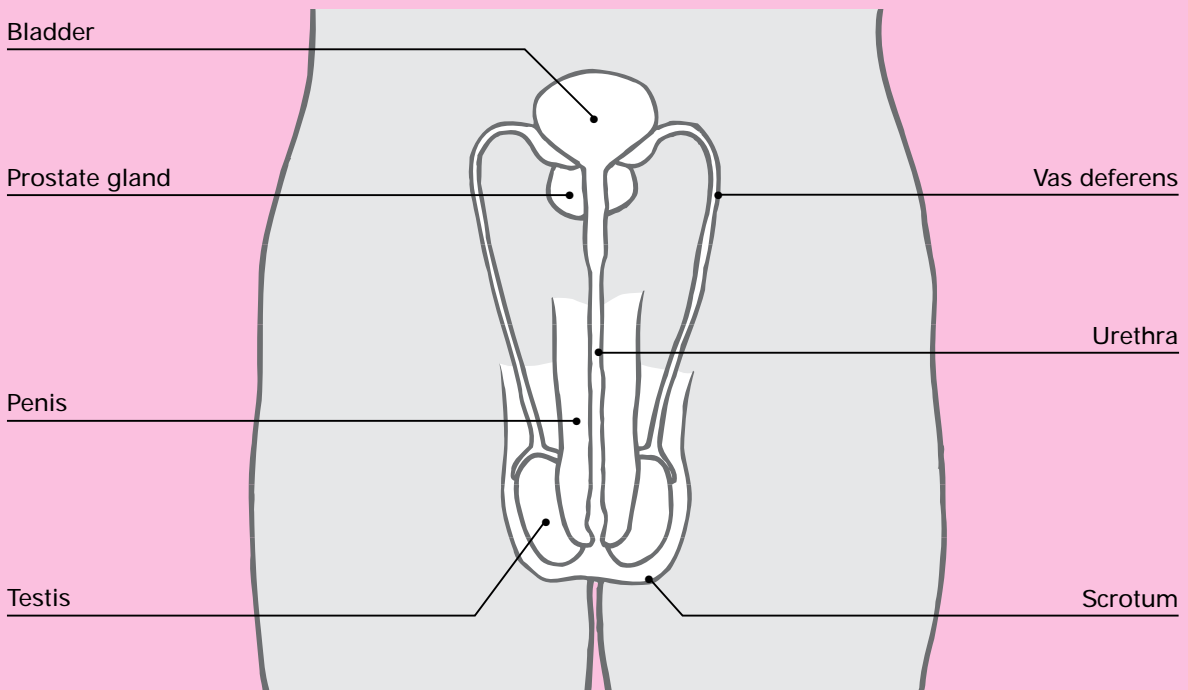
Internal male genitals

The male genitals are closely associated with the excretory system, which includes the kidneys and bladder (which holds urine and is drained through the urethra in the penis). Consequently the genitals are often described as part of the urinogenital (or urogenital) system.

Each testis forms, along with its epididymis, a testicle. Normally there are two testicles inside the scrotum, although some men have just one.

Both of the testicles are linked to the outside of the body by a system of ducts. The matured sperm leave the epididymis and travel along the vas deferens to the prostate gland. Inside this donut-shaped gland the sperm cells are mixed with fluids and nutrients that make up semen. The seminal fluids activate the sperm before it is forced out along the urethra by contractions of the glands. This is called ejaculation.

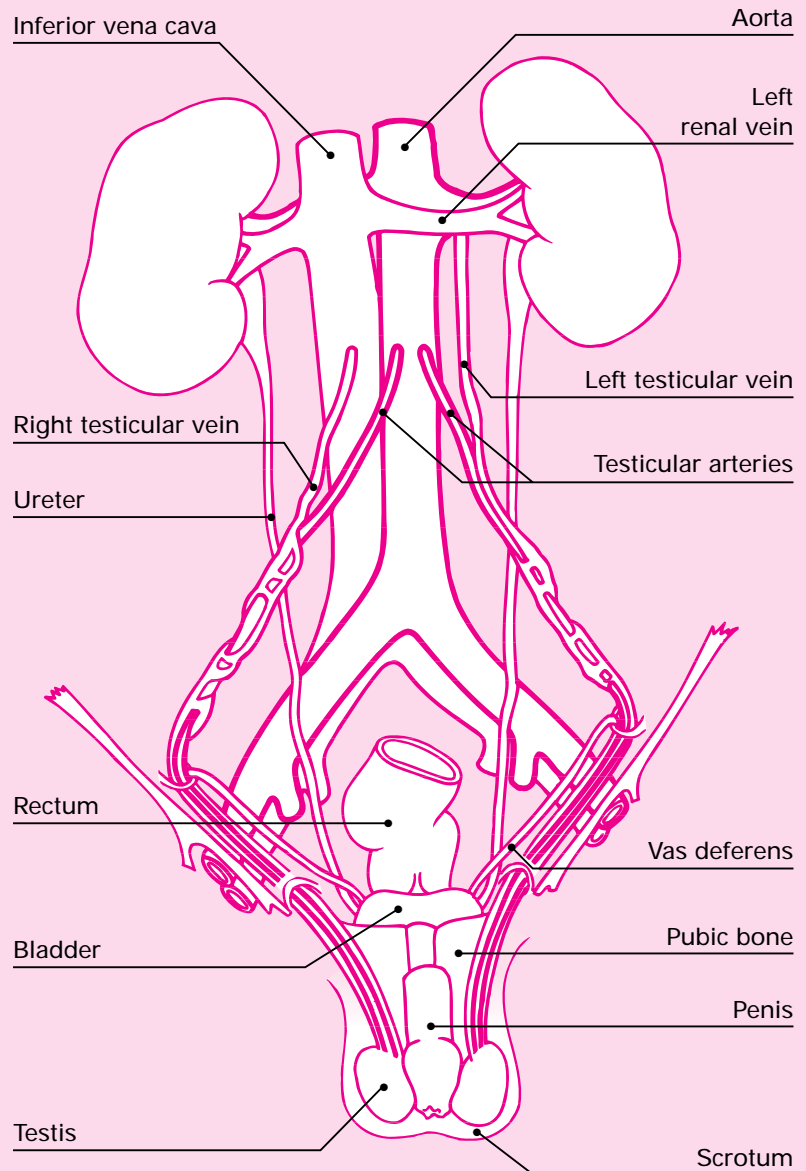
Front view of the male reproductive tract



Genital blood supply

The male genitals are supplied with blood in the same way as the female system. The blood supply for both testicles arrives directly from the aorta, the main artery coming directly from the heart. The left testicle's blood drains into the left renal vein, which serves the left kidney, while the right testicle's vein joins directly to the vena cava, the body's main vein.

Front view of male urinogenital system



Lower gonads

- The male gonads descend into the scrotum during fetal development, so the blood vessels that serve them have to be a little longer than their female counterparts.

The formation of sperm

Male gametes (sex cells) are commonly known as sperm. “Sperm” is actually short for spermatozoon (plural: spermatozoa). Spermatozoa are relatively small cells. They are unusual because they can move independently, propelled by tail-like flagella (singular: flagellum). Just like female gametes, sperm differ from somatic cells (those in the rest of the body) in that they contain half a full set of chromosomes.

(Chromosomes are cellular structures that carry genes—inherited genetic material.) When a sperm fuses with a female gamete (an ovum) their half-sets of genes are combined to make a full set, which is unique. Gametes are produced from a set of body cells called the germ line. Any mutations (genetic errors) that occur in the germ line may be passed on to the next generation. The process by which male gametes are formed is known as spermatogenesis. It involves two types of cell division: mitosis and meiosis. Spermatogenesis begins around the age of 14 and continues throughout life. Pubescent boys may be able to ejaculate before spermatogenesis has started, but their semen does not contain viable sex cells. It takes several weeks for a spermatozoon to be formed and reach full maturity.

1 Inside the testes

Spermatogenesis takes place within seminiferous tubules (coiled tubes) inside the testes. The seminiferous tubules are lined with immature cells

called spermatogonia or stem cells. Each stem cell has 46 chromosomes. This is a full set for a normal human being.

2 Mitosis

At first, spermatogonia multiply by mitosis. Mitosis is the most common type of cell division. It involves a cell splitting into two daughter cells, each of which are genetically identical, that is, they contain the same set of genes. Each of the cells produced by mitosis of spermatogonia are called primary spermatocytes. These still have 46 chromosomes.

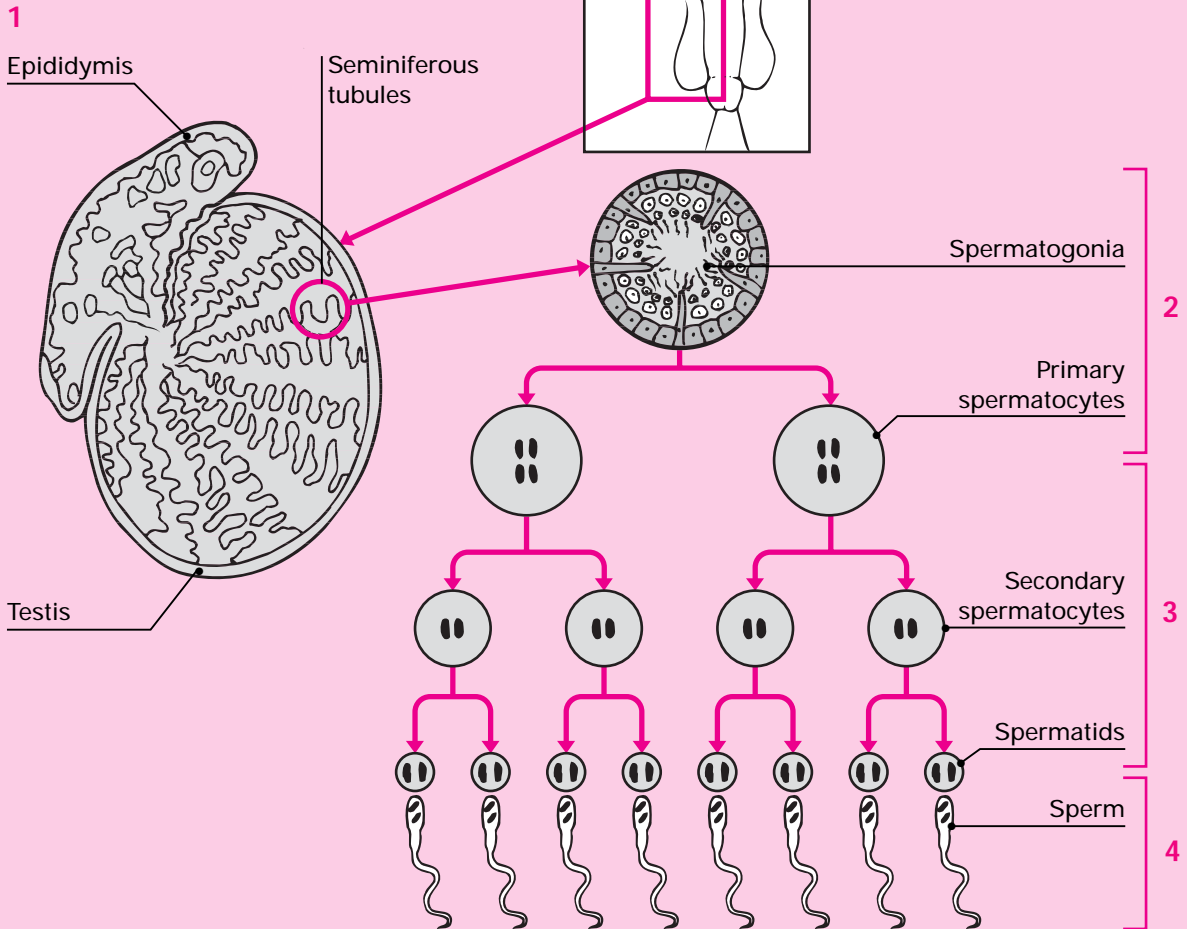
3 Meiosis

This cell division is used to make gametes only. It involves two divisions, which together produce four daughter cells, each with a unique half set of genes. The first meiotic division of a primary spermatocyte produces two secondary spermatocytes. These cells have 23 chromosomes each. The second meiotic division splits these two secondary spermatocytes into a total of four spermatids, still with 23 chromosomes in each cell.

4 Spermiogenesis

The final stage of spermatogenesis is called spermiogenesis. It occurs when spermatids mature into spermatozoa (or sperm). The final maturation process takes place in the epididymides above the testes. The entire spermatogenesis process takes about 90 days.

The process of spermatogenesis



Gametes

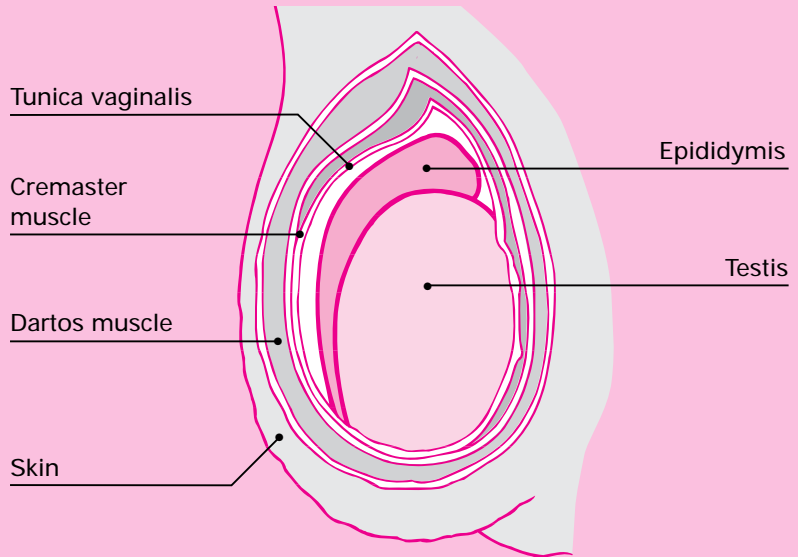
Ova (female sex cells, also known as eggs) and spermatozoa (male sex cells, also known as sperm) are collectively called gametes. Human body cells have 46 chromosomes (structures that carry inherited material). Gametes

differ from other body cells in that they only have 23 chromosomes. This ensures that when a sperm and ova fuse together the resulting fertilized cell has 46 chromosomes and no more.

The scrotum

The scrotum is made up of several layers. The outer layer is a covering of loose skin. Inside this is the dartos muscle, which contracts to wrinkle the scrotal skin. Beneath the dartos layer is the cremaster muscle. This muscle contracts to pull the testicle up. This is done chiefly when the testes are too cold. The next layer is the tunica vaginalis or vaginal tunic. This covers the testis and epididymis.

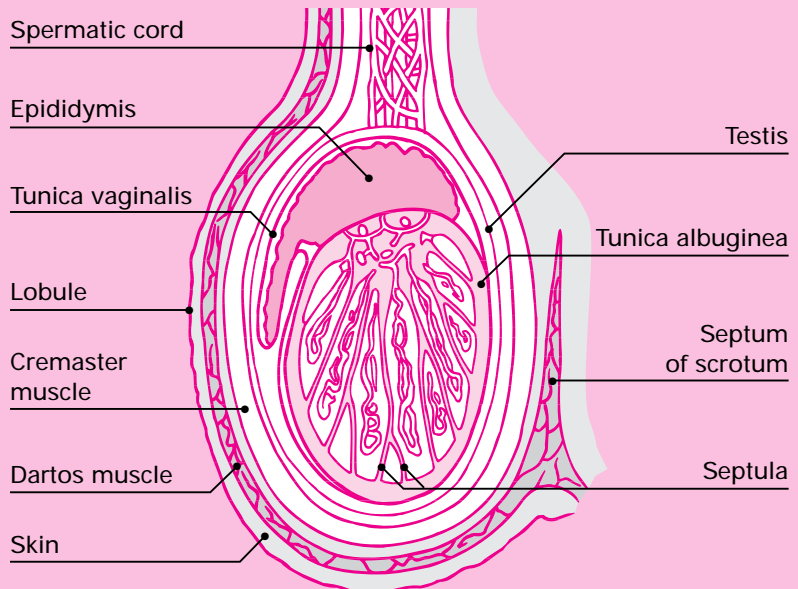
Section through the layers of the scrotum



Internal structure

The testicle is connected to the rest of the reproductive system via the spermatic cord. This holds the vas deferens, artery, vein, and nerves. Inside the tunica vaginalis is a white tissue called the tunica albuginea, which covers the lobules of the testis. These lobules are separated by septula. The fold of skin at the join between the scrotum's two testicles is called the septum.

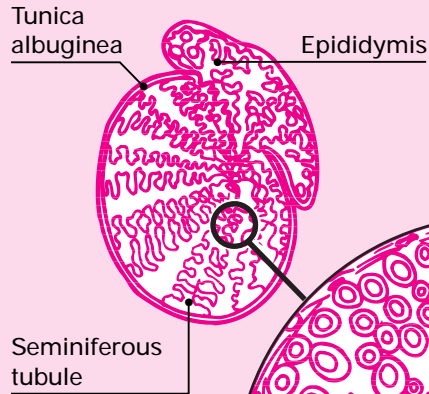
Section through testis and epididymis



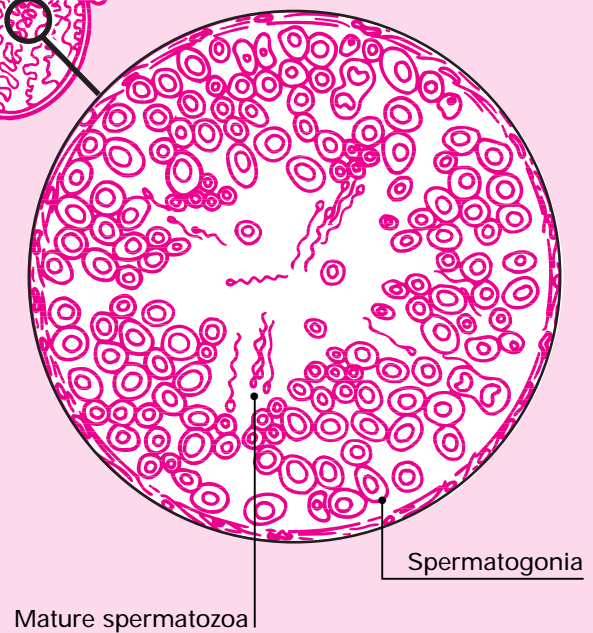
Inside the testis

Each lobule of the testis is filled with seminiferous tubules. These are lined with spermatogonia which divide into spermatocytes. These build up toward the center of the tubule. In the middle of the tubule maturing spermatozoa are found. These travel along the tubules through the testis to the epididymis. There the sperm are stored for about 10 days until they are mature.

Cross section through testis



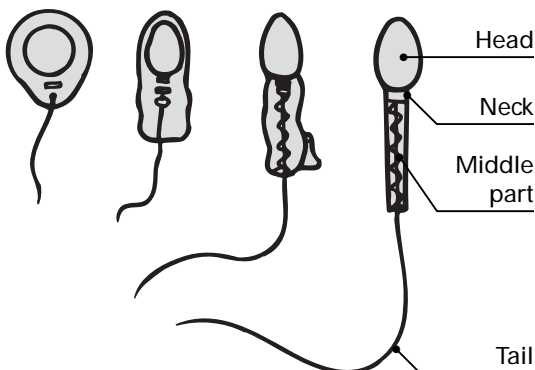
Section through a seminiferous tubule



Sperm maturation

Male gametes do not begin to develop their flagella until they become spermatids. Mature sperm are about 0.002 inches (55 μ m) long.

Stages in maturation of spermatozoa



Sperm facts

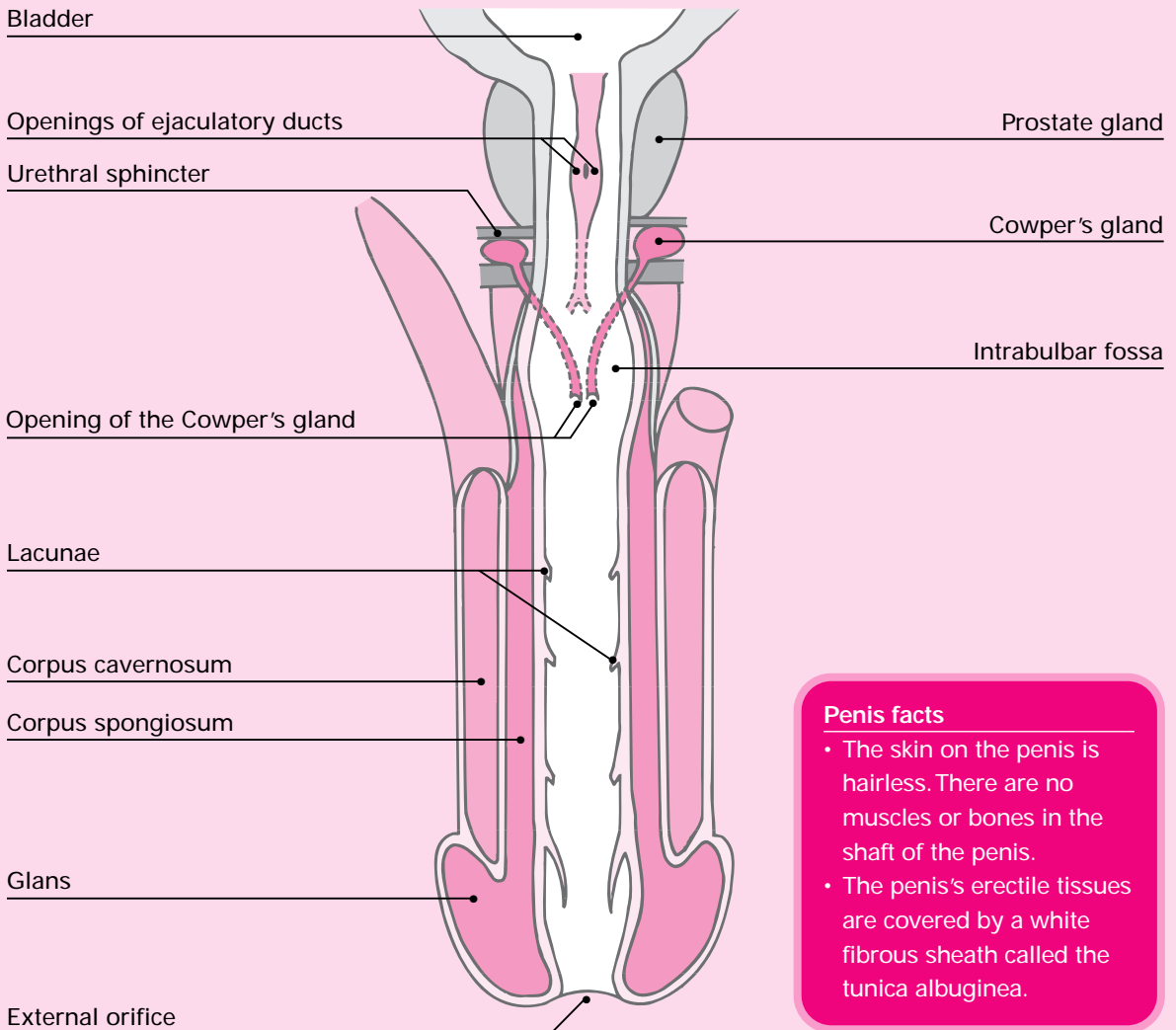
- A healthy adult male produces about 200 million sperm every day.
- The volume of ejaculated semen is generally between from 0.07 to 0.2 fluid ounce (2 to 6 ml). Each milliliter of semen contains 100 million sperm.
- Although male humans do not undergo menopause like females, sperm production does begin to drop at the age of 45.

Inside the penis

The penis is the outlet for both urine from the bladder and sperm from the gonads. Both fluids travel down the urethra, a tube at the center of the penis. The fleshy part of the penis is made up

of three shafts of erectile tissue: two cavernous bodies (corpora cavernosa) and one spongy body (corpus spongiosum). The urethra passes through the spongy body.

Section through the male urethra as seen from above



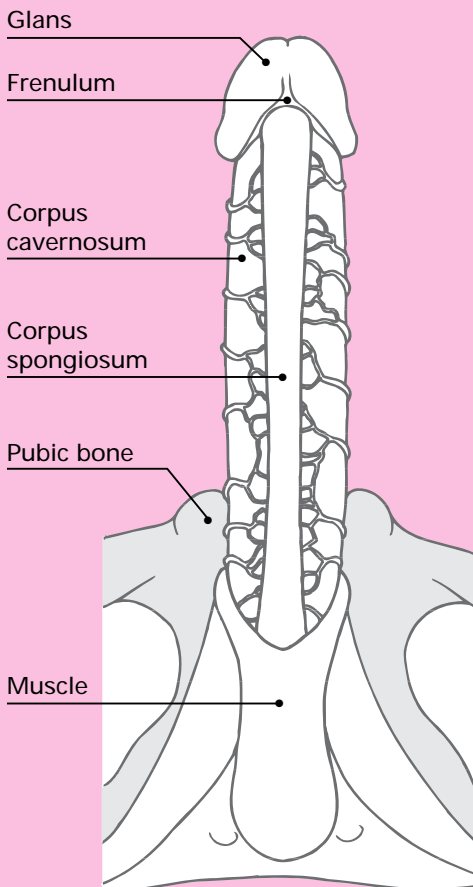
Penis facts

- The skin on the penis is hairless. There are no muscles or bones in the shaft of the penis.
- The penis's erectile tissues are covered by a white fibrous sheath called the tunica albuginea.

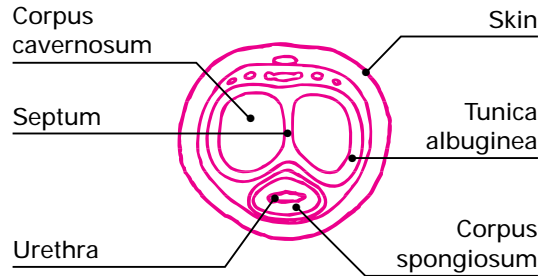
Erectile tissue

The corpora cavernosa and corpus spongiosum are erectile tissue. The two corpora cavernosa are divided by part of the tunica albuginea called the septum. The tip of the corpus spongiosum expands into the glans. This is covered by the foreskin, which is attached to the frenulum. The erectile tissue is filled with hollow caverns, or lacunae, which fill with blood during erection.

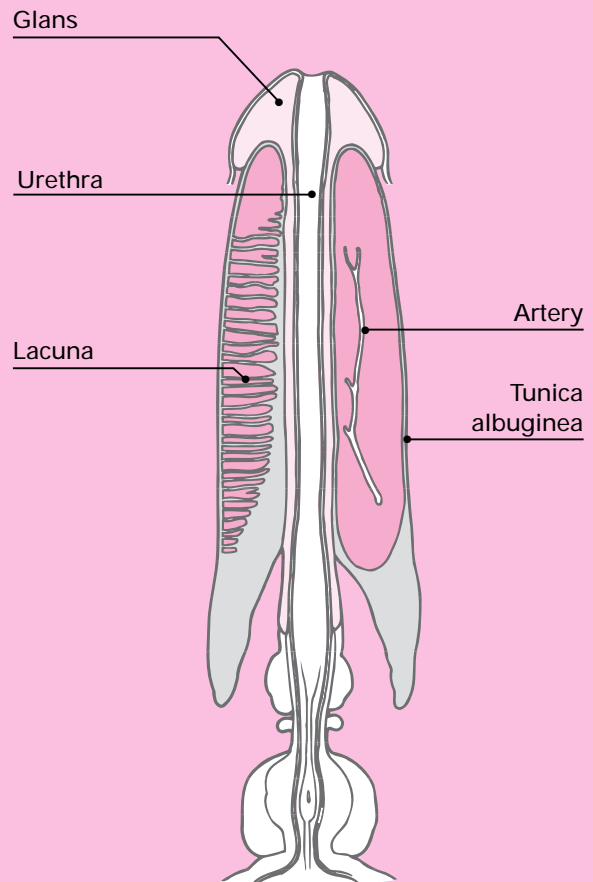
Erectile bodies and muscles



Cross section through shaft



Longitudinal section seen from above

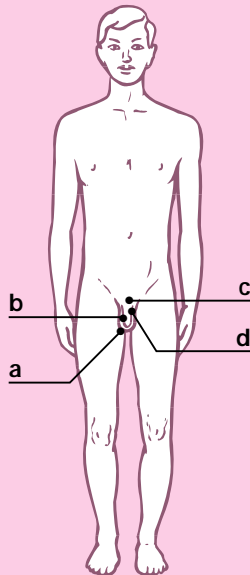


The main male sex organs are the penis and two bean-shaped testes suspended in the scrotal sac, visible below the base of the penis. Testes produce the male hormone testosterone, and sperm for fertilizing a woman's ova. Tubes carry sperm through the reproductive tract, where glands lubricate and nourish them. At orgasm muscular contractions force the resulting semen

(a sticky white fluid) through the urethra and from the tip of the penis, which is then stiff and hard. The main problems afflicting the male reproductive system are infections, congenital malformations, and benign and malignant prostate gland conditions. Most sexual conditions can be helped and anyone with a reproductive system problem should see a doctor.

Onset of puberty

This varies from boy to boy but usually starts about age 12, soon after the so-called adolescent growth spurt has set in. By age 12 the testes (a) are growing noticeably (two years earlier they are only a fraction of their adult size). Between the age of 12 and 15 the penis (b) starts to grow and undergoes spontaneous erection more often than before. Pubic hair (c) begins to grow around the base of the penis and the testes begin secreting immature sperm, with nocturnal emission possible. The prostate gland (d) grows. Between the ages of 15 and 18, mature sperm are produced and pubic hair coarsens.



Prostate problems

Prostatitis is inflammation of the prostate gland, due to urinary tract infection, and occurs in younger men. There may be pain, local tenderness, and difficulty passing urine. The acutely ill need bed rest, antibiotics, analgesics, and eight to ten glasses of water daily. Weekly prostatic massage for six to eight weeks may help. Avoid alcohol and sex. Benign prostate enlargement occurs mainly in men over 60. It may be symptomless. But if you pass urine little and often, with difficulty or discomfort, and your stools are very thin, you may need surgery. Cancer of the prostate has similar symptoms and requires surgery or hormone treatment.

Hygiene

Poor penis hygiene encourages accumulations of white smegma under the foreskin in uncircumcised men, causing inflammation of the foreskin and penis tip with an offensive discharge. Accumulating smegma is also linked with certain cancers in men and in women with whom they have intercourse. Good penis hygiene stops smegma from collecting and so prevents such troubles. Uncircumcised males should take care to wash beneath the foreskin regularly. To do this they should first retract the foreskin; if inflammation prevents this, a doctor may prescribe ointment to clear up the infection.

Hydrocele

This is a soft swelling in the scrotum, produced by a larger than normal accumulation of the fluid that helps protect the testes and leaves them free to move about. One side or both sides of the scrotal sac may be affected. A hydrocele is present in many newborn male babies and the condition usually corrects itself within the first two years of life. But if a loop of intestine herniates down into the scrotum through a channel, this may also fill with fluid, producing swelling in both the groin and scrotum. If this happens surgery is required. Any swelling in the scrotum or groin should be investigated by a doctor.

Circumcision

This practice involves removing the foreskin, a loose fold of skin that covers the glans of the penis near its tip. Circumcision is a religious requirement for Jews and Muslims. This operation has the practical benefit of preventing the build-up of smegma beneath the foreskin. However, circumcised babies are liable to get ulcers at the penis tip. As a man ages, the skin in the glans may harden and become less sensitive. Provided males maintain good penis hygiene there is no medical reason for routine circumcision; rare emergency circumcision may be required if the foreskin swells

Undescended testes

Testes develop in the abdomen and normally descend into the scrotum about eight weeks before birth. Sometimes they are only in the groin by birth but fall soon afterward. Even normally descended testes temporarily rise into the groin. If in any doubt whether testes have descended examine the baby after a warm bath, but avoid handling the testes. If both have not descended by the age of two a doctor may advise surgery if only one testis is involved, or hormonal drugs if both are undescended. Patients must be treated before puberty. Otherwise, testes and sperm may not develop properly, causing infertility and a risk of cancer.

Inguinal hernia

An inguinal hernia occurs when part of the intestine bulges down into the inguinal canal—the channel through which, in men, the testes drop into the scrotum before birth. Because this canal is larger in men than in women, more males suffer inguinal hernias than females. In men, inguinal hernia results from weak inguinal muscles; in boys it may be linked with a small developmental defect. A hernial sac may disappear while the patient lies down if the intestine slips back into the abdomen. Inguinal hernias are usually corrected by surgery to avoid the severe complications that may arise if they are left untreated.

The main problems afflicting the male reproductive system are infections, congenital malformations, and benign and malignant prostate gland conditions. Problems can arise in any part of the system. Infections and other problems involving the kidneys,

bladder, and intestines can impact the genitals. Most health problems with the sexual organs can be treated. Some can cause serious problems or even be fatal, so anyone with a worrying condition should see a doctor.

Male reproductive system and its problems

The two testes hang below the body in the scrotum where they are cool enough to produce fertile sperm. Testes secrete testosterone, a hormone producing male sex characteristics.

1 Testes that remain inside the abdomen fail to produce fertile sperm, and may also develop cancer.

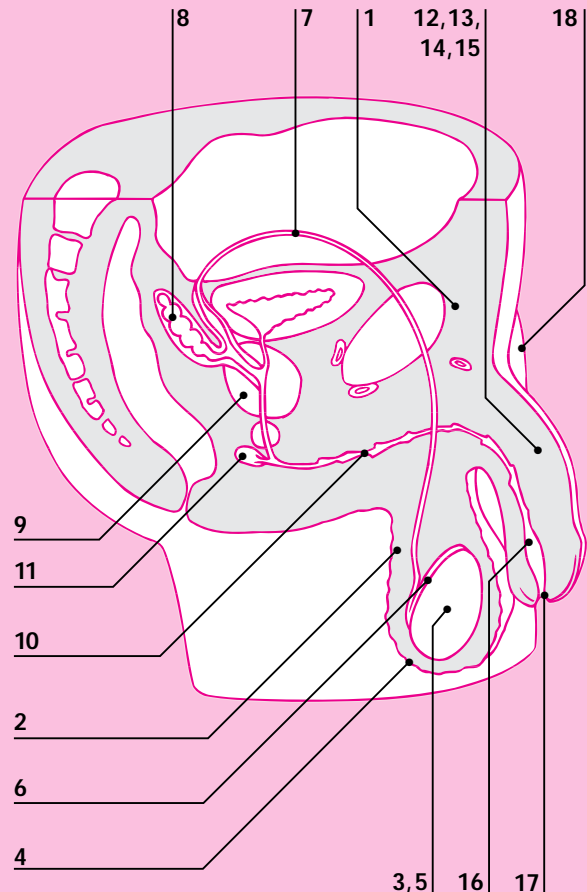
2 Scrotal swelling may result from accumulated fluid, hernias, cysts, or tumors.

3 Inflammation of testes (orchitis) is usually due to mumps but can be caused by gonorrhea. Either way the consequence may be infertility, although this is a rare complication of mumps.

4 Varicose veins around the scrotum produce the condition varicocele, sometimes causing infertility. Regularly bathing the testes in cold water may help, or veins can be removed.

5 Billions of tiny, tadpole-like sperm cells develop in tiny tubes inside the testes each month. But if a high proportion is misshapen or lacks mobility, the producer may be infertile.

6 Epididymides are convoluted tubes at the top and rear of each testis. They store maturing sperm until these are ejaculated or disintegrate. In gonorrhea, epididymides may grow inflamed and become painful.



7 The vas deferens tubes take sperm from the epididymides to the seminal vesicles. Tubal blockage by venereal diseases can cause infertility, though this can be treated by bypass surgery.

8 Seminal vesicles store sperm and secrete fluid for it. They seldom get infected.

9 The prostate gland produces fluid to feed and stimulate sperm. It is liable to suffer inflammation or enlargement. This will also cause problems with urination.

10 The urethra carries sperm and urine from the body. It sometimes suffers inflammation or blockage due to infection or kidney stones.

11 Cowper's gland adds lubricating fluid to semen. It is rarely infected.

12 The penis encloses the outer end of the urethra. When erect, the penis can be inserted into a vagina.

13 Congenital penis problems include a misplaced urethral outlet.

14 Acquired penis deformations include crooked erection due to injury; and nonsexual erection (priapism) with various possible causes.

15 Inability to achieve an erection may occur from psychological or physical causes.

16 A painful penis may be due to inflammation or obstruction elsewhere in the urinary tract.

17 Some sexual infections show as sores on, or discharge from, the tip of the penis.

18 Pubic skin troubles include sores, ulcers, warts, and mite and louse infestations—all resulting from sexual contact.

Impotence

This means being unable to gain or maintain an erection and so have sexual intercourse. Many men are impotent at some time. Nine-tenths of cases are due to fear of failure, dislike of sex, or other psychological causes. Most temporary bouts of impotence can be cured by the restoration of good communication between the partners, so that misunderstandings, fears, and unreal expectations can be removed; if the man has a warm, loving, and understanding partner his confidence, and potency, will soon return. Cases of long-term impotence may need psychological counseling, and many respond to therapy.

Urethritis

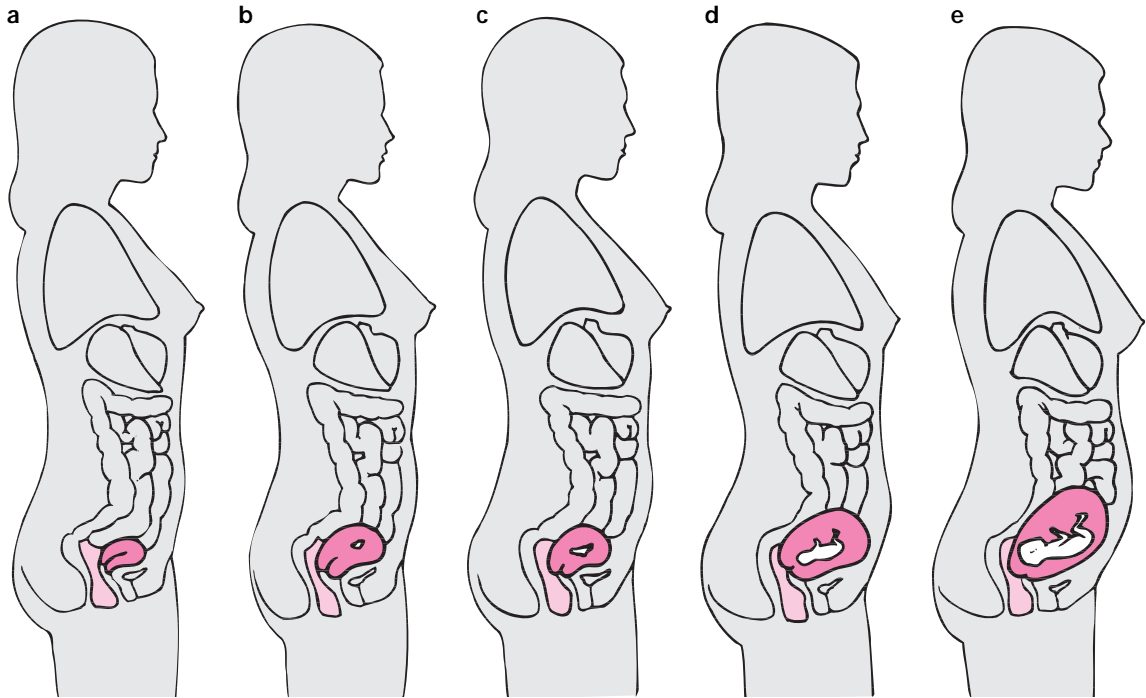
As its name implies, urethritis involves inflammation of the urethra. There may be discharge from the penis and urination can be painful. If untreated, the prostate, bladder, and testes may all become involved, with local pain and swelling. The cause may be gonorrhea, or bacteria invading the urinary system. Nonspecific urethritis (the most common type) can be due to unidentified germs or a reaction to chemicals in the vagina of the sexual partner. Patients should drink eight to ten glasses of water daily. Analgesics may relieve pain, and antibiotics kill most kinds of urethritis-causing germs.

Pregnancy is the period from conception (when a sperm and ovum fuse at fertilization) to the birth of the baby. During this time, the zygote (the single cell produced by the fusion of sperm and ovum) changes into an embryo and then, after eight weeks, a fetus. Pregnancy, also called gestation, lasts for about 40 weeks in humans. During this time the uterus expands many times over to make room for the growing baby. The word “pregnancy” is derived from the Middle English for “before birth.”

Pregnancy facts

- The average time it takes for a couple to achieve a pregnancy is six months.
- Embryos produce human chorionic gonadotrophin (HCG). This is detected by pregnancy tests.

Stages in pregnancy



a Four weeks: The zygote has developed into a ball of cells called a blastocyst. Near the end of the month, the blastocyst is implanted into the uterus's endometrium.

b Eight weeks: The major organs begin to develop from three distinct layers of cells in the fetus.

c 12 weeks: The fetus has well-developed eyes, genitals, and heart.

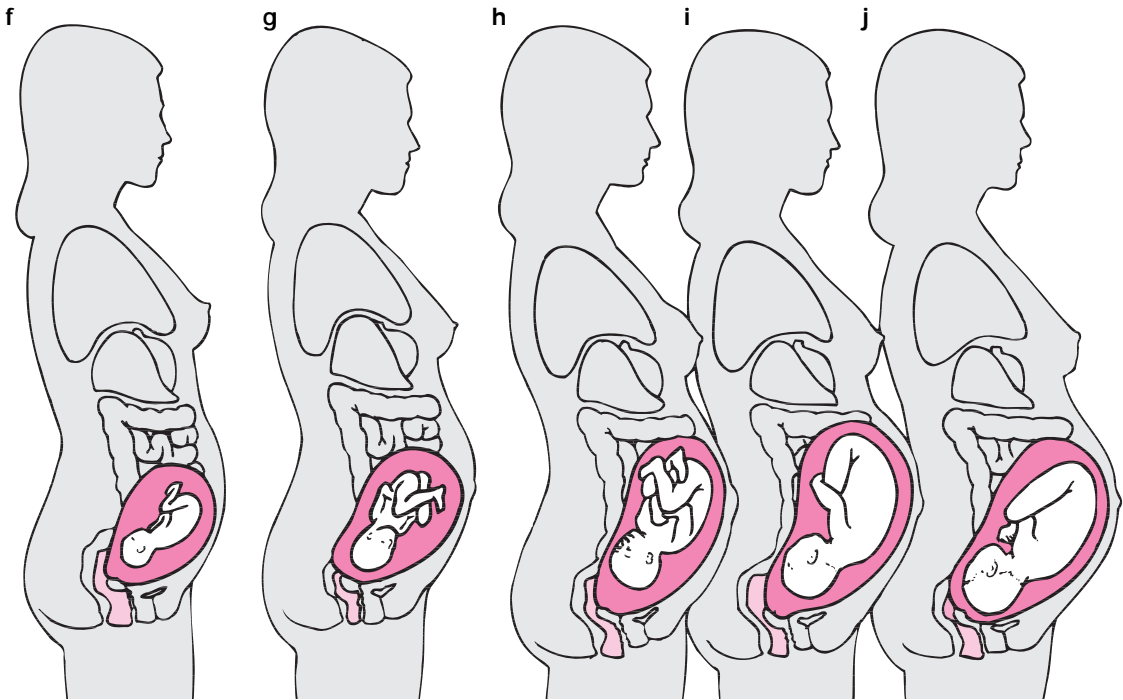
d 16 weeks: The fetus's body parts are now all in place. It can hear. Fine hairs appear on the body.

e 20 weeks: The fetus's muscles develop and its movements increase.

Signs of pregnancy

In most cases the first sign of a possible pregnancy is the lack of a period at the expected time. Soon after this, and sometimes before, a woman may start to feel sick owing to large changes in hormone levels. This may be worse in

the morning but may occur at any time. Other signs include a metallic taste in the mouth; tiredness and dizzy spells; changes in the breasts, such as tingles and tenderness; food cravings; and mood swings.



f 24 weeks: The fetus follows a pattern of sleep and wakefulness.

g 28 weeks: Fat deposits build up in the fetus's body. Waxy vernix

waterproofs the skin inside the fluid-filled uterus.

h 32 weeks: The baby's head moves down to the cervix in preparation for birth.

i 36 weeks: The fetus puts on weight and has hair and fingernails.

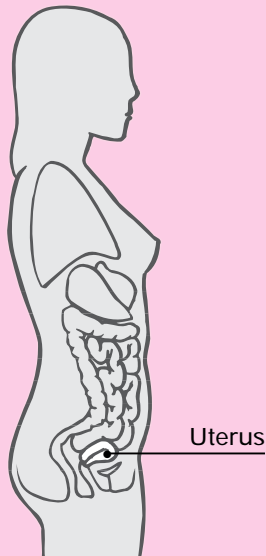
j 40 weeks: The baby is full size and is ready to be born.

A full-term pregnancy lasts approximately 266 days. Since it is impossible to pinpoint exactly when conception occurred, pregnancies are timed from the last menstrual period. This is generally 14 days before conception becomes possible. Therefore the average pregnancy lasts 280 days, or 40 weeks. For convenience this time-span is divided into three equal parts, or trimesters. Each trimester presents its own particular concerns and problems for the

mother as the baby within her develops and her body changes to accommodate it. As well as the physical changes during pregnancy, the expectant mother has to adapt her routine and her family life to prepare for the birth and homecoming of the baby. The mother's life will be altered radically, particularly with a first baby, and much of the advice given during pregnancy is designed to help her make this transition easily.

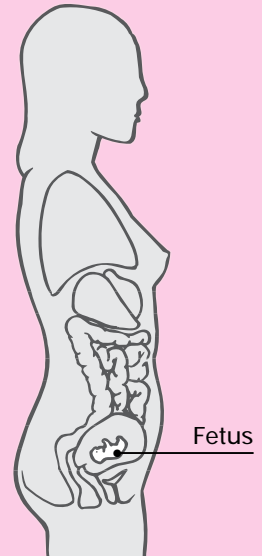
The first trimester

This period covers the first three months, or 13 weeks, of the pregnancy. By the fourth week, illustrated below, the fertilized egg is established in the uterus, and the embryo is forming, but the uterus has not yet started to enlarge. Pregnancy can usually be confirmed at week five by a urine test and at week eight by an internal examination. Drugs, alcohol, and tobacco can affect the baby's development adversely in this trimester, and so should be avoided as much as possible. Morning sickness is common during this time, but usually disappears by the end of the trimester.



The second trimester

This period covers the second three months of the pregnancy, weeks 14 to 26. By week 16, illustrated below, the mother's abdomen has begun to swell visibly; by the end of the trimester the swelling will be very marked. Early in the trimester the fetal heart can be heard through a stethoscope; by the end of the trimester the fetus will be about 13 inches (33 cm) long. By that stage its eyes will be open and it will be moving about in the uterus. These movements can be felt by the mother. The mother may develop food cravings during this trimester, but these should be indulged only if they are nutritious.



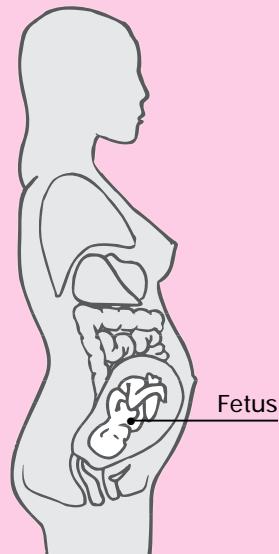
Danger signs

If any of these symptoms occur, a doctor should be seen immediately.

- Continuous headache.
- Frequent fainting.
- Blurred vision.
- Excessive vomiting.
- Severe abdominal pain.
- No fetal movements for two days in late pregnancy.
- Release of amniotic fluid from the uterus (breaking of the waters).
- Vaginal bleeding, other than small amounts at the times of the first missed periods.
- Pain on urination.
- Bad swelling of the hands, face, or ankles.

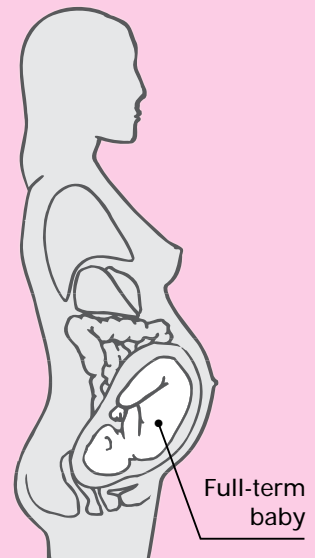
The third trimester

This period covers the last three months of pregnancy, from week 27 to about week 40. At week 28, illustrated below, the fetus is legally regarded as capable of independent life; if born at this stage it has a five percent chance of survival. Babies born before week 38 and weighing less than 5 lbs., 8 oz. (2.5 kg) are termed premature, and often require special care. During this trimester the baby increases rapidly in size and weight, and the mother's posture changes as she adapts to the increased load. Her navel flattens, and heartburn often occurs as the stomach is pushed upward by the displaced diaphragm.



At birth

By week 40, illustrated below, the baby's head is engaged in the mother's pelvic cavity ready for birth. If the baby is not in the correct position, it can sometimes be turned by careful manipulation of the mother's abdomen. The baby is about 20 inches (50 cm) long and weighs on average 7 lbs., 8 oz. (3.4 kg). When the mother's body is ready to give birth, the uterus contracts rhythmically, producing labor pains. The early contractions soften and open the cervix, and later contractions push the baby out of the mother's body through the vagina, or birth canal.



Fertilization

Fertilization (or conception) occurs when the nucleus (control center containing the genetic material) of a sperm (the male sex cell) penetrates the cell body of an ovum (the female sex cell, also called an egg). The genetic material of both sex cells are combined to make a single cell with a full and unique set of genes. The resulting fertilized cell is called a zygote. The fertilization process involves several steps.

1 The sperm releases an enzyme (a specific protein that acts as a biological

catalyst) from its acrosome, a vesicle on its head. This enzyme helps the sperm to burrow through the cells surrounding the egg.

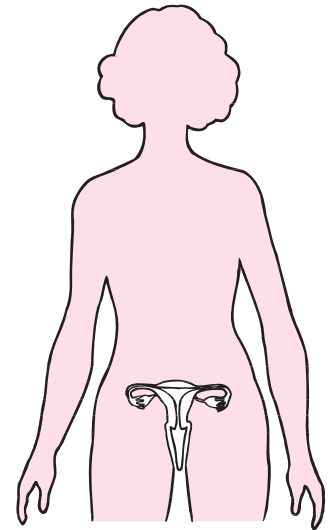
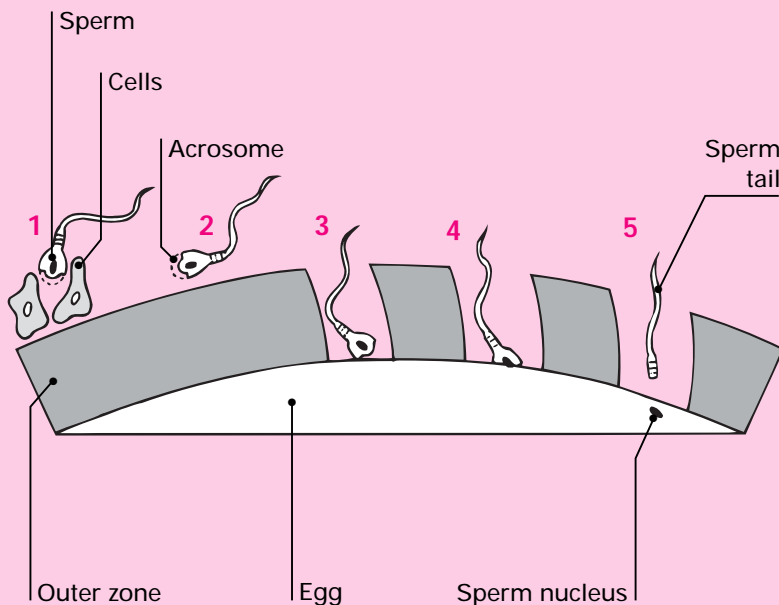
2 The acrosome disintegrates and the head binds itself to the egg's outer zone.

3 The sperm tunnels through the outer zone.

4 The sperm fuses with the egg.

5 The nucleus of the sperm enters the egg and the sperm tail drops off. The surface of the egg changes to shut out other sperm.

Stages of fertilization



Key position of reproductive organs

Fertilization generally takes place in the fallopian tubes.

The egg's journey

1 Within an ovary, a follicle (saclike structure) ruptures, releasing an egg. Ovulation has occurred.

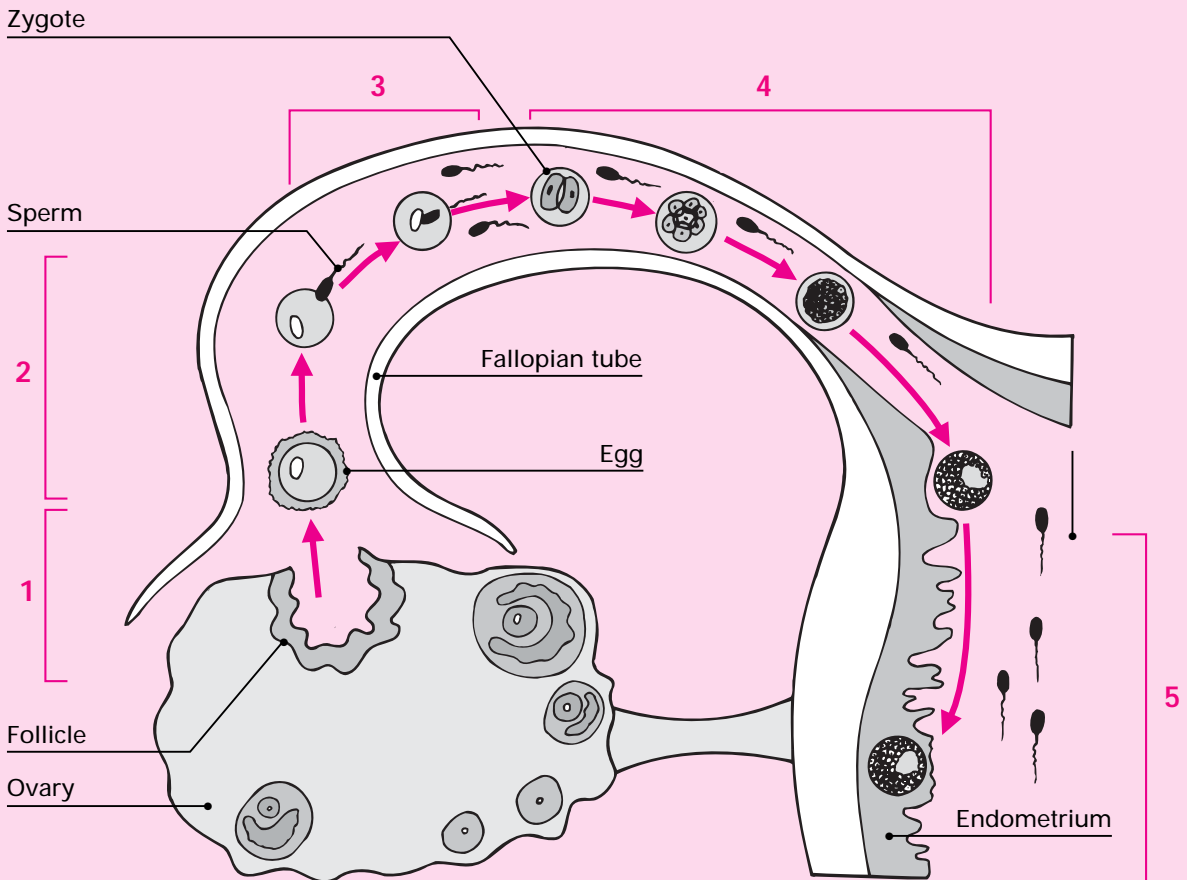
2 The egg passes into the fallopian tube. There is no direct link between the ovary and its fallopian tube. In the seconds after ovulation, the egg is moving freely in the body cavity.

3 In the tube, the egg is fertilized by a sperm swimming the other way.

4 The resulting zygote starts to divide by mitosis as it passes down the fallopian tube toward the uterus.

5 In the uterus, the ball of cells resulting from the original zygote becomes embedded in the endometrium (uterine lining), and the placenta develops.

From ovary to uterus



Development of the egg

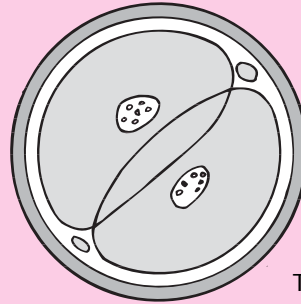
As soon as fertilization occurs, the nucleus of the sperm fuses with that of the egg. This effectively creates a new cell, which is called a zygote. The zygote immediately begins to divide.

1 First, it is divided by mitosis into two cells. Mitosis is the most common type of cell division. It produces two daughter cells from the original. Each cell has a full set of genes. In the case of humans this is 46 chromosomes. Mitosis continues, with the two daughter cells dividing into four cells, then eight, and so on, forming a ball of cells.

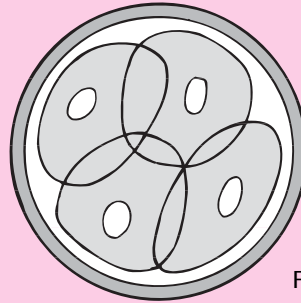
Early signs of pregnancy

The sign most usually noticed first by a woman who has conceived is that her next period fails to arrive. She may notice a tingling, fullness, or heaviness in her breasts or abdomen, or she may need to pass urine more often than usual. Morning sickness may appear very early in pregnancy, and she may notice a sudden distaste for alcohol, smoking, or certain foods. The pregnancy is usually confirmed by a urine test, using a home kit or arranged by a doctor. As soon as a pregnancy is certain, medical advice on prenatal care should be sought for the welfare of both mother and baby.

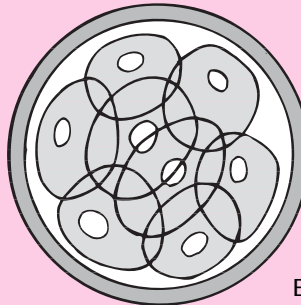
1



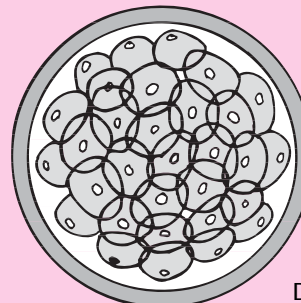
Two cells



Four cells

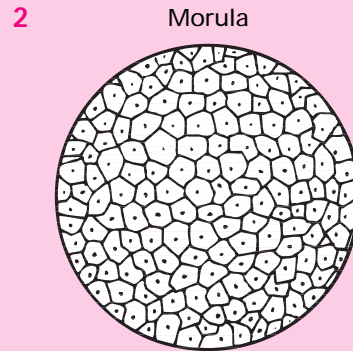


Eight cells

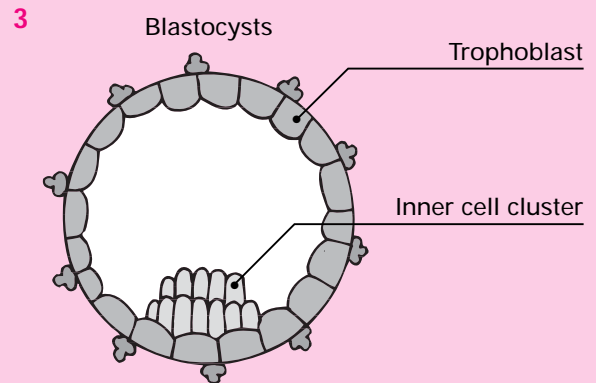


Division continues

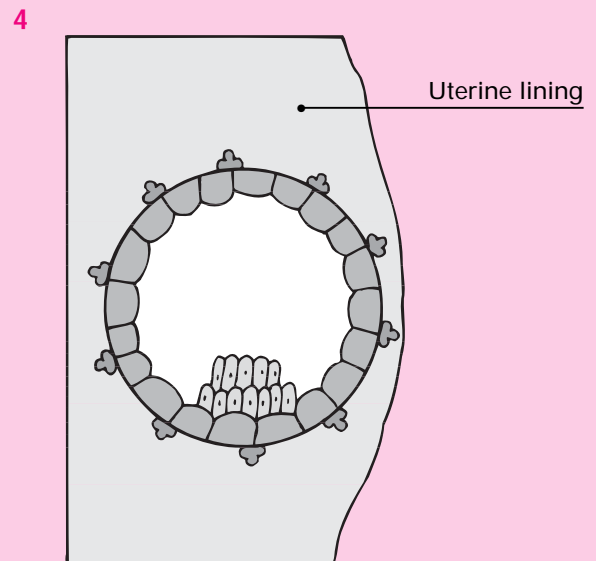
2 After three days, a ball of cells (called a morula) has formed from the single zygote. This travels along the fallopian tube into the uterus.



3 After four to five days, the morula turns into a hollow ball called a blastocyst. It has outer cells that form a wall called a trophoblast within which are a fluid-filled yolk sac and a cluster of inner cells. Certain cells in this cluster will develop into the embryo. Others will form part of the placenta.



4 The blastocyst sinks into the uterine lining, where the inner cells are nourished by a rich supply of blood vessels. The placenta, a nourishing organ, grows from both uterus cells and those in the blastocyst.

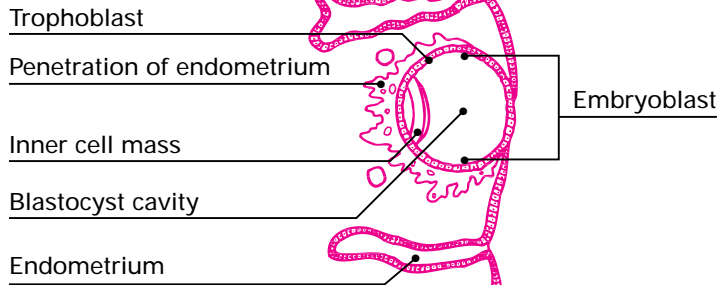


Development of the embryo

Blastocyst implantation

The outer layer of the blastocyst is called the trophoblast. A thick point in the trophoblast forms the inner cell mass, also called the embryoblast. The embryo will develop from this mass. Some outer trophoblast cells penetrate the endometrium.


Implantation



Early development

The trophoblast forms an outer membrane called the chorion. Two cavities form in the inner cell mass. The yolk sac surrounds the more central cavity, while the amnion surrounds the other. In humans, the yolk sac remains small. The amnion grows to surround the embryo as it develops.


Three membranes



Embryo and placenta

A connecting stalk develops from the cells beside the two inner cavities. This is the start of the umbilical cord. The embryo develops from the cells between these two cavities. These cells first differentiate into two layers: the endoderm and ectoderm.

Further development



Pregnancy guidance

Do

- See a doctor as soon as you suspect you may be pregnant.
- Follow any health care advice given by your doctor or clinic.
- Attend all your recommended prenatal visits and classes.
- Take a bland drink during the night or first thing in the morning if you suffer from morning sickness.
- Take extra care of your teeth and gums during pregnancy.
- Try to rest with your feet up at least once a day.
- Eat a diet rich in calcium and vitamins.
- Eat plenty of fruit and cereal to avoid constipation.
- Take regular gentle exercise in the fresh air.
- Wear comfortable, loose-fitting clothes.
- Wear shoes with low, wide heels.
- Wear a well-fitting brassiere.
- Wash and massage your nipples daily.
- Wear support stockings if you suffer from tired legs.
- See a doctor immediately if you develop any of the warning signs listed on page 61, or have any other cause for alarm.
- Completely avoid alcohol and smoking.

Don't

- Use a vaginal douche.
- Use any drugs, including over-the-counter preparations and home remedies, without consulting a doctor.
- Use powerful laxatives to relieve constipation.
- "Eat for two."
- Put on more weight than recommended by your doctor.
- Eat a diet high in carbohydrates.
- Eat spiced or fatty foods if you suffer from morning sickness.
- Eat spiced foods or carbonated drinks if you suffer from indigestion, gas, or heartburn.
- Have intercourse in the last few weeks of pregnancy.
- Have intercourse earlier in pregnancy if your doctor advises against it.
- Continue sports that include a high risk of falling, such as horseback riding, skiing, or rock climbing.
- Travel in airplanes late in pregnancy. Lower cabin pressure can prevent oxygen from reaching the baby.
- Wear shoes with high, spindly heels.
- Wear tight-fitting clothes that may restrict the circulation.

Amniotic fluid

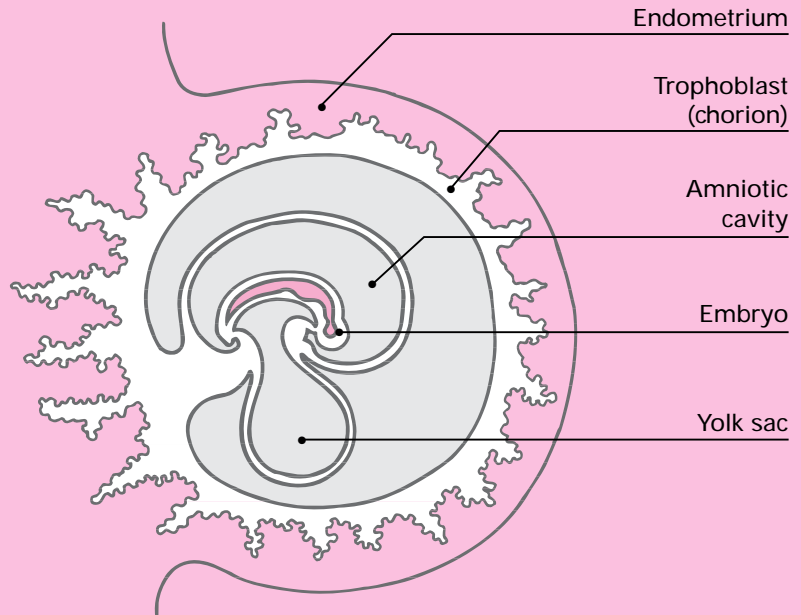
- The fetus drinks amniotic fluid during its development. It is absorbed into its bloodstream and passes through the placenta into the mother's blood.

Amniocentesis

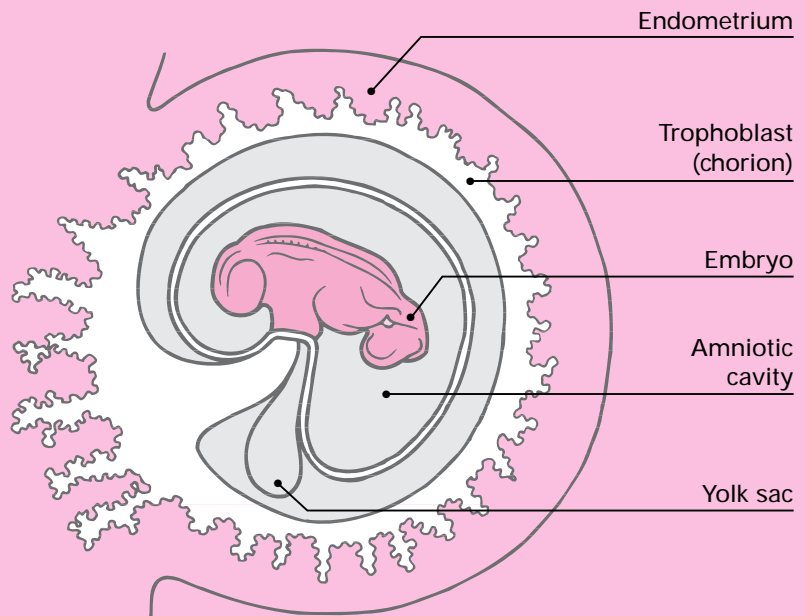
- Doctors take a sample of the amniotic fluid using a syringe to find out about the health of a fetus. The fluid contains the DNA of the fetus, which can show congenital problems.

Embryo: 3 weeks

At three weeks the embryo is differentiated from the rest of the blastocyst. Now the growing blastocyst protrudes from the endometrium. Nutrients pass through the chorion to nourish the embryo. The amniotic cavity begins to engulf it, while the yolk sac begins to shrink. The connective stalk lengthens as the umbilical cord begins to develop.

**Embryo: 4 weeks**

In the fourth week the head, heart, and coiled tail section of the embryo become visible. The yolk sac continues to shrink. The chorion below the lengthening connective stalk enlarges and extends into the endometrium forming the first part of the placenta. The placenta will supply oxygen and nutrients to the embryo and take its waste away.



Embryo growth: 4 to 8 weeks



Embryo at
4 weeks



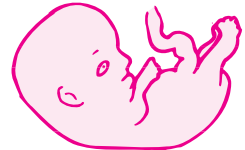Embryo at
5 weeks



Embryo at
6 weeks



Embryo at
7 weeks



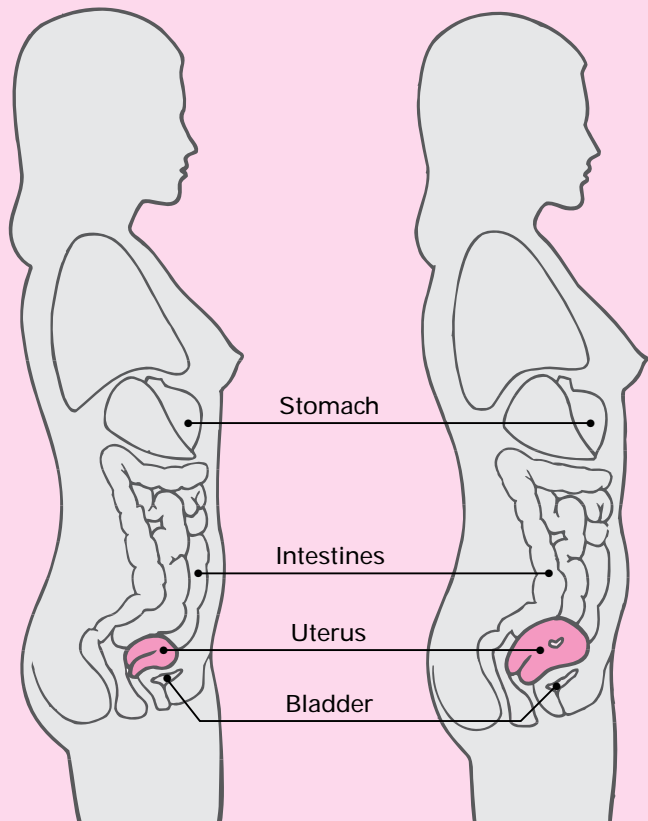
Embryo at
8 weeks

Pregnancy development

At four weeks the uterus has not yet begun to enlarge. By eight weeks, the developing early fetus begins to fill the uterus cavity and causes the uterus to grow. This has the effect of squeezing the bladder against the pubic bone, causing more frequent urination. The larger uterus pushes up against the mother's intestines and diaphragm. This raises the stomach and causes acidic stomach juices to rise up the esophagus, resulting in indigestion.

Pregnancy at four weeks

Pregnancy at eight weeks

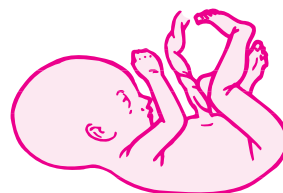

Development from 12 to 24 weeks



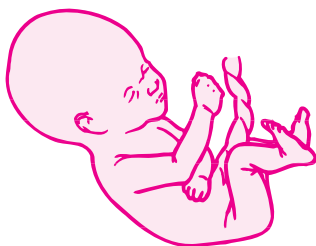Fetus at 12 weeks

At this time the fetus's genitals are visible by ultrasound. The eyes are formed as are most of the internal organs. The fingers and toes are forming but are still webbed.



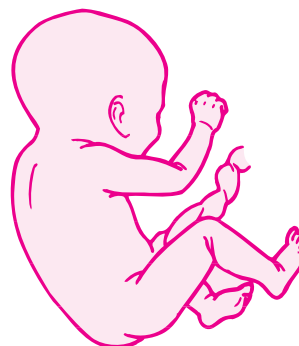Fetus at 16 weeks

All the organs and body systems of the fetus are defined. From now on the body will just grow in size. The ears begin to work and the fetus's fingerprints form.



Fetus at 20 weeks

The fetus's teeth are forming inside the jawbone, and muscles are being laid down. Consequently the fetus's movements become stronger. The fetus also responds to touch.



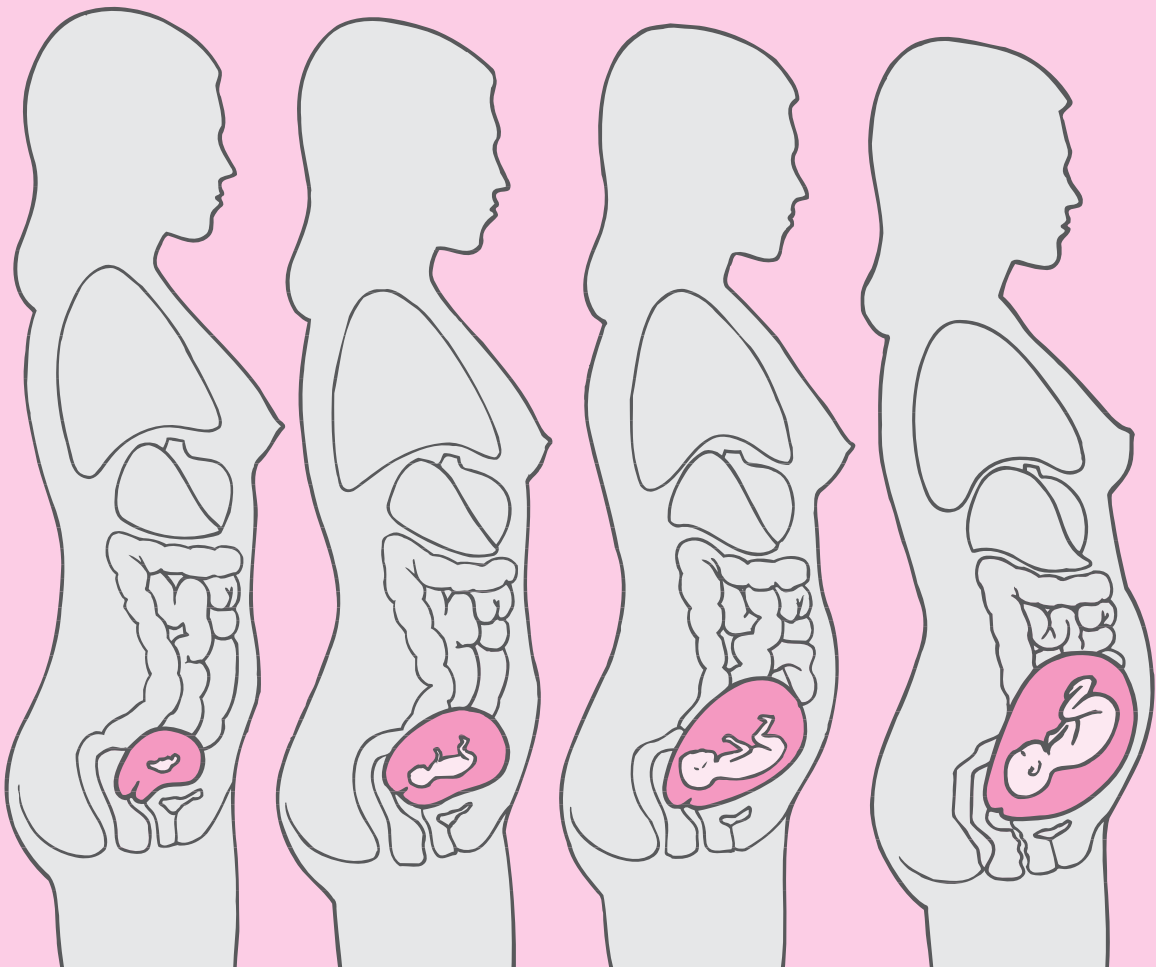
Fetus at 24 weeks

Palm lines appear on the hands. The fetus follows a pattern of sleep and wakefulness. It can even hiccup. The diaphragm begins to produce breathing motions.

Development from 12 to 24 weeks

During this period the woman becomes visibly pregnant with the uterus swelling in size. Her hormones start to stabilize ending the large fluctuations of the early pregnancy. Because of this, mood swings and feelings of nausea that may

have accompanied the first few months of pregnancy are now on the wane. The skin may darken and the enlarged fetus can be felt above the pubic bone. The mother can feel the movements of the fetus, which may begin to knock against her ribs.



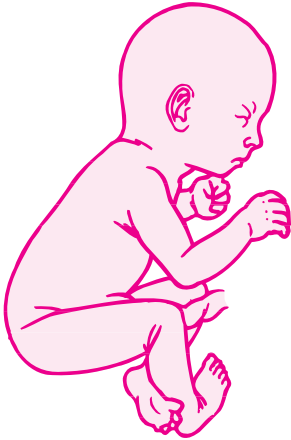
Pregnancy at
12 weeks

Pregnancy at
16 weeks

Pregnancy at
20 weeks

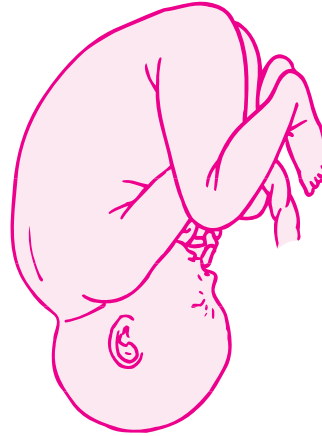
Pregnancy at
24 weeks

Development from 28 to 36 weeks



Fetus at 28 weeks

Deposits of fat are laid down under the baby's skin. To avoid becoming soggy in the amniotic fluid, the skin is coated with a waxy substance called vernix.



Fetus at 32 weeks

The fetus can now see. Generally at this time it turns head down in preparation for birth. The lungs are almost fully developed. Four out of five babies born at this time survive.

Fetus at 36 weeks

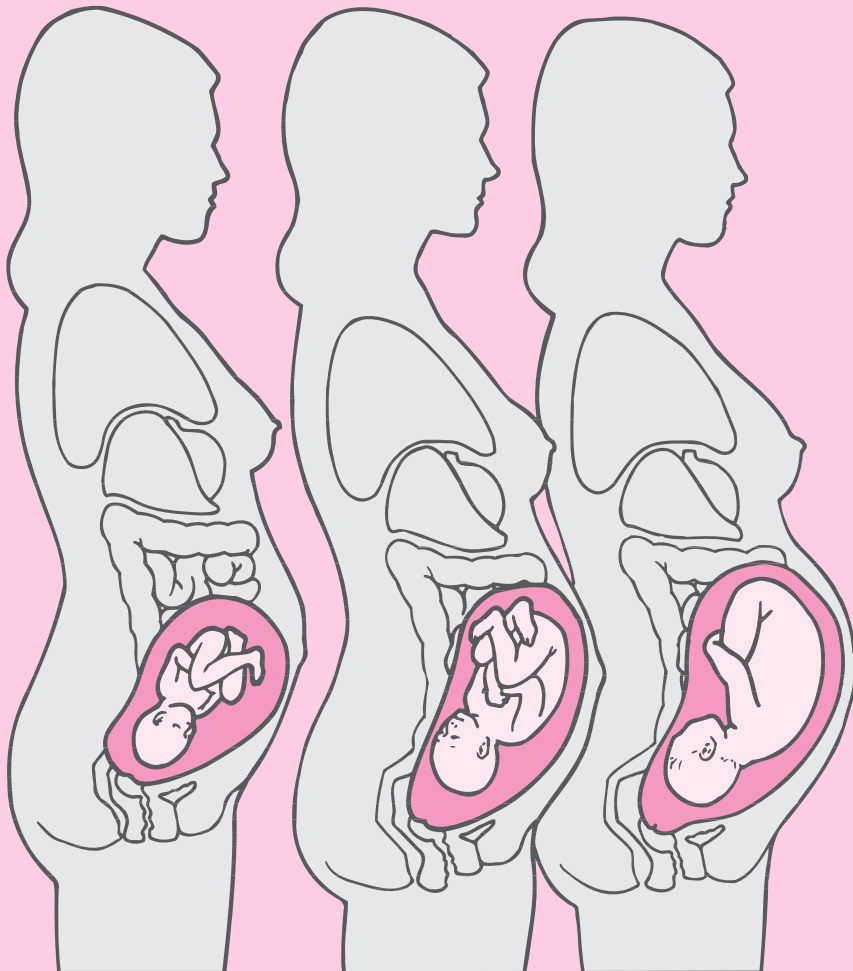
The fetus puts on weight steadily. There is at least some hair on the head and body, and the fingernails have grown to cover the ends of fingers.



Development from 28 to 36 weeks

The woman becomes noticeably bigger in this period. She may notice stretch marks on her stomach and thighs, and have a sore back. This is caused by the loosening of the pelvis in preparation for birth. The lower ribcage feels sore and the navel becomes flat. A dark line

may appear between the navel and pubic hair. In the eighth month of pregnancy the baby drops and breathlessness and indigestion problems reduce. The large abdomen may make it harder for the woman to find a comfortable position to sleep in.



Pregnancy at
28 weeks

Pregnancy at
32 weeks

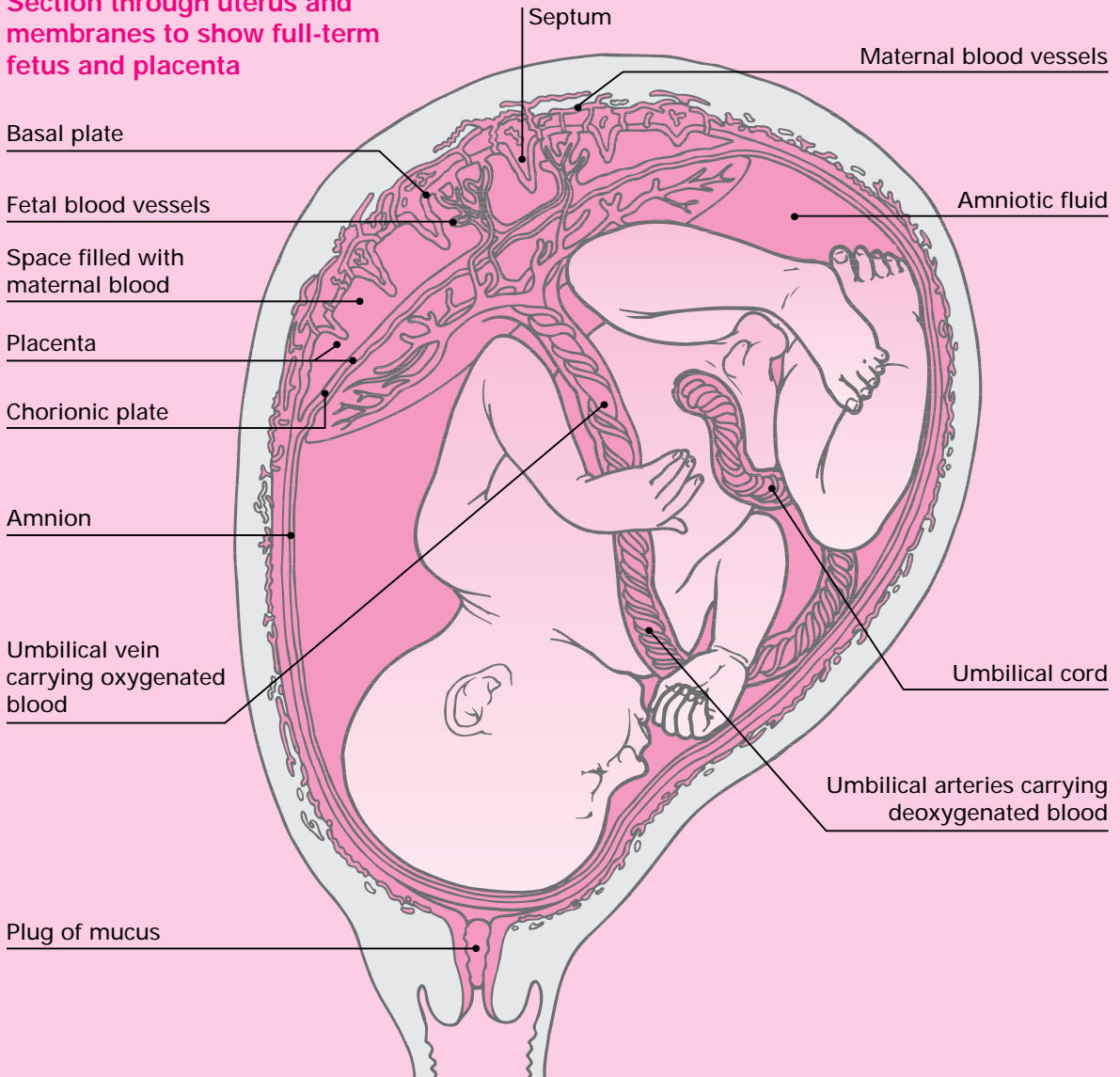
Pregnancy at
36 weeks

Placenta

The placenta is a temporary organ formed from tissues that have developed from both the mother's body and cells in the blastocyst. It is connected to the fetus by the umbilical

cord, and it brings the blood of the fetus into close proximity with the mother's. Oxygen and nutrients pass from the mother's blood into the fetus's, while waste products move the other way.

Section through uterus and membranes to show full-term fetus and placenta

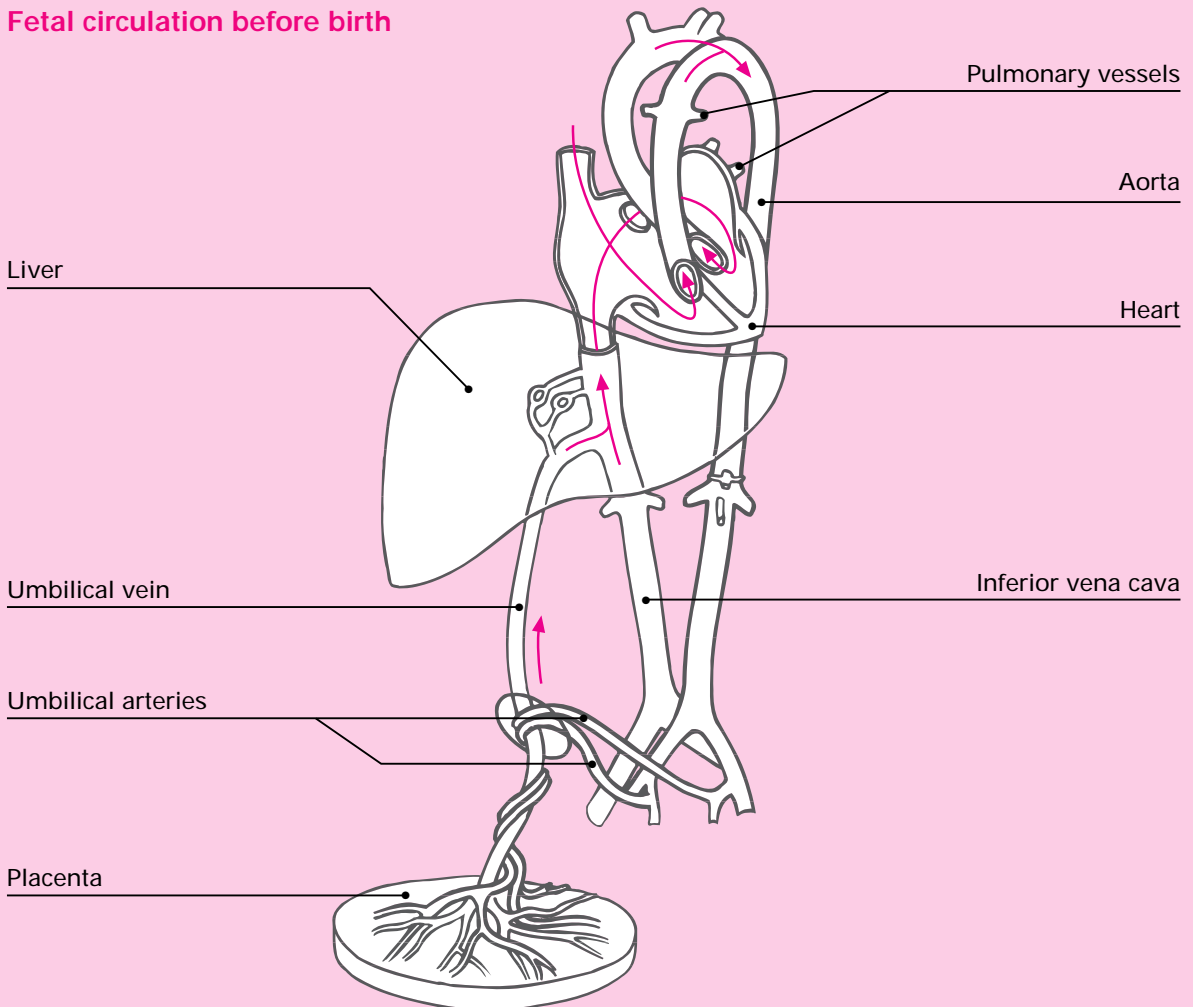


Fetal circulation

The fetus's blood not only pumps around the body, but it also circulates through the placenta via vessels in the umbilical cord. Arteries carry blood away from the heart while veins bring it back again. Generally arteries carry oxygenated blood. However, the umbilical arteries carry deoxygenated

blood away from the heart to the placenta. This blood is oxygenated by the mother's, and the large umbilical vein carries it back into the fetus where it travels through the liver and connects to the vena cava just under the heart. The pulmonary vessels bypass the fetus's developing lungs.

Fetal circulation before birth

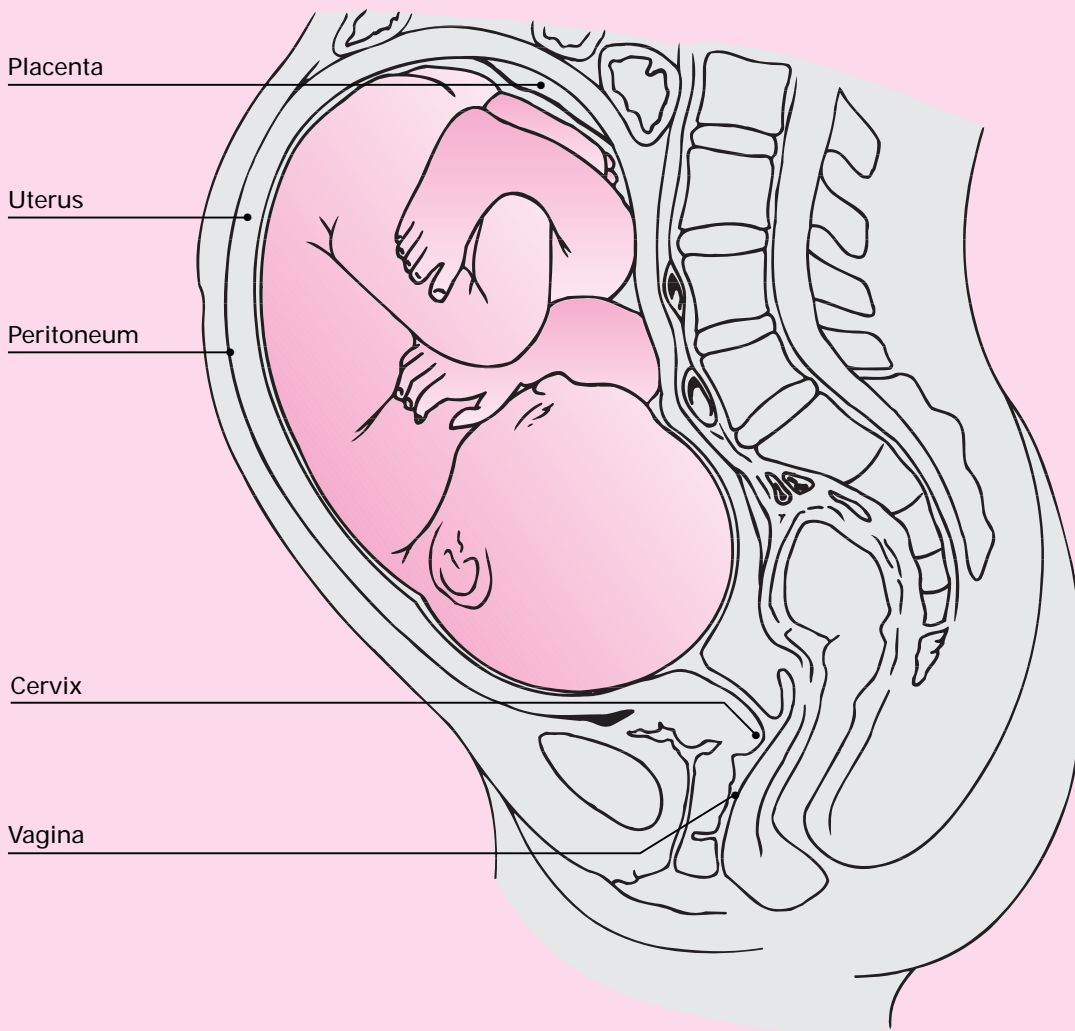


Fully grown fetus

By the 40th week the fetus is fully grown. It is held tightly in the uterus, which restricts its movements. The placenta is squeezed between the fetus and the uterus wall. If this is a woman's

first baby, the fetus's head will be engaged in the pelvis, pushing down on the cervix. Later babies may not engage until just before they begin to be pushed out by labor contractions.

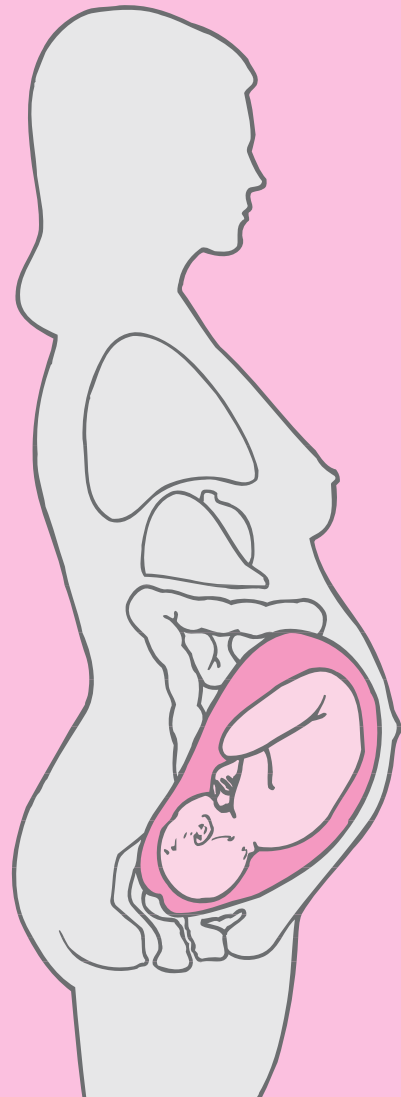
Section through the mother's abdomen, showing a baby ready to be born



Preparing for labor

The mother may experience Braxton-Hicks contractions in the last few weeks of pregnancy. These are less severe and not as regular as true labor contractions. As labor approaches the muscles of the cervix begin to soften and the pelvis widens to make room for the baby's head. The fetus presses down on the pelvis so much that it may disrupt blood supply to the legs slightly, causing pins and needles.

Full-term fetus



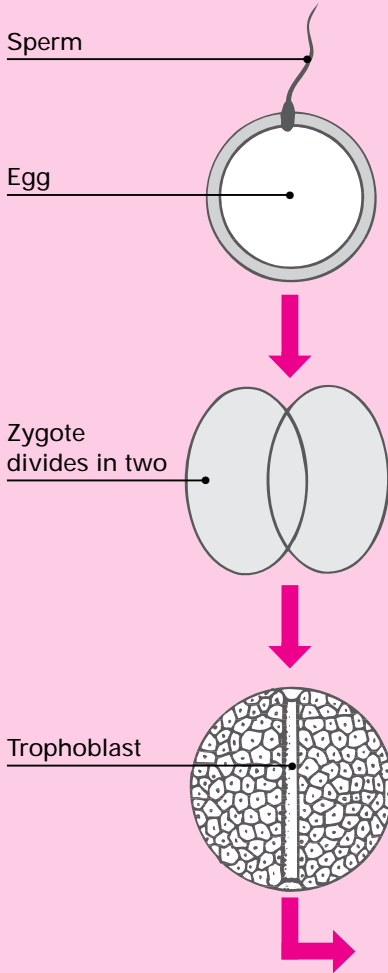
A show

- As the cervix softens and opens, the plug of mucus inside it may leak out. This bloodied mucus is called a “show” and is often the first sign that labor is beginning.

Nesting

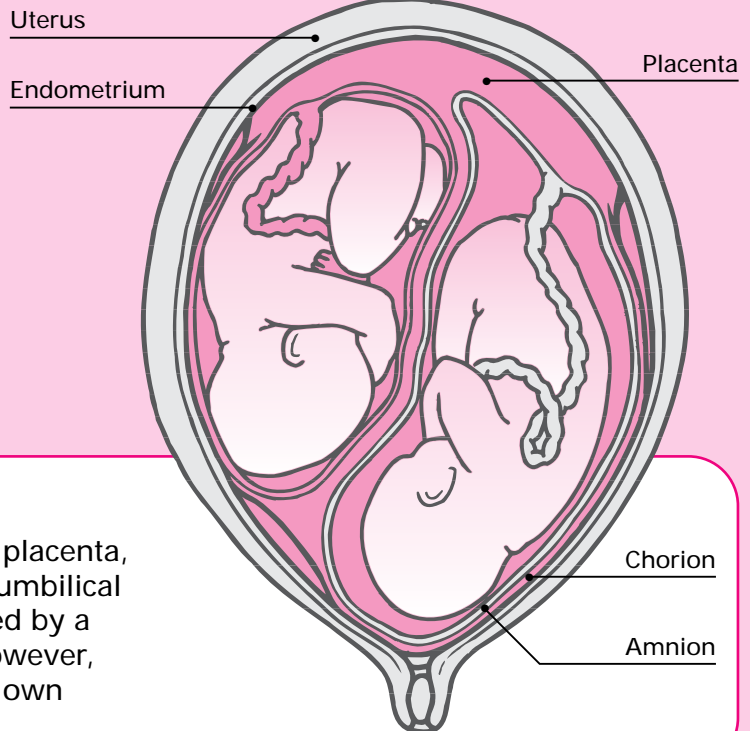
- In the weeks before birth, many expectant mothers want to clean their home and make things ready for the arrival of the new baby.

Monozygotic development



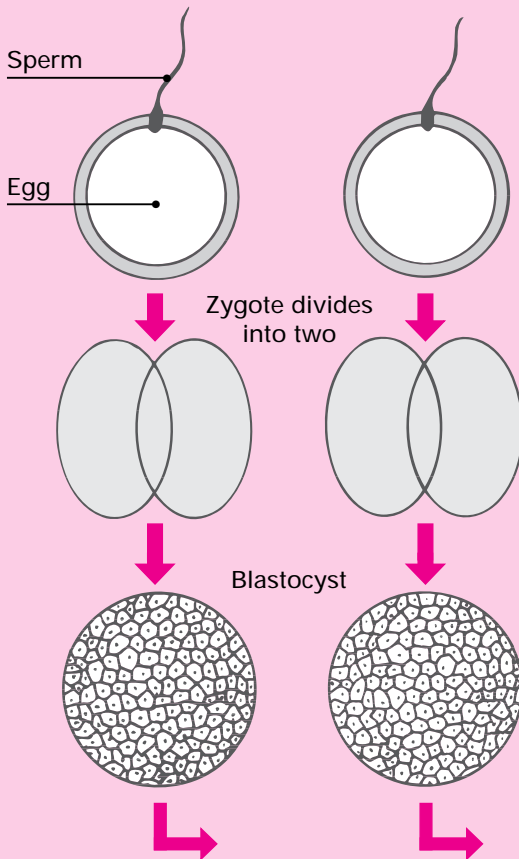
Identical twins

Identical twins develop when an egg (female sex cell) fertilized by a sperm (male sex cell) that form a zygote completely splits into two soon after fertilization. These twins are called monozygotic because they grow from a single cell. Two embryoblasts develop inside a single trophoblast. When the embryoblasts overlap they result in conjoined (formerly called Siamese) twins. The resulting two embryos have the same genetic (inherited) information and usually share the same placenta (source of nourishment).

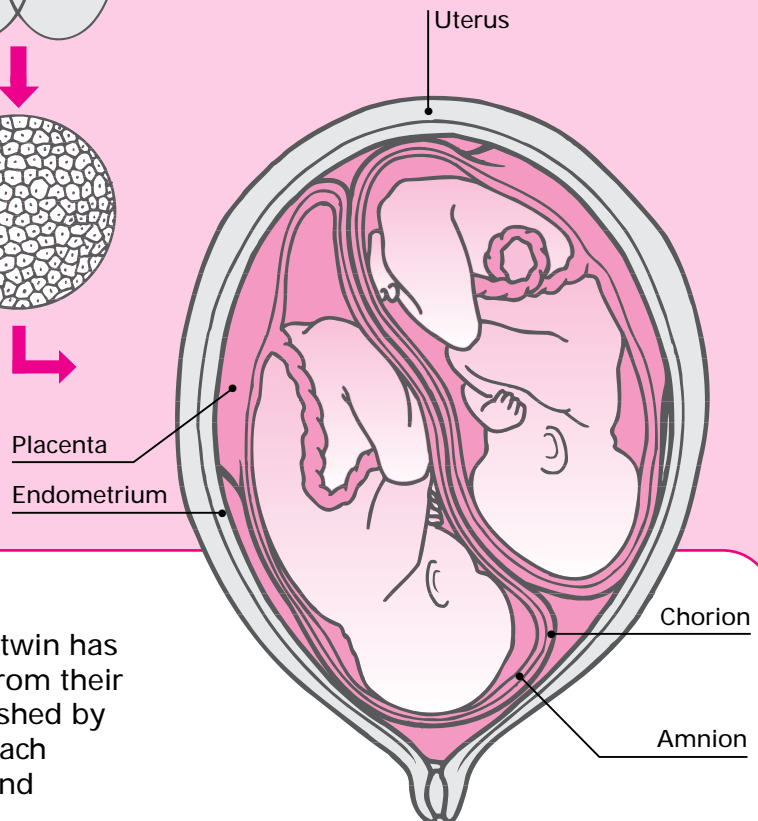


In the womb

Identical twins share a single placenta, although each has their own umbilical cord. The twins are surrounded by a single chorion membrane. However, each developing fetus has its own amnion membrane.

Dizygotic development**Nonidentical twins**

Nonidentical (or dizygotic—"two zygotes") twins develop when two eggs are fertilized by two different sperm. Therefore the twins each have a different set of genetic information. Although they are born at the same time, nonidentical twins are no more closely related to each other than normal siblings. Each egg divides as normal to produce a separate blastocyst containing a single embryo. Each embryo has its own placenta.

**In the womb**

Because each nonidentical twin has developed independently from their own zygote, they are nourished by their own placentas. Also each fetus has its own chorion and amnion membrane.


The three main stages of a woman's reproductive life—puberty, pregnancy, and menopause—are all associated with changes in hormone levels, physical characteristics, and behavior patterns. In pregnancy the hormonal changes cause the menstrual periods to stop, and they reprogram the body to provide for the development and growth of

the baby inside the uterus. The physical changes involve not only the mother's enlarging abdomen, but also modifications elsewhere. Some ways in which a pregnant woman can help to keep herself in good condition through all the changes associated with pregnancy and birth are discussed in the following pages.

Age and pregnancy

The age of the mother may affect several factors in a pregnancy and birth, especially in a first pregnancy.

- a** Mothers under age 20 run a higher risk of anemia, toxemia of pregnancy, and congenital abnormality of the baby, but labor is usually easier.
- b** Mothers aged 20 to 30 have the lowest rates of stillbirth and early infant death.
- c** Mothers aged 30 to 40 have longer labors, a greater chance of twins, heavier babies, and more complications of pregnancy and birth.
- d** Mothers over 40 have a high risk of Down syndrome babies and other complications, but have shorter labors.



Changes in pregnancy

The diagram on the right plots the sites of many of the physical changes and minor physical problems that may be encountered during a pregnancy.

- 1** Fainting.
- 2** Brittle hair.
- 3** Nasal congestion and nosebleeds, resulting from a rise in blood supply.
- 4** Increase in skin pigmentation, especially in dark-haired women.
- 5** Aggravation of dry or greasy skin problems.
- 6** Slight rise in basal body temperature.
- 7** Bleeding from swollen and tender gums.
- 8** Heartburn.
- 9** Shortness of breath.

10 Increase in size and weight of the breasts, and possible tenderness.

11 Raised blood pressure.

12 Changes in appetite. These may take the form of cravings, distaste for certain foods, or an increase or decrease in the amounts eaten.

13 Nausea and vomiting, especially in the morning during the early months of pregnancy.

14 Palpitations.

15 Postural changes as the body adapts to the extra load of pregnancy.

16 Backache caused by changes in the muscles and tendons of the back.

17 Clumsiness, caused by changes in the nerves and circulation and also by increased size and weight.

18 Tingling hands.

19 Brittle nails.

20 Congestion of the pelvis and abdomen caused by the increased blood supply.

21 Stretch marks: small red lines that develop over the abdomen during pregnancy and later fade to silvery marks.

22 Cessation of the menstrual periods.

23 Constipation.

24 Gas in the intestines.

25 Hemorrhoids.

26 Frequent urination, a result of the enlarging uterus pressing on the bladder.

27 Vaginal discharge.

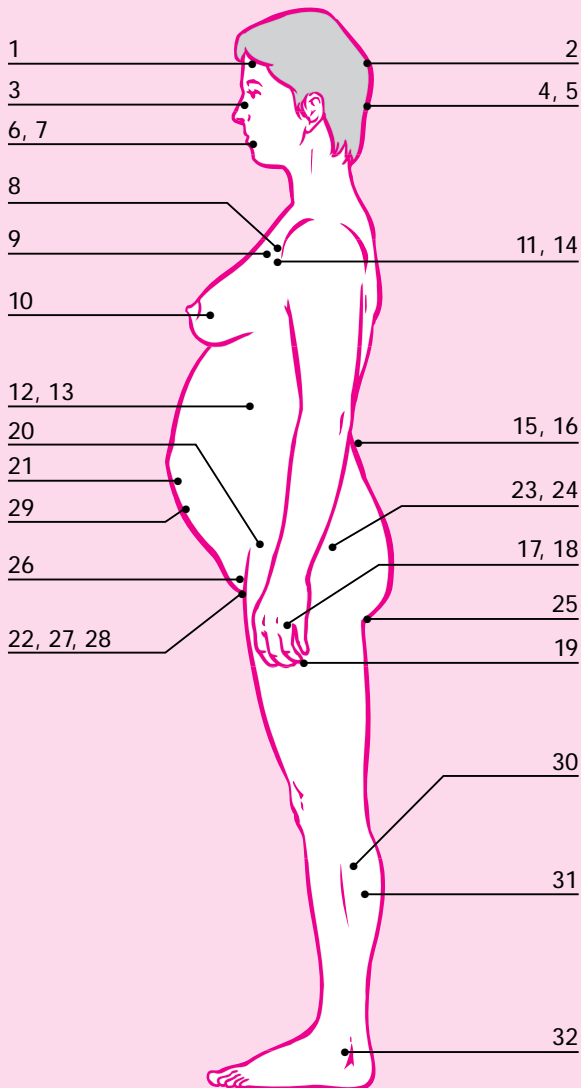
28 Darkening in color of the vagina, from pale pink to dark pink or violet.

29 Weight gain caused by the baby itself; the fluid around it in the uterus; fluid retained in the mother's tissues; the placenta; the increase in volume of the mother's blood; and some laying down of fat.

30 Cramps in the calves.

31 Varicose veins.

32 Swelling of the ankles and feet.



Prenatal care

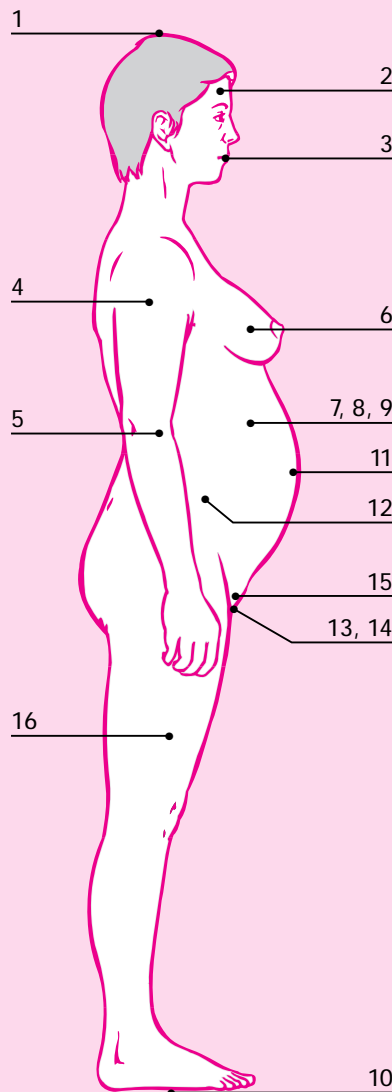
Prenatal facilities are designed to provide the best possible care for the pregnant mother and her baby. They provide frequent checks on the well-being of mother and baby, give advice on daily care and routines, and watch for any signs of conditions that may endanger the baby or complicate the birth. A detailed history of the present and previous pregnancies is taken, and close attention is paid to all of the following points:

1 Height. This is measured at the first prenatal visit. Body measurements provide clues as to whether the mother's physique will allow an easy birth.

2 Relaxation. The ability to relax fully aids labor, and so is usually taught during the prenatal period.

3 Diet. A good diet throughout pregnancy ensures that mother and baby are well nourished.

4 Blood pressure. This is a good monitor of the mother's circulation, and is taken at every prenatal visit.



5 Blood tests. These will be used to check for infection, anemia etc.

6 Breast care. The mother will be advised on how to keep her breasts in good condition during pregnancy and prepare them for breastfeeding.

7 Amniocentesis. A sample of the fluid around the baby may be taken to check for abnormal signs if this is thought necessary (for instance during an older woman's pregnancy). Amniocentesis occasionally causes some risk to the fetus.

8 Ultrasound. This method of checking the progress of the baby is used in many clinics, and involves bouncing sound waves off the fetus.

9 X-ray. This technique was once used to check the size and position of the baby, but is now avoided as much as possible and used only when complications occur that cannot be checked in any other way.

10 Weight. The mother's weight is checked to ensure that it is not rising too rapidly or slowly.

11 Abdomen. An external examination of the abdomen is made at the first prenatal appointment.

12 Pelvic examination. This is done to establish the presence of the pregnancy and to check for abnormalities in the

vagina or uterus.

13 Smear test. This is sometimes performed as an extra safety precaution.

14 Vaginal swab. The vaginal secretions are examined for any infection or abnormality.

15 Urine test. This is done regularly to test for diabetes or other irregularities.

16 Exercises. Prenatal advisors recommend suitable exercises for the pregnant mother.

Nausea and vomiting

Morning sickness affects many women in early pregnancy. Some may simply feel nauseous first thing in the morning, but others actually retch or vomit. Although this problem usually disappears by the third or fourth month, it is miserable while it lasts. But with a little care its effects can be minimized. Drinking a bland liquid such as milk or water during the night or immediately on waking will help to allay much of the nausea, and so will eating something bland such as dry toast, cookies, or an apple. Pregnant women prone to nausea should avoid all rich and fatty foods as much as possible.

Digestive problems

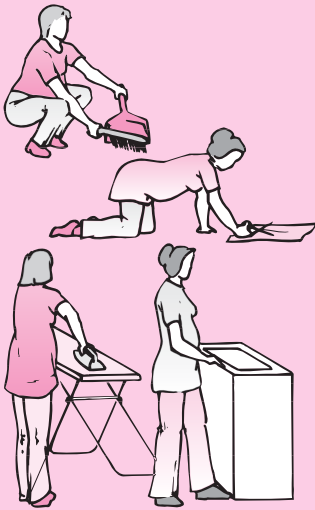Digestive problems are rife in pregnancy. One of the chief causes is pressure from the uterus, which presses the diaphragm upward and so exerts pressure on the stomach. This can cause heartburn and indigestion. Eating bland foods and avoiding strong spices and heavy meals may ease the problem. Constipation is also a frequent problem during pregnancy. It is caused by the slowing down of the digestive system and the relaxation of the muscle walls. It can be alleviated by drinking plenty of fluids and eating sufficient fiber, but strong laxatives should never be used.

Miscarriage

Miscarriage, or natural abortion, is the death of an embryo or fetus in the uterus or its expulsion before it is capable of sustaining life. As many as 20 percent of pregnancies may end in miscarriage, but many of these are very early and may be mistaken for a slightly overdue period. Most miscarriages take place in the first three months of pregnancy, but later cases may occur if there is a weakness of the cervix, or if the mother has used violent bowel laxatives which initiate contractions. If a miscarriage is suspected, the mother should go straight to bed and a doctor must be called.


Careful attention to posture, relaxation, and exercise will be invaluable to the expectant mother throughout her pregnancy and after the baby's birth. Muscles and tendons are prone to softening and sagging during pregnancy, and the mother's extra weight and increased size tend to aggravate the problem. Her posture alters as the pregnancy progresses, and she may experience aches

and pains in her back and legs as a result. On these pages we look at some of the ways in which the expectant mother can use her body as efficiently as possible during pregnancy. These hints will help her to avoid strain and unnecessary health problems, and encourage the developing fetus to move into the best position for birth. Keeping fit will help new mothers recover their figures after birth.



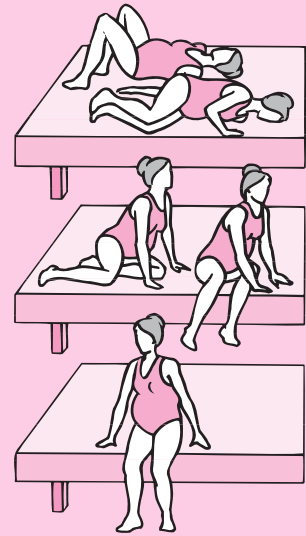
Daily activities

Because the back carries much of the burden of the extra weight during pregnancy, its muscles are susceptible to strain imposed by bending at the waist. The correct posture for various everyday activities are shown above. The back is kept as straight as possible and the strain is taken by the legs.



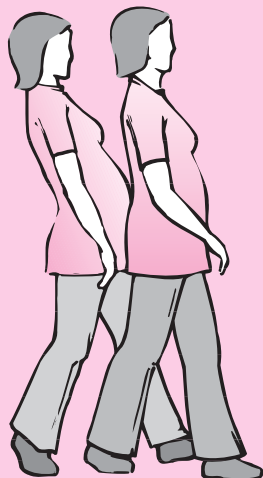
Lifting

Avoid lifting heavy objects as this can cause unnecessary strain on the back and abdomen. If lifting is unavoidable, try using the methods shown above. Squat right down with your knees apart and your spine straight and then straighten up slowly. Hold the load high in the arms.



Getting out of bed

As the abdomen grows it becomes increasingly difficult to rise from a lying position. The method shown above is safe, and can also be modified for getting up from the floor. Bend your knees up and roll over onto one side; your arms can be used to raise your trunk from the bed. Then swing your legs onto the floor.

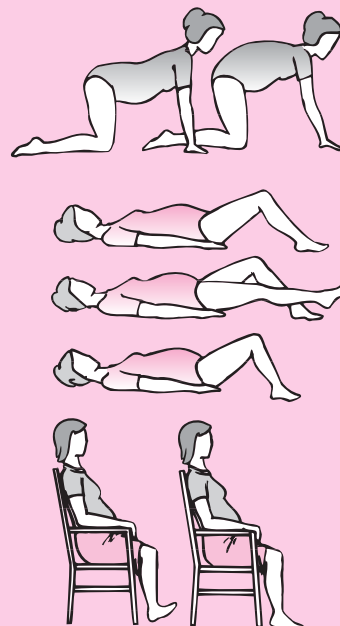


Posture

During pregnancy there is a great temptation to walk badly, with the pelvis tilted forward and the back hollowed (left). Wearing high-heeled shoes increases this tendency as they throw the trunk forward and leave the body off-balance. A hollowed back may be inevitable in the very late stages of pregnancy, when the abdomen is very large, but in the early and middle stages try to walk with the spine as straight as possible. The head should be erect, and the abdomen and chest supported by the trunk muscles (right). Wearing sensible shoes will help.

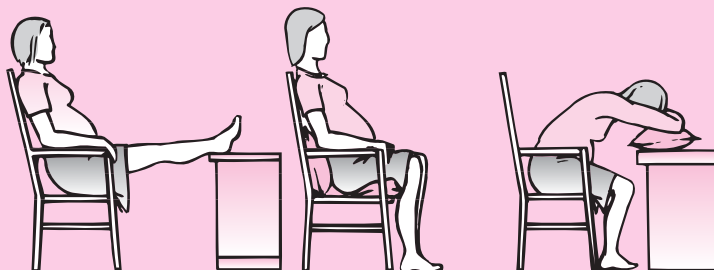
General exercises

These exercises will help to improve muscle tone and circulation. Kneel on all fours and arch the back to exercise the pelvic floor. Lie on your back with your knees bent and your feet flat on the ground. Slowly extend each leg. From the same position, tighten your buttocks and hold this position for a moment. Sit in a chair with your heels resting on the floor. Bend your feet upward and then point them down.



Relaxation

It is very valuable for pregnant women to spend some part of each day relaxing, especially in the later stages of pregnancy. Daily relaxation rests the mother's body, and also teaches her to relax; this ability will be very useful during the birth, when she needs to conserve energy between contractions. Raising the feet above the level of the head improves a sluggish circulation, and the mother should try to do this whenever she rests.



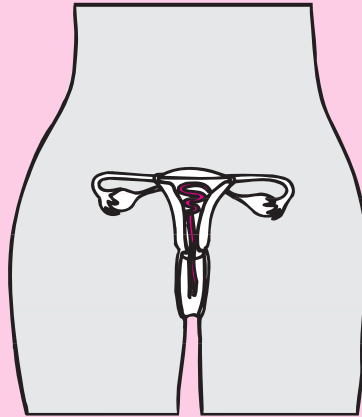
Methods of birth control have been practiced for centuries, but the search still continues for the safest and most reliable form of contraception. In the United States about 80 percent of all couples use some kind of contraceptive. Many women prefer the reliability of the contraceptive pill or the intrauterine device (IUD), but their side-effects and possible health risks have persuaded

some to return to using a diaphragm or other type of cap. The male forms of contraception, the condom and coitus interruptus, are still the most widely-practiced contraceptive methods. Male pills have been developed but have not become widely used. Hormone treatments, similar to the work of pills, may also be delivered by implants or patches stuck on the skin.

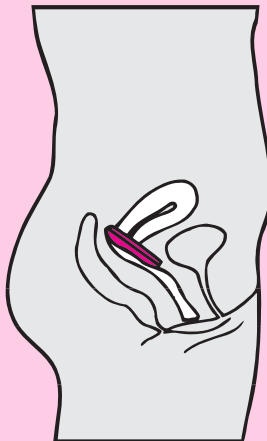
Contraceptive methods

Oral contraceptives or the birth control **pill**. Oral contraception is the most reliable method of non-surgical birth control. By altering the body's natural hormone balance, the pill interferes with the woman's normal monthly cycle of ovulation and menstruation and suppresses fertility. The pill is easy to use and does not interfere with lovemaking, but is not recommended for forgetful people.

Calendar method. This involves monitoring body temperature changes, cervical mucus consistency, and other body signs to pinpoint the fertile days. This is also known as the sympto-thermal method. All these methods are fairly unreliable and perhaps of more use to



Intrauterine device (IUD, loop, coil)



Diaphragm or cap

couples wanting to get pregnant than those trying not to.

Morning-after pill. This is available as an emergency measure. It prevents implantation of a fertilized egg into the uterine lining.

Injections of slow-releasing hormones.

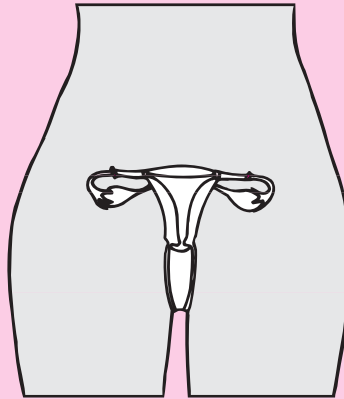
Implantation of slow releasing hormone capsules.

Intrauterine device (IUD) to prevent the fertilized egg from establishing a pregnancy. IUDs are nearly as efficient as the pill, are very convenient, and do not interfere with lovemaking. They need to be fitted by a doctor. Complications include perforation of the uterus, ectopic pregnancy (a pregnancy that occurs outside the uterus), miscarriage if pregnancy

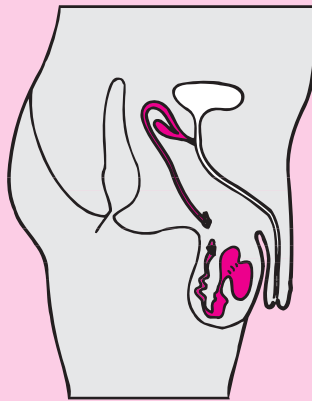
occurs, abdominal pain, backache (often a sign of infection), and heavy periods. Expulsion of the IUD is also a possible problem. Users should regularly check that the tail threads are in the vagina.

Female sterilization. This is achieved by cutting or blocking the fallopian tubes, which prevents the eggs' normal journey from the ovaries to the uterus and their possible fertilization by sperm. Sterilization is reliable but is rarely reversible.

Diaphragm or cap. Used together with spermicide, a diaphragm or cap provides a barrier to sperm. The cap must always be used with spermicide, which is smeared on before inserting into the upper



Female sterilization



Male sterilization (vasectomy)

vagina, and it should be left in position for at least six hours following intercourse.

Condom. A condom fits tightly over an erect penis so that ejaculated sperm is trapped inside. Condoms are cheap, have no side-effects, and give protection against sexually transmitted diseases.

Coitus interruptus or withdrawal. This involves removal of the penis before ejaculation. This is highly unreliable.

Male sterilization or vasectomy. This involves cutting and tying the vas deferentia. The man continues to ejaculate but the semen no longer includes sperm.

Choice of contraceptive

The choice of contraceptive will be influenced by individual needs. Teenagers or young adults at the start of sexual activity often use withdrawal or condoms. Once sexual activity is established many young women use the pill, but concern about the side-effects of pill hormones may persuade others

to choose one of the IUDs developed for women who have not had children. Between children some women continue using the pill or an IUD; others change to the slightly less effective diaphragm. Once the family is complete, some couples opt for sterilization of either the man or the woman.

The inability to conceive can be a source of great unhappiness and anxiety for couples. As a general guideline, if a couple who want children have been having sex regularly without contraception for more than a year and the woman has not become pregnant, they should seek medical advice. There may be a simple solution to the problem. For example, by combining knowledge about the likely time of a woman's ovulation with

information about the life span of sperm inside a woman, it becomes possible to predict those times of the month when she is most likely to conceive. Some couples can increase the likelihood of conception by using a different intercourse position.

Other causes of failure to become pregnant may be due to stress, physical problems, or infections. The most common causes are highlighted here and on pages 90–91.

Female physical problems

As in men there may be hormone disorders and defects of the central nervous system. Other problem sites are shown on the diagram (right).

1 Cervix: infection, injury, or the presence of fibrous growths (endometriosis) cause pain.

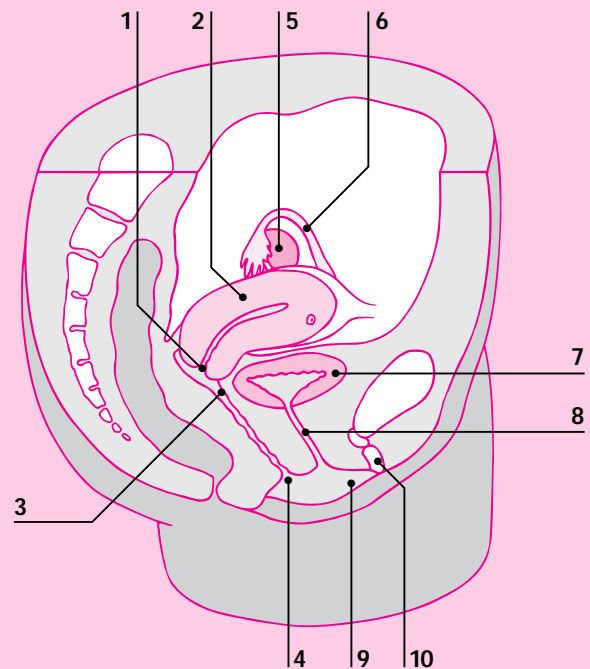
2 Uterus: there may be pain; fertility may be affected if the uterus is tilted, divided, or double.

3 Vagina: causes of pain on intercourse include infection, lack of lubrication, slackness or tightness of the vaginal walls, sensitivity to rubber devices, and vaginismus.

4 Vaginal outlet: labia fused over the outlet prevent intercourse; pain may result from a very rigid hymen, from atrophy due to aging, or from injury associated with first intercourse, IUD strings, rape, abortion, or childbirth.

5 Ovaries: ovulatory problems are a cause of infertility; pain on intercourse may be due to inflammation, displacement or ovarian cysts.

6 Fallopian tubes: infection may cause pain on intercourse; blockage of the tubes is a common cause of infertility.



7 Bladder: infection is a cause of painful intercourse.

8 Urethra: infection is a cause of painful intercourse.

9 Vulva: atrophy in old age may make intercourse painful.

10 Clitoris: smegma, infection, and injury are causes of pain during intercourse.

Male physical problems

The sites of some possible problems involving the male sex organs are located on the drawing (below).

1 Seminal vesicles: infection causes pain on intercourse; the production of too much or too little seminal fluid are causes of infertility.

2 Prostate gland: infection, over-enlargement, cancer and, in older men, spasmodic contractions are causes of pain during intercourse.

3 Compressor muscles: failure of these muscles to relax at ejaculation causes seminal fluid to be discharged into the bladder instead of being discharged through the urethra. This problem—termed retrograde ejaculation—may result from prostate surgery or an accident.

4 Bladder: infection causes pain on intercourse.

5 Urethra: adhesions following gonorrheal infection cause pain on intercourse.

6 Testes: failure of the testes to descend before puberty causes infertility, as does inadequate production of sperm; painful intercourse can result from unrelieved congestion of the testes following prolonged erection without ejaculation.

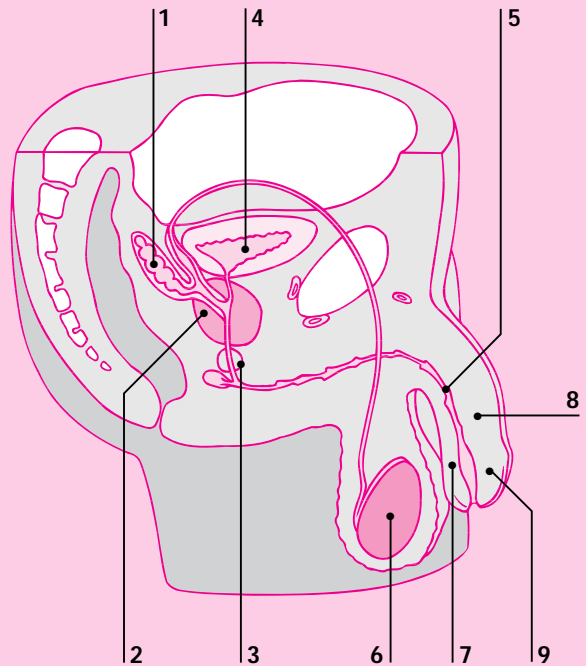
7 Blood vessels: hardening of blood vessels leading to the erectile tissue of the penis means that older men take longer to obtain an erection.

8 Shaft of the penis: pain on intercourse may be the result of a badly performed circumcision, or may be caused by Peyronie's disease (in which the penis on erection is painfully bowed up or

sideways) or by chordee (in which the erect penis is painfully bowed down).

9 Glans: pain in the glans during intercourse may be caused by a build-up of smegma and bacteria, by adhesion of the glans to an overtight foreskin, by inflammation of the urethra or prostate, or by contact with germs, acid, or a partner's contraceptive cream.

Other physical problems that interfere with male sexual performance include disorders of hormone production in the pituitary or the testes, and defects of the central nervous system.



Although modern medicine can cure most sexually transmitted diseases (STDs), annual numbers of cases remain alarmingly high. In the U.S. there are more than 360,000 new cases of gonorrhea reported each year, and more than three million people may be infected with chlamydia annually. Meanwhile new cases of AIDS in the U.S. exceed 42,000

each year and there may be more than 45 million Americans infected with the genital herpes virus. Hindrances in the eradication of sexual diseases include increased promiscuity, global travel by sexually active individuals if combined with a failure to use condoms, and the appearance of new strains of disease that resist drugs and have symptom-free carriers.

Symptoms and treatments

- **Candidiasis** (thrush): women have an itchy, swollen vulva, curdy vaginal discharge, and pain during coitus and urination; men may have a red, spotty penis and inner foreskin, with a burning sensation. Treatment is with fungicide.
- **Chlamydia**: this is a bacterial infection that causes discharge from the penis and pain on urination; women may have increased vaginal discharge, pain on urination, and abdominal pain. It is treated with antibiotics. If left untreated, it can cause infertility.
- **Crab lice**: these produce itching in areas covered by pubic or other body hair. Special lotions cure the problem.
- **Genital herpes**: four to five days after infection itchy blisters appear on the genitals and then burst to produce ulcers. All symptoms go away in two weeks but milder attacks may recur. As yet there is no cure.
- **Genital warts**: appearing one to six months after infection, these form a tiny "cauliflower" around genitals or anus. Caustic substances, freezing, or cauterization remove them.
- **Gonorrhea**: first symptoms in men, usually 210 days after infection, are a watery (later thicker, greenish-yellow) penile discharge, frequent urge to urinate and pain on urination; only 20 percent of females infected show early symptoms—a red, raw vulva, white, yellow or green vaginal discharge, and perhaps pain on urination. Treatment is with antibiotics.
- **HIV** (human immunodeficiency virus): The cause of AIDS (acquired immunodeficiency syndrome), a fatal condition that destroys the body's immune system. There is no cure.
- **Scabies**: small itchy lumps and thin dark lines caused by mites.
- **Syphilis**: in the first month a small painless sore appears on the part directly infected. About two months after infection there is a skin rash and patchy hair loss, lasting up to a year. The symptoms then disappear, but may return up to 30 years after infection, when organs are damaged.
- **Trichomoniasis**: symptoms in women are a foul-smelling, greenish, foamy vaginal discharge, and inflammation of the vagina and vulva; men usually have no symptoms but can transmit the disease. Treatment is by drugs.

Disease prevention

The following precautions reduce the risk of genital infection:

- Wash genitals daily.
- Change underwear daily.
- Avoid underwear made of nylon as this tends to harbor germs.
- Avoid contact with chemicals that irritate the genitals.
- Wipe the bottom from front to back at toilet visits to avoid transferring germs from the anus to the urethra.
- Keep sexual contact to one infection-free partner.
- Leave six weeks between sexual partners in order to reduce your risk of unknowingly incubating a sexual infection that might be passed on.
- Look for discharge or sores on a new partner's genitals.
- Use a condom during intercourse. Contraceptive creams and foams also help to block some infections.
- Wash genitals before and after intercourse.
- Urinate after intercourse.

Early treatment of sexually transmitted disease is essential. The following measures should prevent serious complications developing:

- If you suspect you have a sexually transmitted disease, have a confidential medical examination as soon as possible.
- Advise your partner to seek medical aid.
- Avoid sexual contact.
- Follow the treatment prescribed.
- Have a repeat test to make sure you are cured.

The aging female

Although menopause ends a woman's reproductive potential, any loss of sex drive at this time is usually temporary. In fact women usually find that their cycle of sexual response is less affected by age than is that of their partner. The postmenopausal changes listed here may make intercourse uncomfortable for some women, but hormone pills and local applications are available to alleviate their effects.

1 The vulva atrophies. **2** The vaginal walls get thinner; reduced lubrication may lead to vaginal irritation. **3** Ovaries shrink. **4** The uterus shrinks; uterine muscle becomes fibrous but is probably still contractile.

The aging male

Most older men remain physically capable of sexual activity. Impotence does increase with age, but in most cases this is due to psychological causes. By about age 60, however, aging will have brought the following physical changes. **1** Hardening of blood vessels affects erectile capacity. **2** Scrotal tissue sags and wrinkles. **3** Testes shrink, lose firmness, and are less elevated on arousal. **4** Thickening and degeneration of the seminiferous tubules inhibit sperm production. **5** The prostate gland may be enlarged and its contractions during orgasm are weaker. **6** Seminal fluid is thinner and reduced in quantity.

Most babies are born after a gestation period of between 38 and 42 weeks. During a natural birth the baby travels from the uterus through the vagina, or birth canal, into the outside world. This process is called labor. Labor is very painful and can last a few hours or even two or three days.

Labor facts

- Most babies are born head first.
- The head is the largest part of the newborn baby.

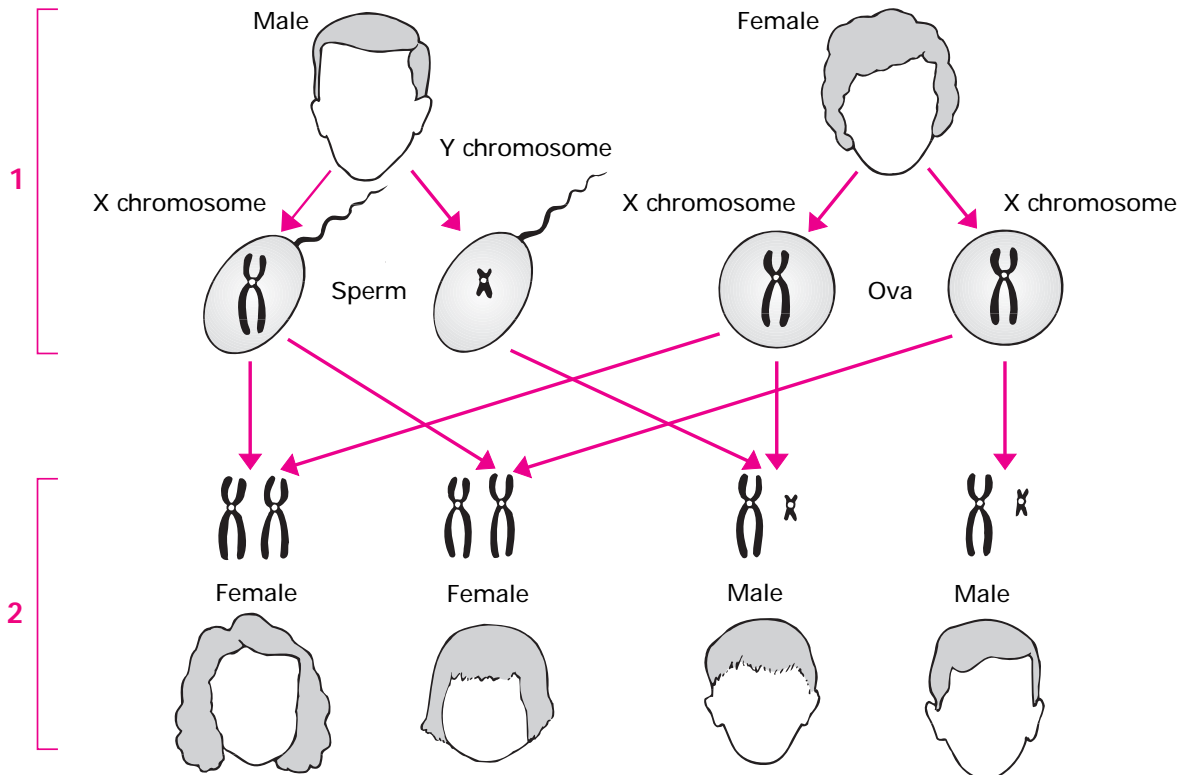
How sex is determined

Female cells contain two X chromosomes. Male cells have an X and a Y chromosome.

1 A male produces sperm which contains, with equal probability, either an X or a Y chromosome. A female

produces ova which always carry an X chromosome.

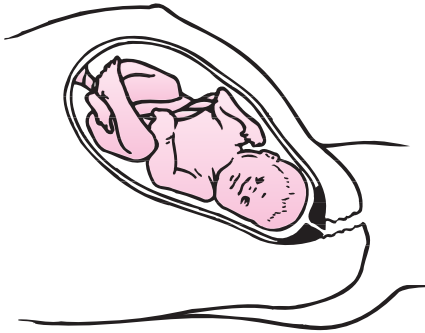
2 When a sperm and ovum fuse at fertilization, the sex of the resulting child is determined by the type of sex chromosome passed on in the sperm.



First stage of labor

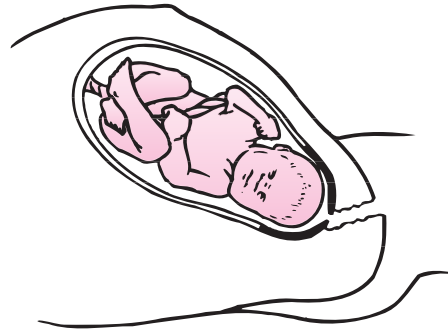Most labors follow a similar general pattern. In the first stage, the cervix of the uterus “effaces” and dilates (widens) to allow the fetus to pass without damaging it. The process takes

about eight hours for women having their first baby and about four to five hours for subsequent babies. Contractions become stronger and more frequent through this stage.



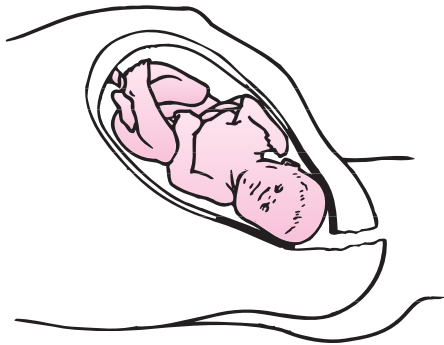
1 Partial effacement

Contraction and retraction of the uterus shorten the neck of the cervix. Contractions occur every ten minutes.



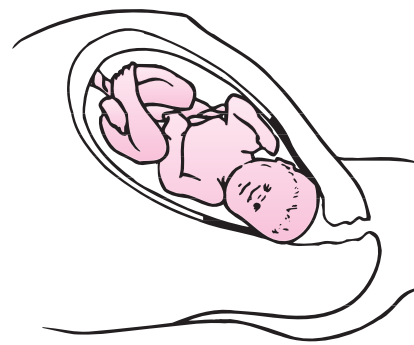2 Full effacement

Contractions every five minutes. Pain is now felt abdominally.



3 Partial dilation

Continued contraction and retraction. Contractions every two to five minutes. Amniotic sac ruptures (if not earlier).



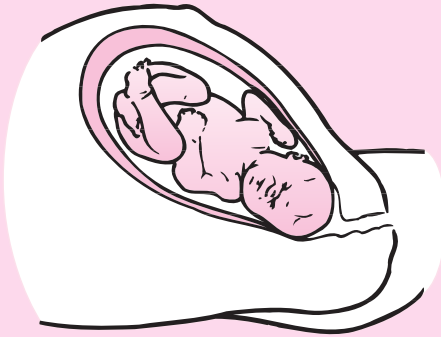
4 Full dilation

The fetus is able to pass through the cervix without damaging it. Contractions every two to three minutes.

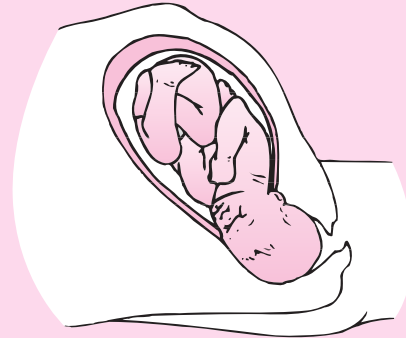
Second stage of labor

Transition to the second stage is characterized by feelings of pressure in the lower pelvis, backache, and often nausea, and leg cramps. There is a strong desire to bear down, and it is

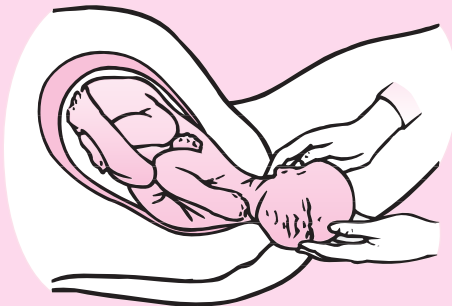
safe to do so once the cervix is fully dilated. The baby is now pushed out of the uterus and down the vagina, and will be delivered in anything from five to 40 minutes.



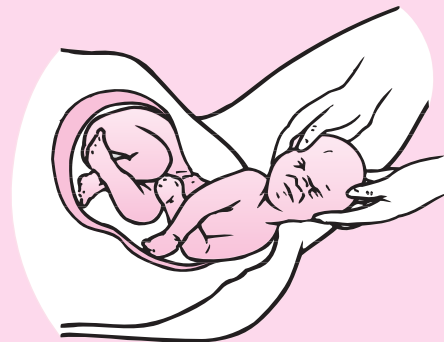1 Full dilation marks the beginning of delivery. The woman “bears down” to help expel the baby.



2 The baby's head passes through the cervix and rotates to squeeze beneath the pubic arch.



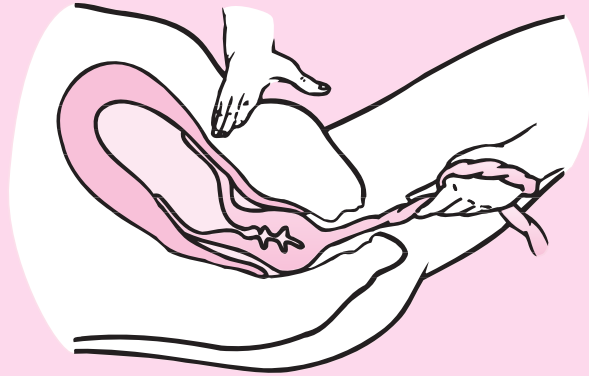3 The head is born, and rotates back to its previous position. The baby's shoulders rotate to pass through the pelvis.



4 The right shoulder, then the left, is born. The baby starts breathing. Mucus is cleaned from its face and airways. The umbilical cord is clamped.

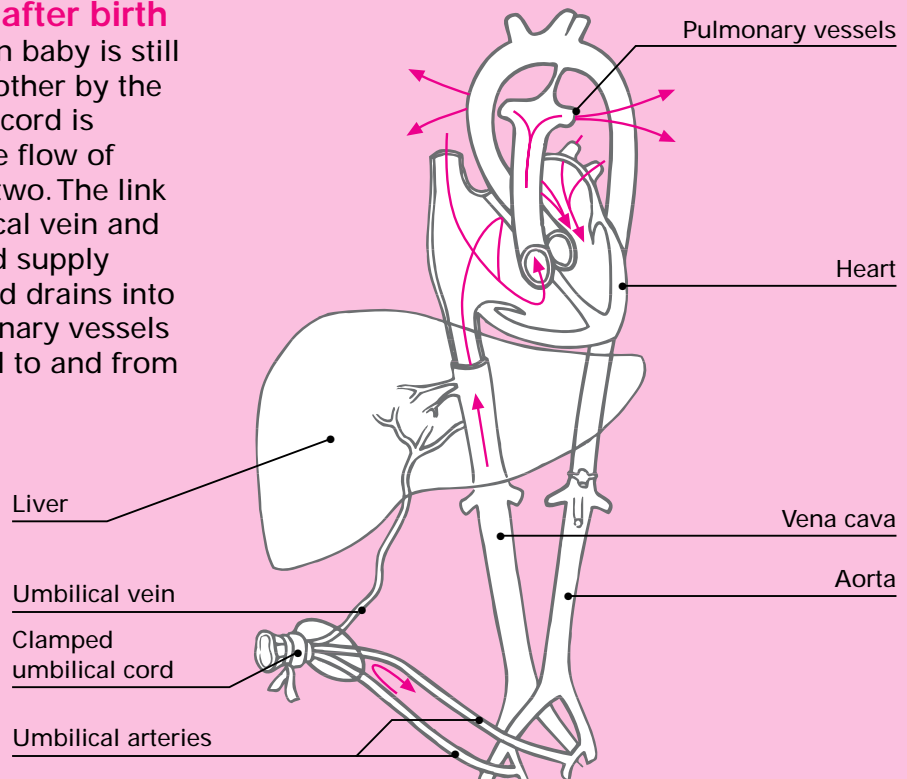
Third stage of labor

This final stage involves the delivery of the placenta. Hormones cause this to become detached from the endometrium and it is generally delivered within 30 minutes of the baby. Often the mother is given a hormone injection to hasten this process. If the placenta does not detach, it must be removed surgically.



Fetal circulation after birth

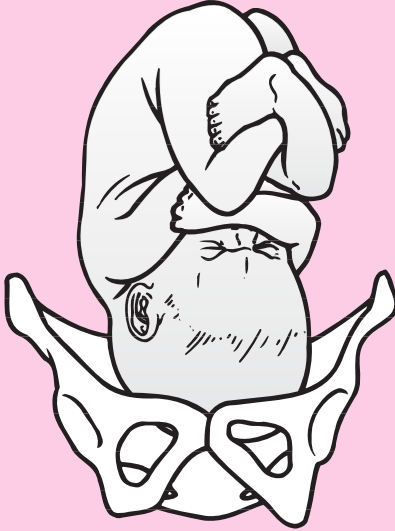At birth the newborn baby is still connected to the mother by the umbilical cord. This cord is clamped to stem the flow of blood between the two. The link between the umbilical vein and the newborn's blood supply breaks and the blood drains into the liver. The pulmonary vessels begin to carry blood to and from the lungs.



Fetal positions

Most babies are head down just before birth. The next most common position is breech. One percent of babies are

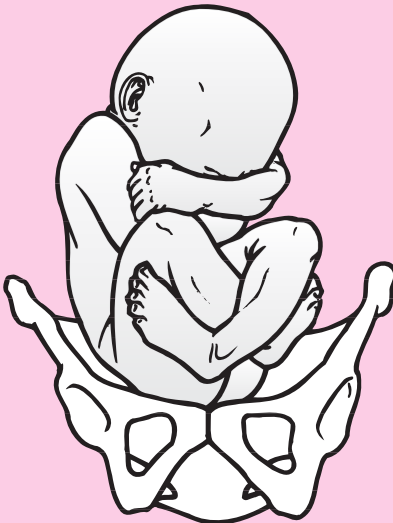
transverse, while half as many are face down. Midwives use their hands to feel how the baby is positioned before birth.



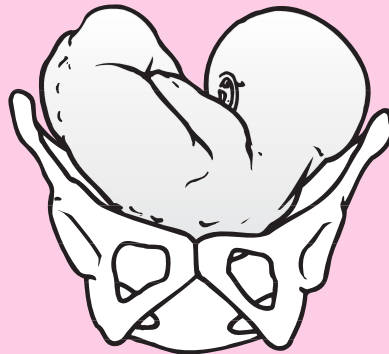Vertex: head down



Vertex: face down



Breech

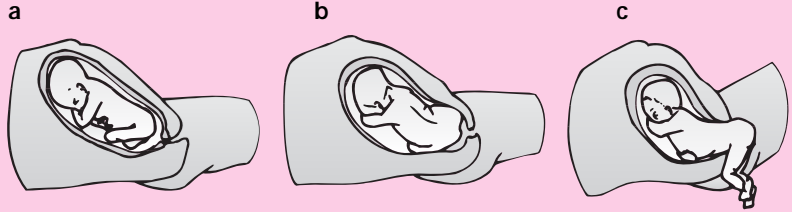


Transverse

Breech birth

Normally the fetus moves from breech to vertex position between the 24th and 28th week. However, some fail to do so, and 3.5 percent of fetuses remain breech (a) until birth. A normal-sized baby in breech position will usually be delivered with no problems for mother or child. But a small pelvis or a large fetal head may lead to

Stages in a breech delivery



difficulty. The duration of delivery can be critical. A long delivery may result in oxygen starvation if the head squeezes the umbilical cord. During a breech delivery the bottom

passes through the cervix and rotates (b) to squeeze under the pubic arch. The bottom and legs are born first (c), then the shoulders, then the head.

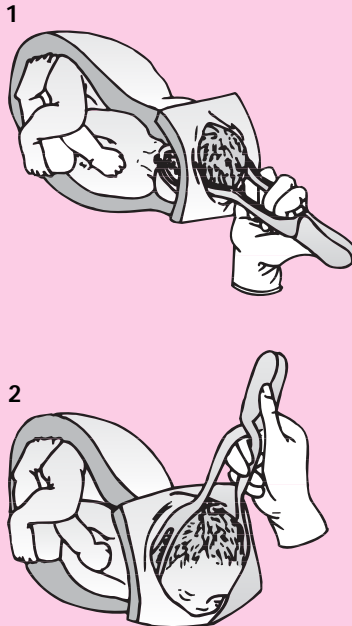
Forceps delivery

Forceps are sometimes used in the second stage of labor to aid delivery because of:

- slow or no fetal progress;
- maternal distress exacerbated by the effort required; or
- fetal distress.

Forceps have two curved blades that fit around the fetal head. One blade is inserted into the uterus and located in position around the head. The other blade is inserted, and locked into the first blade (1). Gentle traction then draws the fetus through the vagina (2).

Stages in a forceps delivery



Cesarean birth

Cesarean section is an operation carried out on a pregnant woman to deliver her baby if this is not possible through the vagina. Reasons for this include:

- fetal distress;
- a placenta lying over the cervical opening;
- very small pelvis;
- obstructive fibroids;
- transverse fetal position; or
- previous uterine injury.

A general anesthetic is given. A cut is made below the navel into the abdomen and uterus, and the baby is delivered through this.

During the first week of life, a baby is not capable of any significant voluntary or controlled movements. However, it does exhibit a variety of reflexes—involuntary or automatic reactions to particular changes in its surroundings or to touch. These “primitive” reflexes are thought to be a legacy of humanity’s earliest ancestors, when such actions were vital for an infant’s survival.

Development of a baby’s muscle control starts from the head and moves gradually downward to the arms, legs, and feet. Within a week, from a cradled position a baby can move its head up for a second or two, and by a month it can balance its head for several

seconds, provided the rest of its body is supported. By this time, too, it can stretch out its limbs and fan out its fingers and toes.

Vital statistics

Newborn babies vary greatly in size and weight but on average measure:

- 19.9 inches (50.5 cm) in length
- 7.5 pounds (3.4 kg) in weight and, after an initial loss of weight, by three months measure:
 - 23.6 inches (59.8 cm) in length
 - weigh 12.5 pounds (5.7 kg)

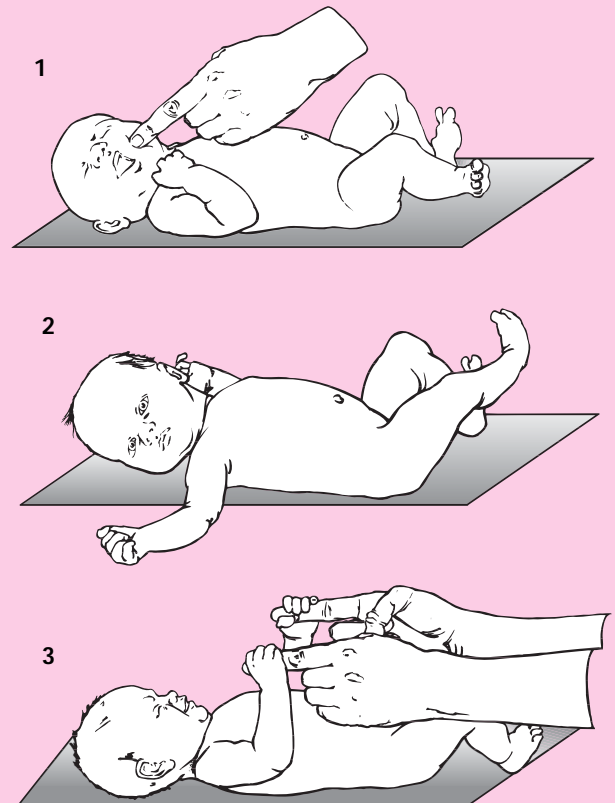
Newborn reflexes

A newborn’s reflexes last for several days then fade. The physical abilities are re-learned months later.

1 Rooting reflex If one side of a baby’s cheek or mouth is gently touched, the baby will turn its head in the direction of the touch. This ensures that the baby will seek out its mother’s nipple when its cheek is brushed by her breast. Along with the sucking and swallowing reflexes, the rooting reflex is essential for successful feeding of the newborn.

2 Neck reflex When on its back and not crying, a newborn baby turns its head to one side, the arm on that side extends as shown, and the opposite leg bends at the knee.

3 Grasp reflex If an object is placed in the baby’s hand, it clenches its fist. If a finger is slipped into each of its palms, the baby will grasp them so tightly that it can support its own weight.



Growth pattern

Babies do not all grow and develop at the same rate. Growth depends on a mixture of diet, health, metabolism, functioning of glands, and genetic factors. Also, babies that are born prematurely have a great deal of catching up to do. For example, a baby born after a pregnancy of only eight months will still be a month behind a full-term baby six months later. However, a baby's weight will have roughly doubled after six months, and by a year its height will have increased from about 20 inches (50 cm) to 30 inches (75 cm). On average, at birth boys are longer and taller than girls and stay ahead until the age of about four or five years.

Proportions

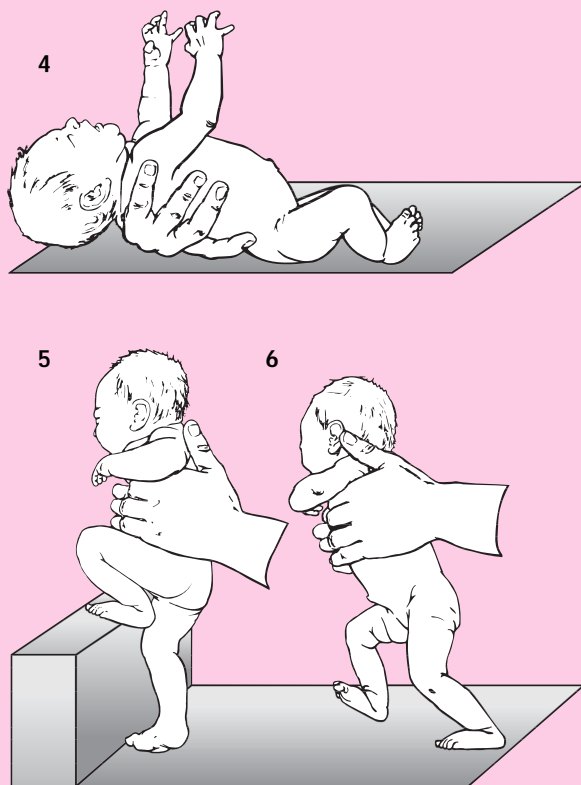
Compared to an adult, a newborn baby's head is relatively large and its legs are comparatively short. At first, the legs and arms grow quickly. Then the whole body elongates. By about two years, a child reaches half its adult height. It is not until the age of about six or seven that a child is properly proportioned.

4 Moro reflex This reflex is seen when the baby is startled. The arms and legs are outstretched and then drawn inward with the fingers curled as if ready to clutch at something. A baby's Moro reflex is tested to check muscle tone—if the limbs respond asymmetrically, there may be an injury or weakness of a particular limb.

5 Stepping reflex If the front of the baby's legs are brought into contact with the edge of a table, the baby will raise its legs and take a step up onto the table.

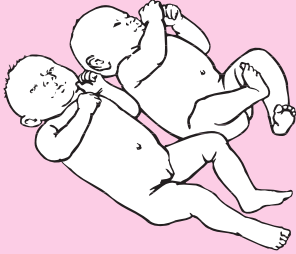
6 Walking reflex If a baby is held upright with the soles of its feet on a flat surface, and is then moved forward slowly, it will respond with walking steps.

Other reflexes include blinking in response to a stimulus such as touching the baby on the bridge of the nose and, when the baby is lying down, drawing one leg up toward its body when the sole of the foot on the other leg is stroked.



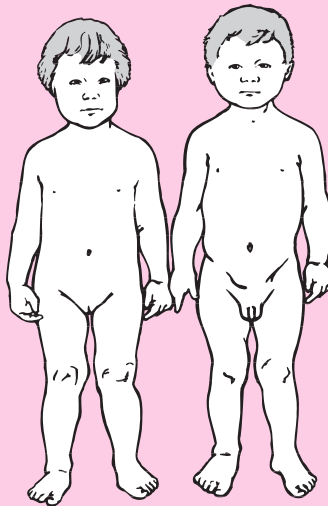
Six months old

At this age, babies still cannot sit or stand unaided. They can use their hands well and continually handle and bang objects. They are now learning the meaning of people's expressions and gestures, and react with two-syllabled sounds.



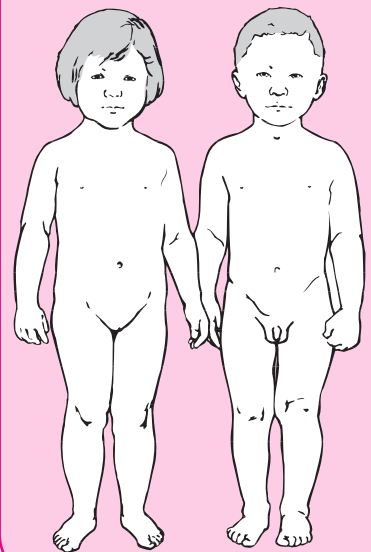
18 months old

Having learned to stand, walk, and run, young children—now often called infants—are immensely active. But they cannot easily coordinate their hands and feet. They are dexterous, but lack wrist control. Their use of words is very limited. Self-willed, they take but cannot give and, unable to see other people like themselves, they cannot share in their play.



Two years old

Young children are now referred to as toddlers—they are surer on their feet, and love to romp, chase, and be pursued, but sometimes fall over. Rising and bending down are still done somewhat awkwardly. Hand movements are now more varied and assured. They love exploring objects, testing everything by taste and touch. They can speak many words clearly.



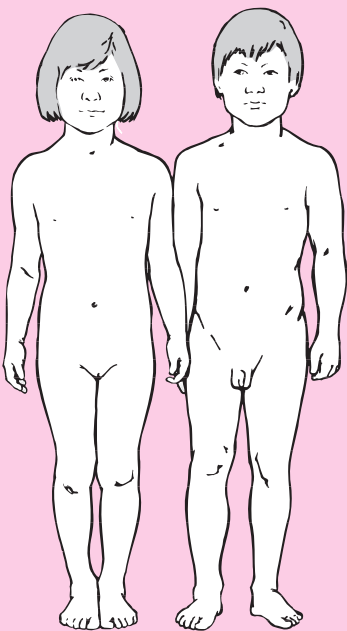
One year old

Agile crawling has given mobility, and babies can now nearly stand and walk unaided. They love to imitate actions and start to speak.

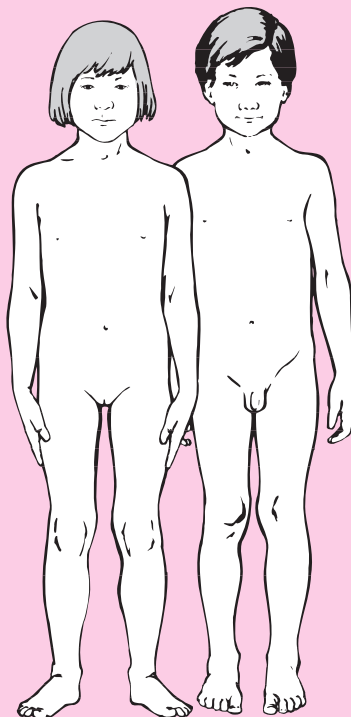


Four years old

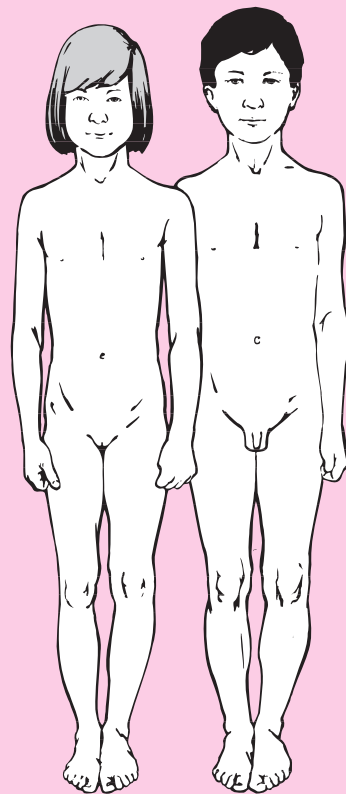
Well-controlled muscles help youngsters energetically jump, hop, skip, climb, and ride a tricycle. Their hand-eye coordination is well developed, allowing them, for example, to draw, lace their shoes, and cut with scissors. They talk incessantly, trying out new words and using adult terms out of context. Their mental life is blossoming.

**Six years old**

Lively, expansive, and eager, six-year-olds have an insatiable appetite for fresh experiences. Many youngsters are now demanding, stubborn, and unruly. At school, they take their first steps in reading, writing, and using numbers. But what they learn must still be firmly based on things they can see and do. They cannot reason in an adult abstract way.

**Eight years old**

Physically, children now have adult body proportions and believe no task or action is beyond their capabilities. Their vocabulary is enriched by many adjectives because they now appreciate the qualities of objects and actions. They have a new, maturing independence and start to show what sort of people they will become.



Adipose tissue Connective tissue containing numerous fat cells.

Adrenal glands (*or* Suprarenal glands) Endocrine glands located on each kidney. The cortex and medulla produce a range of hormones.

Afferent Directed toward a central organ or part of the body.

Alimentary canal (*or* Gastrointestinal tract *or* Gut) The digestive tract: a tube starting at the mouth and ending at the anus.

Anus The lower end of the rectum, forming the outlet of the alimentary canal.

Aorta The largest artery, arising from the left ventricle of the heart.

Appendix (*or* Vermiform appendix) A short, wormlike tube opening into the cecum but closed at the other end. It contains lymphoid tissue, which is involved in immunity.

Arteriole A small artery supplying blood from a main artery to a capillary.

Artery A blood vessel transporting blood from the heart to elsewhere in the body.

Atrioventricular valve (*or* AV valve) A valve between a ventricle and an atrium. The right atrioventricular valve (*or* tricuspid valve) has three cusps. The left atrioventricular

valve (mitral valve or bicuspid valve) has two cusps.

Auditory Relating to hearing.

Axillary Relating to the armpit.

Backbone See **Vertebral column**.

Basal ganglia Paired structures deep in the forebrain: they help coordinate and control willed muscle movements.

Basophil A type of white blood cell that is readily stained by basic dyes.

Biceps A muscle with two heads: biceps brachii in the upper arm and biceps femoris in the thigh.

Bile ducts Tiny tubes that carry bile (a liver secretion) from the liver to the duodenum.

Bladder A sac, especially the muscular bag inside the pelvis where urine collects before being expelled from the body.

Blood A sticky red fluid consisting of colorless plasma, red blood cells (Erythrocytes), white blood cells (Leukocytes), and platelets (thrombocytes).

Blood pressure The pressure of blood against blood-vessel walls, especially artery walls.

Bone The hard, dense connective tissue that forms the skeleton's components.

Bone marrow Soft red and yellow substances that fill cavities in bone.

Bowel See **Large intestine**.

Brain The body's chief control center, consisting of billions of interconnected nerve cells.

Brainstem A stalklike part of the brain, between the cerebrum and spinal cord. It contains the midbrain, pons, and medulla oblongata.

Breast A female breast consists mainly of a mammary (milk-secreting) gland embedded in fatty tissue.

Breastbone See **Sternum**.

Bronchiole A small subdivision of a bronchus, ending in tiny air sacs called alveoli.

Bronchus The main tubes branching from the lower end of the trachea and forming the main airways to and from the lungs (plural: bronchi).

Capillary The tiniest type of blood vessel, connecting an arteriole and a venule.

Cardiac Relating to the heart.

Cardiovascular Relating to the heart and blood circulatory system.

Cartilage Gristle: dense, white connective tissue cushioning bones.

Cecum The first part of the large intestine, forming a blind pouch.

Cell The basic unit of the body, usually comprising an outer membrane, cytoplasm, a nucleus, and organelles.

Central nervous system

(CNS) The brain and spinal cord.

Cerebellum The largest part of the hindbrain. It helps coordinate muscular movements.

Cerebral cortex The cerebrum's thin outer layer of gray matter.

Cerebral hemisphere Either of the two halves of the cerebrum.

Cerebrospinal fluid A clear fluid filling the brain's ventricles and surrounding the brain and spinal cord to protect them from injury.

Cerebrum The upper, major part of the brain, comprising cerebral hemispheres and diencephalon.

Cervix A neck, especially the neck of the uterus (womb) where it opens into the vagina.

Clavicle Either of the two collarbones.

Clitoris An erectile, pea-sized organ above the opening of the vagina; it is highly sensitive and is involved in female sexual response.

CNS See **Central nervous system**.

Coccyx Four fused vertebrae forming the "tail" of the backbone.

Collagen A fibrous protein that is a major constituent of connective tissue.

Colon The part of the large intestine between the cecum and rectum.

Connective tissue Tissue that supports, binds, or separates more specialized body tissues or acts as packing.

Corium See **Dermis**.

Cornea The transparent circular area at the front of the eye, which acts as a lens.

Coronary arteries Supply the heart muscle.

Corpuscles A term often used for red and white blood cells.

Cortex The outer layer of the brain.

Cranial nerves Twelve pairs of nerves linking the underside of the brain with parts of the head, neck, and thorax.

Cranium The part of the skull that contains the brain.

Cutaneous Relating to the skin.

Cuticle See **Epidermis**.

Deoxyribonucleic acid (DNA) A nucleic acid in the cell's chromosomes containing the cell's coded genetic instructions.

Dermis (*or* **Corium**) The layer of skin below the epidermis, containing nerves, blood vessels, glands, and hair follicles.

Diaphragm A muscular sheet used in breathing. It separates the thorax (chest) and abdomen (belly).

Digestion The chemical and mechanical breakdown of foods into substances that can be absorbed by the body.

DNA See **Deoxyribonucleic acid**.

Duodenum The upper part of the small intestine, where most chemical digestion takes place.

Ejaculation The discharging of semen from the penis.

Endocardium The membrane that lines the heart and the heart valves.

Endothelium The cell layer that lines the inside of the heart, blood vessels, and lymph vessels.

Enzymes Biological catalysts: proteins that speed up chemical reactions without undergoing change themselves.

Epidermis (*or* **Cuticle**) The skin's outer layer.

Epiglottis A cartilage flap behind the tongue that is closed during swallowing to stop food from entering the larynx.

Epiphysis See **Pineal gland**.

Epithelium The cell layer covering the body, and lining the alimentary canal and respiratory and urinary tracts.

Erythrocytes Red blood cells.

Esophagus (*or* **Gullet**) The muscular tube through which food travels between the pharynx and the stomach.

Fallopian tubes (or Uterine tubes or Oviducts) The tubes through which ova (eggs) travel from the ovaries to the uterus.

Femur The thigh bone: the long bone between the hip and the knee.

Follicle A small secreting cavity or sac. Ova (egg cells) develop in follicles in the female ovaries.

Forebrain The front part of the brain comprising diencephalon and telencephalon.

Gallbladder A pear-shaped bag where bile is stored, below the liver.

Gametes Sex cells: sperm in males; ova in females.

Gastric Of the stomach.

Gastrointestinal tract See **Alimentary canal**.

Genes Basic biological hereditary units, consisting of DNA, located on chromosomes.

Genitalia Sex organs.

Gland A structure that synthesizes and secretes a fluid.

Gonads Primary reproductive organs: the ovaries and testes.

Granulocytes White blood cells with cytoplasm that contains granules: basophils, eosinophils, and monocytes.

Gray matter The darker tissue of the brain and spinal cord mainly consisting of neurons' cell bodies and dendrites.

Gullet See **Esophagus**.

Gut See **Alimentary canal**.

Heart The hollow, muscular, fist-sized organ that pumps blood around the body.

Hemoglobin The iron-rich, oxygen-transporting pigment in red blood cells that gives them their color.

Hepatic Relating to the liver.

Hepatic portal vein See **Portal vein**.

Hindbrain Brain structures below the midbrain, comprising the pons, medulla oblongata, and cerebellum.

Hormones Chemical substances released into the blood by endocrine glands to influence organs or tissues in other parts of the body.

Hypophysis See **Pituitary gland**.

Hypothalamus A part of the brain with endocrine functions.

Ileum The last part of the small intestine.

Immune system The body's defense system against infective organisms or other foreign bodies. It includes the lymphatic system.

Involuntary muscle Muscle that is not under conscious control. See also **Smooth muscle**.

Jejunum The middle part of the small intestine.

Joint The junction between bones.

Karyotype The chromosome complement of a person or species: the genome.

Kidney A bean-shaped organ that filters wastes from blood to form urine.

Lactation Milk production by the mammary glands.

Large intestine (or Bowel) The lower part of the alimentary canal, comprising the cecum, colon, and rectum.

Larynx The cartilaginous voice box.

Leukocytes White blood cells. They attack invading microorganisms and help to combat injuries.

Ligament Fibrous tissue that connects bones.

Liver The largest organ in the body, it is involved in various metabolic processes.

Lungs The two organs of respiration, filling most of the chest cavity inside the rib cage and above the diaphragm.

Lymph A transparent fluid that leaks from blood vessels into tissue spaces.

Lymph gland See **Lymph node**.

Lymph node (or Lymph gland) One of the "knots" in the lymphatic system, which contain lymphocytes and macrophages that filter the lymph passing through the nodes.

Lymphatic system A network of lymph vessels and lymph nodes. Vessels collect lymph from body tissues and return it to the blood after harmful substances have been filtered out in the lymph nodes.

Mammary glands The milk-producing structures in the breast.

Medulla oblongata The lowest part of the brain stem, containing the vital centers that control heartbeat and respiration.

Meiosis A type of cell division that produces daughter cells (sperm and ova) each with half as many chromosomes as the parent cell.

Meninges Three protective membranes surrounding the brain and spinal cord.

Menopause When a woman ceases to have menstrual periods.

Menstruation Menstrual periods: the monthly flow of blood and uterine lining from the vagina of nonpregnant females of childbearing age.

Metabolism The array of continuous chemical changes that maintain life in the body.

Mitosis Ordinary cell division in which both daughter cells have as many chromosomes as the parent cell.

Mucous membranes The mucus-secreting linings of the

digestive, respiratory, reproductive, and urinary tracts.

Nasal Relating to the nose.

Nasal cavity The space inside the nose between the base of the skull and the roof of the mouth.

Nerve A bundle of nerve fibers (axons) that transmit impulses to (in the case of sensory nerves) or from (in the case of motor nerves) the central nervous system.

Nervous system The coordinated networks of neurons that control the body. It is divided into the central nervous system (brain and spinal cord), and the peripheral nervous system (the somatic and autonomic nervous systems).

Neuron (*or* Neurone) A nerve cell: the basic unit of the nervous system.

Neurone *See* **Neuron**.

Neurotransmitter A chemical released at nerve endings to transmit nerve impulses across synapses.

Nucleic acids Molecules that store genetic information.

Nucleus The control center of a cell, which contains coded genetic instructions.

Olfactory Relating to smell.

Optic Relating to the eye.

Organ A body part with different types of tissue that performs a particular task.

Organelles Tiny structures (miniorgans) in a cell's cytoplasm with particular tasks.

Ovaries Female sex organs that produce ova (eggs) and sex hormones.

Oviducts *See* **Fallopian tubes**.

Ovulation The release of a ripe egg from a female's ovary.

Ovum An egg; a female sex cell (plural: ova).

Palate The roof of the mouth.

Pancreas An abdominal organ that produces pancreatic juice and the hormones glucagon and insulin.

Parasympathetic nervous system The part of the autonomic nervous system that predominates when the body is at rest.

Parathyroid glands Four pea-sized endocrine glands on the thyroid gland. They produce parathyroid hormone, which controls blood calcium level.

Pelvis A bony basin formed by the two hip bones, the sacrum, and the coccyx.

Pericardium The double-layered membrane that encloses the heart and attaches it to the diaphragm and sternum.

Peristalsis Waves of muscular contraction that propel substances through passageways, such as the alimentary canal.

Phagocytes Types of leukocytes that engulf and destroy microorganisms and foreign bodies.

Pharynx The throat.

Pineal gland (or Epiphysis) An endocrine gland in the brain that secretes melatonin.

Pituitary gland (or Hypophysis) A three-lobed, pea-sized gland below the hypothalamus. It produces growth hormone, hormones that act on other endocrine glands, oxytocin, and ADH. It is often called the body's "master gland."

Plasma The fluid part of blood.

Pleura The membrane that covers the lungs (visceral pleura) and lines the chest wall (parietal pleura).

Plexus A network of nerves (or blood or lymph vessels).

Portal vein (or Hepatic portal vein) Drains blood from digestive organs to the liver.

Prostate gland A gland situated below the bladder in males. It produces a sperm-activating fluid that forms nearly a third of the semen's volume.

Pudendum See **Vulva**.

Pulmonary Relating to the lungs.

Receptor A structure, such as a sensory nerve ending, specialized to detect environmental stimuli.

Rectum The last part of the colon, where feces collects before leaving the body.

Reflex action The body's automatic response to a stimulus, such as blinking.

Renal Relating to the kidney.

Respiration 1) Breathing; 2) Taking in oxygen and giving out carbon dioxide; 3) Deriving energy from food with or without using oxygen.

Respiratory system In humans, the mouth, nose, pharynx, larynx, trachea, bronchi, bronchioles, alveoli, and lungs.

Ribonucleic acid (RNA) A nucleic acid concerned with protein synthesis.

Ribs Twelve pairs of bones that protect the chest cavity and assist breathing by moving up and out during inspiration and down and in during expiration.

Salivary glands The lingual, parotid, sublingual, and submandibular glands that produce saliva.

Serum Blood plasma that does not contain clotting factors but does contain antibodies.

Sinus A cavity, such as the channels draining venous blood from the brain.

Skeleton The bony framework that protects and supports the body's soft tissues.

Skin The body's waterproof covering; its largest organ, comprising two main layers: the epidermis and dermis.

Small intestine The alimentary canal between the stomach and large intestine, comprising the duodenum, jejunum, and ileum. Most digestion occurs here.

Smooth muscle (or Unstriated muscle or Involuntary muscle) Muscle without striped fibers that automatically operates internal organs such as the stomach, bladder, and blood vessels.

Sphincter A ring-shaped muscle that contracts to close an orifice.

Spinal cord The cable of nerve tissue running down inside the vertebral column (spine) and linking the brain with nerves supplying most of the body.

Spine See **Vertebral column**.

Sternum The breastbone.

Subcutaneous tissue The sheet of connective tissue below the dermis.

Suprarenal glands See **Adrenal glands**.

Suture An immovable fibrous joint between the skull bones.

Taste buds Tiny sensory organs of the tongue and palate, distinguishing salty, sweet, sour, and bitter tastes.

Teeth Bonelike structures in the jaws. Different types (incisors, canines, premolars, molars) are specialized to tear, crush, and/or grind food.

Tendons Bands of fibrous connective tissue joining muscles to bones.

Testis (*or* Testicle) One of a pair of primary male sex organs that manufacture sperm (plural: testes).

Thalamus A brain structure above the hypothalamus. It sends sensory impulses to the cerebral cortex, links sensations with emotions, and affects consciousness.

Thymus An endocrine gland located behind the sternum. It produces thymosin.

Thyroid An endocrine gland at the front of the neck, producing thyroid hormone.

Tissue A collection of similar cells that perform a particular task.

Trachea (*or* Windpipe) The tube between the larynx and the bronchi.

Tubule A tiny tube.

Tunica A tissue layer forming a coating. Blood vessels have three such layers (intima, media, adventitia).

Unstriated muscle *See* **Smooth muscle**.

Ureter The tube conveying urine from a kidney to the bladder.

Urethra The passage taking urine from the bladder to the body's exterior.

Urinary system The kidneys, ureters, bladder, and urethra.

Urine Liquid waste excreted by the kidneys.

Uterine tubes *See* **Fallopian tubes**.

Uterus (*or* Womb) A hollow muscular organ located above the bladder. Inside it, a fertilized ovum develops into a fetus.

Uvula A conical tag hanging from the back of the palate. It helps to keep food out of the nasal cavities.

Vagina The muscular passage between the vulva and cervix (neck of the uterus).

Vascular Relating to or richly supplied with vessels, especially blood vessels.

Vein A blood vessel that transports blood from capillaries back to the heart. Veins contain valves to prevent the backflow of blood.

Venous Relating to veins.

Ventricle A cavity: one of the two lower chambers of the heart.

Venule A small vein.

Vermiform appendix *See* **Appendix**.

Vertebra A bone of the vertebral column (plural: vertebrae).

Vertebral column (*or* Backbone *or* Spine) The column of vertebrae between the skull and the hip bones, supporting the body and shielding the spinal cord. It has five sections: cervical, thoracic, lumbar, sacral, and coccygeal.

Vestibule A space before a passage begins, as in the inner ear beyond the oval window, between the semicircular ducts and cochlea.

Vocal cords Two belts of tissue stretched across the larynx which produce sounds when air rushes past them.

Vulva (*or* Pudendum) The external female genitals.

White matter The paler tissue of the brain and spinal cord comprised mainly of myelin-sheathed nerve fibers.

Windpipe *See* **Trachea**.

Womb *See* **Uterus**.

There is a lot of useful information on the internet. There are also many sites that are fun to use. Remember that you may be able to get information on a particular topic by using a search engine such as Google (<http://www.google.com>). Some of the sites that are found in this way may be very useful, others not. Below is a selection of Web sites related to the material covered by this book. Most are illustrated, and they are mainly of the type that provides useful facts.

Facts On File, Inc. takes no responsibility for the information contained within these Web sites. All the sites were accessible in January 2005.

Anatomy of the Human Body : Gray's Anatomy

Online version of the classic *Gray's Anatomy of the Human Body*, containing over 13,000 entries and 1,200 images.
<http://www.bartleby.com/107/>

Biology Online

A source for biological information, suitable for homework, research projects, and general interest, with hundreds of biology Web site links.
<http://www.biology-online.org/>

BIOME

A guide to selected, quality-checked internet resources in the health and life sciences.
<http://biome.ac.uk/>

Health Sciences and Human Services Library

Provides links to selected Web sites that may be useful to both students and researchers.
<http://www.hshsl.umaryland.edu/resources/lifesciences.html>

Human Anatomy Online

Interactive resource, with visual keys to text on the human body.
<http://www.innerbody.com>

North Harris College Biology Department

Tutorials and graphics on biology, human anatomy, human physiology, microbiology, and nutrition.
<http://science.nhmccd.edu/biol/>

Open Directory Project: Reproductive Health

Comprehensive list of internet resources.
http://dmoz.org/Health/Reproductive_Health/

Open Directory Project: Teen life: Sexuality

Comprehensive list of internet resources.
http://dmoz.org/Kids_and_Teens/Teen_Life/Sexuality/

The Biology Project

Structured tutorials on life sciences. Particularly strong on cell biology, human biology, and molecular biology.
<http://www.biology.arizona.edu>

University of Texas: BioTech Life Sciences Resources and Reference Tools

Enriching knowledge of biology and chemistry, for everyone from high school students to professional researchers. The Dictionary and Science Resources are particularly useful.
<http://biotech.icmb.utexas.edu>

- A**
abortion 39, 88
acne 20
Adam's apple 19
adolescence 18, 19, 20, 21
amnion 14, 66, 68
 twins 78, 79
amniotic fluid 14
 labor 93
 placenta 74
 pregnancy 61
 testing 67
androgens 16
- B**
birth 22, 23, 92–97
 menstruation 39
 positions 96
 problems 97
blastocyst 14, 15, 23, 65, 66, 68
 placenta 74
 pregnancy 58
 twins 79
blood supply 7, 25, 47
body odor 20
Braxton-Hick contractions 77
breastfeeding 40
breasts (mammary glands) 6, 7, 10, 11, 34–35
 hormones 17
 pregnancy 59, 81
 puberty 18, 38
breech birth 14, 95, 97
- C**
cancer
 breast 35
 female reproductive problems 37, 39
 male reproductive problems 54, 55, 56
 sexual problems 89
cervix 6, 10, 14, 23, 24
 female reproductive problems 37, 42, 43
 labor 93, 94
 pregnancy 76, 77
 sexual problems 88
cesarean birth 97
child development 100–101
chorion 14, 66, 68
 twins 78, 79
chromosomes 15
 oogenesis 26, 27
 sex determination 92
 sperm production 48, 49
 zygote development 64
circulation, baby 75, 95
circumcision 13, 55, 89
clitoris 6, 8, 10, 22, 23, 24
 sexual problems 88
condom 86, 87, 90, 91
contraception 86–87
contraceptive device 39, 41, 86–87, 88
contraceptive pill 41, 86
corpus luteum 10, 11, 17, 28, 29, 32
Cowper's gland 12, 13, 52, 57
cystitis 37
- D**
dartos muscle 12, 50
delivery 94–95, 97
displaced uterus 37
dysmenorrhea 41
- E**
ejaculation 6
 contraception 87
 female reproductive problems 42
 male reproductive system 9, 12, 13, 44, 45, 46
 puberty 18, 19
 sexual problems 89
 sperm production 48
embryo 6, 8, 14, 15, 30
 development 65, 66, 68–69
 miscarriage 83
 pregnancy 58, 60
 twins 78, 79
endocrine glands 10, 16, 29
endometrium 30, 31
 embryo development 66, 68
 female reproductive system 10, 42, 43
 fertilization 63
 labor 95
 menstrual cycle 32, 33
 pregnancy 58
epididymis 6, 9, 12, 13, 45, 46, 50, 51
 male reproductive problems 56
 sperm production 48, 49
erectile tissue
 female 6, 10, 24
 male 12, 13, 44, 52, 53
 sexual problems 89
erection 13, 44, 53
 puberty 54
 sexual problems 57, 89, 91
estrogen 8, 10, 17, 23
 female reproductive problems 42

- menstrual cycle 32, 33
- ovaries 28, 29
- excretory system 24, 46
- exercise
 - menstruation 40, 41
 - pregnancy 83, 84–85
- F**
 - fallopian tubes (oviducts)
 - 6, 8, 10, 23, 24, 30, 31
 - blood supply 25
 - female reproductive problems 37, 39, 42
 - fertilization 62, 63
 - sexual problems 88
 - zygote development 65
 - female reproductive system 6, 8, 22–43
 - problems 42–43
 - fertilization (conception) 6, 14, 62–63
 - accessory organs 30
 - female reproductive system 8, 22, 23, 42
 - male reproductive system 9
 - oogenesis 26, 27
 - pregnancy 58
 - twins 78, 79
 - zygote development 64
 - fetus 6, 7, 14
 - circulation 75
 - development 69–73
 - female reproductive system 8, 22, 23
 - full term 76–77
 - labor 93
 - miscarriage 83
 - placenta 74
 - position for birth 95, 96
 - pregnancy 58, 59, 60
 - fibroids 42
 - follicle-stimulating hormone (FSH) 10, 11, 28, 29, 32
 - foreskin (prepuce) 12, 53
 - problems 54, 55, 89
- G**
 - gametes (sex cells) 8, 49
 - female 10, 14
 - male 9, 12, 48
 - genetic material 7, 27, 48, 62, 78, 79
 - genitals
 - female 6, 8, 24, 36
 - fetus development 70
 - male 6, 12, 44, 45, 46, 47
 - problems 20, 91
 - puberty 18, 19
 - germ cells 14, 48
 - glans 12, 44, 52, 53, 55, 89
 - gonadotrophins 10
 - gonads
 - female 8, 10, 24
 - male 12, 16, 44
 - growth
 - child development 101
 - male hormones 16
 - newborn babies 99
 - puberty 18, 19
- H**
 - hair
 - female hormones 17
 - male hormones 16
 - puberty 18, 19, 38, 54
 - heavy periods 39, 40, 41
 - hernia 55, 56
 - hormones 16–17
 - contraception 86
 - female 8, 10, 11, 23, 42, 80
 - fetus development 70
 - labor 95
 - male 9, 13, 45, 54, 56
 - menstrual cycle 32, 38, 39, 40, 41
 - ovaries 28, 29
 - pregnancy 59
 - puberty 18, 20
 - sexual problems 42, 89, 91
 - hygiene 36, 54
 - hymen 11, 22, 88
 - hypothalamus 16, 17, 32, 39, 41
 - hysterectomy 37
- I**
 - implantation 15
 - accessory organs 30
 - contraception 86
 - embryo development 66
 - female reproductive system 17, 42
 - menstrual cycle 32, 33
 - pregnancy 58
 - impotence 57, 91
 - infection
 - breast 34
 - contraception 87
 - female reproductive problems 36, 37, 42
 - male reproductive problems 54, 56
 - sexual problems 88, 90–91
 - infertility 42, 56, 88, 89
 - infestations 43, 57, 90
 - intrauterine device (IUD) 39, 41, 86–87, 88
- L**
 - labia 6, 8, 10, 11, 22, 23, 24, 88

labor 14, 15, 92, 93–95
 accessory organs 31
 female hormones 17
 full term fetus 76, 77
 mother's age 80
 pregnancy 61
 lactation 11
 larynx 16, 19
 luteinizing hormone (LH)
 11, 32

M

male reproductive system
 6, 9, 44–57
 blood supply 47
 problems 54–57
 meiosis 15, 26, 27, 48
 menopause 11, 35, 41, 80,
 91
 menstruation (periods) 10,
 11, 23, 31, 86
 cycle 17, 22, 32–33
 pregnancy 59, 60, 80, 81
 problems 20, 37, 38–39,
 40–41, 42
 puberty 18
 milk 6, 7, 11, 17, 34–35
 miscarriage 37, 83
 mitosis 15, 26, 48, 63, 64
 morning sickness 59, 60,
 67, 81, 83, 64
 morula 15, 65
 mucus 22, 23, 43, 77, 94

N

newborn baby 95, 98–99
 nipple 6, 10, 11, 34, 35
 puberty 18, 38

O

oocyte 26, 29
 oogenesis 26, 27

orgasm 12, 13, 22, 54
 sexual problems 91
 ovarian (Graafian) follicle
 10–11, 28, 29
 fertilization 63
 hormones 17
 menstrual cycle 32
 ovaries 6, 7, 8, 10, 11, 17,
 22, 23, 24, 30
 blood supply 25
 fertilization 63
 oogenesis 26
 problems 38, 39, 42, 43,
 88, 91
 puberty 18, 38
 structure 28
 ovulation 8, 11, 17, 30, 38
 contraception 86
 fertilization 63
 menstrual cycle 32
 ovarian cycle 29
 ovum (egg) 6, 7, 8, 9, 10,
 11, 22, 23, 30
 chromosomes 49
 development 64–65
 fertilization 62, 63
 menstrual cycle 32, 33,
 38
 oogenesis 26, 27
 ovaries 28, 29
 pregnancy 58, 60
 problems 38, 42
 sex determination 92
 twins 78, 79

P

penis 6, 7, 9, 12, 13, 44, 45,
 46, 52–53
 contraception 87
 problems 54, 55, 57, 89,
 90
 puberty 19

perineum 11, 12, 24
 pituitary gland 10, 11, 16,
 17, 28, 29, 32, 39
 sexual problems 89
 placenta 6, 7, 8, 11, 14, 15,
 67, 74–75
 development 65, 68, 76
 fertilization 63
 labor 95
 menstrual cycle 32
 twins 78, 79
 pregnancy (gestation) 8,
 15, 67, 58–85
 breast 35
 diet 82, 83
 exercise 84–85
 female hormones 17
 fetus development
 69–73
 mother's age 80
 problems 37, 40, 41, 42,
 61, 80–83
 signs 59, 64
 trimesters 60–61
 premature babies 61
 premenstrual tension
 38–39, 40
 prenatal care 82
 progesterone 8, 11, 17, 23,
 28, 32
 problems 39, 42
 prostate gland 6, 12, 13,
 45, 46
 problems 54, 56, 57, 89,
 91
 puberty 19, 54
 puberty 18–19, 21, 80
 breast 35
 female hormones 17
 oogenesis 26
 problems 20–21, 38, 54
 sperm production 48

S

scrotum 6, 9, 12, 13, 44, 45, 46, 50
 blood supply 47
 hormones 16
 problems 54, 55, 56, 91
 secondary sexual characteristics 10
 semen 6, 9, 12, 13, 44, 45, 46
 contraception 87
 female reproductive system 22, 42
 problems 42, 54, 57
 sperm production 48
 volume 51
 seminal fluid 6, 12, 13
 problems 91
 seminal vesicles 6, 9, 12, 13, 45
 problems 56, 57, 89
 seminiferous tubules 48, 49, 51, 91
 sex determination 92
 sexual intercourse (copulation) 12, 22, 23, 45
 pregnancy 67
 problems 36, 37, 54, 57, 88–89, 91
 sexually transmitted (venereal) diseases (STDs) 43, 56, 90
 sperm (spermatozoa) 6, 7, 9, 12, 13, 15, 44, 45, 46, 51
 contraception 87
 female reproductive system 23, 30, 42
 fertilization 62, 63, 92

gametes 49
 hormones 16
 penis 52
 pregnancy 58
 problems 42, 54, 55, 56, 57
 production (spermatogenesis) 27, 48–49
 puberty 54
 twins 78, 79
 zygote development 64
 stroma 28

T

testes 6, 7, 9, 12, 13, 44, 45, 46, 50–51
 blood supply 47
 hormones 16
 problems 54, 55, 56, 89, 91
 puberty 54
 sperm production 48, 49
 testosterone 9, 12, 13, 16, 45
 problems 54
 tumors 34, 35, 39, 42, 43, 56
 twins 78–79, 80

U

umbilical cord 15, 74, 75
 embryo 66, 68
 labor 94, 95
 twins 78
 urethritis 57
 uterus (womb) 6, 7, 8, 10, 11, 22, 23, 24
 accessory organs 30, 31

birth 15, 92, 93, 94
 blood supply 25
 fertilization 63
 hormones 17
 menstrual cycle 32, 33
 pregnancy 58, 59, 60, 65, 69, 70, 76, 83
 problems 37, 39, 42, 43, 83, 88, 91
 puberty 38

V

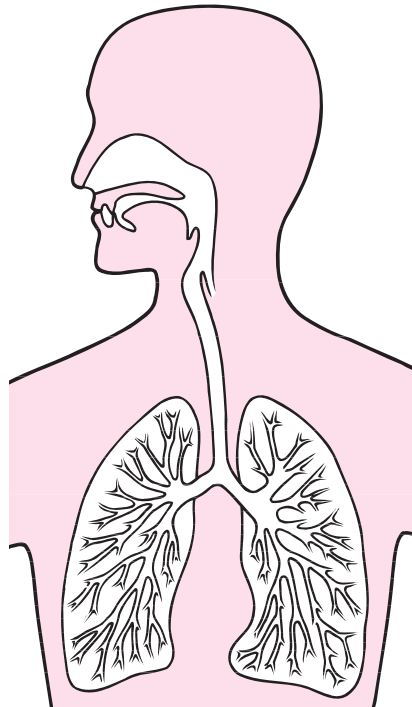
vagina (birth canal) 6, 7, 8, 10, 11, 22, 23, 24
 accessory organs 31
 birth 15, 92, 94
 hormones 17
 menstrual cycle 33
 pregnancy 61
 problems 37, 38, 42, 43, 88, 91
 puberty 18
 vas deferens 6, 9, 13, 45, 46, 50, 56
 sterilization 87
 vertex presentation 15, 96
 vestibular glands 6, 22, 23
 vulva (pudendum) 6, 8, 11, 22, 23, 24
 problems 36, 37, 43, 88, 90, 91
 puberty 18

Z

zona pellucida 15
 zygote 8, 14, 15, 22, 23
 development 64, 65
 fertilization 62, 63

THE FACTS ON FILE
ILLUSTRATED GUIDE TO
THE HUMAN BODY

RESPIRATORY SYSTEM



THE DIAGRAM GROUP

The Facts On File Illustrated Guide to the Human Body: Respiratory System

Copyright © 2005 The Diagram Group

Editorial: Lionel Bender, David Harding, Denis Kennedy,
Gordon Lee, Steve Parker, Jamie Stokes

Scientific consultant: Stephen Rudd

Design: Anthony Atherton, Richard Hummerstone,
Lee Lawrence, Kim Richardson, Ben White

Illustration: Pavel Kostal, Kathleen McDougall

Picture research: Neil McKenna

Indexer: Jane Parker

All rights reserved. No part of this book may be reproduced or utilized in any form or by any means, electronic or mechanical, including photocopying, recording, or by any information storage or retrieval systems, without permission in writing from the publisher. For information contact:

Facts On File, Inc.
132 West 31st Street
New York NY 10001

Library of Congress Cataloging-in-Publication Data

The Facts on File illustrated guide to the human body. The respiratory system / The Diagram Group.

p. cm.

Includes index.

ISBN 0-8160-5983-7 (hc : alk. paper)

1. Respiratory organs. I. Diagram Group.

QP121.F23 2005

612.2—dc22

2004030423

Set ISBN: 0-8160-5979-9

Facts On File books are available at special discounts when purchased in bulk quantities for businesses, associations, institutions, or sales promotions. Please call our Special Sales Department in New York at 212/967-8800 or 800/322-8755.

You can find Facts On File on the World Wide Web at
<http://www.factsonfile.com>

Printed in the United States of America

EB Diagram 10 9 8 7 6 5 4 3 2 1

This book is printed on acid-free paper.

Note to the reader

This book is not intended to serve as a medical textbook for either physicians or patients. The information and advice it contains should not be used or relied upon without consulting the advice of a qualified physician. The publishers disclaim any responsibility for the accuracy of the information or advice that this book contains and any responsibility for any consequences that may result from any use or reliance thereon by the reader.

Contents

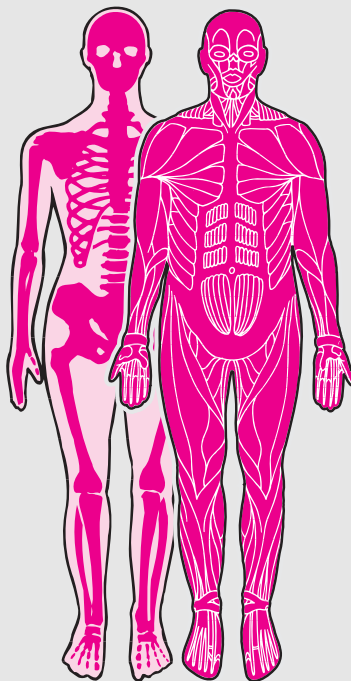
Introduction: About this book	4	Skeleton of the chest	62
		Chest landmarks	64
		Trachea	66
SECTION 1			
RESPIRATORY SYSTEM			
Introduction	6	SECTION 4	
Respiration: key words and diagram	8	LUNGS	
Process of respiration	10	Introduction	68
Mechanics of breathing	12	Relationship of lungs and heart	70
Muscles of breathing	14	Lung structure	72
Blood and nerve supplies	16	Pleurae	74
Upper and lower respiratory tracts	18	Bronchial tree	76
Control of respiration	20	Bronchioles and alveoli	78
Aerobic exercises	22	Lung functions	80
Respiration and exercises 1	24	External and internal respiration	82
Respiration and exercises 2	26	Gas exchange in the lungs	84
Smoking and respiration 1	28	Blood transport of oxygen	86
Smoking and respiration 2	30	Blood transport of carbon dioxide	88
Major respiratory disorders	32	Pulmonary and systemic circulation	90
Allergy-based disorders	34	Lung disorders 1	92
		Lung disorders 2	94
SECTION 2			
UPPER TRACT		SECTION 5	
Introduction	36	NONRESPIRATORY	
Pharynx and larynx	38	Introduction	96
Respiratory linings and mucosa	40	Speech	98
Nose	42	Coughs, sneezes, and hiccups	100
Nasal cavity and sinuses	44		
Pharyngeal anatomy	46	Glossary of the human body	102
Laryngeal anatomy 1	48	Web sites to visit	108
Laryngeal anatomy 2	50	Index	109
Upper tract disorders 1	52		
Upper tract disorders 2	54		
SECTION 3			
CHEST & AIRWAYS			
Introduction	56		
Anatomy of the chest wall	58		
Chest contents and musculature	60		

This book is a concise, illustrated guide to the anatomy, physiology, well-being, and disorders of the human respiratory system. It has been written and illustrated specially for students and laypeople interested in medicine, health, fitness, and first aid. The subject is dealt with in clear steps, so that the reader can steadily acquire a good overall understanding. Explanatory texts, diagrams, illustrations, captions, and fact boxes are combined to help readers grasp important information at a glance. A glossary of scientific and jargon words defines medical terms in everyday language. A list of Web sites provides links to other relevant sources of information, and the index enables quick access to articles.

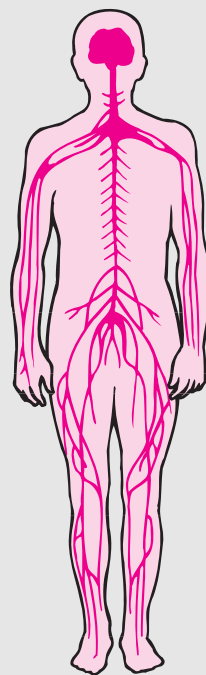
There are five sections within the book. The first section surveys the respiratory system and details the mechanism of breathing. It also deals with exercises related to respiration and the ill-effects of smoking. Sections 2, 3, and 4 focus on the major regions of the respiratory system, from the mouth, nose, and bronchial tubes, to the lungs and their associated blood circulation. Section 5 deals with the nonrespiratory functions of these regions, especially speech. Within each section, normal structure and function are followed by the principles of healthcare and fitness. These are followed by a survey of the main disorders and diseases affecting the region. Information is presented as double-page topics arranged in subsections.

Human body systems

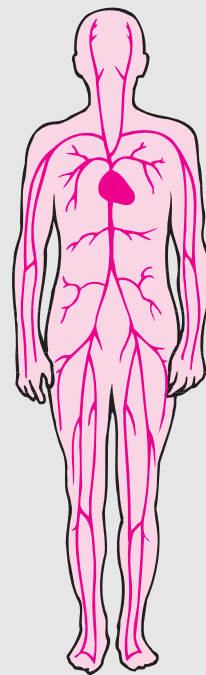
This book is one of eight titles in THE FACTS ON FILE ILLUSTRATED GUIDE TO THE HUMAN BODY series, which looks at each of the major body systems in turn. Some of the titles in the series include more than one system. The skeletal and muscular systems, and the blood and lymphatic systems, for example, work in conjunction and so are treated together. There is a separate title for human cells and genetics, which are the building blocks and underlying chemistry of all body systems.



**Skeletal and
Muscular Systems**



**Brain and
Nervous System**



**Heart and
Circulatory System**

Section 1: RESPIRATORY SYSTEM looks at the process of inhaling fresh, oxygen-rich air and exhaling used, carbon dioxide-laden air. It also deals with exercises that stimulate and promote the respiratory system, and with the ill-effects of smoking.

Section 2: UPPER TRACT investigates how air enters and leaves the nasal cavity, pharynx, and larynx leading to the lungs.

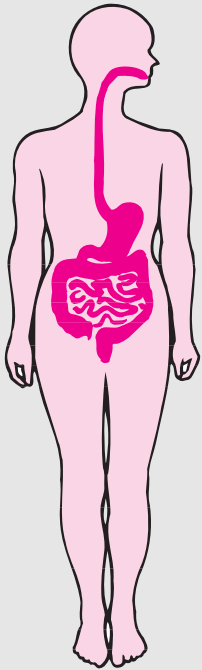
Section 3: CHEST & AIRWAYS focuses on the structure and function of the ribcage and trachea, or windpipe.

Section 4: LUNGS features the blood supply to and from the lungs, gaseous exchange across the thin walls of the lungs, and the major lung disorders.


Section 5: NONRESPIRATORY looks at functions and actions associated with the respiratory system that are not related to breathing or gaseous exchange.

This book has been written by anatomy, physiology, and health experts for non-specialists. It can be used:


- as a general guide to the way the human body functions
- as a reference resource of images and text for use in schools, libraries, or in the home
- as a basis for examination preparation for students of human biology, medicine, nursing, physiotherapy, and general healthcare.



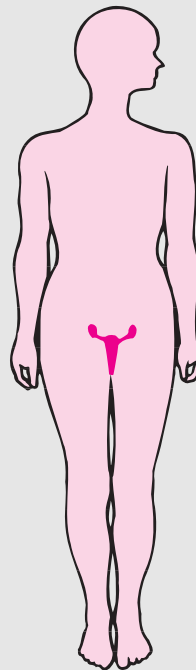
Digestive System



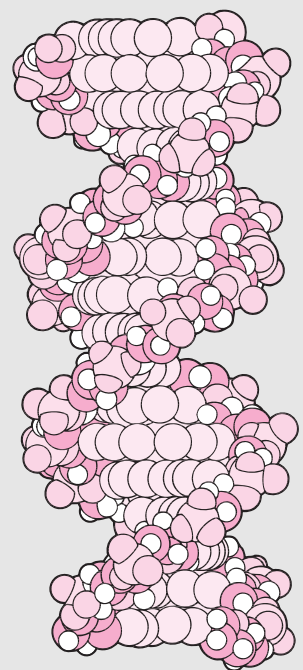
The Senses



Respiratory System



Reproductive System



Cells and Genetics

The respiratory system of branching tubes and cavities alternately admits air to the chest cavity, supplies the blood with oxygen, and expels it to remove waste carbon dioxide and water. These processes occur by muscle-powered movements known as breathing, or bodily respiration. Oxygen exchange within the body's microscopic cells is known as cellular respiration.

Urgent needs

- The respiratory system is perhaps the most vital of all bodily functions. If it fails, all other systems cease within a few minutes.

Risks to the respiratory system

Like the integumentary system (skin, hair, and nails), the respiratory system has continuous communication with the external environment. It takes in and expels air every few seconds. This puts it at particular risk from pollutants.

To protect the delicate linings of the respiratory system from these hazards, the body makes use of glandular structures known as goblet cells.

Making mucus

Goblet cells are the most common mucus-secreting cells. Mucus is a thick, slimy fluid, which protects body surfaces from abrasion, catches foreign objects, and lubricates passageways. Goblet cells are common in the respiratory and digestive systems, and also in the urinary and reproductive tracts.

Mucous layers

Mucus-making cells are found in the sheets of epithelial, or covering, tissue that coat most of the surface lining of the respiratory tract. The amounts of mucus they produce vary depending on the quality of the air breathed, and any infection or disease. Excess mucus may be coughed up or blown from the nose.

Respiratory system

Nose

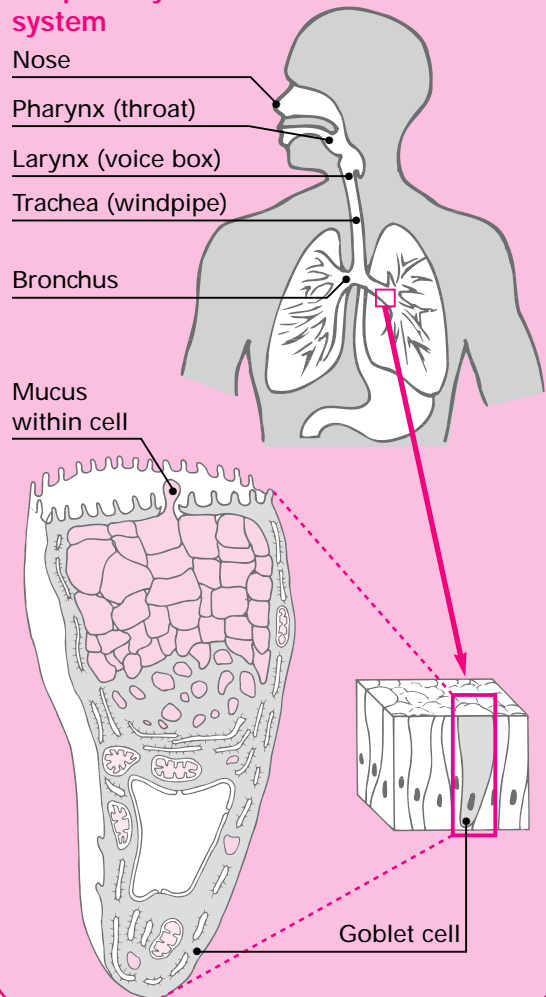
Pharynx (throat)

Larynx (voice box)

Trachea (windpipe)

Bronchus

Mucus within cell



Main parts

The respiratory system is often divided into upper and lower parts. The upper part consists of components within the head and neck; the lower portion is within the chest.

The **nose** is used for breathing and smelling. This organ admits air through two openings—the nostrils—separated by the nasal septum (a wall of bone and cartilage). The nasal cavity connects with sinuses (cavities in the skull), and leads to the pharynx below.

The **pharynx** is also known as the throat. It consists of the nasopharynx (the space at the back of the nose above the soft palate), the oropharynx (between the soft palate and the hyoid bone), and the laryngopharynx (the part of the pharynx below the hyoid bone).

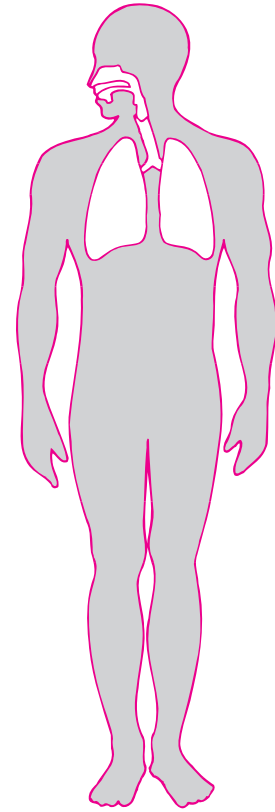
The **larynx** is the voice box, located above the trachea. This organ of vocal sound production also serves as an air passage between the pharynx and trachea.

Trachea This is the windpipe, a broad tube leading down from the larynx. It consists of fibrous and elastic tissue, smooth muscle, and rings of cartilage to keep it open while allowing it to flex with head and neck movements.

Bronchi and bronchioles Each bronchus (plural: bronchi) branches out from the lower trachea to carry air to the left and right lungs. There they divide into smaller branches, called segmental bronchi, which further subdivide into smaller and smaller tubes known as bronchioles.

Alveoli There are more than 600 million of these small cuplike sacs situated at the tips of the bronchioles. Capillaries (tiny blood vessels) in the alveoli walls absorb oxygen from inhaled air, and release carbon dioxide and water for exhalation.

Bronchial tree A treelike structure that comprises the trachea, bronchi, bronchioles, and alveoli.



Lungs These twin organs, divided into lobes, are located in the chest cavity and contain the bronchi, bronchioles, and alveoli. Movements of intercostal and diaphragm muscles draw air into and out of the lungs.

Pleura This thin, transparent membrane wraps around the lungs and lines the inside of the chest cavity.

Respiratory system key words

Aerobic respiration A process that uses oxygen from the air to break complex molecules down into simpler ones, releasing energy.

Anaerobic respiration In living cells, a process that breaks down complex molecules into simpler substances releasing energy without using oxygen.

Bronchiole A subdivision of a bronchus.

Bronchus The main tubes branching from the lower end of the trachea and forming the main airways to and from the lungs.

Diaphragm A muscular sheet used in breathing. It separates the thorax (chest) and abdomen (belly).

Epiglottis A cartilage flap behind the tongue that is closed during swallowing to stop food entering the respiratory airways.

Epithelium The layer of cells covering the body's surfaces and lining internal passages such as the respiratory tract.

Exhalation (or Expiration) Breathing out.

Inhalation (or Inspiration) Breathing in.

Intercostal muscles The muscles between the ribs, which assist breathing.

Interpleural space (or Pleural cavity)

The space between the parietal pleura and the visceral pleura. *See* **Pleura**.

Larynx The cartilaginous voice box containing the vocal cords.

Lobes Major divisions of the lungs.

Lungs The twin organs of respiration, filling most of the chest cavity inside the rib cage and above the diaphragm.

Mucous membranes The mucus-secreting linings of internal passages.

Nares The nasal openings: nostrils.

Nasal cavity The space inside the nose between the base of the skull and the roof of the mouth.

Nasopharynx The space at the back of the nose, above and behind the soft palate.

Palate The roof of the mouth comprising the hard palate at the front and the soft palate behind.

Pharynx The throat.

Pleura The membrane that covers the lungs (visceral pleura) and lines the chest wall (parietal pleura).

Pleural cavity *See* **Interpleural space**.

Pulmonary Relating to the lungs.

Pulmonary artery The artery carrying blood to each lung for oxygenation.

Pulmonary vein The vein carrying oxygenated blood from each lung to the heart to be pumped around the body.

Respiration 1) Breathing; 2) taking up oxygen and giving out carbon dioxide; 3) deriving energy from food.

Ribs Twelve pairs of bones that protect the chest cavity and assist breathing by moving up and out during inspiration, and down and in during expiration.

Sinuses Air-filled cavities in the bones surrounding the nose. There are four pairs of nasal sinuses: ethmoidal, frontal, maxillary, and sphenoidal.

Trachea (or Windpipe) The tube between the larynx and the bronchi.

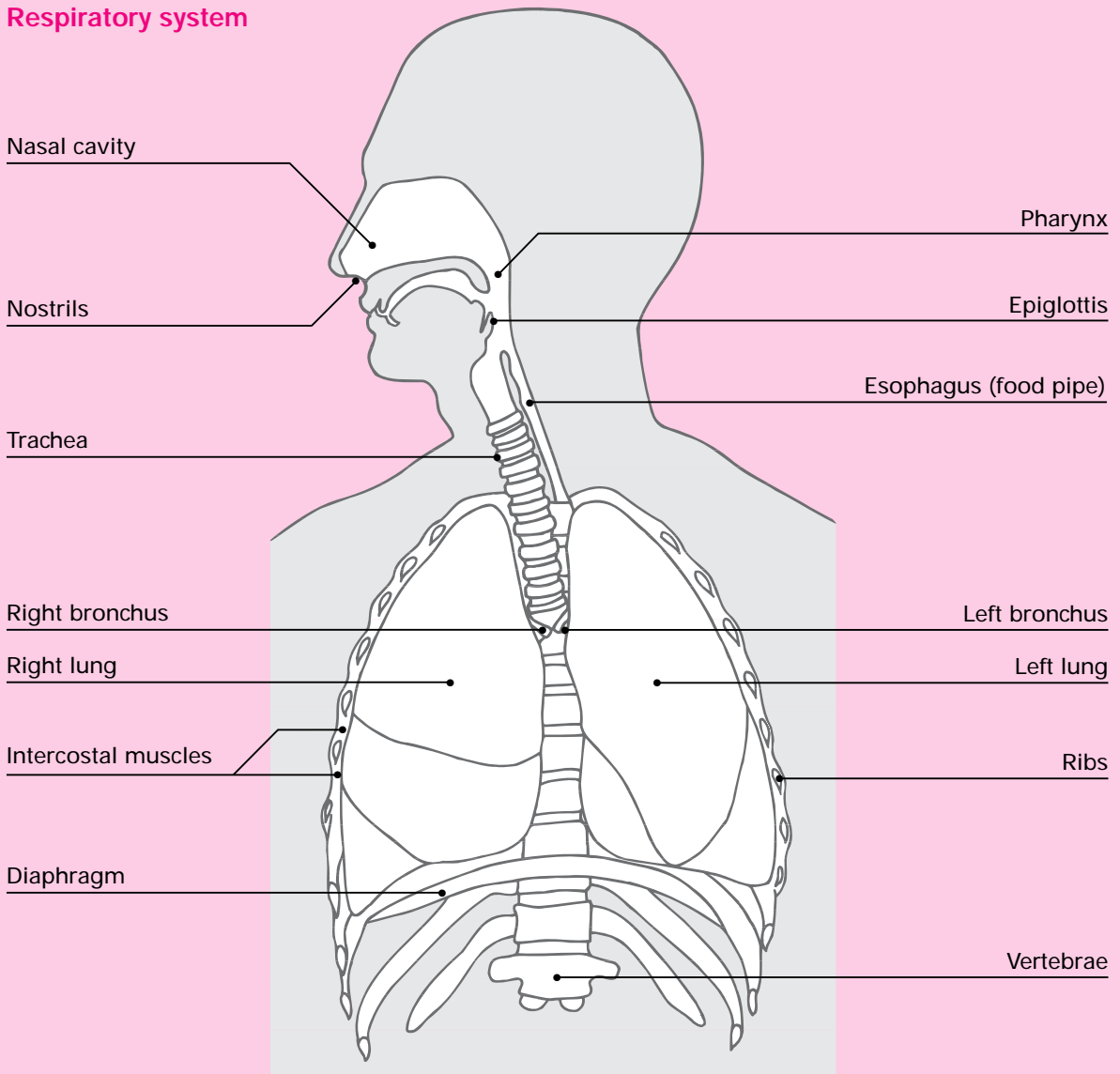
Uvula A conical tag hanging from the back of the palate. It helps to keep food out of the nasal cavities.

Vocal cords Two belts of elastic tissue in the larynx which produce sounds when air rushes past them.

Inside the head, neck, and chest

The major parts of the respiratory system extend from the front center of the head, down to the base of the chest. The respiratory tract consists of the

tubes or airways themselves, plus associated air spaces such as the sinuses. The respiratory system includes surrounding tissues such as muscles.

Respiratory system

The process of respiration

A descriptive summary of respiration is the process that supplies the vital gas oxygen to the body's tissue cells and removes the harmful gas carbon

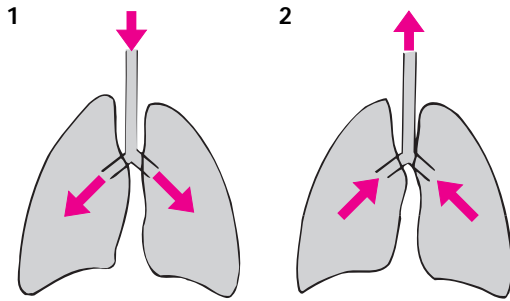
dioxide. It involves events such as ventilation, bodily or external respiration, transport of gases, internal respiration, and cellular respiration.

Process

Definition

Functions

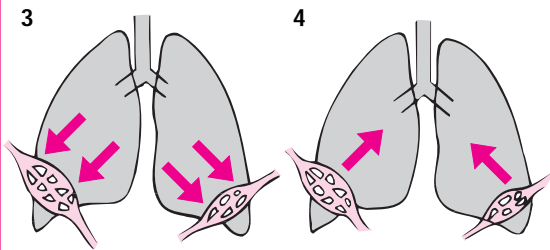
Ventilation



Usually called the breathing process, this involves inspiration (inhalation or breathing in) and expiration (exhalation or breathing out).

The lungs are ventilated, or air is moved in (1) and out (2) by the tidal flow created by the ventilating or breathing muscles.

External or bodily respiration



The exchange of gases between the air in the lungs, and the blood and the body as a whole. This term is also sometimes used to mean the mechanical movements of breathing, as in ventilation (above).

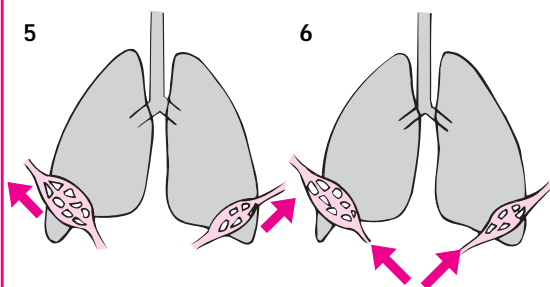
Oxygen is absorbed into the blood from the air inside the lungs (3), and carbon dioxide is taken out of the blood and passes into the air inside the lungs (4).

Process

Definition

Functions

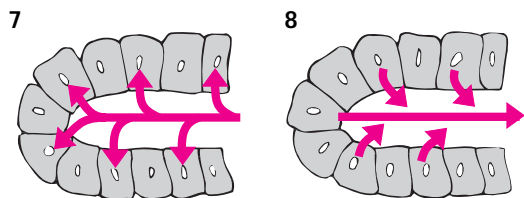
Transport of gases



The carriage or transport of gases between the lungs and the tissue cells, using blood as the transport medium.

Oxygen is distributed from the lungs to the body tissues where it is needed (5), and carbon dioxide is taken away from sites of production and delivered to the lungs (6).

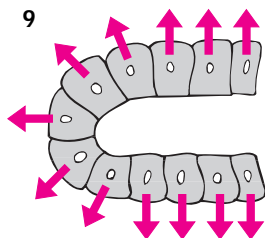
Internal respiration



The exchange of gases between the blood and the tissues and cells all over the body.

Oxygen passes from the blood into the individual cells of the tissues (7), and carbon dioxide is taken away from the tissue cells into the blood (8).

Cellular respiration



Cells' use of oxygen by the breaking down of energy-rich sugars to yield energy; carbon dioxide is a waste product of this process.

Energy can be released for the cell's specialized activities as required, such as making new products (9), movement, maintenance and repair, or cell division.

Breathing mechanism

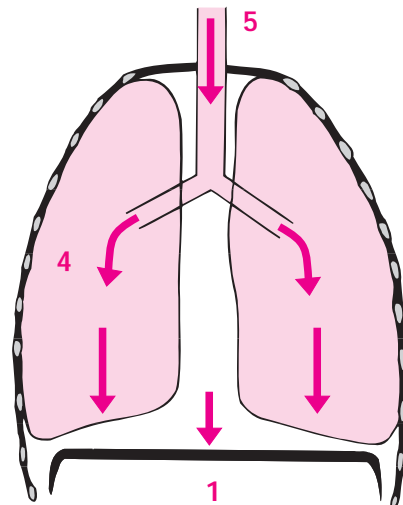
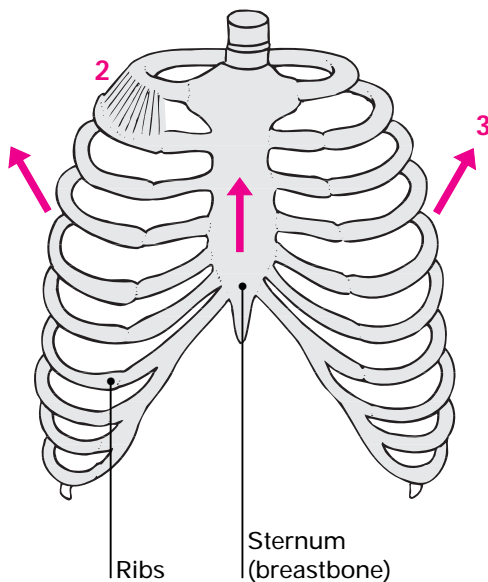
Ventilation is the physio-mechanical process of breathing. It supplies fresh air to, and removes used or “stale” air from, the lungs. It involves the inspiration (inhalation or breathing in) and expiration (exhalation or breathing

out) of air. In normal quiet breathing, only a small proportion of the stale air in the lungs leaves, to be replaced by the same volume of fresh or unused air from outside. Much of the exchange of gases takes place by diffusion.

Inspiration

- 1** The diaphragm (dome-shaped muscle below the lungs, separating the chest cavity from the abdominal cavity) contracts and flattens.
- 2** The external intercostal muscles (outer layer of muscle connecting ribs to each other) also contract.

- 3** The rib cage is pulled out and upward, and this enlarges the space within the chest cavity.
- 4** As the chest cavity enlarges, the lungs are stretched and expanded.
- 5** Air is drawn into the lungs as air pressure in the chest cavity decreases.



Breathing out

Exhalation is mostly a passive process, in that the stretchy tissues of the lungs follow their natural tendency to recoil back to their smaller size. Forced expiration uses muscles of the abdomen, chest, back, and shoulders.

Tidal volume

- In quiet breathing, when the body is at rest, about 30 cubic inches (500 ml) of air is taken into the lungs, and then expelled, with each in-and-out breath.

Expiration

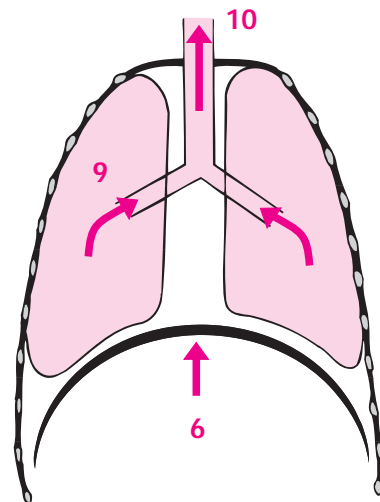
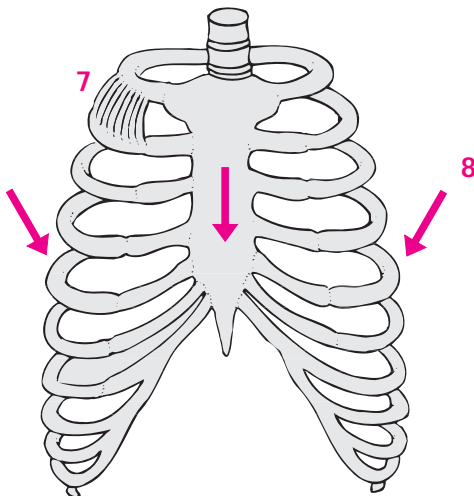
6 The diaphragm relaxes and returns from its flatter shape to its normal, more domed shape.

7 Also, the external intercostal muscles between each pair of ribs relax.

8 The rib cage is allowed to sink down and inward, compressing the chest cavity from the front.

9 The total volume of the chest cavity becomes smaller. This makes the lung volume smaller, aided by the natural recoil of the elastic lung tissues, which have been stretched by expiration.

10 Air is forced out of the lungs as air pressure in the chest cavity increases above atmospheric pressure.



Breathing muscles

Type of breathing

Normal inspiration

Muscle

Diaphragm

Action in respiration

Most important muscle of inspiration; pushes abdominal contents downward to increase vertical capacity of thoracic cavity

Intercostal muscles
(11 pairs)

Move ribs nearer to each other; when first rib is fixed by neck muscles, ribs are raised; when twelfth rib is fixed by quadratus lumborum, ribs are lowered

Levatores costarum
muscles (12 pairs)

Each muscle raises rib below

Scalenus interior

Raises first rib

Scalenus medius

Raises first rib

Scalenus posterior
(not always present
due to individual
variation in
musculature)

Raises second rib

Serratus posterior
inferior

Pulls down lower ribs

Serratus posterior
superior

Raises upper ribs

Normal expiration
(largely passive)

Serratus posterior
inferior

Minor role in pulling down lower ribs

Forced inspiration

All muscles used in
normal inspiration

As for normal inspiration

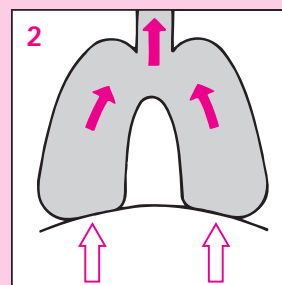
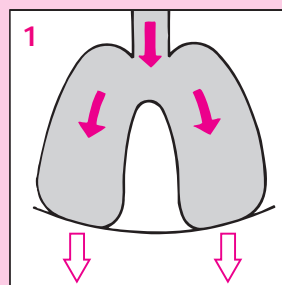
Sternocleidomastoid

Acts as accessory muscle of respiration when head is fixed by contraction of prevertebral and postvertebral muscles

Type of breathing	Muscle	Action in respiration
Forced expiration	Muscles of anterior abdominal wall	Most important muscles of expiration
	Quadratus lumborum	Fixes or lowers twelfth rib
	Serratus posterior inferior	Pulls down lower ribs
	Latissimus dorsi	Accessory muscle when arms are fixed
Respiratory distress	All normal/forced inspiration muscles	As for normal and forced inspiration
	Levator scapulae	Raises medial border of scapula
	Pectoralis major	Can raise second to sixth ribs
	Pectoralis minor	Raises third to fifth ribs if shoulder is fixed
	Rhomboideus major	Raises medial border of scapula and draws it toward midline
	Serratus anterior	Draws scapula forward and rotates to side
	Trapezius	Scapula: upper fibers raise; middle fibers pull to midline; lower fibers depress

Role of diaphragm

When the diaphragm contracts (1) it compresses the abdominal contents, and these bulge forward if the anterior



abdominal wall muscles are relaxed. Contraction of the abdominal muscles exerts pressure upward and aids recoil of the diaphragm (2).

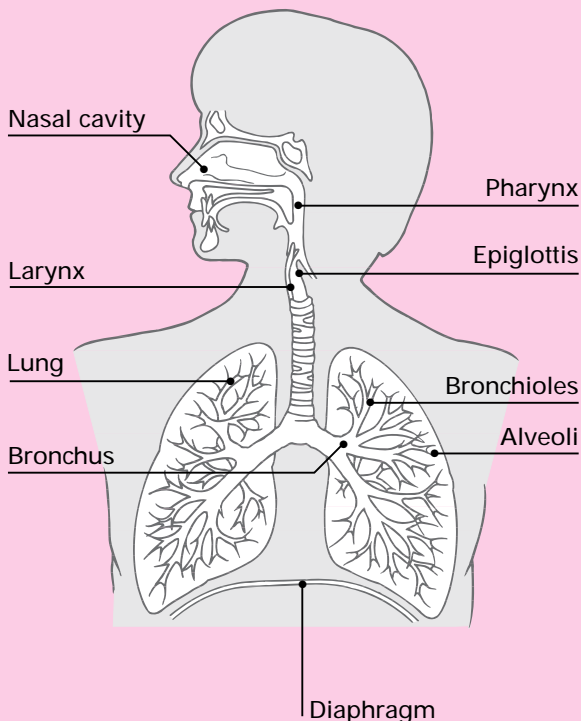
Respiratory system blood and nerve supplies (diagram opposite)

Body part	Blood supply	Nerve supply
Alveoli	Pulmonary capillaries	Pulmonary plexus
Bronchioles	Bronchial artery and vein	Pulmonary plexus
Bronchus	Bronchial artery and vein	Pulmonary plexus
Diaphragm	Phrenic arteries; inferior phrenic veins	Phrenic nerve
Epiglottis	Laryngeal branches of thyroid arteries/veins	Internal laryngeal nerve
Larynx	Thyroid arteries and veins	External, internal, and recurrent laryngeal nerves
Lung	Pulmonary and bronchial arteries and veins	Pulmonary plexus
Nasal cavity	Branches of maxillary and facial arteries; sphenopalatine, facial, and ophthalmic veins	Olfactory nerve; branches of ophthalmic nerve; maxillary divisions of trigeminal nerve
Pharynx	Superior thyroid and ascending pharyngeal branches of external carotid artery; venous plexus drains into internal jugular vein	Pharyngeal branch of maxillary nerve; lesser palatine nerves; internal laryngeal nerve

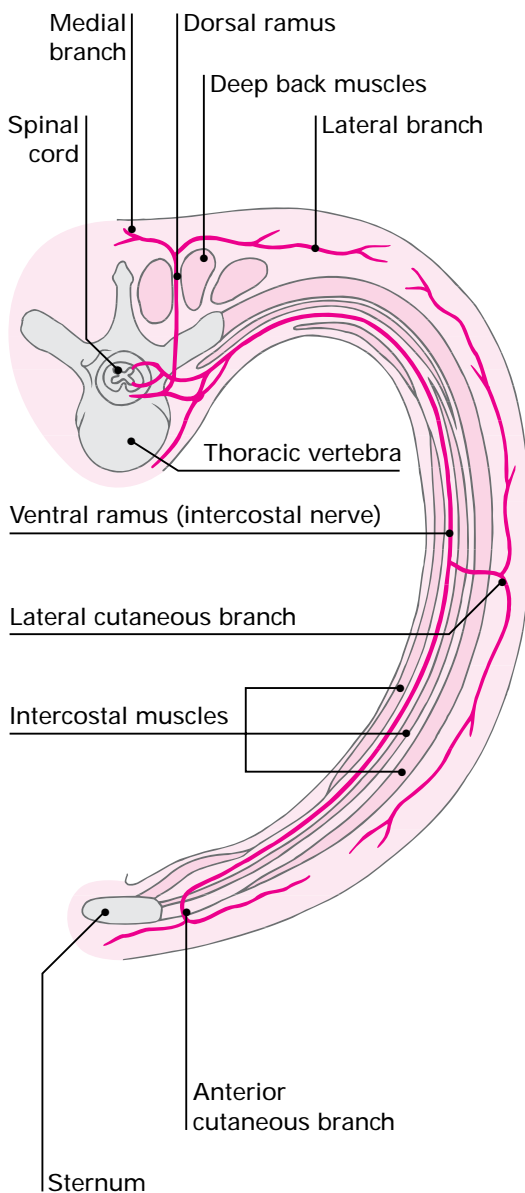
Nerve control

Most nerves controlling the intercostal muscles between the ribs emerge from the spinal cord between the thoracic vertebrae (backbones). Each nerve has two main branches to the rear—one to the central back (medial), and one slightly to the side. The major ventral ramus curves around to the side and front of the body, and is known as the intercostal nerve.

Key to chart (page 16)



Course of a typical thoracic spinal nerve



The respiratory tract, or system of air tubes and chambers, is conventionally divided into upper and lower parts. This division has an anatomical basis in the types of tissues forming the walls of the tract, the nature of the tract linings, and the origins of the blood and nerve supplies. In general the upper tract includes parts within the head and neck,

while the lower tract is within the thorax (chest). Also, problems such as infections tend to affect either one part of the tract or the other; only occasionally, and usually seriously, are both parts infected. The upper respiratory tract, URT, is generally more at risk from airborne microbes, including bacteria causing sore throats, and viruses of the common cold.

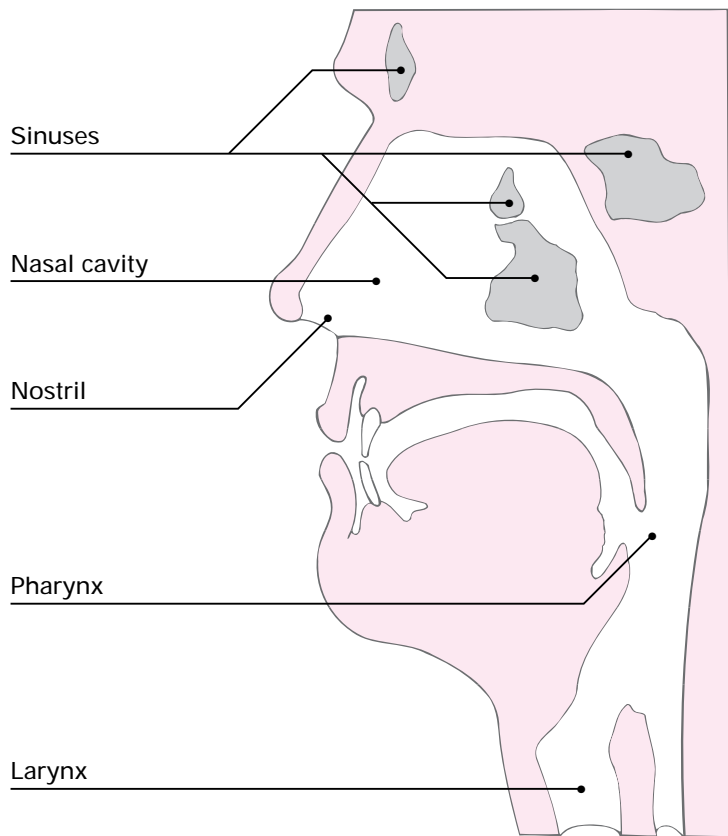
Upper respiratory tract

The upper tract consists of the nose and nasal cavity; the pairs of sinuses or air spaces which branch from this; the pharynx (throat); and the larynx (voice box), which is in effect the uppermost part of the trachea. The main function of these parts is to act as a passageway for air, between the external nasal openings or nostrils, and the lungs in the chest below.

Relative volume

- The combined volume of all of the conducting airways, from the nasal cavity to the small bronchioles, represents less than four percent of the total air volume of the respiratory system.

Upper tract organs



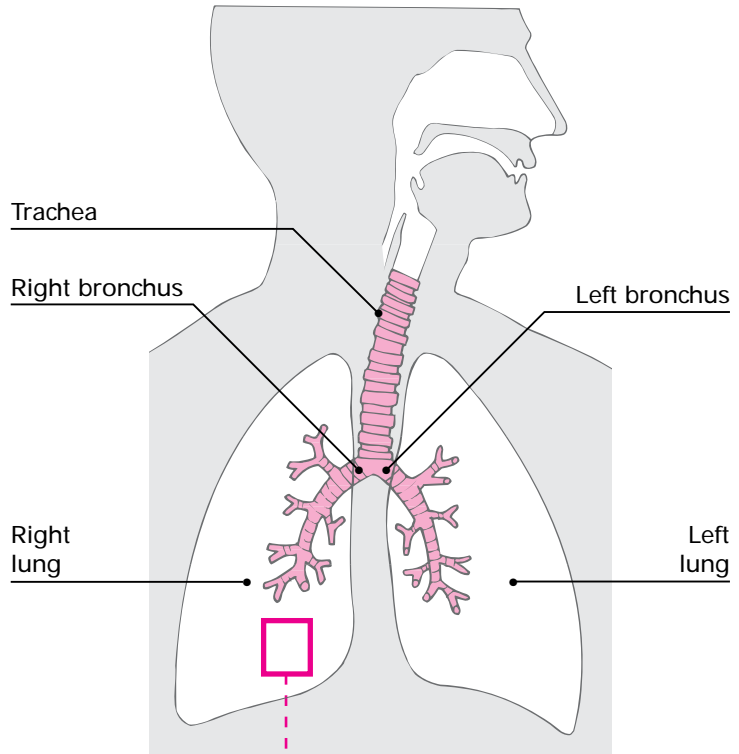
Lower respiratory tract

The lower tract is traditionally regarded as starting at the top of the trachea (windpipe) and extending to the deepest parts of the lungs. It consists of the trachea itself; the two major airways, or bronchi, branching from its base; the smaller airways, or bronchioles; and the tiniest airways, terminal bronchioles. These end in millions of microscopic bubble- or cup-shaped chambers, called alveoli, where gas exchange takes place.

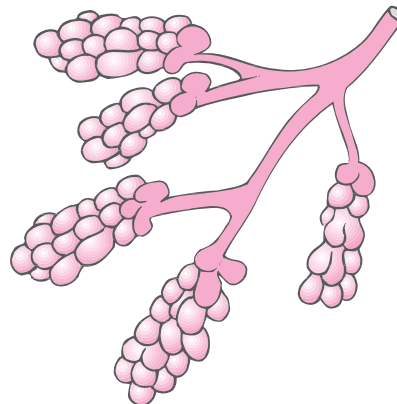
Speed of air flow

- During normal quiet breathing the average linear speed of air flowing through the smallest bronchioles is only one-fiftieth of the linear speed of air along the trachea.

Lower tract organs



Lung tissues
(bronchioles
and alveoli)



Control of respiration

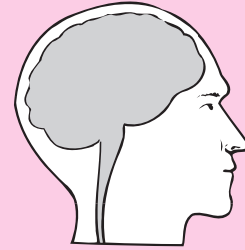The usual breathing rate for adults is 12 to 18 respirations per minute. For small children, the rate can be anything up to 40 respirations per minute. One respiration equals one inhalation (breathing in) and one exhalation

(breathing out). The rate, rhythm, and depth of breathing are controlled by nerves linked to the brain. This control is affected by various factors, such as chemical, emotional, physical, and sensory stimuli.

Involuntary nervous control

The normal breathing rate is regulated by nerve impulses from controlling centers in the brain. This is largely an involuntary process (not under conscious control).

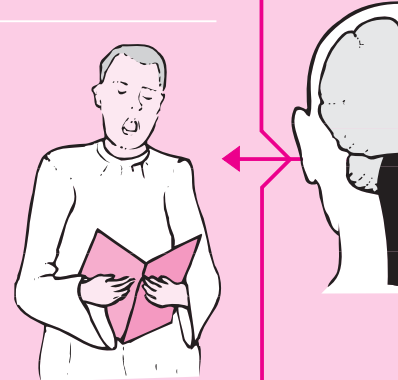
Involuntary control occurs when at rest, during sleep, or when unconscious.



Voluntary nervous control

Involuntary nervous control of breathing can be temporarily overridden to allow voluntary activities (under conscious control), such as eating or speaking. It is not possible, however, to override the involuntary mechanism indefinitely. It is impossible, therefore, to hold your breath until suffocation occurs.

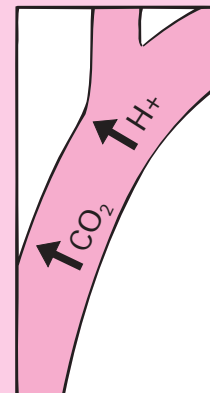
Voluntary control occurs mainly when speaking, eating, or clearing the throat.



Chemical stimuli

Chemoreceptors (chemically responsive cells or nerve endings) in the brain and blood vessels are stimulated by high levels of carbon dioxide. These instruct the brain to increase the rate and depth of breathing until the levels drop. Low levels of oxygen in the blood only become an important stimulating factor when high carbon dioxide content is caused by a condition such as emphysema.

Chemoreceptors in major blood vessels respond to levels of dissolved carbon dioxide.



Sudden changes

Breathing rate and depth can be altered in less than half a second as part of the body's self-protection mechanism. For example, an item stuck in the throat triggers the cough reflex, using fast-moving air to blast the item out.



Basic instincts such as fear override conscious control of breathing.

Take a deep breath . . .

- A sudden need to concentrate, or an unexpected event, can cause a sharp intake of breath involving three times as much air as normal quiet breathing uses.

Emotional stimuli

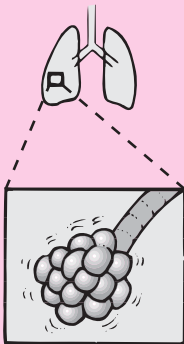
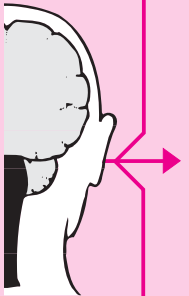
Emotional responses such as laughing and crying interrupt breathing. Emotional states such as fear and anxiety alter the rate and depth of breathing, often increasing them.

Physical stimuli

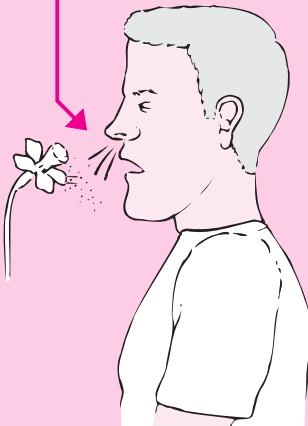
As the lungs fill with air, stretch receptors within their tissues are stimulated that trigger a reaction known as the Hering-Breuer reflex. This prevents overinflation of the lungs and possible damage to the delicate tiny airways and alveoli.

Sensory stimuli

Strong smells, food entering the throat, and irritants entering the air passageways can trigger reflexes such as sneezing, swallowing, and coughing. These temporarily interrupt normal breathing. Chronic or sudden pain alters the rate and depth of breathing, as can sudden temperature changes, such as jumping into cold water.



Natural body reflexes protect the lungs and breathing system.



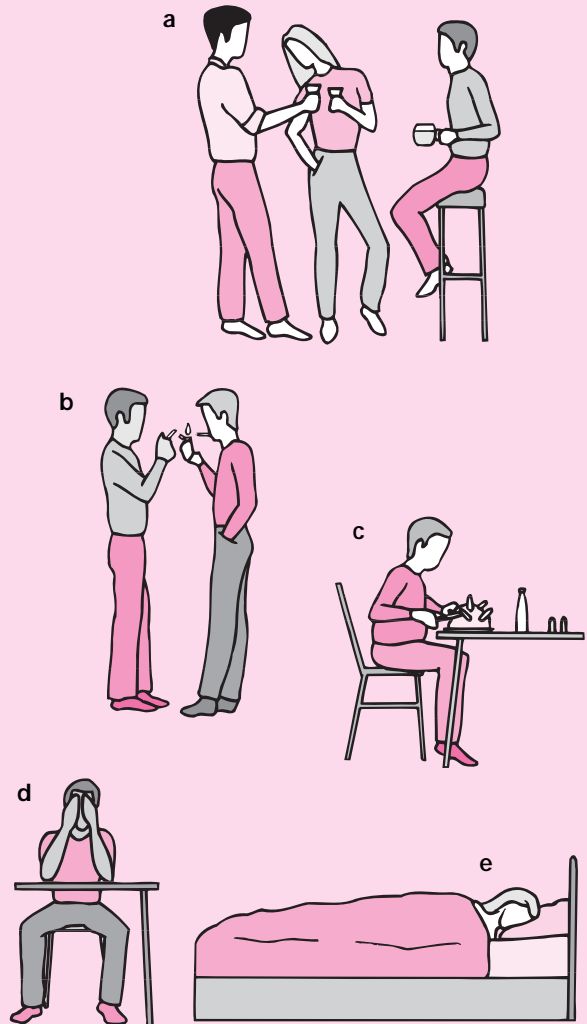
Allergy to pollen causes sudden fast nasal exhalation—sneezing.

Aerobic exercises are those that improve the performance and endurance of the lungs and respiratory system, and the heart and cardiovascular system. Mobility and strength exercises alone will have little effect on your overall bodily fitness unless you include some aerobic exercise in your fitness program. Whether your lifestyle is completely sedentary or you engage in a lot of active sports and

pastimes, your body will benefit from an improvement in the respiratory and cardiovascular systems; your lungs and heart will work more efficiently and become more resistant to disease and disorders, and your circulation in general will be improved. Regular aerobic exercise should always begin gently, as shown here, and be subject to assessments (see pages 24 and 26).

Avoiding unfitness

Even before your exercise program begins, there are ways in which you can improve your fitness in other areas of your life. (a) Drinking to excess drastically reduces your body's efficiency. The direct effect of tobacco smoke on the lungs (b) makes them less capable of exchanging carbon dioxide for oxygen. Because the blood carries less oxygen, the muscles tire more easily. Giving up smoking will add enormously to the benefits of aerobic exercise. Being overweight will hamper your efforts to become fit; lose the excess weight gradually and safely. Even if you are not overweight, eating large meals (c) will make you less inclined to exercise; try to eat several smaller meals each day rather than one or two large ones. Stress also has an effect on your physical well-being (d); learn to relax so your body is not overtaxed in the wrong ways. Also make sure you get enough sleep (e). If your body is run down it will not be able to function efficiently. A sedentary life will increase any tendency to eat, drink, or smoke too much; develop sports, interests, and pastimes that are as active as possible.



Fit and less fit

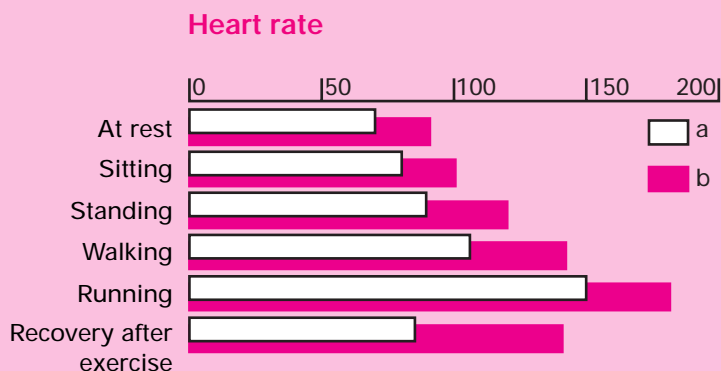
It is the respiratory system's task to take in enough oxygen for the body's most active muscle—the heart.

The diagram shows the comparative amounts of work done by a fit heart (a) and an unfit heart (b) during various activities.

The higher the heart rate, the harder the heart is having to work; when the heart rate is lower for the same level of exercise, the heart is usually

pumping more efficiently. All this time the breathing muscles and lungs are working to supply oxygen

to the bloodstream. Their health and efficiency have a knock-on effect through all body systems.



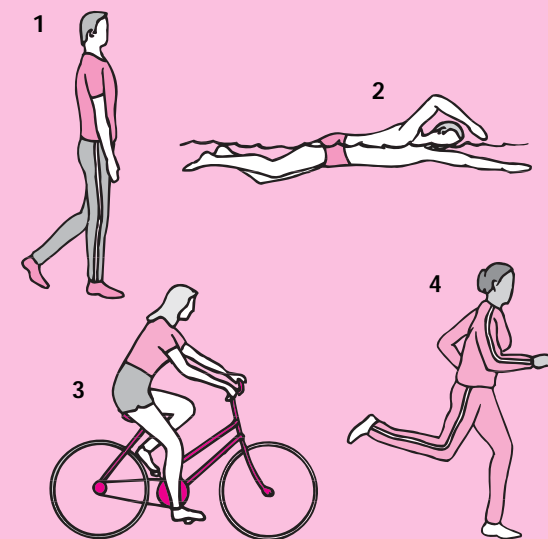
Starting aerobic activities

If you are very unfit, and cannot perform even the simple aerobic tests well, then your body will need to be eased very gradually into exercise. Have a thorough physical examination before you embark on any kind of exercise, and take advice from your doctor.

1 Walking is an excellent way to begin. On your first day, walk as far as you can without excessive tiredness, and then increase the distance gradually. Once you can walk several miles, increase the speed so that your lungs are exercised.

2 Swimming can also be increased gradually as fitness improves.

3 Cycling will probably quickly leave you breathless, but it is good exercise. Start with a gentle ride on level ground, and increase the distance each day.



4 Jogging can be started as part of your walk; jog for a few yards every five or ten minutes, and gradually make the jogging stretches longer.

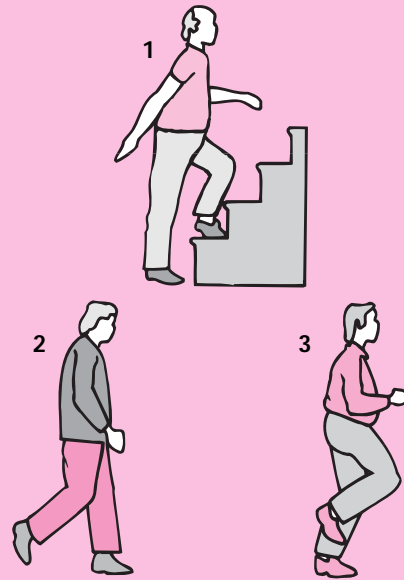Basic aerobic tests

You can judge the condition of your respiratory-circulatory system by your performance in simple tests such as these. If you are very unfit you will find even these tests strenuous; stop as soon as you feel out of breath, or if your heart begins to race uncomfortably.

1 Walk up and down an average staircase at normal speed three times. Can you do this without feeling out of breath, and hold a normal conversation immediately?

2 Can you easily walk for one mile at your normal speed?

3 Can you run for 50 yards?



More strenuous aerobic activities

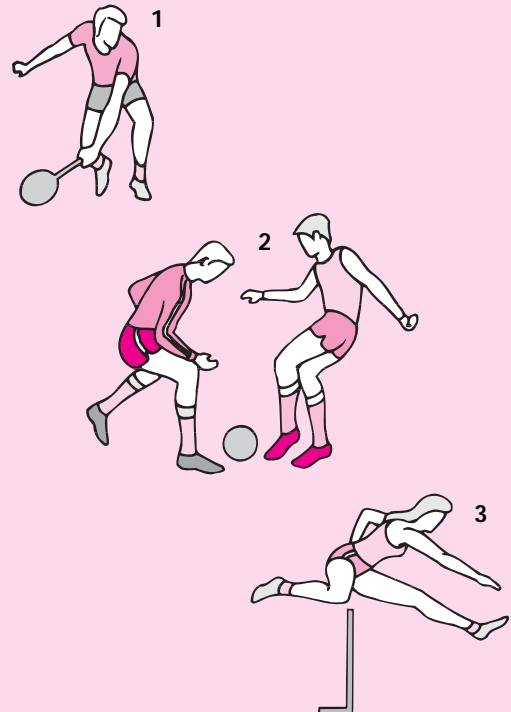
When you have gradually built up your fitness and capabilities through walking, jogging, or cycling, as shown previously, you will find that the following activities provide more strenuous aerobic exercise.

1 Racket sports provide good exercise due to the running they entail.

2 The same is true of most ball games such as football, soccer, hockey, basketball, and volleyball.

3 Competitive sports such as canoeing, rowing, skiing, swimming, hurdling, skating, and cycling tend to provide aerobic exercise because of the speed at which they are executed in competition. They are less recommended for people with heart trouble or past middle age.

4 Hill-walking, or walking over any rough terrain, will provide good aerobic



exercise if you keep up a brisk walking pace and cover several miles or more.

5 Vigorous repetition of many physical movements will provide aerobic exercise if the action is repeated many times without pause.

Running and jumping

Running and jumping provide very good aerobic exercise for people who already have some level of fitness.

6 Jogging over long distances will improve your respiratory-circulatory system considerably as both lungs and heart are working hard.

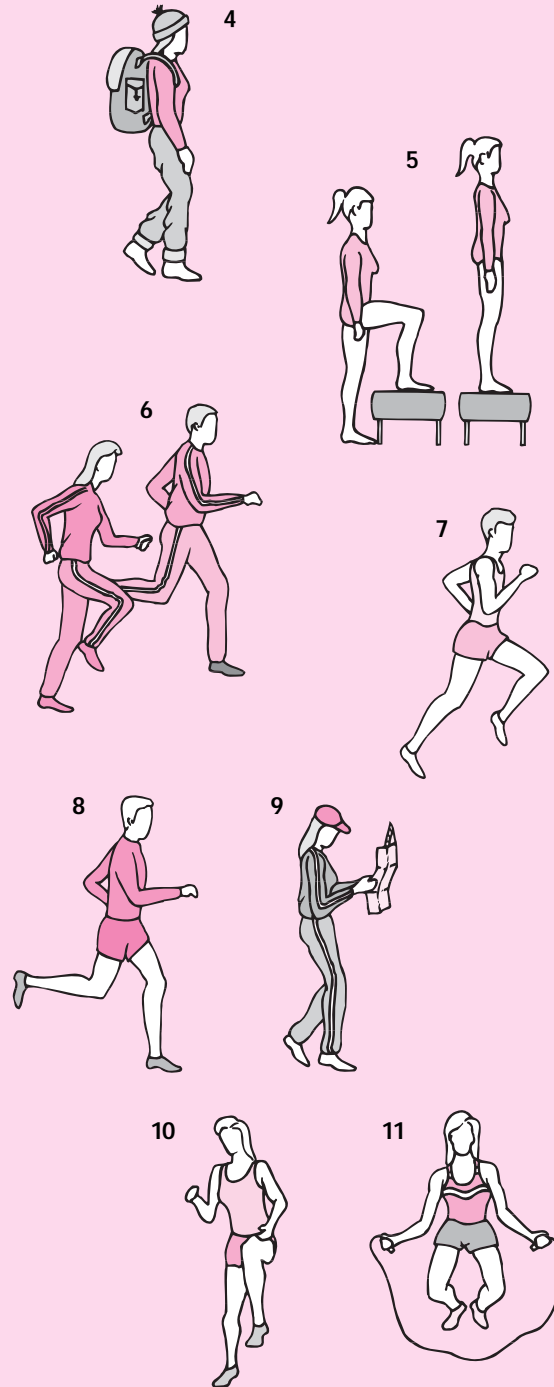
7 Sprinting requires short bursts of immense energy, and will tax your lungs and your heart with the extra oxygen required and the speed at which your heart needs to pump the blood around your body.

8 Long-distance running is excellent exercise for the lungs and heart as it requires a continuous, sustained effort.

9 Orienteering and crosscountry running are pleasant ways of getting aerobic exercise; hard running can alternate with easier terrain.

10 Running in place is an indoor alternative to ordinary running in bad weather; or you could use a treadmill that measures the number of steps you take and converts them into distance equivalents.

11 Jumping rope (skipping) provides very vigorous aerobic exercise if done strenuously. Try turning the rope backward or extra fast so that it passes under your feet twice before you land back on the ground.



Respiration exercises

Here are some advanced exercises that can be undertaken when you have increased your mobility, strength, and aerobic endurance. If you already have a high level of fitness, you could go straight to these exercises. But never try to do them before your body is ready. There are no shortcuts to fitness, and if you try to do too much too quickly, you may strain your body and possibly cause it permanent damage. Your lungs, heart, muscles, and joints need to be conditioned in a slow and graded manner.

When you feel that you are ready, try one of the activities shown here slowly and gently, and stop if you feel that you are taxing your body too much. The tests of strength and endurance detailed below will help to tell you if your body is in good condition. Remember that variations in body size, weight, build, and proportions have effects on performance in such tests. A key approach is to measure your gradual improvements against your own past performances, rather than against those of other people.

Advanced aerobic fitness tests

This table shows “good” fitness ratings for men and women of different ages taking part in a test run/walk. Do not do this test unless you have been taking part in an aerobic fitness program for at least three months. To do the test, cover 1.5 miles (2.4 km) of level ground in your own mixture of running, jogging, and walking. Compare your time with the average times for your age and sex, as shown in the table.

	Age	Time (mins: secs)
Men	13–19	9:41–10:48
	20–29	10:46–12:00
	30–39	11:01–12:30
	40–49	11:31–13:00
	50–59	12:31–14:30
	60+	14:00–16:15
Women	13–19	12:30–14:30
	20–29	13:31–15:54
	30–39	14:31–16:30
	40–49	15:56–17:30
	50–59	16:31–19:00
	60+	17:31–19:30

Gymnasium activities

The equipment available in gymnasiums often requires a high level of fitness, strength, and flexibility in order to make proper use of it. Always use equipment under supervision, and obey all safety rules.

1 Sloping benches may be used in many strengthening exercise programs; weights on the legs and arms are often used in conjunction with these benches.

2 Using gymnastic equipment such as rings, the horse, the parallel bars, and the asymmetric bars can be very strenuous.

3 Rowing and cycling machines simulate these activities and are ideal for use in confined spaces.

4 The wall bars of a gymnasium provide ideal equipment for improving muscle strength in various areas of the body.

5 Field events such as pole vault and triple jump require great strength and flexibility.

6 Treadmills or joggers are a series of rollers



used to simulate outdoor running; the rollers can be inclined to make the task more difficult.

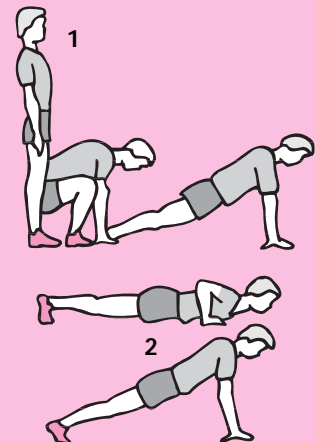
7 Sophisticated equipment such as leg presses, chinning stations, and combined exercise units can be used for strenuous workouts.

Endurance tests

Lungs, heart, and muscle endurance are tested by the following tasks.

1 Stand upright, then bend your knees and lean forward, hands flat on the ground. Kick your legs back as shown, then return to the squatting position and stand up. Ten times without stopping is average.

2 Lie face down with your legs straight, toes tucked under, and hands flat under your shoulders. Straighten your arms to raise your body into the push-up position, then lower again. For men, 20 is good and 30 very good; for women, ten is good, 15 very good.



In the last century, the smoking of cigarettes, cigars, and pipes has almost totally replaced chewing and snuff-taking as the main way of using tobacco. The mass production and forceful promotion of tobacco products meant that consumption of cigarettes soared. Over the last 50 years, medical research has shown that smoking constitutes a grave health risk,

with more and more diseases proving to be associated with, or aggravated by, smoking. Women who smoke while pregnant can cause damage to their babies. More recently smoking has been recognized as a major air pollutant. Here we look at some of the risks associated with smoking, and examine ways of lessening those risks.

Immediate effects of smoking

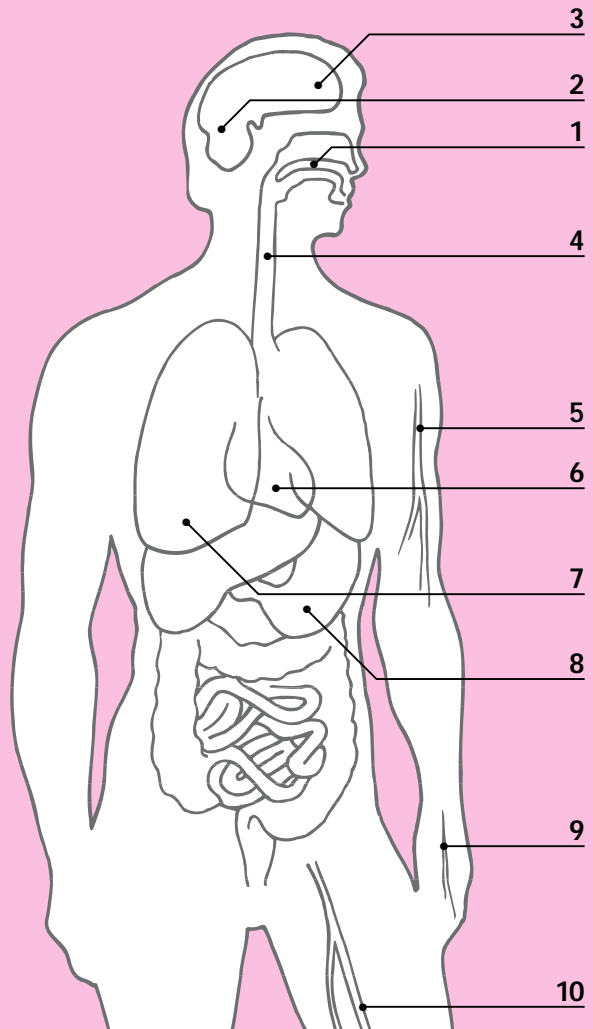
This diagram illustrates some of the parts of the body affected by smoking tobacco. These effects wear off gradually when the smoking stops, but if smoking is frequent or continuous the affected parts of the body have no time to revert to their normal states.

1 Nicotine is absorbed through the lining of the mouth (as well as through the lungs) and enters the bloodstream.

2 The nicotine releases a small quantity of catecholamines, which subdue the transmission of nerve signals and reduce feelings of fatigue.

3 The toxins carbon monoxide and cyanide in the smoke may cause a headache. Carbon monoxide is only absorbed through the lungs, and its presence in the bloodstream indicates that the smoker has inhaled the smoke into the lungs.

4 Nicotine acts on the nerves, and paralyzes the cilia of the airways. Cilia are the tiny hairlike projections responsible for removing the mucus that traps harmful particles. When they are put out of action, the mucus and the particles remain in the airways. Nicotine also inhibits microscopic cells, alveolar phagocytes, which clean the



lungs. These are responsible for engulfing and destroying bacteria and viruses in inhaled air. One cigarette puts them out of action for 15 minutes.

5 The blood pressure rises because of the constriction of the blood vessels caused by the nicotine absorbed from the smoke.

6 The heart rate increases because of the action of these various chemicals, and so the reserve energy of the heart is decreased, rendering the person less capable of physical exertion or strain.

7 The lungs fill with a mixture of air and tobacco smoke, which deposits minute amounts of tar inside the lungs.

8 Hunger is abated because of the action of nicotine on the autonomic nervous system—the part of the nervous system that governs the actions of the involuntary muscles including those in the digestive system. Slight nausea may be experienced if the stomach is empty.

9 The blood vessels to the hands and feet are constricted. This may lead to cold extremities, slow healing of cuts and abrasions there, and poor general circulation.

10 Certain chemicals in the tobacco smoke may contribute to the raising of the serum cholesterol level in the bloodstream.

Effects of long-term smoking

Any or all of these symptoms may appear in long-term smokers.

- Decreased lung efficiency caused by modification of the lung tissue; this makes exertion unpleasant or even dangerous.
- Persistent cough, caused by the hypersecretion of mucus in response to the irritant constituents of the tobacco smoke. The mucus is at first clear, but later it becomes purulent as increased infections occur.
- Permanently depressed appetite caused by the effect of nicotine on the autonomic nerve supply. This often leads to poor or inadequate nutrition among heavy smokers.
- Severe circulatory problems in the hands and feet. People with peripheral vascular disease from other causes

(such as diabetes), and who continue to smoke at their peril, may have to have limbs amputated in later life.

- Decreased senses of taste and smell caused by prolonged contact with tobacco smoke.
- Discolored teeth and fingers from nicotine staining.
- Varicose veins caused by decreased blood supply to the legs.
- Lung cancer, emphysema, and chronic bronchitis are among the many debilitating or fatal diseases that result from long-term smoking.

Shorter life

- For the long-term smoker who is unlikely to quit, it is estimated that each cigarette shortens life by approximately 5–7 minutes.

When tobacco smoke is taken into the mouth, throat, airways, and lungs, various chemicals are absorbed into the bloodstream through the linings of these parts (see previous page). The chemicals include nicotine, toxins (poisons), and carcinogens (cancer-inducing substances). The nicotine and toxins alter the blood vessels and heartbeat, increasing the likelihood of circulatory and heart disease. If the smoke is inhaled deeply, tar collects in the lungs and the cells lining the airways are destroyed, causing respiratory diseases.

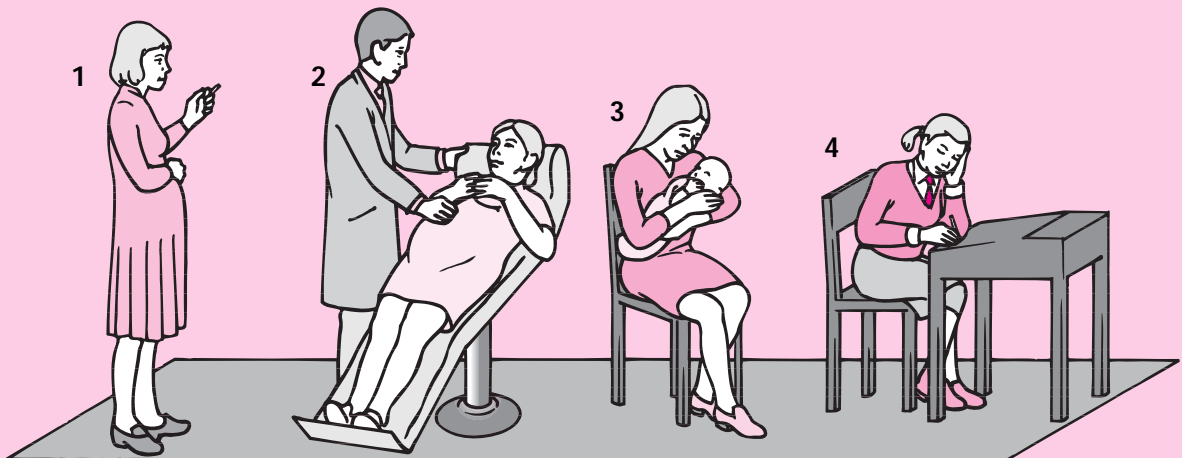Passive smoking

- Passive smoking is when non-smokers in the vicinity of smokers take in tobacco chemicals. It is becoming increasingly recognized as a source of

Lifetime effects

The effects of tobacco smoke on the body can have far-reaching consequences for a woman who is pregnant (1). The decreased efficiency of the circulation while the mother is smoking means that less blood and less oxygen reaches the fetus. These are likely to affect the fetus adversely and slow growth and development. The likelihood of a pregnant woman miscarrying her baby is doubled if she smokes (2). Fetal malformation, congenital heart disease, and breathing difficulties are more likely among the babies of mothers who smoked through

pregnancy. Because of difficulties with the placenta, premature births among smoking mothers are common, and the chances of the baby dying within the first few months after birth are double those of the babies of non-smokers (3). The progress of children from birth suggests that smoking through pregnancy may lead to an educational disadvantage for them later in life. At the age of 11, those children whose mothers had smoked through pregnancy tended to be several months behind in educational progress, and also slightly shorter than their classmates (4).



Individual attitudes

The dangers of smoking are nowadays widely publicized, especially as more diseases are found to be caused or aggravated by smoking. Individual smokers are increasingly aware of the damage they are doing to their own bodies. Many of those who become concerned give up smoking completely; many others cut down their consumption, or change to a brand of cigarette that is lower in tar. Some people establish a no-smoking rule in their house, especially if a pregnant woman or a baby is part of the household. It is now normal to ask permission to smoke rather than assume it is acceptable.

Public attitudes

The results of research on the health and pollution dangers of smoking have led to governments forcing cigarette companies to put health warnings on packs, and also for cigarette advertising to be banned on television and billboards and at public events. Smoking is forbidden in most food shops, restaurants, theaters, concert halls, and places of work. Smoking is now prohibited on most public transport systems and even at some open-air events. Various pressure groups continue to campaign against smoking on fire-prevention and general safety grounds, as well as for individual and public health reasons.

Ways of giving up

- If you plan to give up totally, it is probably better to do so all at once rather than to cut down slowly. Your body will get over its craving for nicotine more quickly, and it will be easier for you to refuse cigarettes if you can say you have given up.
- Think about the many reasons—financial and social, as well as health—that you have for giving up.
- Set a particular day for giving up, and get rid of spare cigarettes, lighters, ashtrays, and any other reminders of the habit.
- Ask your doctor for help.
- Save up your tobacco money for a particular luxury.
- If possible, give up with someone else for moral support.
- Join a stop-smoking support group.
- Keep reminding yourself of the health benefits of giving up.
- If you find the cravings very difficult to resist, nicotine replacement therapies (NRTs) in the form of gum or lozenges can help wean you away from the habit of smoking cigarettes. Patches may be better at breaking the habit by replacing the nicotine craved without requiring a habitual physical action to be performed. However, all NRTs maintain a nicotine dependence that you will eventually have to break if you genuinely want to stop smoking.

Most major respiratory diseases are those that affect the lungs, sometimes starting as milder conditions higher up in the respiratory tract. The main causes are certain infections, inhaled particles of proteins and dust that affect the lungs, accidentally inhaled objects like particles of food, and cancers. Some lung troubles soon clear up but others progress or

leave damage likely to be extended by later attacks. In certain conditions the lungs become so ineffective that untreated patients die from lack of oxygen—they suffocate. Fortunately self-help, antibiotics, and surgery can now prevent or minimize the effects of some lung diseases that were once usually fatal.

Serious respiratory problems

These problems can have serious consequences, but early treatment may help to minimize their effects.

1 Asthma narrows the airways of the respiratory system (see page 35).

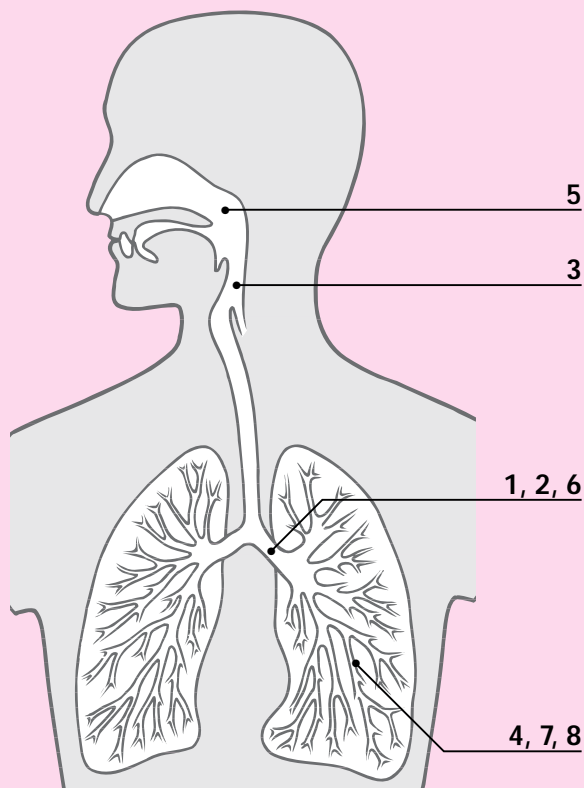
2 Whooping cough occurs when the germ *Bordetella pertussis* attacks the bronchi, inflaming lung tissue and producing thick fluid that hampers breathing.

3 Choking is often caused by inhaling a foreign body. Many a life has been saved by striking the victim sharply several times between the shoulders, or by using the Heimlich maneuver.

4 Tuberculosis is a bacterial infection of the cavities in the lungs, with potentially fatal results. However it can be treated very effectively by modern antibiotics.

5 Influenza occurs when a virus invades the respiratory system, producing a running nose, sore throat, cough, general aching, and other symptoms. Bed rest, painkillers, and plenty of fluids to drink are usually treatment enough. Younger, older, or weaker patients should contact their doctor.

6 Bronchitis is inflammation of the bronchi, causing the coughing up of yellow sputum (see opposite).




7 Pneumonia is inflammation of the lung due to infection; parts of the lung fill with fluid and become airless. Lobar pneumonia affects one or more lung lobes; bronchopneumonia affects both lungs in a patchy way (see opposite).

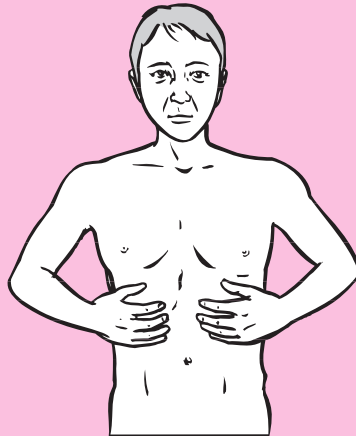
8 Lung cancer—see page 92.

People at risk

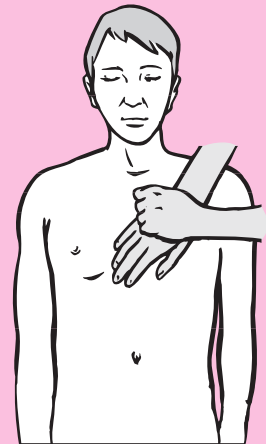
The very young and very old are especially liable to serious respiratory troubles. Pregnant women who smoke may give birth to babies with respiratory diseases or increased susceptibility to chest infections, or even sudden unexplained death. Children who catch whooping cough or measles, or accidentally inhale such things as peanuts may suffer permanent lung damage. Untreated sinus or tonsil troubles may lead to chronic bronchitis. Anyone who is overweight or smokes is more at risk.


**Treating bronchitis**

In an acute attack stay in bed in a room with warm but not dry air, until body temperature is normal. Antibiotics and a soothing inhalant help; use a cough suppressant only for an irritating, unproductive cough. Treat aches with analgesics that do not irritate the stomach. Chronic bronchitics can practice breathing when sitting relaxed with fingertips on the lower rib cage. Breathe out and feel your rib cage sink below your fingers. Breathe in and feel the rib cage rise. Practice controlled breathing for several minutes.

**Treating pneumonia**

Severe pneumonia needs hospital care. Antibiotics help in treating lobar and bronchopneumonia. The patient sits up in bed in a well-ventilated warm room, at first taking only bland fluids. Postural drainage (lying tilted with the affected part of the lung uppermost) may assist coughing up sputum. So may percussion—placing a hand on that part of the patient's chest and pressing it smartly with a clenched fist. Similar treatment aids lung abscesses, bronchiectasis, and cystic fibrosis.





Allergic conditions

Very common substances can cause distressing allergic reactions in sensitized people. The symptoms often affect the respiratory system and include swelling, redness, itching, and soreness of the membranes of the nose, throat, and airways. Causes of allergies include pollen, house dust, animal fur, chemicals, certain foods, or particular plants. The main control of allergies consists of identifying the source of the reaction and avoiding it as much as possible. Prescribed medication may help to alleviate the symptoms.



Medications

The range of medications designed to cure or relieve nose, mouth, and throat problems is enormous, and constitutes a major portion of over-the-counter medicines consumed. Some examples are decongestant sprays for the nose, mouth, and throat, various aromatic or perfumed lozenges to suck, menthol inhalants and rubs, antiseptic sprays, painkillers, catarrh remedies, and patent "cold cures." In general the fancy brand names usually contain substances that you can obtain much more cheaply in their plain generic form.

Stuffy noses

The misery of a blocked nose, with its likely side effects of headache, partial deafness, and nasal speech, may be relieved by inhaling vapor from warm water. The warmth soothes the nose and helps to clear the airways, and if medication such as menthol is added, the benefits are increased. Special vaporizers can be bought that work for several hours, such as overnight in the bedroom; these may also be beneficial for relieving bronchitis.



Hay fever (seasonal rhinitis)

This is a common allergy where the body reacts abnormally to breathed-in pollen, stimulating the release of histamine. This in turn swells blood vessels and produces a runny, itchy, blocked nose; sneezing; bloodshot eyes; and itching or soreness in the mouth or throat. Hay fever usually occurs in spring or summer when pollen is plentiful. Dust, animal dander, and other allergens have a similar but continuous effect known as perennial rhinitis.

Asthma

The narrowed airways and breathing difficulties produced by asthma attacks tend to be caused by an allergy, usually to household dust. Infection, sudden activity, or excitement may provoke an attack. Ways of preventing attacks include desensitization and avoidance of the conditions listed above. Removing pets may be necessary if animal fur acts as an allergen. Doctors prescribe airway dilator drugs as aerosol sprays, tablets, powders, or injections to widen airways and curb the output of mucus. Some treatments prevent attacks; others relieve symptoms already present.

Air pollution and respiratory illness

Atmospheric pollution and smoking are the prime causes of chronic bronchitis, a major cause of illness and death in industrialized countries. Reductions in air pollution produce a decrease in the incidence of chronic bronchitis, but an increase in smoking causes a corresponding rise in cases. People working with asbestos, silica, and other dangerous dusts may avoid potentially fatal lung diseases if they wear protective clothing and masks. If you think you are at risk, consult your workplace health advisor or doctor.

Respiratory guidance

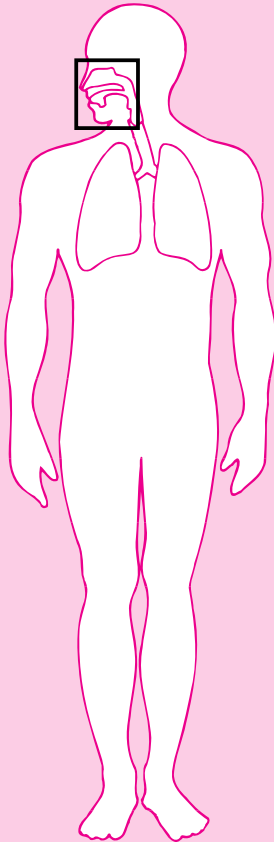
- Don't allow small children to eat peanuts, or to play with beads, or any other items small enough to be swallowed.
- Don't allow yourself to become alcoholically intoxicated; this can lead to the aspiration of food or vomit, which can be fatal or which may lead to aspiration pneumonia.
- Don't work in dusty air without a suitable mask, filter, or other breathing apparatus, especially if the type of dust present is known to be harmful.
- Don't call the doctor for a common cold or mild influenza unless the patient is old or has heart or chronic chest ailments.
- Don't enter stuffy rooms or breathe cold, damp air if you are subject to chest troubles.
- Don't ignore symptoms such as a very swollen face and mouth, paleness, and collapse that could be due to serious allergic reaction (anaphylaxis).

The upper respiratory tract (URT) consists of all parts of the respiratory airways above and including the larynx (voice box). The main sections are the nasal cavity or chamber, the pharynx or throat, and the larynx itself. The upper tract is essentially a conduit or thruway for air passing into and out of the lungs. However it also carries out several other functions, chiefly processing incoming air so this is warmed, humidified, and filtered to remove particles of floating dust and debris.

"Accessory" functions

- The upper respiratory tract is vital for life, as it is the passageway for oxygen.
- Two of its "accessory" functions may seem more important—the sense of smell, and ability to speak.

Respiratory key

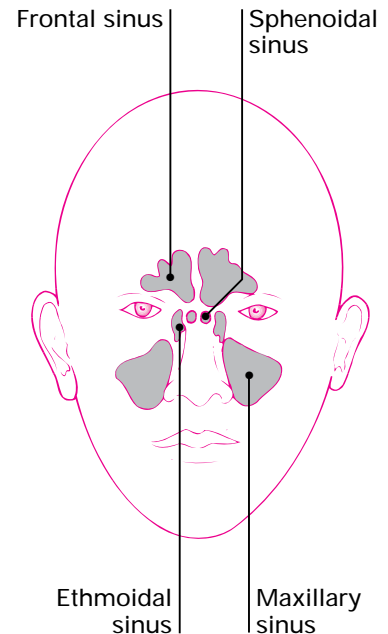


Sinuses

The respiratory or paranasal sinuses are air-filled, mucous-membrane-lined cavities within the skull and facial bones surrounding the nose. The mucus they produce drains through linking passages into the nasal cavity. There are four pairs: frontal, sphenoidal, ethmoidal, and maxillary. They are named after the skull or facial bones in which they are sited. For example, the maxillary sinuses are in the maxilla, or upper jaw bone. (See also pages 44–45.)

Functions

- Help to warm and moisten inhaled air.
- Produce mucus that helps to trap dust, microbes, and other particles.
- Lighten the skull and head by decreasing the amount



- of heavy bony material present.
- Provide resonance or amplifying chambers for speech production, giving each person's voice its unique characteristics.

Nose

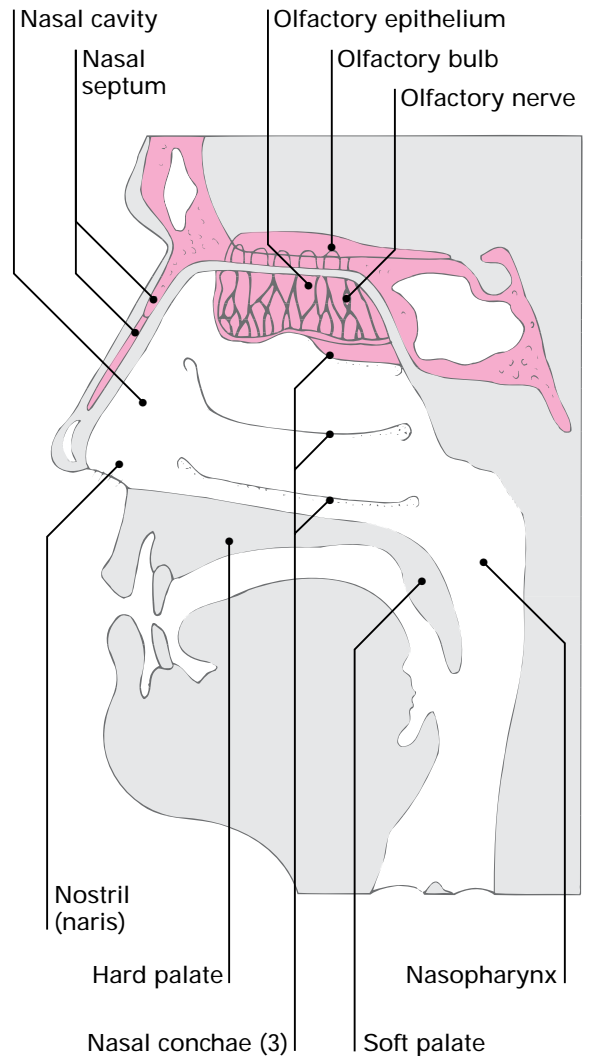
The nose is made of flesh-covered bone and cartilage (dense connective tissue).

- The nasal cavity connects the nostrils (openings at the front of the nose) to the upper part of the pharynx (throat).
- This cavity is divided into two parts, left and right, by the nasal septum (a central wall of bone and cartilage).
- Projecting from each wall of the nasal cavity are three nasal conchae (thin, shelflike plates of bone).
- The whole cavity is lined with mucous membrane (lining that secretes slimy fluid) and tiny hairs—cilia.
- The nose also contains the olfactory apparatus or epithelium, providing the sense of smell.

Functions

- The nose is a passageway for air.
- Nasal hairs trap particles and can trigger sneezing to remove them.
- Mucus traps particles and harmful substances and carries them to the pharynx, to be swallowed and destroyed by digestive juices in the stomach.
- Air traveling through the cavity is warmed by the blood in the lining.
- Inhaled air absorbs water from the mucus and is moistened.
- The conchae increase the surface area of the nasal cavity and the turbulence of air passing through it, further helping the nose to filter, cleanse, warm, and moisten air.
- The nasal cavity and its associated sinuses also provide resonance chambers for speech (see page 36).

Section through the nasal region



Pharynx

The pharynx (throat) has mainly muscular walls lined with mucous membrane. It connects the back of the nose and mouth above, with the esophagus (food tube leading to the stomach) and the larynx (voice box). (See also pages 46–47.)

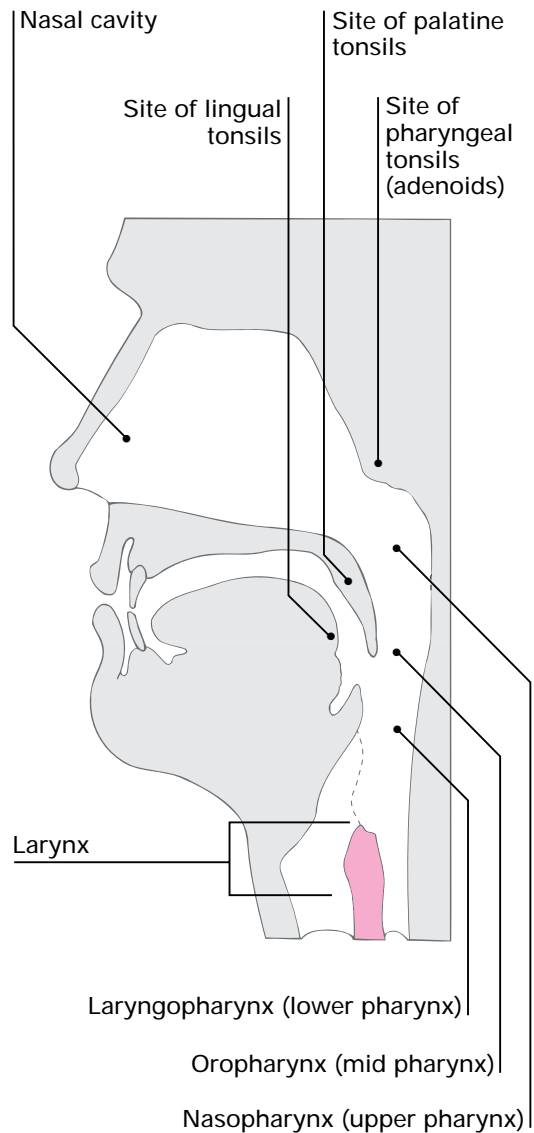
Functions

- The pharynx provides a passageway for air traveling between the nasal cavity and the larynx.
- The mucus secreted by its lining traps particles and harmful substances, and carries them to the lower pharynx. They can then be swallowed and destroyed by digestive juices in the stomach.
- The pharynx changes shape slightly to help alter vocalizations from the larynx, and especially to help form the vowel sounds of speech.
- The pharynx has a nonrespiratory function in conveying food from the mouth into the esophagus, by the process of swallowing. It is a “dual tube” for both the respiratory and digestive systems.

Tonsils

- Paired lingual tonsils are at the base of the tongue.
- Paired palatine tonsils are on either side of the oropharynx.
- Paired pharyngeal tonsils, or adenoids, are in the upper part of the nasopharynx.
- Tonsils consist of masses of lymphoid tissue and help to fight harmful microbes.

Upper respiratory tract: pharynx



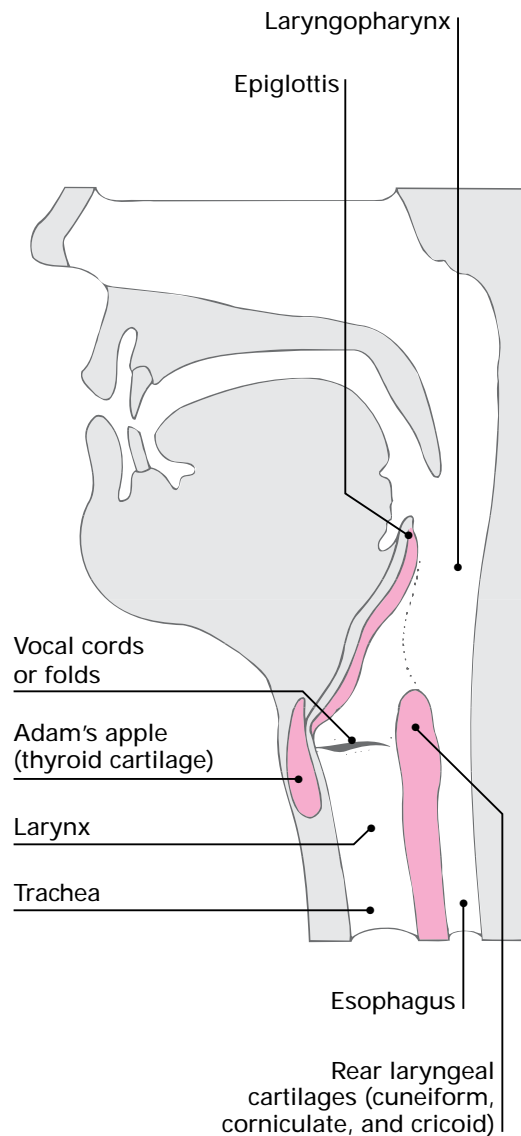
Larynx

The larynx (voice box) is mainly made up of cartilage (dense connective tissue or “gristle”) coated by mucous membranes. The largest piece of cartilage is known as the “Adam’s apple,” which, when viewed from the outside, is more pronounced in mature males than in females and children, because of the action of male sex hormones during puberty. The larynx forms an opening between the pharynx and the trachea (windpipe). Above, the larynx can be covered by a flap of cartilage called the epiglottis. Beneath the epiglottis, the vocal cords (two fibrous shelflike sheets of tissue) stretch across the larynx.

Functions

- The larynx’s main respiratory function is as a passageway for air traveling between the pharynx, and the trachea and lungs below.
- The epiglottis prevents choking by tilting back and down during swallowing, to prevent food from entering the trachea and to guide it into the esophagus.
- The larynx is also responsible for speech production (see pages 48–49).

Upper respiratory tract: larynx



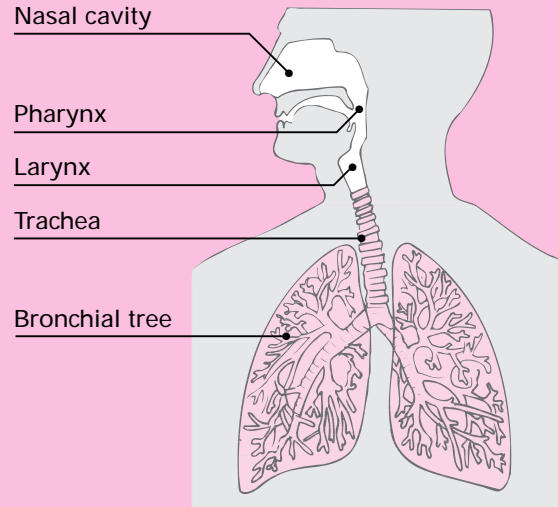
Distribution of the respiratory mucosa

The respiratory mucosa lines most of the air distribution tubes of the respiratory system. It is found in the:

- nasal cavity;
- pharynx;
- larynx (voice box);
- trachea (windpipe); and
- most of the bronchial tree of the lungs.

The density of mucus-producing glands becomes reduced as the larger airways, or bronchi, divide and become the narrower or thinner airways known as bronchioles. Mucus production is much reduced in these narrower airways.

Location of respiratory mucosal linings



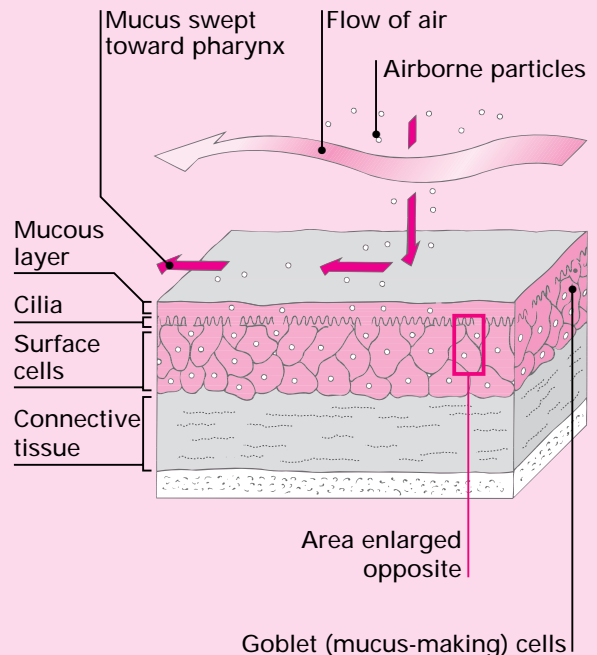
Mucosal microstructure

The respiratory mucosa consists of: a mucous layer secreted by goblet cells in the layer or lining of surface cells; millions of cilia (tiny, hairlike projections of the lining); and connective tissue lying above bone, cartilage, or muscle.

Functions

- The mucous layer cleanses the air entering lungs by trapping particles and irritants such as insects, dust, pollen, and bacteria.
- The waving or beating motions of the cilia (see opposite) move the mucus toward the pharynx (throat) for swallowing.
- Air entering the lungs is warmed and moistened by the mucous layer. The gases in humid air are more easily absorbed in the lungs.

Close-up of mucosal lining

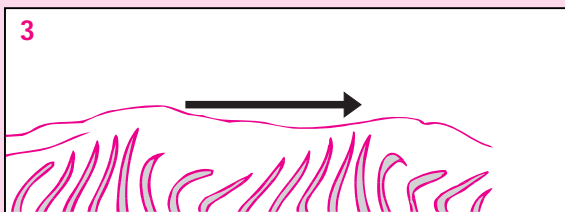
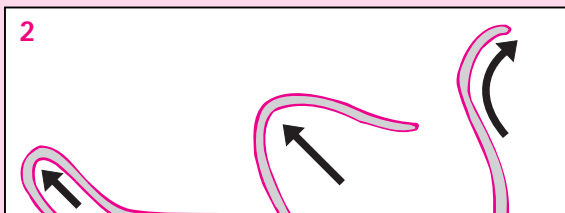
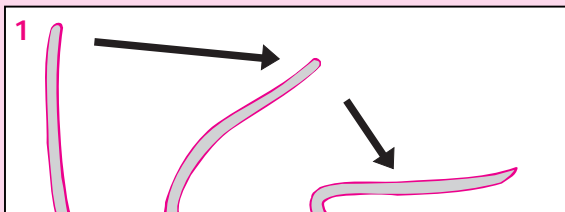


Role of cilia in the respiratory system

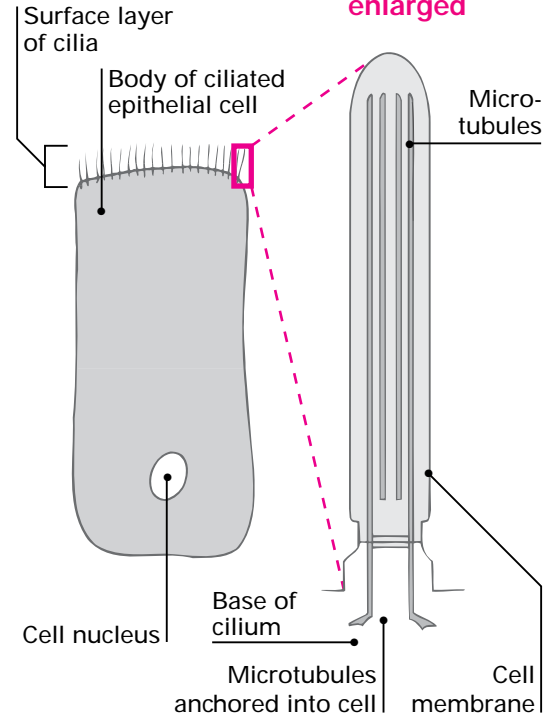
Millions of cilia (singular: cilium) line the respiratory airways. They appear as tiny, hairlike fronds on the exposed surfaces of epithelial or covering cells. Each cilium is made of bundles of microtubules (tiny tubes) covered by the cell membrane.

Functions

Ciliary wavelike movement enables them to carry matter in one direction over the cell's surface. Ciliated cells that line the airways move mucus (thick, slimy fluid) toward the pharynx (throat) to be removed by swallowing. This gets rid of the dust, bacteria, and other small items trapped in the mucus, and helps to clean and protect the lining.



Ciliated cell



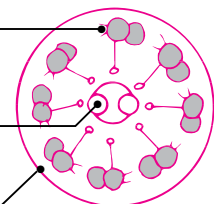
Single cilium enlarged

Cross section through cilium

9 pairs of outer microtubules

1 pair of central microtubules

Cell membrane



Ciliary motion

1 Power stroke.

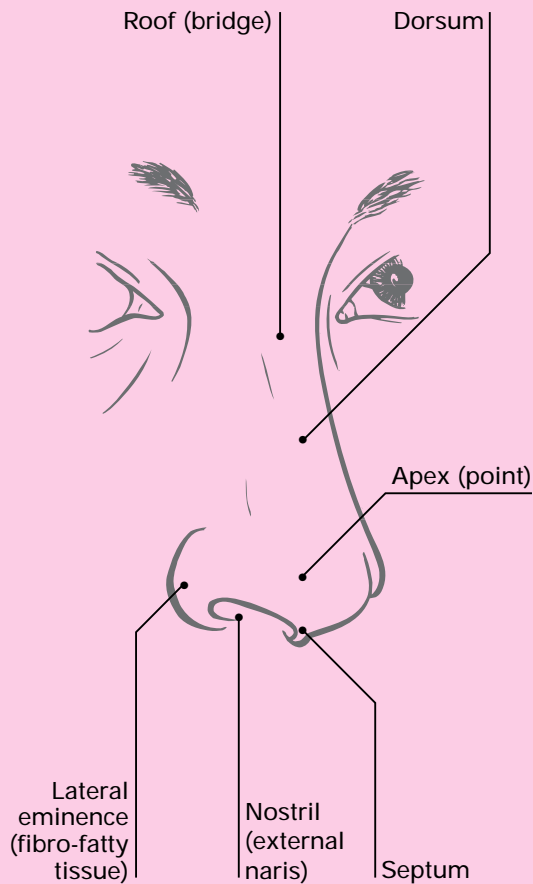
2 Recovery stroke.

3 Direction of propulsion of substance (for example, mucus) by wavelike ciliary motion.

External features of the nose

The most prominent external features of the nose are the airway openings, the nostrils. These are separated by the nasal septum, which extends upward and rearward into the nasal cavity.

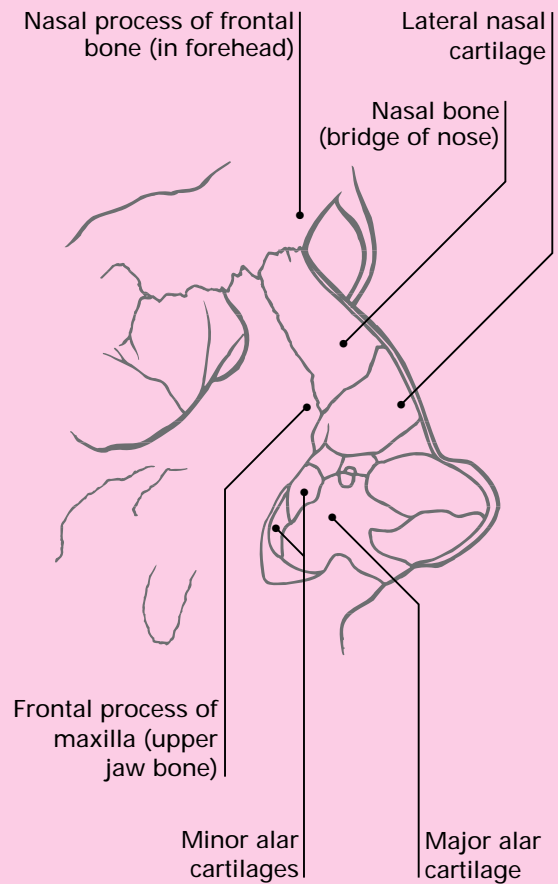
Anterolateral view of the external nose



Cartilaginous framework

The framework of the nose consists of approximately 11 curved pieces or plates of cartilage (dense, springy connective tissue or "gristle"), connected to bones and each other.

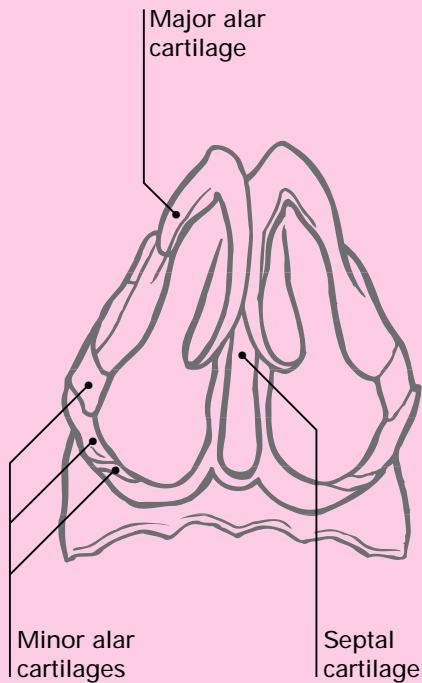
Anterolateral view of the bones and cartilages of the external nose



Nasal septum

The septal cartilage, along with bony plates of the ethmoid and vomer at the upper rear, divides the nasal chamber into two halves. Minor alar cartilages underlie the lateral eminence.

Inferior view (from below) of nasal cartilages



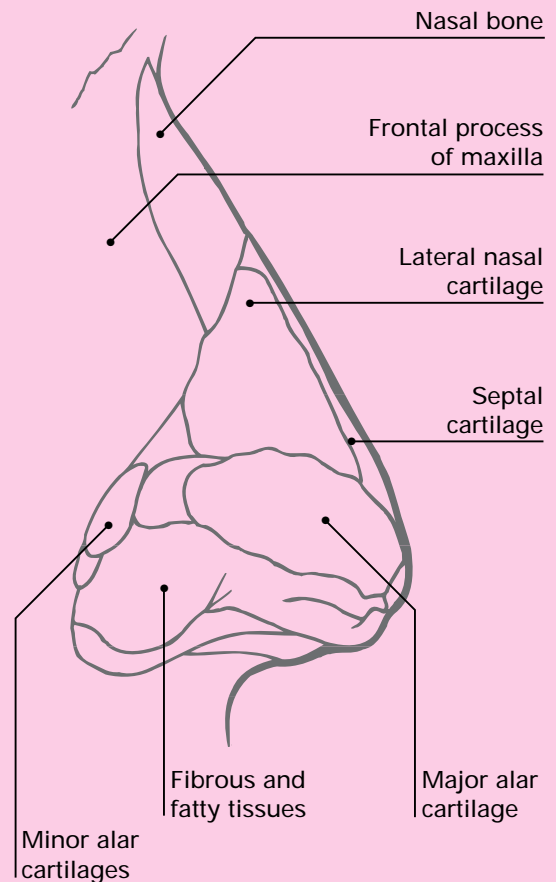
Variable number

- The number of minor alar cartilages, within the fleshy lower side of the nose, is variable. Some people have three on each side, others have two or four.

Lateral and alar cartilages

Facial muscles can pull on the nasal cartilages and tilt the major alar cartilages outward to “flare” the nostrils. This allows more air to pass through with each breath.

Lateral (side) view of nasal cartilages

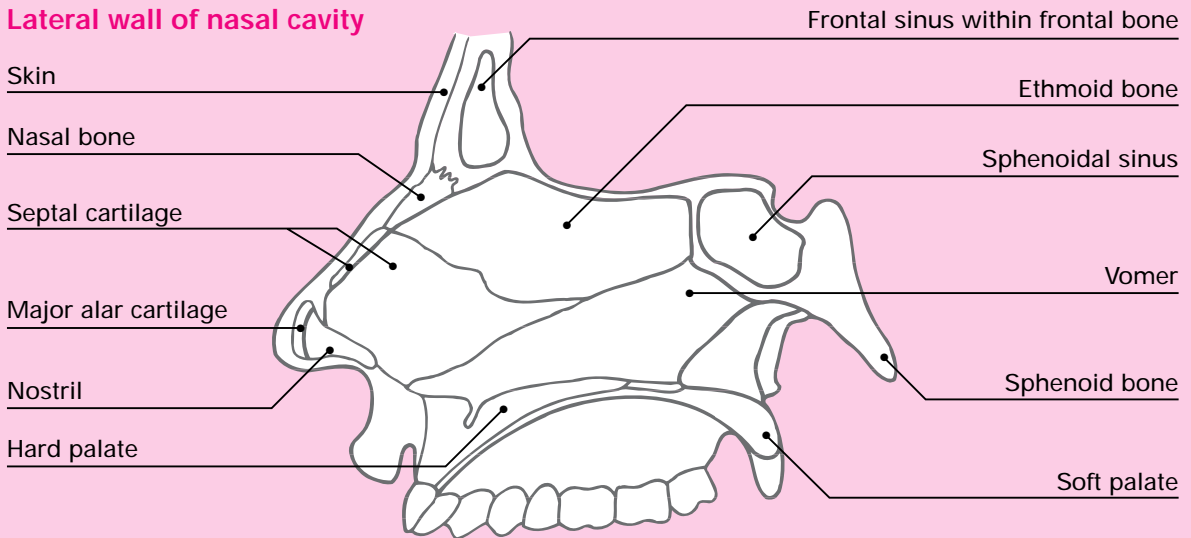


Skeleton of nasal cavity

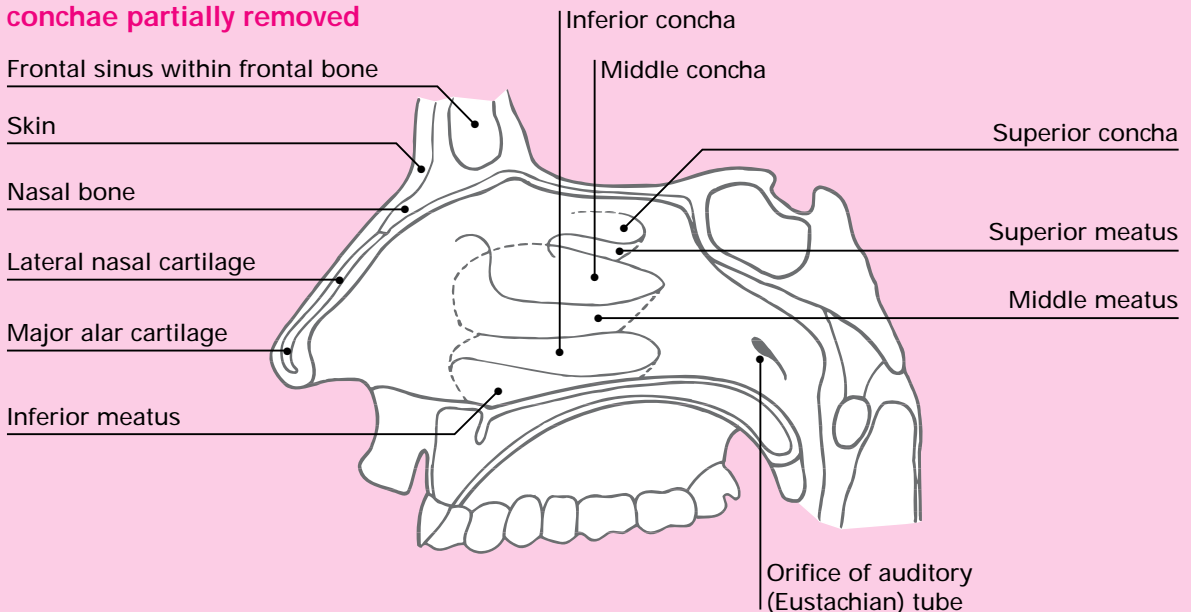
The nasal cavity or chamber is divided by a central partition composed of the septal nasal cartilage and plates of the

ethmoid and vomer (facial bones). Its sides have shelflike bony projections, conchae (see also page 37).

Lateral wall of nasal cavity



Lateral wall of nasal cavity: nasal conchae partially removed

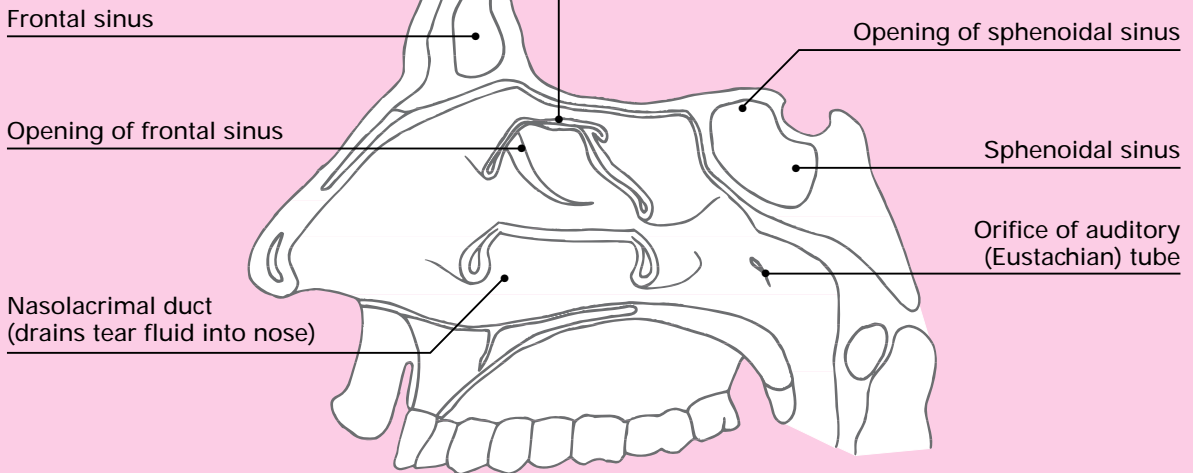


Nasal cavity and nasal sinuses

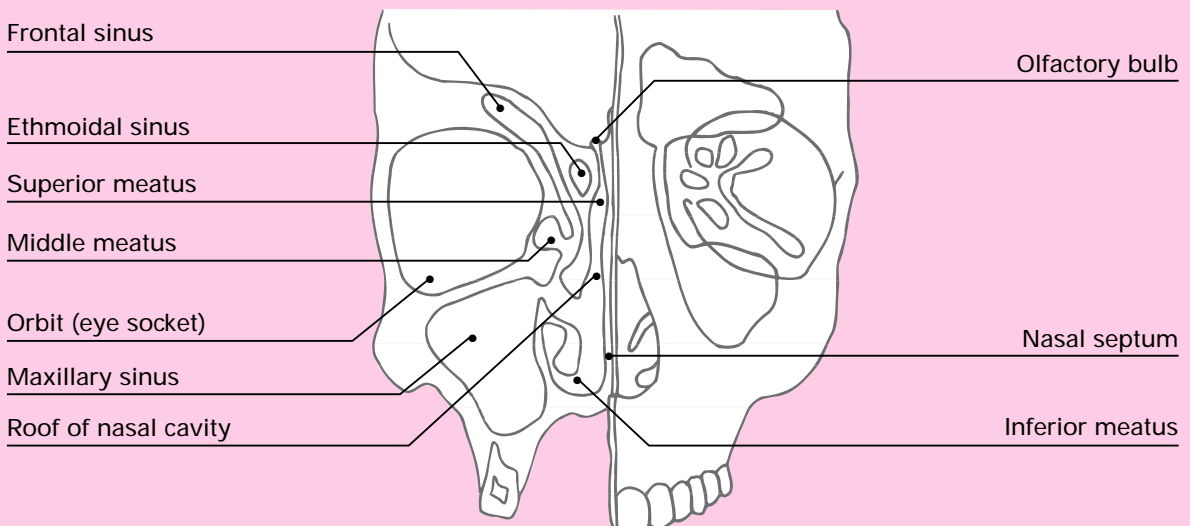
The functions of the paranasal or nasal sinuses are described on page 36. They are air-filled chambers within the bones

of the skull and face that have communicating passages or openings, foramina, into the main nasal cavity.

Lateral wall of nasal cavity showing openings of sinus



Anterior view of nasal sinuses

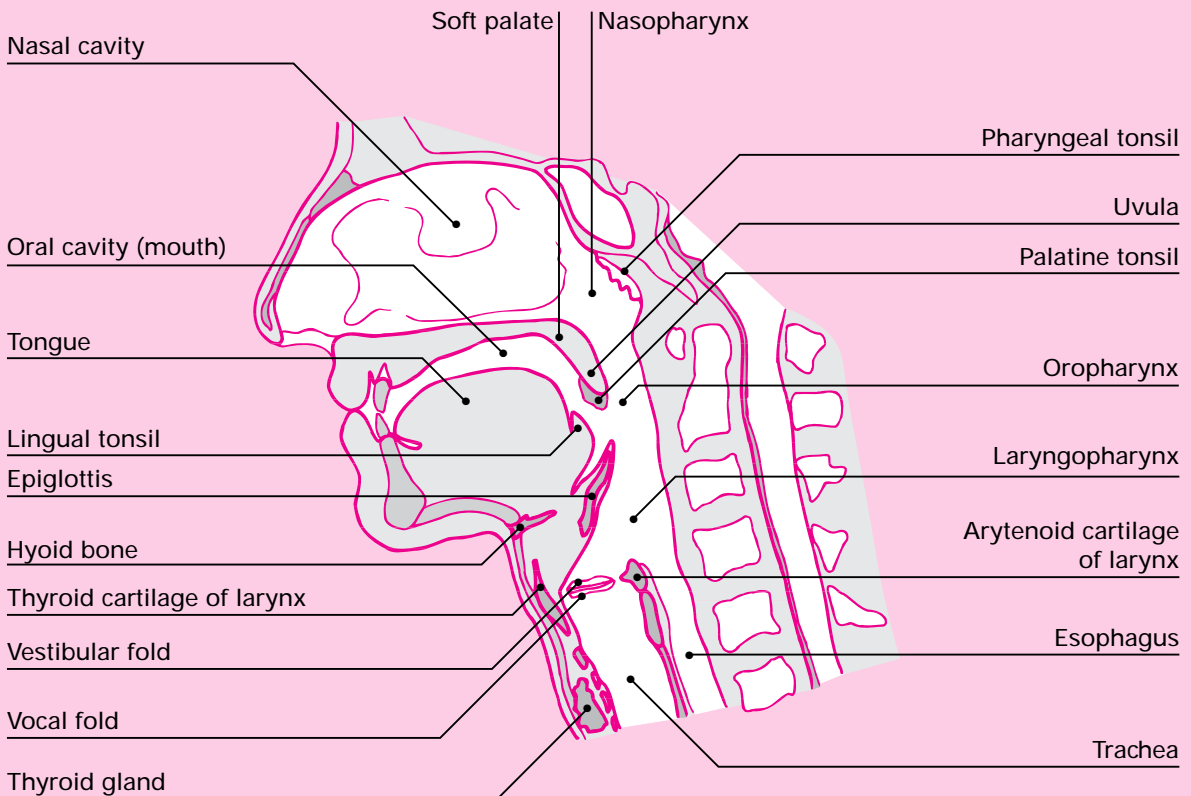


Framework of the pharynx

The dual respiratory and digestive functions of the pharynx, or throat, are described on page 39. Anatomically this region extends from the nasopharynx, at the rear of the nasal cavity, through the oropharynx, at the back of the

mouth behind the uvula, to the laryngopharynx, just above the larynx (voice box). The lower part or laryngopharynx is perhaps the part of the pharynx usually represented by the everyday term "throat."

Sagittal (midline) view of pharynx



Fast replacement

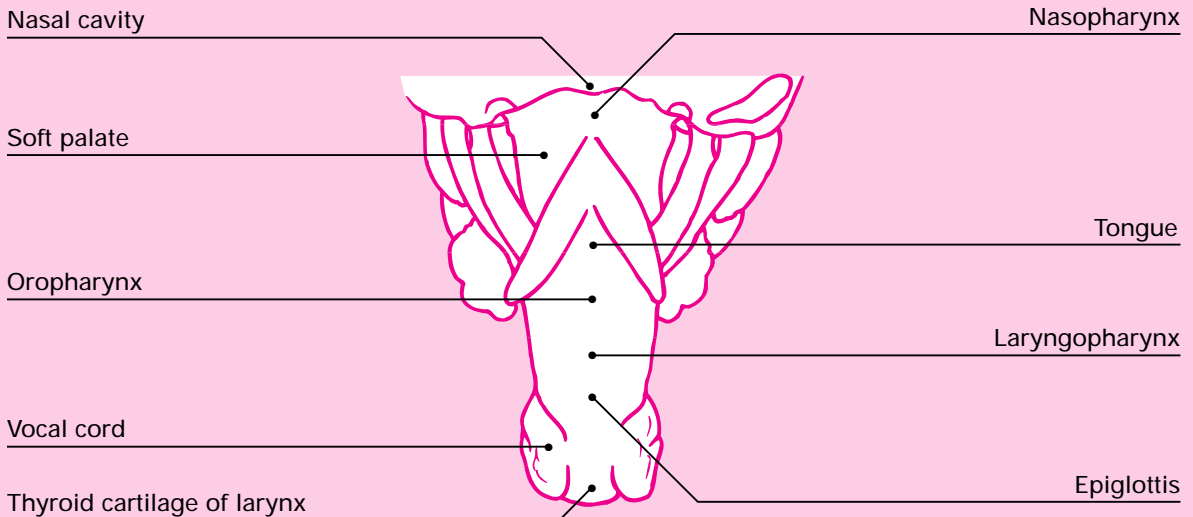
- The lining of the pharynx is one of the fastest-renewing parts of the body, with some areas replaced every 8–10 hours.

Soft tissues of the pharynx

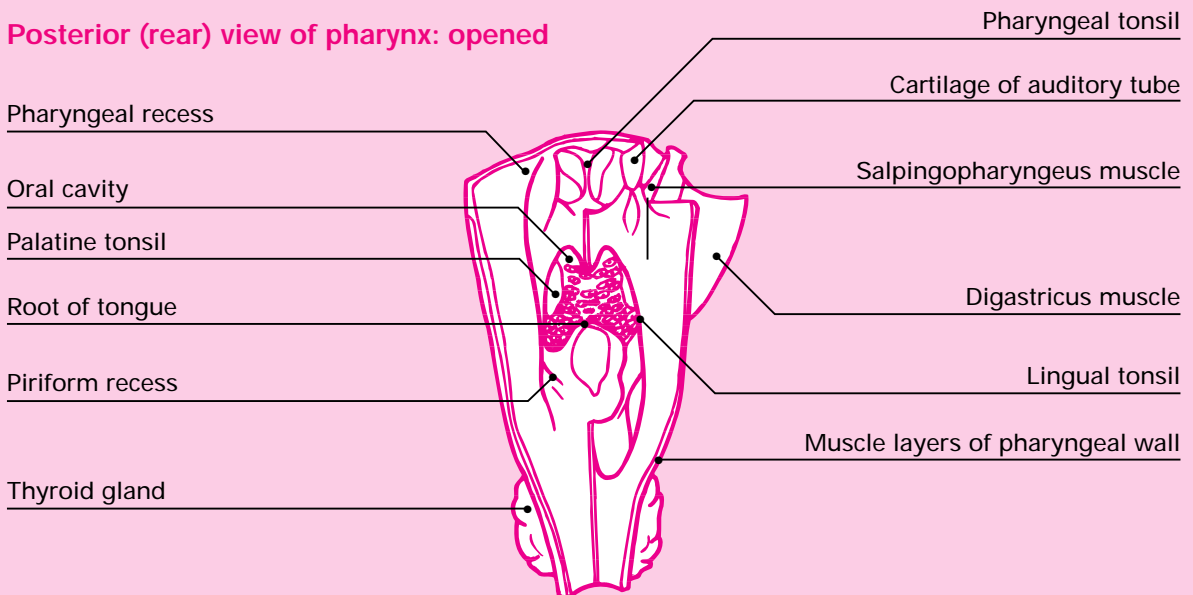
The pharynx is relatively mobile, allowing it to change shape with the contraction and relaxation of the

muscles both within its wall and around it—especially during the process of deglutination, or swallowing.

Posterior (rear) view of pharynx



Posterior (rear) view of pharynx: opened

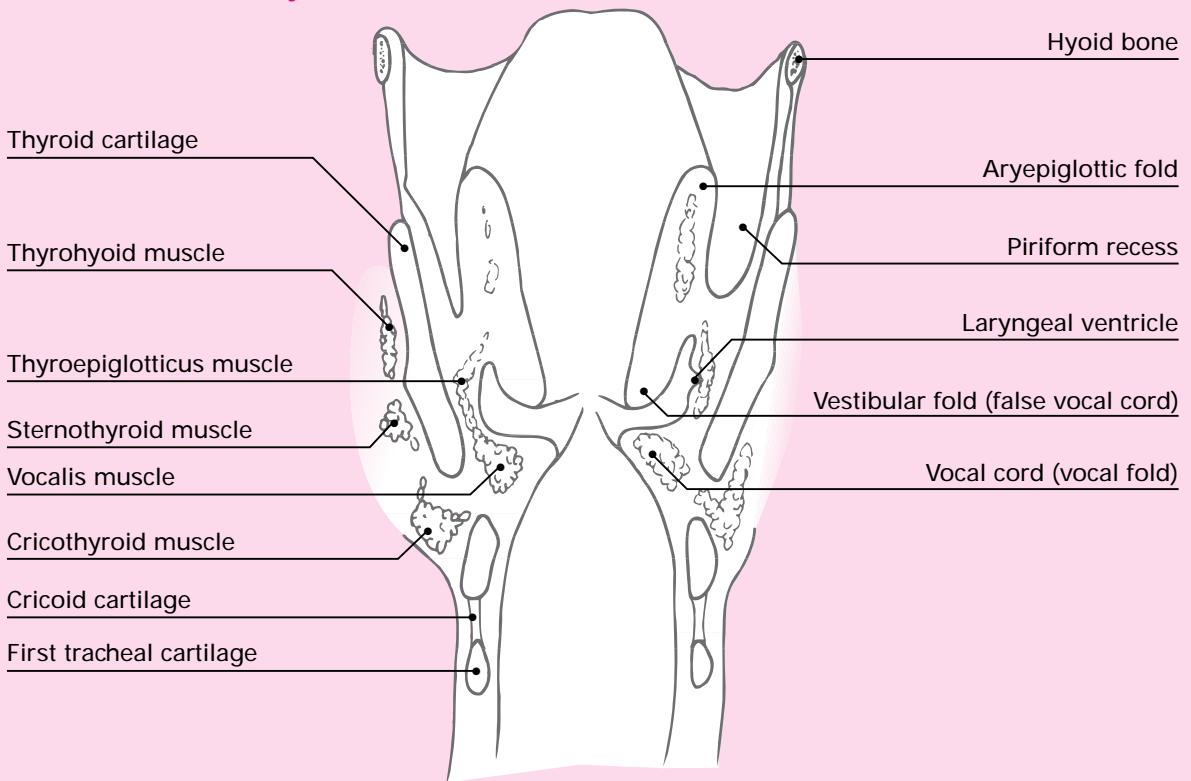


Vocalization

The main functions of the larynx are described on page 39. One of these is vocalization—the production of sounds by the vocal cords. Vocalizations range from the well-formed words of speech to murmurs, hums, and involuntary

noises such as screams, gasps, and sobs. The actual sounds from the vocal cords are relatively quiet, featureless, and “flat.” Additional tone, volume, articulation, and “color” are added by the upper parts of the tract.

Frontal section of larynx



Deeper voice

- On average, under the influence of the male hormone testosterone, the vocal folds are slightly longer and thicker in men than in women. This is why males typically have deeper voices than females.

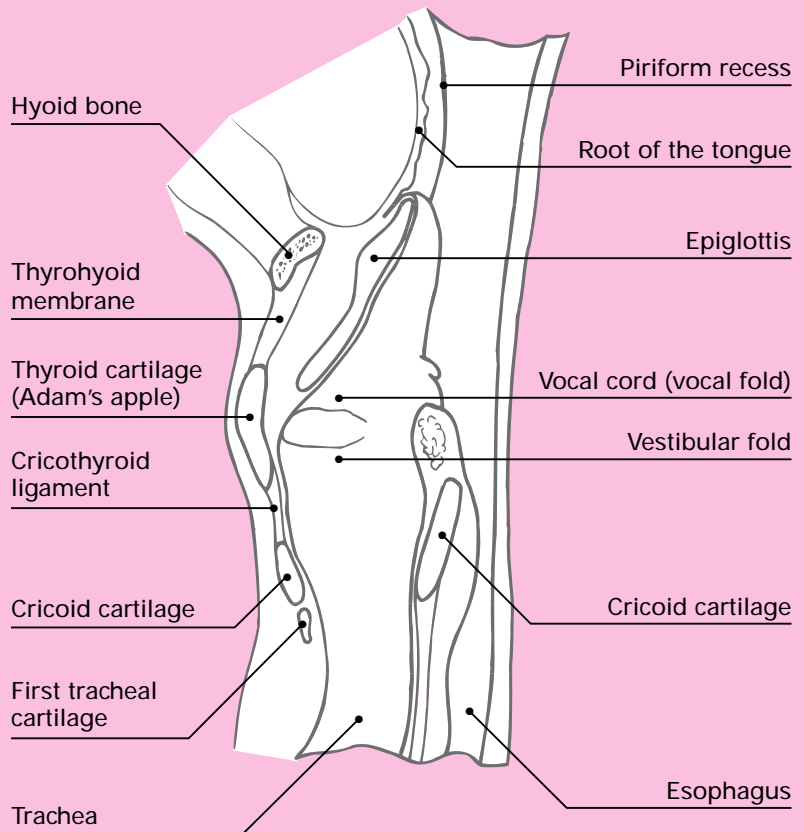
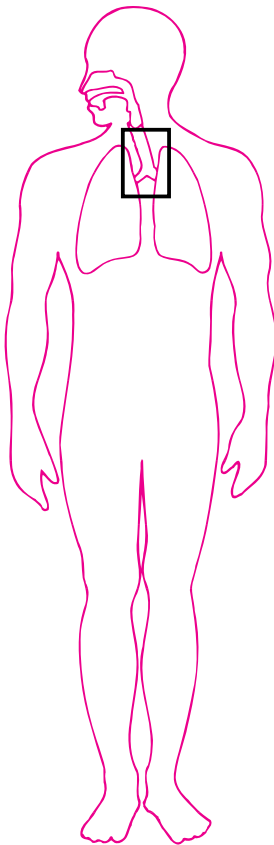
Production of sounds

Projecting from each side of the larynx is a shelflike fold of stiff tissue, the vocal cord (vocal fold). In quiet breathing there is a triangular gap between the two vocal cords, the glottis. When the

laryngeal muscles swing the cord-bearing cartilages together, the gap narrows to a slit, and air passing through makes the vocal cords vibrate. See pages 96–99 for further details.

Sagittal section (midline side view) of larynx

Locator

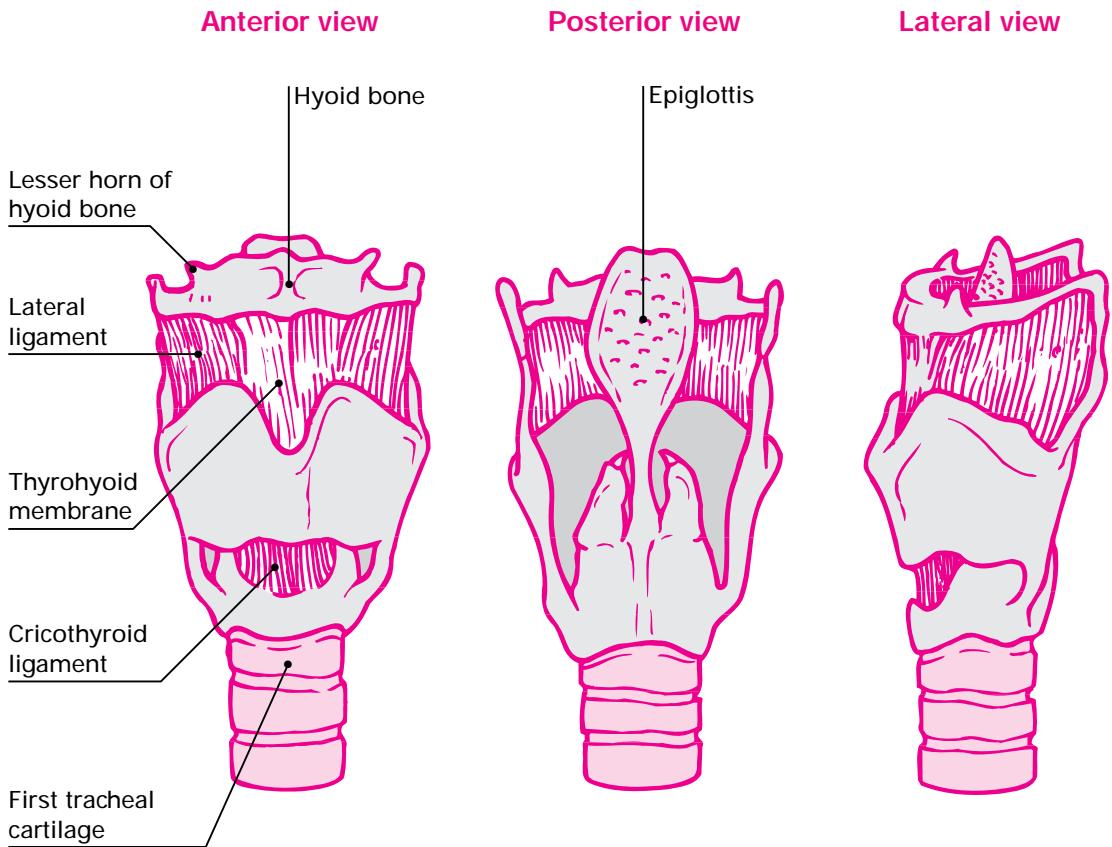


Structure of the larynx

The framework of the larynx is formed by nine curved pieces of cartilage (dense connective tissue or "gristle"). There are also two closely associated tritiate cartilages in the ligaments on either side of the larynx, and the hyoid

bone and epiglottic cartilage just above. The laryngeal cartilages are attached to each other by ligaments, muscles, and connective tissue. They move in relation to each other, usually when swallowing or vocalizing.

Hyoid and laryngeal soft tissues

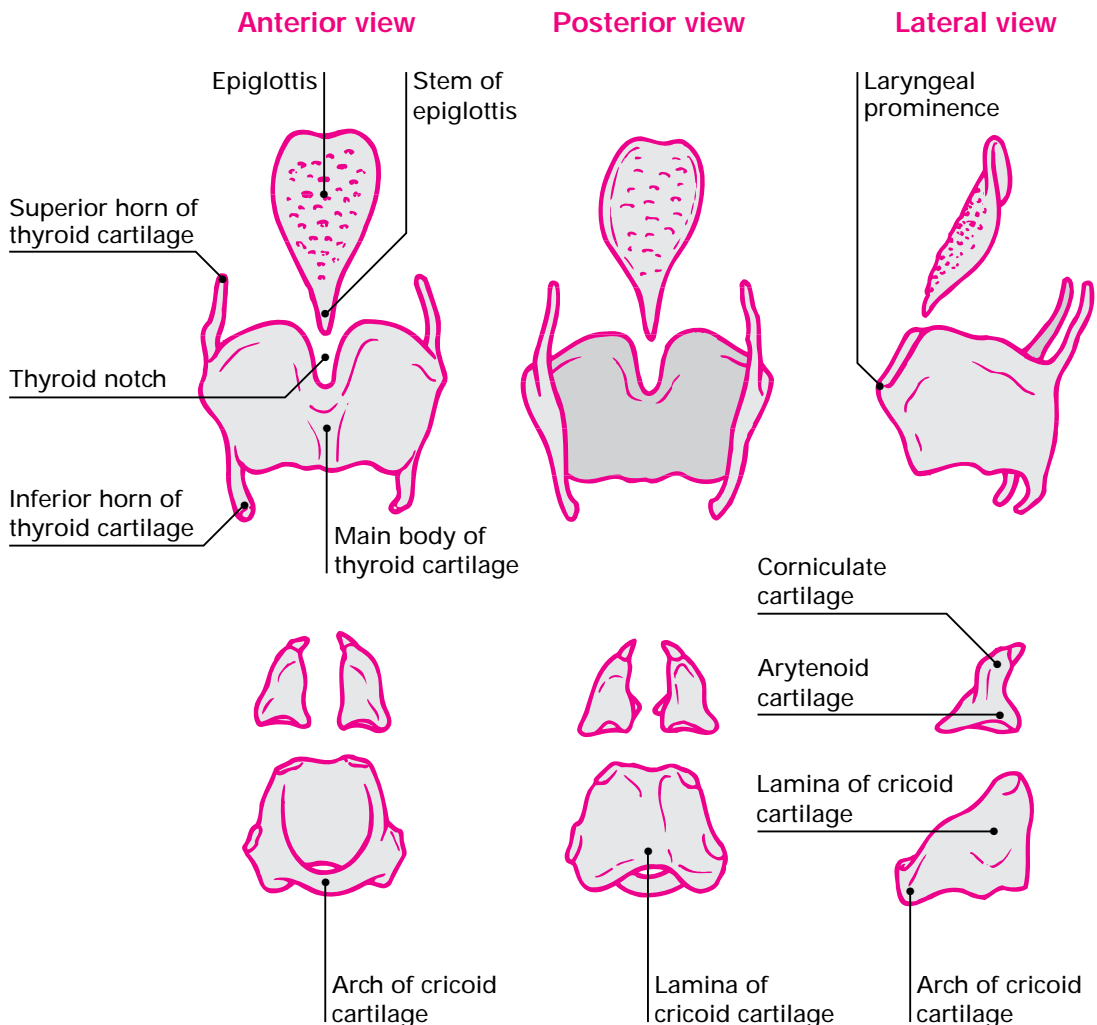


Cartilaginous larynx

The largest of the laryngeal cartilages is the thyroid cartilage (the thyroid gland is just below the larynx). This has four corni or horns. Its main

U-shape wraps around the front of the larynx and forms the protuberance under the skin known as the Adam's apple (laryngeal prominence).

Individual laryngeal cartilages



The nose and throat tend to be particularly susceptible to viral and bacterial infections. Airborne and foodborne infectious organisms have easy access, and the warm, moist mucous membranes lining the nasal and oral cavities encourage the culture of these organisms. Bacterial infections such as tonsillitis and strep-throat (*Streptococcus* bacteria) can usually be cured by antibiotics.

Most viral infections, such as common colds, cannot be cured by drugs, although the troublesome symptoms may be relieved by medications. On these pages we look at some of the infections and other problems that affect the nose and mouth, and describe some of the ways in which you can help yourself toward better health, by preventing such problems or minimizing their effects.

Nosebleeds


The lining of the nose is rich in tiny blood vessels that are very near the surface. These may easily be broken by scratching the inside of the nose, blowing the nose too hard, or being hit on the nose. The resulting nosebleed can be alarming in appearance as the nose seems to pour blood. To halt a nosebleed, pinch the lower part of the nose gently, or press the thumb against the affected side, as shown below. Hold the pressure for about ten minutes. Do not sniff or blow the nose for several hours, or you may prevent the blood from clotting. If this fails, consult a doctor promptly.



Side-effects of URT problems

The diagram here shows some of the other parts of the body that may be affected by upper respiratory tract problems.

- 1** Head: infections of the nose and sinuses may lead to headaches.
- 2** Ears: temporary deafness is a frequent side-effect of many nose and throat infections.
- 3** Lungs: mucus and phlegm from nose and throat infections may travel down into the lungs and cause coughing, or in severe cases, lung infection.



Common nasal and associated oral problems

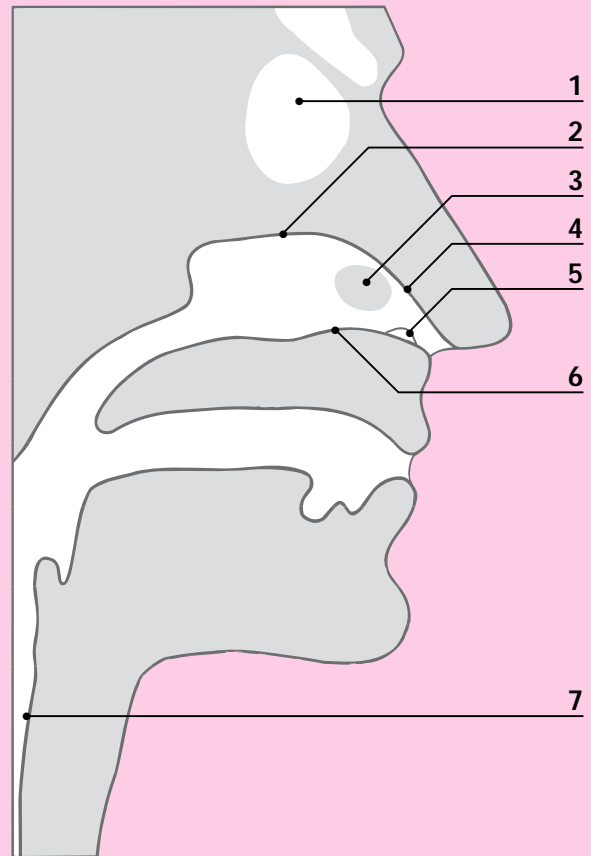
The diagram plots the location of some common problems in these areas.

- 1** Sinusitis: this condition often occurs when bacteria from a nose infection spread into the sinuses. It produces a purulent discharge from the nose. Sinusitis pain may be relieved by analgesics and applying heat to the affected area.
- 2** Inflamed nasal membranes: this condition is frequently a result of an allergic reaction, as shown earlier.
- 3** Foreign body in the nose: if a child has a blockage and discharge in only one nostril, suspect a small object is lodged there and visit the doctor. Do not try to remove the object yourself.
- 4** Nosebleed: See opposite.
- 5** Boil in the nose: this very painful condition is often caused by scratching the lining of the nostril with a dirty fingernail, pencil, etc. The boil should be bathed several times daily with twists of

cotton dipped in hot antiseptic solution, and it is wise to seek a doctor's advice.

6 Dry mucous membranes: this condition may be caused by a lack of humidity in a centrally heated home, or by an infection and fever.

7 Laryngitis: this is inflammation of the voice box. Where the vocal cords are affected, hoarseness results. Causes include infection and excessive shouting. Treatments include vapor inhalation and complete voice rest. *(Problems continued on next page.)*



Coughs

Coughs are caused by irritation of the respiratory tract, for instance by infection, inhaled food, or smoke particles. If a cough is merely tickling and mild, suppress it with a cough mixture. For a rattling cough that produces sputum, an expectorant will help clearance. Medical advice should be sought for coughs that cause pain just below the breastbone or lower in the chest, or for hoarseness that persists without apparent cause.

More minor URT problems

The sites of other relatively minor problems that can affect the upper respiratory tract are illustrated (right). Most of those that affect the trachea or above are minor, and will clear up of their own accord or with simple treatment. Some troubles that occur in the lungs are more stubborn as these parts of the respiratory system are less easily accessible.

1 Nasal polyps: See opposite.

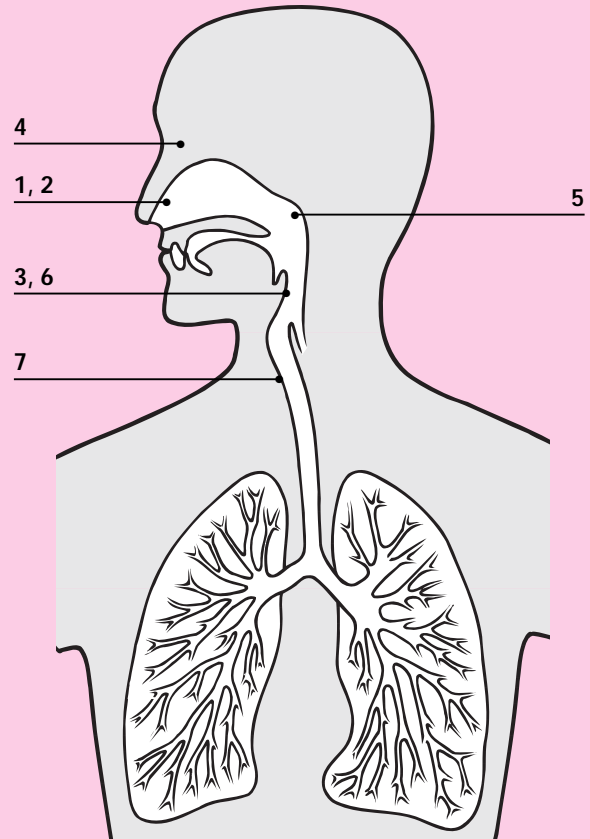
2 A nose blocked by mucus can usually be cleared by blowing the nose. If you use nose drops, make sure that they are a brand approved by your doctor, as frequent use of some nose drops can damage the linings of the nose and the paranasal sinuses.

3 The common cold virus causes sneezing, watery eyes, a watery nasal discharge, and often a sore throat. The condition usually lasts for only two to three days: See opposite.

4 Discharges from the nose with simultaneous headaches are usually caused by sinusitis (see page 53). Longterm antibiotic treatment or sinus-clearing surgery may be required.

5 Adenoids (pharyngeal tonsils), the soft masses of lymphatic tissue at the back of the nose, may become chronically enlarged in some children and cause mouth-breathing by day and snoring by night. The adenoids usually shrink back to a normal size.

6 A sore throat is usually caused by a viral infection, and is best treated by sucking lozenges that lubricate the throat with saliva. Gargling may ease



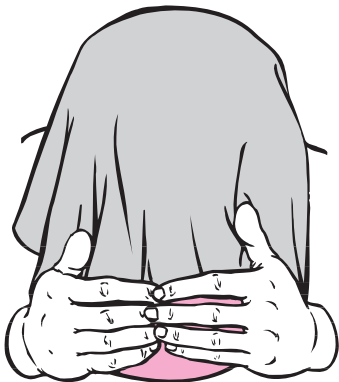
the condition. A recurrent sore throat may be linked with tonsillitis, which is inflammation of the lymphatic (disease-fighting) palatine tonsils at the back of the throat. This is treatable but may be recurrent and eventually require surgical removal of the tonsils.

7 Hiccups (hiccoughs) are caused by spasms of the diaphragm, the domed muscle below the chest. They are often cured by holding the breath briefly, applying gentle pressure to the chest, or sipping water from the opposite side of a glass (the side facing away from you).

Cold “cures”

Although much time and money have been spent in trying to find a prevention or a cure for the common cold, neither has yet been done effectively.

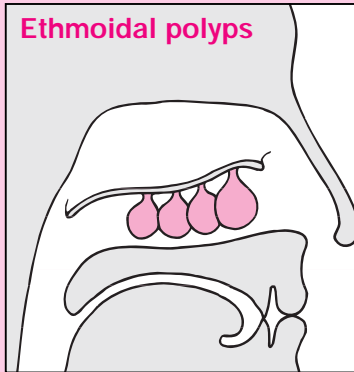
The main predisposing factor to catching a cold is low resistance due to stress, poor diet, and other illnesses. A cold will normally be self-limiting in about seven days. So-called “treatments” are usually symptom-relieving, such as inhalations with menthol or eucalyptus vapors to clear a blocked nose as shown below, and simple analgesics. Plentiful warm drinks may have a soothing effect and help to replace lost bodily fluids.



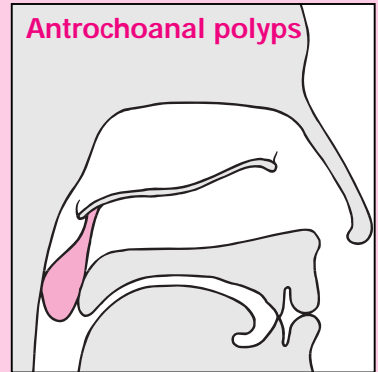
Nasal polyps

Polyps are soft growths hanging from the mucous membranes lining the inside of the nose. They are often likened to grapes on stalks, and may be smaller than a pea or larger than a real grape. They can occur singly or in groups, and develop in the roof, sides, or rear of the nasal cavity. Two common types are clusters of ethmoidal polyps in the roof of the cavity, and single antrochoanal polyps at the rear. If polyps are small, they may not produce symptoms. However if they grow large enough to block the nasal airway, for example, when they become inflamed through infection or allergy, they can be removed surgically.

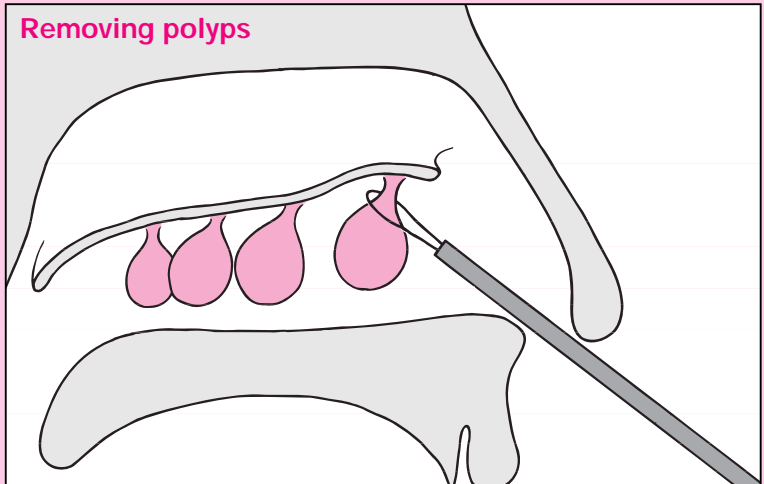
Ethmoidal polyps



Antrochoanal polyps



Removing polyps



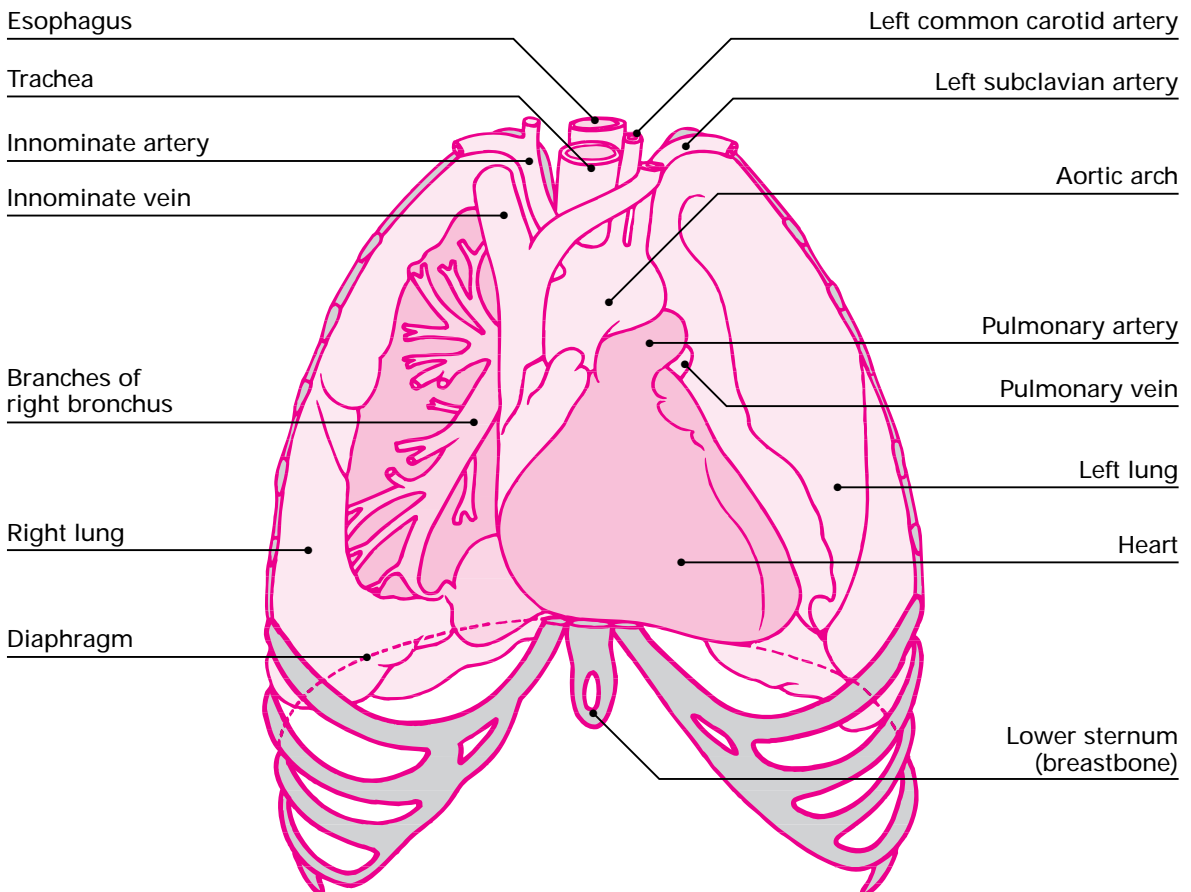
The chest, or thorax, forms the upper part of the main body or torso. It extends from the neck down to the diaphragm, the domelike sheet of muscle beneath the lungs. The chest is

a central location for organs from both the respiratory system—main airways and lungs—and the circulatory system—heart and major vessels.

Inside the chest

This view from the front shows the interior of the chest. The left lung (on the right of the diagram) has been retracted or pulled back to reveal the details of the


heart and major blood vessels. The right lung has been partially removed to show the airways and other tissues of the interior.



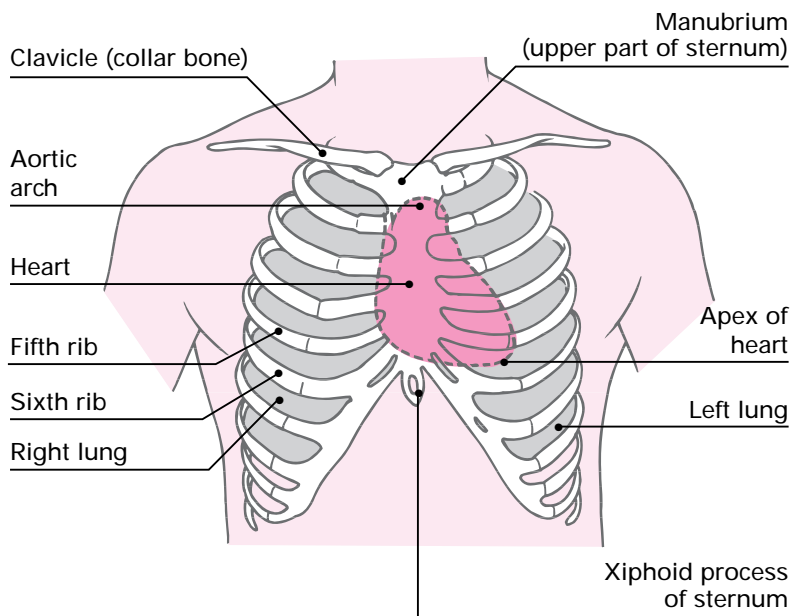
Major chest contents

The lungs are positioned on either side of the heart. The heart itself is slightly to the left of the body's midline, and tilted at an angle. So its lower tip, or apex, points to the left front, between the fifth and sixth ribs. The heart's bulk means the left lung is smaller than the right one.

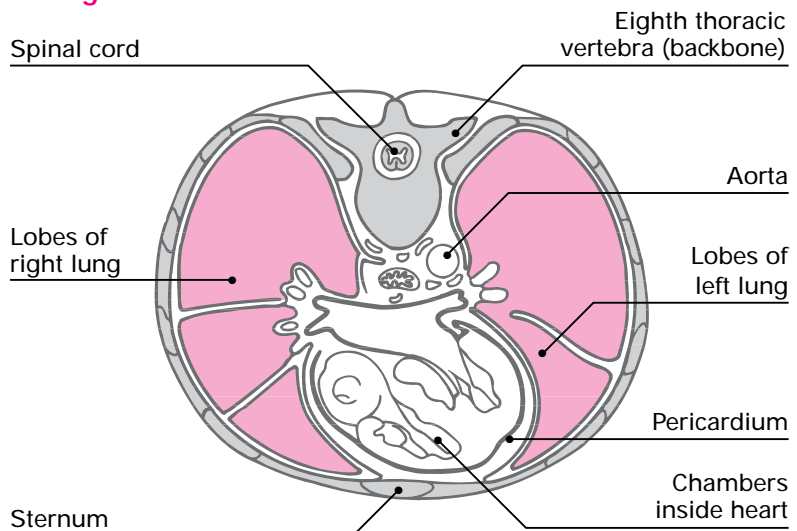
Locator



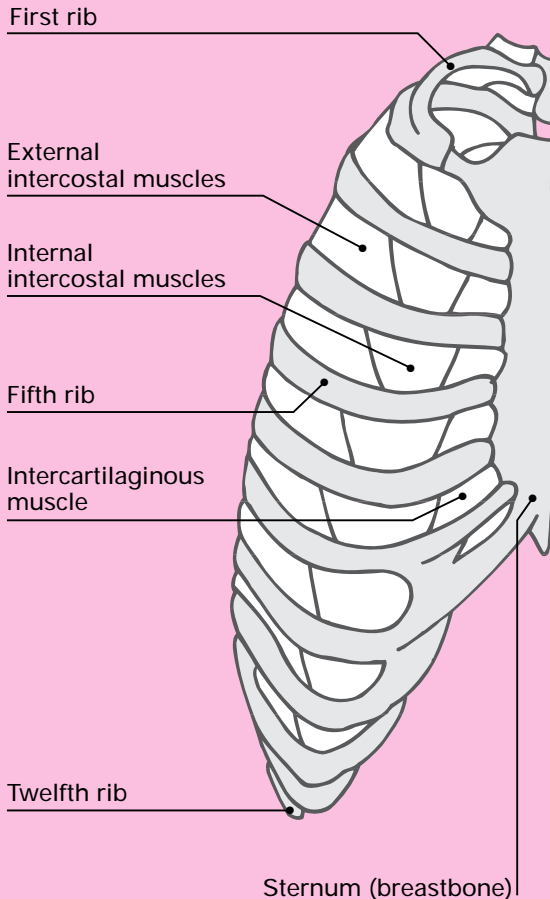
Relative position of lungs and heart in thorax



Transverse section through chest



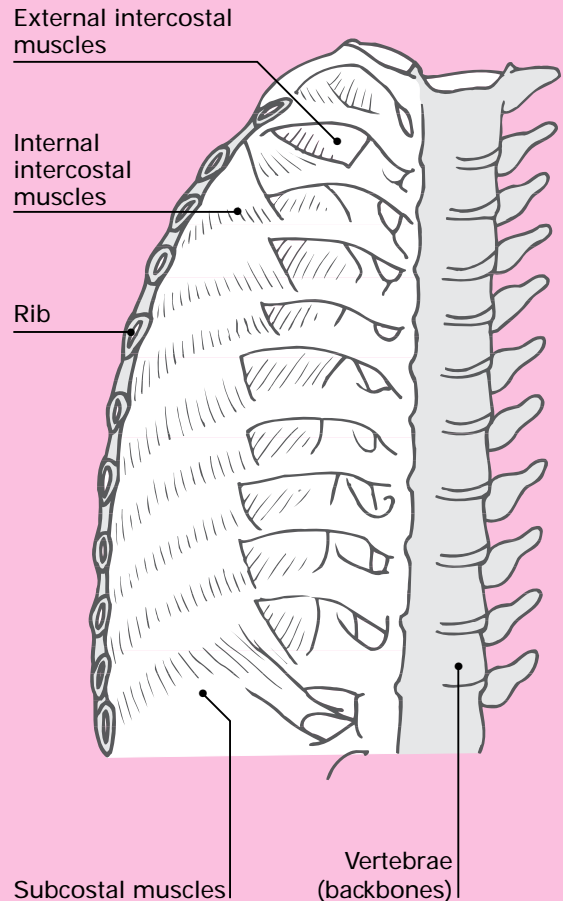
Anterior view of intercostal muscles



Muscles binding rib pairs

On either side, the intercostal muscles run between each adjacent pair of ribs (which are also known as costal bones or costae). They are long and narrow, shaped like straps, with their muscle fibers orientated vertically.

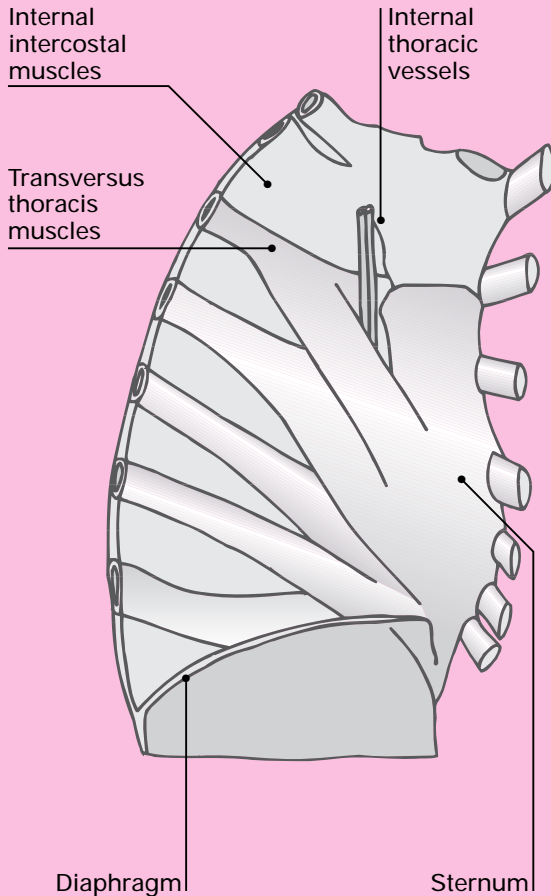
Posterior view of intercostal muscles



Rib muscles near spine

The external sets of intercostal muscles are important in breathing in, or inhalation. The internal intercostals are limited to the region of each rib near the sternum and are important in forced exhalation.

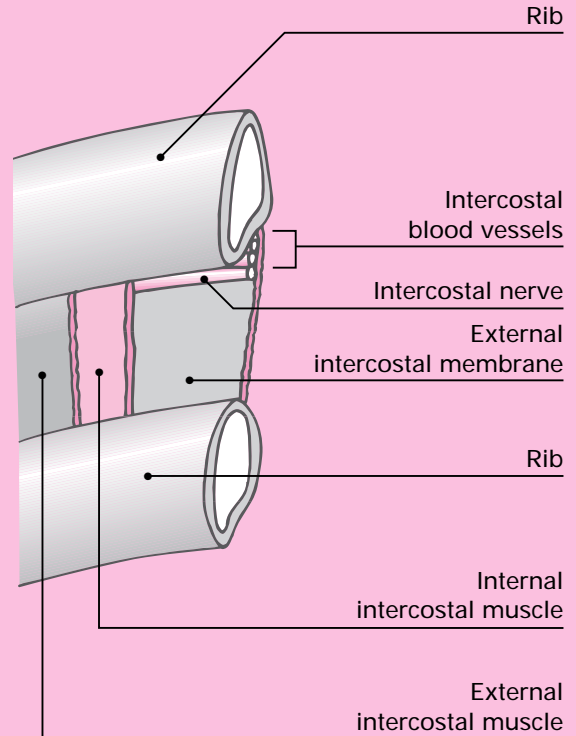
Posterior view to show transversus thoracis muscles



Muscles of upper ribs

The transversus thoracis muscles are positioned on the inside of the upper ribs, between the rib cage and the lungs. They run from the second to sixth ribs, to the sternum, and they contract to assist forced exhalation.

Close-up of thoracic wall to show ribs, muscles, vessels, and nerves



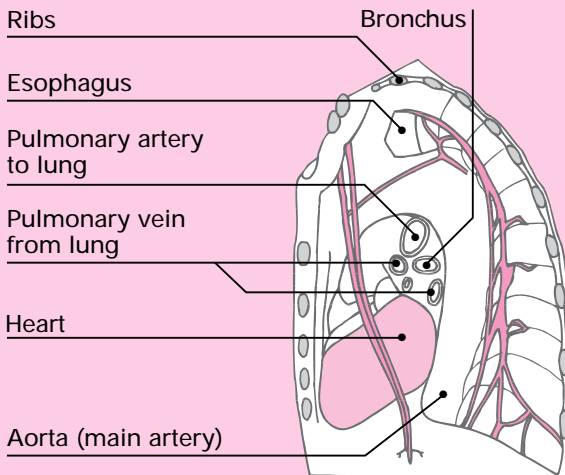
Blood and nerve supply

On either side of the chest, each pair of adjacent ribs has a similar set of muscles, nerves, and blood vessels between them, in the intercostal space. The view shown above is from inside the chest cavity.

Chest contents

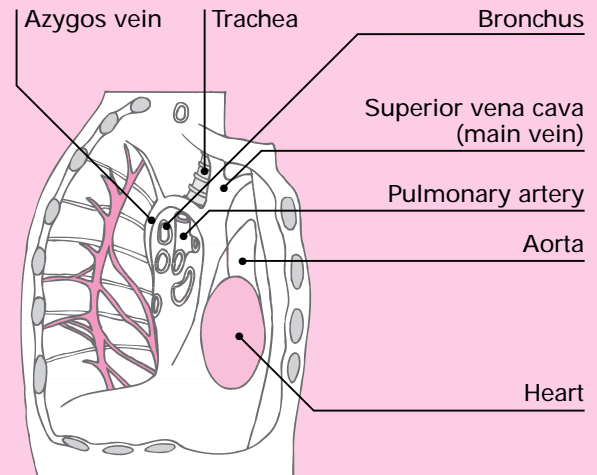
About one third of the intrathoracic volume—the space inside the chest—is occupied by the main airways or bronchi of the respiratory system, and the heart and its major blood vessels.

Lateral section: left view



The esophagus (food pipe) also travels the length of the chest (from the neck, behind the trachea) and exits through the diaphragm, conveying food to the stomach in the upper abdomen.

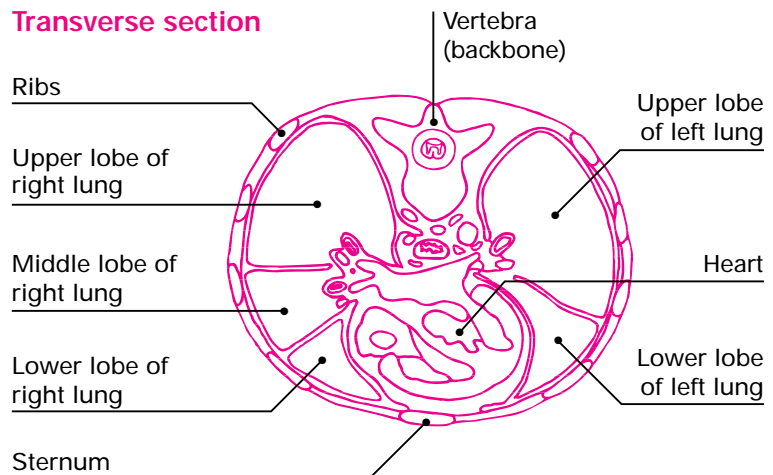
Lateral section: right view



Lung lobes

A transverse (horizontal) section reveals the lobular structure of the lungs (see pages 68–69). The left lung has two main parts or lobes, while the right lung has three. The lungs wrap around the rear of the heart and lie against the backbone or spinal column of vertebrae.

Transverse section

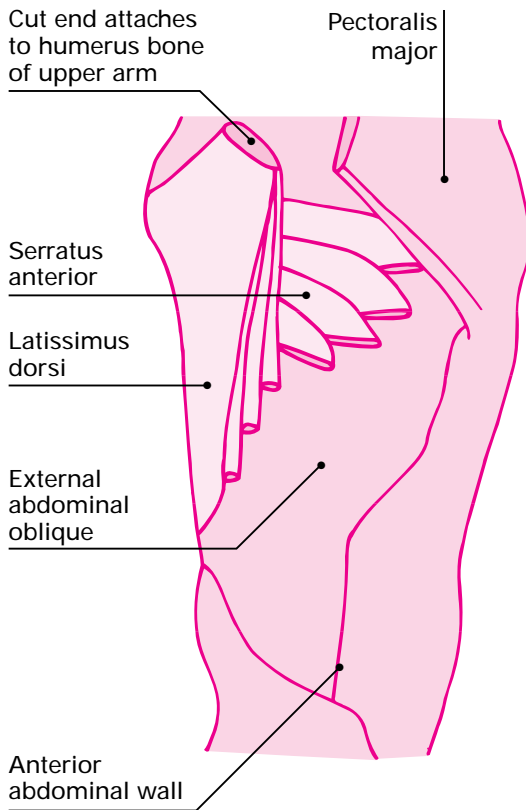


Chest and shoulder musculature

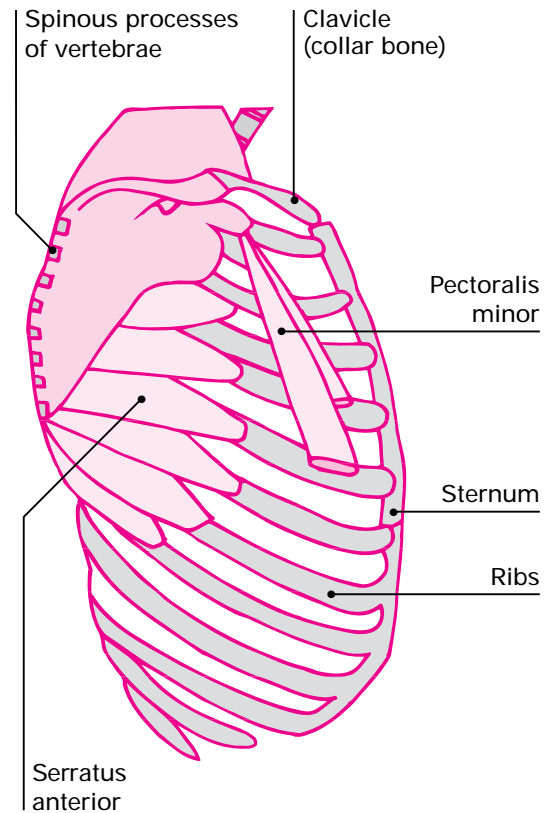
In addition to the external and internal intercostal muscles (see pages 58–59), the chest also acts as an anchorage site for muscles that move the shoulder girdle and upper arm. The latissimus

dorsi muscle pulls the shoulder and arm back and down, and also helps to twist the upper arm. The pectoralis major pulls the arm down and around to the front (see also page 65).

Lateral view: superficial muscles



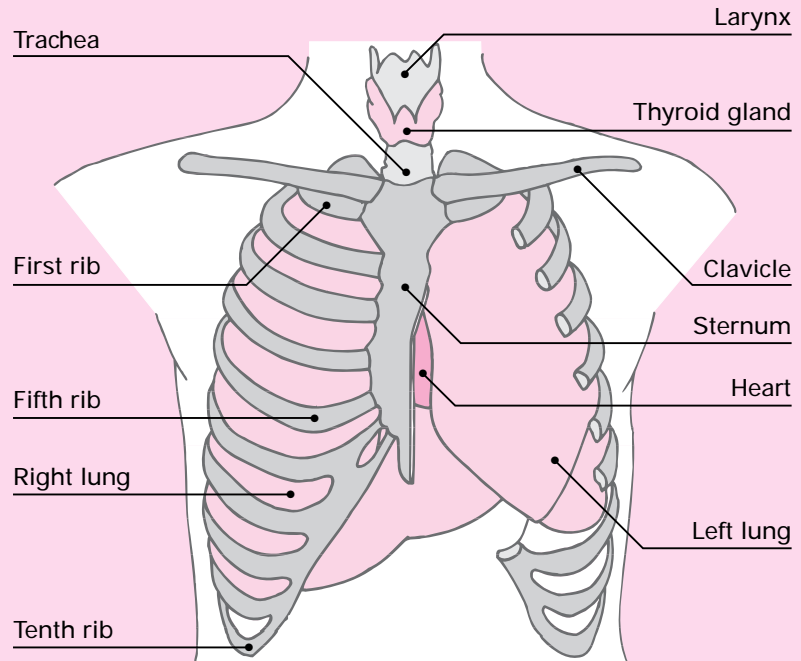
Lateral view: deep muscles



Thoracic cage

The "rib cage" is an enclosure of bones around the trachea, bronchi, and lungs, and the heart and major blood vessels. Its movements are vital for changing the volume of the lungs during breathing. The main skeletal elements of the thoracic region are the twelve thoracic vertebrae (backbones) at the rear; the twelve pairs of ribs linked to these; the sternum, or breastbone; and the associated clavicles (collar bones) and scapulae (shoulder blades).

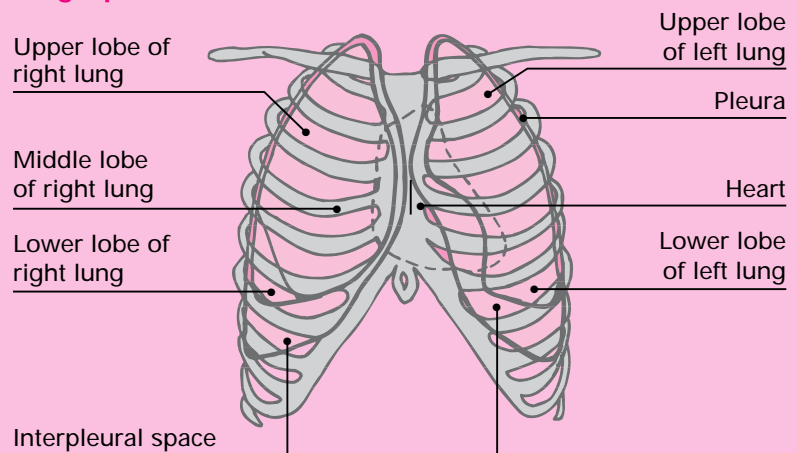
Anterior view of contents of chest



Content outlines

The major organs within the chest typically occupy set positions within the cage of the ribs. Their outlines and borders are important when examining patients, for example, by chest percussion (tapping). The pleurae are slippery membranes enveloping the lungs, which lubricate the breathing movements (see pages 64 and 65).

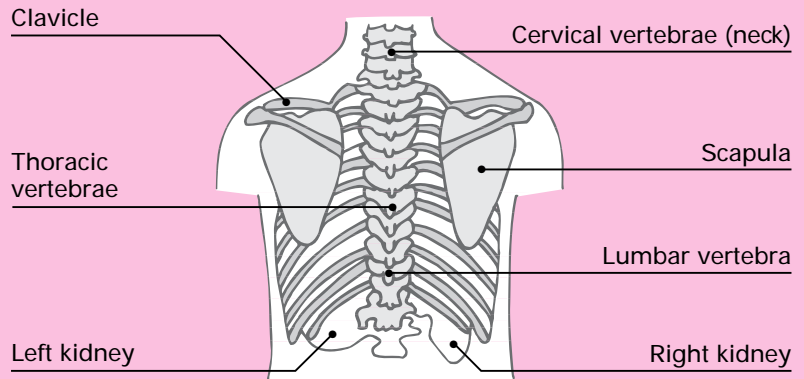
Anterior view of chest showing borders of lungs, pleurae, and heart



Spinal column

Each of the 12 thoracic vertebrae bears a pair of ribs. The lowermost two pairs of ribs, the 11th and 12th, do not arch round to the front and connect to the sternum; they are floating ribs. The upper portions of the kidneys are behind the lower ribs due to the upward dome of the diaphragm.

Posterior view of thoracic cage

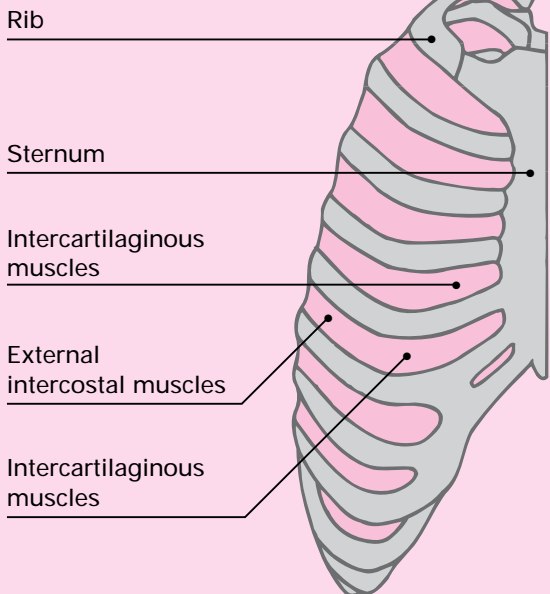


Ribs and intercostals

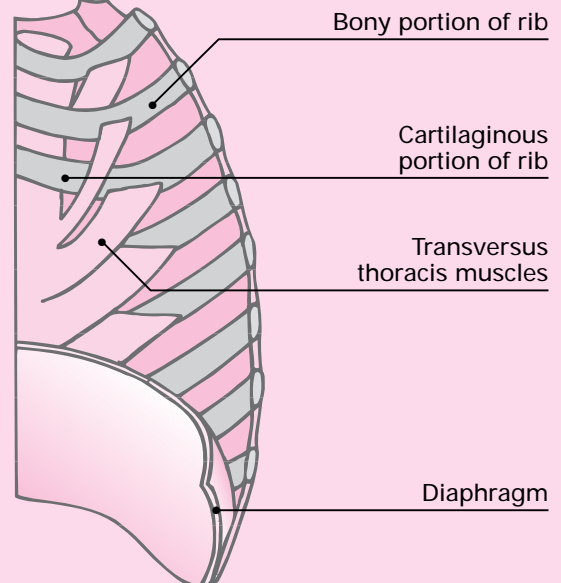
The ribs are not complete arches of bone. The portion of each rib nearest the sternum and joining to the sternum is

made mostly of cartilage, giving a flexible, springy consistency to the whole thoracic cage.

Anterior view



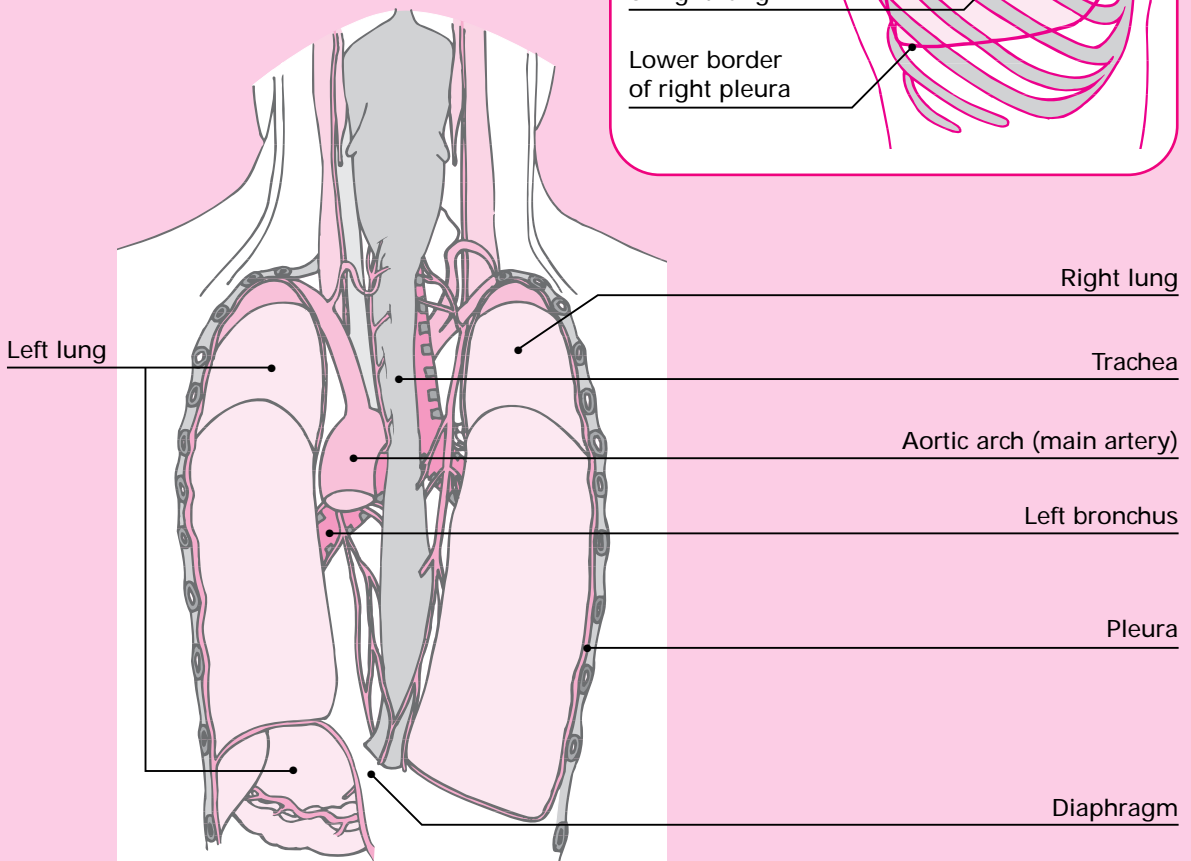
Posterior view



Lobes and pleurae

The slippery pleural membranes or pleurae both wrap around the lungs, and line the inside of the thoracic cavity (see page 74). They lubricate the motions of breathing, and their extent and condition are important in the medical examination and diagnosis of conditions such as pneumonia and pleurisy.

Posterior view of thoracic contents



Lung and pleural borders: right side

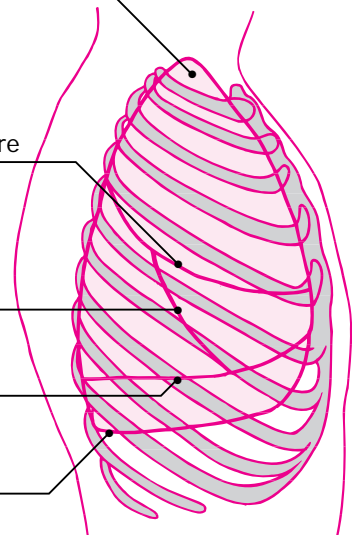Apex of right lung

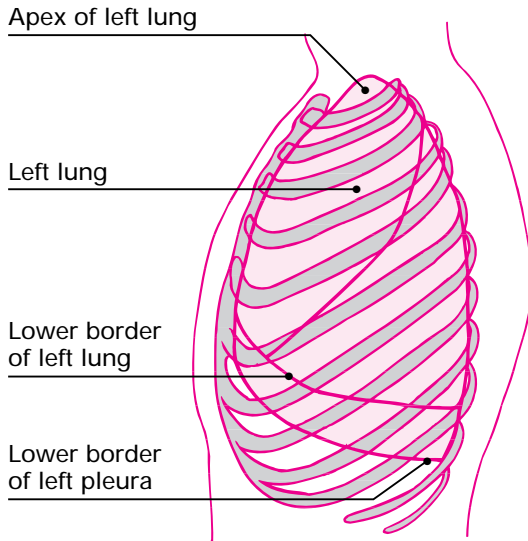
Horizontal interlobar fissure

Oblique interlobar fissure

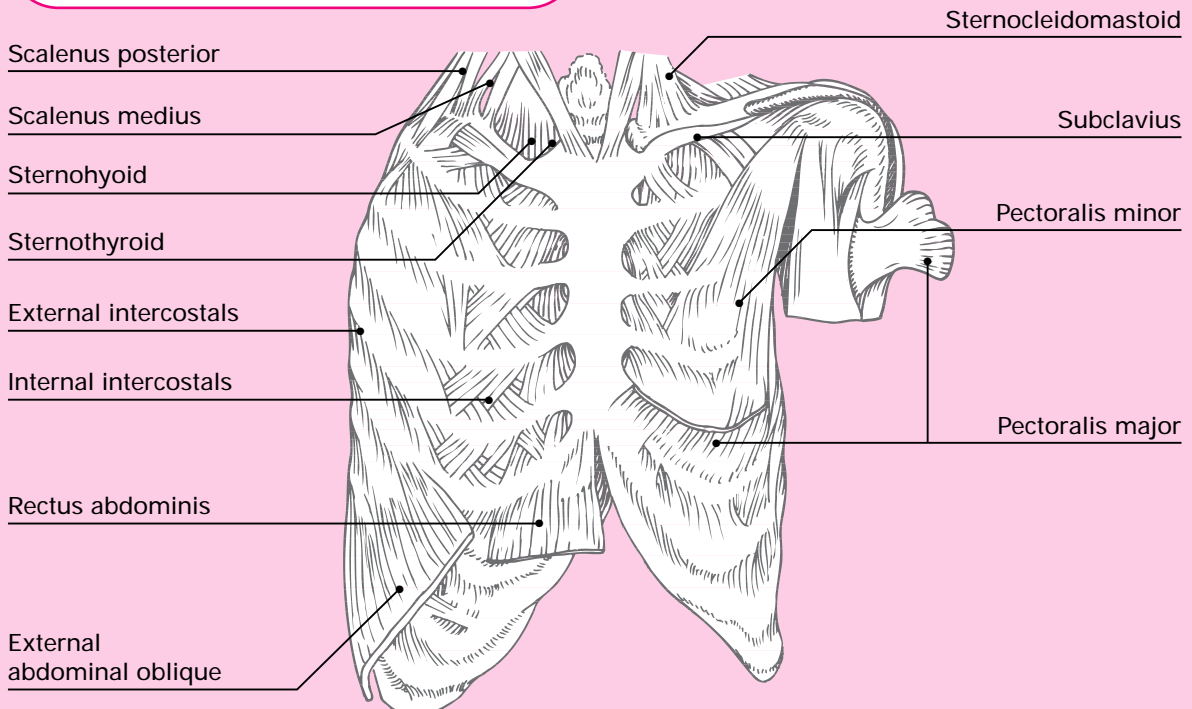
Lower border of right lung

Lower border of right pleura



Lung and pleural borders: left side**Anterior thoracic muscles**

As also shown on pages 60–61, the thorax is an anchorage area for muscles extending up to the neck and head, out to the shoulders and upper limbs, and down to the abdomen. Some of these muscles tense to provide a steadying effect during the movements of breathing. Examples include the scalenus muscles, which steady the upper ribs, and may assist in elevating them during deep inspiration. The rectus abdominis extends from the lower ribs downward to the pelvis and forms a major component of the anterior abdominal wall. ("Rectus" denotes that its muscle fibers run in a vertical or upright direction, i.e. head-toe).



Tracheal extent and structure

- The trachea (windpipe) is made up of muscle, fibrous, and elastic tissues supported by 16–20 incomplete rings (C-shaped hoops) of springy cartilage.
- It is lined with respiratory mucosa which secretes mucus and bears tiny, hairlike cilia (see opposite).
- The trachea is joined at the top to the pharynx (throat) by the larynx (voice box).
- It extends down into the chest and branches into the two main bronchi (tubes leading into the lungs).

Location of trachea

Pharynx

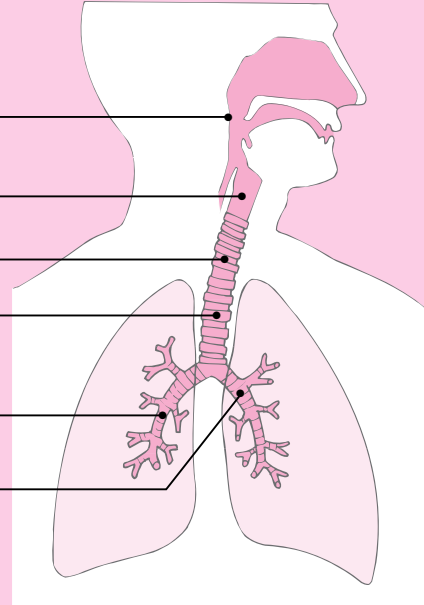
Larynx

Trachea

Cartilage hoops or rings

Right bronchus

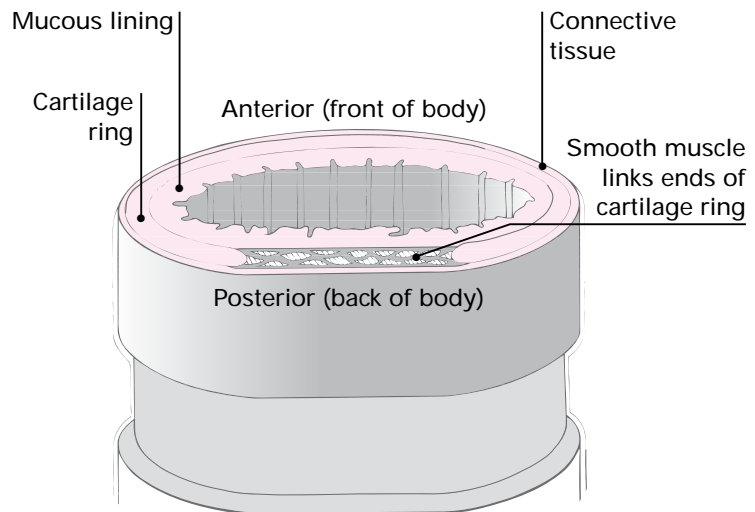
Left bronchus



Functions

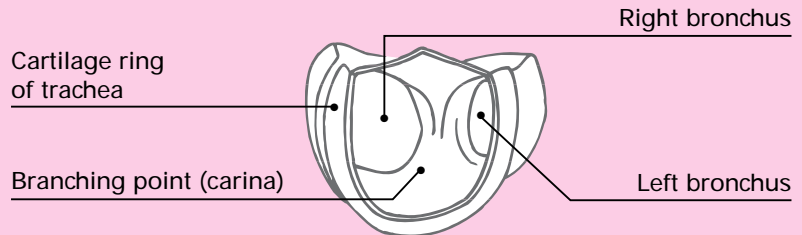
- The main function of the trachea is to act as a passageway for air between the larynx and the lungs.
- The respiratory mucosa cleanses air entering the lungs by trapping particles in its mucous layer.
- The one-way motions of the cilia move the mucus up to the pharynx for swallowing.
- Air is also warmed and moistened.

Cross section of the trachea

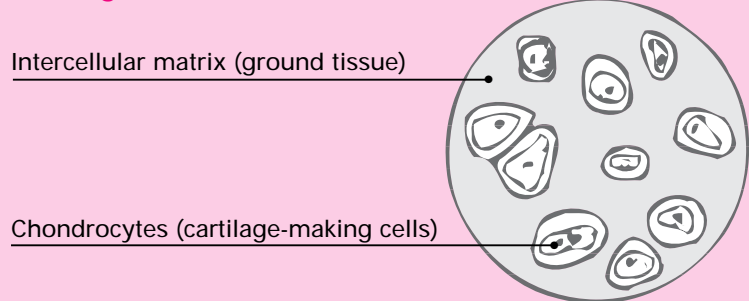


Tracheal lumen

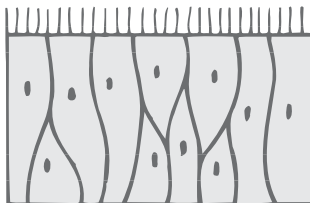
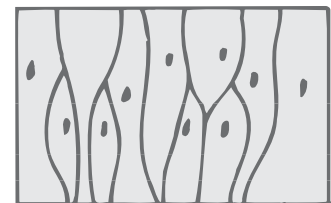
The space or lumen within the trachea is about half an inch (12 mm) wide in a typical adult male. The entire trachea is about four inches (10–11 cm) in length.

Lower trachea viewed from above**Tracheal cartilage**

The strengthening C-shape rings of the trachea and lower airways are made of hyaline cartilage. This has a flexible, springy nature and holds open the airways against the natural internal pressure of the body (intrathoracic pressure).

Cartilage detail**Epithelial lining**

The lining of the trachea is rich in microscopic hairlike cilia and mucus-producing goblet cells (see page 6). These constantly trap dust, bacteria, and other tiny items. The mucus is swept upward, and then coughed into the pharynx and swallowed when "clearing the throat."

With cilia (tiny hairs)**With goblet (mucus-producing) cells**

The two lungs are the major organs of the respiratory system. They are shaped like distorted cones with various indentations especially on their medial surfaces (those facing the midline of the body, which are joined with the central chest organs). Lung tissue is soft and spongy, and pinkish-gray in color when healthy.

Segmented structure

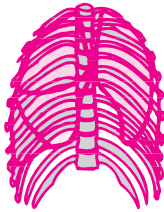
- Each lung segment is supplied by its own large airway, or bronchus, and functions as a “mini-lung”

Lungs

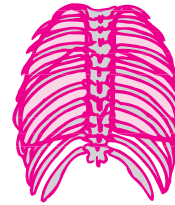
The lungs are higher in the chest than popularly imagined. The upper tip or apex protrudes above the level of the

collarbone. Due to the upward dome of the diaphragm the lung bases extend to the 9th–10th pairs of ribs.

Anterior position



Posterior position



Anterior view

Segments of right lung

Apical

Posterior

Anterior

Lateral

Medial

Anterior basal

Segments of left lung

Apical

Posterior

Anterior

Superior lingular

Superior (apical)

Inferior lingula

Anterior basal

Lateral basal

Posterior view

Segments of right lung

Apical

Posterior

Superior (apical)

Anterior basal

Lateral basal

Posterior basal

Posterior basal

Surface features

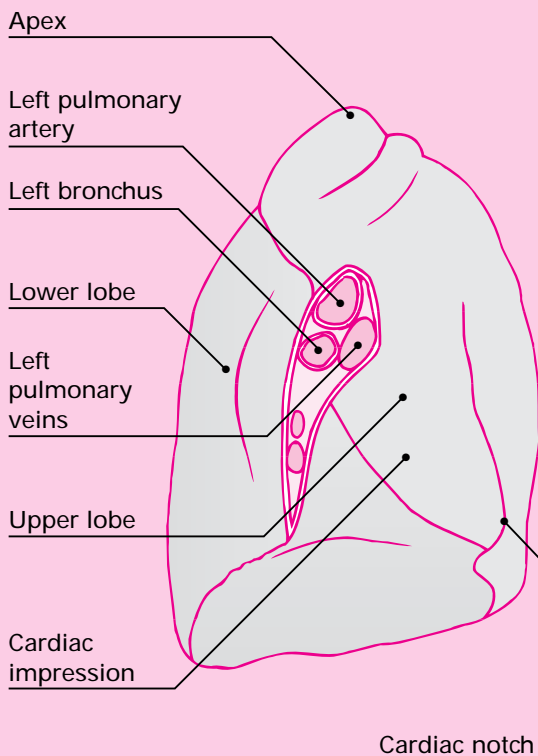
Due to the natural pressure within the chest (intrathoracic pressure), the various organs, vessels, and tubes press against the surfaces of the lungs and conform their shape. The right lung has three major parts, or lobes, while the left lung has two. Both lungs possess a cavity called the cardiac impression,

where the heart sits. Due to the heart projecting more to the left side of the sternum, this cavity is larger in the left lung.

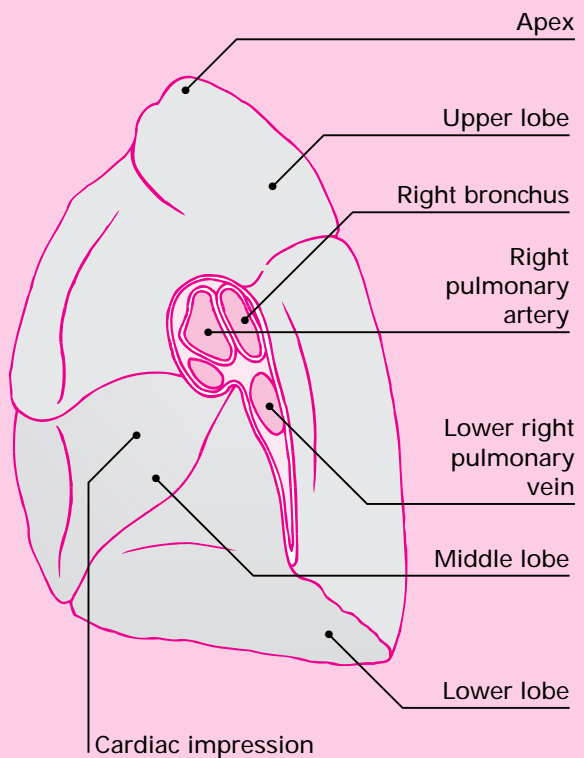
Ligaments of elastic tissue connect most of the lobes and vessels to keep these in position. All of these soft tissues move constantly with breathing.

Lung relationships and surface markings

Medial view of left lung



Medial view of right lung

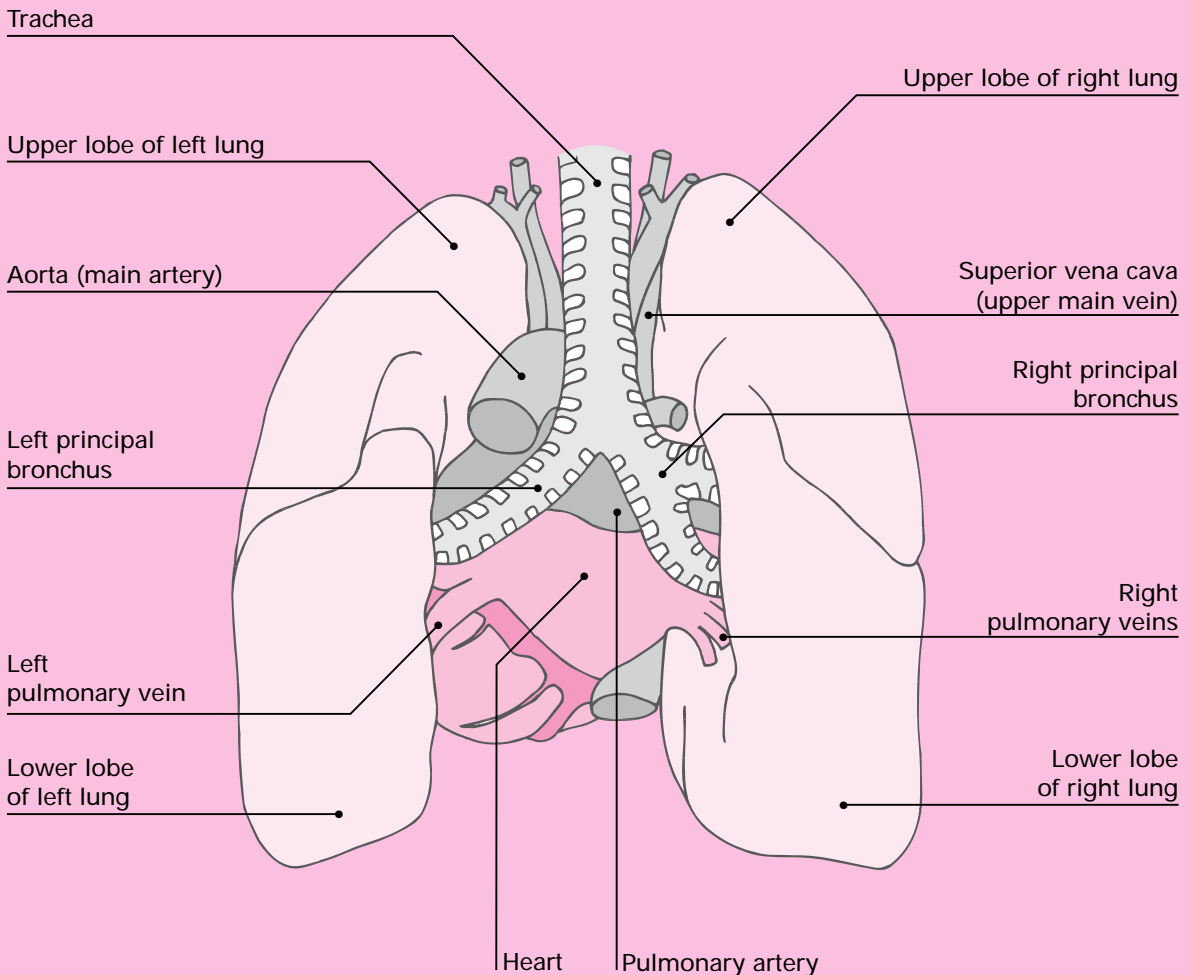


Heart-lung complex

The heart and lungs are closely linked by the short, wide pulmonary vessels—one pulmonary artery and two pulmonary veins on each side—that convey blood between them. The midthoracic or

midventral region occupied by the heart and major vessels, rather than lung tissues, is called the interpleural space or mediastinum.

Posterior view of lungs and heart

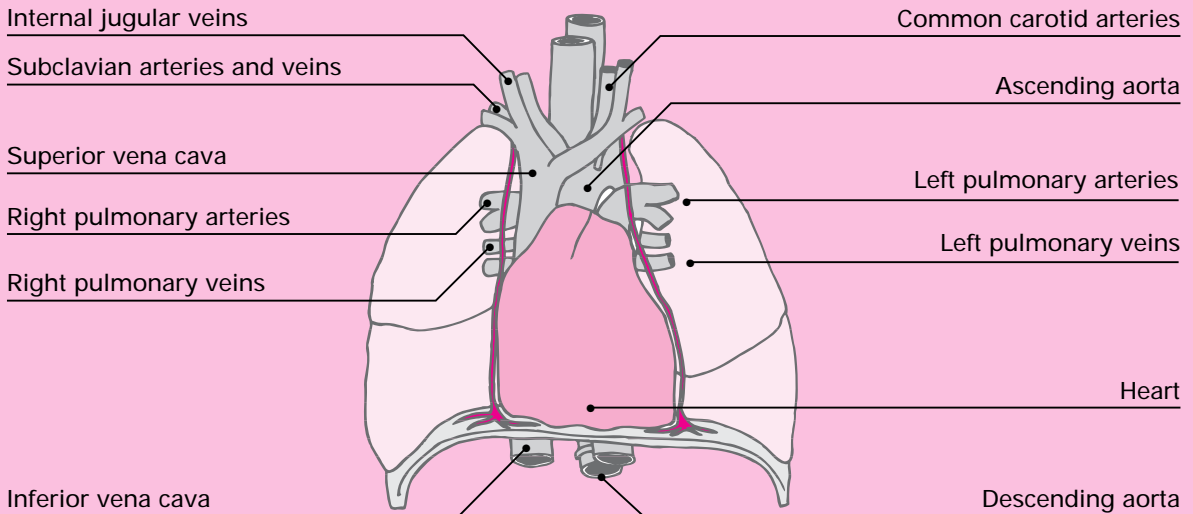


Layout of major vessels

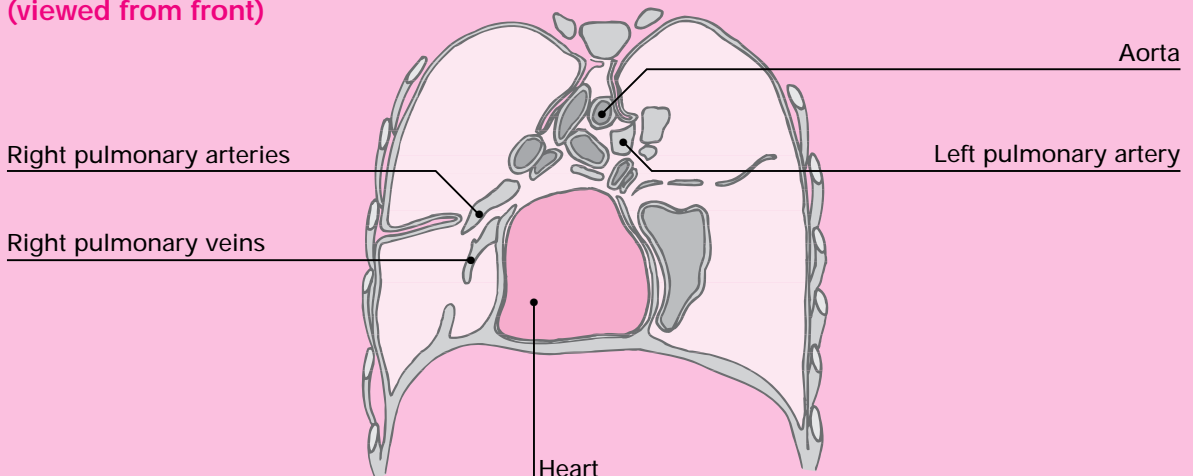
The main artery from the left side of the heart, the aorta, arches up and around and down, giving off branches to the head, arms, and upper body. It then runs

down between the lungs and behind the heart, alongside the esophagus, to emerge through the diaphragm into the abdomen.

Anterior view of lungs and heart



Vertical section through thorax (viewed from front)



Position and gross structure

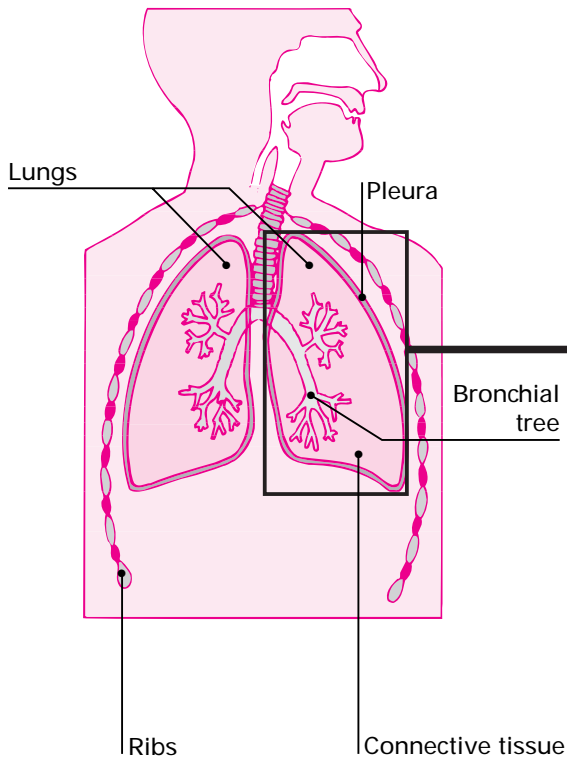
The lungs lie in either side of the chest, or thoracic cavity, protected by the ribs (1). They are covered by the pleurae (fluid-secreting membranes). The lungs consist of spongy connective tissue surrounding the air passageways of the bronchial tree.

Bronchi and bronchioles

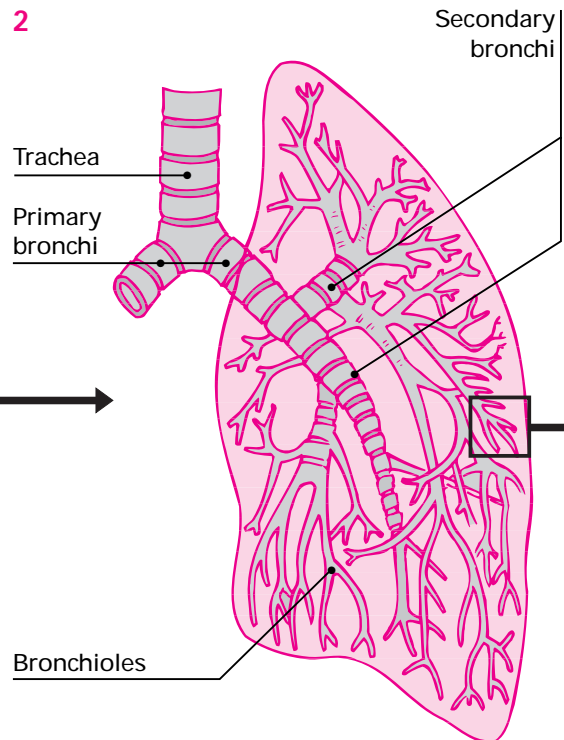
The trachea (windpipe) branches into the bronchial tree (2), formed by the bronchi and bronchioles. The tree is lined with respiratory mucosa, which secretes slimy mucous fluid and bears tiny, hairlike cilia (see page 41).

Lung structure

1



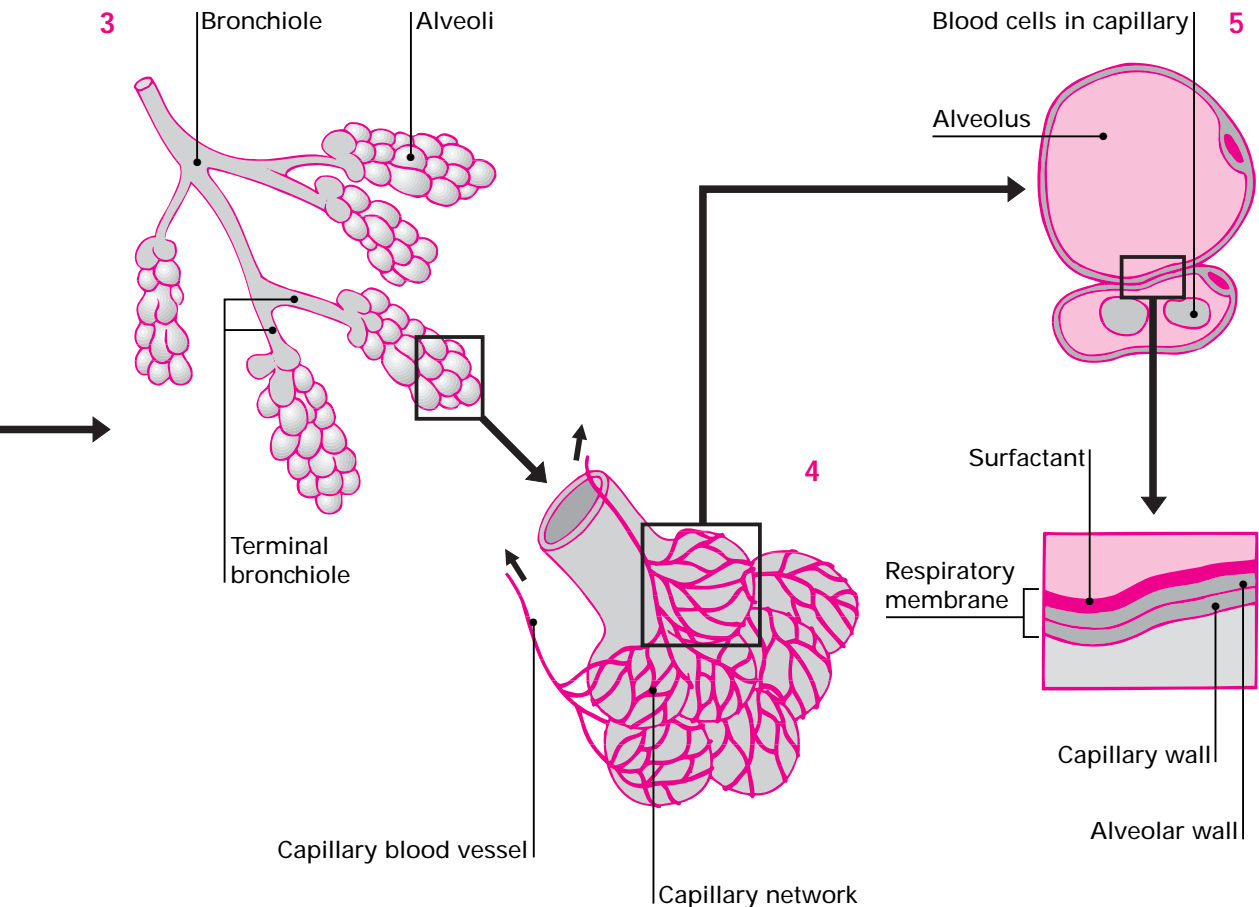
2



Alveoli and capillaries

The bronchioles continue to branch and become narrower, eventually forming terminal bronchioles (3). These lead to the alveoli—microscopic, grapelike air sacs or “bubbles.” A fine network of microscopic blood vessels, or capillaries, covers their walls (4). The wall of an

alveolus and the wall of a capillary together form a respiratory membrane (5). The inside of the alveolar wall is coated with surfactant, a fluid composed of fat and protein molecules. These structures are examined in greater detail on the following pages.

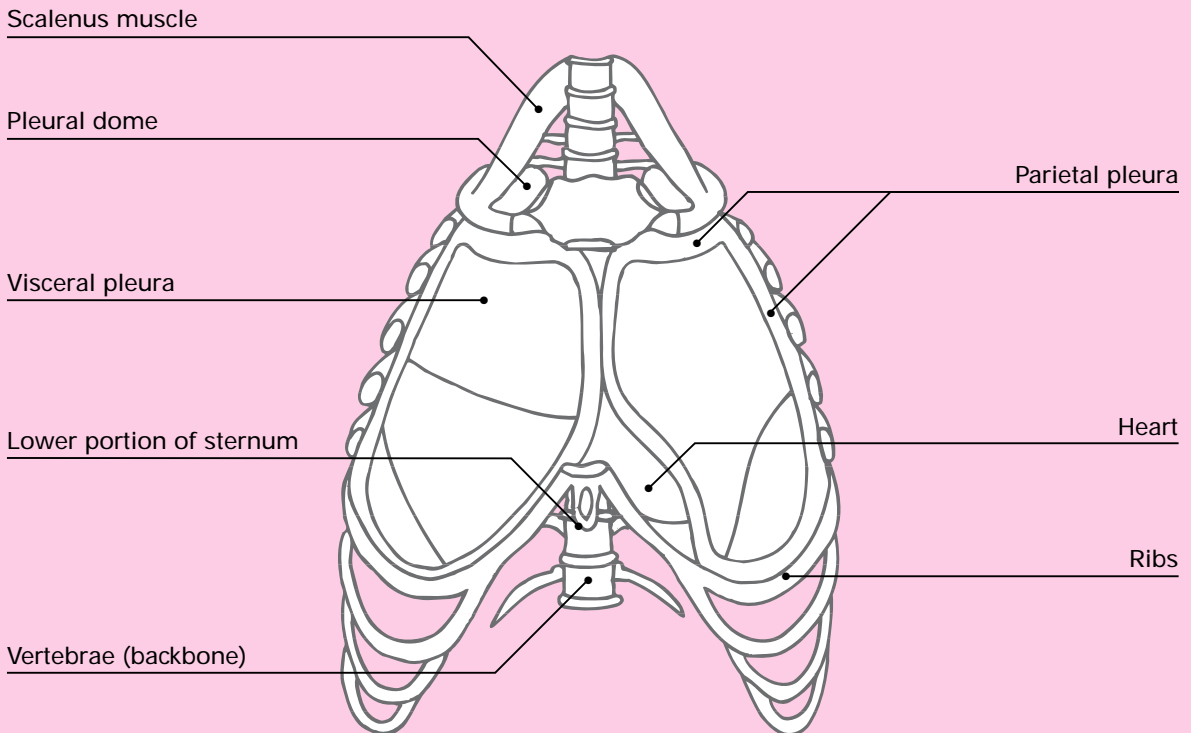


Chest cavity and pleurae

The pleurae are slippery, thin membranes that wrap around and cover the lungs, and fold back on themselves to line the chest or thoracic cavity. The part of the pleura covering each

lung is the visceral pleura, and the portion lining the thoracic cavity is the parietal pleura, although the two are continuous. Between them is a very thin layer of fluid in the pleural cavity.

Anterior view



Pleurae

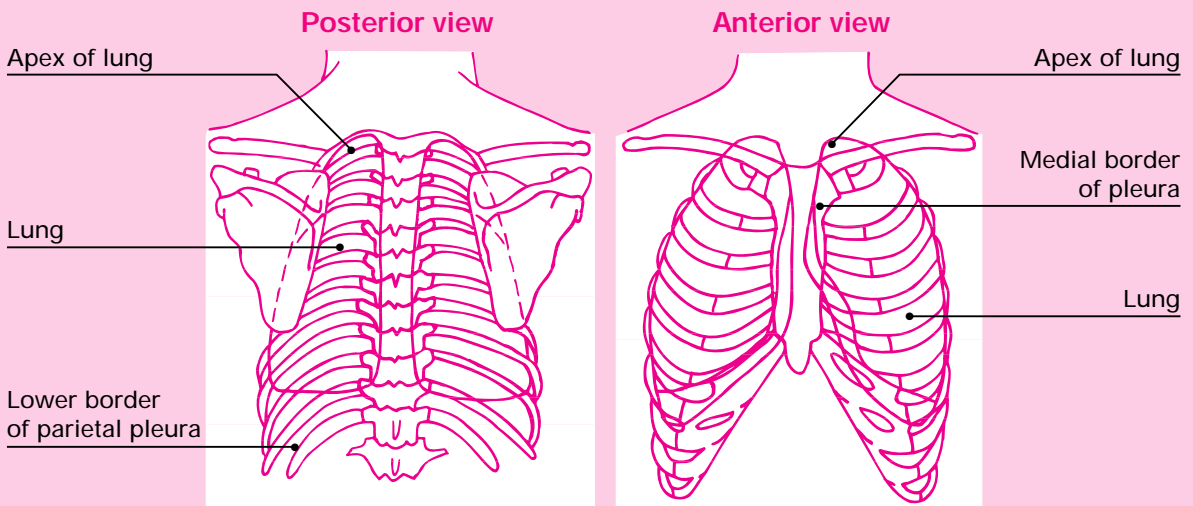
- The pleural membranes enclose every surface and contour of the lungs, separating them from the other organs and vessels in the center of the chest.
- Like the lungs, the heart is also wrapped in a slippery two-layered bag that lubricates its beating movements. These layers are known as the pericardial membranes.

Functions of the pleurae

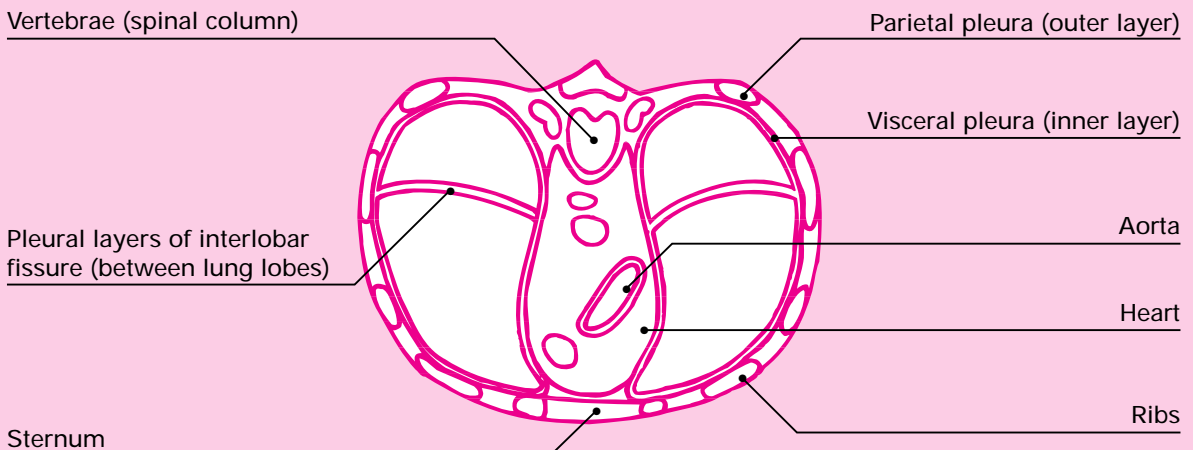
The pleurae are moist and slippery and slide over each other easily. With each breath, the lungs expand and contract with the chest cavity, and the visceral pleura slips over the parietal pleura to

make the movement smooth and well lubricated. The pleural cavity is a “potential gap,” since the two layers of pleurae are usually in close contact with only a thin layer of fluid between.

Borders of lung and pleurae



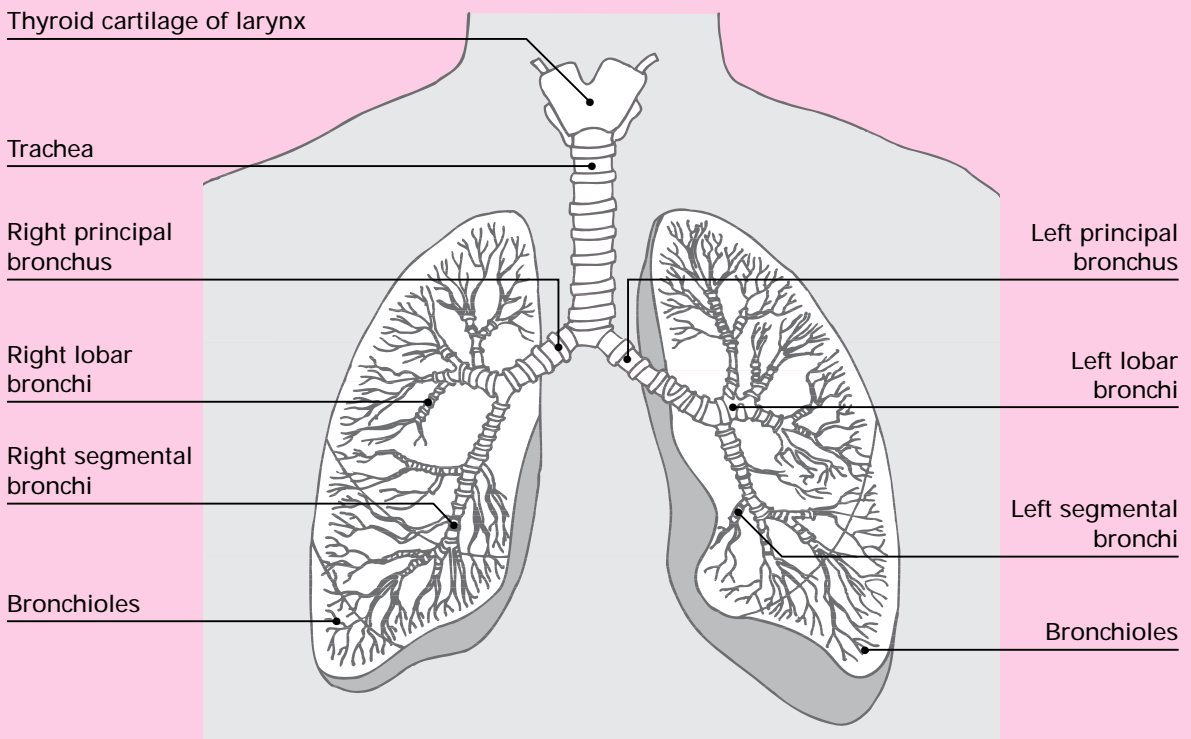
Transverse section



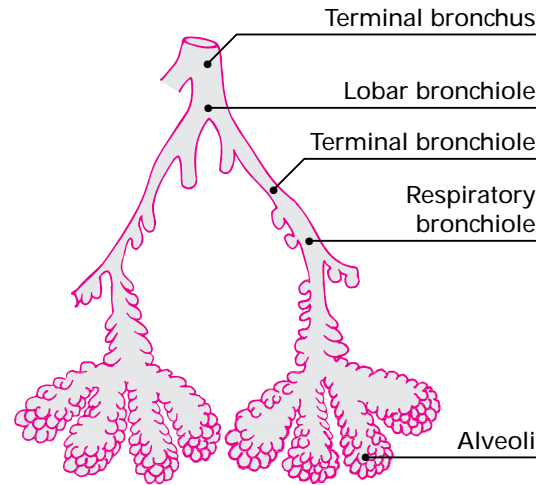
Branching of the airways

The branching system of airways within the lungs is often called the “bronchial tree.” It is comparable to an upside-down tree with the trachea as the trunk, the main bronchi as the chief branches, the bronchioles as the smaller twigs, and the alveoli as the terminal tips of shoots and buds. The branching system reflects the organization of lobes and segments in the lungs (see opposite).

General arrangement of the bronchial tree



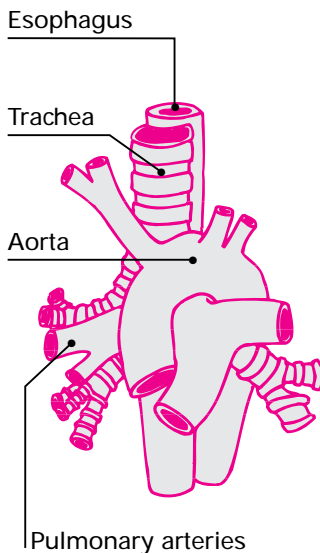
Sequential structure of the trachea and lungs



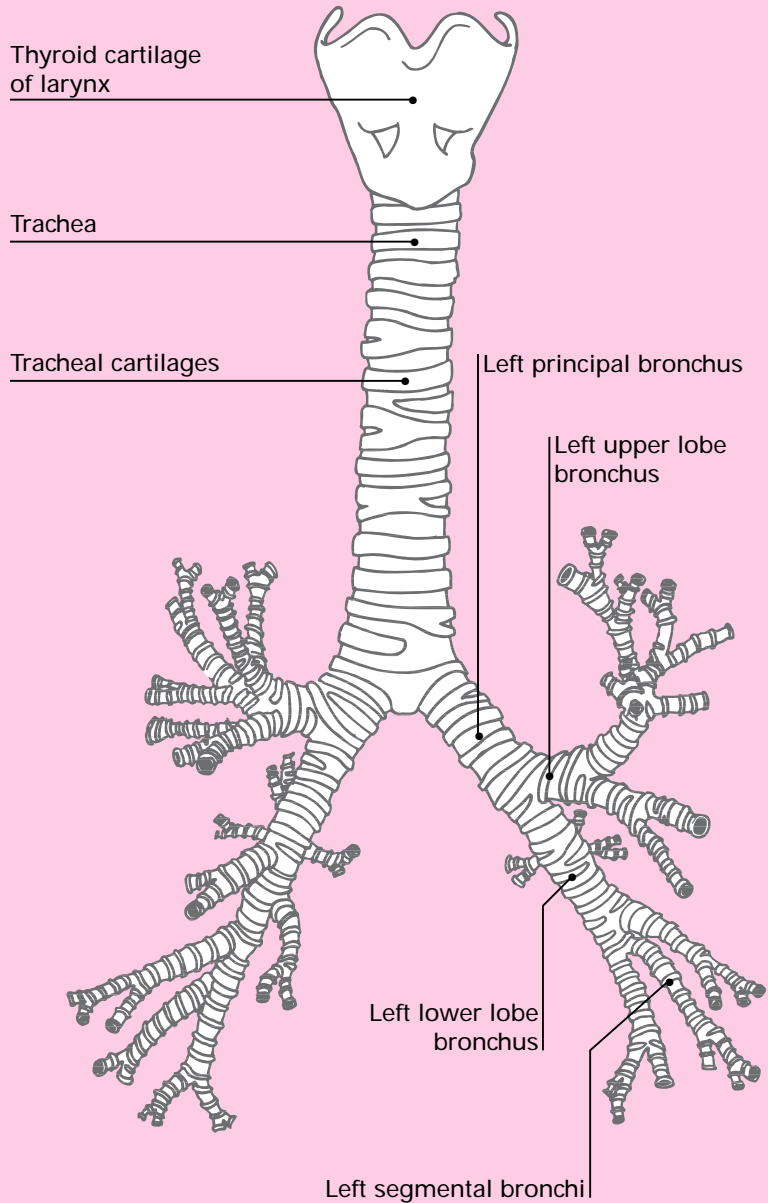
Organization

The two airways branching from the base of the trachea are the main or principal bronchi, one to each lung. Each of these divides to supply one lobe of that lung—three on the right, two on the left. In turn each of the lobar bronchi branches several times to form segmental bronchi that supply the ten or so separate segments (bronchopulmonary segments) of the lobe.

Position of airways in relation to vessels and esophagus



Details of the larynx, trachea, and bronchi

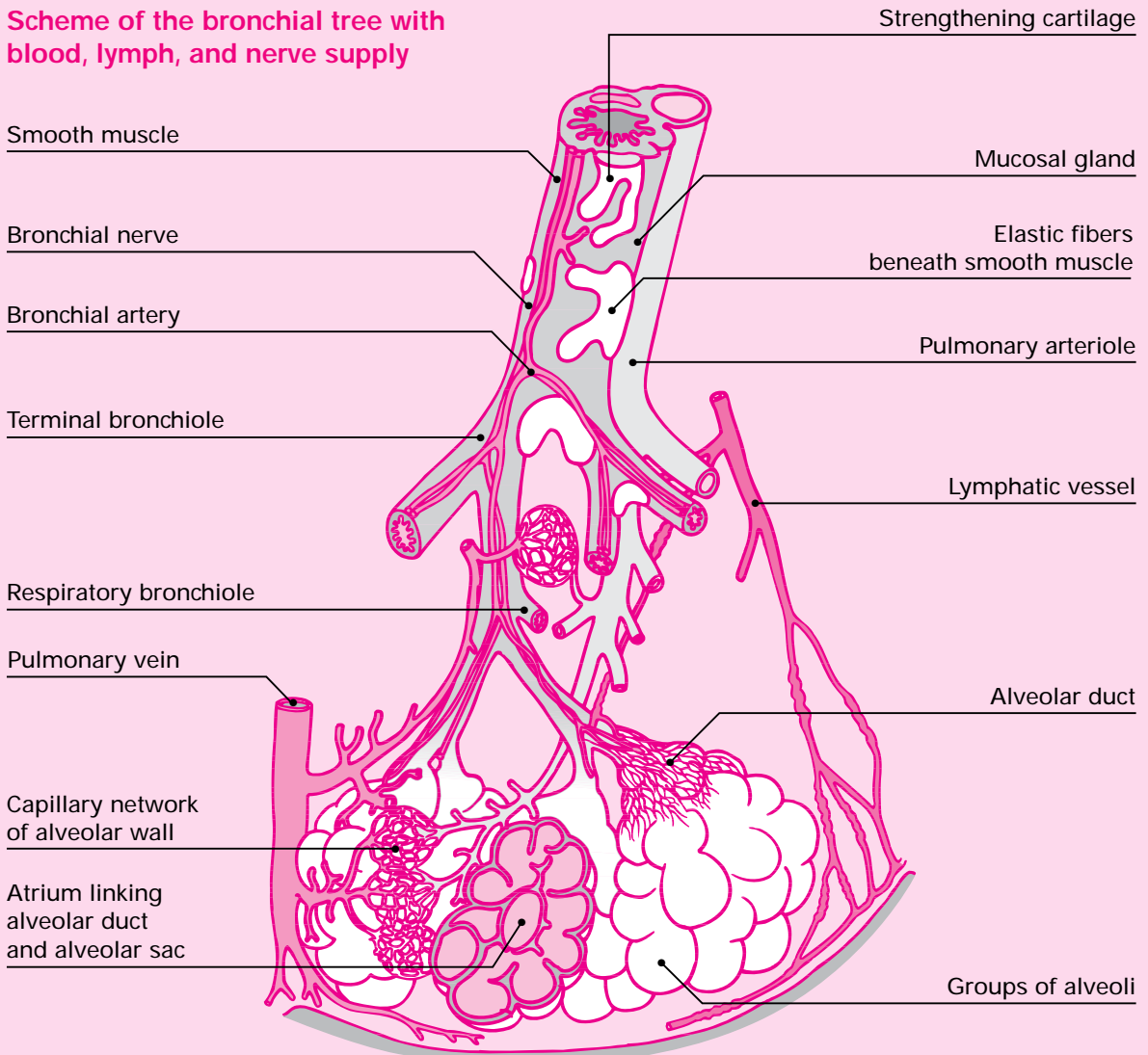


Terminal bronchioles

After dividing about 16 or 17 times from the original principal bronchus, the airway system forms terminal bronchioles. Unlike the larger airways, the terminal bronchioles lack

strengthening rings or hoops of cartilage. Their walls are composed mainly of smooth or involuntary muscle (which is under autonomic control).

Scheme of the bronchial tree with blood, lymph, and nerve supply

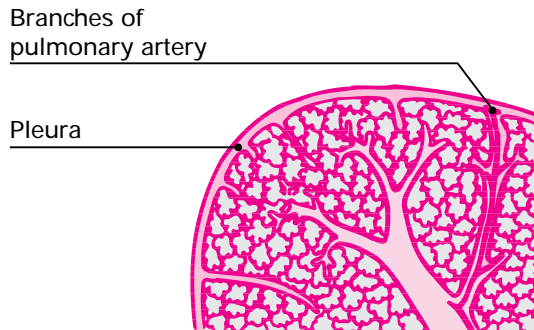


Pulmonary arterial and venous trees

In a similar way to the bronchial tree formed by branching airways, there are two other trees within each lung.

The pulmonary arteries divide many times into smaller arteries and arterioles, eventually forming capillaries that envelop the alveoli. These capillaries then join into wider venules and finally the wide pulmonary vein.

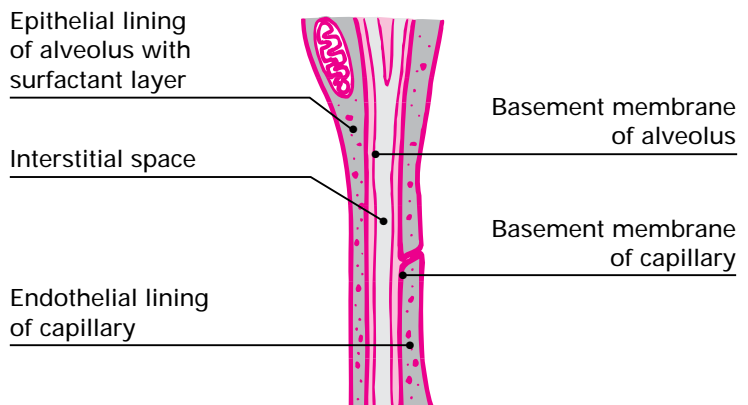
Lung section showing air passages and blood vessels



Respiratory membrane

The wall or lining of each alveolus is adjacent to the wall or lining of the capillary. Together with the surfactant fluid on the alveolar lining, and the interstitial space of intervening tissue fluid between the two linings, these layers all form the respiratory membrane. Oxygen must pass or diffuse across the membrane, from the air space in the alveolus, to the blood flowing through the capillary.

Respiratory membrane (blood-air barrier) as shown by electron microscopy



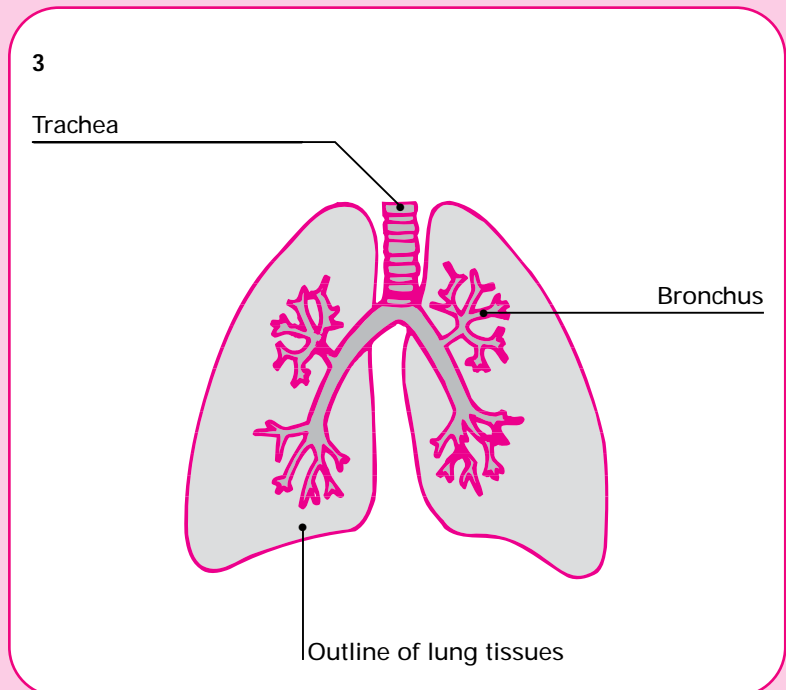
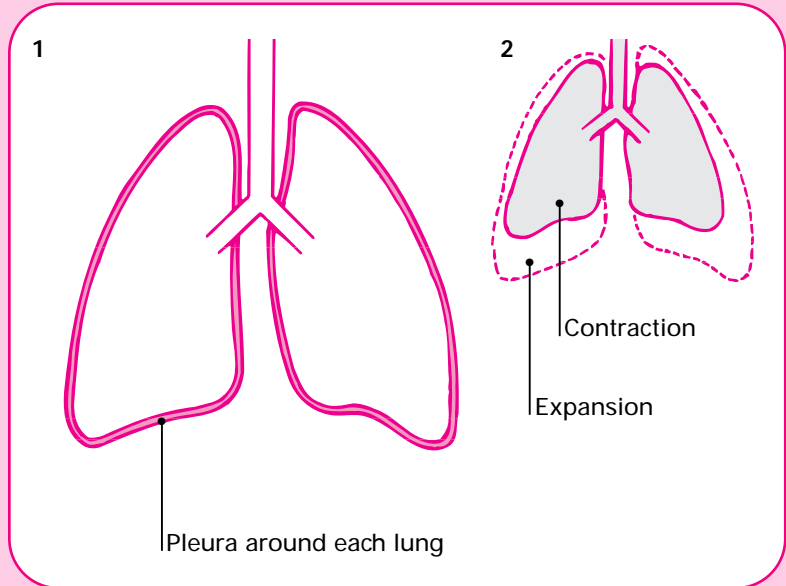
Chief functions of the lungs

The pleurae (slippery membranes) around the lungs (1) allow the lungs to slide freely as they expand and contract during breathing (2). The lungs themselves have three main functions.

They provide the site for the exchange of gases between the alveoli and the blood, across the respiratory membrane (see previous page and opposite).

They are involved in the physical process of breathing (inhalation-exhalation) by which air travels to these sites.

They house the airways of the bronchial tree and route these airways to the gas-exchange sites (3).

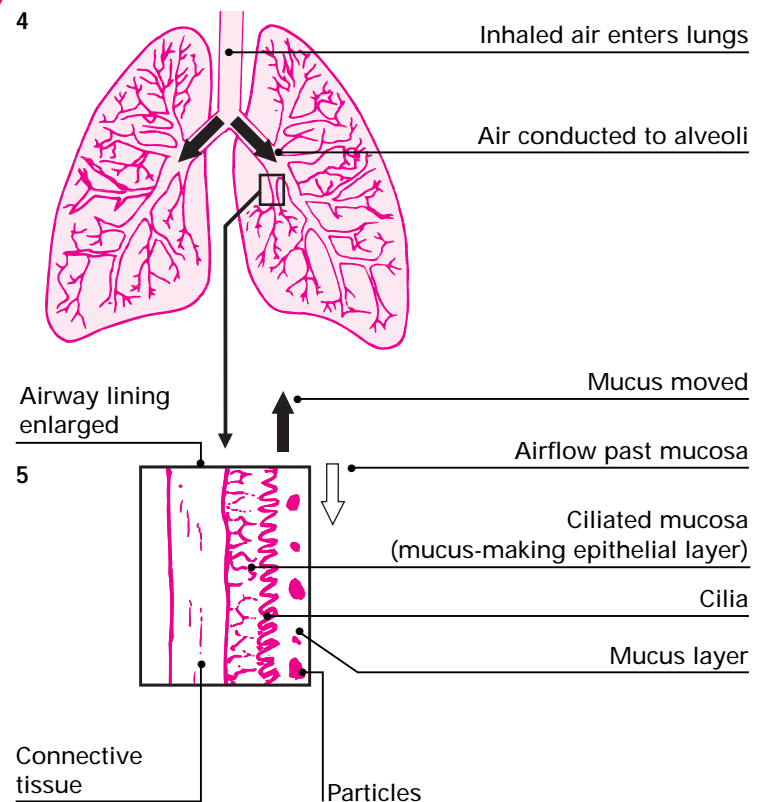


Numbers of alveoli

- It is estimated that each lung contains 250–300 million alveoli.
- Spread out flat, the alveoli altogether form the respiratory membrane. Its total surface area would cover the area of a tennis court.

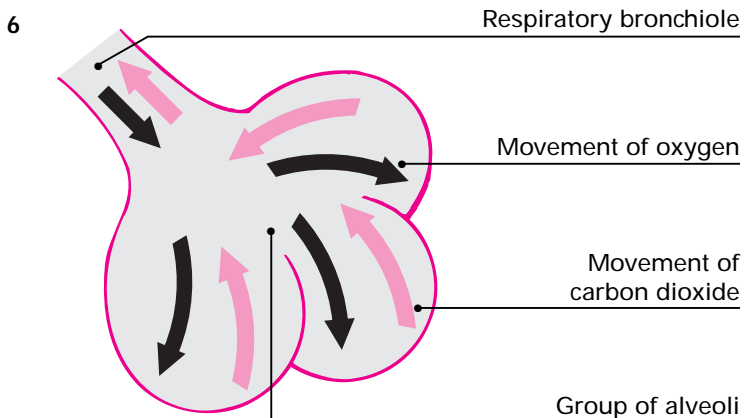
The bronchial tree provides the passageways by which air reaches the collective respiratory membrane (4). The respiratory mucosa of the bronchial tree both warms and moistens the air to facilitate the exchange of gases, and cleanses the inhaled air by trapping particles in the mucous layer (5). This layer is moved to the throat by the cilia, for swallowing.

The alveoli and blood vessels create the vast surface area of the collective respiratory membrane. Surfactant fluid keeps the alveoli from collapsing due to surface tension as the air moves in and out (6).



Gaseous exchange within alveoli

Oxygen seeps or diffuses from the airways into the alveoli, and passes through their walls into the blood (6). The gaseous waste product carbon dioxide diffuses in the opposite direction (see page 84).



External and internal respiration

Respiration is the process that supplies the vital gas oxygen to the body's tissue cells and removes the harmful gas carbon dioxide. The movements of these gases rely on the process of diffusion (see page 86). This is the tendency for substances to spread from an area where they are more concentrated (higher partial pressure or tension) to where they are less concentrated (lower partial pressure).

External respiration

External respiration is the exchange of gases between the air in the lungs and the blood and the body as a whole, across the respiratory membrane.

1 Oxygen diffuses from an area of high concentration in inhaled air to one of lower concentration in oxygen-poor or "used" blood.

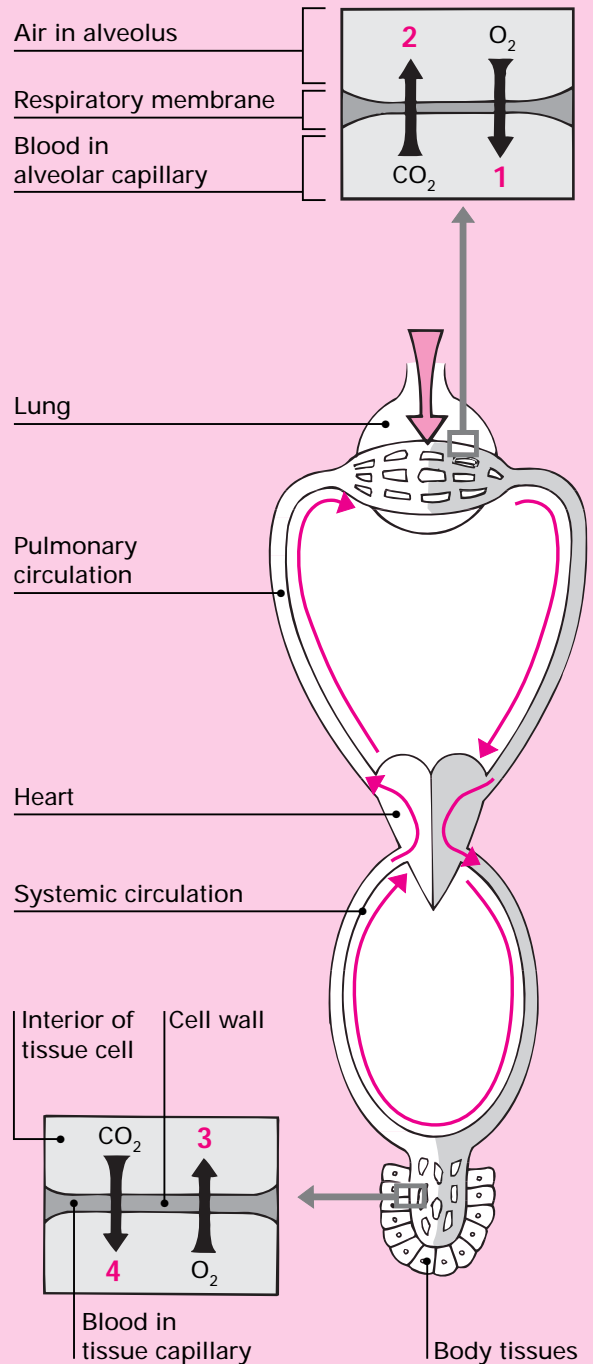
2 Carbon dioxide diffuses from an area of high concentration in "used" blood to one of lower concentration in the inhaled air in the alveoli.

Internal respiration

Internal respiration is the exchange of gases between the blood and the tissue cells of the body, through vessel and cell walls. All cells need oxygen to release energy to carry out their life functions. Using oxygen to obtain this energy produces carbon dioxide.

3 Oxygen diffuses from higher concentration in oxygen-rich blood, to lower concentration within tissue cells.

4 Carbon dioxide diffuses from higher to lower concentration: from cell to blood.



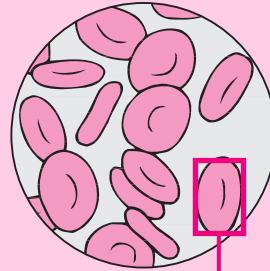
Oxygen transport and red blood cells

Red blood cells, known as erythrocytes, are the vehicles that transport the vital gas oxygen from the lungs through the bloodstream to all the tissues and cells of the body. They also carry some of the harmful waste gas carbon dioxide from cells to the lungs, where it is expelled in exhaled air. The structure of a red blood cell reflects its main tasks. The lack of a nucleus and any organelles maximizes its oxygen-carrying capacity. The cell membrane or outer “skin” of an erythrocyte contains around 15 different classes of transmembrane proteins, which are vital in transporting or carrying molecules such as oxygen and carbon dioxide, into and out of the cell.

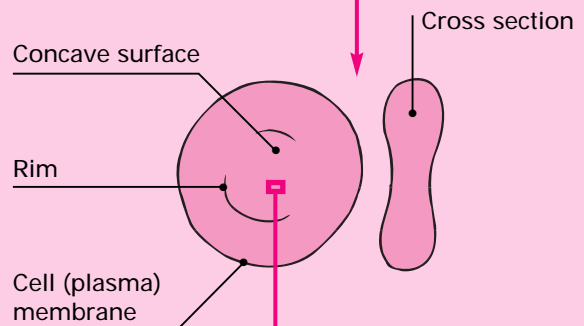
Red blood cell structure

Red blood cells have a very simple structure. They consist of little more than the cell or plasma membrane, which is stiffened with internal proteins and has a protein filling, plus contents. In shape, each red cell is a biconcave disk—it has two inwardly curving sides. The diameter of the whole cell is about 0.00028 inches (7 micrometers) and the rim thickness is about 0.00008 inches (1.9 μm). Red cells are filled with hemoglobin, an iron-containing protein with a high affinity for oxygen. This gives red blood cells their color. A molecule of hemoglobin consists of one globin protein linked to four iron-containing heme groups. Each red cell contains 250–300 million molecules of hemoglobin (see also page 87).

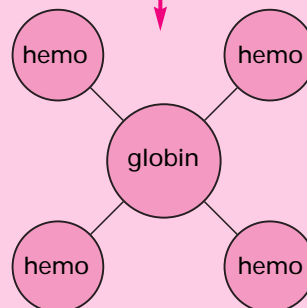
Red blood cells under microscope



Individual red blood cell



Structure of hemoglobin

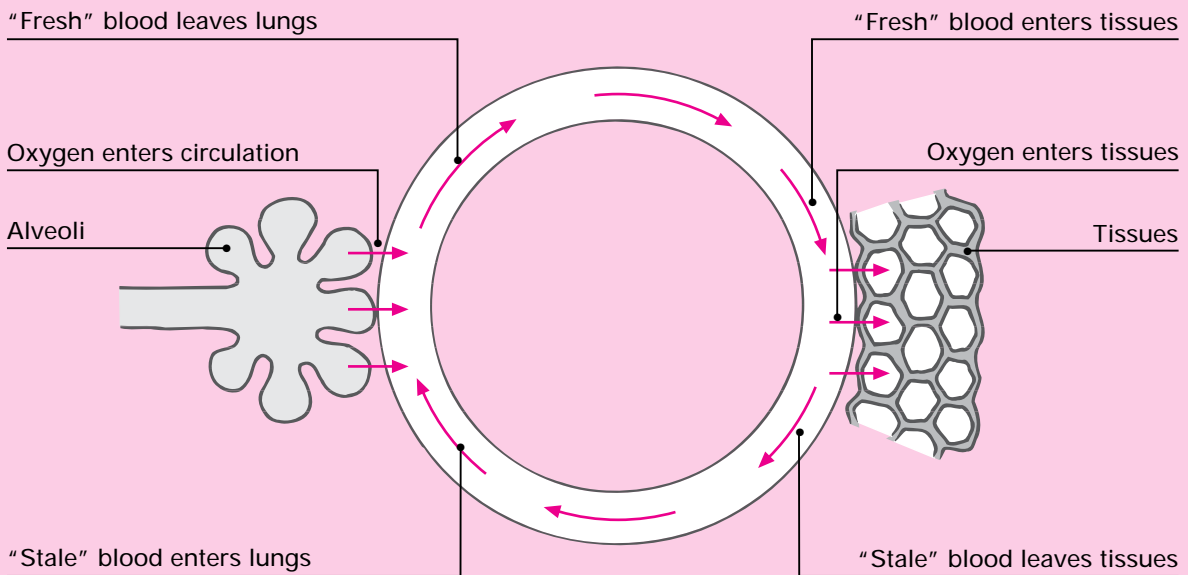


Lung capacity and exchange of oxygen

In a typical adult, the total volume of air in the lungs is about 340–360 cubic inches (6 l) in a male, and 260–280 cubic inches (4.5 l) in a female. During quiet breathing, only about 30 cubic inches (0.5 l) of air is breathed in and out. The physical flow and exchange of air in the

small bronchioles and alveoli is nearly nonexistent. The exchange of gases in these regions occurs almost exclusively by diffusion (pages 82–83). Oxygen passes from alveolar air into the pulmonary bloodstream, which is then sent to all tissues (see pages 86–87).

Transfer of oxygen from lungs to tissues



Inhaled air

- "Fresh" air before inhalation contains about 78% nitrogen, 21% oxygen, and 0.04% carbon dioxide. Nitrogen takes little part in respiration and is carried passively in and out of the lungs.

Exhaled air

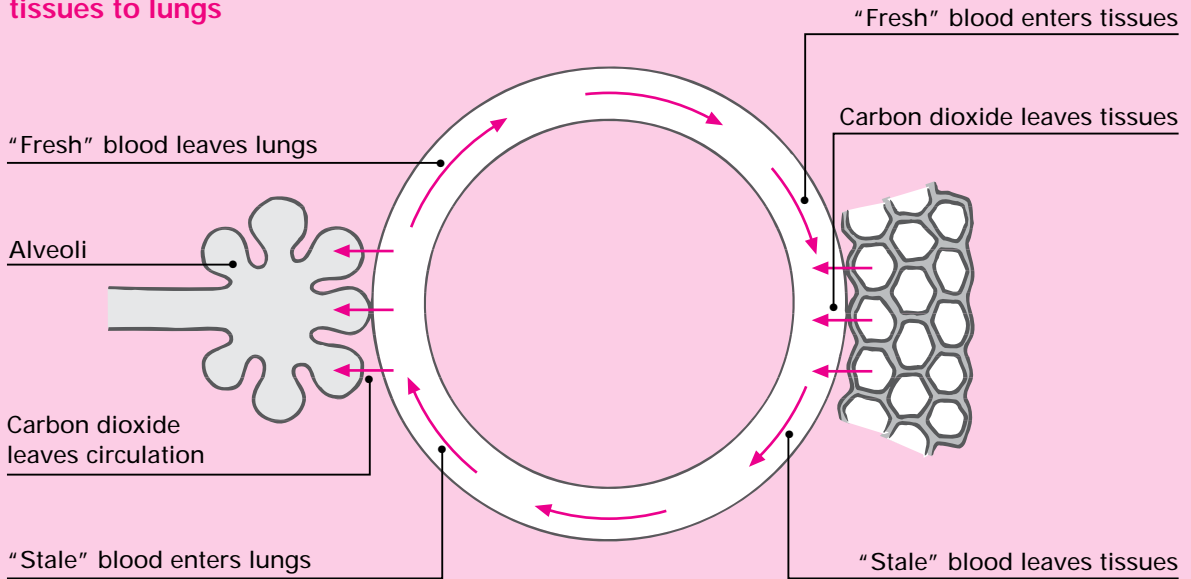
- "Stale" air exhaled from the lungs contains about 16% oxygen and 4% carbon dioxide. In emergencies where no other air is available the oxygen content is sufficient to allow limited "rebreathing" of exhaled air.

Exchange of carbon dioxide

Unlike oxygen, carbon dioxide is carried in the blood in three forms. These are: dissolved in blood's watery part, the

plasma; combined with other chemicals, as bicarbonate ions; and by red blood cells (see page 88–89 for details).

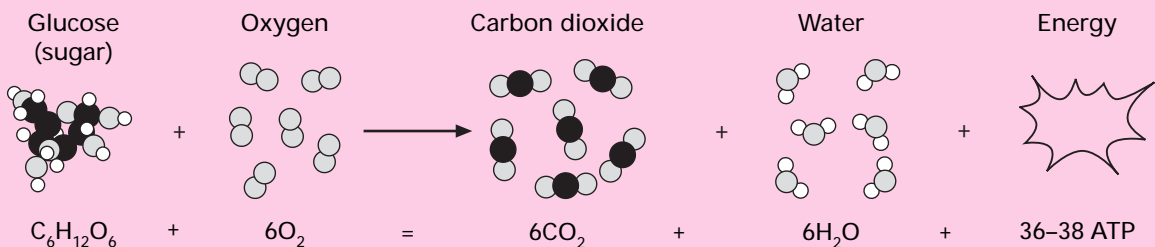
Transfer of carbon dioxide from tissues to lungs



The need for oxygen: glycolysis

Cellular respiration is the breakdown of the sugar glucose to release enough energy to produce the energy-storage molecule ATP (adenosine triphosphate).

This can be summarized by a simple equation showing the need for oxygen. In reality, cellular respiration occurs in a series of complex stages.



Diffusion and loading/unloading

In the respiratory system, blood carries the gases oxygen and carbon dioxide between the lungs and the tissue cells. The transport of these gases uses diffusion—the tendency for substances to diffuse from an area where they are highly concentrated to where they have

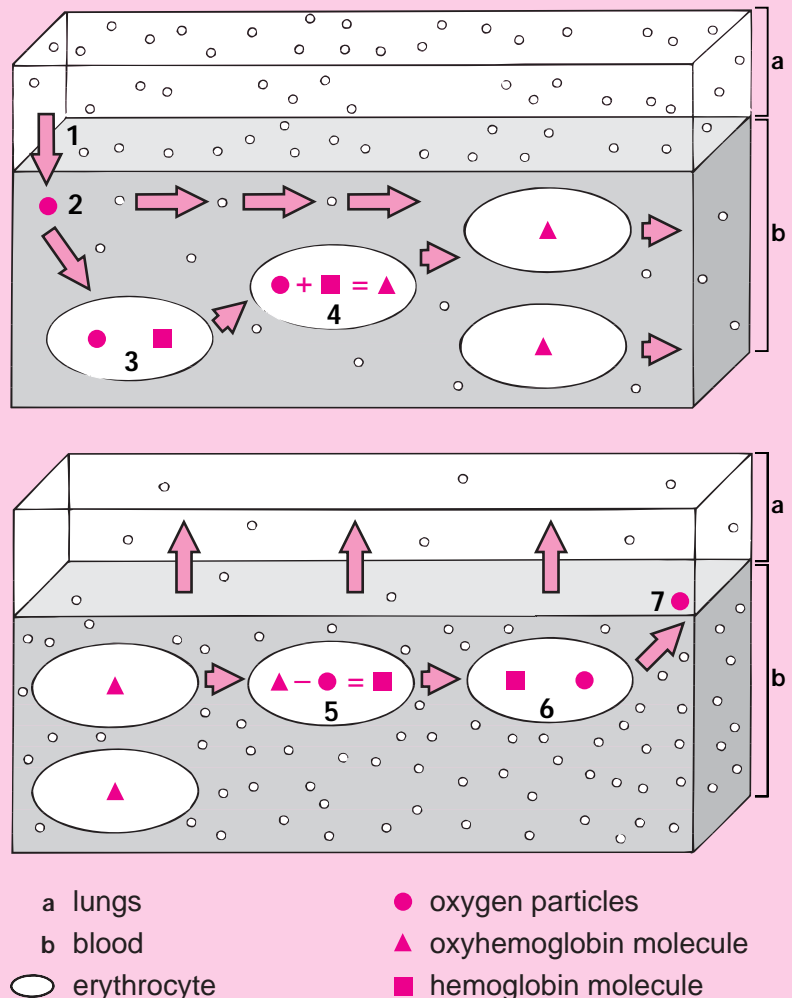
a lower concentration (see also page 82). Erythrocytes (red blood cells) and plasma (watery fluid) are the main components of blood involved. The process can be divided into two stages: the loading (picking up) and the unloading (dropping off) of the gases.

Loading of oxygen

- 1 Oxygen enters the blood from the lungs in external respiration.
- 2 It then dissolves in the plasma.
- 3 Most of the oxygen will then diffuse from the plasma into the red blood cells. (About 3% remains in solution in the plasma.)
- 4 The oxygen combines with hemoglobin molecules in the red cells to form a compound called oxyhemoglobin.

Unloading of oxygen

- 5 When the blood reaches the tissue cells, the bonds linking the oxygen and the hemoglobin break.
- 6 The oxygen can then diffuse back into the plasma.
- 7 The oxygen is then free to enter the tissue cells in internal respiration.



Respiration and blood components

Blood is a special type of connective tissue in which formed elements (red and white blood cells) are suspended in plasma (a watery fluid). The proportions are plasma (55%), white blood cells (1%), and red blood cells (44%).

Roles of blood components

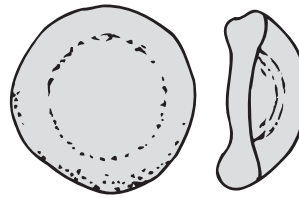
- Red blood cells, or erythrocytes, are by far the major component for oxygen transport, and are also involved in carbon dioxide transport. (See page 83 for further details of red cells.)
- White blood cells or leukocytes have little role in gas transport.
- Plasma is more than 90 percent water and contains, both in solution and in suspension, many salts, proteins, nutrients, waste products, and hormones. It is heavily involved in carbon dioxide transport but only minimally in oxygen transport.

Principal components of blood

Plasma

White blood cells

Red blood cell component



Red blood cells

Blood functions

Transport functions

- Carries oxygen and nutrients to cells;
- transports waste gases (e.g. carbon dioxide) from cells to the lungs to be expelled;
- transports wastes from cells to the kidneys to be eliminated; and
- carries hormones from the endocrine glands to where they are needed.

Regulatory functions

- Regulates body temperature by dissipating heat from active areas (such as muscles);
- helps regulate the water content of cells; and
- contains buffering chemicals that keep pH (acid-alkali) levels in tissues normal.

Protective functions

- Clotting helps prevent hemorrhage when blood vessels are damaged.
- Certain white blood cells help protect against harmful microorganisms by engulfing them.
- Antibodies in plasma help protect against disease.

Loading of carbon dioxide

The process of blood transport for respiratory gases is divided into two stages: the loading (picking up), and the unloading (dropping off), as described on page 86.

- 1** Carbon dioxide gas enters the blood from the tissue cells, as part of the process of internal respiration.
- 2** Some of the carbon dioxide dissolves straightaway into the blood plasma.
- 3** Another proportion of the carbon dioxide diffuses into the red blood cells.
- 4** Some of this carbon dioxide combines with hemoglobin in the red blood cells,

replacing the oxygen which is leaving. The carbon dioxide and hemoglobin together form a compound called carbaminohemoglobin.

- 5** Most of the carbon dioxide (about 70%) combines with water in the red blood cells (rather than the hemoglobin there) to form carbonic acid.
- 6** This acid then separates into its component hydrogen and bicarbonate ions within the red blood cells.
- 7** The bicarbonate ions then diffuse out of the red blood cells and into the plasma for carriage.

Unloading of carbon dioxide

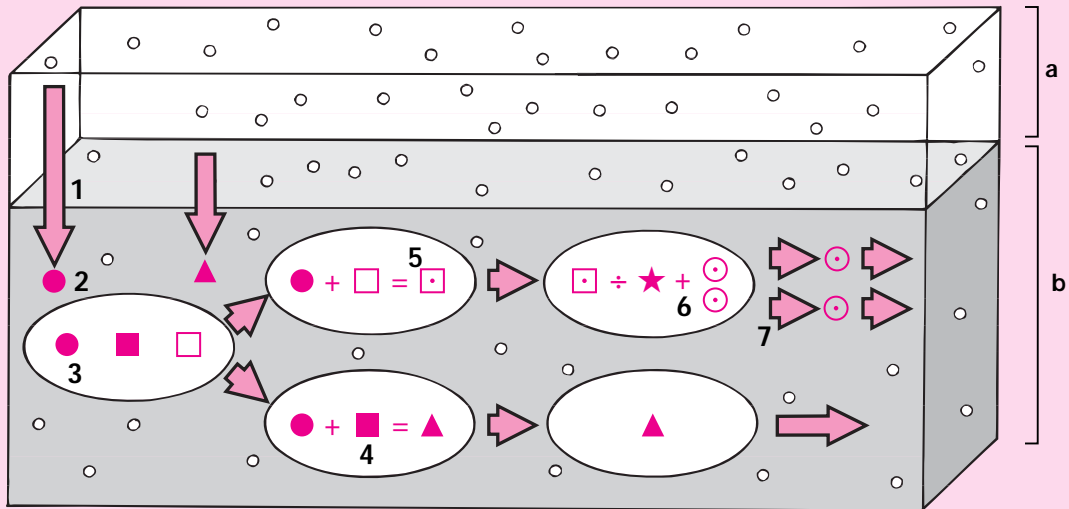
- 1** On reaching the lungs, the bicarbonate ions diffuse back into the red blood cells.
- 2** The bicarbonate and hydrogen ions recombine into carbonic acid.
- 3** The carbonic acid separates into water and carbon dioxide.
- 4** The carbon dioxide then reenters the blood plasma component by diffusion.

- 5** Also, the bonds linking the carbaminohemoglobin break.
- 6** The carbon dioxide from this process also diffuses back into the plasma.
- 7** From the plasma, the carbon dioxide is free to enter the air in the lungs, in external respiration.

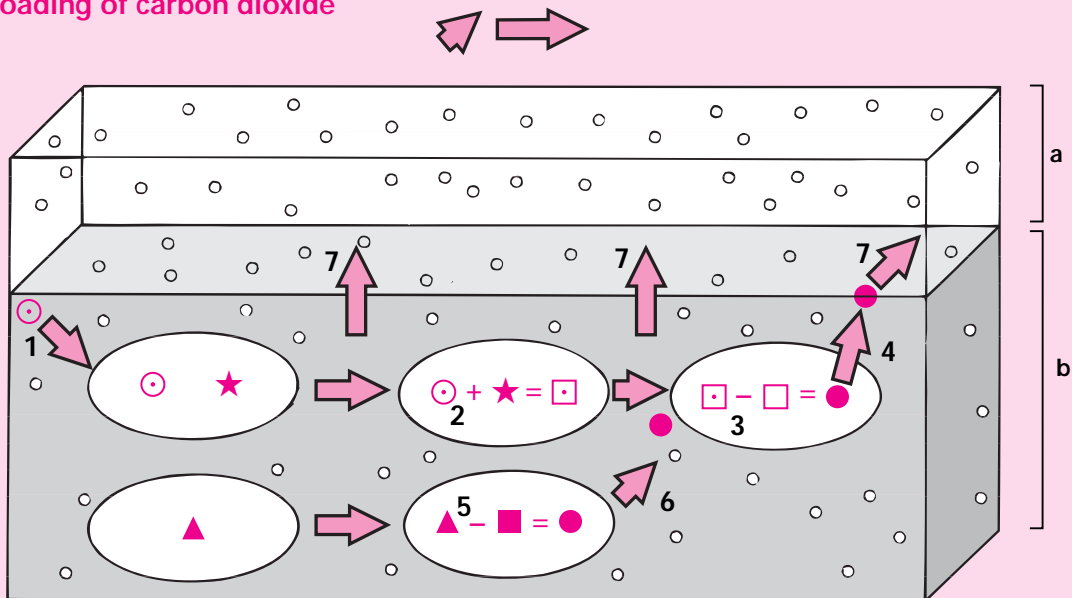
Key to diagrams on page 89

- | | | |
|---------------------------|-----------------------|----------------|
| a lungs | ▲ carbaminohemoglobin | □ water |
| b blood | ⊙ bicarbonate ion | ★ hydrogen ion |
| ○ erythrocyte | ■ hemoglobin molecule | |
| ● carbon dioxide particle | ◻ carbonic acid | |

Loading of carbon dioxide



Unloading of carbon dioxide



Circulatory system

Circulation through blood vessels is referred to as systemic or pulmonary.

Pulmonary circulation

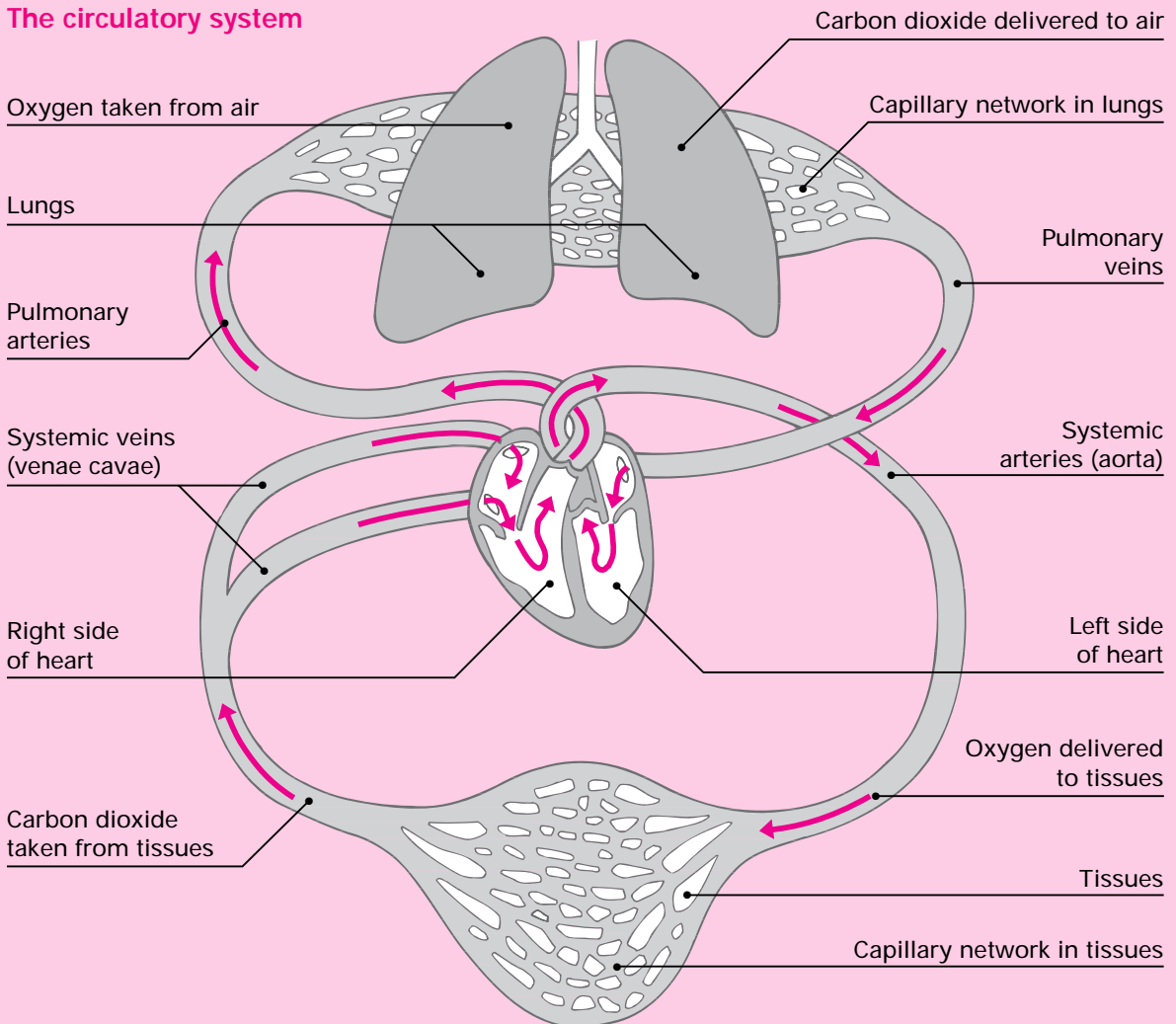
The right side of the heart pumps blood to the lungs to pick up oxygen and lose carbon dioxide. This oxygen-rich blood returns to the left side of the heart. This is called the pulmonary circuit.

Systemic circulation

The left side of the heart pumps blood to the main body tissues, which return this blood to the right side of the heart. This is called the systemic circuit.

Blood in the systemic circuit gives up its oxygen to the tissues and gains carbon dioxide from them.

The circulatory system

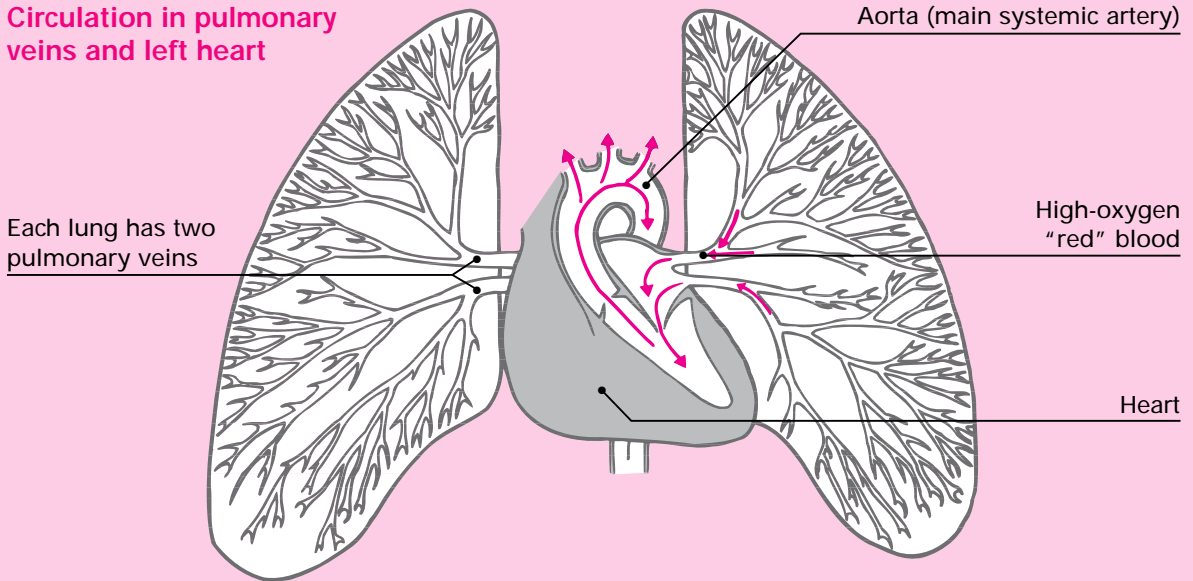


Pulmonary arteries and veins

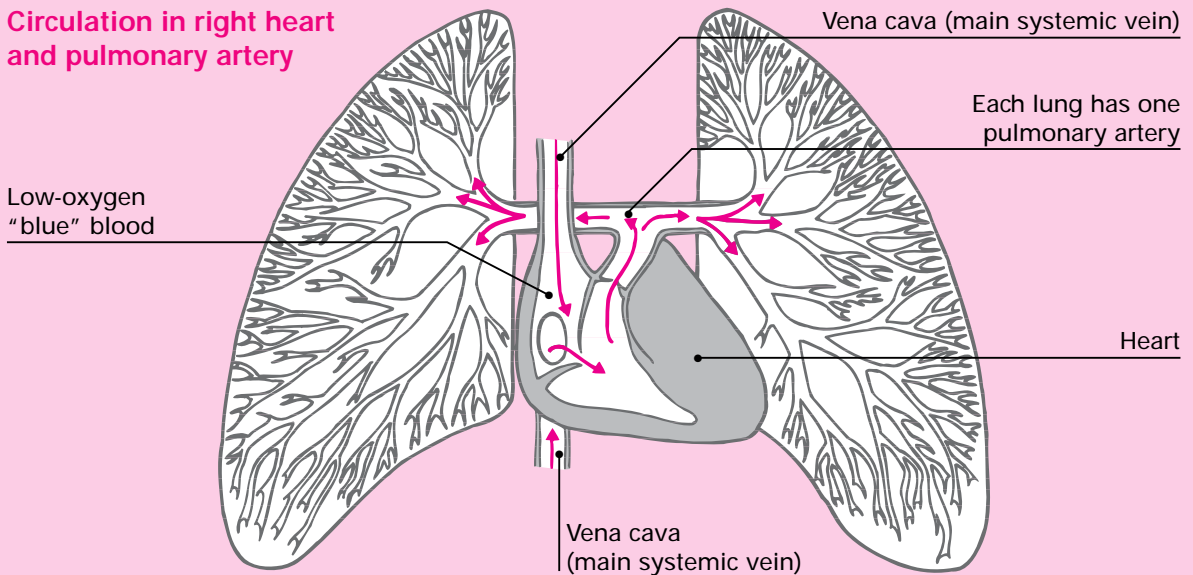
In contrast to arteries elsewhere, pulmonary arteries carry low-oxygen “stale” or “blue” blood, from the heart’s

right side to the lungs. Pulmonary veins transport “fresh” or “red” blood from the lungs to the heart’s left side.

Circulation in pulmonary veins and left heart



Circulation in right heart and pulmonary artery



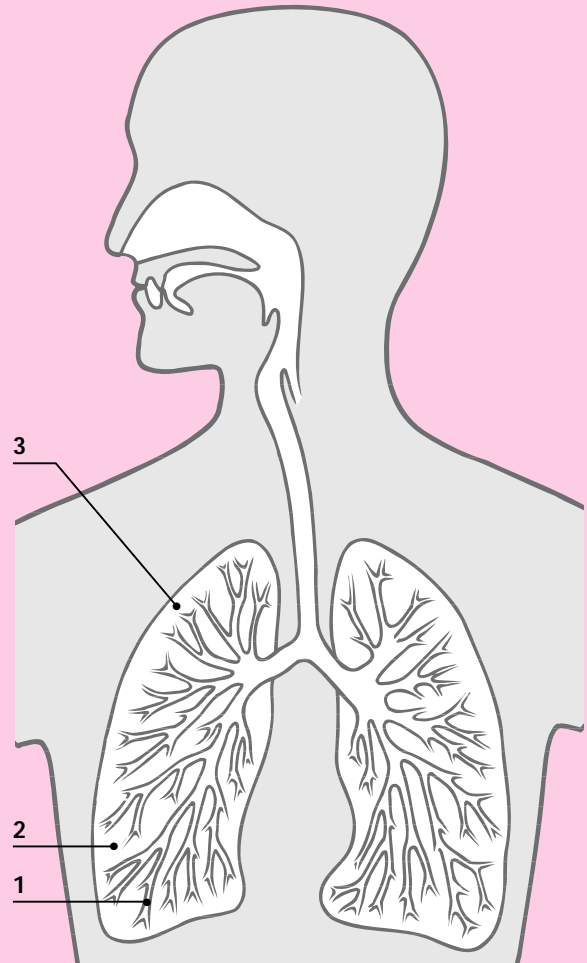
Major lung diseases

1 Bronchiectasis involves permanent dilation of the smaller bronchi. Antibiotics, postural drainage as used for cystic fibrosis (see page 33), and surgery may be helpful.

2 Pleurisy is inflammation of the pleurae—the membranes that cover each lung and line the chest wall. Pleurisy may accompany pneumonia, carcinoma (cancer), or pulmonary infarction (caused by obstruction of local circulation). The membranes become swollen, reddened, inflamed, and sore. There may be pain in the side of the chest, depending on the extent of the problem, and/or shortness of breath.

3 Lung cancer causes pressure on the surrounding structures and often the development of secondary cancerous deposits spreading to the brain, bone, liver, adrenals, and skin. The disease usually begins when cells in the bronchi start to grow in an uncontrolled way and invade other tissues (see opposite). Lung cancer is caused by the deposition of carcinogenic material in the airways, from smoking, polluted urban air, or the inhalation of asbestos dust or certain other dusts produced by mines or factories. By far the most common cause is smoking. Lung cancer kills many thousands each year, yet could be almost entirely prevented if people stopped smoking and lived and worked in clean air. Warning signs include coughing and spitting blood-stained sputum, weight loss, malaise, and lassitude. In certain conditions the lungs become so ineffective that untreated

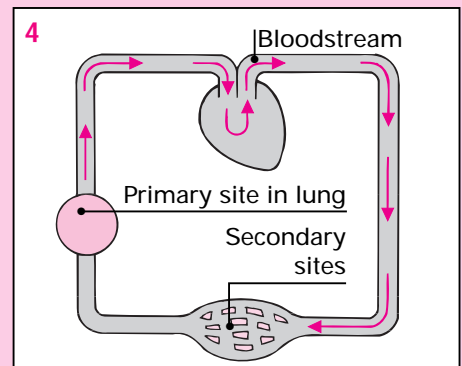
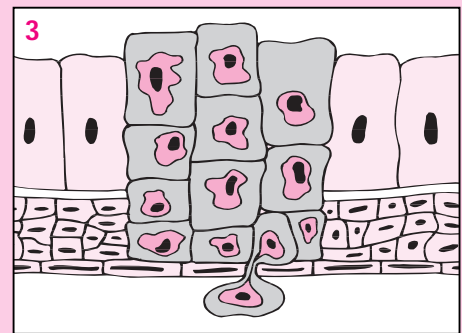
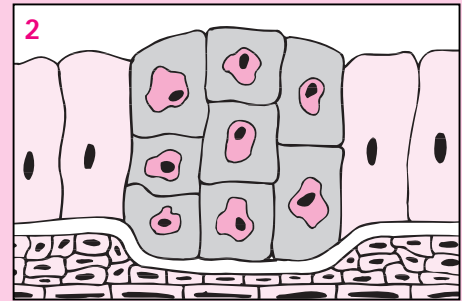
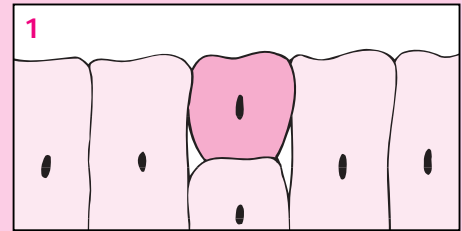
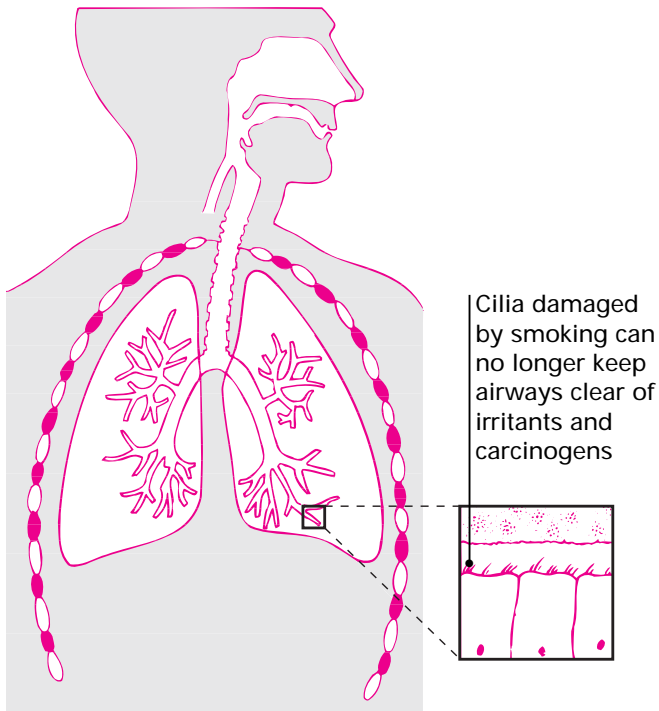
patients die of oxygen deprivation. Fortunately, antibiotics, surgery, and self-help can prevent or minimize the effects of some lung cancers that used to be fatal in the majority of cases. In particular, prompt reporting of the symptoms to a doctor, followed by early diagnosis of the problem, and urgent surgery with chemotherapy, can be of great help.



Cancerous changes in the lungs

One or more cells are damaged by toxic carcinogens, or cancer-triggering substances (1). These usually come from tobacco smoke. The cell's process of multiplication is disrupted and it begins to divide rapidly in an abnormal, uncontrolled way (2). The multiplying cells begin to invade nearby tissues causing pressure and damage to adjacent structures (3). The altered cell mass forms a growing area known as a tumor, which may be lumplike or diffuse and spreading. Tumors metastasize or travel around the body (4), setting up secondary tumors.

Development of lung cancer



Lung problems

Asbestosis A lung disease caused by the inhalation of fibers of the building material mineral asbestos (which exists in several forms). The fibers penetrate the lungs and encourage scar tissue to form around them. They eventually cause thickening of the lung tissue, and this interferes with its flexibility and gas-exchange functions.

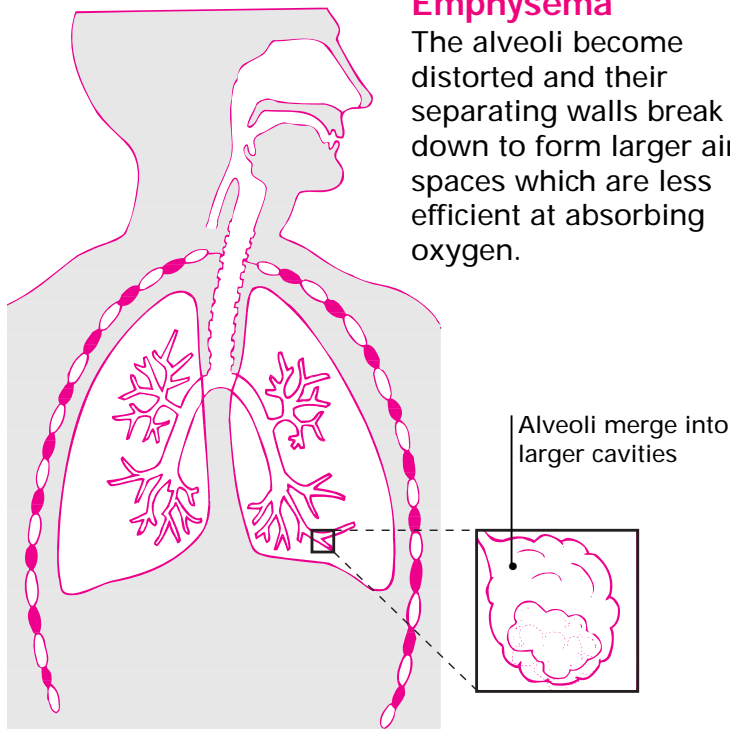
Cystic fibrosis A group of inherited or genetically transmitted conditions that involves oversecretion of a heavy mucus (thick, slimy fluid). It clogs the respiratory passages and interferes with oxygen absorption. The thick mucus cannot be shifted by the normal airway-clearing processes such as the beating of the cilia. It becomes stagnated and

so sufferers are more prone to catching respiratory infections.

Emphysema A disease in which the alveoli (tiny air sacs) of the lungs are damaged. Their separating walls are destroyed and the alveoli are enlarged and merge together. This leads to a decrease in the surface area available for gas exchange, and breathing becomes very difficult.

The major cause of emphysema is tobacco smoking, but pollution and hereditary factors may also be involved. A further group of causes includes inflicting high air pressure on the interior of the lungs by processes such as forceful blowing.

Infant respiratory distress syndrome (IRDS) A lung disorder that affects premature babies who have not developed surfactant in their lungs. Surfactant is a fatty secretion that lines the respiratory tree and prevents the lungs from collapsing. Its lack means that the airways and alveoli do not open readily just after birth.



Lung problems (continued)

Lung abscess An area of lung tissue that has broken down and become a pus-filled cavity. It is usually caused by inhalation of foreign material that gets trapped in the lung tissue, setting up infection and inflammation. Symptoms include coughing, fever, and chest pain. Untreated, the problem may lead to blood poisoning.

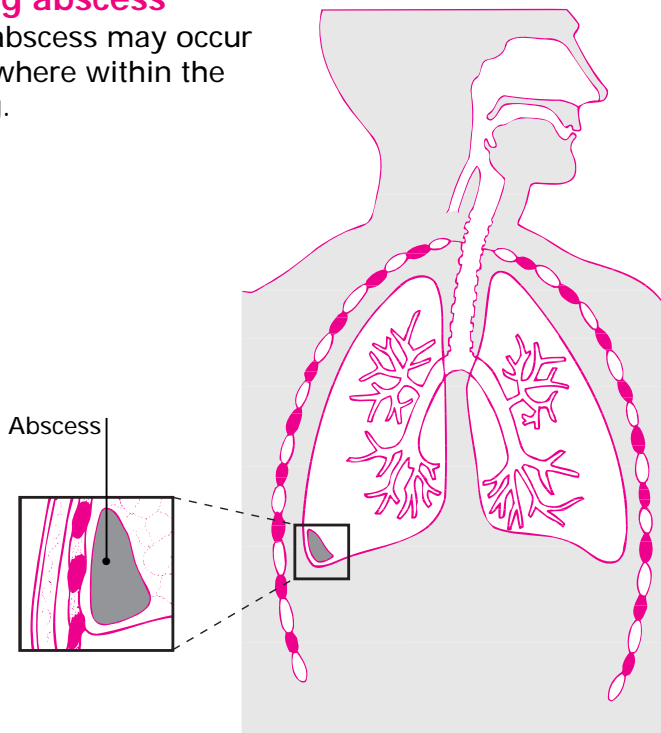
Treatment is usually with antibiotic drugs to quell the infection. Surgery may be needed to drain the abscess. Drainage tubes through the chest wall into the site may be left in place for a few days before the site is washed out with sterile solution. Scans or X-rays are taken regularly to check that the abscess site is fully drained.

Pulmonary embolism

A condition in which an embolus (blood clot, usually formed in a vein) breaks off and travels in the bloodstream. It enters a pulmonary artery which supplies blood to the lungs, and becomes stuck as this artery divides and narrows. It can result in pain and breathlessness, and in some cases, a medical emergency.

Lung abscess

An abscess may occur anywhere within the lung.



Mucus at birth

A newborn baby may be held upside down to allow fluid and mucus to drain from the respiratory system, in case of IRDS (see opposite).



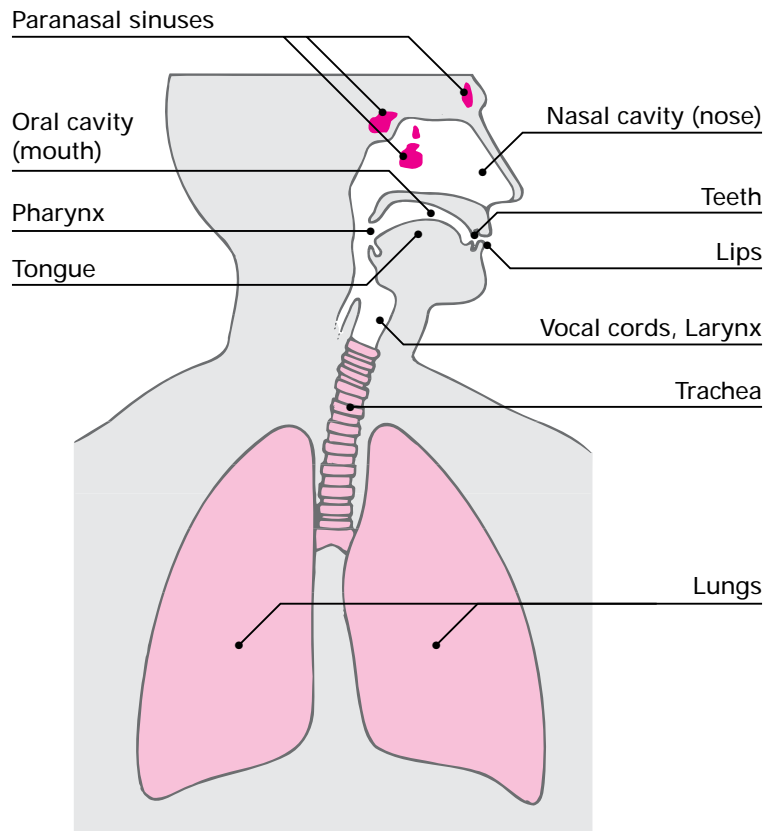
The respiratory system, as already discussed, has one central function that is vital to life. This is obtaining oxygen for the biochemical processes within cells that release energy from sugars. However the system also has several nonrespiratory functions. Perhaps the most noticeable of these in daily life is the production of sound and speech. This is based in the larynx, or voice box, but also involves other parts of the respiratory system (see also pages 48–49).

Range of the human voice

- The volume, or intensity of sounds, is measured in decibels, dB.
- A quiet whisper is 10–20 dB. Normal conversation is 50–60 dB. A loud scream exceeds 100 dB.

Organs of sound and speech

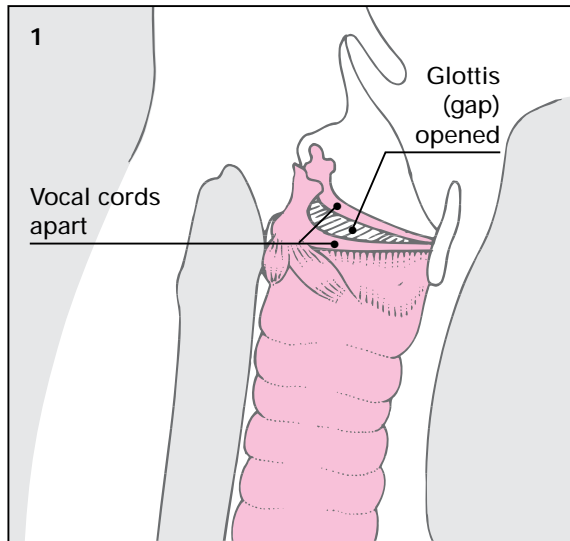
The vocal cords are also known as the vocal folds. They are shelflike projections rather than freely-vibrating “strings.” They consist of two fibrous sheets of tissue housed in the larynx (voice box) and are mainly responsible for the production of sounds. Other organs of sound production and speech include the mouth, tongue, teeth, lips, nose, paranasal sinuses, pharynx (throat), trachea (windpipe), lungs, the muscles of breathing, especially the diaphragm, and the muscles associated with the larynx, which alter the position of the vocal cords, and the amount of pull or tension which stretches them.



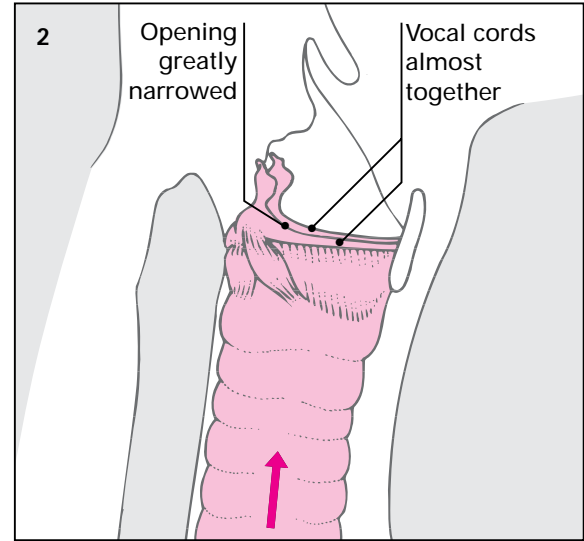
Sound production

Muscles in the larynx can stretch or relax the vocal cords. This narrows or widens the opening between them.

1 When we breathe, the vocal cords are relaxed so that air can pass silently.

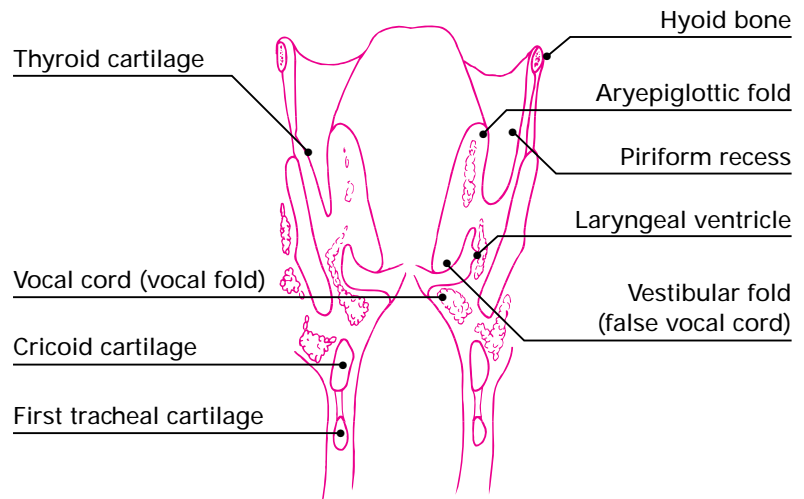


2 To speak, the larynx muscles stretch the cords, and the opening narrows. Air is forced from the lungs and up through the trachea. This vibrates the tensed cords, and sound is produced.



Larynx structure

The vocal cords or folds project from each side of the larynx. Above them are similar but less pronounced projections, vestibular folds or false vocal cords. Both sets of folds are held firmly yet able to move due to the skeleton of the larynx, which is composed of cartilaginous plates (see pages 50–51).



Speech production

Sounds produced by the vocal cords are turned into words by the lips, tongue, teeth, mouth, nose, pharynx, and soft palate. These organs help shape consonants and vowels by changing their shape and position.

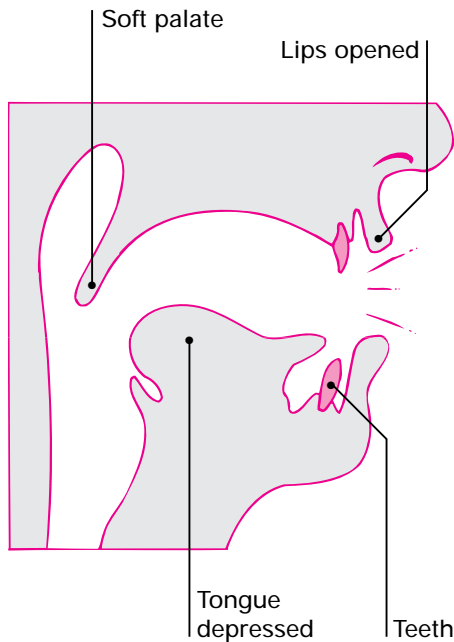
- The oral, nasal, and sinus cavities act as resonating chambers which give timbre (quality of tone) to the voice.
- The nose distinguishes certain nasal sounds such as "m," "n," and "ng." To produce these sounds, the soft palate is lowered to divert more air through the nasal cavity.

- The speed and acceleration of air movement is also important. The tongue's tip is placed just behind the upper front teeth and then pulled away to release air through the mouth to produce "th." The lips are closed and then opened to allow a sudden rush of air in the consonants "b" and "p."

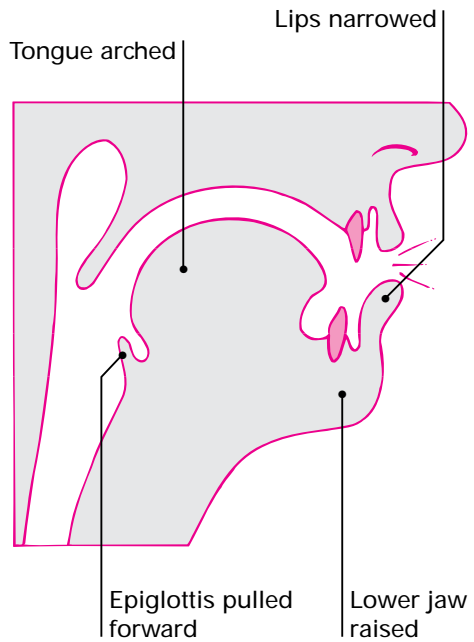
1 Diagram shows the position of the lips and tongue to produce an "ah" vowel sound.

2 Diagram shows the position of the lips and tongue to produce an "eye" vowel sound.

1



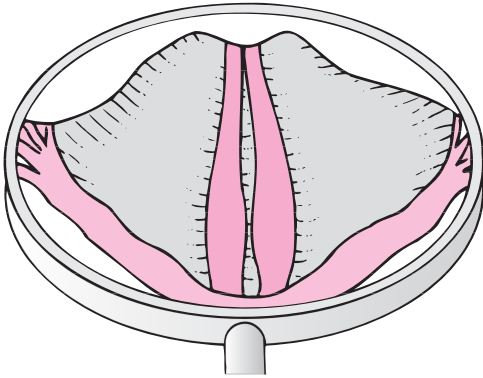
2



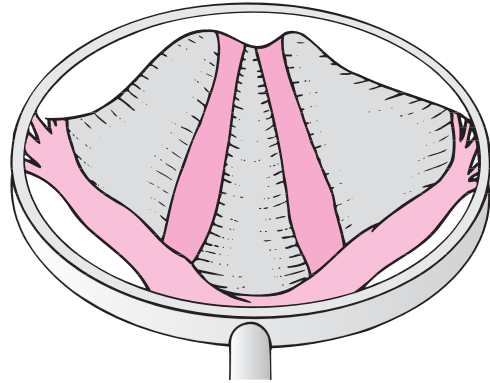
Pitch and volume

- The pitch (depth) of the voice is determined by the length and tension of the vocal cords. Men's voices are usually lower than women's because their vocal cords tend to be longer and looser. Tighter vocal cords produce a high-pitched sound. Relaxed vocal cords produce a deeper sound.
- The volume (loudness) of sounds produced depends on the energy with which the vocal cords vibrate. The greater the pressure used to exhale air from the lungs, and the higher the airflow speed, the greater the movements of the vocal cords and the louder the sound produced.

Vocal cords together for speech

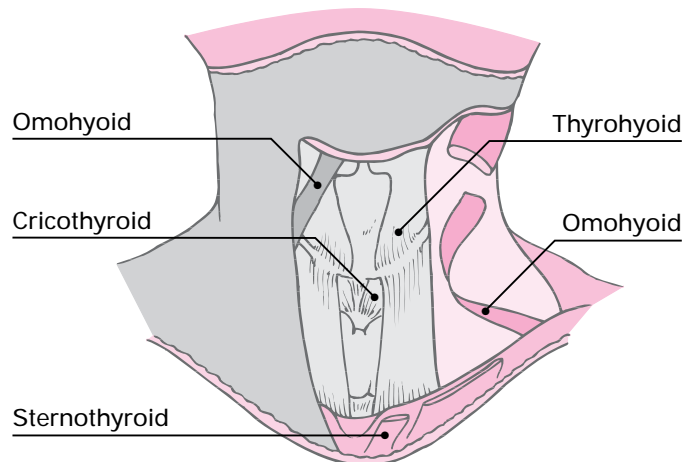


Vocal cords apart for normal breathing



Laryngeal musculature

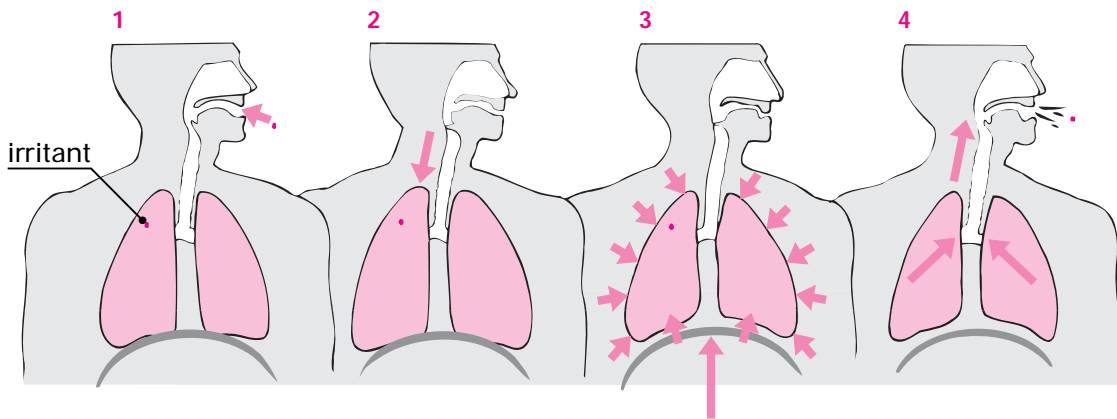
The larynx and its vocal cords are moved by about 20 major pairs of muscles and several single muscles (such as the transverse arytenoid). About ten pairs are within the larynx itself, connecting its various parts. Of the other ten pairs, some extend up to the head, and others extend down to the chest and shoulders.



Clearance of obstructions

Coughing, sneezing, and hiccups are automatic reflex reactions to problems within the respiratory system. Coughing and sneezing are designed to rid the respiratory tract of obstructions. They may be occasional isolated incidents when a small particle or airborne fragment enters the tract, and then lands on its sensitive mucosal lining. Nerve endings detect the presence of the foreign particles and initiate sneezing to clear them from the nasal cavity or nasopharynx (the upper part of the pharynx), or a cough to remove

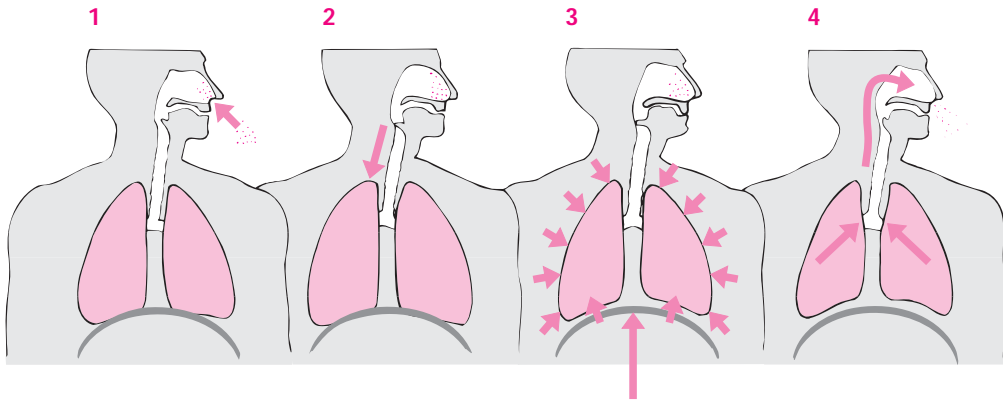
items from the lower pharynx, larynx, or below. Coughing and sneezing are symptoms of respiratory problems such as sore throat, common cold, and allergies such as hay fever (seasonal rhinitis). In these instances they are caused by overproduction of mucus by the respiratory lining. Hiccups (hiccoughs) are caused by spasms of the diaphragm, the domed muscle below the chest. There are several possible reasons why they occur, including pressure on the diaphragm or the nerves supplying it (see opposite).



Coughing

An irritant such as dust enters the upper respiratory tract and triggers the reflex coughing action. First a deep breath is taken and the lungs fill with air (1). The glottis (space between the vocal cords) closes within the larynx (voice box), sealing air in the trachea and lungs (2). The ribs and diaphragm

push against the lungs, raising the internal chest pressure (3). As the glottis opens a blast of air rushes up from the lungs (4), dislodging the irritant and associated mucus, and rattling the vocal cords to produce the coughing sound.



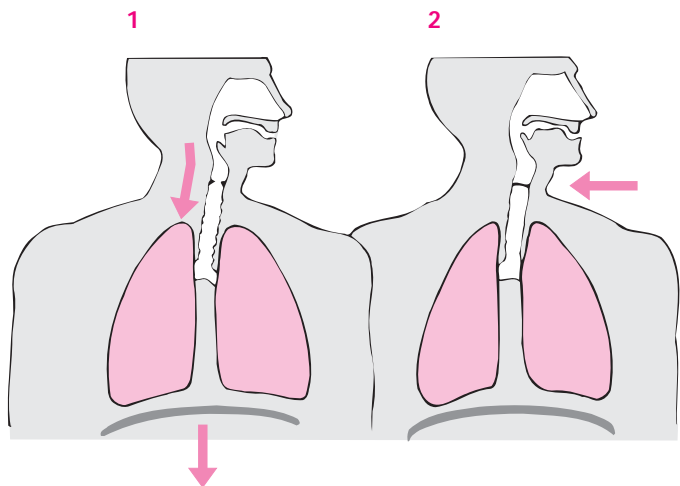
Sneezing

An irritant such as dust enters the nose (1) and triggers the reflex sneezing action. A deep breath is taken and the lungs fill with air (2). The ribs and diaphragm push suddenly against

the lungs (3), increasing air pressure within them. A blast of air rushes up from the lungs and expels the irritant and associated mucus through the nasal cavity (4).

Hiccups

The diaphragm contracts suddenly, causing a rapid and jerky inhalation of air. As this happens the vocal cords snap shut to produce a "hiccup" sound. The movement is then repeated a few seconds later. There are many possible cures for hiccups (see page 54). A common cause is eating or drinking copiously and quickly, so the stomach becomes very full and presses on the diaphragm just above.



Adipose tissue Connective tissue containing numerous fat cells.

Adrenal glands (*or* Suprarenal glands) Endocrine glands located on each kidney. The cortex and medulla produce a range of hormones.

Afferent Directed toward a central organ or part of the body.

Alimentary canal (*or* Gastrointestinal tract *or* Gut) The digestive tract: a tube starting at the mouth and ending at the anus.

Anus The lower end of the rectum, forming the outlet of the alimentary canal.

Aorta The largest artery, arising from the left ventricle of the heart.

Appendix (*or* Vermiform appendix) A short, wormlike tube opening into the cecum but closed at the other end. It contains lymphoid tissue, which is involved in immunity.

Arteriole A small artery supplying blood from a main artery to a capillary.

Artery A blood vessel transporting blood from the heart to elsewhere in the body.

Atrioventricular valve (*or* AV valve) A valve between a ventricle and an atrium. The right atrioventricular valve (*or* tricuspid valve) has three cusps. The left atrioventricular

valve (mitral valve or bicuspid valve) has two cusps.

Auditory Relating to hearing.

Axillary Relating to the armpit.

Backbone See **Vertebral column**.

Basal ganglia Paired structures deep in the forebrain: they help coordinate and control willed muscle movements.

Basophil A type of white blood cell that is readily stained by basic dyes.

Biceps A muscle with two heads: biceps brachii in the upper arm and biceps femoris in the thigh.

Bile ducts Tiny tubes that carry bile (a liver secretion) from the liver to the duodenum.

Bladder A sac, especially the muscular bag inside the pelvis where urine collects before being expelled from the body.

Blood A sticky red fluid consisting of colorless plasma, red blood cells (Erythrocytes), white blood cells (Leukocytes), and platelets (thrombocytes).

Blood pressure The pressure of blood against blood-vessel walls, especially artery walls.

Bone The hard, dense connective tissue that forms the skeleton's components.

Bone marrow Soft red and yellow substances that fill cavities in bone.

Bowel See **Large intestine**.

Brain The body's chief control center, consisting of billions of interconnected nerve cells.

Brainstem A stalklike part of the brain, between the cerebrum and spinal cord. It contains the midbrain, pons, and medulla oblongata.

Breast A female breast consists mainly of a mammary (milk-secreting) gland embedded in fatty tissue.

Breastbone See **Sternum**.

Bronchiole A small subdivision of a bronchus, ending in tiny air sacs called alveoli.

Bronchus The main tubes branching from the lower end of the trachea and forming the main airways to and from the lungs (plural: bronchi).

Capillary The tiniest type of blood vessel, connecting an arteriole and a venule.

Cardiac Relating to the heart.

Cardiovascular Relating to the heart and blood circulatory system.

Cartilage Gristle: dense, white connective tissue cushioning bones.

Cecum The first part of the large intestine, forming a blind pouch.

Cell The basic unit of the body, usually comprising an outer membrane, cytoplasm, a nucleus, and organelles.

Central nervous system

(CNS) The brain and spinal cord.

Cerebellum The largest part of the hindbrain. It helps coordinate muscular movements.

Cerebral cortex The cerebrum's thin outer layer of gray matter.

Cerebral hemisphere Either of the two halves of the cerebrum.

Cerebrospinal fluid A clear fluid filling the brain's ventricles and surrounding the brain and spinal cord to protect them from injury.

Cerebrum The upper, major part of the brain, comprising cerebral hemispheres and diencephalon.

Cervix A neck, especially the neck of the uterus (womb) where it opens into the vagina.

Clavicle Either of the two collarbones.

Clitoris An erectile, pea-sized organ above the opening of the vagina; it is highly sensitive and is involved in female sexual response.

CNS See **Central nervous system**.

Coccyx Four fused vertebrae forming the "tail" of the backbone.

Collagen A fibrous protein that is a major constituent of connective tissue.

Colon The part of the large intestine between the cecum and rectum.

Connective tissue Tissue that supports, binds, or separates more specialized body tissues or acts as packing.

Corium See **Dermis**.

Cornea The transparent circular area at the front of the eye, which acts as a lens.

Coronary arteries Supply the heart muscle.

Corpuscles A term often used for red and white blood cells.

Cortex The outer layer of the brain.

Cranial nerves Twelve pairs of nerves linking the underside of the brain with parts of the head, neck, and thorax.

Cranium The part of the skull that contains the brain.

Cutaneous Relating to the skin.

Cuticle See **Epidermis**.

Deoxyribonucleic acid (DNA) A nucleic acid in the cell's chromosomes containing the cell's coded genetic instructions.

Dermis (or **Corium**) The layer of skin below the epidermis, containing nerves, blood vessels, glands, and hair follicles.

Diaphragm A muscular sheet used in breathing. It separates the thorax (chest) and abdomen (belly).

Digestion The chemical and mechanical breakdown of foods into substances that can be absorbed by the body.

DNA See **Deoxyribonucleic acid**.

Duodenum The upper part of the small intestine, where most chemical digestion takes place.

Ejaculation The discharging of semen from the penis.

Endocardium The membrane that lines the heart and the heart valves.

Endothelium The cell layer that lines the inside of the heart, blood vessels, and lymph vessels.

Enzymes Biological catalysts: proteins that speed up chemical reactions without undergoing change themselves.

Epidermis (or **Cuticle**) The skin's outer layer.

Epiglottis A cartilage flap behind the tongue that is closed during swallowing to stop food from entering the larynx.

Epiphysis See **Pineal gland**.

Epithelium The cell layer covering the body, and lining the alimentary canal and respiratory and urinary tracts.

Erythrocytes Red blood cells.

Esophagus (or **Gullet**) The muscular tube through which food travels between the pharynx and the stomach.

Fallopian tubes (or Uterine tubes or Oviducts) The tubes through which ova (eggs) travel from the ovaries to the uterus.

Femur The thigh bone: the long bone between the hip and the knee.

Follicle A small secreting cavity or sac. Ova (egg cells) develop in follicles in the female ovaries.

Forebrain The front part of the brain comprising diencephalon and telencephalon.

Gallbladder A pear-shaped bag where bile is stored, below the liver.

Gametes Sex cells: sperm in males; ova in females.

Gastric Of the stomach.

Gastrointestinal tract See **Alimentary canal**.

Genes Basic biological hereditary units, consisting of DNA, located on chromosomes.

Genitalia Sex organs.

Gland A structure that synthesizes and secretes a fluid.

Gonads Primary reproductive organs: the ovaries and testes.

Granulocytes White blood cells with cytoplasm that contains granules: basophils, eosinophils, and monocytes.

Gray matter The darker tissue of the brain and spinal cord mainly consisting of neurons' cell bodies and dendrites.

Gullet See **Esophagus**.

Gut See **Alimentary canal**.

Heart The hollow, muscular, fist-sized organ that pumps blood around the body.

Hemoglobin The iron-rich, oxygen-transporting pigment in red blood cells that gives them their color.

Hepatic Relating to the liver.

Hepatic portal vein See **Portal vein**.

Hindbrain Brain structures below the midbrain, comprising the pons, medulla oblongata, and cerebellum.

Hormones Chemical substances released into the blood by endocrine glands to influence organs or tissues in other parts of the body.

Hypophysis See **Pituitary gland**.

Hypothalamus A part of the brain with endocrine functions.

Ileum The last part of the small intestine.

Immune system The body's defense system against infective organisms or other foreign bodies. It includes the lymphatic system.

Involuntary muscle Muscle that is not under conscious control. See also **Smooth muscle**.

Jejunum The middle part of the small intestine.

Joint The junction between bones.

Karyotype The chromosome complement of a person or species: the genome.

Kidney A bean-shaped organ that filters wastes from blood to form urine.

Lactation Milk production by the mammary glands.

Large intestine (or Bowel) The lower part of the alimentary canal, comprising the cecum, colon, and rectum.

Larynx The cartilaginous voice box.

Leukocytes White blood cells. They attack invading microorganisms and help to combat injuries.

Ligament Fibrous tissue that connects bones.

Liver The largest organ in the body, it is involved in various metabolic processes.

Lungs The two organs of respiration, filling most of the chest cavity inside the rib cage and above the diaphragm.

Lymph A transparent fluid that leaks from blood vessels into tissue spaces.

Lymph gland See **Lymph node**.

Lymph node (or Lymph gland) One of the "knots" in the lymphatic system, which contain lymphocytes and macrophages that filter the lymph passing through the nodes.

Lymphatic system A network of lymph vessels and lymph nodes. Vessels collect lymph from body tissues and return it to the blood after harmful substances have been filtered out in the lymph nodes.

Mammary glands The milk-producing structures in the breast.

Medulla oblongata The lowest part of the brain stem, containing the vital centers that control heartbeat and respiration.

Meiosis A type of cell division that produces daughter cells (sperm and ova) each with half as many chromosomes as the parent cell.

Meninges Three protective membranes surrounding the brain and spinal cord.

Menopause When a woman ceases to have menstrual periods.

Menstruation Menstrual periods: the monthly flow of blood and uterine lining from the vagina of nonpregnant females of childbearing age.

Metabolism The array of continuous chemical changes that maintain life in the body.

Mitosis Ordinary cell division in which both daughter cells have as many chromosomes as the parent cell.

Mucous membranes The mucus-secreting linings of the

digestive, respiratory, reproductive, and urinary tracts.

Nasal Relating to the nose.

Nasal cavity The space inside the nose between the base of the skull and the roof of the mouth.

Nerve A bundle of nerve fibers (axons) that transmit impulses to (in the case of sensory nerves) or from (in the case of motor nerves) the central nervous system.

Nervous system The coordinated networks of neurons that control the body. It is divided into the central nervous system (brain and spinal cord), and the peripheral nervous system (the somatic and autonomic nervous systems).

Neuron (*or* Neurone) A nerve cell: the basic unit of the nervous system.

Neurone *See* **Neuron**.

Neurotransmitter A chemical released at nerve endings to transmit nerve impulses across synapses.

Nucleic acids Molecules that store genetic information.

Nucleus The control center of a cell, which contains coded genetic instructions.

Olfactory Relating to smell.

Optic Relating to the eye.

Organ A body part with different types of tissue that performs a particular task.

Organelles Tiny structures (miniorgans) in a cell's cytoplasm with particular tasks.

Ovaries Female sex organs that produce ova (eggs) and sex hormones.

Oviducts *See* **Fallopian tubes**.

Ovulation The release of a ripe egg from a female's ovary.

Ovum An egg; a female sex cell (plural: ova).

Palate The roof of the mouth.

Pancreas An abdominal organ that produces pancreatic juice and the hormones glucagon and insulin.

Parasympathetic nervous system The part of the autonomic nervous system that predominates when the body is at rest.

Parathyroid glands Four pea-sized endocrine glands on the thyroid gland. They produce parathyroid hormone, which controls blood calcium level.

Pelvis A bony basin formed by the two hip bones, the sacrum, and the coccyx.

Pericardium The double-layered membrane that encloses the heart and attaches it to the diaphragm and sternum.

Peristalsis Waves of muscular contraction that propel substances through passageways, such as the alimentary canal.

Phagocytes Types of leukocytes that engulf and destroy microorganisms and foreign bodies.

Pharynx The throat.

Pineal gland (or Epiphysis) An endocrine gland in the brain that secretes melatonin.

Pituitary gland (or Hypophysis) A three-lobed, pea-sized gland below the hypothalamus. It produces growth hormone, hormones that act on other endocrine glands, oxytocin, and ADH. It is often called the body's "master gland."

Plasma The fluid part of blood.

Pleura The membrane that covers the lungs (visceral pleura) and lines the chest wall (parietal pleura).

Plexus A network of nerves (or blood or lymph vessels).

Portal vein (or Hepatic portal vein) Drains blood from digestive organs to the liver.

Prostate gland A gland situated below the bladder in males. It produces a sperm-activating fluid that forms nearly a third of the semen's volume.

Pudendum See **Vulva**.

Pulmonary Relating to the lungs.

Receptor A structure, such as a sensory nerve ending, specialized to detect environmental stimuli.

Rectum The last part of the colon, where feces collects before leaving the body.

Reflex action The body's automatic response to a stimulus, such as blinking.

Renal Relating to the kidney.

Respiration 1) Breathing; 2) Taking in oxygen and giving out carbon dioxide; 3) Deriving energy from food with or without using oxygen.

Respiratory system In humans, the mouth, nose, pharynx, larynx, trachea, bronchi, bronchioles, alveoli, and lungs.

Ribonucleic acid (RNA) A nucleic acid concerned with protein synthesis.

Ribs Twelve pairs of bones that protect the chest cavity and assist breathing by moving up and out during inspiration and down and in during expiration.

Salivary glands The lingual, parotid, sublingual, and submandibular glands that produce saliva.

Serum Blood plasma that does not contain clotting factors but does contain antibodies.

Sinus A cavity, such as the channels draining venous blood from the brain.

Skeleton The bony framework that protects and supports the body's soft tissues.

Skin The body's waterproof covering; its largest organ, comprising two main layers: the epidermis and dermis.

Small intestine The alimentary canal between the stomach and large intestine, comprising the duodenum, jejunum, and ileum. Most digestion occurs here.

Smooth muscle (or Unstriated muscle or Involuntary muscle) Muscle without striped fibers that automatically operates internal organs such as the stomach, bladder, and blood vessels.

Sphincter A ring-shaped muscle that contracts to close an orifice.

Spinal cord The cable of nerve tissue running down inside the vertebral column (spine) and linking the brain with nerves supplying most of the body.

Spine See **Vertebral column**.

Sternum The breastbone.

Subcutaneous tissue The sheet of connective tissue below the dermis.

Suprarenal glands See **Adrenal glands**.

Suture An immovable fibrous joint between the skull bones.

Taste buds Tiny sensory organs of the tongue and palate, distinguishing salty, sweet, sour, and bitter tastes.

Teeth Bonelike structures in the jaws. Different types (incisors, canines, premolars, molars) are specialized to tear, crush, and/or grind food.

Tendons Bands of fibrous connective tissue joining muscles to bones.

Testis (*or* Testicle) One of a pair of primary male sex organs that manufacture sperm (plural: testes).

Thalamus A brain structure above the hypothalamus. It sends sensory impulses to the cerebral cortex, links sensations with emotions, and affects consciousness.

Thymus An endocrine gland located behind the sternum. It produces thymosin.

Thyroid An endocrine gland at the front of the neck, producing thyroid hormone.

Tissue A collection of similar cells that perform a particular task.

Trachea (*or* Windpipe) The tube between the larynx and the bronchi.

Tubule A tiny tube.

Tunica A tissue layer forming a coating. Blood vessels have three such layers (intima, media, adventitia).

Unstriated muscle *See* **Smooth muscle**.

Ureter The tube conveying urine from a kidney to the bladder.

Urethra The passage taking urine from the bladder to the body's exterior.

Urinary system The kidneys, ureters, bladder, and urethra.

Urine Liquid waste excreted by the kidneys.

Uterine tubes *See* **Fallopian tubes**.

Uterus (*or* Womb) A hollow muscular organ located above the bladder. Inside it, a fertilized ovum develops into a fetus.

Uvula A conical tag hanging from the back of the palate. It helps to keep food out of the nasal cavities.

Vagina The muscular passage between the vulva and cervix (neck of the uterus).

Vascular Relating to or richly supplied with vessels, especially blood vessels.

Vein A blood vessel that transports blood from capillaries back to the heart. Veins contain valves to prevent the backflow of blood.

Venous Relating to veins.

Ventricle A cavity: one of the two lower chambers of the heart.

Venule A small vein.

Vermiform appendix *See* **Appendix**.

Vertebra A bone of the vertebral column (plural: vertebrae).

Vertebral column (*or* Backbone *or* Spine) The column of vertebrae between the skull and the hip bones, supporting the body and shielding the spinal cord. It has five sections: cervical, thoracic, lumbar, sacral, and coccygeal.

Vestibule A space before a passage begins, as in the inner ear beyond the oval window, between the semicircular ducts and cochlea.

Vocal cords Two belts of tissue stretched across the larynx which produce sounds when air rushes past them.

Vulva (*or* Pudendum) The external female genitals.

White matter The paler tissue of the brain and spinal cord comprised mainly of myelin-sheathed nerve fibers.

Windpipe *See* **Trachea**.

Womb *See* **Uterus**.

There is a lot of useful information on the internet. There are also many sites that are fun to use. Remember that you may be able to get information on a particular topic by using a search engine such as Google (<http://www.google.com>). Some of the sites that are found in this way may be very useful, others not. Below is a selection of Web sites related to the material covered by this book. Most are illustrated, and they are mainly of the type that provides useful facts.

Facts On File, Inc. *takes no responsibility for the information contained within these Web sites. All the sites were accessible in January 2005.*

Anatomy of the Human Body: Gray's Anatomy

Online version of the classic *Gray's Anatomy of the Human Body*, containing over 13,000 entries and 1,200 images.
<http://www.bartleby.com/107/>

Biology Online

A source for biological information, suitable for homework, research projects, and general interest, with hundreds of biology Web site links.
<http://www.biology-online.org>

BIOME

A guide to selected, quality-checked internet resources in the health and life sciences.
<http://biome.ac.uk>

Health Sciences & Human Services Library

Provides links to selected Web sites that may be useful to both students and researchers.
<http://www.hshsl.umaryland.edu/resources/lifesciences.html>

Human Anatomy Online

Interactive resource, with visual keys to text on the human body.
<http://www.innerbody.com>

North Harris College Biology Department

Tutorials and graphics on biology, human anatomy, human physiology, microbiology, and nutrition.
<http://science.nhmccd.edu/biol/>

Open Directory Project: Pulmonary Medicine

Comprehensive list of internet resources.
http://dmoz.org/Health/Medicine/Medical_Specialties/Pulmonary_Medicine/

Open Directory Project: Respiratory Disorders

Comprehensive list of internet resources.
http://dmoz.org/Health/Conditions_and_Diseases/Respiratory_Disorders/

The Biology Project

Structured tutorials on life sciences. Particularly strong on cell biology, human biology, and molecular biology.
<http://www.biology.arizona.edu>

University of Texas: BioTech Life Sciences Resources and Reference Tools

Enriching knowledge of biology and chemistry, for everyone from high school students to professional researchers. The Dictionary and Science Resources are particularly useful.
<http://biotech.icmb.utexas.edu>

A

adenoids 54
aerobic respiration 8
aerobic exercises 22–27
air
 breathing 12, 13
 composition 84
 larynx 39
 lung function 81
 mucosa 40
 pharynx 38
 respiration 10
 respiratory system 6
 URT (upper respiratory tract) 36, 37
alar cartilages 42, 43, 44
allergies 34–35
 breathing control 21
 coughing 100
 URT disorders 53
alveoli 7, 16, 17
 bronchial tree 76
 bronchioles 78, 79
 gas exchange 84
 lower respiratory tract 19
 lung disorders 94
 lung function 80, 81
 lung structure 73
 respiration 82
anaerobic respiration 8
anterior abdominal wall
 muscles 15
asbestosis 94
asthma 32, 35
auditory (Eustachian) tube 45

B

bacteria 18
 diseases and disorders 32, 52, 53

 mucosa 40, 41
 smoking 29
 trachea 67
blood
 alveoli 79
 carbon dioxide transport 88
 components 87
 exercise 23
 gas exchange 84, 85
 lung function 10, 80, 81
 oxygen transport 86
 pulmonary vessels 70
 respiration 82
 respiratory system 6
 smoking 22
 tissues 11
 URT 37
blood vessels
 alveoli 73
 chemoreceptors 20
 chest 56, 59, 60
 heart-lung complex 70, 71
 lung function 81
 pulmonary circulation 90, 91
 respiratory system 16
 smoking 29, 30
 URT disorders 52
brain 20
breathing (bodily respiration) 6, 10, 12–13
 chest 58
 control 20–21
 lungs 69, 80
 pleurae 64, 75
 speech 96, 97
 thoracic muscles 65
bronchi 9, 16, 17, 64
 bronchial tree 76–77
 bronchioles 78

 chest 60
 diseases 32
 lower respiratory tract 19
 lung disorders 92
 lung structure 72
 respiratory system 6, 7, 8
 trachea 66, 67
bronchioles 7, 8, 16, 17, 78
bronchial tree 76, 78
gas exchange 84
lower respiratory tract 19
lungs 69, 72, 73, 80, 81
mucosa 40
bronchitis 32, 33, 35

C

cancer 92, 93
carbon dioxide
 air composition 84
 alveoli 7
 blood 86, 87
 breathing control 20
 lung function 81
 lungs 10
 pulmonary blood vessels 90
 red blood cells 83, 85
 respiration 82
 respiratory system 6
 smoking 22
 tissues 11
 transport 88–89
carotid artery 16
cellular respiration 6, 11, 82, 85
chest (thorax) 8, 56–67
 breathing 12–13
 lung structure 72
 pleurae 74, 75

respiratory system 6, 7
 thoracic cage 62–63
 choking 32
 chondrocytes 67
 cilia
 lung disorders 93, 94
 lung function 81
 lung structure 72
 mucosa 40, 41
 smoking 28
 trachea 66, 67
 clavicle 62, 63
 common cold 18, 35, 52,
 54, 55, 100
 coughing 21, 32, 100
 lung disorders 95
 smoking 29
 URT disorders 52, 53
 cycling 23
 cystic fibrosis 33, 92, 94

D

diaphragm 7, 8, 9, 16, 17
 breathing 12, 13, 14, 15
 chest 56, 59
 coughing 100
 lungs 68
 sneezing 101
 speech 96
 thoracic cage 63, 64
 URT disorders 54
 diffusion 12, 82, 84, 86
 disorders 32–33, 64
 lungs 92–95
 smoking 30, 31
 URT 52–55

E

emotion 20, 21
 emphysema 20, 94
 energy release 8, 11, 82, 85
 epiglottis 46, 47, 49, 50, 51

epithelium 8
 alveoli 79
 mucus 6, 41
 ethmoid bone 44
 exercise, aerobic 22–27
 exhalation 7, 8, 10, 12, 13,
 15
 breathing rate 20
 chest 58, 59
 lung function 80

F

fitness 23, 24, 25, 26, 27

G

gas exchange
 lower respiratory tract
 19
 lung disorders 94
 lungs 10, 80, 81
 respiration 82
 tissues 11

glycolysis 85
 goblet cells 6, 40, 67
 gymnasium exercises 27

H

hay fever (seasonal
 rhinitis) 35
 heart
 chest 56, 57, 60, 62
 exercise 22, 23, 25, 26,
 27
 lungs 69
 pleurae 74
 pulmonary blood
 vessels 90, 91
 smoking 29, 30
 heart-lung complex 70–71
 hemoglobin 83, 86, 88
 hiccups 54, 100, 101
 hyoid bone 46, 48, 49, 50

I

infant respiratory distress
 syndrome (IRDS) 94, 95
 infections 18, 32
 lung disorders 94, 95
 smoking 29
 URT disorders 52
 inferior phrenic nerves 16
 influenza 32, 35
 inhalation (inspiration) 8,
 10, 12, 14
 breathing rate 20
 chest 58
 gas exchange 84
 lung function 80
 thoracic muscles 65
 intercostal muscles 7, 8
 breathing 12, 13, 14
 chest 58, 59, 63
 nerves 17
 involuntary breathing
 control 20

J

jogging 23, 25, 26
 jugular vein 16
 jumping 25

L

laryngeal blood vessels 16
 laryngitis 53
 larynx (voice box) 6, 7, 8,
 16, 17, 39, 48–51, 66, 97
 bronchial tree 76, 77
 coughing 100
 mucosa 40
 speech 96, 97, 99
 URT 18, 36, 53
 latissimus dorsi muscle 15
 levator scapulae muscle 15
 levatores costarum
 muscles 14

lower respiratory tract 7, 19
 lungs 7, 8, 9, 17, 64, 68–95
 blood vessels 16
 breathing 12, 13, 21
 bronchial tree 76, 77
 chest 56, 57, 59, 60
 coughing 100
 disorders 32, 52, 92–95
 exercise 22, 23, 25, 26, 27
 function 80–81
 gas exchange 84–85
 gas transport 11, 86, 89
 heart 70–71
 lower respiratory tract 19
 nerves 16
 pleurae 74, 75
 position 68
 pulmonary blood
 vessels 90, 91
 red blood cells 83
 respiration 10, 82
 smoking 28–29, 30
 sneezing 101
 speech 97, 99
 structure 72–73
 surface 69
 thoracic cage 62
 thoracic muscles 65
 trachea 66

M

maxillary nerve 16
 meatus 44, 45
 mouth (oral cavity),
 pharynx 38
 smoking 28, 30
 speech 96, 98
 mucus and mucosa 6, 8,
 40–41
 at birth 95
 coughing 100

larynx 39
 lung disorders 94
 lungs 72, 81
 pharynx 38
 smoking 28, 29
 sneezing 101
 trachea 66, 67
 URT 36, 37
 URT disorders 52, 53, 54
 muscles 14–15
 breathing 7, 8, 10, 12, 13
 bronchioles 78
 chest 58, 59, 61
 exercise 23, 26, 27
 larynx 50, 51
 nerves 17
 nose 43
 pharynx 47
 respiratory system 6
 smoking 22, 29
 speech 48, 96, 97, 99
 thorax 63, 65
 trachea 66

N

nasal cartilages 42, 44
 nasal polyps 55
 nasolacrimal duct 45
 nerves 16–17, 59
 breathing rate 20
 reflexes 100
 smoking 28
 nicotine 28, 29, 30, 31
 nose 6, 7, 8, 42–45
 allergies 34, 35
 disorders 32, 52, 53, 54, 55
 mucosa 40
 pharynx 38
 sneezing 101

speech 96, 98
 URT 18, 36, 37
 nosebleeds 52, 53

O

olfactory nerve 16, 37
 overweight 22
 oxygen
 air 84
 alveoli 7, 79
 blood components 87
 breathing control 20
 diseases 32, 92
 exercise 23
 gas exchange 84
 lung function 81
 lungs 10, 90
 pulmonary circulation
 90, 91
 respiration 8, 82
 respiratory system 6
 smoking 22, 30
 tissues 11, 90
 transport 83, 86–87
 URT 36

P

passive smoking 30
 pectoralis muscles 15, 61
 phagocytes 28
 pharynx (throat) 6, 7, 8, 17
 allergies 34
 anatomy 46
 blood vessels 16
 coughing 100
 disorders 52
 functions 38
 mucosa 40, 41
 nerves 16
 smoking 30
 soft tissues 47
 speech 96, 98

trachea 66
 URT 18, 36, 37
 phrenic nerve 16
 pleurae 7, 8, 62, 64,
 74–75
 alveoli 79
 lung disorders 92
 lung function 80
 lung structure 72
 pneumonia 32, 33, 35, 92
 pollution 6, 28, 31, 35, 92,
 94
 pregnancy, smoking 28, 30,
 31
 pulmonary blood vessels
 8, 16, 90–91
 alveoli 79
 bronchial tree 77
 bronchioles 78
 chest 56, 60
 gas exchange 84
 lung disorders 95
 lungs 69, 70, 71
 pulmonary embolism 95
 pulmonary plexus 16

Q

quadratus lumborum
 muscle 15

R

rectus abdominis muscle
 65
 red blood cells 87
 carbon dioxide transport
 85, 88, 89
 oxygen transport 83,
 86
 reflex actions 21, 100, 101
 respiration 8, 10–11, 82–83
 control 20–21
 gas transport 86, 88

respiratory system 6–7, 9,
 56
 diseases 32, 33
 exercise 22, 23, 24
 rhinitis 35
 rhomboideus muscle 15
 ribs 8, 9
 breathing 12, 13, 14, 15
 chest 57, 58, 59, 60, 61
 muscles 65
 nerves 17
 pleurae 74
 sneezing 101
 thoracic cage 62–63
 running 25, 26

S

scalenus muscles 14, 65
 scapula 15
 septal cartilage 43, 44
 serratus muscles 14, 15, 61
 sinuses 7, 8, 18, 36, 44, 45
 speech 96, 98
 URT disorders 52, 53, 54
 smell 36, 37
 smoking 22, 28–31
 allergies 35
 diseases 33, 92, 93, 94
 sneezing 21, 54, 100, 101
 sore throat 18, 32, 54, 100
 speech 48, 96–99
 larynx 39
 pharynx 38
 URT 36, 37
 sphenoid bone 44
 spinal column 63
 sternocleidomastoid
 muscle 14, 65
 sternohyoid muscle 65
 sternothyroid muscle 65
 sternum 12, 17, 62, 63, 74,
 75

subclavius muscle 65
 superior concha 44
 surfactant 73, 79, 81, 94
 swimming 23
 systemic circulation 90

T

teeth 96, 98
 thyroid blood vessels 16
 tongue 96, 98
 tonsils 38, 47, 54
 trachea (windpipe) 6, 7, 8,
 9, 64, 66–67
 bronchial tree 76, 77
 chest 60
 lower respiratory tract
 19
 lung function 80
 mucosa 40
 speech 96, 97
 trapezius muscle 15
 trigeminal nerve 16
 tuberculosis 32

U

upper respiratory tract
 (URT) 7, 18, 36–55
 uvula 46

V

ventilation 10
 viruses 18, 29, 32, 52, 54
 voluntary breathing control
 20
 vomer 44

W

walking 23, 24, 26
 water 6, 7, 37
 whooping cough 32, 33