

# WHO STANDARD ACUPUNCTURE POINT LOCATIONS IN THE WESTERN PACIFIC REGION



World Health  
Organization

Western Pacific Region

WHO STANDARD  
ACUPUNCTURE POINT LOCATIONS  
IN THE WESTERN PACIFIC REGION

Updated and Reprinted 2009

WHO Library Cataloguing in Publication Data

WHO Standard Acupuncture Point Locations in the Western Pacific Region

1. Medicine, Traditional. 2. Acupuncture Point Locations

ISBN 978 92 9061 248 7

(NLM Classification: WB50)

© World Health Organization (2008)

Publications of the World Health Organization enjoy copyright protection in accordance with the provisions of Protocol 2 of the Universal Copyright Convention. For rights of reproduction or translation of WHO publications, in part or *in toto*, application should be made to the Office of Publications, World Health Organization, Geneva, Switzerland, or to the Regional Office for the Western Pacific, Manila, Philippines. The World Health Organization welcomes such applications.

The designations employed and the presentation of the material in this publication do not imply the expression of any opinion whatsoever on the part of the Secretariat of the World Health Organization concerning the legal status of any country, territory, city or area or of its authorities, or concerning the delimitation of its frontiers or boundaries.

The mention of specific companies or of certain manufacturers' products does not imply that they are endorsed or recommended by the World Health Organization in preference to others of a similar nature that are not mentioned. Errors and omissions excepted, the names of proprietary products are distinguished by initial capital letters.

The authors alone are responsible for the views expressed in this publication.

# TABLE OF CONTENTS

---

FOREWORD	v
ACKNOWLEDGEMENTS	vii
GENERAL GUIDELINES FOR ACUPUNCTURE POINT LOCATIONS	1
WHO STANDARD ACUPUNCTURE POINT LOCATIONS	23
Lung Meridian	25
Large Intestine Meridian	33
Stomach Meridian	45
Spleen Meridian	69
Heart Meridian	81
Small Intestine Meridian	87
Bladder Meridian	99
Kidney Meridian	135
Pericardium Meridian	151
Triple Energizer Meridian	157
Gallbladder Meridian	171
Liver Meridian	195
Governor Vessel	203
Conception Vessel	219
REFERENCES	233
ANNEX	235

# FOREWORD

---

Along with herbal medicine, acupuncture has been used for more than 2500 years as one of the main pillars of traditional medicine in the Western Pacific Region. Accordingly, the WHO Regional Committee for the Western Pacific adopted resolutions supporting the proper use of acupuncture and herbal medicine in 1985 and 1987.

With the aim of standardization in the field of acupuncture, the WHO Regional Office for the Western Pacific organized a Working Group for the Standardization of Acupuncture Nomenclature in 1981 and, after 10 years of effort, a consensus was reached on the proposed standard international acupuncture nomenclature. In 1991, *A Proposed Standard International Acupuncture Nomenclature* was published by WHO Headquarters and a revised edition of *Standard Acupuncture Nomenclature* was published by the WHO Regional Office for the Western Pacific.

It was reported, however, that there was controversy among Member States regarding approximately one-fourth of regular acupuncture point locations, raising doubts and uncertainty regarding the efficacy and safety of acupuncture treatment. It is not known when this disparity in location of acupuncture points first arose but, in recent decades, there has been a growing international demand for standardization of acupuncture point locations for education, research and clinical practice. However, since each Member State has its own initiatives and traditions, international standardization of acupuncture point locations has proved extremely difficult.

As an initial step in standardizing acupuncture point locations, the WHO Western Pacific Regional Office convened the first Informal Consultation on the Development of WHO Standard of Acupuncture Point Locations in October 2003. Experts from China, Japan and the Republic of Korea attended that consultation, and 10 further serial meetings were organized subsequently by the Regional Office. In the beginning, it appeared it would be almost impossible to harmonize the activities of the various participants. However, with the passing of time and the development of mutual understanding and trust, the experts managed to reach a consensus on most of the controversial acupuncture point locations, one by one. It took three years to achieve a set of internationally unified acupuncture point locations, an effort that has provided a firm and solid basis in the field of acupuncture.

Recently, modern scientific apparatus, such as functional magnetic resonance imaging (f-MRI) and positron emission tomography (PET) has been utilized for acupuncture research. However, that research has not focused on developing standard acupuncture point locations. Therefore, the experts taking part in the consultations agreed on the development of principles and methods by combining document analysis, experts' clinical experiences and factual measurements. Their efforts and the resulting outcomes will further enhance scientific research on acupuncture point locations.

I would like to highlight that the experts involved in this project will be remembered, not just for standardizing acupuncture point locations, but also for building team spirit among international scholars in the field of traditional medicine.

**Shigeru Omi, MD, Ph.D.**  
Regional Director

# ACKNOWLEDGEMENTS

---

The World Health Organization, Regional Office for the Western Pacific expresses its appreciation to all those who contributed to the production of this document.

The Regional Office recognizes the experts who supported and attended eleven serial meetings on developing standard of acupuncture point locations such as Professor Wang Xuetai, Professor Huang Longxiang, Professor Shuichi KATAI, Professor Shoji SHINOHARA, Professor Kang Sung-keel and Professor Kim Yong-suk.

We also wish to extend our gratitude to the Ministry for Health, Welfare and Family Affairs, Republic of Korea for their financial support, to the State Administration of Traditional Chinese Medicine, China, the Japan Liaison of Oriental Medicine, the World Federation of Acupuncture and Moxibustion Societies, the Institute of Acupuncture and Moxibustion of the China Academy of Chinese Medical Sciences, the Korean Society for Meridian and Acupoint, and IDO-NO-NIPPON-SHA with the 2nd Japan Acupuncture Point Committee for their technical supports.

# GENERAL GUIDELINES FOR ACUPUNCTURE POINT LOCATIONS

---

## PREFACE

Acupuncture has been practised for more than 2500 years in the Western Pacific Region and has become a global therapeutic method in recent decades. However, it was reported that acupuncturists differed by up to 25% in the acupuncture points they used, raising doubts and uncertainty regarding the efficacy and safety of acupuncture treatment, as well as causing difficulties in the fields of acupuncture research and education. Member States therefore increasingly began to demand standardization in acupuncture point locations. Responding to this request, the WHO Western Pacific Regional Office initiated a project to reach consensus on acupuncture point locations and thus convened 11 serial meetings, resulting in these guidelines.

The standard for acupuncture point names used in the guidelines is based on WHO 90/8579-Atar-8000, *A Proposed Standard for International Acupuncture Nomenclature*. However, while standardized measurement systems for length and width generally require adoption of an international unit system, it is impossible to use any absolute standard value to determine the location of acupuncture points on the human body due to the vast differences in peoples' sizes and heights. Only by using the Equal Proportional Measurement method, also known as the Proportional Bone (Skeletal) Measurement method, can the proper location of acupuncture points be established for all population groups and individuals. This method was adopted by WHO as the standard measuring unit for acupuncture points at an international conference held in Seoul, Republic of Korea, in 1987. This measuring unit has therefore been adopted in these guidelines for location of acupuncture points.

## I. Scope

This Standard stipulates the methodology for locating acupuncture points on the surface of the human body, as well as the locations of 361 acupuncture points. The Standard is applicable for teaching, research, clinical service, publication and academic exchanges involving acupuncture.

## II. Terms and definitions

The following terms and definitions are used in this Standard.

### 1. Standard measuring units:

#### Proportional bone (skeletal) cun (B-cun)

This method divides the height of the human body into 75 equal units. Using joints on the surface of the body as the primary landmarks, the length and width of every body part is measured by such proportions. The specific method is: divide the height of the human body into 75 equal units, then estimate the length and width of a certain part of the body according to such units. One unit is equal to one cun. For further information on the commonly used proportional bone (skeletal) cun of a whole body, refer to the related section on page 11.

#### Finger cun (F-cun)

This method is based on the finger cun of the person to be measured for acupuncture point locations. For information on the commonly used method of measurement, refer to the section on Locating Method by “finger-cun measurement” on page 13.

#### Fingerbreadth (F-breadth)

This method utilizes the width of the distal phalanx of the middle finger. This should be distinguished from the middle finger cun. This method is rarely used e.g. for locating ST6 and ST40.

### 2. Standard position and terms of direction:

The standard position and the terms for the orientation of the human body used in traditional acupuncture point location are not the same as those used in modern anatomy. For example, according to the traditional method, the palmar side of the upper limbs, or the flexional side, is called the medial aspect. This medial aspect is the distribution area of the acupuncture points of the three Yin hand meridians. The dorsal side of the upper limbs, or the extensional side, is called the lateral aspect. This lateral aspect is the distribution area of the acupuncture points of the three Yang hand meridians. The side of the lower limbs closer to the midline is called the medial aspect, which is the distribution area of the acupuncture points of the three Yin foot meridians. The side of the lower limbs away from the midline is called the lateral

aspect. The posterior portion of the lower limbs is called the posterior aspect, and this aspect, along with the lateral aspect, is the distribution area of the acupuncture points of the three Yang foot meridians. The anterior and posterior median lines of the head, face and trunk are the respective distribution areas of the Conception Vessel and the Governor Vessel. These median lines are the baselines for locating acupuncture points on either side of each pair of the two meridians.

The modern anatomical position is adopted by this Standard to describe acupuncture point locations: the body stands upright, eyes look forward, feet together with toes pointing forward and upper limbs hanging by the sides with palms facing forward. For the location of certain specific points, other positions are recommended, such as the knee-chest position (BL35), lying on the side with the thigh flexed (GB30), etc.

### Terms of direction (Figures 1 and 2)

The terms of direction follow standard anatomical terminology.

- Medial and lateral: closer to the median sagittal plane is medial; further away from the median sagittal plane is lateral. On the forearm, the same concepts are replaced with ulnar and radial, and on the legs, with tibial and fibular.
- Superior and inferior: closer to the upper (head) extremity of the body is superior; closer to the lower (feet) extremity of the body is inferior. Superior and inferior may also be used to relate the location of acupuncture points to other points or anatomical landmarks. In this case they refer to directly above or below on a straight line.
- Anterior and posterior: closer to the ventral surface of the human body is anterior; closer to the dorsal surface is posterior.
- Proximal and distal: closer to the trunk is proximal; further away from the trunk is distal.

### 3. Landmarks on the body surface for locating acupuncture points:

Head	
① Midpoint of the anterior hairline (Fig 3, 5)	The midpoint of the anterior hairline
② Midpoint of the posterior hairline (Fig 4, 5)	The midpoint of the posterior hairline
③ Corner of the forehead (Fig 3, 5)	The lateral corner of the anterior hairline on the forehead
④ The glabella (Fig 3)	The midpoint between the eyebrows

⑤ The auricular apex (Fig 3, 4, 5)	The highest point of the auricle when the ear is folded forwards.
<b>Upper limbs</b>	
⑥ The centre of the axillary fossa (Fig 6)	The centre of the axillary fossa
⑦ The anterior axillary fold (crease) (Fig 7)	The anterior end of the axillary fold
⑧ The posterior axillary fold (Fig 7)	The posterior end of the axillary fold
⑨ The cubital crease (Fig 7, 8)	The crease of elbow when it is flexed 90 degrees.
⑩ The palmar wrist crease (Fig 7, 8)	The crease on the line connecting the distal ends of the styloid processes of the ulna and radius when the wrist is flexed. When more than one crease is present, the most distal is used.
⑪ The dorsal wrist crease (Fig 7)	The crease on the line connecting the distal ends of the styloid processes of the ulna and radius when the wrist is extended. When more than one crease is present, the most distal is used.
⑫ The border between the red and white flesh (Fig 9, 14)	The junction of the palmar and dorsal skin / the junction of the plantar and dorsal skin where there is a change in the texture and colour.
⑬ The corner at the root of the nail (Fig 10)	The angle formed by the medial / lateral border of the nail and the base of the nail bed.
<b>Lower limbs</b>	
⑭ The gluteal fold (Fig 11)	The fold between the buttock and the thigh on the posterior side of lower limbs
⑮ The popliteal crease (Fig 11)	The crease of the popliteal fossa
⑯ The prominence of the lateral malleolus (Fig 12, 13)	The most prominent point of the lateral malleolus
⑰ The prominence of the medial malleolus (Fig 12, 13)	The most prominent point of the medial malleolus

#### 4. Regions of body

The regions of human body used in the description of acupuncture point locations are based mainly on the latest version of *International Anatomical Terminology*, issued by the Federative Committee on Anatomical Terminology (FCAT) in 1998. Some regions in the *International Anatomical Terminology* are too difficult a fit for location of acupuncture points. Here regions of the body are divided into the head, neck, back, chest, abdomen, limbs and perineum. The smaller subdivisions of the body are as follows:

Regions		Borderline
Head	Head	Line connecting the superior margin of orbit, the upper border of the zygomatic arch, the upper border of the external ear, the tip of the mastoid process, the upper border of the neck, and the external occipital protuberance
	Face	Line connecting the superior margin of orbit, the upper border of the zygomatic arch, the upper border of the external ear, the tip of the mastoid process, and the lower border of the mandible
Neck	Anterior region of the neck	Superior: inferior borderline of the head and face Inferior: clavicle Posterior: anterior margin of the trapezius muscle
	Posterior region of the neck	Superior: inferior borderline of head Inferior: line across the spinous process of the seventh cervical vertebra (C7) and the acromion Anterior: anterior margin of the trapezius muscle

Back	Upper back region	<p>Superior: line across the spinous process of the seventh cervical vertebra (C7) and the acromion</p> <p>Lateral: vertical line across the end of the posterior axillary fold</p> <p>Inferior: curved line across the spinous process of the 12th thoracic vertebra (T12) and the end of the 12th rib</p>
	Scapular region	The borderline regions, including the scapular region, groin region, shoulder girdle, axilla and buttock region, cannot be clearly described using the terms in surface anatomy. It would be better to follow the conventional conceptions of those regions.
	Lumbar region	<p>Superior: curved line across the spinous process of the 12th thoracic vertebra (T12) and the end of the 12th rib</p> <p>Lateral: vertical line across the end of the posterior axillary fold</p> <p>Inferior: line across spinous process of the fifth lumbar vertebra (L5) and iliac crest</p>
	Sacral region	<p>Superior: line across spinous process of the fifth lumbar vertebra (L5) and iliac crest</p> <p>Lateral: lateral border of the sacrum</p> <p>Inferior: coccyx</p>
Chest	Anterior thoracic region	<p>Superior: clavicle</p> <p>Inferior: curved line across the sternoxiphoid symphysis, rib arch and inferior margin of the 11th and 12th ribs</p> <p>Lateral: vertical line across the end of anterior axillary fold</p>

	Lateral thoracic region	<p>Superior: line across the anterior axillary fold and posterior axillary fold</p> <p>Inferior: line connecting the rib arch and the inferior margin of the 11th and 12th ribs</p> <p>Anterior: vertical line across the end of the anterior axillary fold</p> <p>Posterior: vertical line across the end of the posterior axillary fold</p>
Abdomen	Upper abdomen	<p>Superior: curved line across the sternoxiphoid symphysis, rib arch and inferior margin of the rib</p> <p>Inferior: transverse line across the umbilicus</p> <p>Lateral: vertical line across the end of the anterior axillary fold</p>
	Lower abdomen	<p>Superior: transverse line across the umbilicus</p> <p>Inferior: upper margin of the symphysis pubis</p> <p>Lateral: fold of the groin, vertical line across the end of the anterior axillary fold</p>
	Lateral abdomen	<p>Superior: inferior borderline of the lateral thoracic region</p> <p>Inferior: iliac crest</p> <p>Anterior: vertical line across the end of the anterior axillary fold</p> <p>Posterior: vertical line across the end of the posterior axillary fold</p>
	Groin region	See the scapular region

Upper limbs	Shoulder girdle	See the scapular region
	Axilla region	See the scapular region
	Arm	Anterior, posterior, medial and lateral aspects of the arm
	Elbow	Anterior, posterior, medial and lateral aspects of the elbow
	Forearm	Anterior, posterior, medial and lateral aspects of the forearm
	Hand	Dorsum and palm of the hand
Lower limbs	Buttock region	See the scapular region
	Thigh	Anterior, posterior, medial and lateral aspects of the thigh
	Knee	Anterior, posterior, medial and lateral aspects of the knee
	Leg	Anterior, posterior, medial and lateral aspects of the leg
	Foot	Dorsum and sole of foot, medial and lateral aspects of the foot
	Ankle	Anterior, medial and lateral aspects of the ankle
	Toes	
Perineal region		See the scapular region

Points which are on the borderline belong to the upper region.

Umbilicus belongs to upper abdomen, gluteal fold belongs to buttock region.

## 5. Reference acupuncture points

The nature and function of a reference acupuncture point are the same as those of an anatomical landmark.

Reference acupuncture points:

LU5: On the anterior aspect of the elbow, at the cubital crease, in the depression lateral to the biceps brachii tendon. (Fig 15)

- LU9: On the anterolateral aspect of the wrist, between the radial styloid process and the scaphoid bone, in the depression ulnar to the abductor pollicis longus tendon. (Fig 15)
- LI5: On the posterolateral aspect of the wrist, at the radial side of the dorsal wrist crease, distal to the radial styloid process, in the depression of the anatomical snuffbox. (Fig 16)
- LI11: On the lateral aspect of the elbow, at the midpoint of the line connecting LU5 with the lateral epicondyle of the humerus. (Fig 16)
- LI15: On the shoulder girdle, in the depression between the anterior end of lateral border of the acromion and the greater tubercle of the humerus. (Fig 15)
- ST8: On the head, 0.5 B-cun directly superior to the anterior hairline at the corner of the forehead, 4.5 B-cun lateral to the anterior median line. (Fig 16)
- ST30: In the groin region, at the same level as the superior border of the pubic symphysis, 2 B-cun lateral to the anterior median line, over the femoral artery. (Fig 15)
- ST34: On the anterolateral aspect of the thigh, between the vastus lateralis muscle and the lateral border of the rectus femoris tendon, 2 B-cun superior to the base of the patella. (Fig 15)
- ST35: On the anterior aspect of the knee, in the depression lateral to the patellar ligament. (Fig 15)
- ST41: On the anterior aspect of the ankle, in the depression at the centre of the front surface of the ankle joint, between the tendons of extensor hallucis longus and extensor digitorum longus. (Fig 15)
- SP9: On the tibial aspect of the leg, in the depression between the inferior border of the medial condyle of the tibia and the medial border of the tibia. (Fig 15)
- SP12: In the groin region, at the inguinal crease, lateral to the femoral artery. (Fig 15)
- BL60: On the posterolateral aspect of the ankle, in the depression between the prominence of the lateral malleolus and the calcaneal tendon. (Fig 16)
- KI3: On the posteromedial aspect of the ankle, in the depression between the prominence of the medial malleolus and the calcaneal tendon. (Fig 16)
- TE17: In the anterior region of the neck, posterior to the ear lobe, in the depression anterior to the inferior end of the mastoid process. (Fig 16)
- TE20: On the head, just superior to the auricular apex. (Fig 16)
- GB7: On the head, at the junction of the vertical line of the posterior border of the temple hairline and the horizontal line of the apex of the auricle. (Fig 16)
- GB9: On the head, directly superior to the posterior border of the auricular root, 2 B-cun superior to the hairline. (Fig 16)
- GB12: In the anterior region of the neck, in the depression posteroinferior to the mastoid process. (Fig 16)

- GB20: In the anterior region of the neck, inferior to the occipital bone, in the depression between the origins of sternocleidomastoid and the trapezius muscles. (Fig 16)
- GV20: On the head, 5 B-cun superior to the anterior hairline on the anterior median line. (Fig 15, 16)

### III. Principles and methods for locating acupuncture points on the surface of the body

#### 1. Principles for locating acupuncture points on the surface of the body:

To locate an acupuncture point, a combined approach using literature analysis, clinical practice and actual and proportional measurement is used. In selecting literature for analysis, special importance is attached to ancient and modern literature about acupuncture point locations that has a ‘national standard’ nature, such as *Huangdi Mingtang Jing*, *Zhenjiu Jiayi Jing*, *Beiji Qianjin Fang* and *Tongren Shuxue Zhenjiu Tujing*. When descriptions of acupuncture point locations in ancient literature are not clear, the following four principles are used to determine the proper location:

- Priority is given to the anatomical landmark method when it does not conform to finger-cun measurement.
- Full consideration should be given to all relevant information in the original literature about the acupuncture point and its location area, sequence and name.
- When determining the location of an acupuncture point, it is important to check its location in relation to the location of other relevant points.
- Relevant acupuncture point charts or models in the original literature should be referred to in order to better understand the location of the acupuncture point.

#### 2. Methods for locating acupuncture points on the surface of the body:

Three methods are used for locating acupuncture points:

- The anatomical landmark method;
- The proportional bone (skeletal) measurement method; and
- The finger-cun measurement method

In practice, it is often necessary to combine all three methods when locating an acupuncture point. The methods primarily used are the anatomical landmark and proportional bone (skeletal) measurement. The finger-cun measurement can be used when it is difficult to locate the acupuncture point with the above two methods.

##### The anatomical landmark method:

This method utilizes anatomical landmarks on the surface of the body to locate acupuncture points. Anatomical landmarks may be classified into two types: fixed

landmarks and movable landmarks.

Fixed landmarks refer to protuberances or depressions formed by the joints and muscles; contours of the eyes, ears, nose and mouth; fingernails and toenails; the nipples; the navel and so on. For example, the location of GB34 is described as “anterior and distal to the head of the fibula”.

Movable landmarks refer to the gaps, depressions, wrinkles and peaks which appear along with the movement of joints, muscles, tendons and skin. For example, SI19 is located in the depression formed just anterior to the centre of the tragus when the mouth is opened slightly.

Locations of commonly used anatomical landmarks on the surface of the body for locating acupuncture points include:

- a) The 2nd rib: the rib at the same level as the sternal angle; it can be palpated inferior to the clavicle. (Fig 17)
- b) The 4th intercostal space: at the same level as the nipples in males. (Fig 17)
- c) The spinous process of the 7th cervical vertebra: the most prominent spinous process on the posterior median line of the neck, which moves with the turning of the head. (Fig 18)
- d) The spinous process of the 3rd thoracic vertebra: the intersection of the posterior median line and the line connecting the medial ends of the two spines of the scapulae, when the subject stands upright with arms by the sides. (Fig 18)
- e) The spinous process of the 7th thoracic vertebra: the intersection of the posterior median line and the line connecting the two inferior angles of the scapulae when the subject stands upright with arms by the sides. (Fig 18)
- f) The spinous process of the 12th thoracic vertebra: on the posterior midline, at the same level as the midpoint of the line connecting the inferior angle of the scapula with the highest point of the iliac crest when the subject stand upright with arms by the sides. (Fig 18)
- g) The spinous process of the 4th lumbar vertebra: the intersection of the posterior median line and the line connecting the highest points of the two iliac crests. (Fig 18)
- h) The spinous process of the 2nd sacral vertebra: the intersection of the line connecting the inferior borders of the two posterior superior iliac spines and the posterior median line. (Fig 18)
- i) The sacral hiatus: at the same level as the two sacral cornu superior to the coccyx, on the posterior median line. (Fig 18)

#### The proportional bone (skeletal) measurement method:

The proportional bone (skeletal) measurement method is also used to locate acupuncture points on the body. This method uses landmarks on the body surface,

primarily joints, to measure the length and width of various parts of the body. Acupuncture point location is based on the measurements of various parts of the body from the book *Lingshu* chapter on *Gudu*, combined with the proportional measurements created by later scholars. (The method is to divide the length between two points of particular joints into equal portions. Each portion is equivalent to one cun, and ten portions equal one chi). The primary proportional bone (skeletal) measurements of the whole body can be seen in the following table.

Proportional Bone (Skeletal) Measurements (Figures 19, 20 and 21)

Head and face	Source
From the midpoint of the anterior hairline to the midpoint of the posterior hairline: 12 B-cun	<i>Lingshu</i>
From the glabella to the midpoint of the anterior hairline: 3 B-cun	<i>Shenghui Fang</i>
Between the bilateral corners of the anterior hairline on the forehead: 9 B-cun	<i>Zhenjiu Jiayi Jing</i>
Between the bilateral mastoid processes: 9 B-cun	<i>Lingshu</i>
Chest, abdomen and hypochondrium	
From the suprasternal notch to the midpoint of the xiphisternal junction: 9 B-cun	<i>Lingshu</i>
From the midpoint of the xiphisternal synchondrosis to the centre of the umbilicus: 8 B-cun	<i>Lingshu</i>
From the centre of the umbilicus to the superior border of the pubic symphysis: 5 B-cun	<i>Zhenjiu Jiayi Jing</i>
Between the two nipples: 8 B-cun	<i>Zhenjiu Jiayi Jing</i>
Back and lumbar region	
Between the bilateral medial borders of the scapula: 6 B-cun	<i>Zhenjiu Jiayi Jing</i>
Upper limbs	
From the anterior or posterior axillary fold to the cubital crease: 9 B-cun	<i>Zhenjiu Jiayi Jing &amp; Xunjing Kaoxue Bian</i>
From the cubital crease to the wrist crease: 12 B-cun	<i>Lingshu</i>

Lower limbs	
From the superior border of the pubic symphysis to the base of the patella: 18 B-cun	<i>Lingshu</i>
From the apex of the patella (the centre of the popliteal fossa) to the prominence of the medial malleolus: 15 B-cun  Note: From the inferior border of the medial condyle of the tibia (SP9) to the prominence of the medial malleolus is 13 B-cun. From the inferior border of the medial condyle of the tibia to the apex of the patella is converted into 2 B-cun.	<i>Lingshu</i>
From the lateral prominence of the greater trochanter to the popliteal crease: 19 B-cun	<i>Lingshu</i>
From the gluteal fold to the popliteal crease: 14 B-cun	<i>Tongren Shuxue Zhenjiu Tujing</i>
From the popliteal crease to the prominence of the lateral malleolus: 16 B-cun	<i>Lingshu</i>
From the prominence of medial malleolus to the sole: 3 B-cun	<i>Lingshu</i>

#### The finger-cun measurement method:

The finger-cun measurement method refers to the proportional measurement method for locating acupuncture points based on the size of the fingers of the person to be measured. This method is mainly used on the lower limbs. When locating an acupuncture point, the practitioner, in addition to using the proportional bone (skeletal) measurement method, may use the finger-cun measurement of the patient being measured in order to verify the standard location of the acupuncture point.

**Middle-finger cun:** The distance between the ends of the two radial creases of the interphalangeal joints of the middle finger is taken as 1 F-cun when the thumb and the middle finger are flexed to form a circle. (Fig 22)

**Thumb measurement:** the width of the interphalangeal joint of the thumb is taken as 1 F-cun. (Fig 23)

**Finger width measurement:** when the index, middle, ring and little fingers of the subject are extended and closed together, the width of the four fingers on the dorsal

crease of the proximal interphalangeal joint of the middle finger is taken as 3 F-cun. (Fig 24)

#### IV. Description of acupuncture point locations

In acupuncture point location, a vertical and horizontal coordinate method is adopted as much as possible. Using two intersecting lines to make a crossing point, first, the distance on the y-coordinate (Y axis) is determined to draw the horizontal line on the body, then the distance on the x-coordinate (X axis) is determined to draw the vertical line on the body. The latest edition of *International Anatomical Terminology* is utilized to describe the relevant anatomical parts of acupuncture point locations.

The description for acupuncture point locations does not include methods for locating the acupuncture points. Notes will be added, when required, to explain the specific body postures that are required to locate certain acupuncture points, as well as the techniques for locating body surface landmarks, proportional bone (skeletal) measurements, and the relationship with adjacent acupuncture points.

The focus of explanations for location of acupuncture points is on general body positions. Only those special body positions required for certain acupuncture points have specific notes under relevant items to explain their locations.

Notes offer supplementary explanations on the following related key points for location of acupuncture points.

- A special body position required for acupuncture point location.
- The proportional bone (skeletal) measurement.
- Explanations of the method of locating certain anatomical landmarks.
- The relationship with adjacent acupuncture points or landmark acupuncture points.
- Explanations of the differences in surface landmarks between different genders and individuals.

#### V. Controversial acupuncture point locations

Through several meetings with Member States organized by the WHO Regional Office for the Western Pacific to review the 92 controversial acupuncture point locations, 86 were standardized. However, the experts could only make a tentative decision on the six remaining points. It was agreed that further scientific research, such as multi-centred clinical trials, should be conducted on the six remaining controversial acupuncture point locations.

The six controversial acupuncture points are LI19, LI20, PC8, PC9, GB30 and GV26. Their alternative acupuncture point locations are described under “Remarks” in this document.

Fig 1

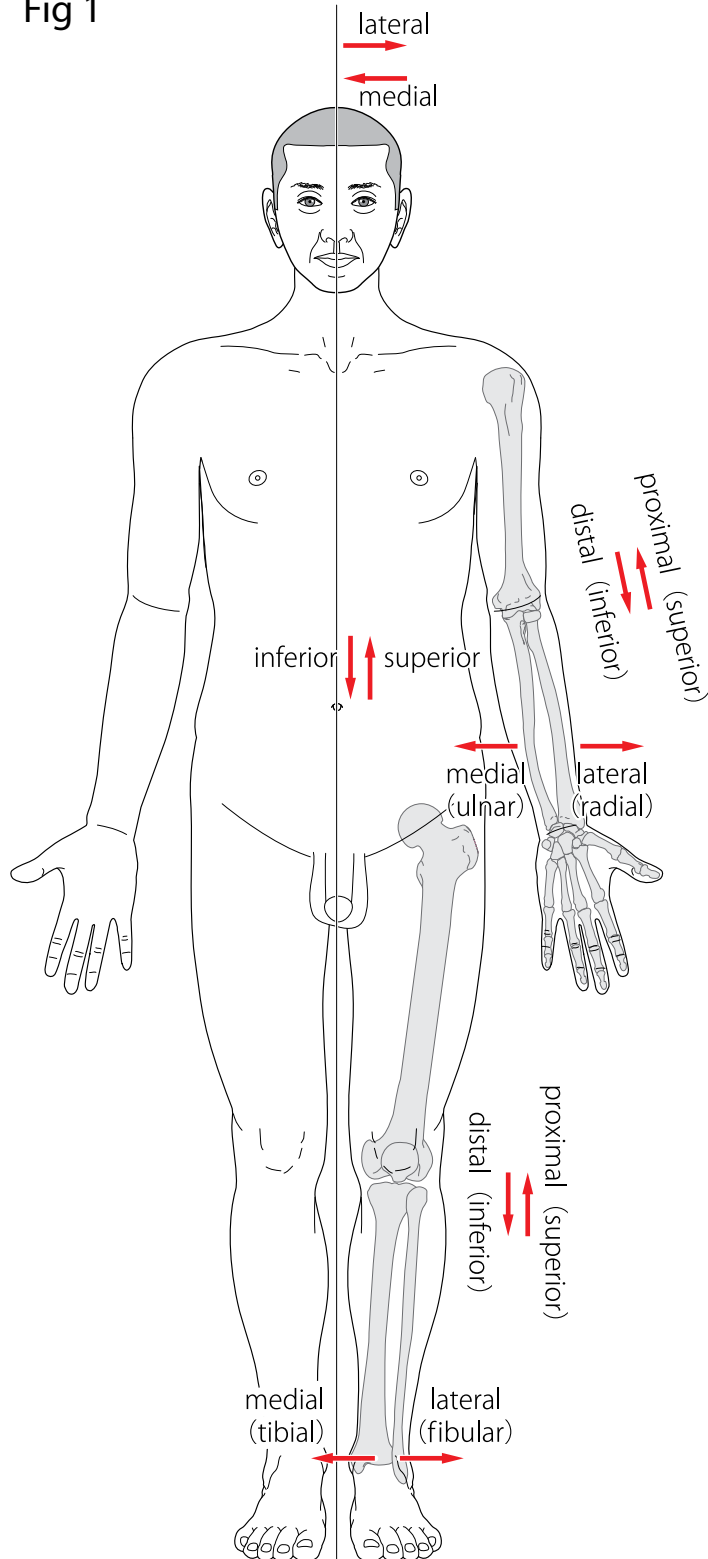


Fig 2

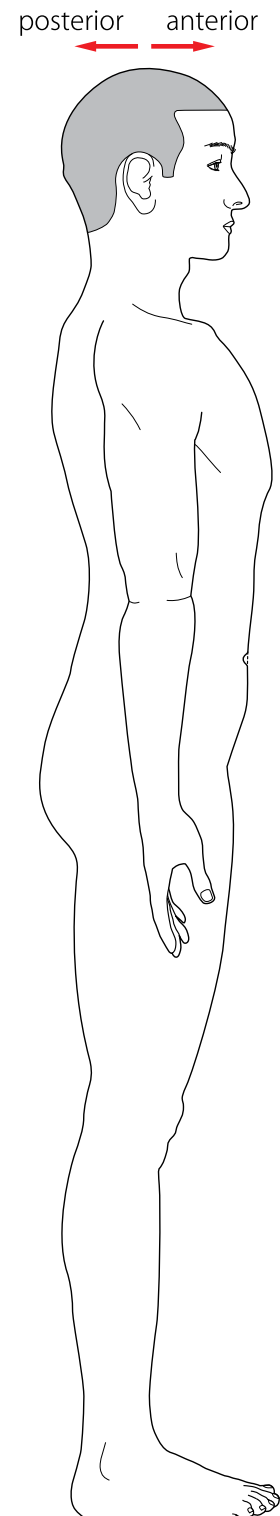


Fig 3

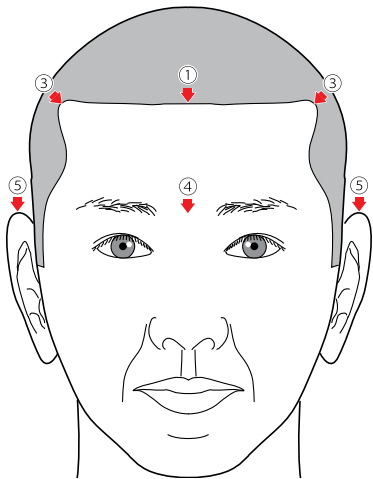


Fig 5

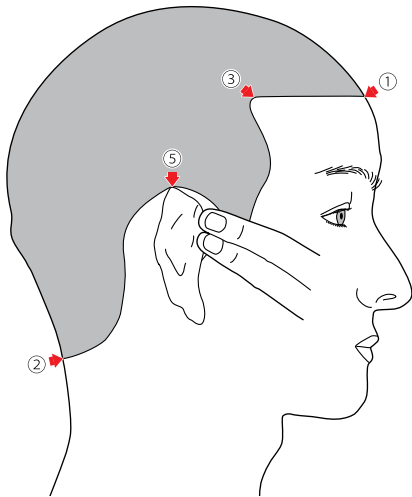


Fig 4

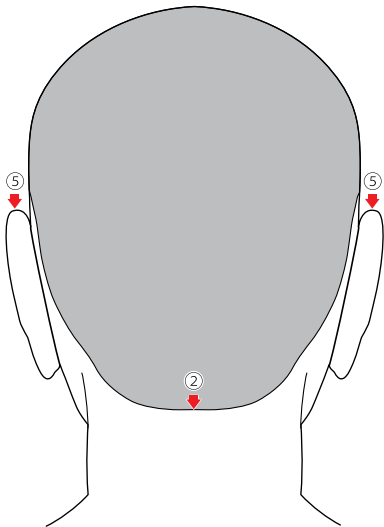


Fig 6

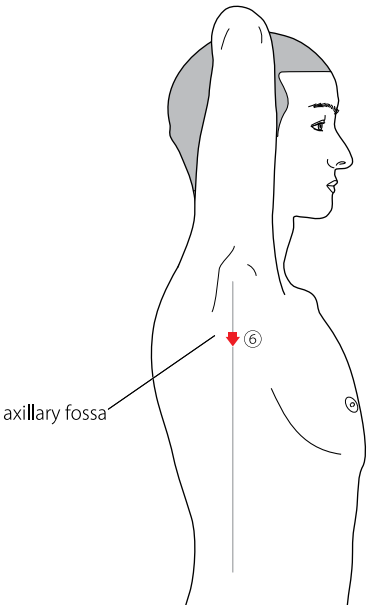


Fig 7

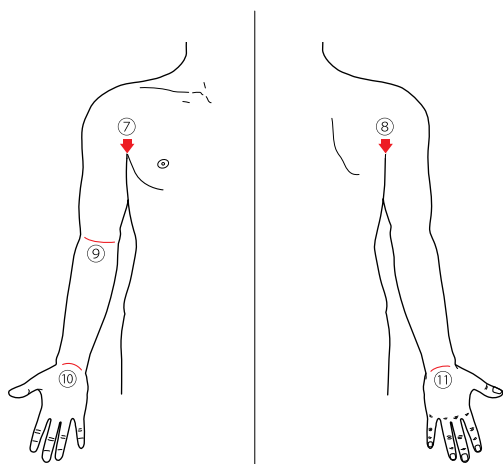


Fig 9

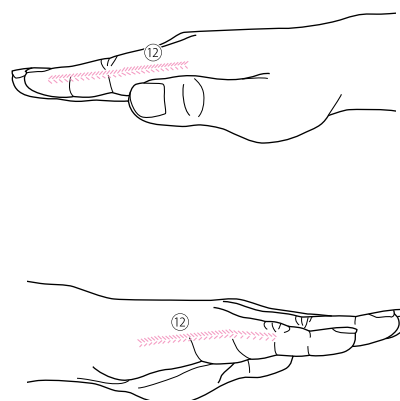


Fig 8

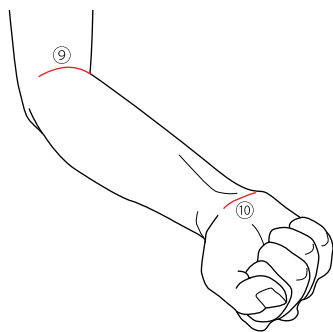


Fig 10

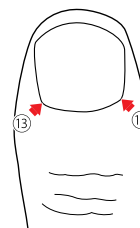


Fig 11

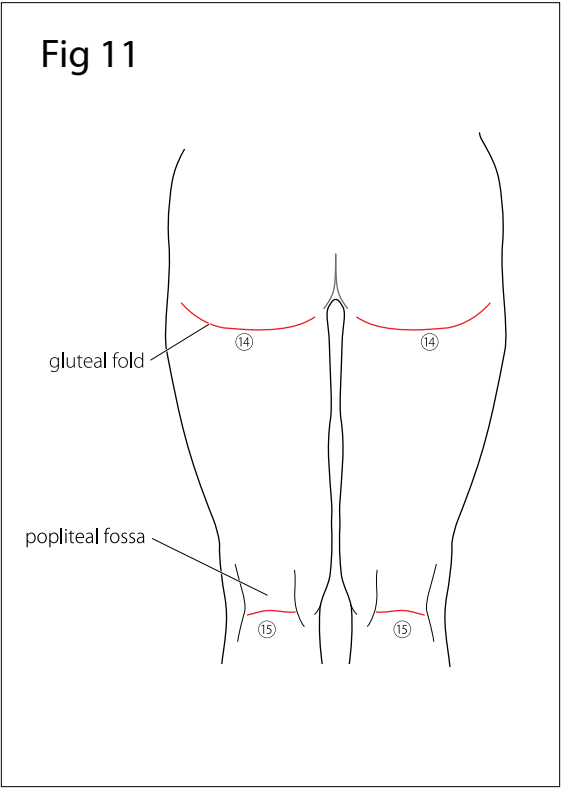


Fig 13

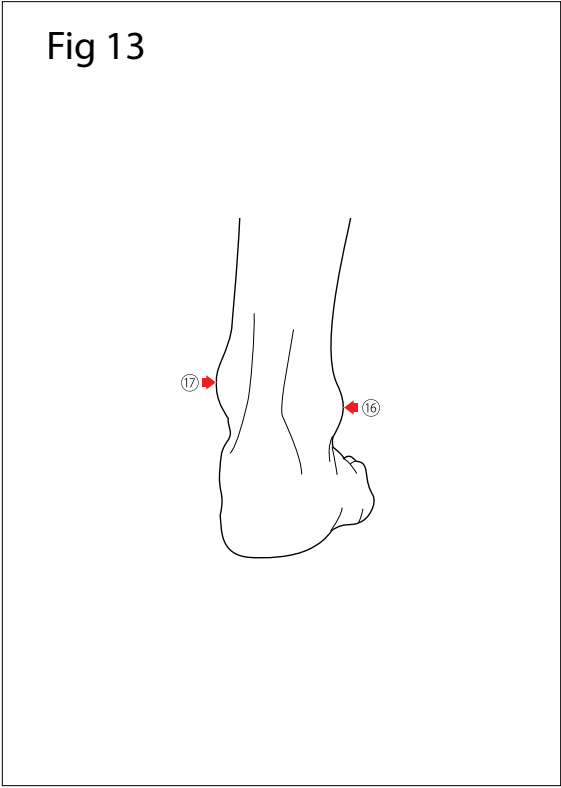


Fig 12

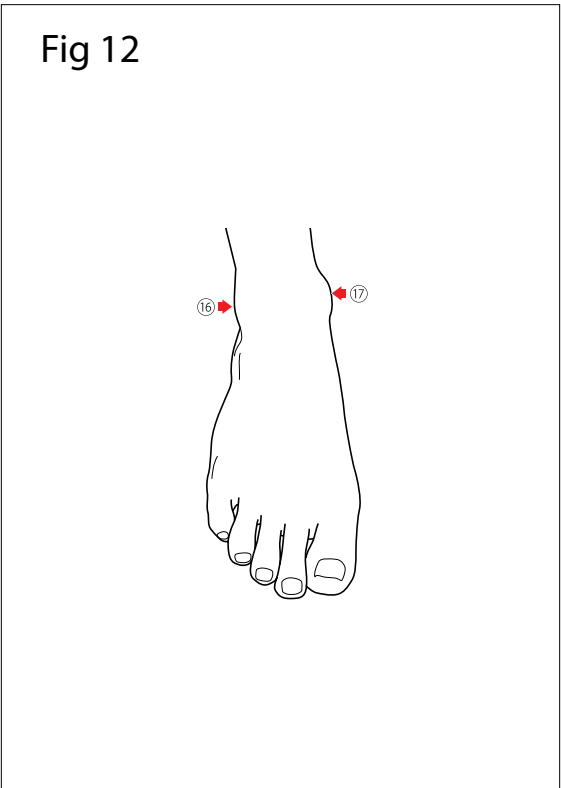


Fig 14

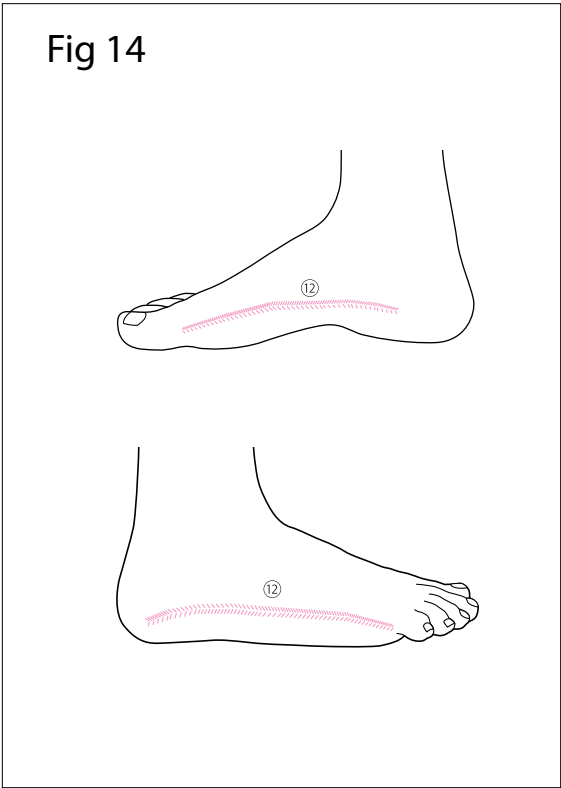


Fig 15

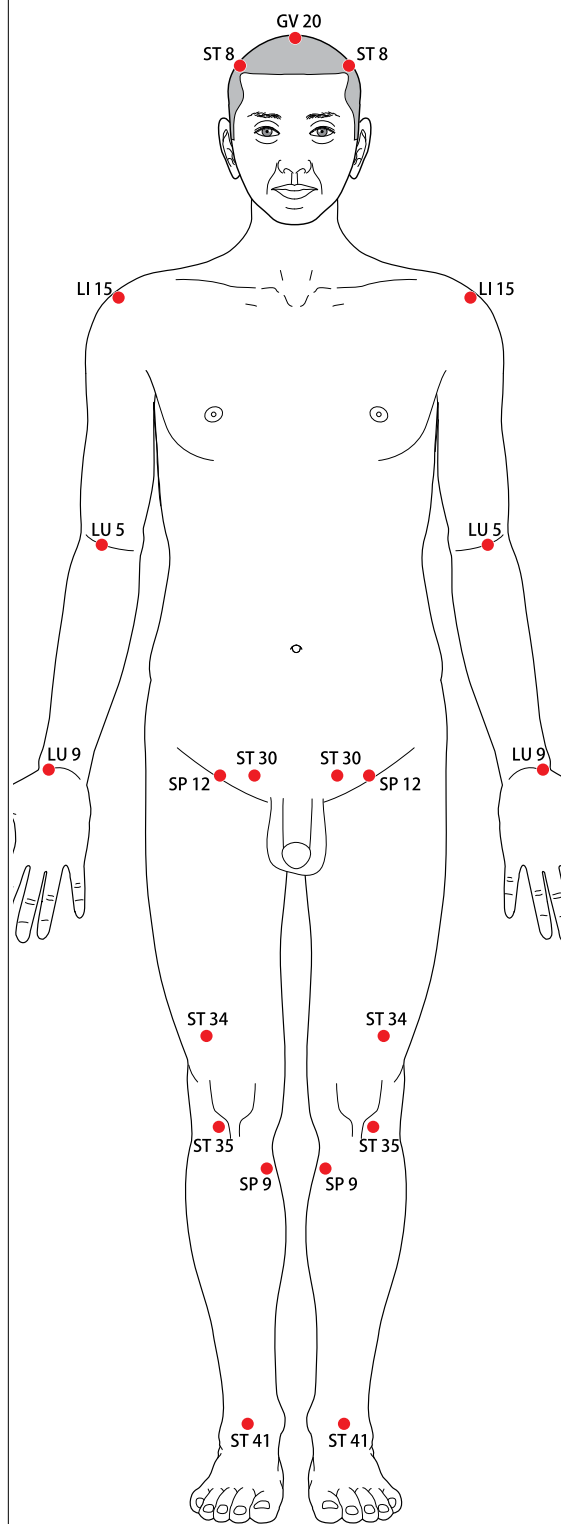


Fig 16

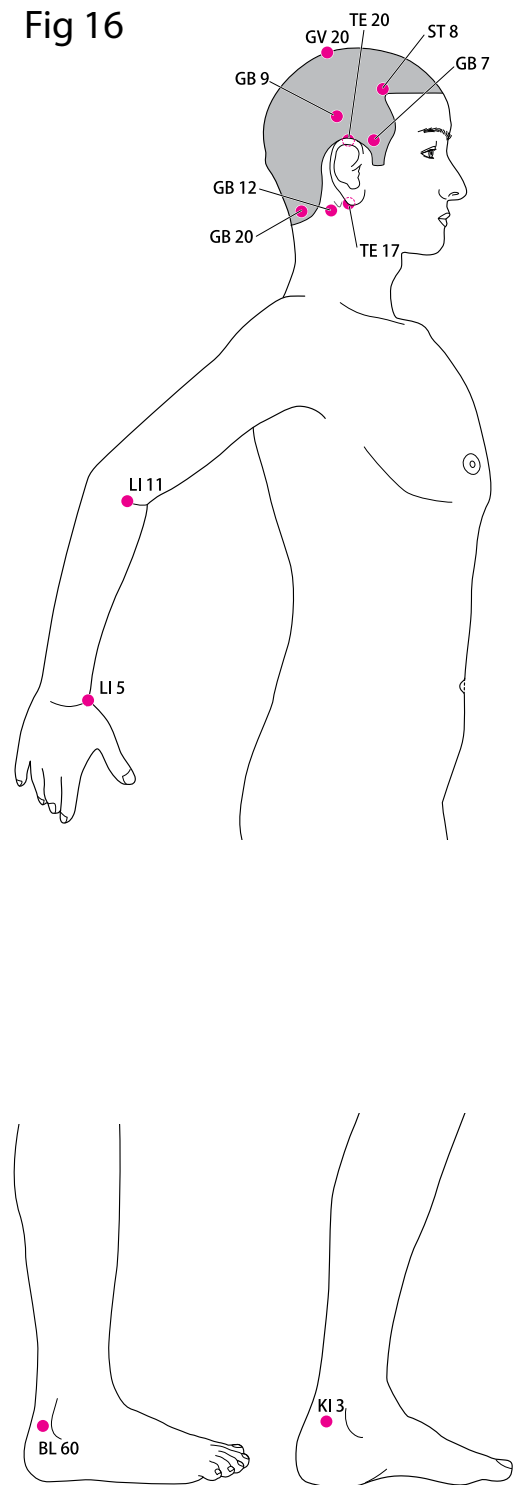


Fig 17

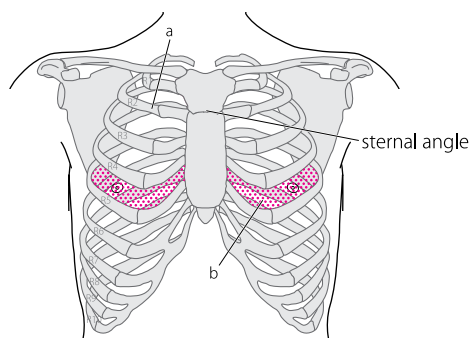


Fig 19

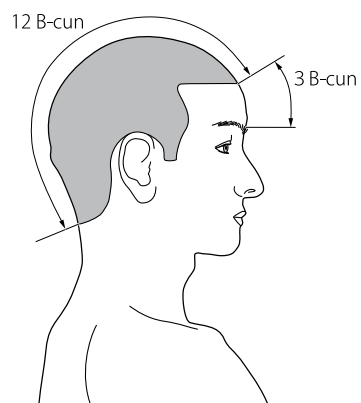


Fig 18

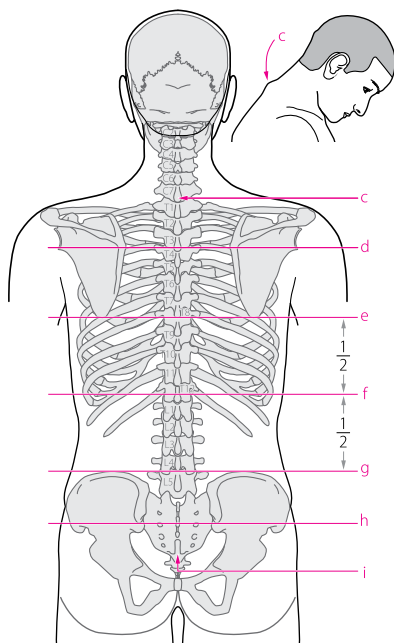


Fig 20

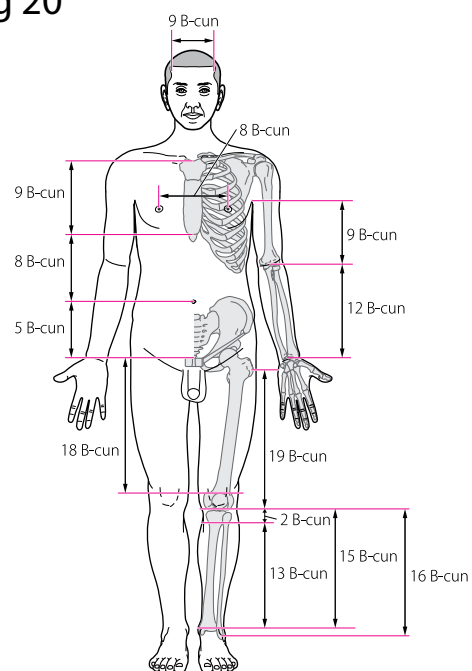


Fig 21

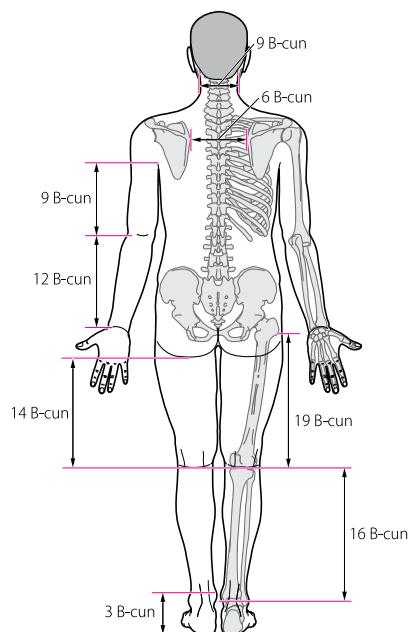


Fig 23

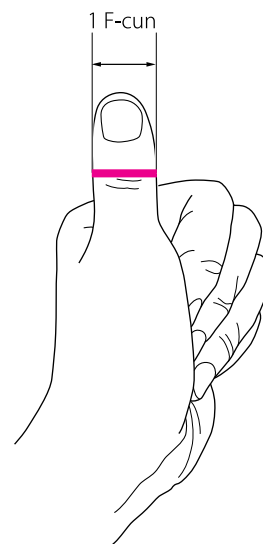


Fig 22

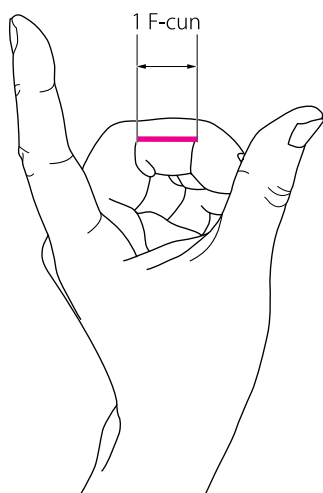
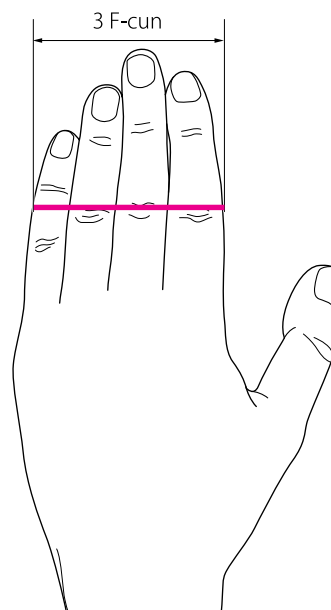



Fig 24





# WHO STANDARD ACUPUNCTURE POINT LOCATIONS

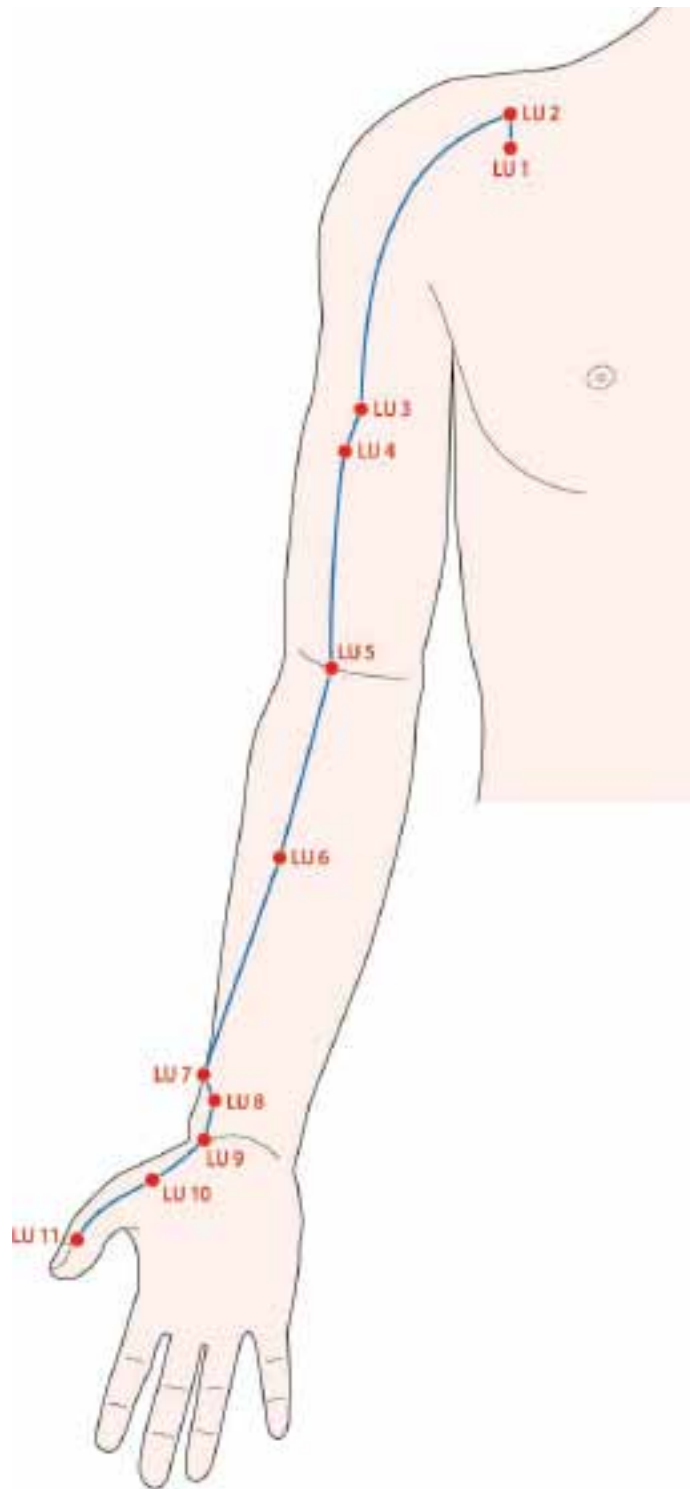
---





# LUNG MERIDIAN

手太陰(阴)肺經(经, 經)

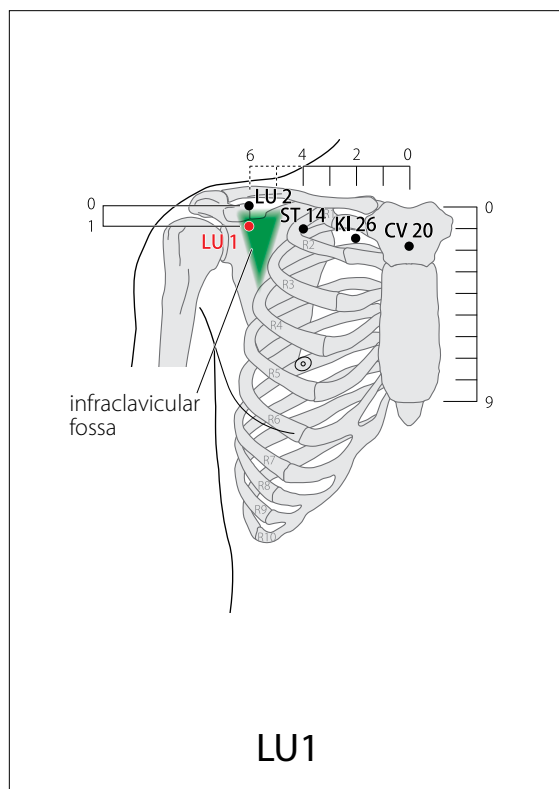


## LU1: Zhongfu 中府

On the anterior thoracic region, at the same level as the first intercostal space, lateral to the infraclavicular fossa, 6 B-cun lateral to the anterior median line.

Note 1: After locating LU2, LU1 is located 1 B-cun inferior to LU2.

Note 2: ST14, KI26, CV20 and LU1 are located on the transverse line along the first intercostal space.

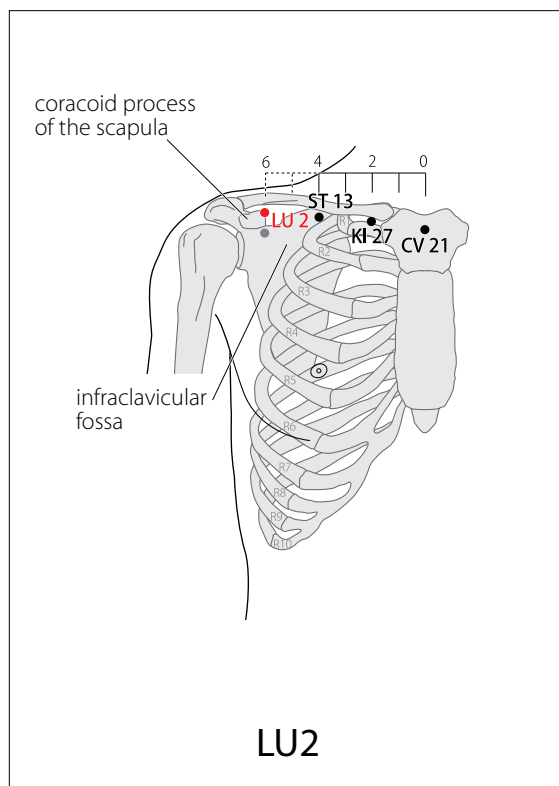


## LU2: Yunmen 雲(云)門(门)

On the anterior thoracic region, in the depression of the infraclavicular fossa, medial to the coracoid process of the scapula, 6 B-cun lateral to the anterior median line.

Note 1: After identifying the deltopectoral triangle when the arm is flexed and slightly abducted against resistance, LU2 is in the centre of the deltopectoral triangle.

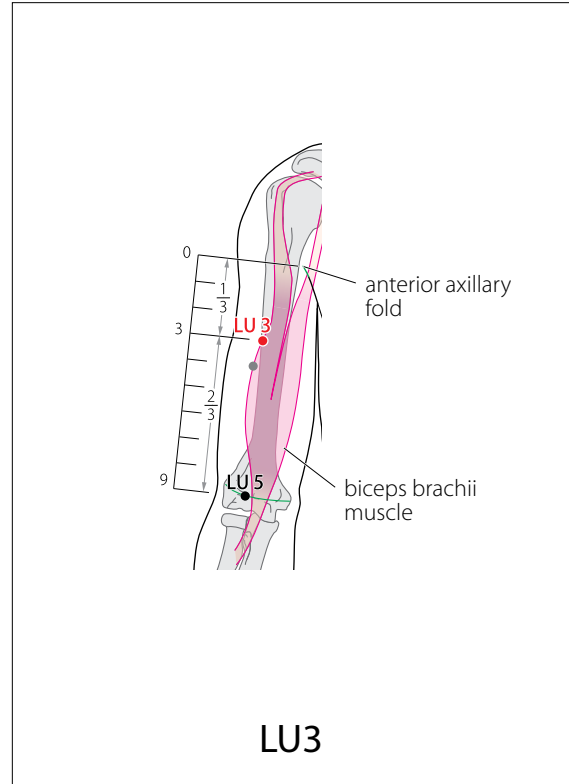
Note 2: ST13, KI27, CV21 and LU2 are located on the transverse line along the inferior border of the clavicle.



### LU3: Tianfu 天府

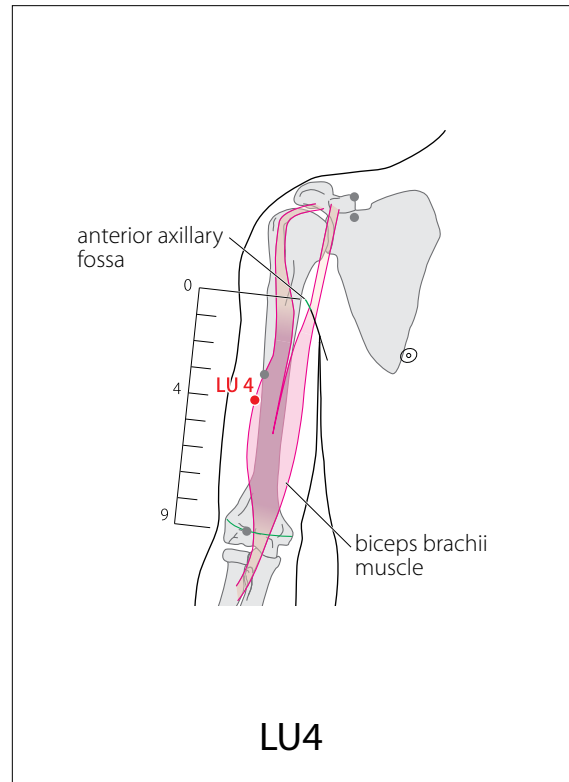
On the anterolateral aspect of the arm, just lateral to the border of the biceps brachii muscle, 3 B-cun inferior to the anterior axillary fold.

Note: Longitudinally, LU3 is located at the same level as the junction of the upper one third and lower two thirds of the line connecting the level with anterior axillary fold to LU5.



### LU4: Xiabai 侠(侠)白

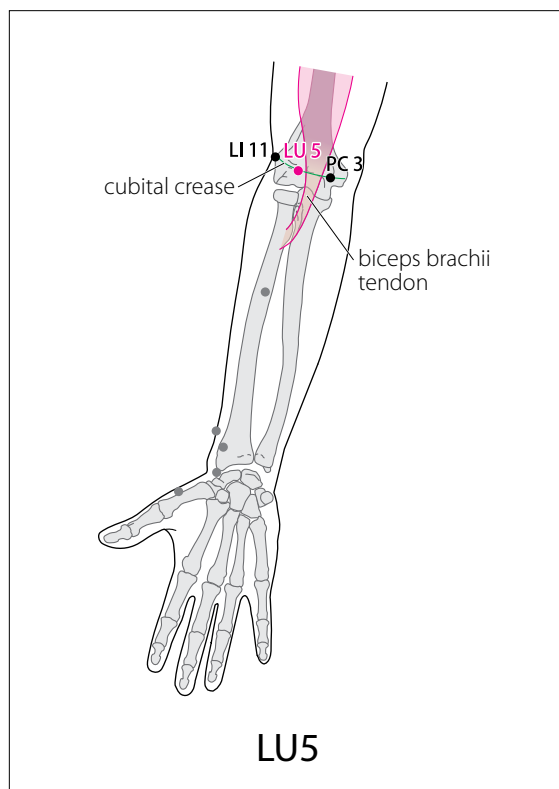
On the anterolateral aspect of the arm, just lateral to the border of the biceps brachii muscle, 4 B-cun inferior to the anterior axillary fold.



### LU5: Chize 尺澤 (泽, 沢)

On the anterior aspect of the elbow, at the cubital crease, in the depression lateral to the biceps brachii tendon.

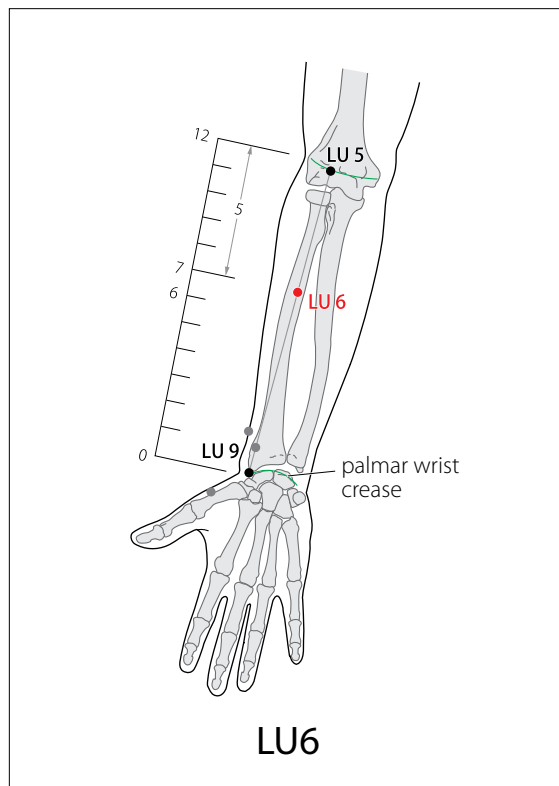
Note: With the elbow flexed, LU5 is located at the cubital crease, between LI11 and PC3, separated from PC3 by the biceps brachii tendon.



### LU6: Kongzui 孔最

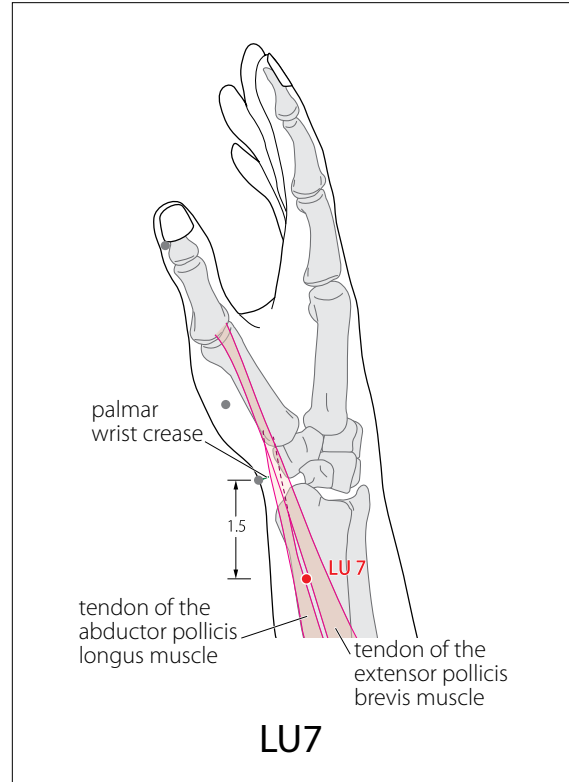
On the anterolateral aspect of the forearm, on the line connecting LU5 with LU9, 7 B-cun superior to the palmar wrist crease.

Note: LU6 is 5 B-cun inferior to LU5, 1 B-cun superior to the midpoint of the line connecting LU5 with LU9.



### LU7: Lieque 列缺

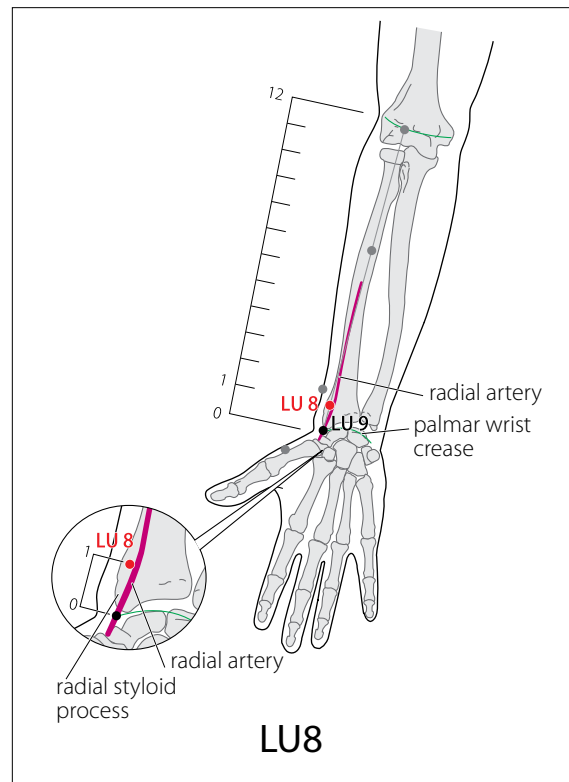
On the radial aspect of the forearm, between the tendons of the abductor pollicis longus and the extensor pollicis brevis muscles, in the groove for the abductor pollicis longus tendon, 1.5 B-cun superior to the palmar wrist crease.



### LU8: Jingqu 經(经, 經)渠

On the anterolateral aspect of the forearm, between the radial styloid process and the radial artery, 1 B-cun superior to the palmar wrist crease.

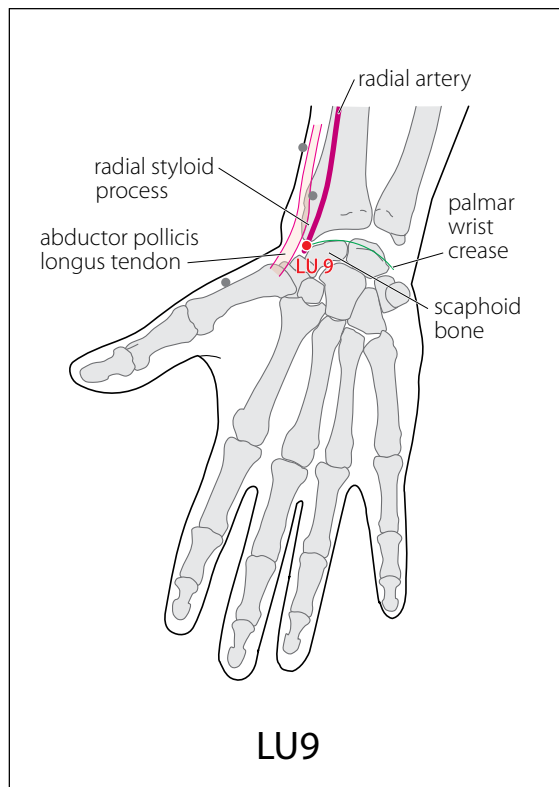
Note: 1 B-cun superior to LU9.



### LU9: Taiyuan 太淵(淵)

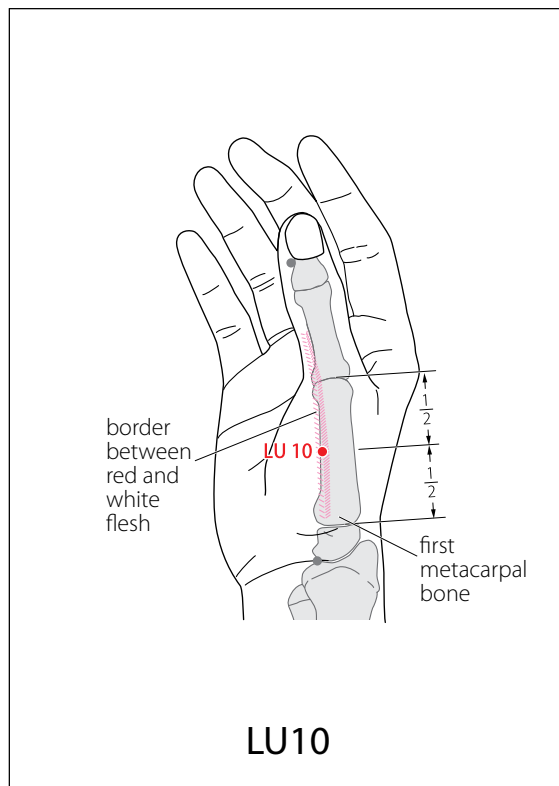
On the anterolateral aspect of the wrist, between the radial styloid process and the scaphoid bone, in the depression ulnar to the abductor pollicis longus tendon.

Note: On the radial side of the palmar wrist crease, over the radial artery.



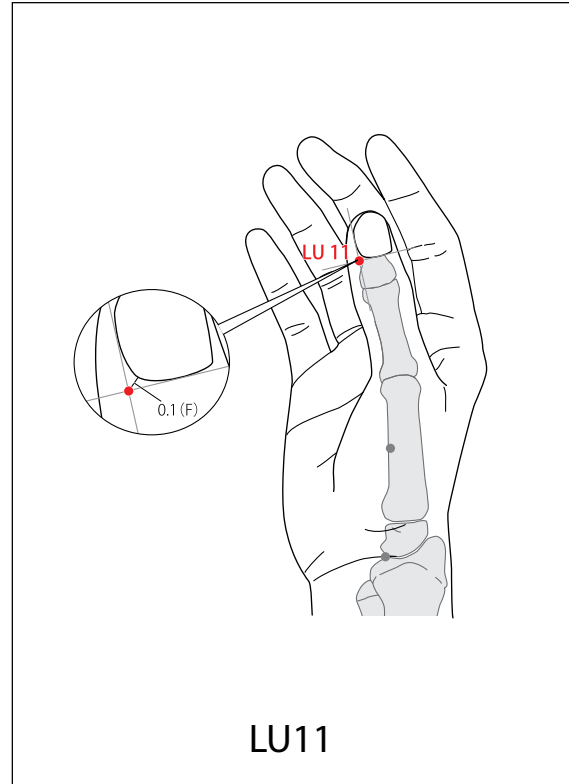
### LU10: Yuji 魚(魚)際(际)

On the palm, radial to the midpoint of the first metacarpal bone, at the border between the red and white flesh.



**LU11: Shaoshang 少商**

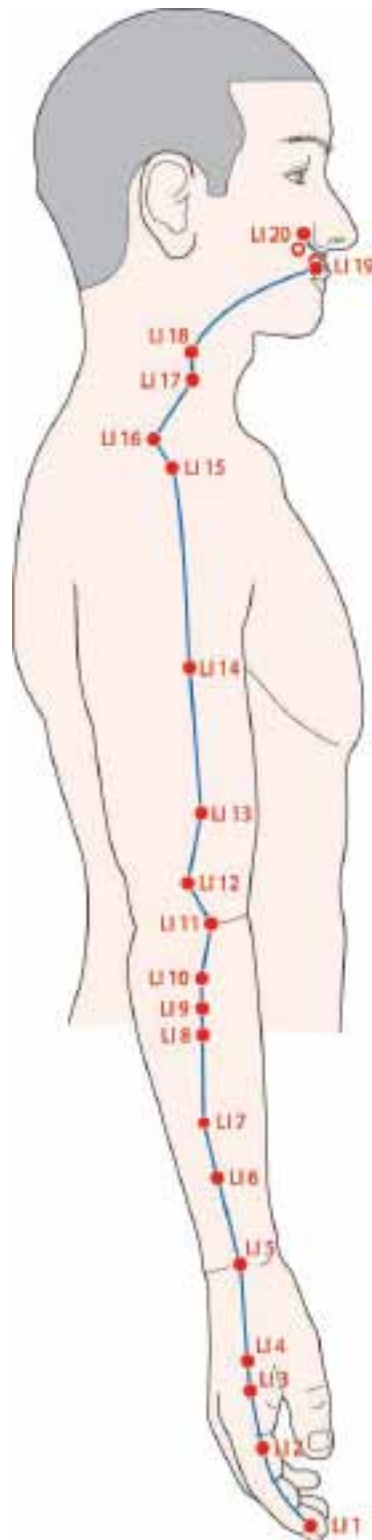
On the thumb, radial to the distal phalanx, 0.1 F-cun proximal-lateral to the radial corner of the thumb nail, at the intersection of the vertical line of the radial border and the horizontal line of the base of the thumb nail.





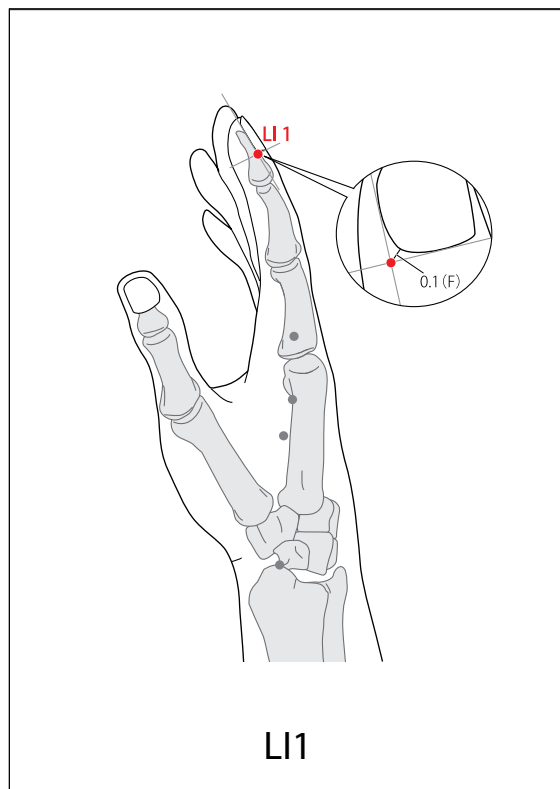
# LARGE INTESTINE MERIDIAN

手陽(阳)明大腸(肠)經(经, 經)

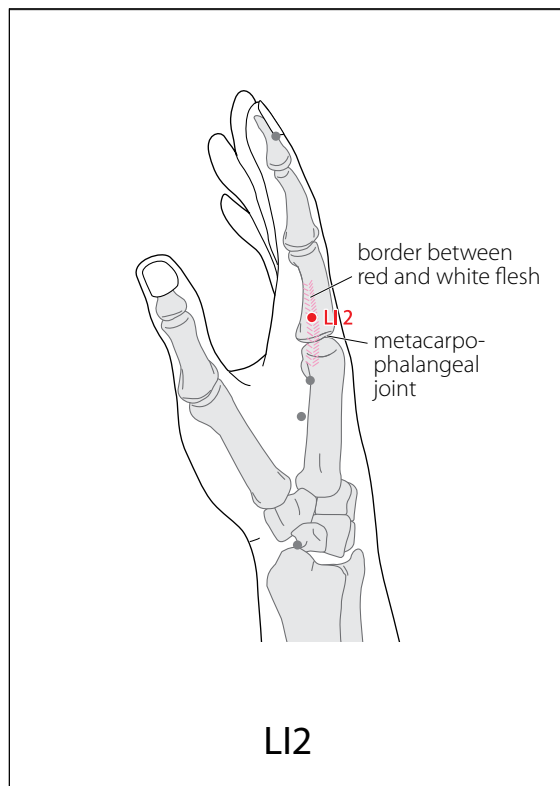


**LI1: Shangyang 商陽 (阳)**

On the index finger, radial to the distal phalanx, 0.1 F-cun proximal-lateral to the radial corner of the index fingernail, at the intersection of the vertical line of the radial border of the fingernail and the horizontal line of the base of the index fingernail.

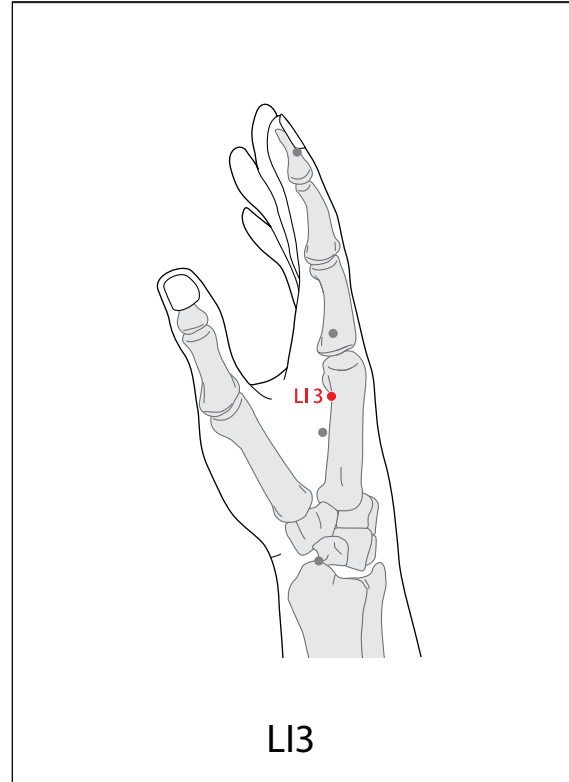
**LI2: Erjian 二間 (间)**

On the index finger, in the depression distal to the radial side of the second metacarpophalangeal joint, at the border between the red and white flesh.

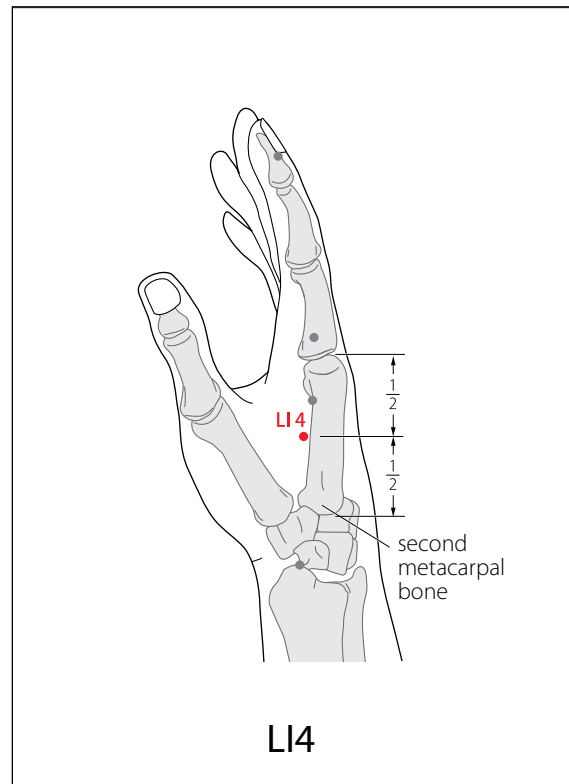


**LI3: Sanjian 三間 (間)**

On the dorsum of the hand, in the depression radial and proximal to the second metacarpophalangeal joint.

**LI4: Hegu 合谷**

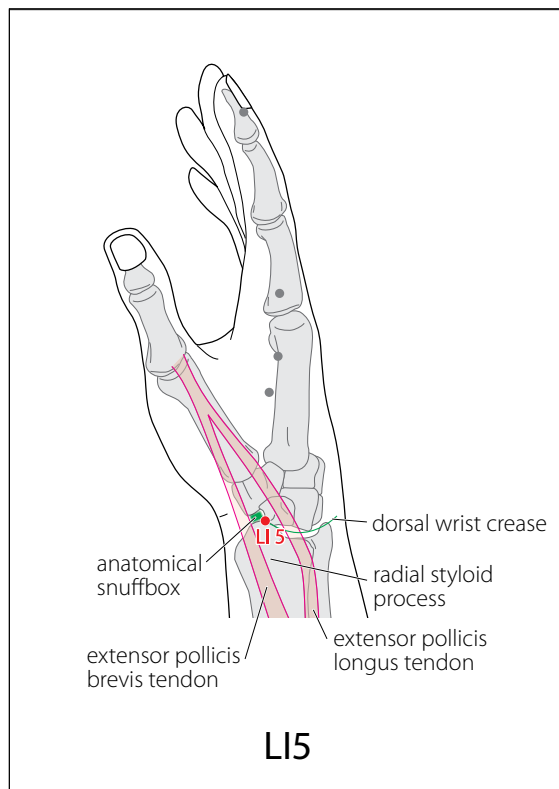
On the dorsum of the hand, radial to the midpoint of the second metacarpal bone.



### LI5: Yangxi 陽(阳)谿(溪)

On the posterolateral aspect of the wrist, at the radial side of the dorsal wrist crease, distal to the radial styloid process, in the depression of the anatomical snuffbox.

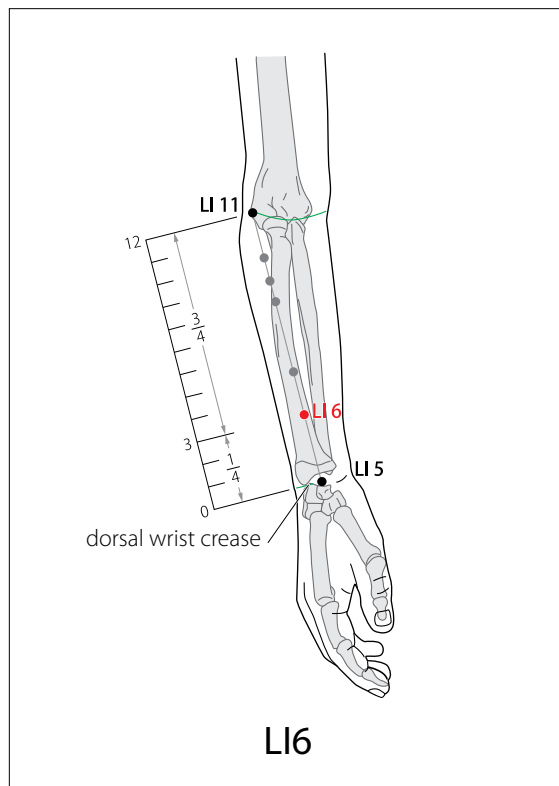
Note : The depression of the anatomical snuffbox is formed when the thumb is fully abducted and extended between the tendons of the extensor pollicis longus and the extensor pollicis brevis.



### LI6: Pianli 偏歷(历)

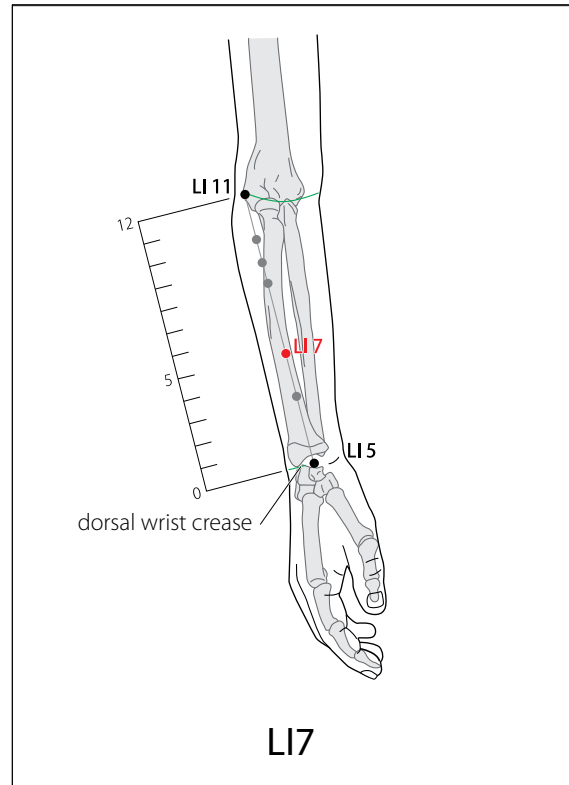
On the posterolateral aspect of the forearm, on the line connecting LI5 with LI11, 3 B-cun superior to the dorsal wrist crease.

Note: LI6 is located at the junction of the upper three fourths and the lower one fourth of the line connecting LI5 with LI11.



### LI 7: Wenliu 溫 (溫) 溜

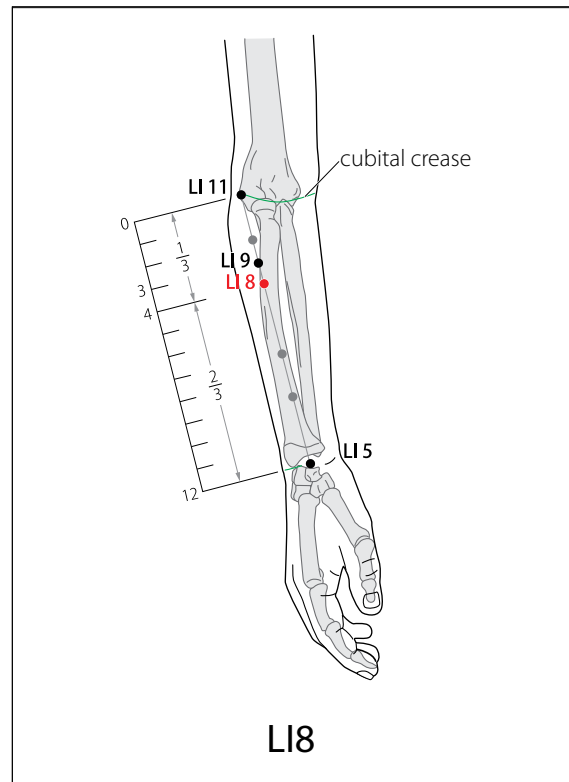
On the posterolateral aspect of the forearm, on the line connecting LI5 with LI11, 5 B-cun superior to the dorsal wrist crease.



### LI 8: Xialian 下廉

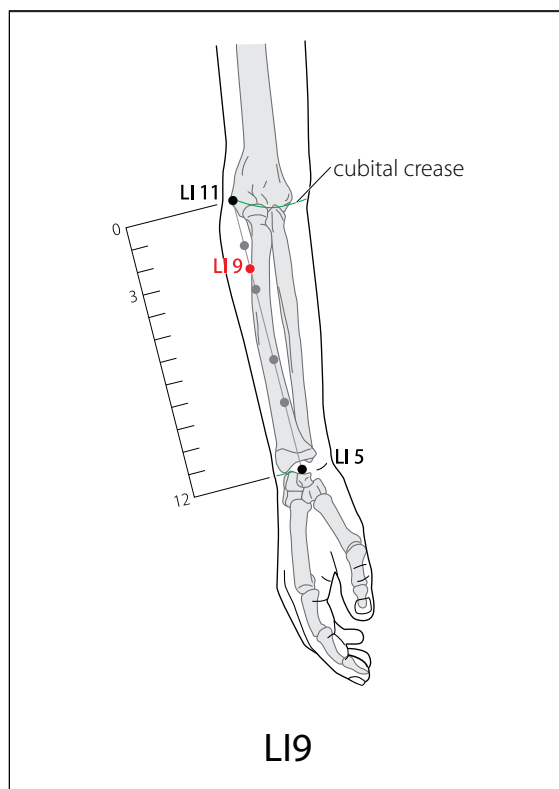
On the posterolateral aspect of the forearm, on the line connecting LI5 with LI11, 4 B-cun inferior to the cubital crease.

Note: LI8 is located at the junction of the upper one third and lower two thirds of the line connecting LI5 with LI11, 1 B-cun inferior to LI9.



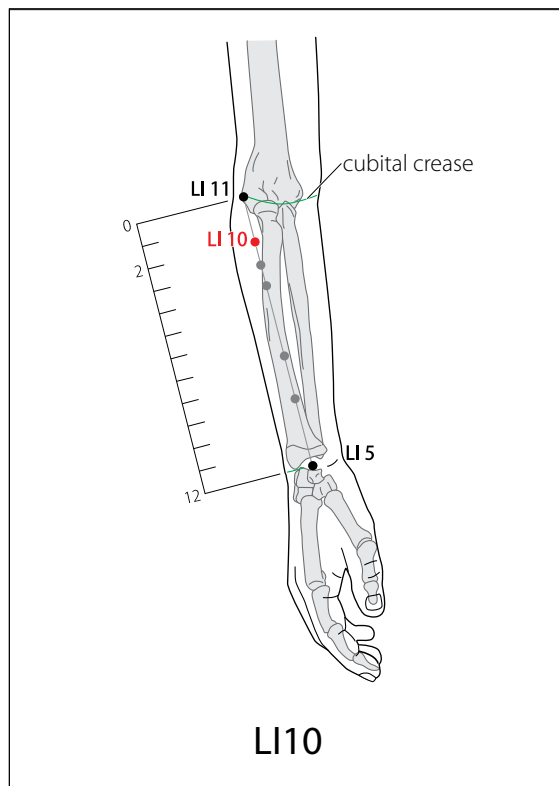
## LI9: Shanglian 上廉

On the posterolateral aspect of the forearm, on the line connecting LI5 with LI11, 3 B-cun inferior to the cubital crease.



## LI10: Shousanli 手三里

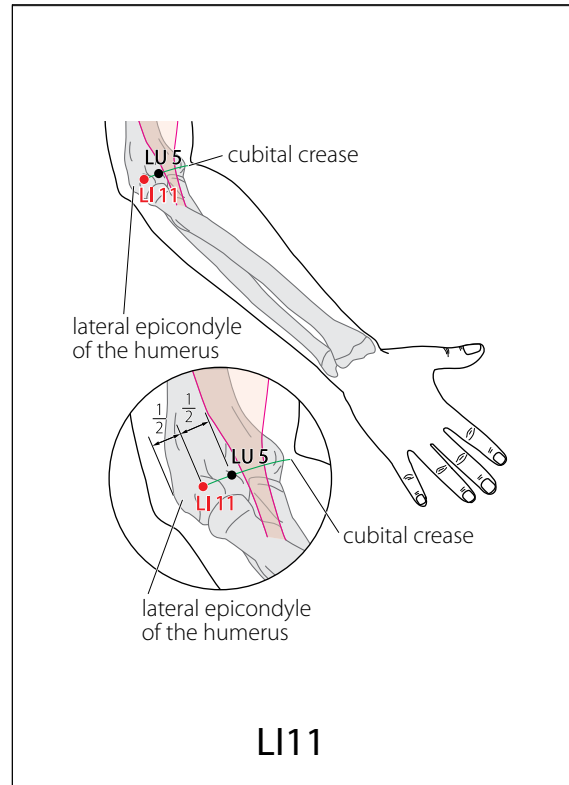
On the posterolateral aspect of the forearm, on the line connecting LI5 with LI11, 2 B-cun inferior to the cubital crease.



### LI11: Quchi 曲池

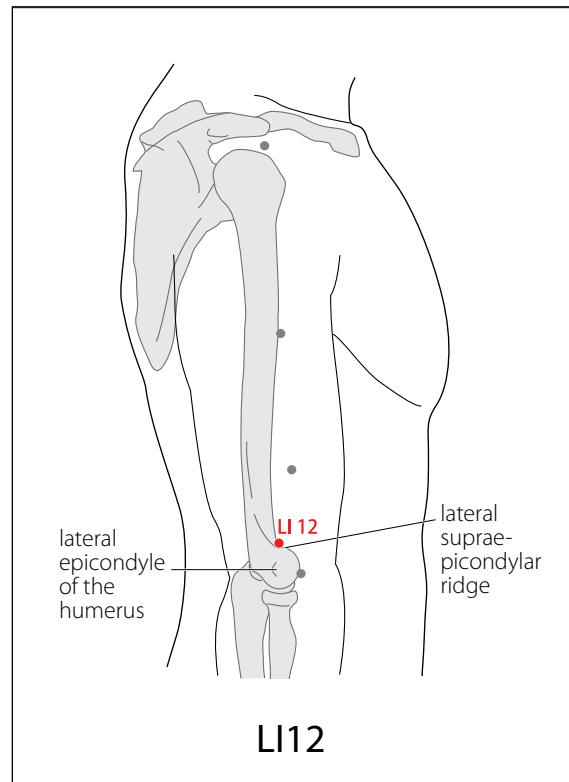
On the lateral aspect of the elbow, at the midpoint of the line connecting LU5 with the lateral epicondyle of the humerus.

Note: When the elbow is fully flexed, LI11 is located in the depression on the lateral end of the cubital crease.



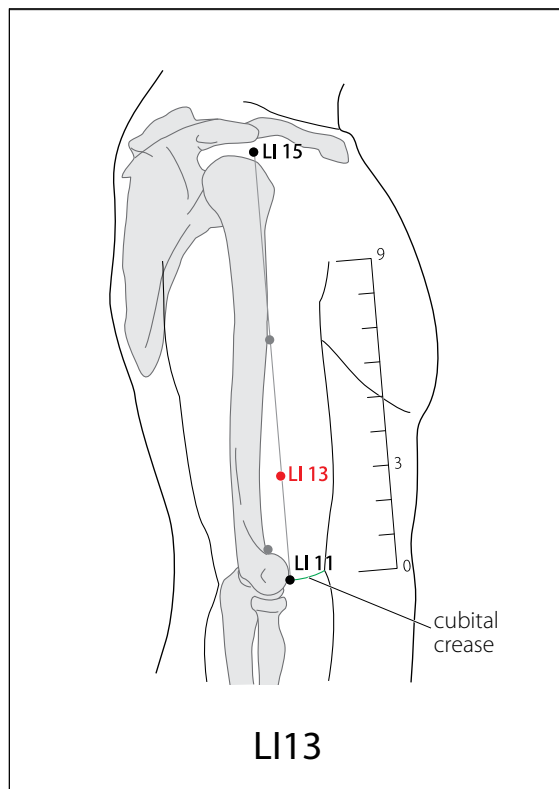
### LI12: Zhouliao 肘髎 (髎)

On the posterolateral aspect of the elbow, superior to the lateral epicondyle of the humerus, anterior to the lateral supraepicondylar ridge.



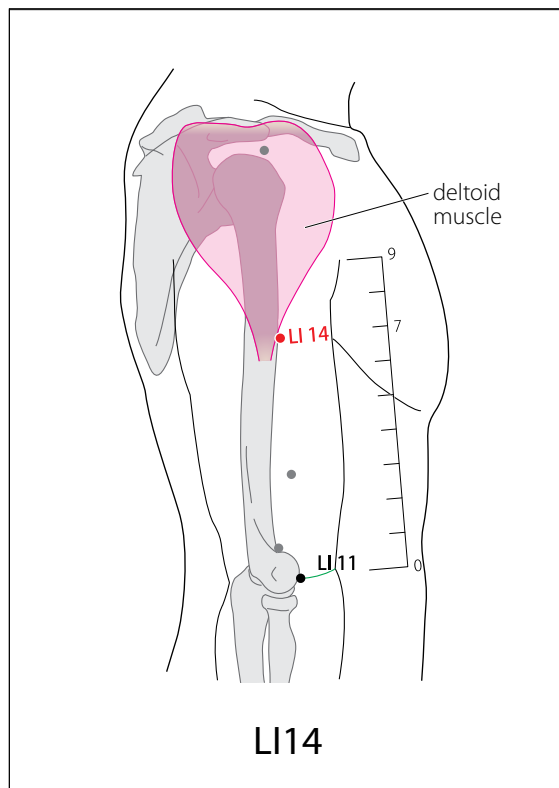
### LI13: Shouwuli 手五里

On the lateral aspect of the arm, on the line connecting LI11 with LI15, 3 B-cun superior to the cubital crease.



### LI14: Binao 臂臑

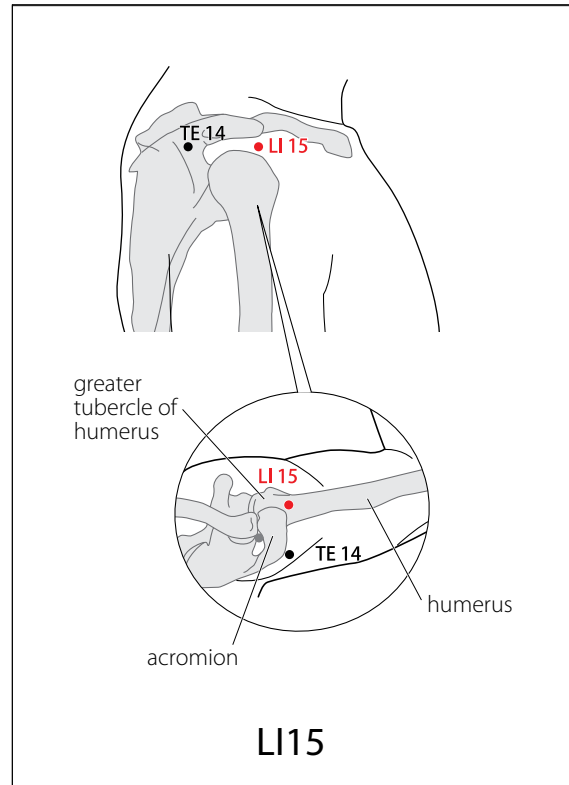
On the lateral aspect of the arm, just anterior to the border of the deltoid muscle, 7 B-cun superior to LI11.



### LI15: Jianyu 肩髃(髃)

On the shoulder girdle, in the depression between the anterior end of lateral border of the acromion and the greater tubercle of the humerus.

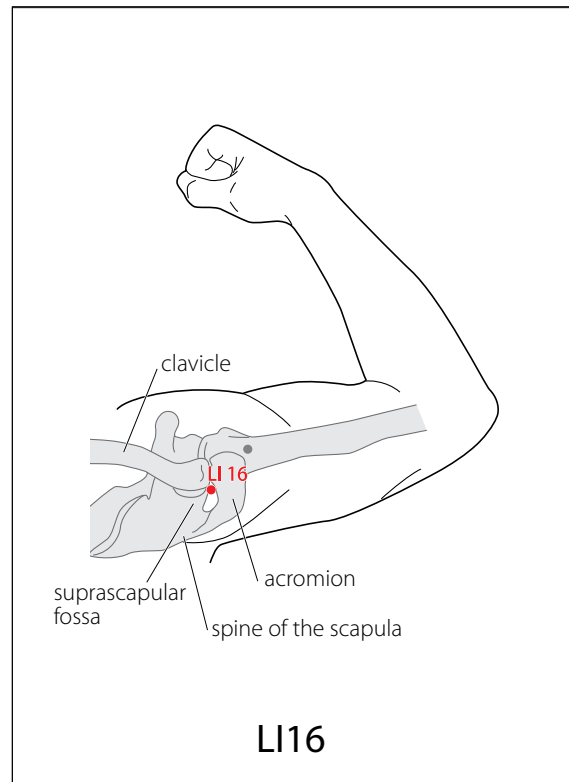
Note: When the arm is abducted, two depressions appear, anterior and posterior to the acromion. LI15 is located in the deeper depression anterior to the acromion. TE14 is located in the posterior depression.



### LI16: Jugu 巨骨(骨)

On the shoulder girdle, in the depression between the acromial end of the clavicle and the spine of the scapula.

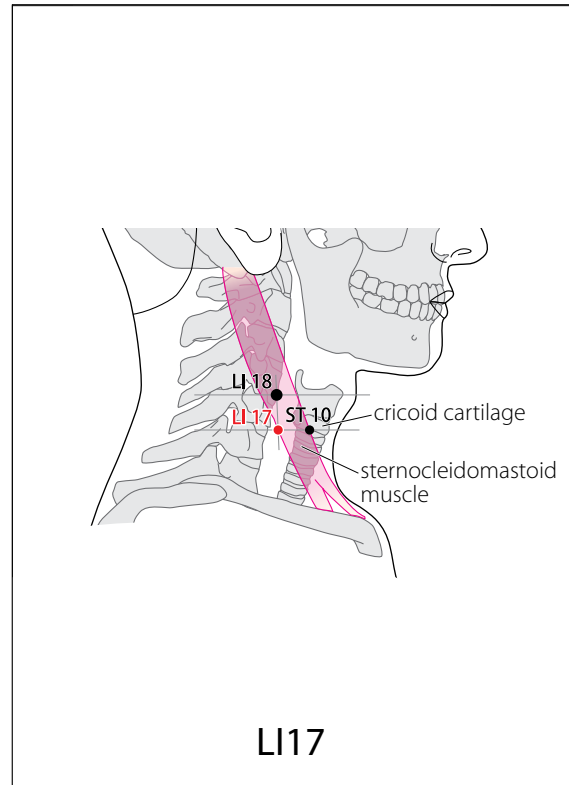
Note: In the depression between the two bones lateral to the suprascapular fossa.



### LI17: Tianding 天鼎

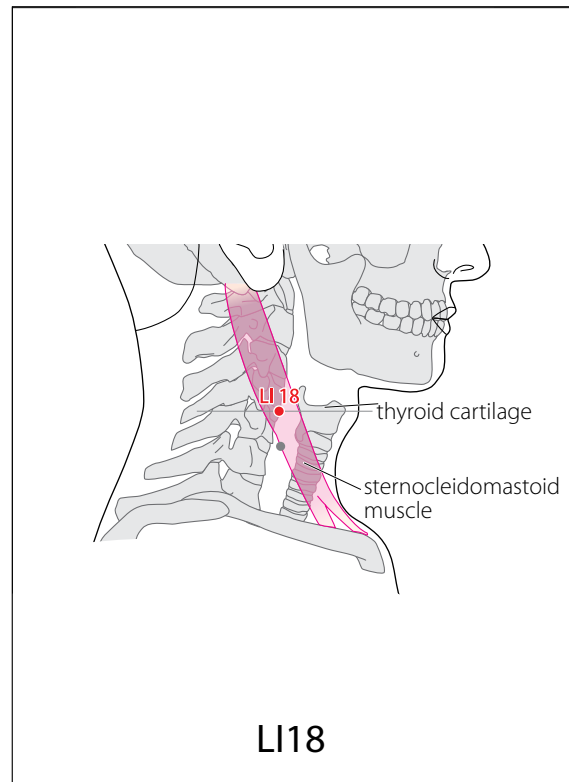
On the anterior aspect of the neck, at the same level as the cricoid cartilage, just posterior to the border of the sternocleidomastoid muscle.

Note: Directly inferior to LI18, at the same level as ST10.



### LI18: Futu 扶突

On the anterior aspect of the neck, at the same level as the superior border of the thyroid cartilage, between the anterior and posterior borders of the sternocleidomastoid muscle.

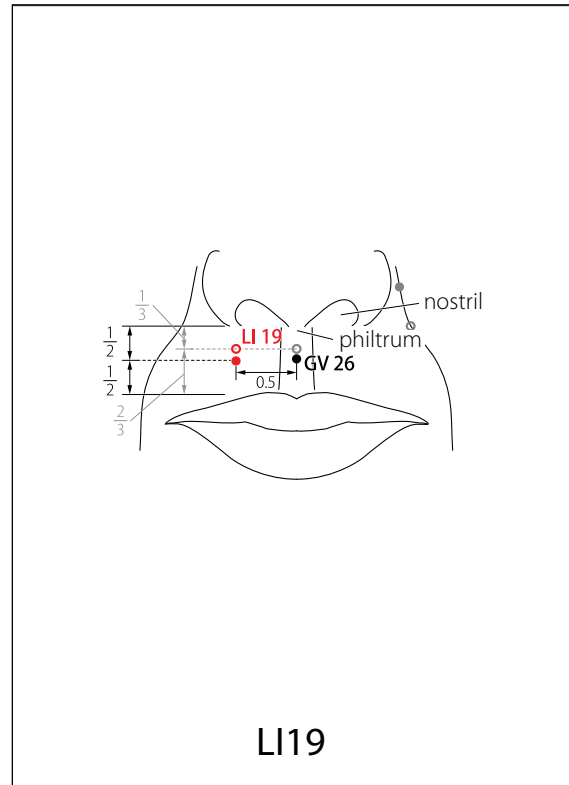


### LI19: Kouheliaio 口禾髎(髎)

On the face, at the same level as the mid-point of the philtrum, inferior to the lateral margin of the nostril.

Note: 0.5 B-cun laterals to GV 26.

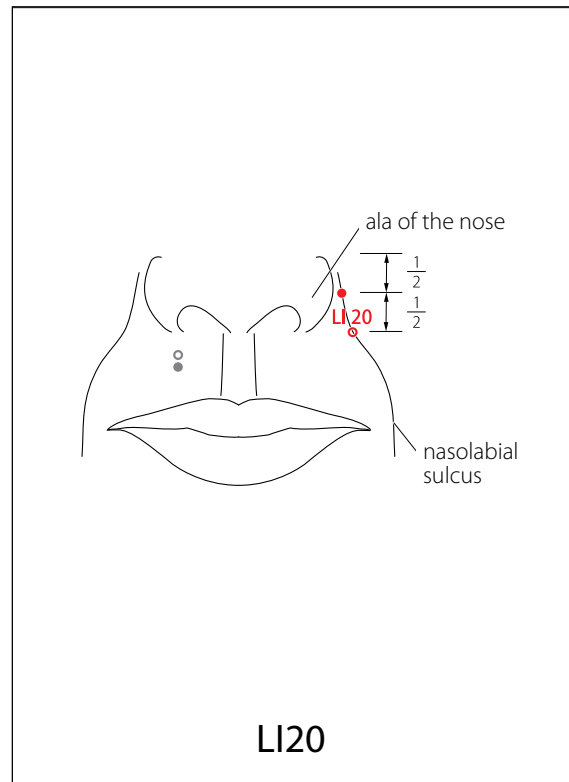
Remarks: Alternative location for LI19 - On the face, at the same level as the junction of the upper one third and lower two thirds of the philtrum, inferior to the lateral margin of the nostril.



### LI20: Yingxiang 迎(迎)香

On the face, in the nasolabial sulcus, at the same level as the midpoint of lateral border of the ala of the nose.

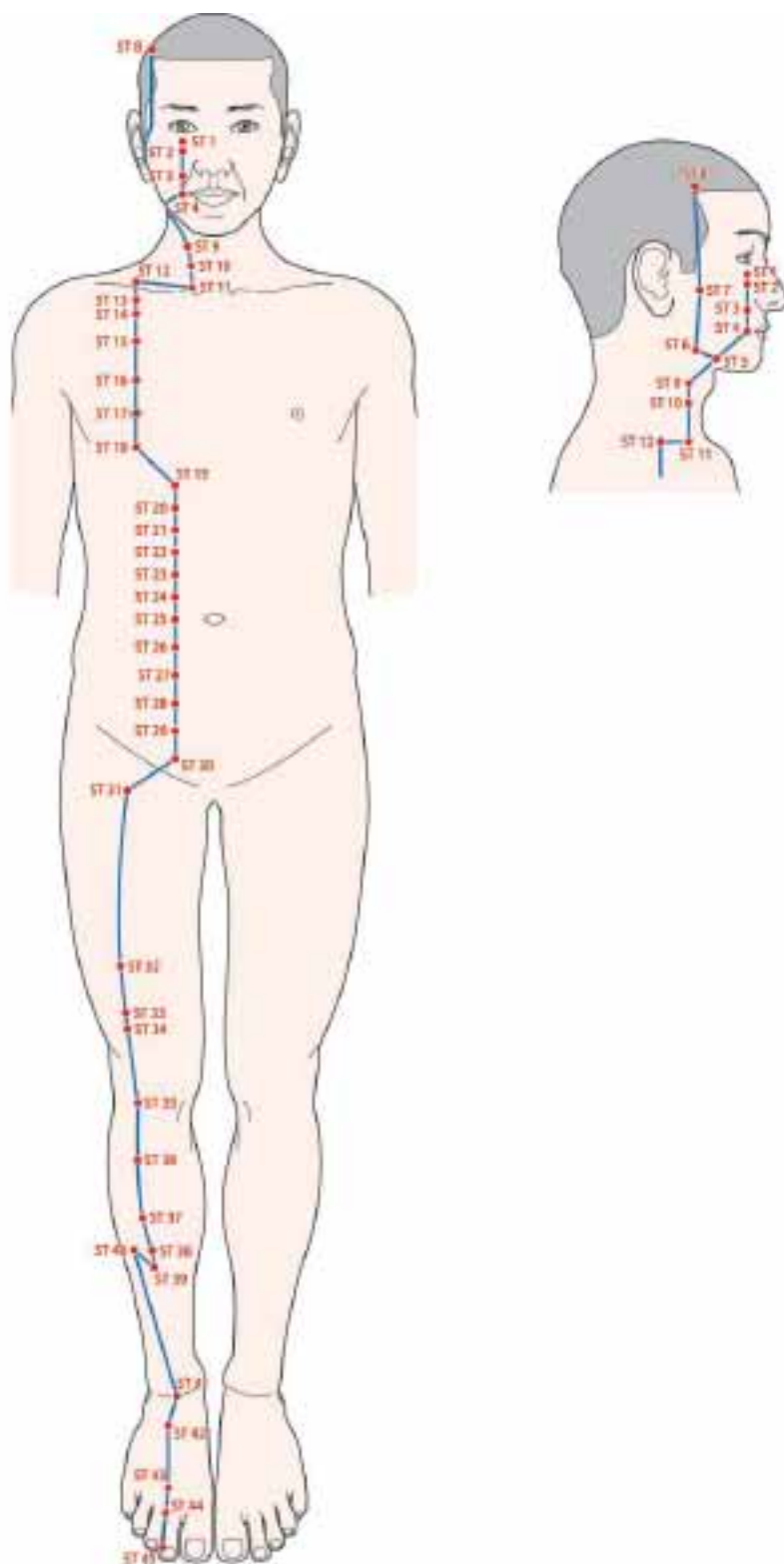
Remarks: Alternative location for LI20 - On the face, in the nasolabial sulcus, at the level of the inferior border of the ala of the nose.





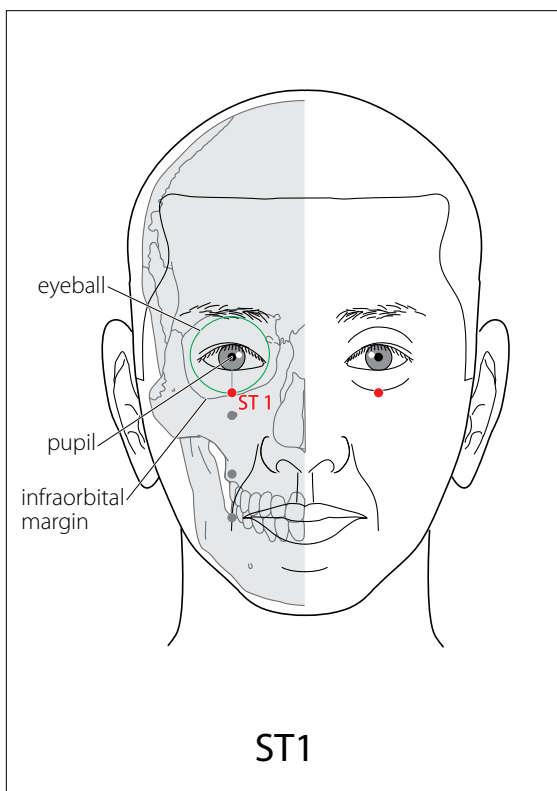
# STOMACH MERIDIAN

## 足陽(阳)明胃經(经, 經)



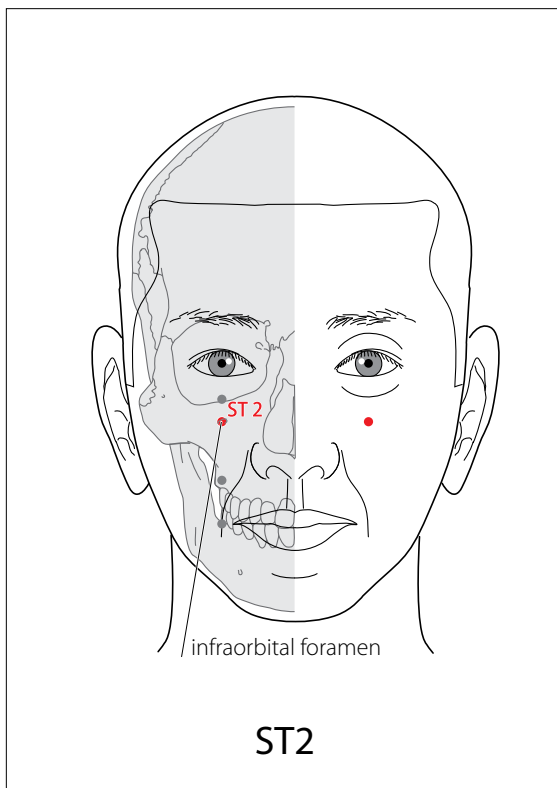
### ST1: Chengqi 承泣

On the face, between the eyeball and the infraorbital margin, directly inferior to the pupil.



### ST2: Sibai 四白

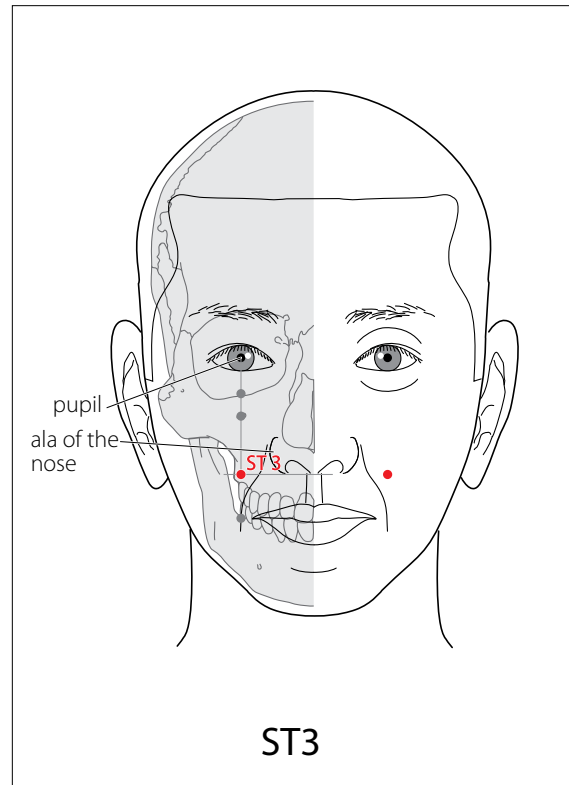
On the face, in the infraorbital foramen.



**ST3: Juliao 巨髎(髎)**

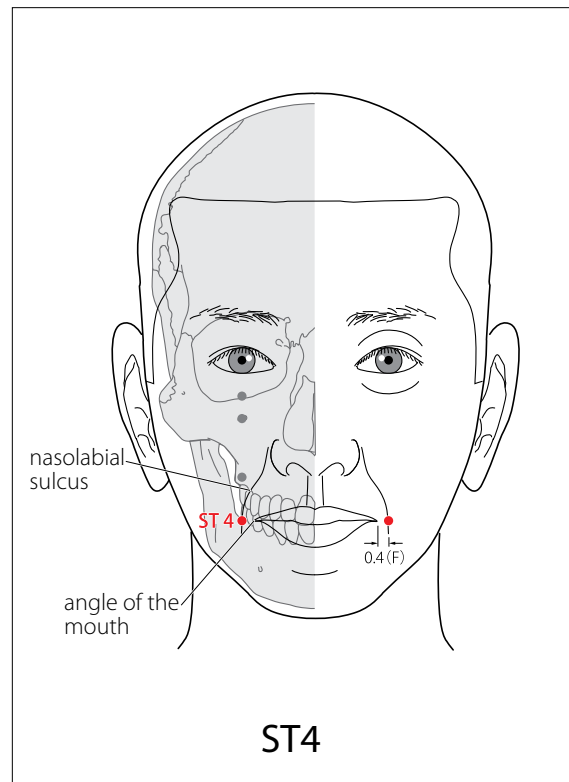
On the face, directly inferior to the pupil, at the same level as the inferior border of the ala of the nose.

Note: When looking straight ahead, ST3 is located at the intersection of the vertical line of the pupil and the horizontal line of the inferior border of the ala of the nose.

**ST4: Dicang 地倉(倉)**

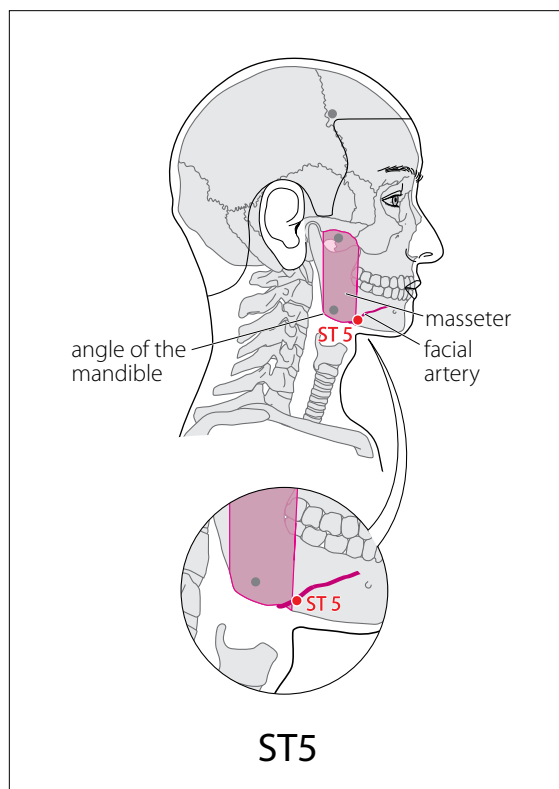
On the face, 0.4 F-cun lateral to the angle of the mouth.

Note: Lateral to the angle of the mouth, the point is located in the nasolabial sulcus or on the continuation of the nasolabial sulcus.



### ST5: Daying 大迎 (迎)

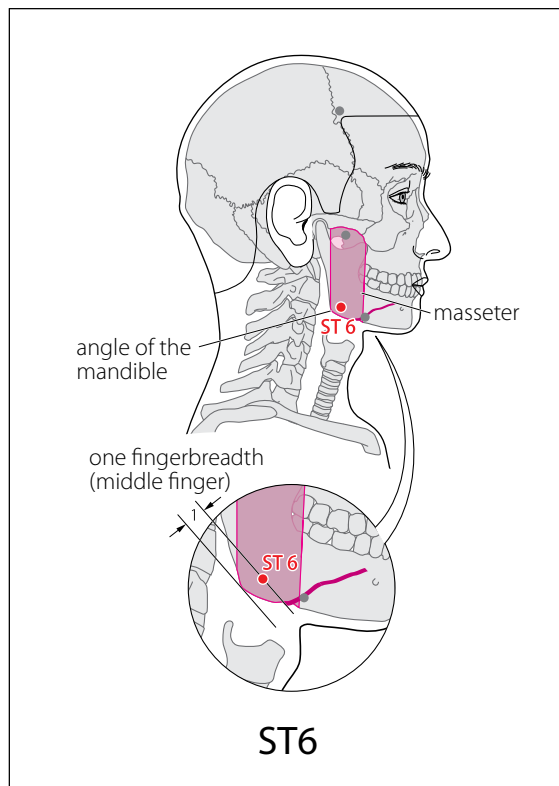
On the face, anterior to the angle of the mandible, in the depression anterior to the masseter attachment, over the facial artery.



### ST6: Jiache 颊 (颊) 车 (车)

On the face, one fingerbreadth (middle finger) anterosuperior to the angle of the mandible.

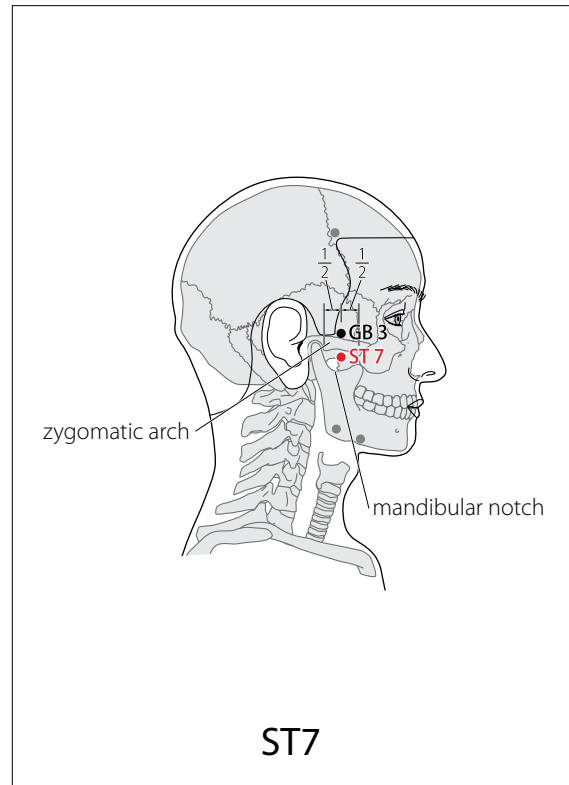
Note: On the bisector of the angle of the mandible. When the mouth is closed and the teeth are clenched, this point is located at the prominence of the masseter and in the depression felt when the clenched teeth are released.



### ST7: Xiaguan 下關(关, 関)

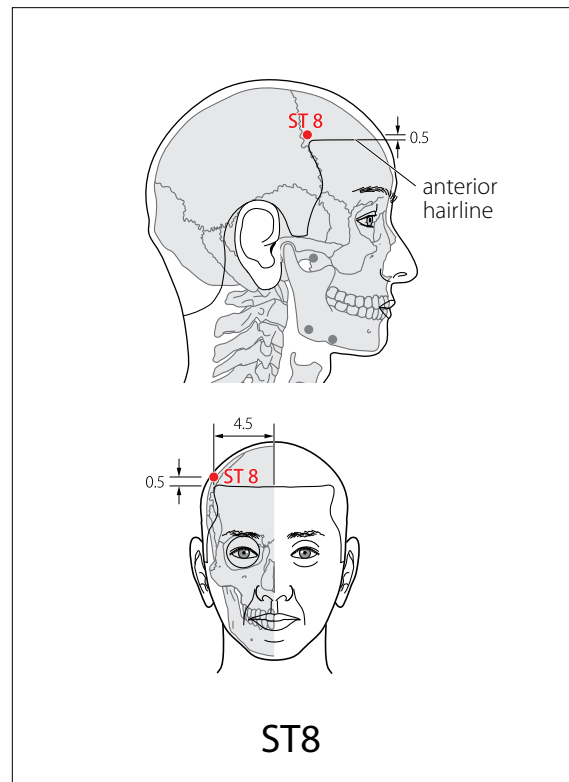
On the face, in the depression between the midpoint of the inferior border of the zygomatic arch and the mandibular notch.

Note: When the mouth is closed, ST7 is located at the depression inferior to the zygomatic arch, directly inferior to GB3.



### ST8: Touwei 頭(头)維(维)

On the head, 0.5 B-cun directly superior to the anterior hairline at the corner of the forehead, 4.5 B-cun lateral to the anterior median line.

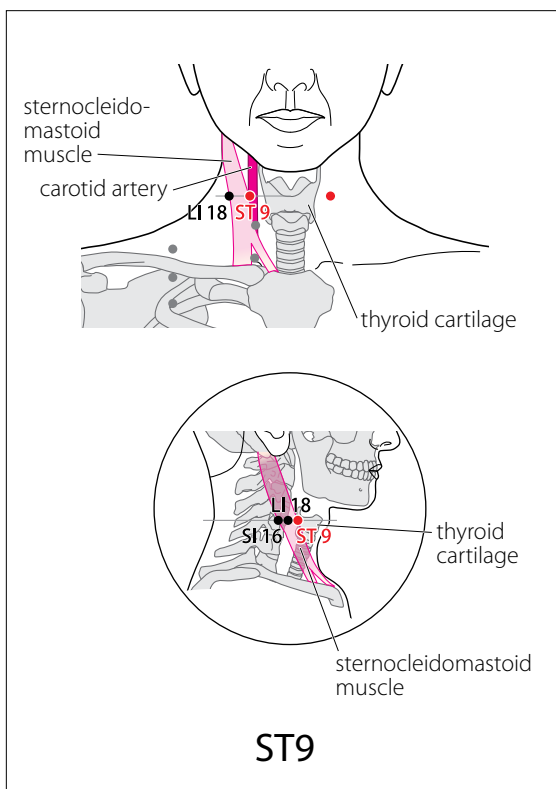


### ST9: Renying 人迎 (迎)

In the anterior region of the neck, at the same level as the superior border of the thyroid cartilage, anterior to the sternocleidomastoid muscle, over the common carotid artery.

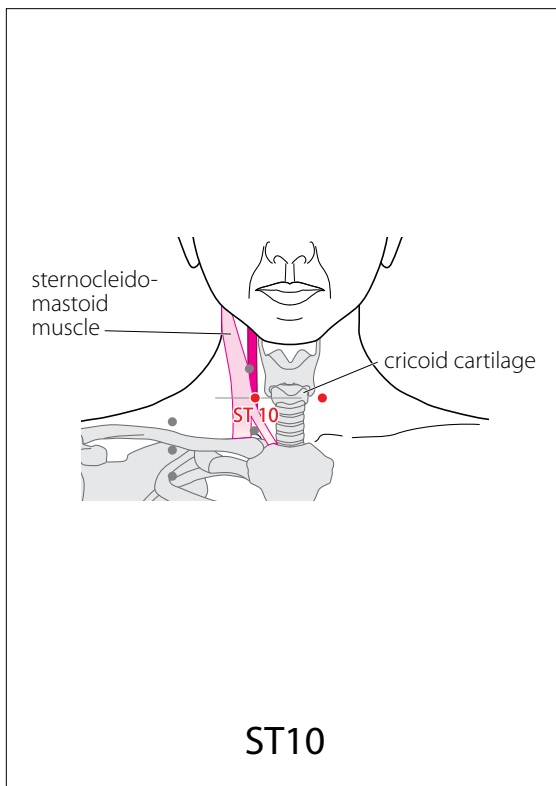
Note 1: The sternocleidomastoid muscle is more distinct when the head is turned to the opposite side against resistance.

Note 2: ST9 is located at the same level as LI18, SI16 and the superior border of the thyroid cartilage. ST9 is located anterior to the sternocleidomastoid muscle, and SI16, posterior to the sternocleidomastoid muscle and LI18, between the anterior and posterior borders of the sternocleidomastoid muscle.



### ST10: Shuitu 水突

In the anterior region of the neck, at the same level as the cricoid cartilage, just anterior to the border of the sternocleidomastoid muscle.

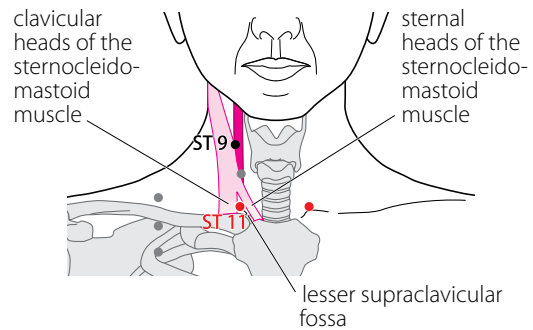


### ST11: Qishe 氣(气, 氣)舍(舍)

In the anterior region of the neck, in the lesser supraclavicular fossa, superior to the sternal end of the clavicle, in the depression between the sternal and clavicular heads of the sternocleidomastoid muscle.

Note 1: The sternocleidomastoid muscle is more distinct when the head is turned to the opposite side against resistance.

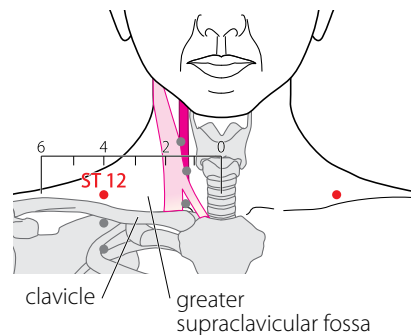
Note 2: ST11 is located superior to the clavicle, inferior to ST9.



ST11

### ST12: Quepen 缺盆

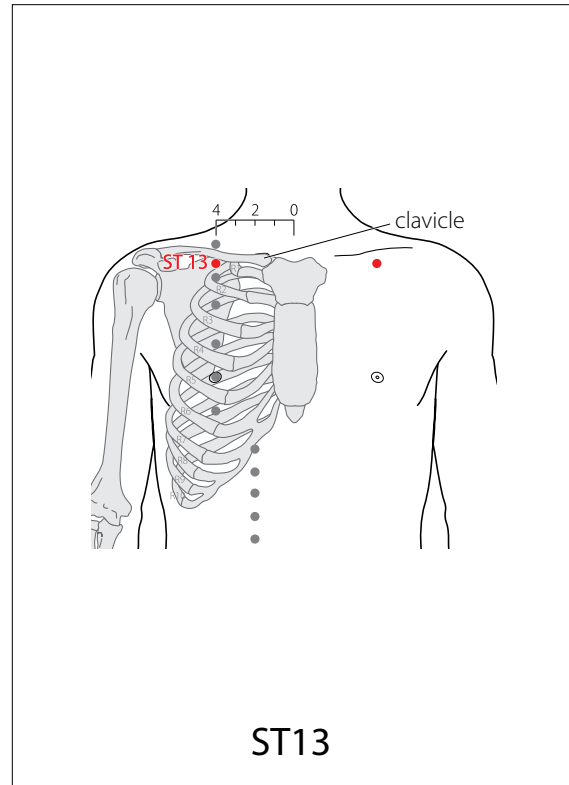
In the anterior region of the neck, in the greater supraclavicular fossa, 4 B-cun lateral to the anterior median line, in the depression superior to the clavicle.



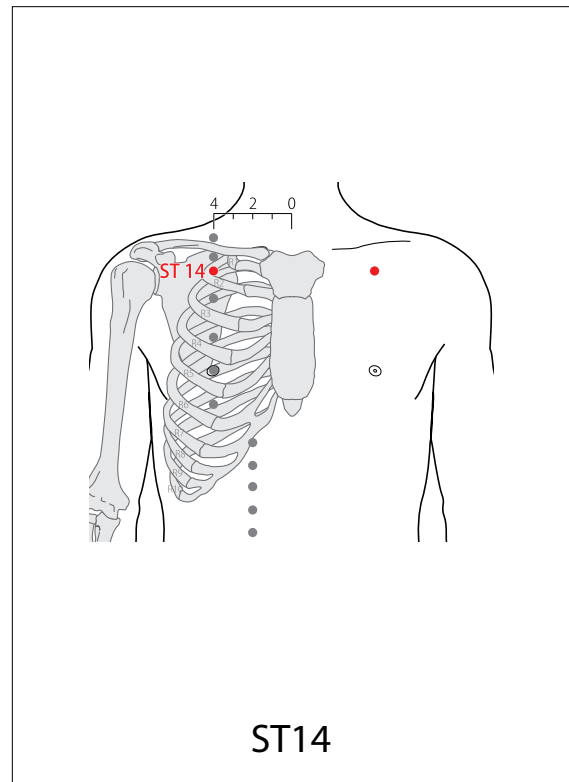
ST12

**ST13: Qihu 氣(气, 氣)戶**

In the anterior thoracic region, inferior to the clavicle, 4 B-cun lateral to the anterior median line.

**ST14: Kufang 庫(库)房**

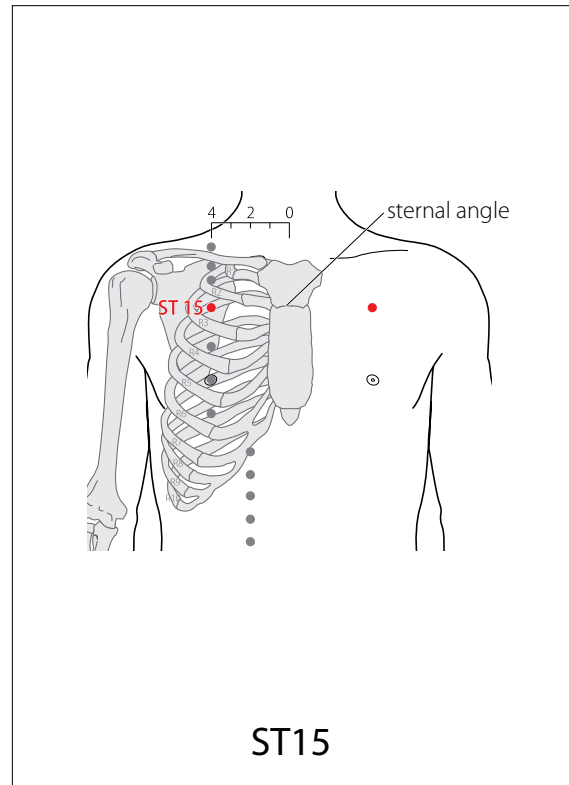
In the anterior thoracic region, in the first intercostal space, 4 B-cun lateral to the anterior median line.



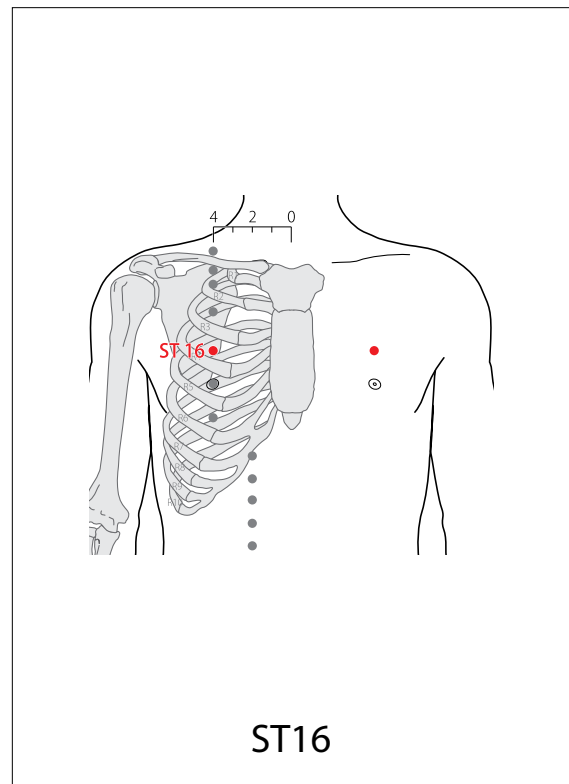
**ST15: Wuyi 屋翳**

In the anterior thoracic region, in the second intercostal space, 4 B-cun lateral to the anterior median line.

Note: The second intercostal space is inferior to the second rib which is located at the same level as the sternal angle.

**ST16: Yingchuang 膺窗 (窓)**

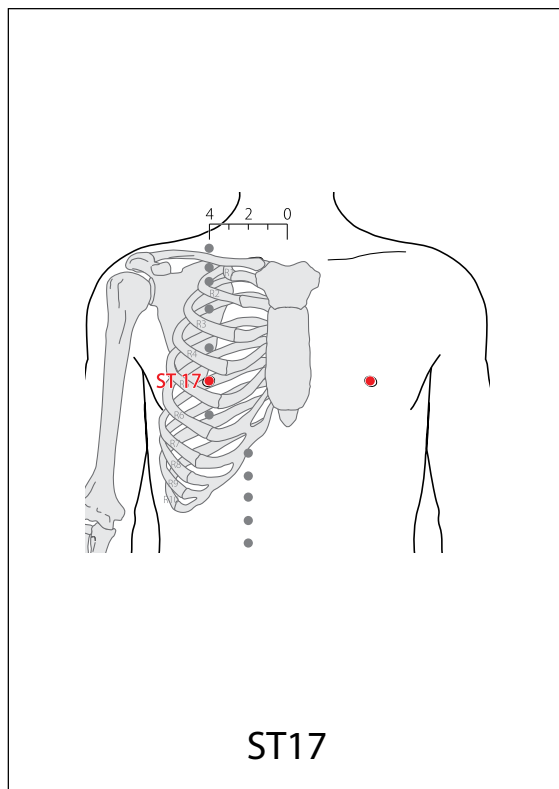
In the anterior thoracic region, in the third intercostal space, 4 B-cun lateral to the anterior median line.



### ST17: Ruzhong 乳(乳)中

In the anterior thoracic region, at the centre of the nipple.

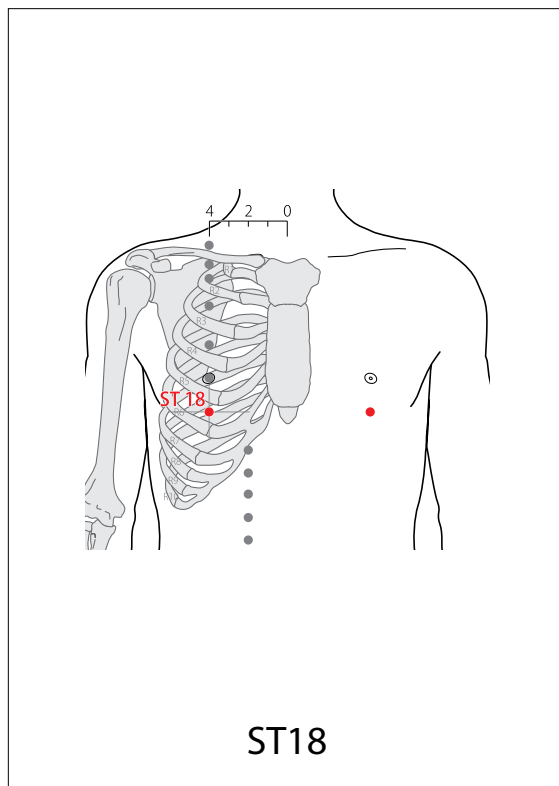
Note: In males, the centre of the nipple is located in the fourth intercostal space.



### ST18: Rugen 乳(乳)根

In the anterior thoracic region, in the fifth intercostal space, 4 B-cun lateral to the anterior median line.

Note: In males, ST18 is located at the intersection of nipple line and the fifth intercostal space. In females, ST18 is located at the midpoint of the inferior crease of the breast.

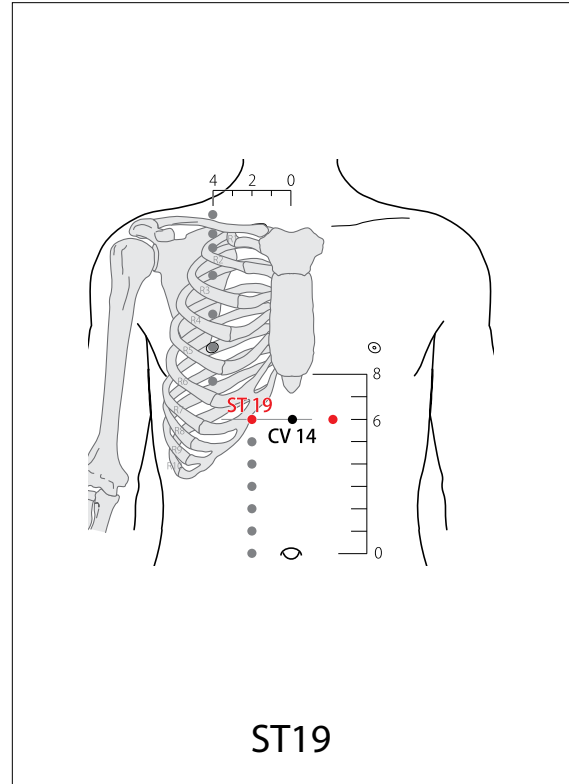


### ST19: Burong 不容

On the upper abdomen, 6 B-cun superior to the centre of the umbilicus, 2 B-cun lateral to the anterior median line.

Note 1: ST 19 is 2 B-cun lateral to CV14.

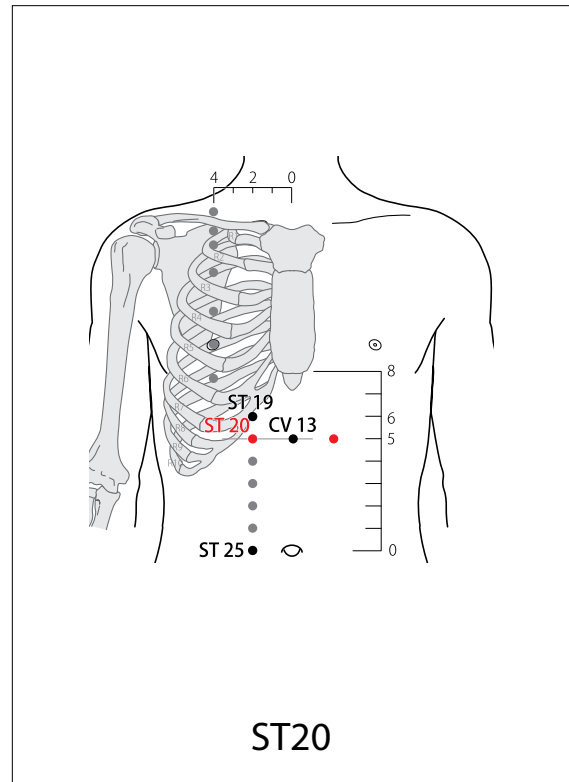
Note 2: If the infrasternal angle is too sharp and the rib is located inferior to ST19, ST19 can be reached by oblique needling.



### ST20: Chengman 承滿 (满, 満)

On the upper abdomen, 5 B-cun superior to the centre of the umbilicus, 2 B-cun lateral to the anterior median line.

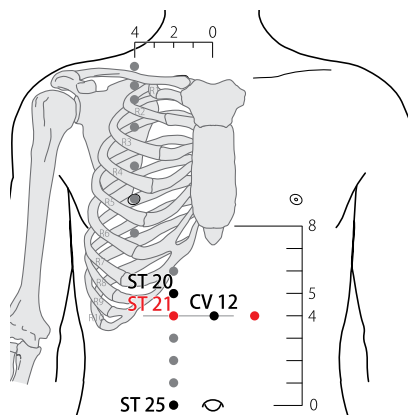
Note: ST20 is 5 B-cun superior to ST25, 1 B-cun inferior to ST19, 2 B-cun lateral to CV13.



### ST21: Liangmen 梁門 (门)

On the upper abdomen, 4 B-cun superior to the centre of the umbilicus, 2 B-cun lateral to the anterior median line.

Note: ST21 is 4 B-cun superior to ST25, 1 B-cun inferior to ST20, 2 B-cun lateral to CV12.

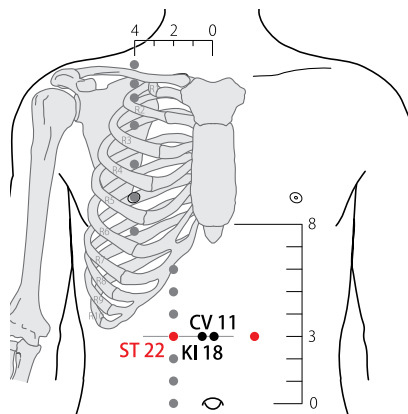


ST21

### ST22: Guanmen 關 (关, 関) 門 (门)

On the upper abdomen, 3 B-cun superior to the centre of the umbilicus, 2 B-cun lateral to the anterior median line.

Note: ST22 is located at the same level and lateral to KI18 and CV11.

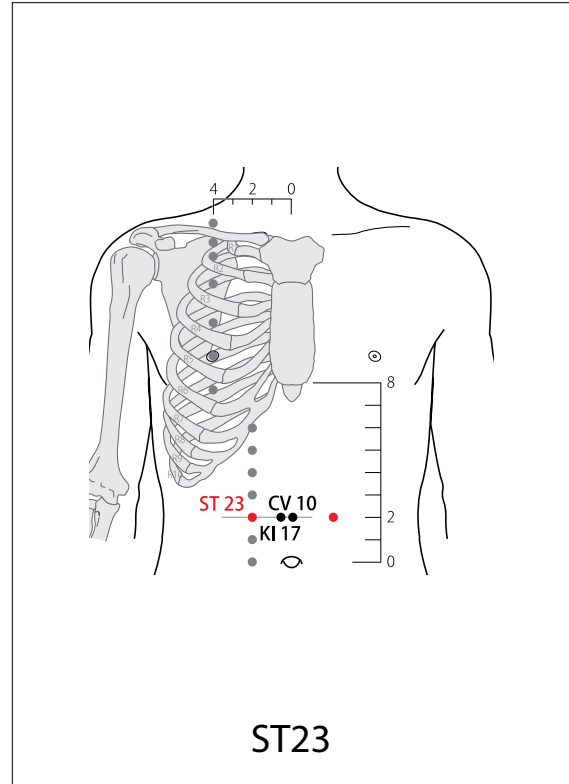


ST22

## ST23: Taiyi 太乙

On the upper abdomen, 2 B-cun superior to the centre of the umbilicus, 2 B-cun lateral to the anterior median line.

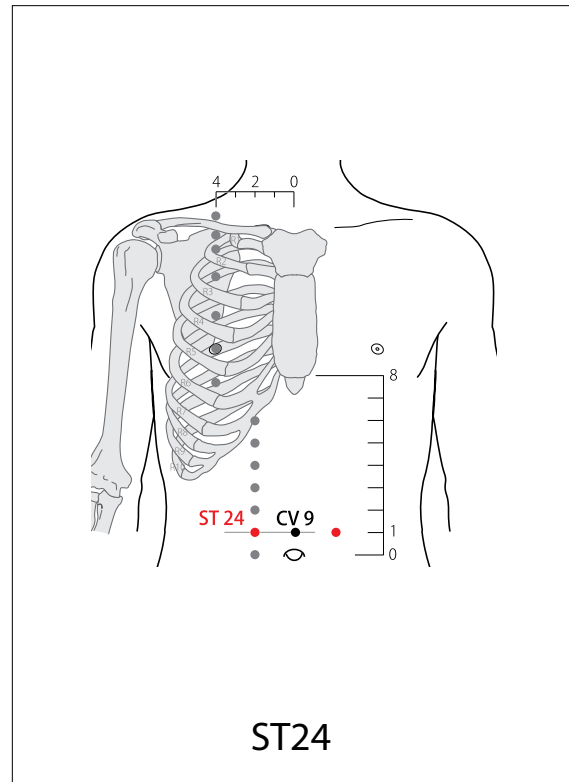
Note: ST23 is located at the same level and lateral to KI17 and CV10.



## ST24: Huaroumen 滑(滑)肉門(门)

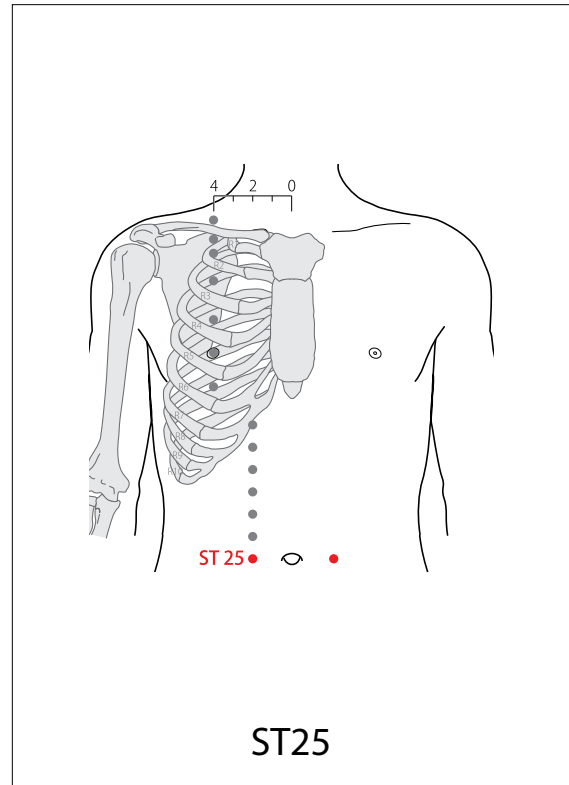
On the upper abdomen, 1 B-cun superior to the centre of the umbilicus, 2 B-cun lateral to the anterior median line.

Note: ST24 is at the same level and lateral to CV9.



### ST25: Tianshu 天樞 (枢)

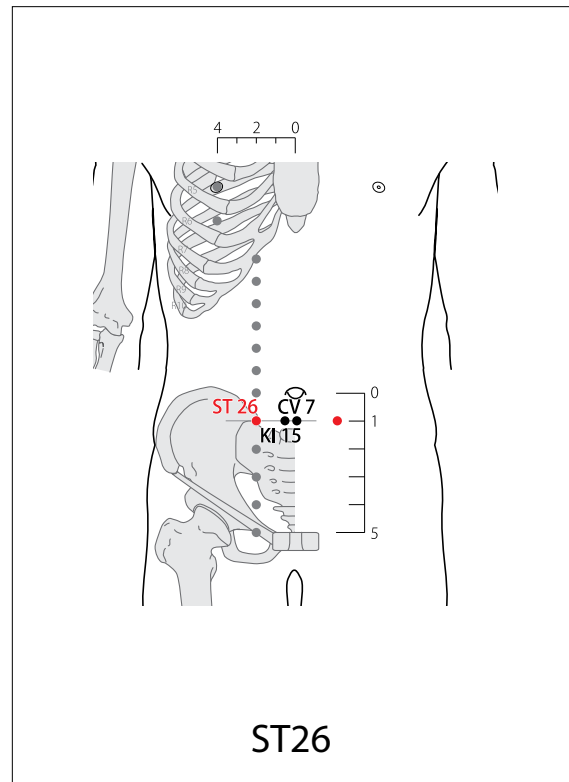
On the upper abdomen, 2 B-cun lateral to the centre of the umbilicus.



### ST26: Wailing 外陵

On the lower abdomen, 1 B-cun inferior to the centre of the umbilicus, 2 B-cun lateral to the anterior median line.

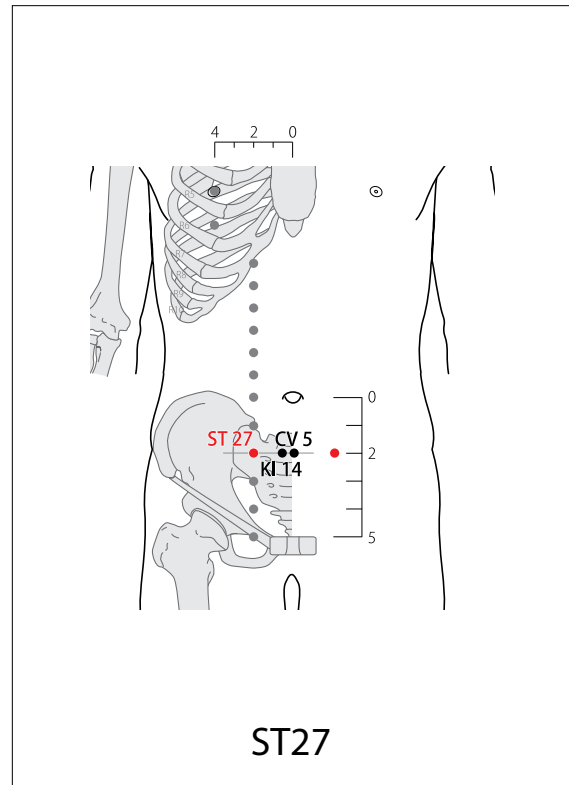
Note: ST26 is at the same level and lateral to KI15 and CV7.



### ST27: Daju 大巨

On the lower abdomen, 2 B-cun inferior to the centre of the umbilicus, 2 B-cun lateral to the anterior median line.

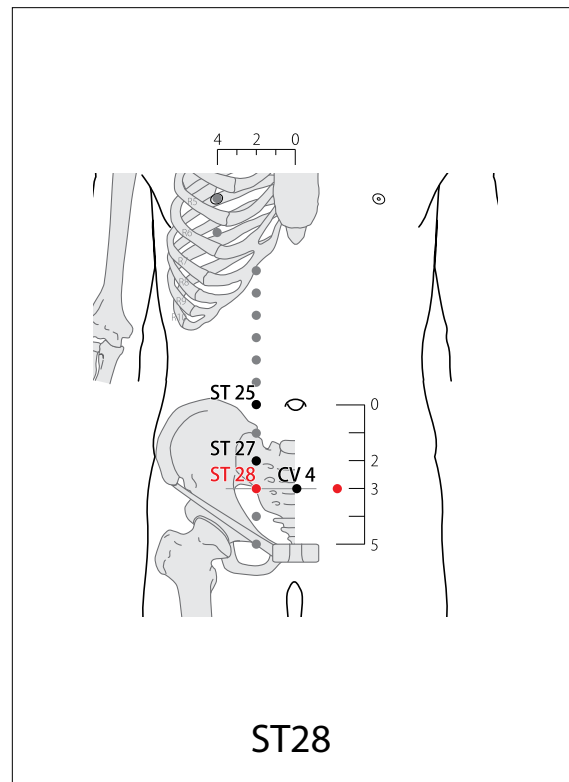
Note: ST27 is at the same level and lateral to KI14 and CV5.



### ST28: Shuidao 水道 (道)

On the lower abdomen, 3 B-cun inferior to the centre of the umbilicus, 2 B-cun lateral to the anterior median line.

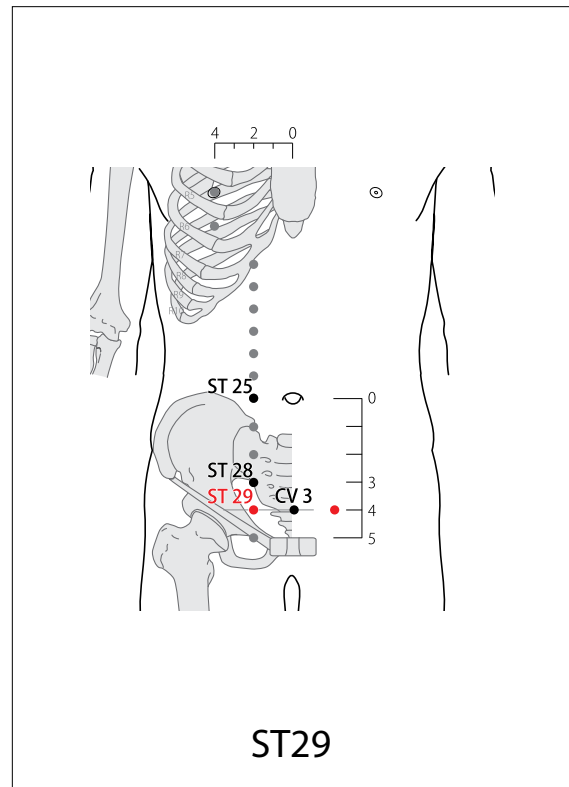
Note: ST28 is 3 B-cun inferior to ST25, 1 B-cun inferior to ST27, 2 B-cun lateral to CV4.



### ST29: Guilai 歸(归, 帰)來(来)

On the lower abdomen, 4 B-cun inferior to the centre of the umbilicus, 2 B-cun lateral to the anterior median line.

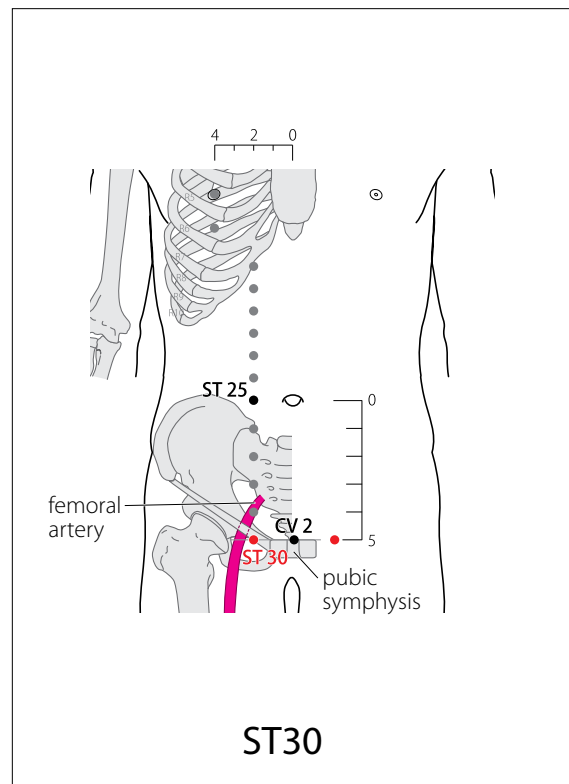
Note: ST29 is 4 B-cun inferior to ST25, 1 B-cun inferior to ST28, 2 B-cun lateral to CV3.



### ST30: Qichong 氣(气, 気)衝(冲)

In the groin region, at the same level as the superior border of the pubic symphysis, 2 B-cun lateral to the anterior median line, over the femoral artery.

Note: ST30 is 5 B-cun inferior to ST25, 2 B-cun lateral to CV2.

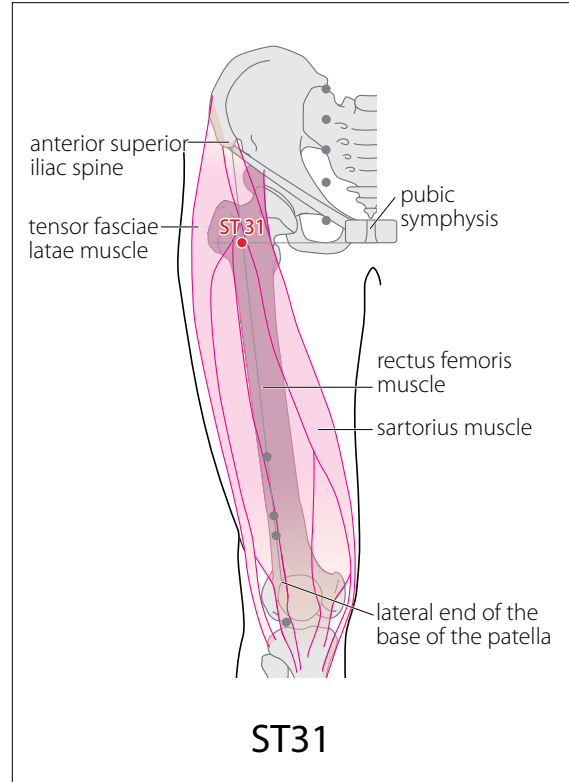


### ST31: Biguan 髀(髀)關(关, 関)

On the anterior aspect of the thigh, in the depression among three muscles: the proximal portion of the rectus femoris muscle, the sartorius muscle and the tensor fasciae latae muscle.

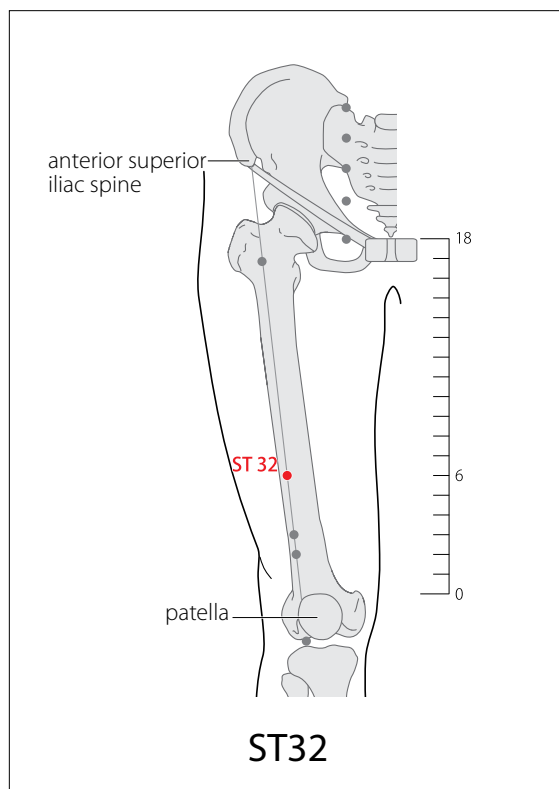
Note 1: With the hip and the knee in slight flexion, and the thigh slightly abducted when resistance is placed against the anteromedial aspect of the thigh, a triangular depression appears. The proximal portion of the rectus femoris muscle is found in the depression between the sartorius muscle medially and the tensor fascia latae muscle laterally. ST31 is located at the deepest point in the depression inferior to the apex of this triangle.

Note 2: ST31 is located at the intersection of the line connecting the lateral end of the base of the patella with the anterior superior iliac spine, and the horizontal line of the inferior border of the pubic symphysis.



### ST32: Futu 伏兔 (兔)

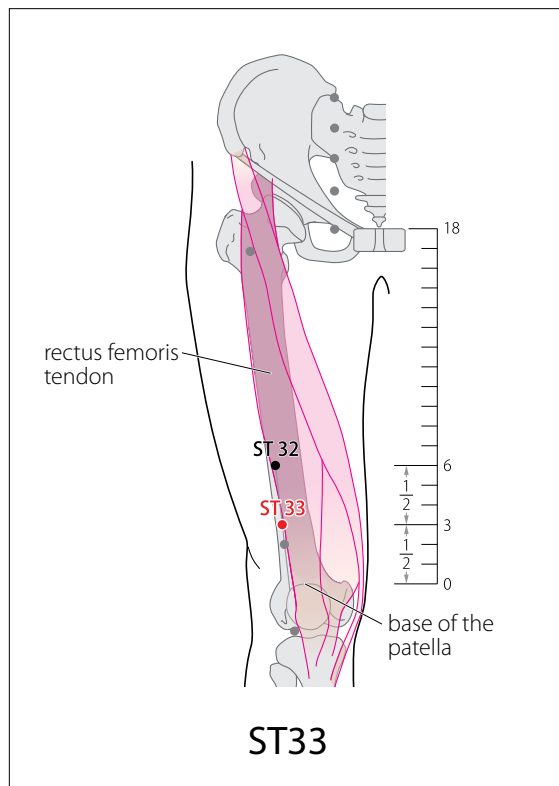
On the anterolateral aspect of the thigh, on the line connecting the lateral end of the base of the patella with the anterior superior iliac spine, 6 B-cun superior to the base of the patella.



### ST33: Yinshi 陰 (阴) 市

On the anterolateral aspect of the thigh, lateral to the rectus femoris tendon, 3 B-cun superior to the base of the patella.

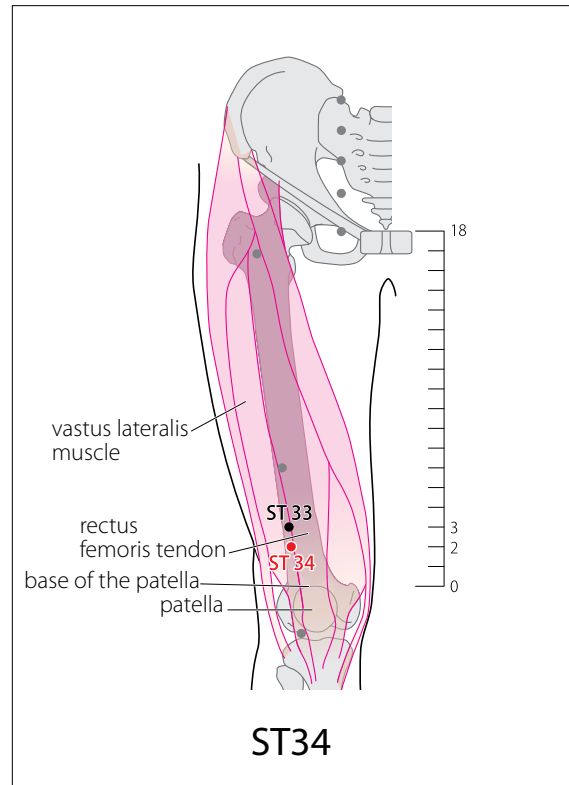
Note: ST33 is at the midpoint of the line connecting ST32 with the lateral end of the base of the patella.



## ST34: Liangqiu 梁丘

On the anterolateral aspect of the thigh, between the vastus lateralis muscle and the lateral border of the rectus femoris tendon, 2 B-cun superior to the base of the patella.

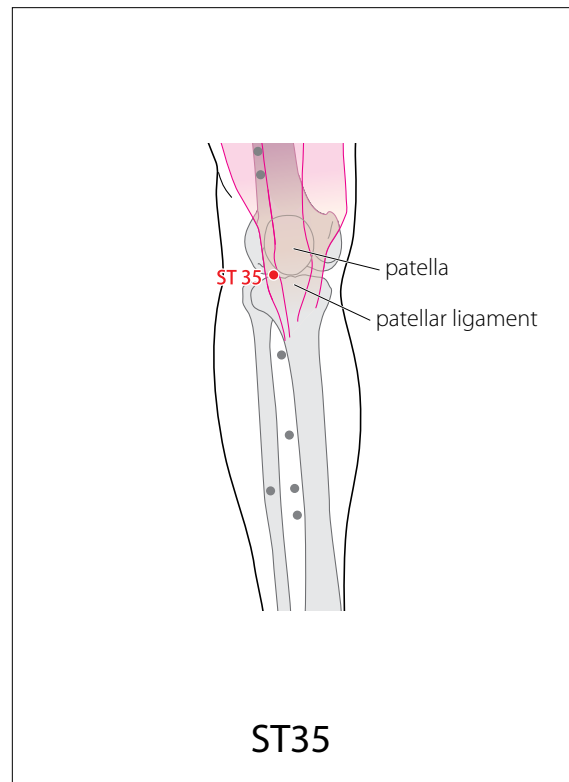
Note: Putting the thigh muscle under tension, the rectus femoris tendon and the vastus lateralis muscle are more distinct. ST34 is located between the muscle and the tendon, 1 B-cun directly inferior to ST33.



## ST35: Dubi 犢(犊)鼻

On the anterior aspect of the knee, in the depression lateral to the patellar ligament.

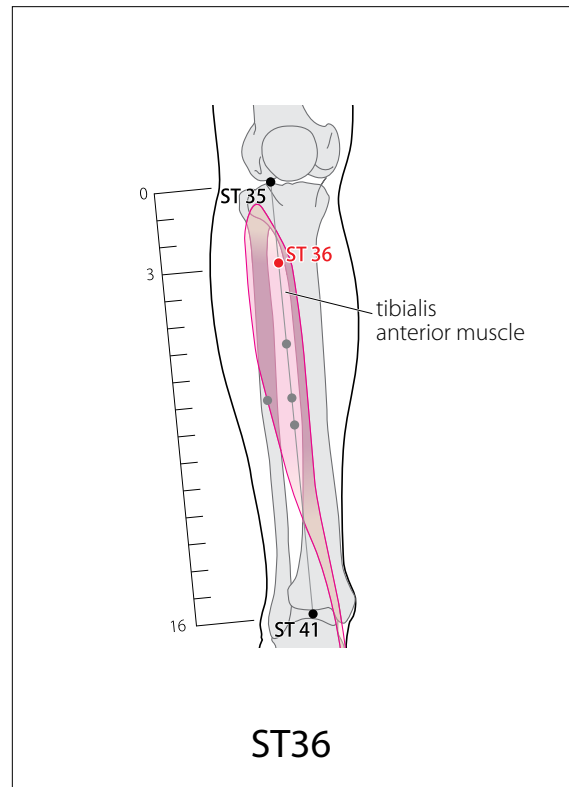
Note: When the knee is flexed, ST35 is located in the depression lateral and inferior to the patella.



### ST36: Zusanli 足三里

On the anterior aspect of the leg, on the line connecting ST35 with ST41, 3 B-cun inferior to ST35.

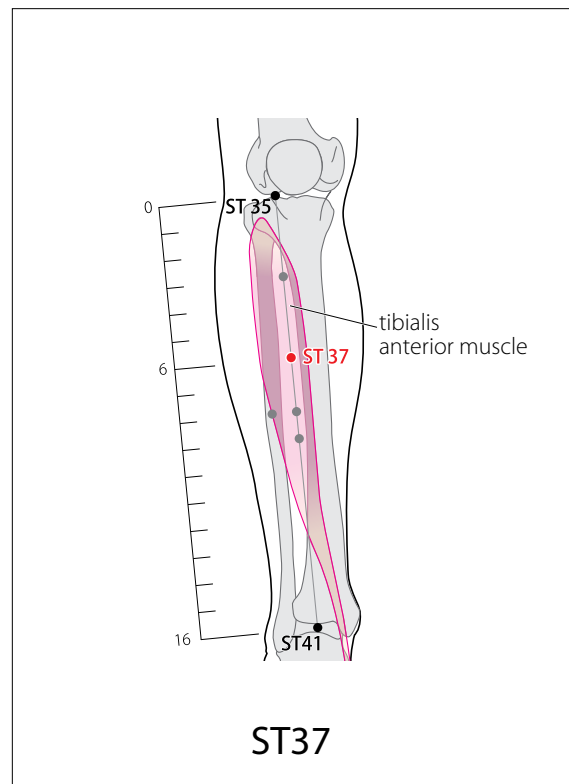
Note: ST36 is located on the tibialis anterior muscle.



### ST37: Shangjuxu 上巨虚 (虚)

On the anterior aspect of the leg, on the line connecting ST35 with ST41, 6 B-cun inferior to ST35.

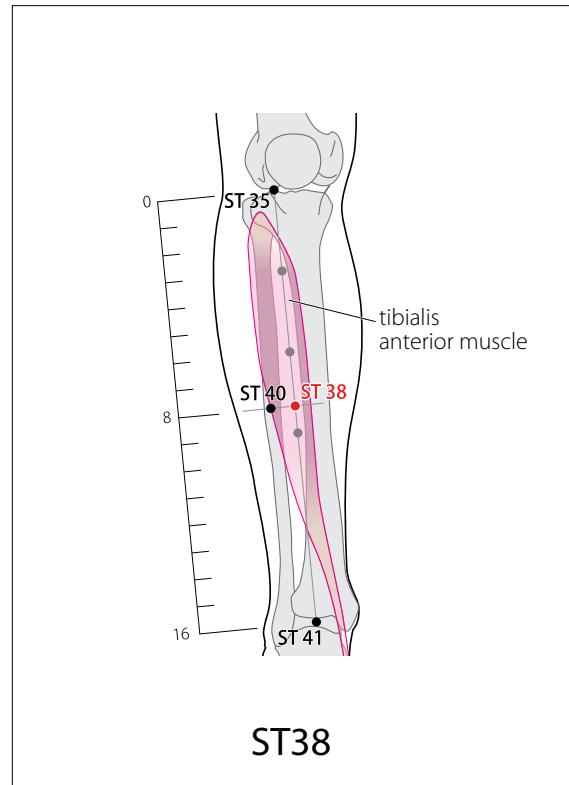
Note: ST37 is located on the tibialis anterior muscle.



### ST38: Tiaokou 條(条)口

On the anterior aspect of the leg, on the line connecting ST35 with ST41, 8 B-cun inferior to ST35.

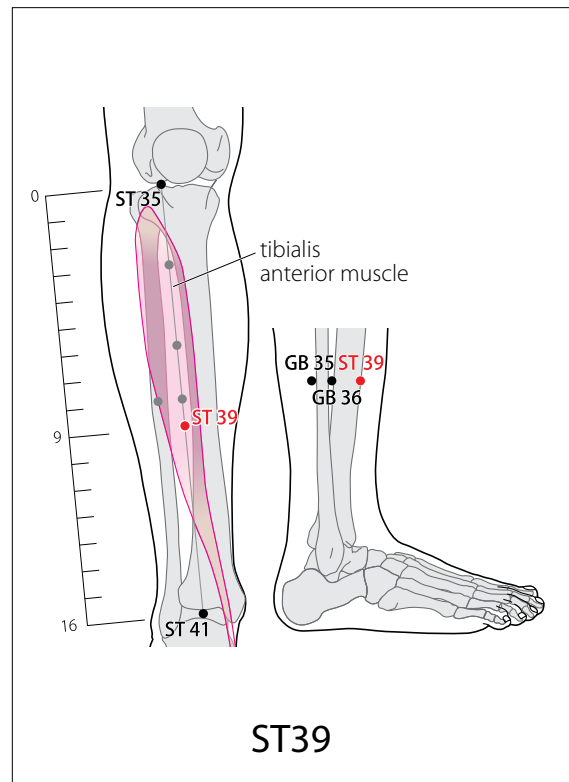
Note: ST38 is located on the tibialis anterior muscle, at the same level as ST40.



### ST39: Xiajuxu 下巨虛(虛)

On the anterior aspect of the leg, on the line connecting ST35 with ST41, 9 B-cun inferior to ST35.

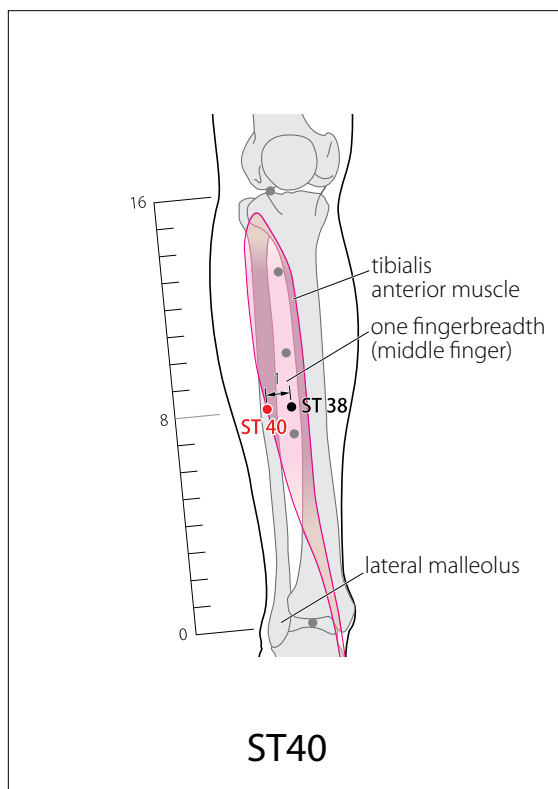
Note: ST39 is located on the tibialis anterior muscle, at the same level as GB35 and GB36.



### ST40: Fenglong 豐(丰, 豊)隆(隆)

On the anterolateral aspect of the leg, lateral border of the tibialis anterior muscle, 8 B-cun superior to the prominence of the lateral malleolus.

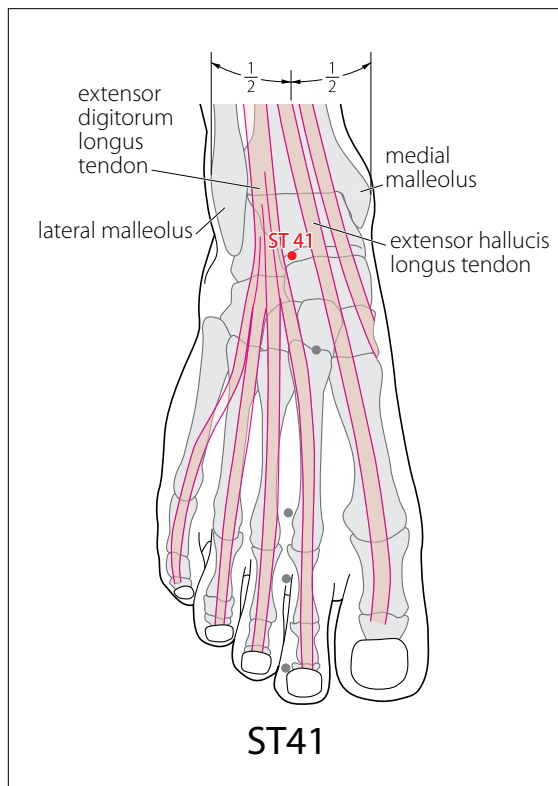
Note: ST40 is one fingerbreadth (middle finger) lateral to ST38.



### ST41: Jiexi 解谿(溪)

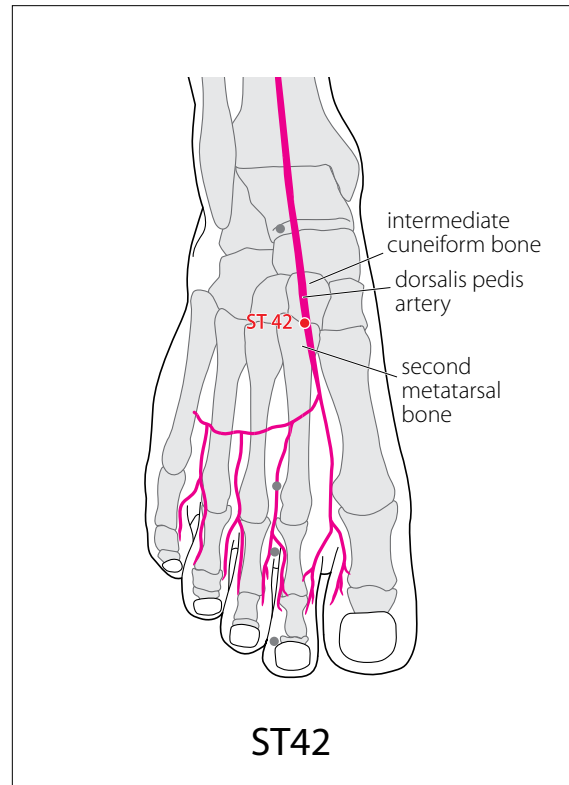
On the anterior aspect of the ankle, in the depression at the centre of the front surface of the ankle joint, between the tendons of extensor hallucis longus and extensor digitorum longus.

Note: ST41 is located between two tendons on the dorsum of the foot which are more distinct when the ankle is in dorsiflexion, and is at the midpoint of the line connecting the prominences of the lateral malleolus and the medial malleolus.

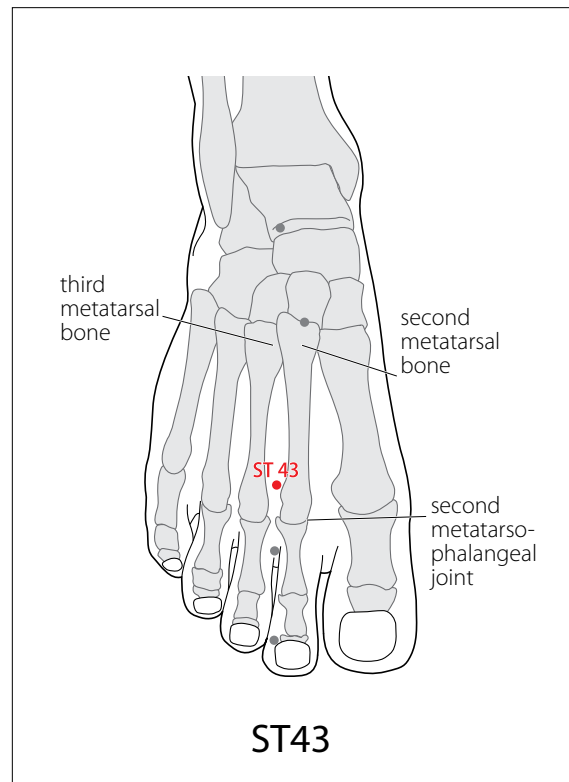


**ST42: Chongyang 衝(冲)陽(阳)**

On the dorsum of the foot, at the joint of the base of the second metatarsal bone and the intermediate cuneiform bone, over the dorsalis pedis artery.

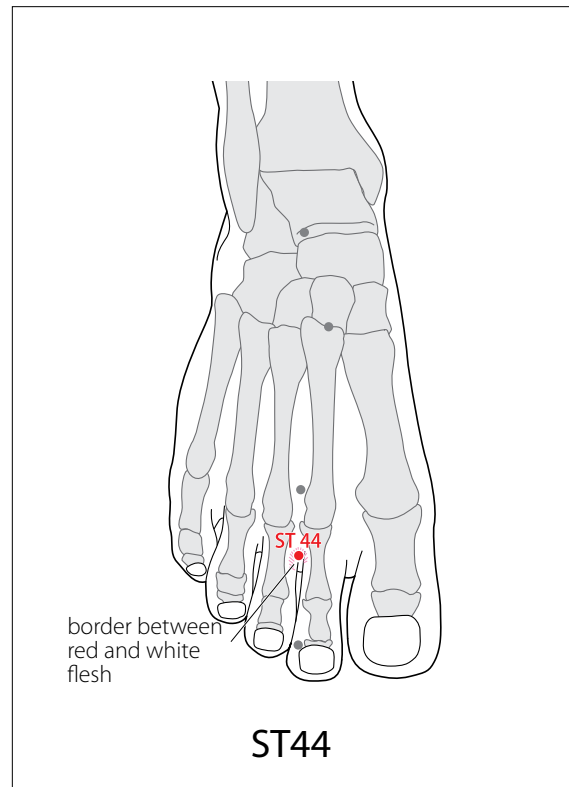
**ST43: Xiangu 陷(陷)谷**

On the dorsum of the foot, between the second and third metatarsal bones, in the depression proximal to the second metatarso-phalangeal joint.

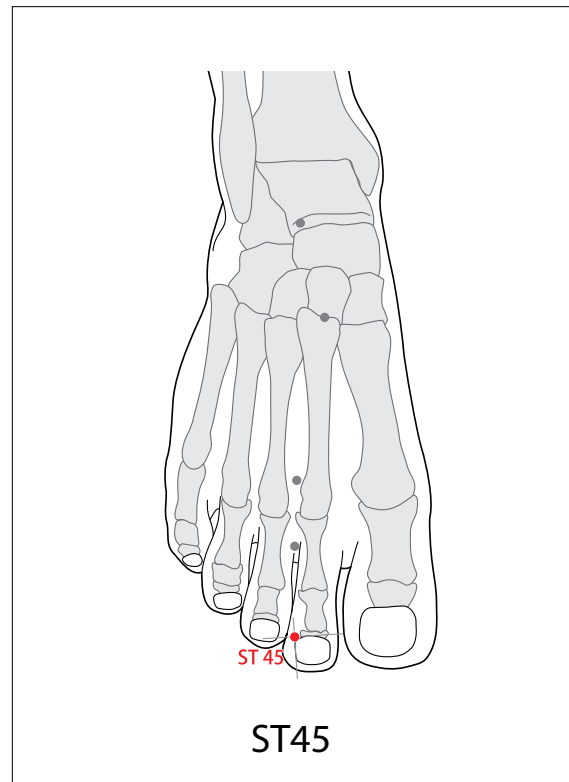


**ST44: Neiting 内庭**

On the dorsum of the foot, between the second and third toes, posterior to the web margin, at the border between the red and white flesh.

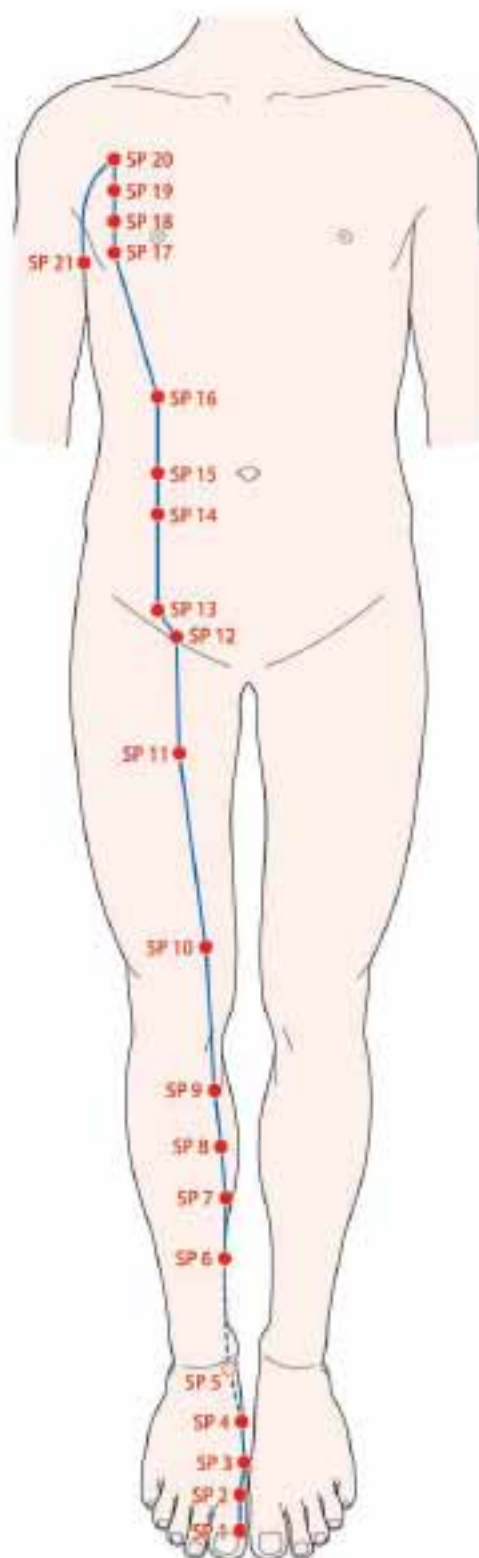
**ST45: Lidui 厲 (厉) 兑 (兑)**

On the second toe, lateral to the distal phalanx, 0.1 F-cun proximal-lateral to the lateral corner of the second toenail, at the intersection of the vertical line of the lateral border and the horizontal line of the base of the second toenail.



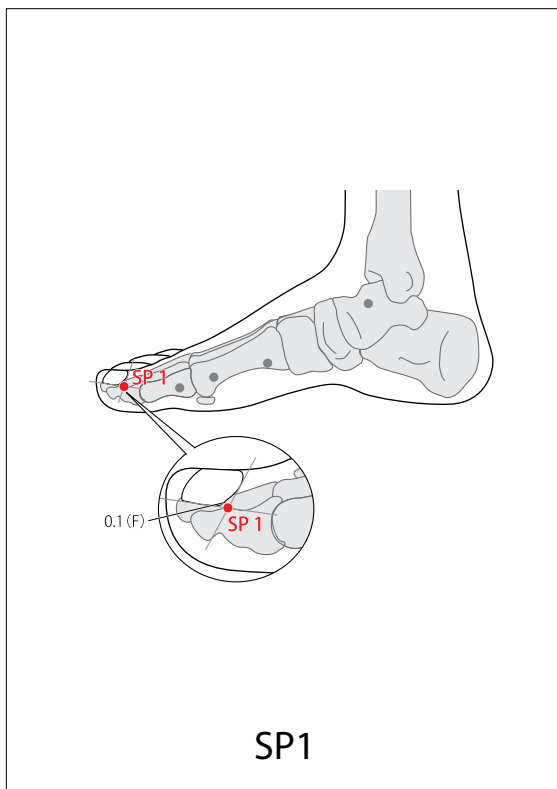
## SPLEEN MERIDIAN

足太陰(阴)脾經(经, 經)



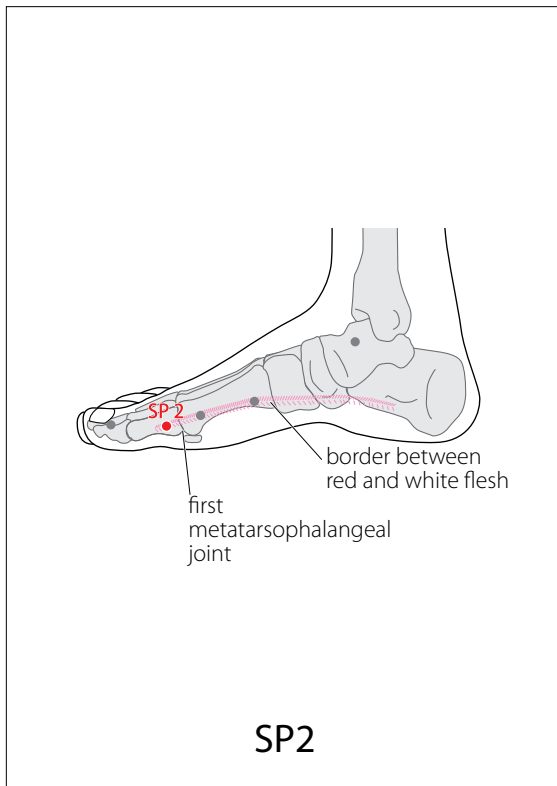
### SP1: Yinbai 隱(隱, 隱)白

On the great toe, medial to the distal phalanx, 0.1 F-cun proximal-medial to the medial corner of the toenail, at the intersection of the vertical line of the medial border and horizontal line of the base of the toenail.



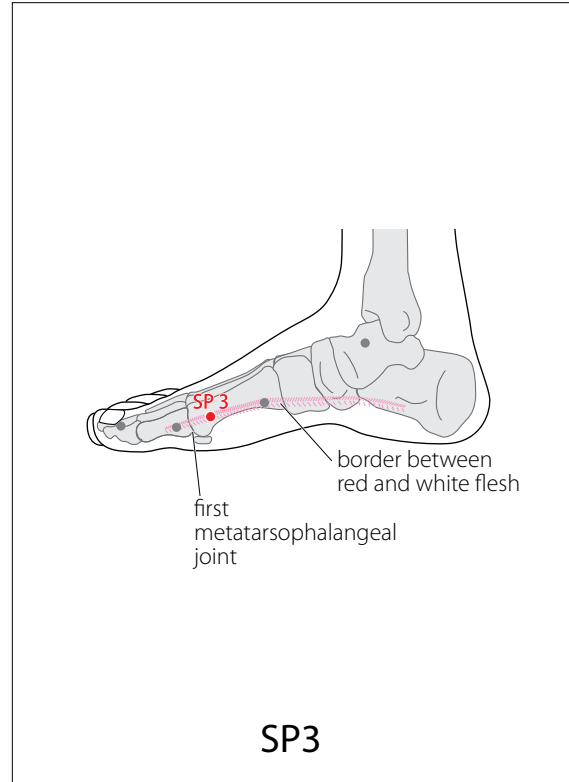
### SP2: Dadu 大都(都)

On the great toe, in the depression distal to the first metatarsophalangeal joint, at the border between the red and white flesh.



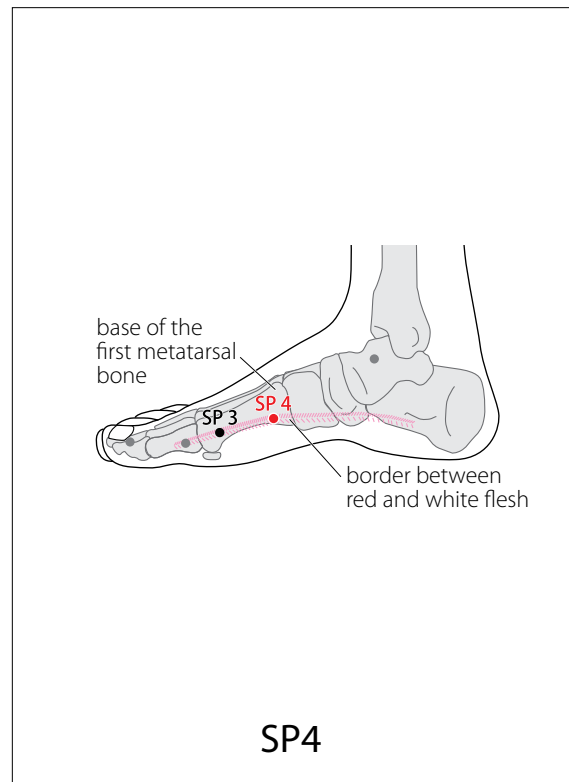
**SP3: Taibai 太白**

On the medial aspect of the foot, in the depression proximal to the first metatarsophalangeal joint, at the border between the red and white flesh.

**SP4: Gongsun 公孫 (孫)**

On the medial aspect of the foot, antero-inferior to the base of the first metatarsal bone, at the border between the red and white flesh.

Note: A depression can be felt when moving proximally from SP3. SP4 is located in the depression distal to the base of the first metatarsal bone.

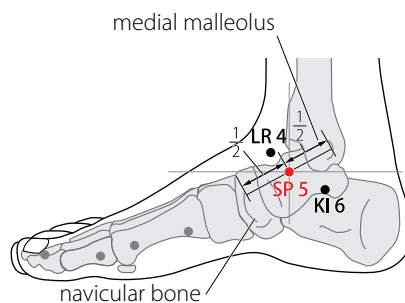


### SP5: Shangqiu 商丘

On the medial aspect of the foot, antero-inferior to the medial malleolus, in the depression midway between the tuberosity of the navicular bone and the prominence of the medial malleolus.

Note 1: SP5 is located at the intersection of two imaginary lines: the vertical line of the anterior border of the medial malleolus and the horizontal line of the inferior border of the medial malleolus.

Note 2: SP5 is located posterior to LR4 and anterior to KI6.

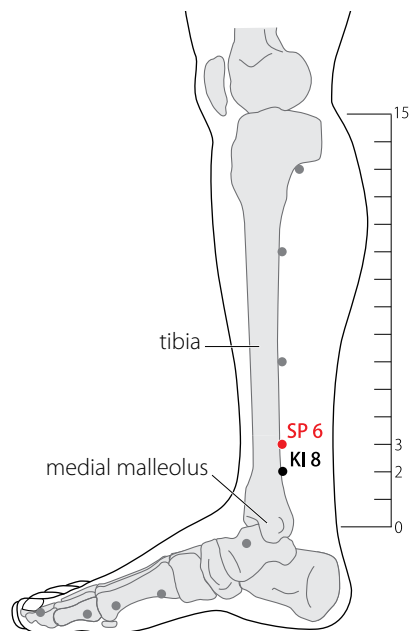


SP5

### SP6: Sanyinjiao 三陰(阴)交

On the tibial aspect of the leg, posterior to the medial border of the tibia, 3 B-cun superior to the prominence of the medial malleolus.

Note: 1 B-cun superior to KI8.

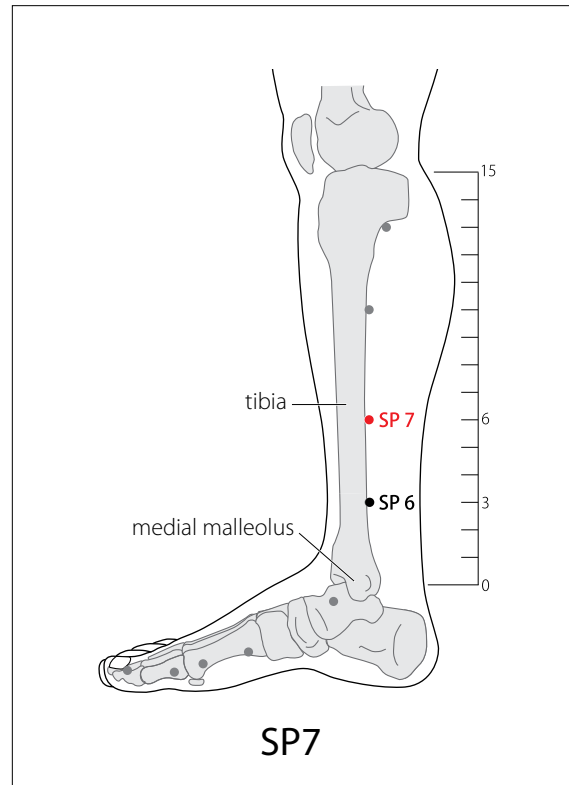


SP6

### SP7: Lougu 漏谷

On the tibial aspect of the leg, posterior to the medial border of the tibia, 6 B-cun superior to the prominence of the medial malleolus.

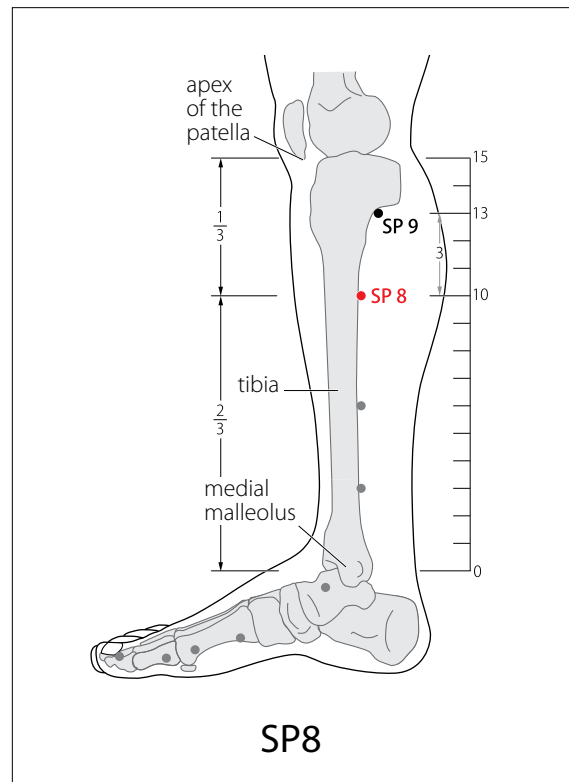
Note: 3 B-cun superior to SP6.



### SP8: Diji 地機(机)

On the tibial aspect of the leg, posterior to the medial border of the tibia, 3 B-cun inferior to SP9.

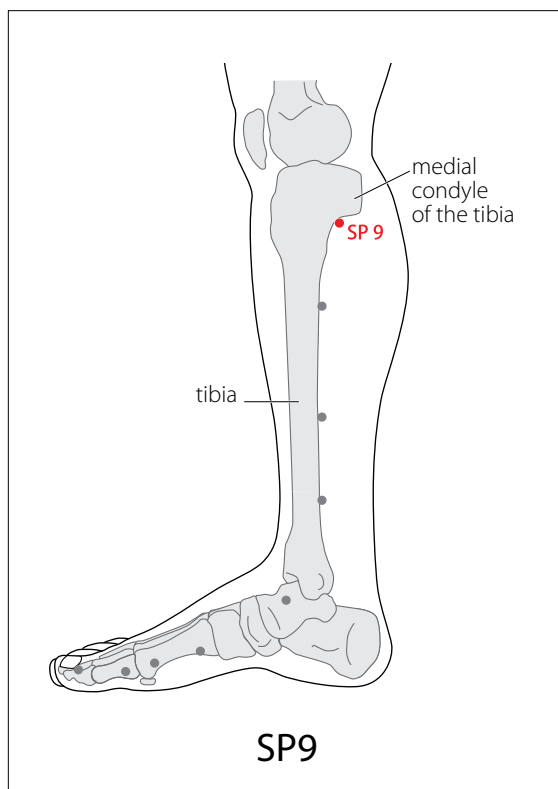
Note: SP8 is located at the junction of the upper one third and lower two thirds of the line connecting the apex of the patella with the prominence of the medial malleolus.



### SP9: Yinlingquan 陰(阴)陵泉

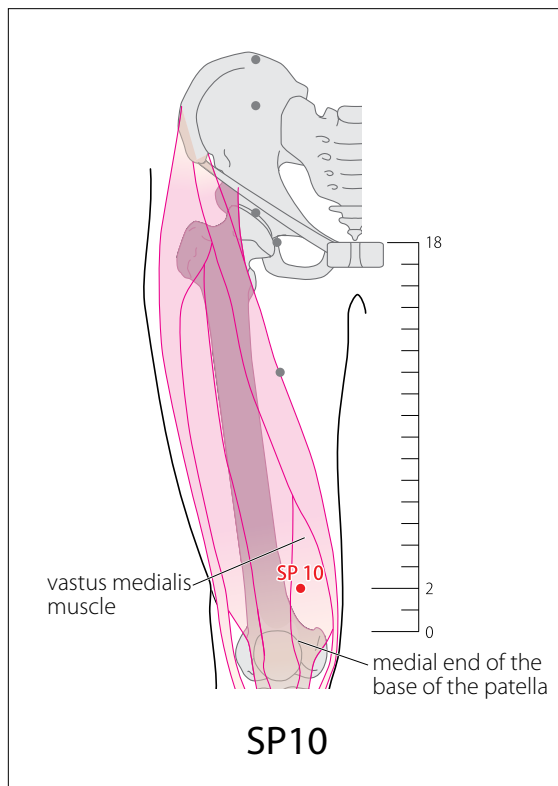
On the tibial aspect of the leg, in the depression between the inferior border of the medial condyle of the tibia and the medial border of the tibia.

Note: A depression can be felt inferior to the knee joint when moving proximally along the medial border of the tibia. SP9 is located in a depression at the angle formed by the inferior border of the medial condyle of the tibia and the posterior border of the tibia.



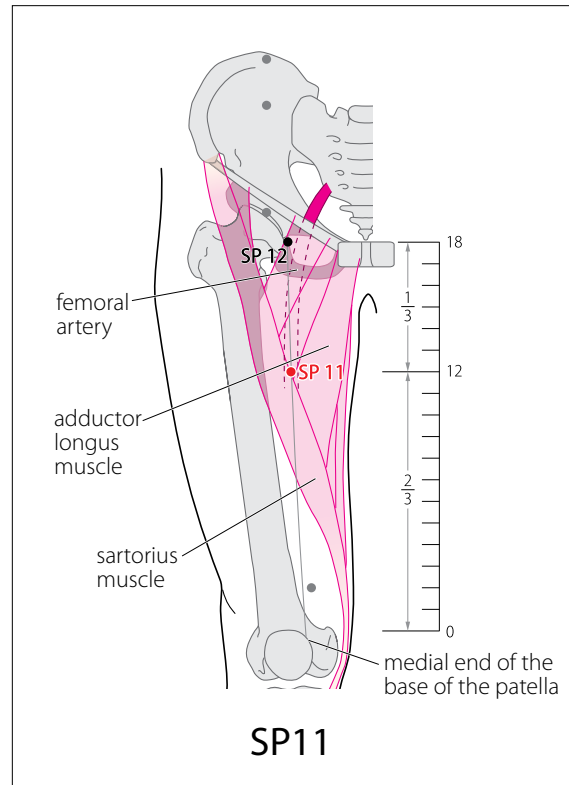
### SP10: Xuehai 血海(海)

On the anteromedial aspect of the thigh, on the bulge of the vastus medialis muscle, 2 B-cun superior to the medial end of the base of the patella.



### SP11: Jimen 箕門 (門)

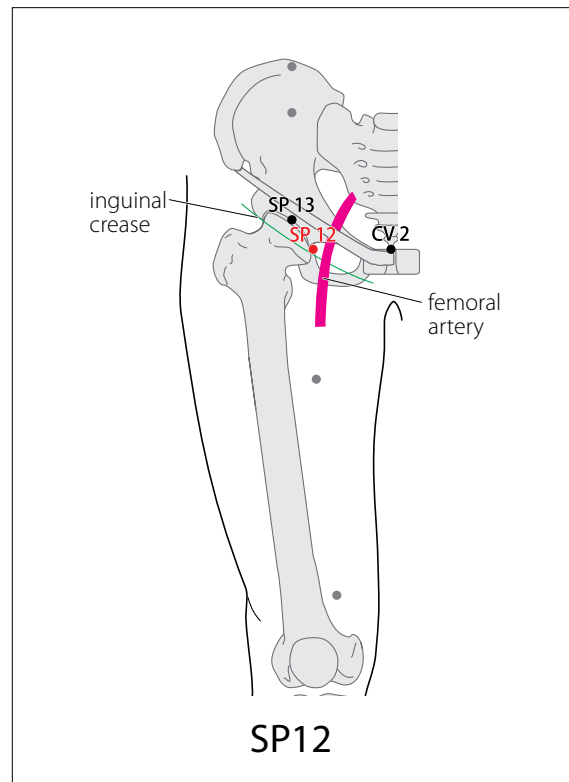
On the medial aspect of the thigh, at the junction of the upper one third and lower two thirds of the line connecting the medial end of the base of the patella with SP12, between the sartorius muscle and the adductor longus muscle, over the femoral artery.



### SP12: Chongmen 衝 (冲) 門 (門)

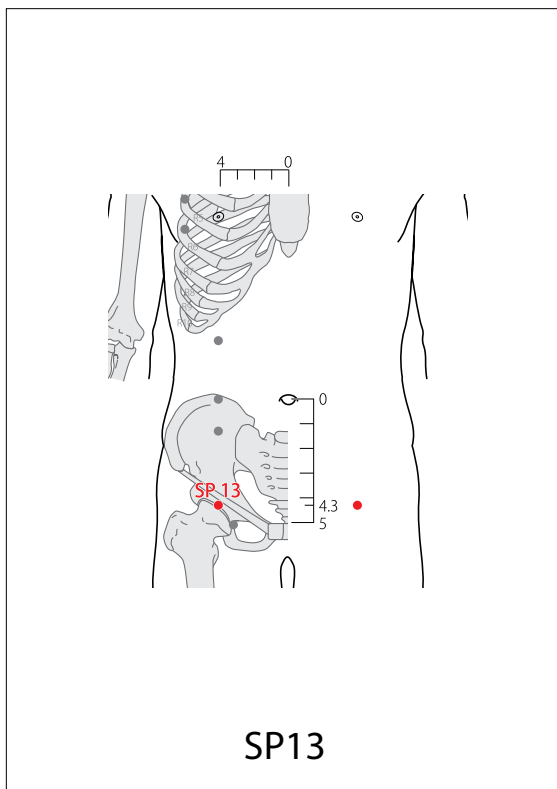
In the groin region, at the inguinal crease, lateral to the femoral artery.

Note: At the same level as CV2, medial and inferior to SP13.



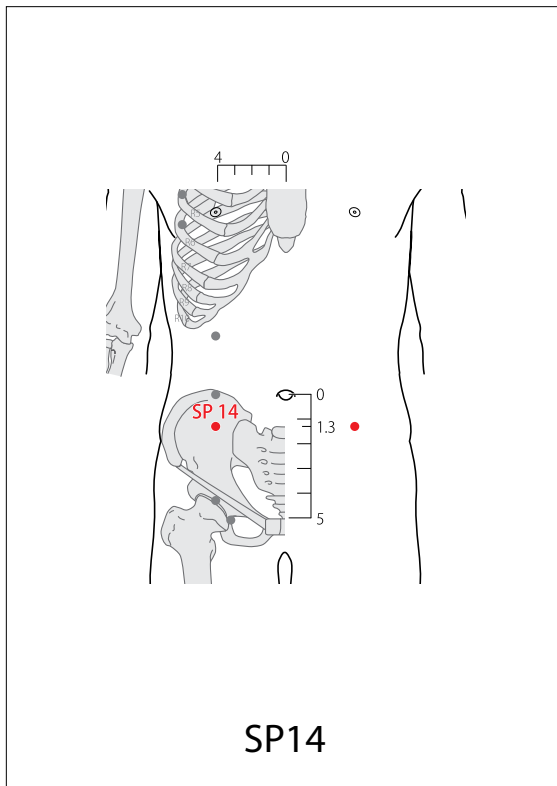
### SP13: Fushe 府舍 (舍)

On the lower abdomen, 4.3 B-cun inferior to the centre of the umbilicus, 4 B-cun lateral to the anterior median line.



### SP14: Fujie 腹結 (结)

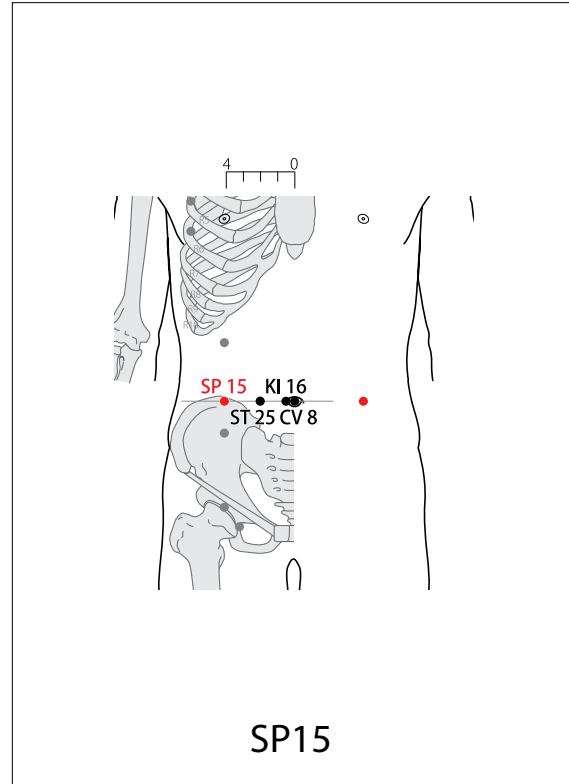
On the lower abdomen, 1.3 B-cun inferior to the centre of the umbilicus, 4 B-cun lateral to the anterior median line.



### SP15: Daheng 大横

On the upper abdomen, 4 B-cun lateral to the centre of the umbilicus.

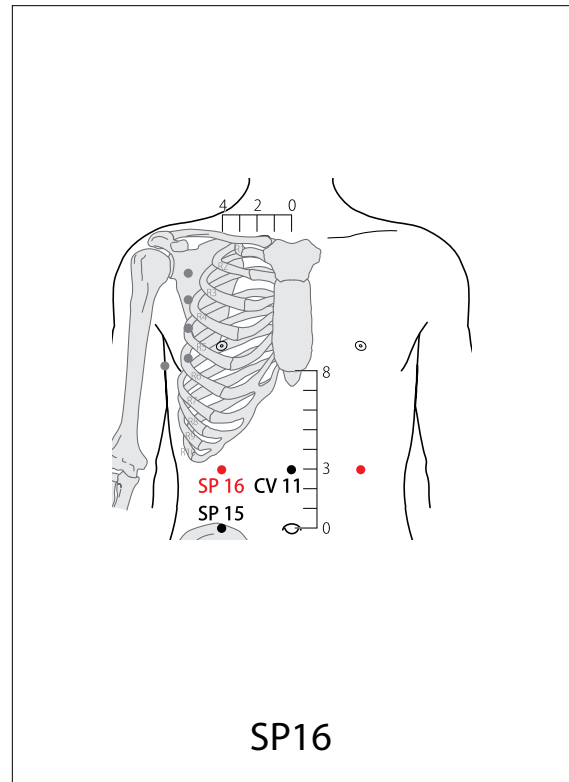
Note: At the same level and lateral to ST25, KI16 and CV8.



### SP16: Fuai 腹哀

On the upper abdomen, 3 B-cun superior to the centre of the umbilicus, 4 B-cun lateral to the anterior median line.

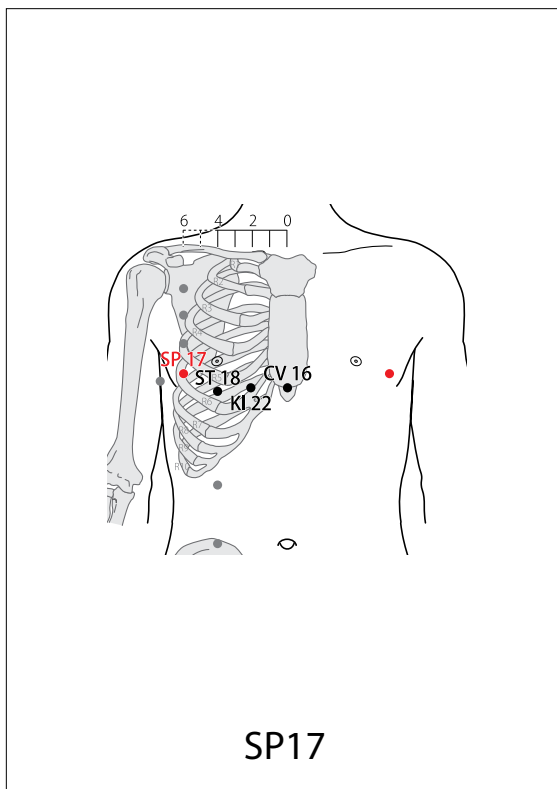
Note: 3 B-cun superior to SP15, at the same level as CV11.



### SP17: Shidou 食竈 (窠)

In the anterior thoracic region, in the fifth intercostal space, 6 B-cun lateral to the anterior median line.

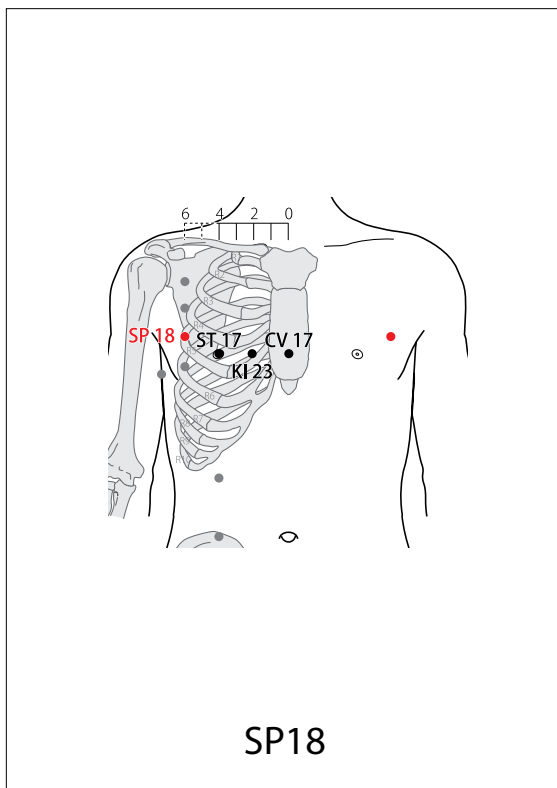
Note: SP17, ST18 and KI22 are located along the curve of the fifth intercostal space.



### SP18: Tianxi 天谿 (溪)

In the anterior thoracic region, in the fourth intercostal space, 6 B-cun lateral to the anterior median line.

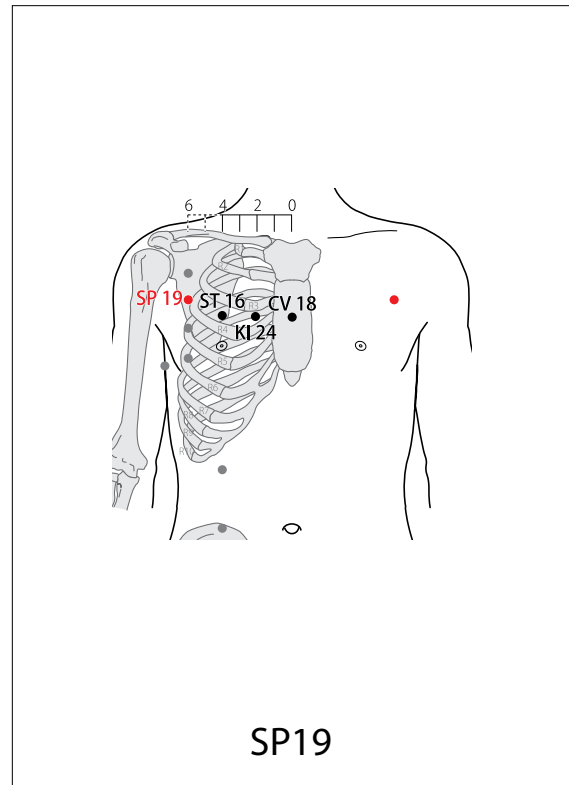
Note: SP18, ST17 and KI23 are located along the curve of the fourth intercostal space.



### SP19: Xiongxiang 胸鄉(乡, 郷)

In the anterior thoracic region, in the third intercostal space, 6 B-cun lateral to the anterior median line.

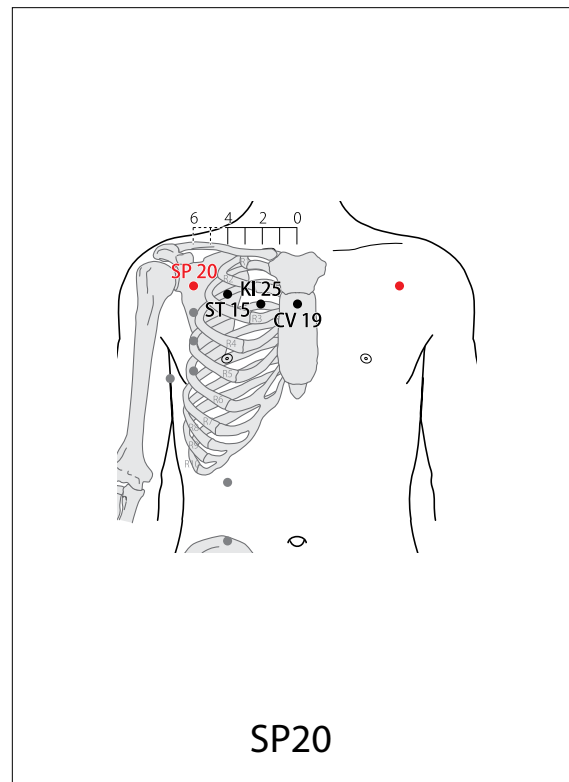
Note: SP19, ST6 and KI24 are located along the curve of the third intercostal space.



### SP20: Zhouyong 周榮(荣, 榮)

In the anterior thoracic region, in the second intercostal space, 6 B-cun lateral to the anterior median line.

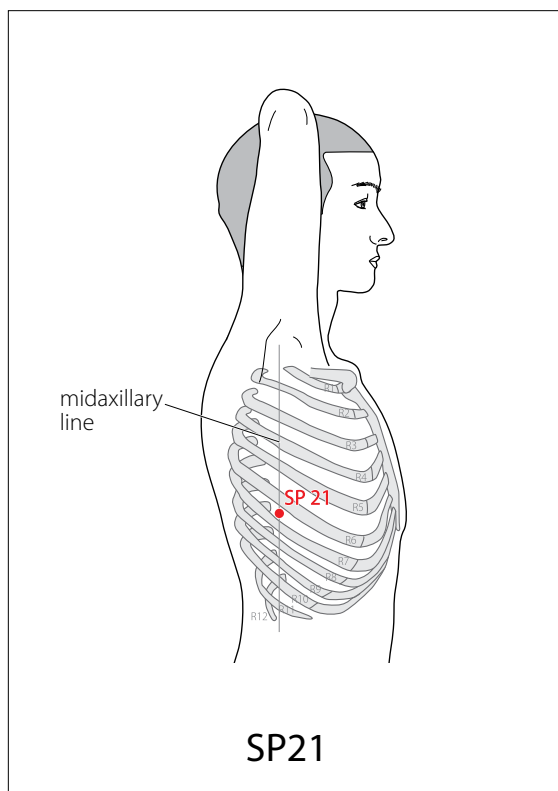
Note: SP20, ST15 and KI25 are located along the curve of the second intercostal space.



**SP21: Dabao 大包(包)**

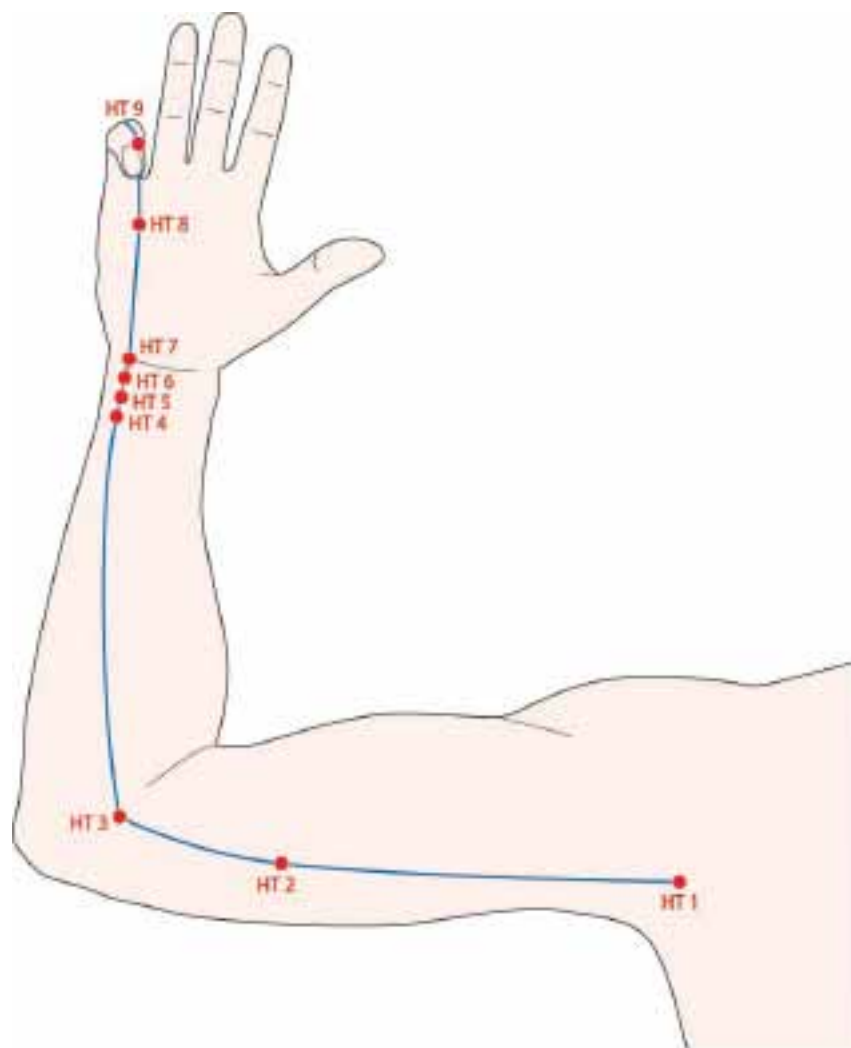
In the lateral thoracic region, in the sixth intercostal space, on the midaxillary line.

Note: With the subject lying on the side and the arm abducted, SP21 is located at the intersection of the midaxillary line and the sixth intercostal space.



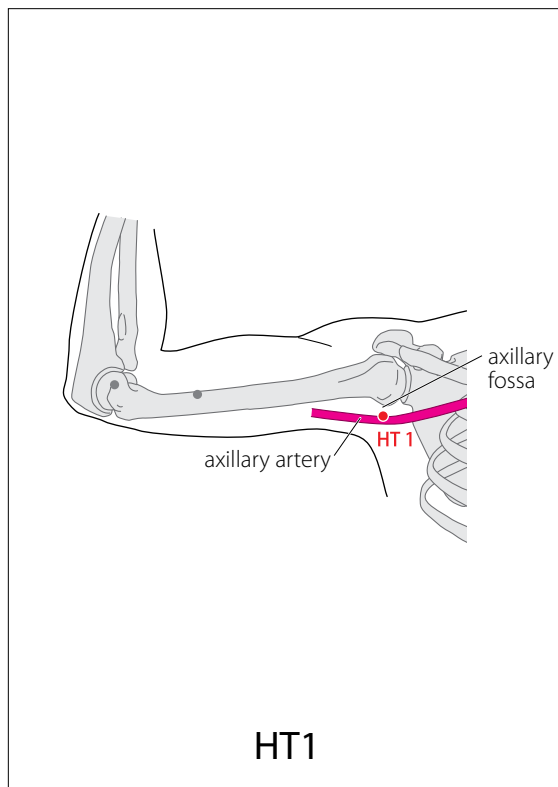
# HEART MERIDIAN

手少陰(陰)心經(经, 經)



## HT1: Jiquan 極(极) 泉

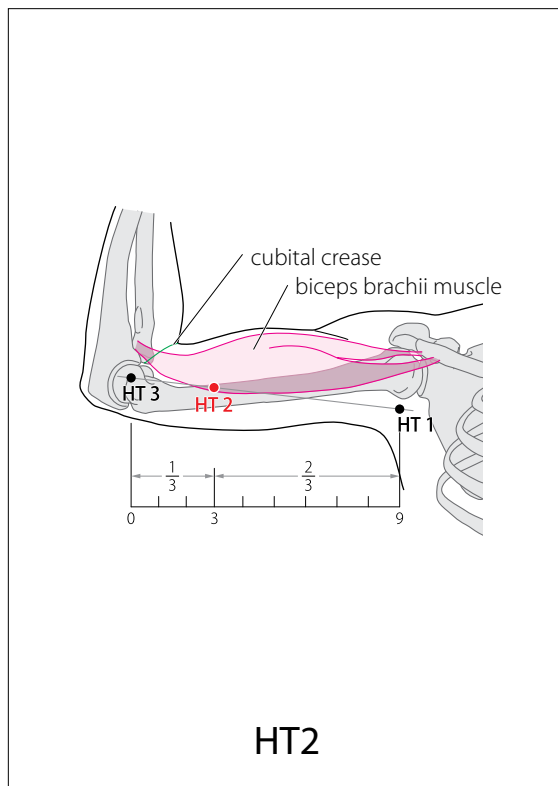
In the axilla, in the centre of the axillary fossa, over the axillary artery.



## HT2: Qingling 青(青) 靈(灵, 靈)

On the medial aspect of the arm, just medial to the biceps brachii muscle, 3 B-cun superior to the cubital crease.

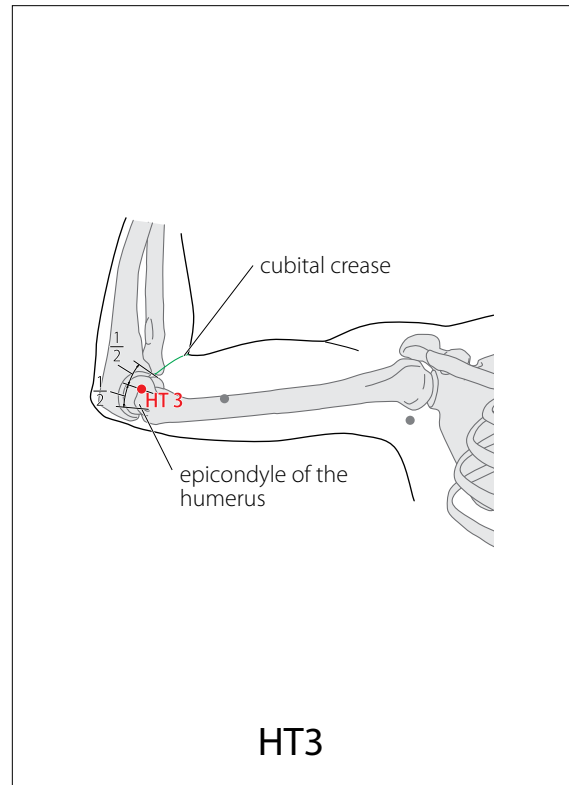
Note: With the elbow flexed and the arm abducted, HT2 is located at the junction of the upper two thirds and lower one third of the line connecting HT1 with HT3.



### HT3: Shaohai 少海 (海)

On the anteromedial aspect of the elbow, just anterior to the medial epicondyle of the humerus, at the same level as the cubital crease.

Note: With the elbow is flexed, HT3 is located at the midpoint of the line connecting the medial end of the cubital crease and the medial epicondyle of the humerus.

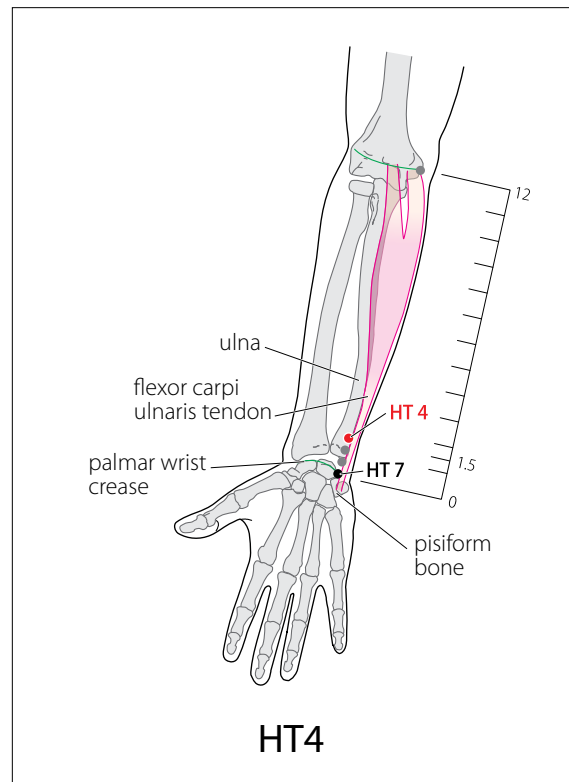


### HT4: Lingdao 靈 (灵, 靈) 道 (道)

On the anteromedial aspect of the forearm, just radial to the flexor carpi ulnaris tendon, 1.5 B-cun proximal to the palmar wrist crease.

Note 1: 1.5 B-cun proximal to HT7, at the same level as the superior border of the head of the ulna.

Note 2: 1.5 B-cun proximal to the radial side of the superior border of the pisiform bone.

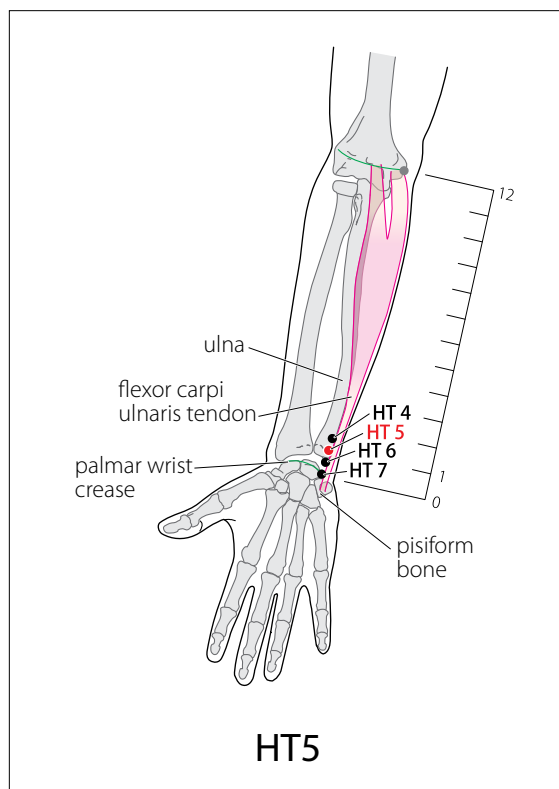


### HT5: Tongli 通(通)里

On the anteromedial aspect of the forearm, radial to the flexor carpi ulnaris tendon, 1 B-cun proximal to the palmar wrist crease.

Note 1: 1 B-cun proximal to HT7. HT 4 is located at the level with the root of the head of the ulna, HT 5, the body of the head of the ulna and HT 6, the base of the head of the ulna.

Note 2: 1 B-cun proximal to the radial side of the proximal border of the pisiform bone.

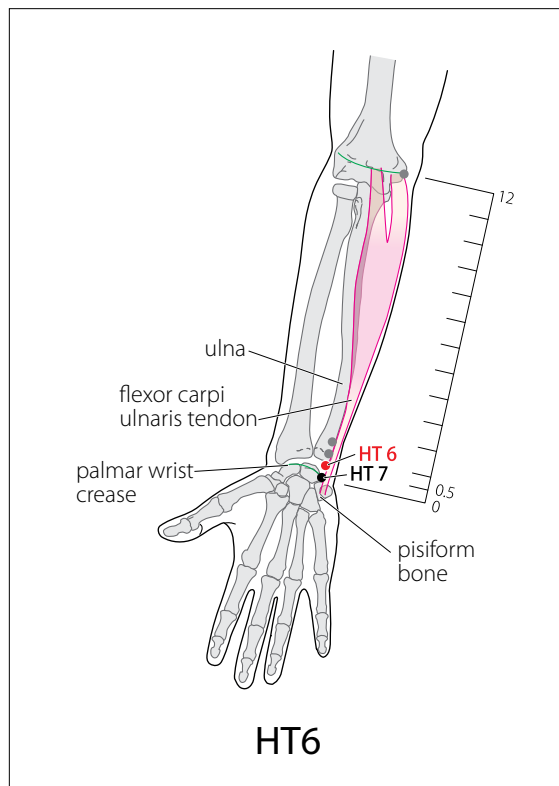


### HT6: Yinxi 陰(陰)郤

On the anteromedial aspect of the forearm, radial to the flexor carpi ulnaris tendon, 0.5 B-cun proximal to the palmar wrist crease.

Note 1: 0.5 B-cun proximal to HT7, at the same level as the distal border of the head of the ulna.

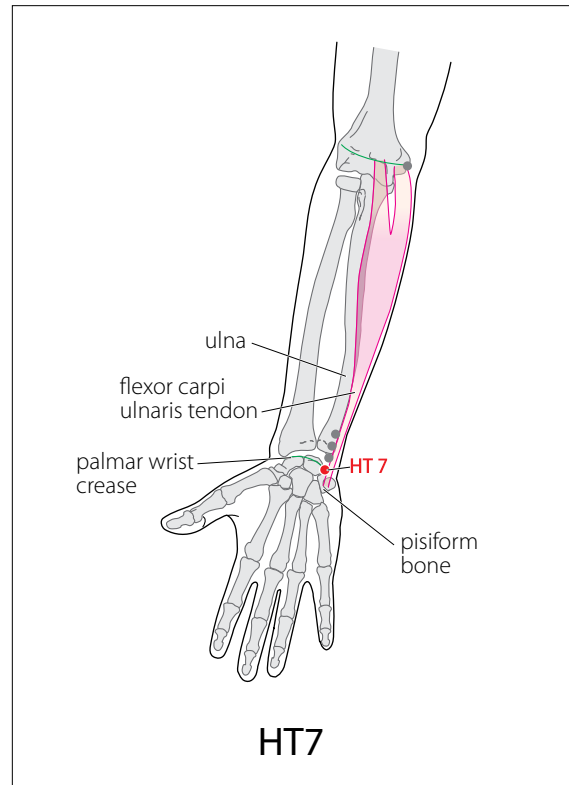
Note 2: 0.5 B-cun proximal to the radial side of the proximal border of the pisiform bone.



### HT7: Shenmen 神(神)門(門)

On the anteromedial aspect of the wrist, radial to the flexor carpi ulnaris tendon, on the palmar wrist crease.

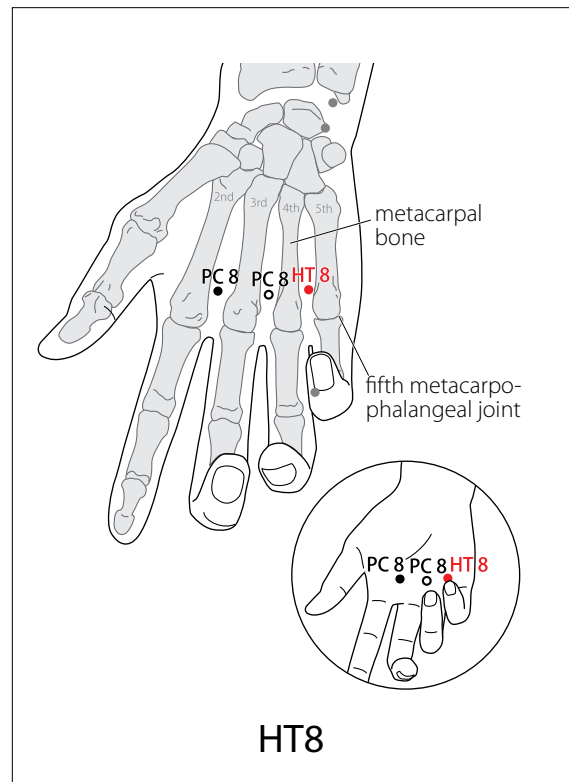
Note: In the depression radial to the proximal border of the pisiform bone, on the palmar wrist crease.



### HT8: Shaofu 少府

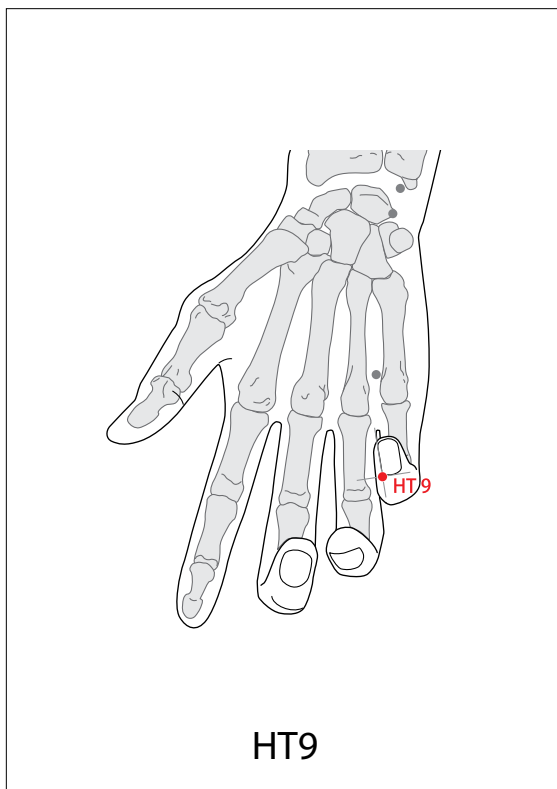
On the palm of the hand, in the depression between the fourth and fifth metacarpal bones, proximal to the fifth metacarpophalangeal joint.

Note: Between the fourth and fifth metacarpal bones, where the tip of the little finger rests when a fist is made, at the same level as PC8.



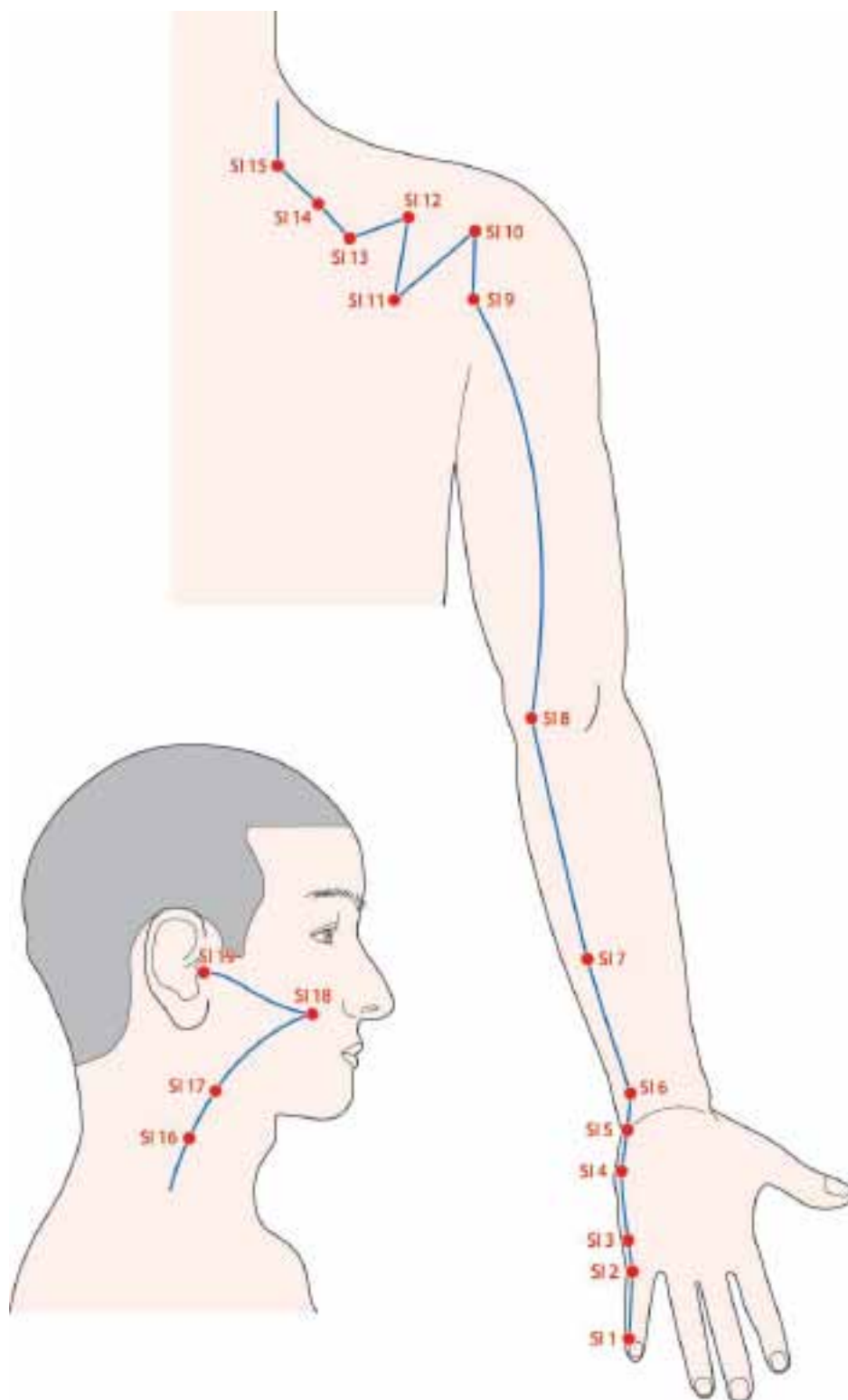
**HT9: Shaochong 少衝 (冲)**

On the little finger, radial to the distal phalanx, 0.1 F-cun proximal-lateral to the radial corner of the little fingernail, at the intersection of the vertical line of the radial border of the nail and horizontal line of the base of the little fingernail.



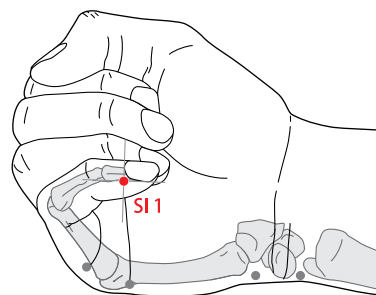
## SMALL INTESTINE MERIDIAN

手太陽(阳)小腸(肠)經(经, 經)



### SI1: Shaoze 少澤 (澤, 沢)

On the little finger, ulnar to the distal phalanx, 0.1 F-cun proximal-medial to the ulnar corner of the little fingernail, at the intersection of the vertical line of ulnar border of the nail and horizontal line of the base of the little fingernail.

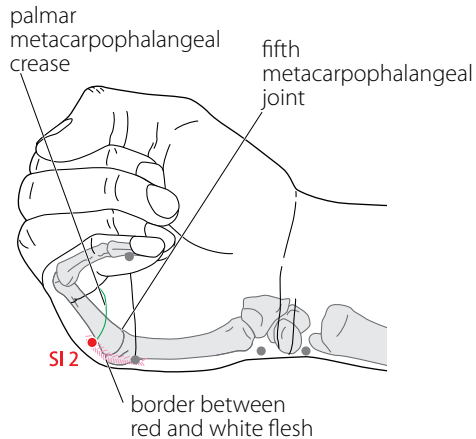


SI1

### SI2: Qianggu 前谷

On the little finger, in the depression distal to the ulnar side of the fifth metacarpophalangeal joint, at the border between the red and white flesh.

Note: When the hand is slightly flexed, the point is located at the ulnar end of the palmar metacarpophalangeal crease of the little finger.

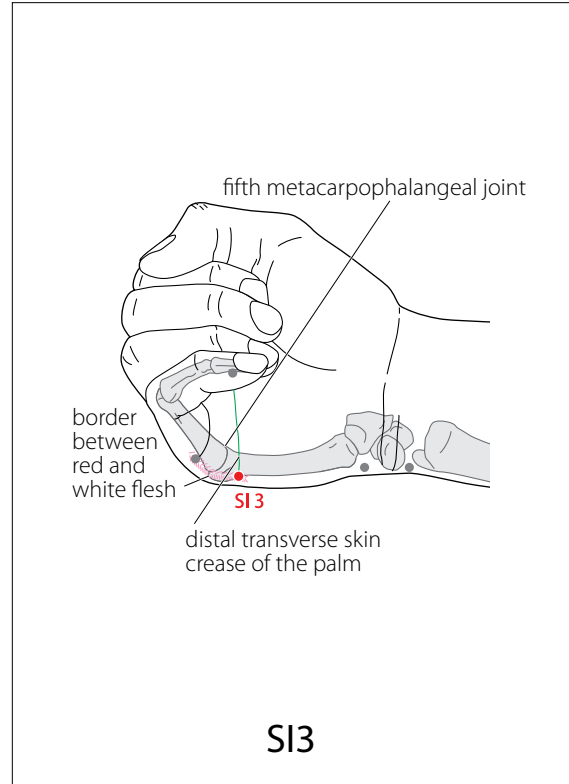


SI2

### SI3: Houxi 後(后)谿(溪)

On the dorsum of the hand, in the depression proximal to the ulnar side of the fifth metacarpophalangeal joint, at the border between the red and white flesh.

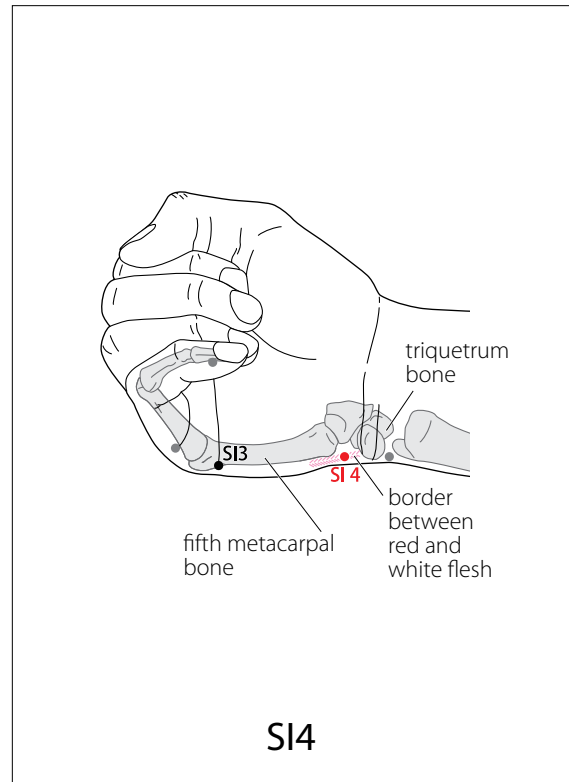
Note: When the hand is slightly flexed, the point is located at the ulnar end of the distal transverse skin crease of the palm, at the border between the red and white flesh.



### SI4: Wangu 腕骨(骨)

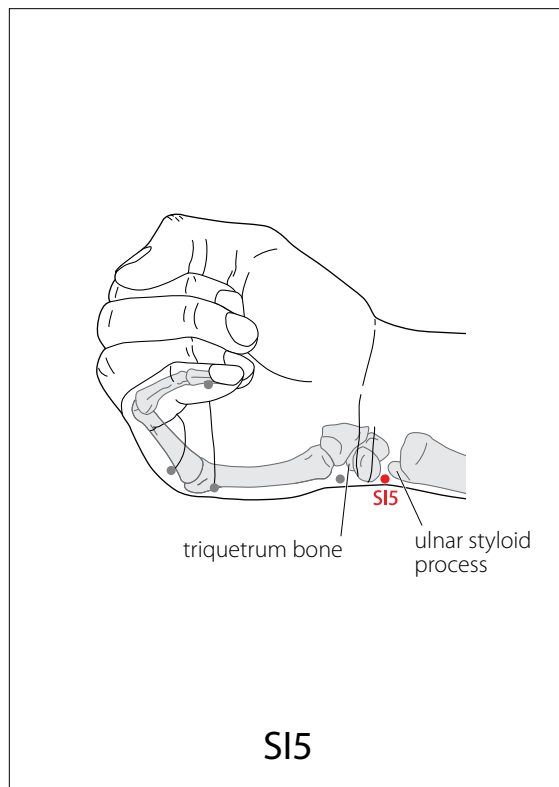
On the posteromedial aspect of the wrist, in the depression between the base of the fifth metacarpal bone and the triquetrum bone, at the border between the red and white flesh.

Note: With one finger placed on SI3, push and slide proximally along the fifth metacarpal bone to the bony projection, SI4 is located in the depression between these two bones.



### SI5: Yanggu 陽(阳)谷

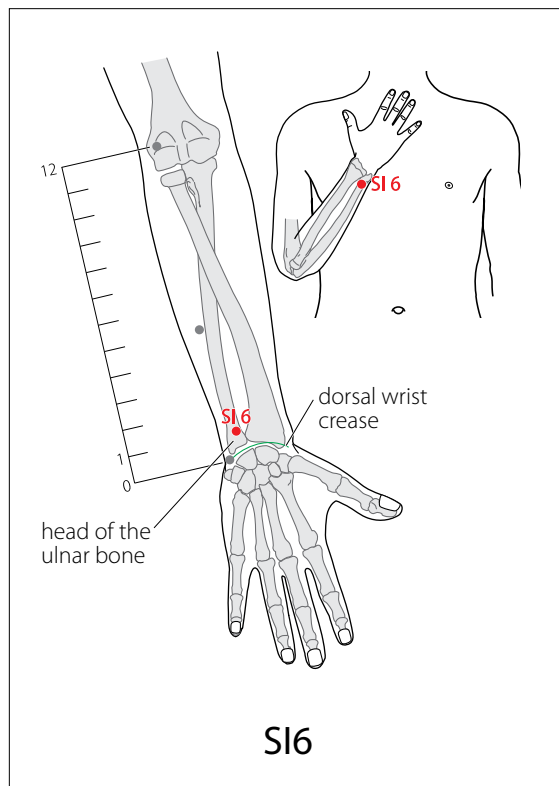
On the posteromedial aspect of the wrist, in the depression between the triquetrum bone and the ulnar styloid process.



### SI6: Yanglao 養(养)老

On the posteromedial aspect of the forearm, in the depression radial to the head of the ulnar bone, 1 B-cun proximal to the dorsal wrist crease.

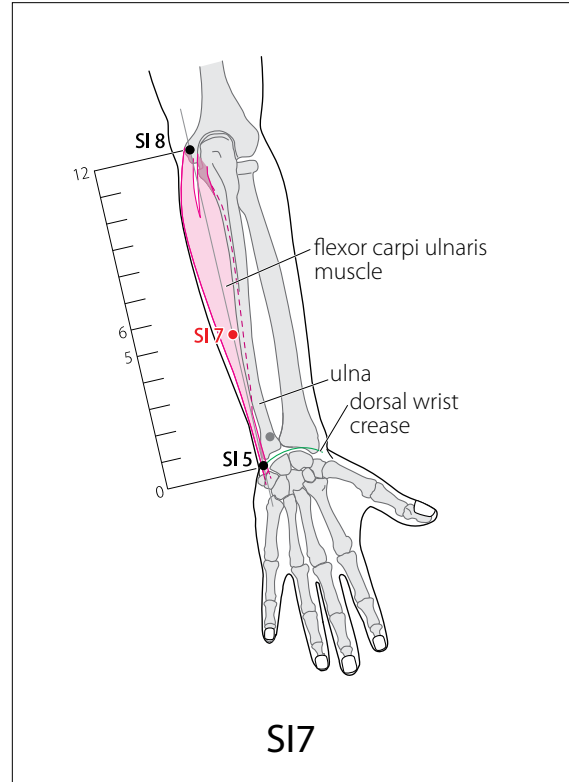
Note: With the palm facing downwards, press the highest point of the head of ulnar bone with a finger, and then turn the palm towards the chest; SI6 is located at the cleft between the bones where the finger slides.



### SI7: Zhizheng 支正

On the posteromedial aspect of the forearm, between the medial border of the ulnar bone and the flexor carpi ulnaris muscle, 5 B-cun proximal to the dorsal wrist crease.

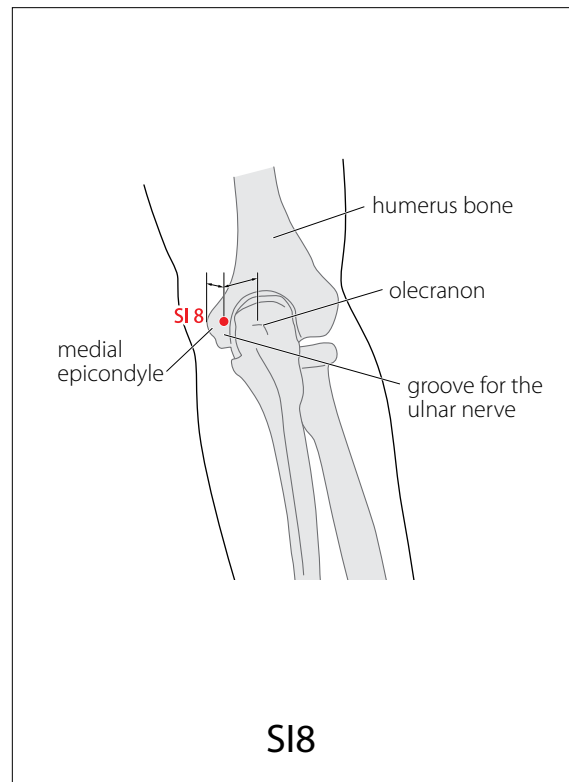
Note: 1 B-cun distal to the midpoint of the line connecting SI5 with SI8.



### SI8: Xiaohai 小海 (海)

On the posteromedial aspect of the elbow, in the depression between the olecranon and the medial epicondyle of the humerus bone.

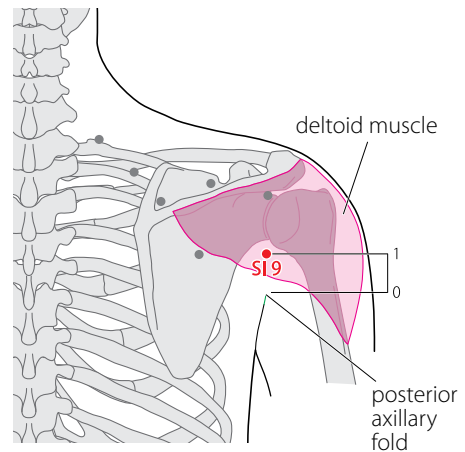
Note: When the elbow is slightly flexed, SI 8 is located in the groove for the ulnar nerve.



### SI9: Jianzhen 肩貞 (貞)

On the shoulder girdle, posteroinferior to the shoulder joint, 1 B-cun superior to the posterior axillary fold.

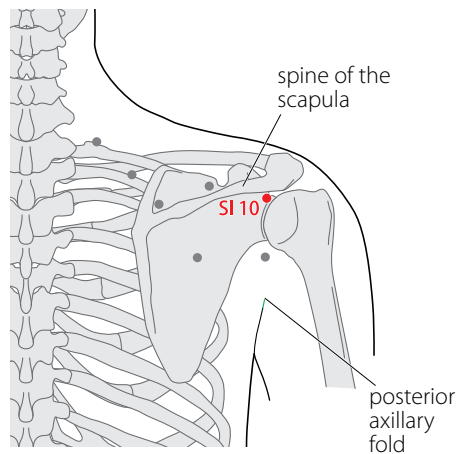
Note: When the arm is adducted, SI 9 is located 1 B-cun superior to the posterior axillary fold, posterior to the deltoid muscle.



SI9

### SI10: Naoshu 臑俞 (俞)

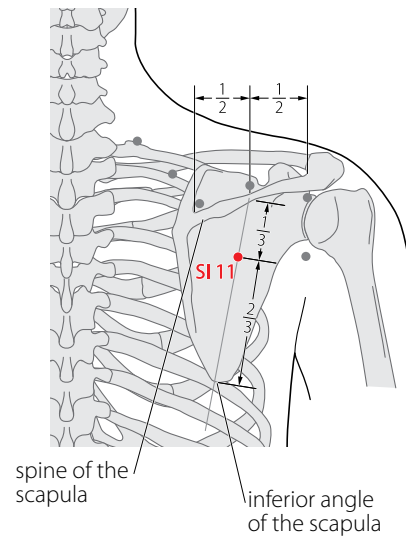
On the shoulder girdle, superior to the posterior axillary fold, in the depression inferior to the spine of the scapula.



SI10

### SI11: Tianzong 天宗

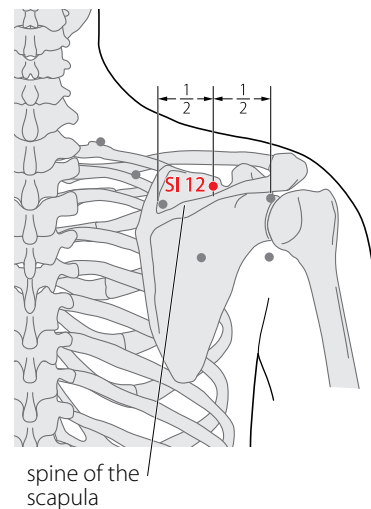
In the scapular region, in the depression between the upper one third and lower two thirds of the line connecting the midpoint of the spine of the scapula with the inferior angle of the scapula.



SI11

### SI12: Bingfeng 秉風 (风)

In the scapular region, in the supraspinatus fossa, superior to the midpoint of the spine of the scapula.

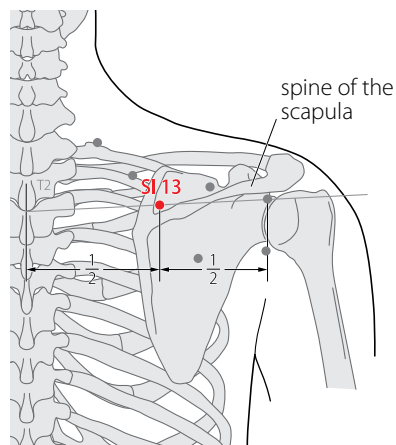


SI12

### SI13: Quyuan 曲垣

In the scapular region, in the depression superior to the medial end of the spine of the scapula.

Note: SI13 is located at the midpoint of the line connecting SI10 with the spinous process of the second thoracic vertebra (T2).



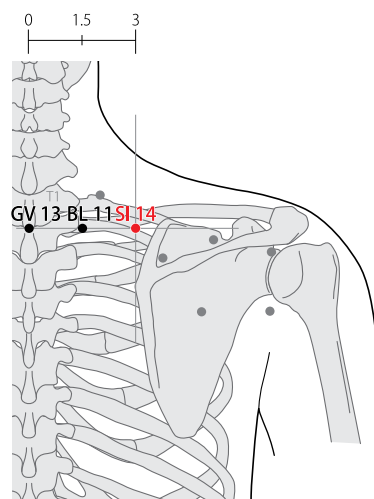
SI13

### SI14: Jianwaishu 肩外俞 (俞)

In the upper back region, at the same level as the inferior border of the spinous process of the first thoracic vertebra (T1), 3 B-cun lateral to the posterior median line.

Note 1: SI14 is located at the intersection of two imaginary lines: the vertical line of the medial extremity of the spine of the scapula and the horizontal line inferior to the spinous process of the first thoracic vertebra (T1).

Note 2: SI14 is located at the same level as BL11, GV13, and the inferior border of the spinous process of the first thoracic vertebra (T1).

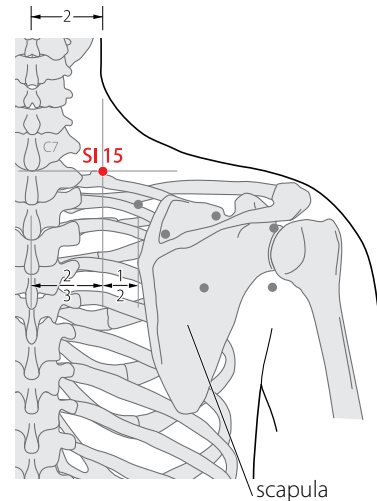


SI14

### SI15: Jianzhongshu 肩中俞 (俞)

In the upper back region, at the same level as the inferior border of the spinous process of the seventh cervical vertebra (C7), 2 B-cun lateral to the posterior median line.

Note: SI15 is located at the intersection of two imaginary lines: the vertical line of the junction of the lateral one third and the medial two thirds of the line connecting the posterior median line with the medial border of the scapula and the horizontal line inferior to the spinous process of the seventh cervical vertebra (C7).



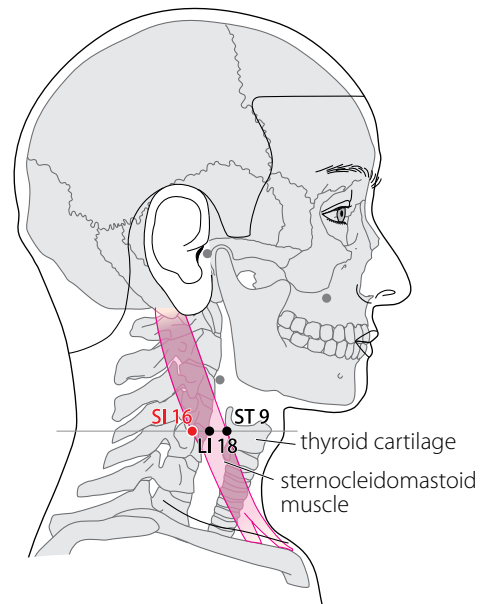
SI15

### SI16: Tianchuang 天窗 (窓)

In the anterior region of the neck, posterior to the sternocleidomastoid muscle, at the same level as the superior border of the thyroid cartilage.

Note 1: The sternocleidomastoid muscle is more distinct when the head is turned to the opposite side against resistance.

Note 2: SI16 is located at the same level as ST9, LI18 and the superior border of the thyroid cartilage. ST9 is located anterior to the sternocleidomastoid muscle, SI16, posterior to the sternocleidomastoid muscle and LI18, midway between the anterior and posterior borders of the sternocleidomastoid muscle.

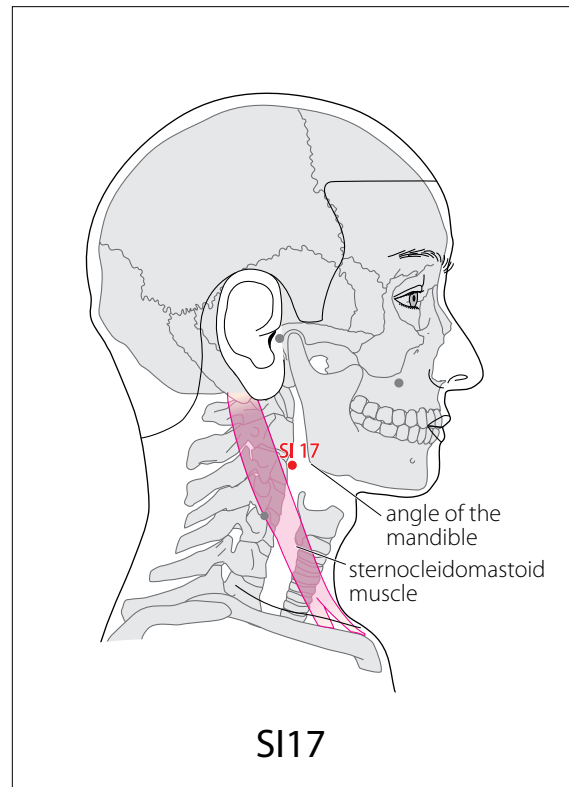


SI16

### SI17: Tianrong 天容

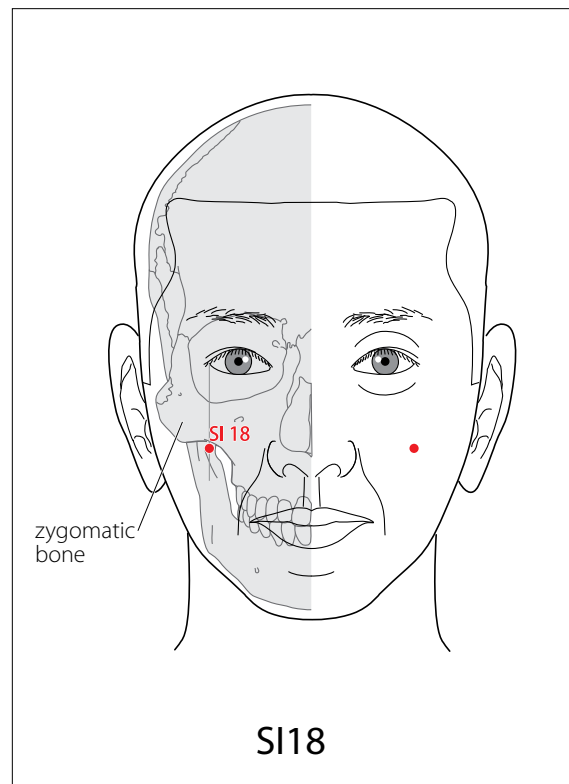
In the anterior region of the neck, posterior to the angle of the mandible, in the depression anterior to the sternocleidomastoid muscle.

Note: The sternocleidomastoid muscle is more distinct when the head is turned to the opposite side against resistance.



### SI18: Quanliao 顴(顴)髎(髎)

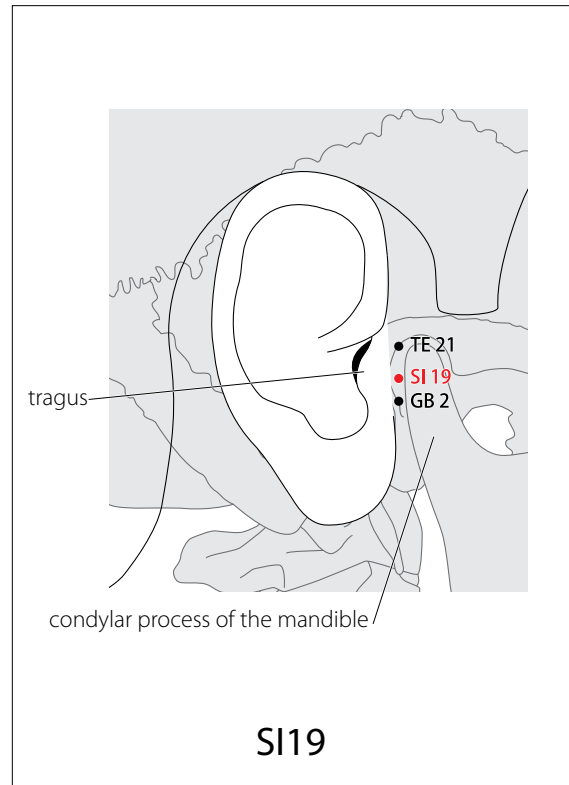
On the face, inferior to the zygomatic bone, in the depression directly inferior to the outer canthus of the eye.



**SI19: Tinggong 聽(听, 聽)宮(宫)**

On the face, in the depression between the anterior border of the centre of the tragus and the posterior border of the condylar process of the mandible.

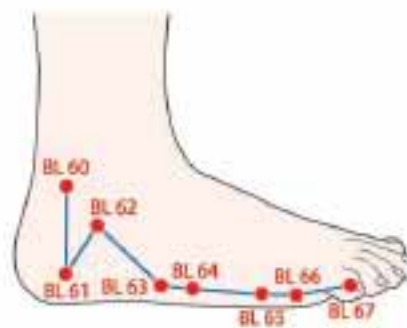
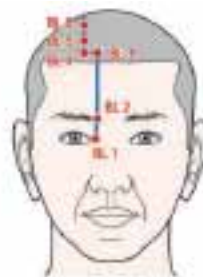
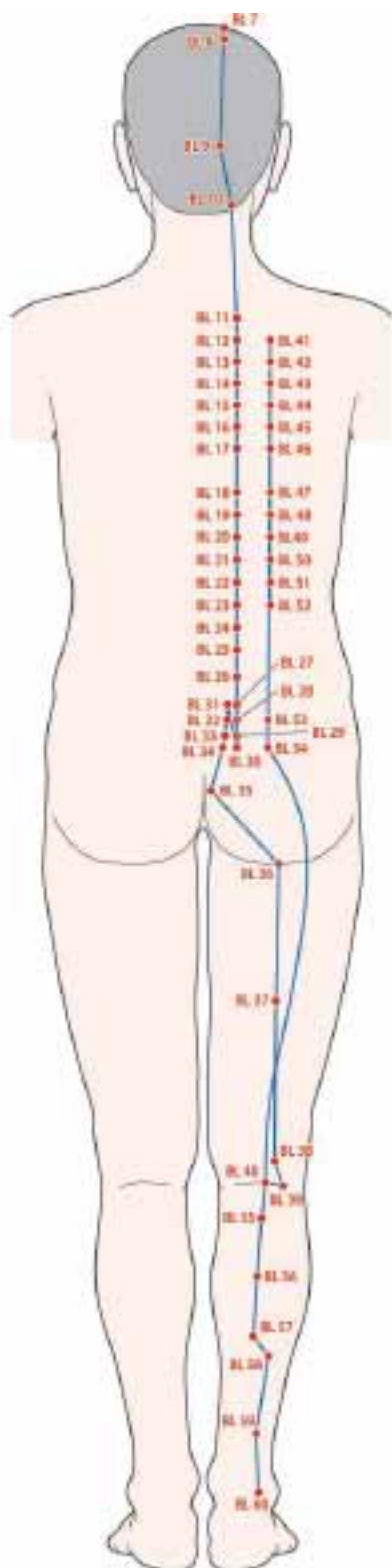
Note: When the mouth is slightly opened, SI19 is located in the depression anterior to the centre of the tragus, between TE21 and GB2.





# BLADDER MERIDIAN

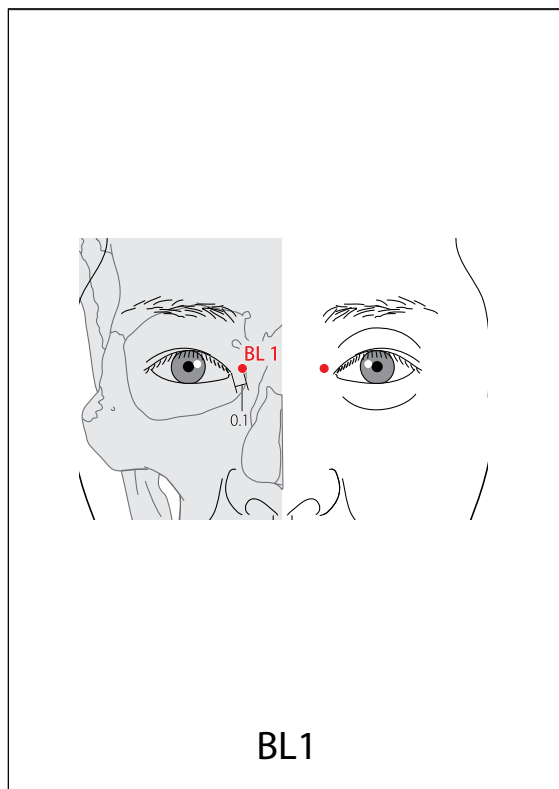
足太陽(阳)膀胱經(经, 經)



### BL1: Jingming 睛(睛)明

On the face, in the depression between the superomedial parts of the inner canthus of the eye and the medial wall of the orbit.

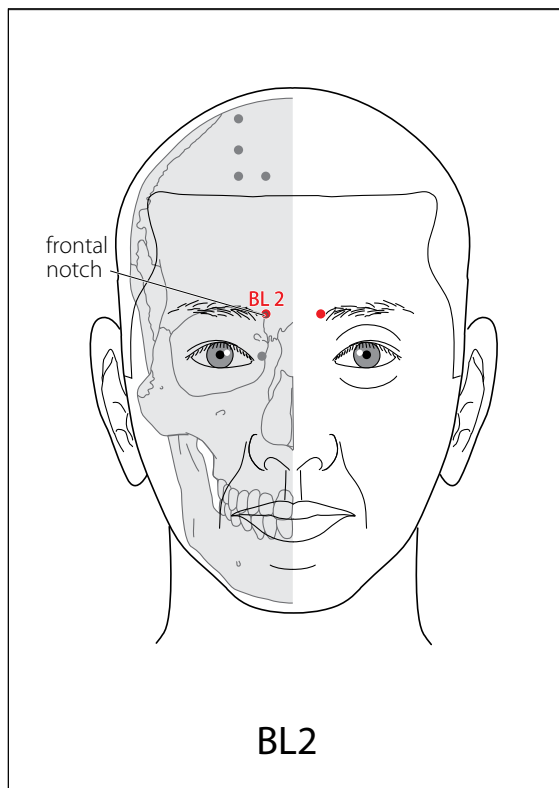
Note: When the eye is closed, BL1 is located in the depression 0.1 B-cun superior and medial to the inner canthus of the eye.



### BL2: Cuanzhu 攢(攢, 攢)竹

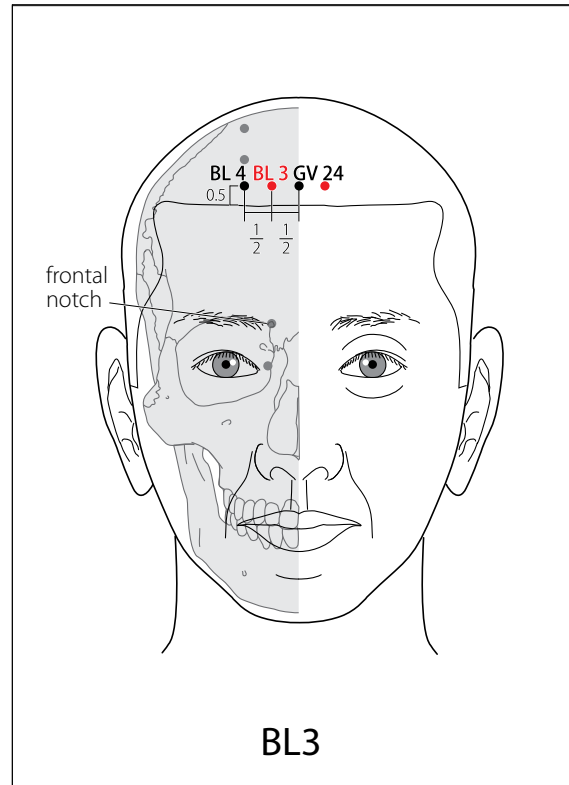
On the head, in the depression at the medial end of the eyebrow.

Note: A depression, the frontal notch, can often be palpated on the medial end of the eyebrow directly superior to BL1.



### BL3: Meichong 眉衝 (冲)

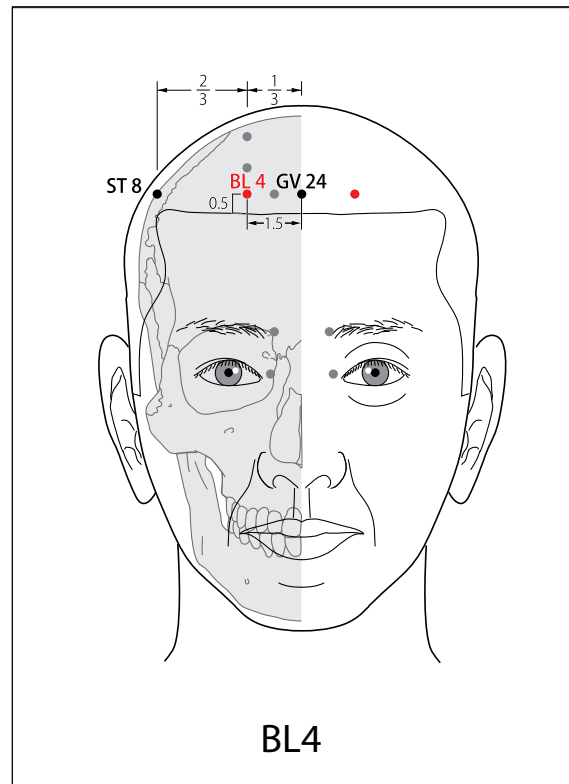
On the head, superior to the frontal notch, 0.5 B-cun superior to the anterior hairline.  
Note: Midway between GV24 and BL4.



### BL4: Qucha 曲差

On the head, 0.5 B-cun superior to the anterior hairline, 1.5 B-cun lateral to the anterior median line.

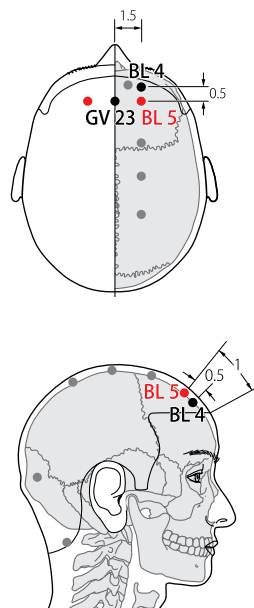
Note: At the junction of the medial one third and lateral two thirds of the line connecting GV24 with ST8.



### BL5: Wuchu 五處(处, 处)

On the head, 1 B-cun superior to the anterior hairline, 1.5 B-cun lateral to the anterior median line.

Note: 0.5 B-cun superior to BL4, at the same level as GV23.

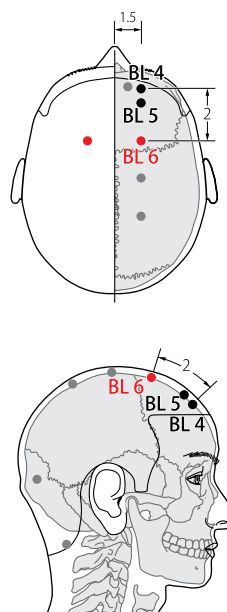


BL5

### BL6: Chengguang 承光

On the head, 2.5 B-cun superior to the anterior hairline, 1.5 B-cun lateral to the anterior median line.

Note: 1.5 B-cun superior to BL5. 2 B-cun superior to BL4

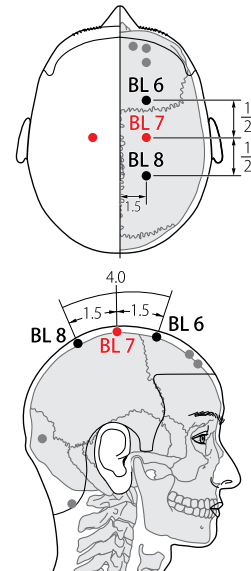


BL6

### BL7: Tongtian 通(通)天

On the head, 4 B-cun superior to the anterior hairline, 1.5 B-cun lateral to the anterior median line.

Note: Midway between BL6 and BL8.

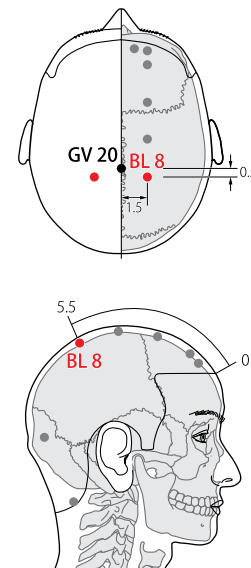


BL7

### BL8: Luoque 絡(络)卻(却)

On the head, 5.5 B-cun superior to the anterior hairline, 1.5 B-cun lateral to the anterior median line.

Note: 0.5 B-cun posterior and 1.5 B-cun lateral to GV20.

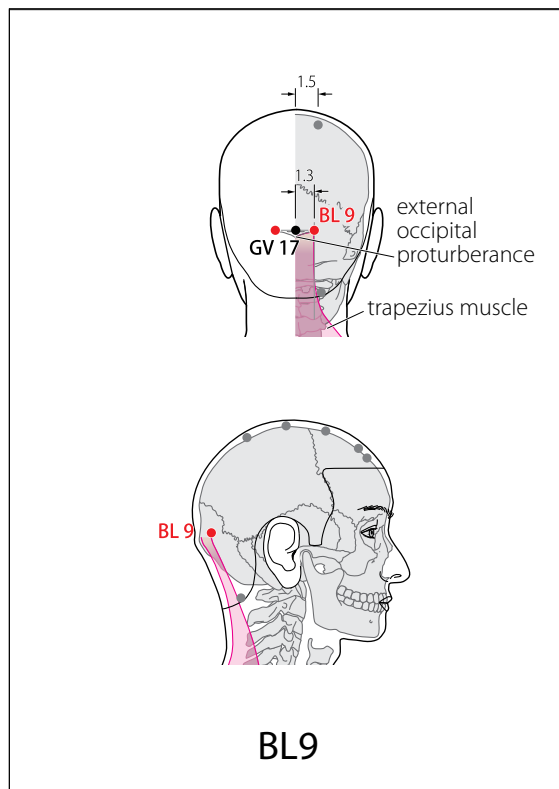


BL8

### BL9: Yuzhen 玉枕

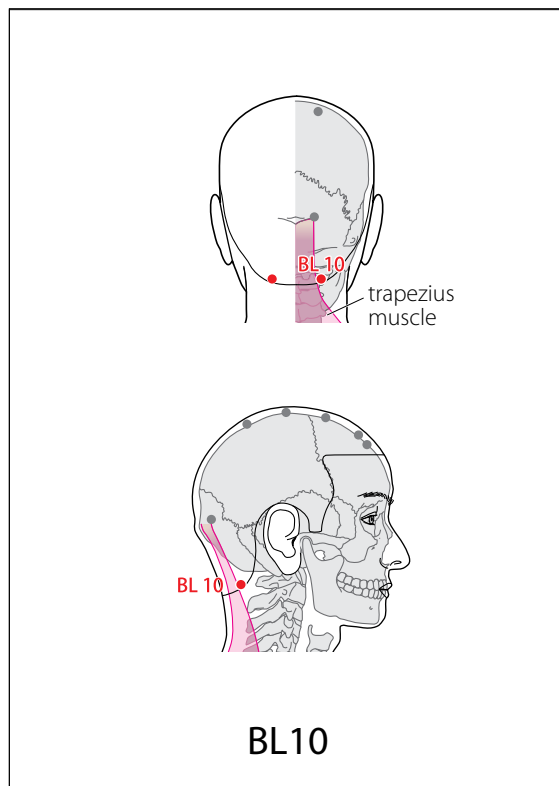
On the head, at the same level as the superior border of the external occipital protuberance, and 1.3 B-cun lateral to the posterior median line.

Note: BL9 is located at the intersection of two imaginary lines: the vertical line of the lateral border of the trapezius muscle and the horizontal line of the superior border of the external occipital protuberance. At the same level as GV17.



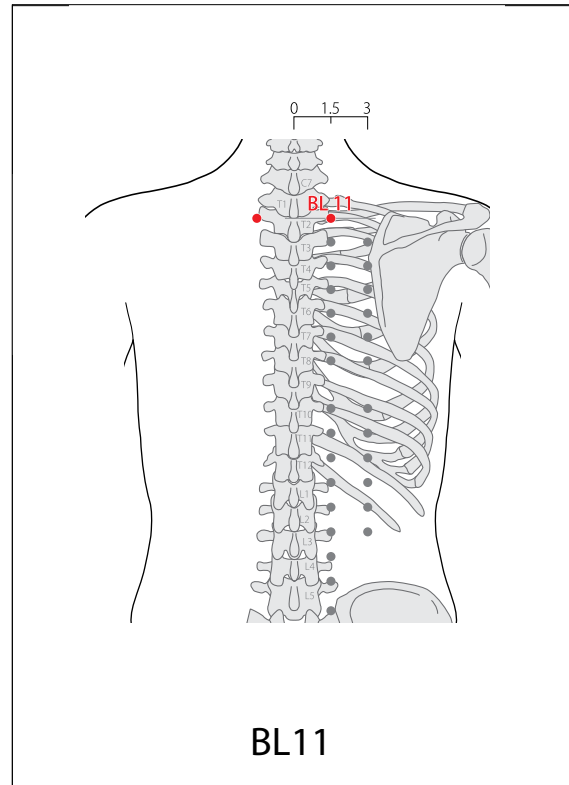
### BL10: Tianzhu 天柱

In the posterior region of the neck, at the same level as the superior border of the spinous process of the second cervical vertebra (C2), in the depression lateral to the trapezius muscle.



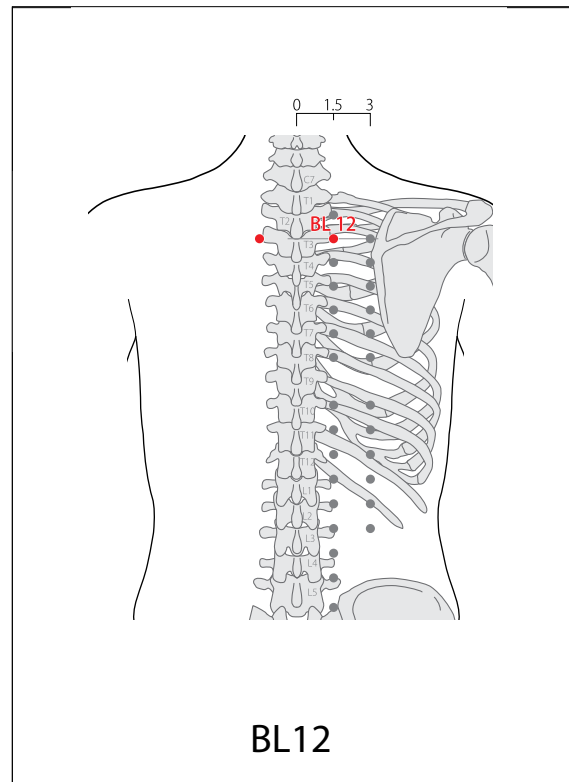
### BL11: Dazhu 大杼

In the upper back region, at the same level as the inferior border of the spinous process of the first thoracic vertebra (T1), 1.5 B-cun lateral to the posterior median line.



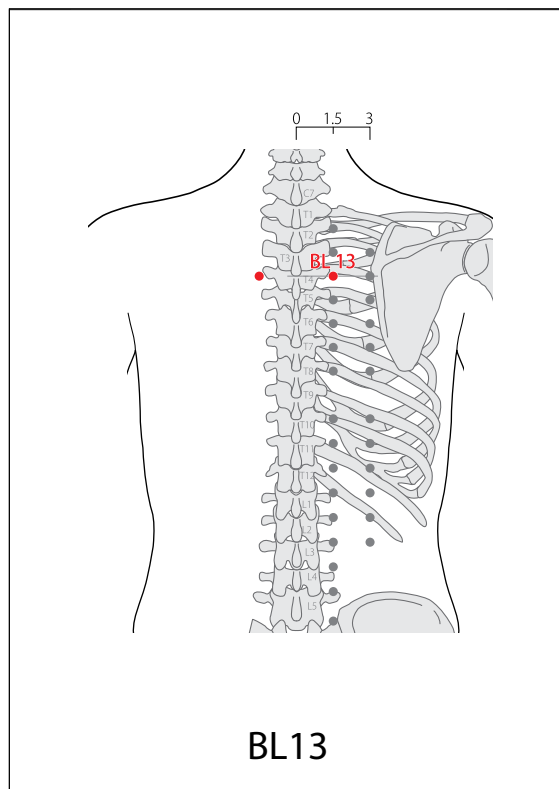
### BL12: Fengmen 風(风)門(门)

In the upper back region, at the same level as the inferior border of the spinous process of the second thoracic vertebra (T2), 1.5 B-cun lateral to the posterior median line.



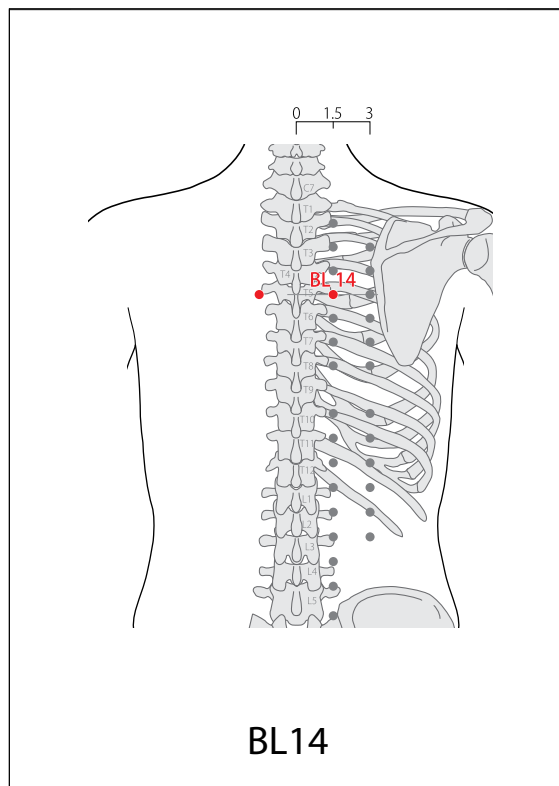
### BL13: Feishu 肺俞 (俞)

In the upper back region, at the same level as the inferior border of the spinous process of the third thoracic vertebra (T3), 1.5 B-cun lateral to the posterior median line.



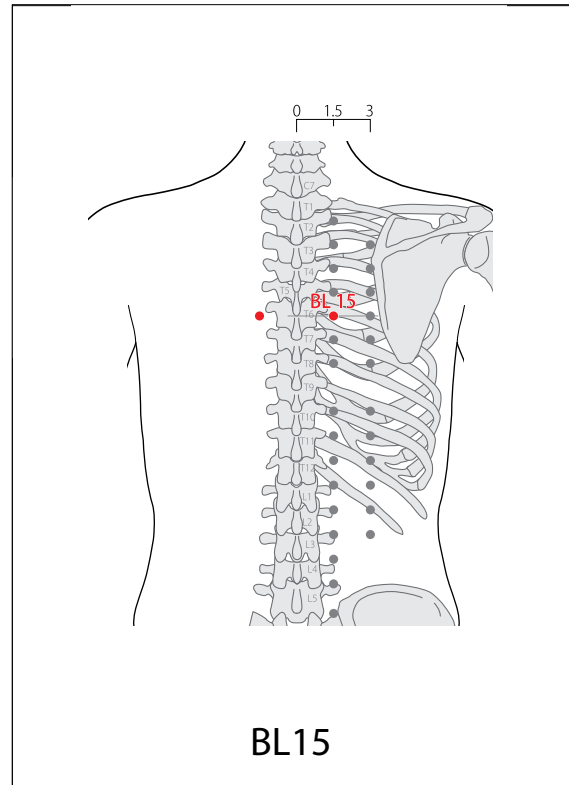
### BL14: Jueyinshu 厥陰 (阴) 俞 (俞)

In the upper back region, at the same level as the inferior border of the spinous process of the fourth thoracic vertebra (T4), 1.5 B-cun lateral to the posterior median line.

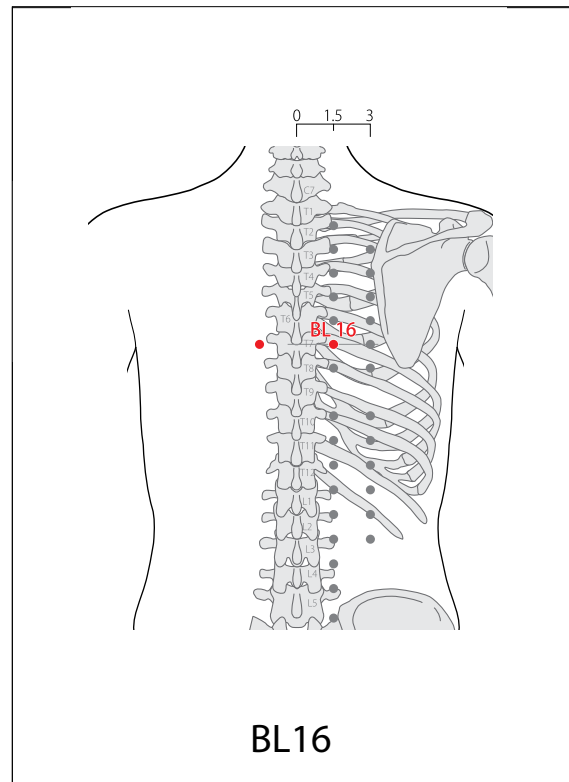


**BL15: Xinshu 心俞(俞)**

In the upper back region, at the same level as the inferior border of the spinous process of the fifth thoracic vertebra (T5), 1.5 B-cun lateral to the posterior median line.

**BL16: Dushu 督俞(俞)**

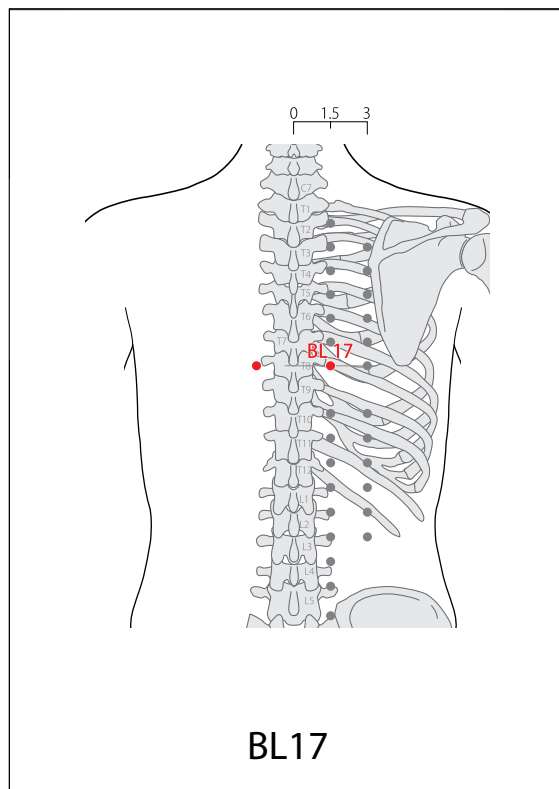
In the upper back region, level with the inferior border of the spinous process of the sixth thoracic vertebra (T6), 1.5 B-cun lateral to the posterior median line.



### BL17: Geshu 膈俞(俞)

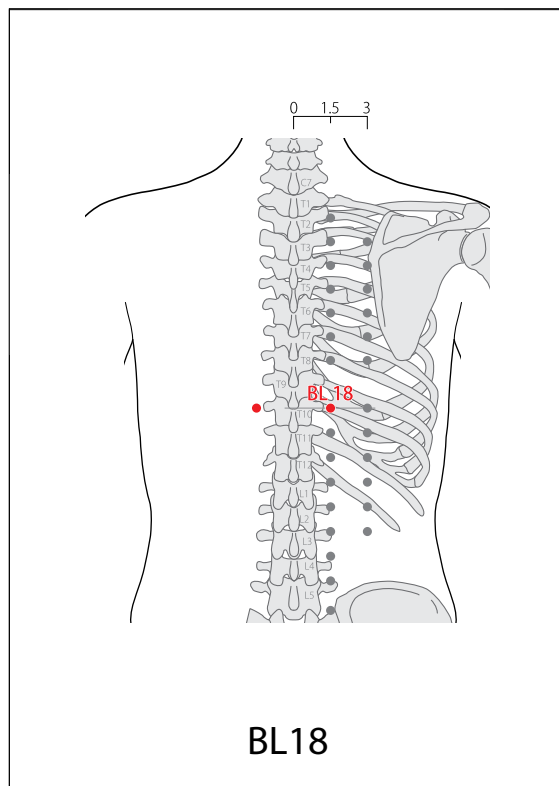
In the upper back region, at the same level as the inferior border of the spinous process of the seventh thoracic vertebra (T7), 1.5 B-cun lateral to the posterior median line.

Note: The inferior angle of the scapula is at the same level as the spinous process of the seventh thoracic vertebra.



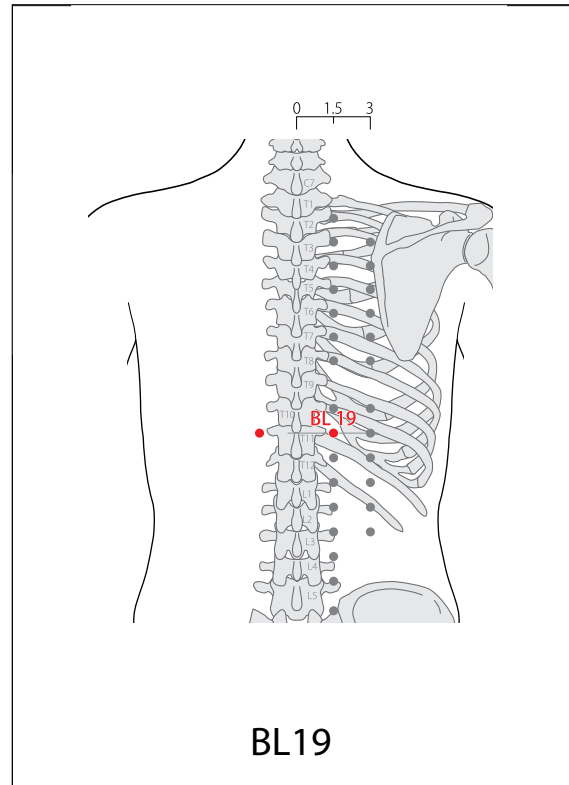
### BL18: Ganshu 肝俞(俞)

In the upper back region, at the same level as the inferior border of the spinous process of the ninth thoracic vertebra (T9), 1.5 B-cun lateral to the posterior median line.

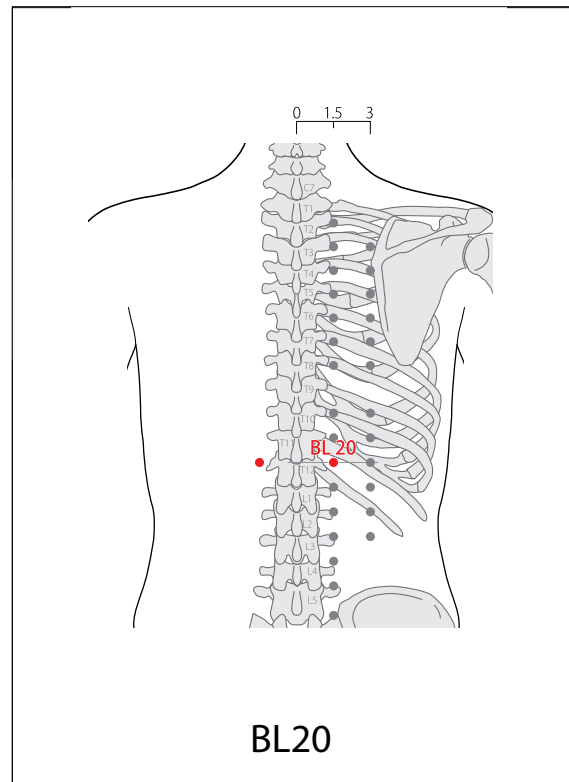


**BL19: Danshu 膽俞(俞)**

In the upper back region, at the same level as the inferior border of the spinous process of the tenth thoracic vertebra (T10), 1.5 B-cun lateral to the posterior median line.

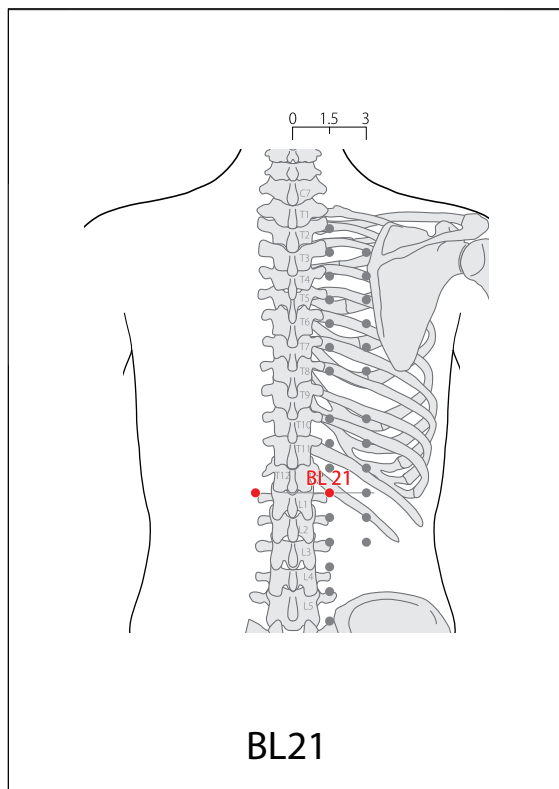
**BL20: Pishu 脾俞(俞)**

In the upper back region, at the same level as the inferior border of the spinous process of the 11th thoracic vertebra (T11), 1.5 B-cun lateral to the posterior median line.



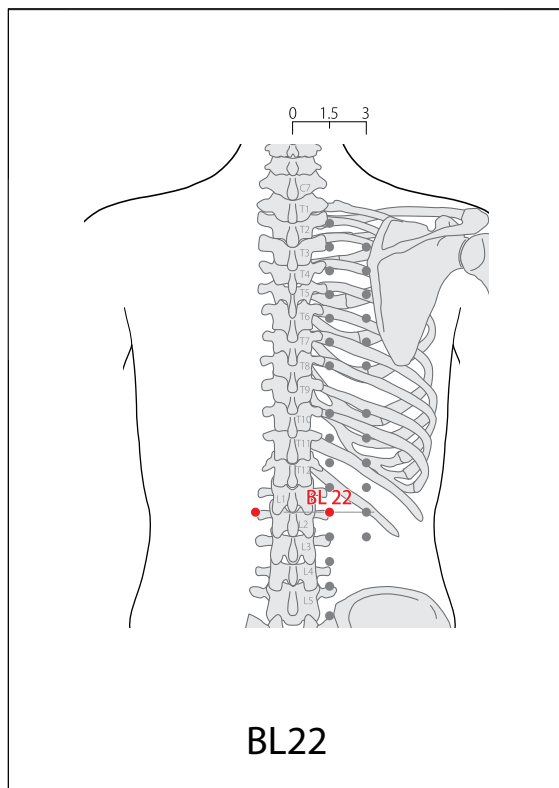
### BL21: Weishu 胃俞(俞)

In the upper back region, at the same level as the inferior border of the spinous process of the 12th thoracic vertebra (T12), 1.5 B-cun lateral to the posterior median line.



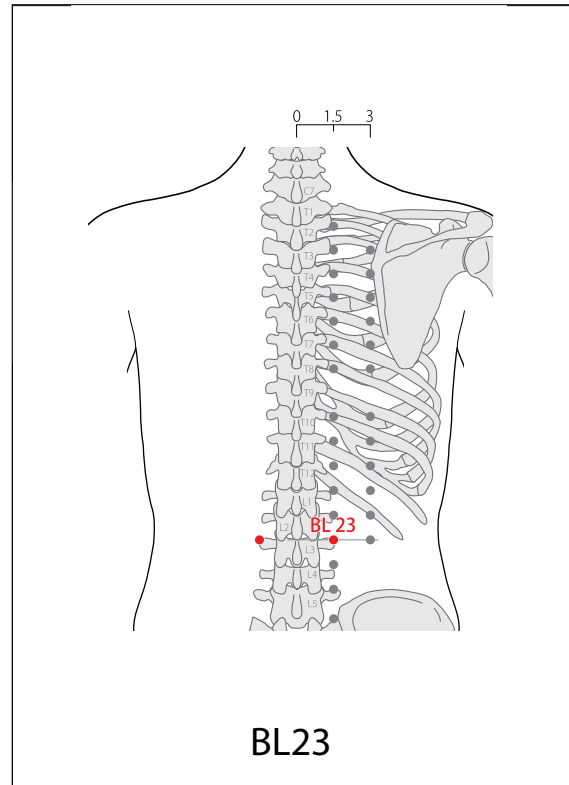
### BL22: Sanjiaoshu 三焦俞(俞)

In the lumbar region, at the same level as the inferior border of the spinous process of the first lumbar vertebra (L1), 1.5 B-cun lateral to the posterior median line.

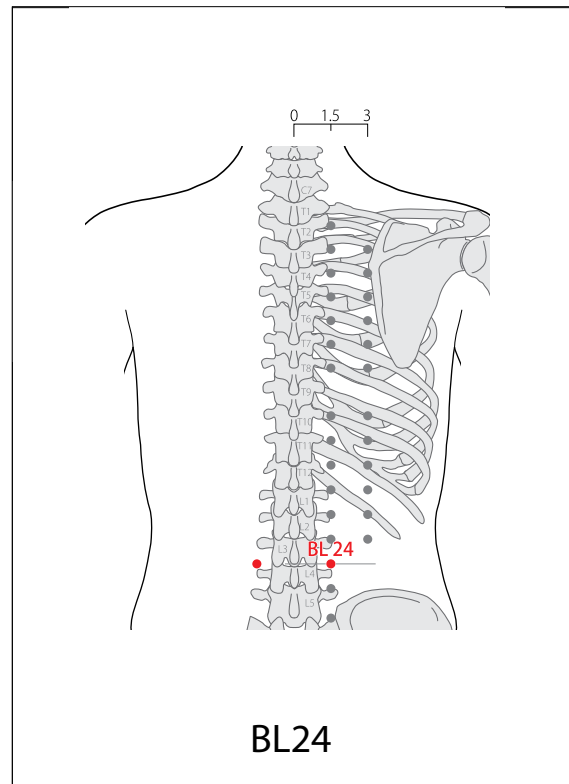


**BL23: Shenshu 腎俞(俞)**

In the lumbar region, at the same level as the inferior border of the spinous process of the second lumbar vertebra (L2), 1.5 B-cun lateral to the posterior median line.

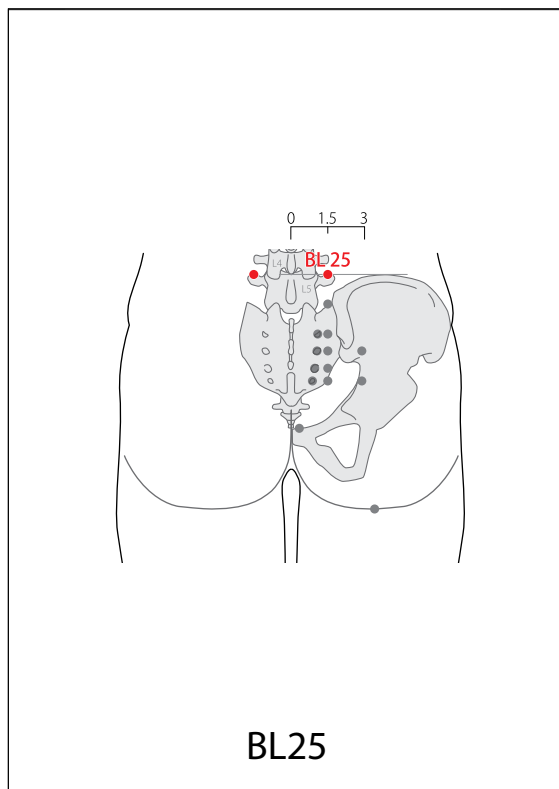
**BL24: Qihaishu 氣(气, 氣)海(海)俞(俞)**

In the lumbar region, at the same level as the inferior border of the spinous process of the third lumbar vertebra (L3), 1.5 B-cun lateral to the posterior median line.



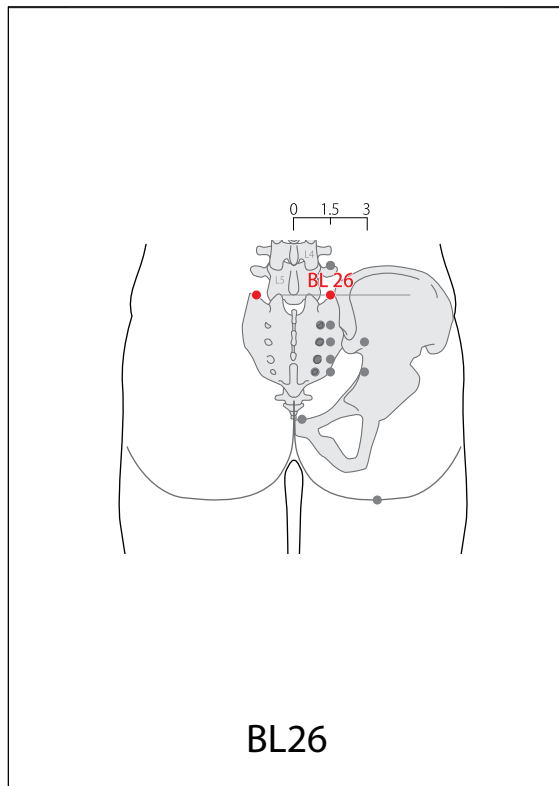
### BL25: Dachangshu 大腸俞 (俞)

In the lumbar region, at the same level as the inferior border of the spinous process of the fourth lumbar vertebra (L4), 1.5 B-cun lateral to the posterior median line.



### BL26: Guanyuanshu 關(关, 関)元俞 (俞)

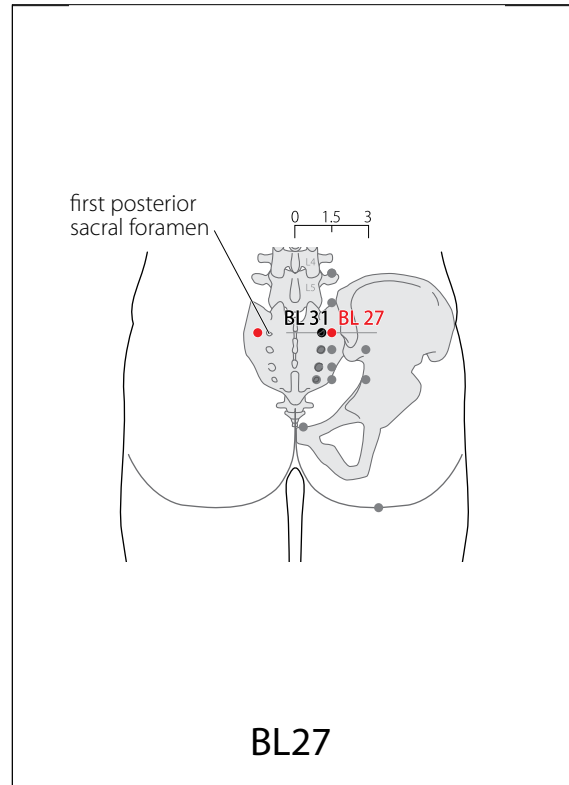
In the lumbar region, at the same level as the inferior border of the spinous process of the fifth lumbar vertebra (L5), 1.5 B-cun lateral to the posterior median line.



### BL27: Xiaochangshu 小腸(腸)俞(俞)

In the sacral region, at the same level as the first posterior sacral foramen, and 1.5 B-cun lateral to the median sacral crest.

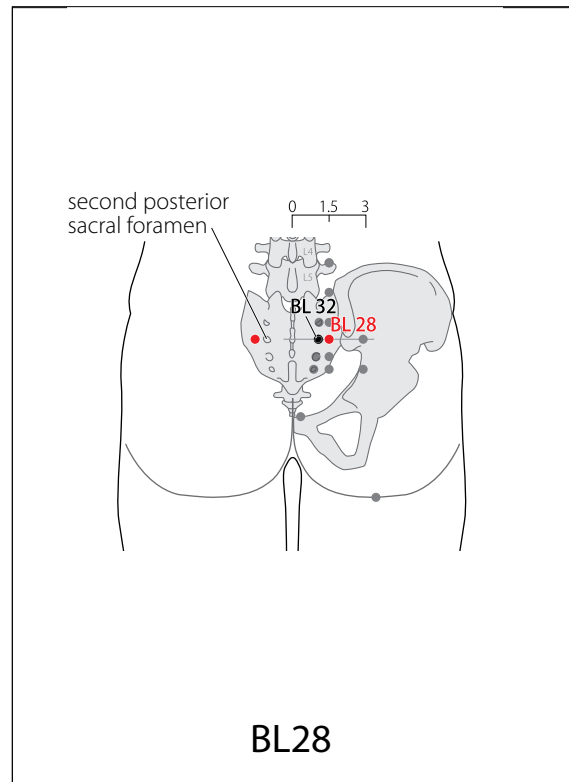
Note: At the same level as BL31.



### BL28: Pangguangshu 膀胱俞(俞)

In the sacral region, at the same level as the second posterior sacral foramen, and 1.5 B-cun lateral to the median sacral crest.

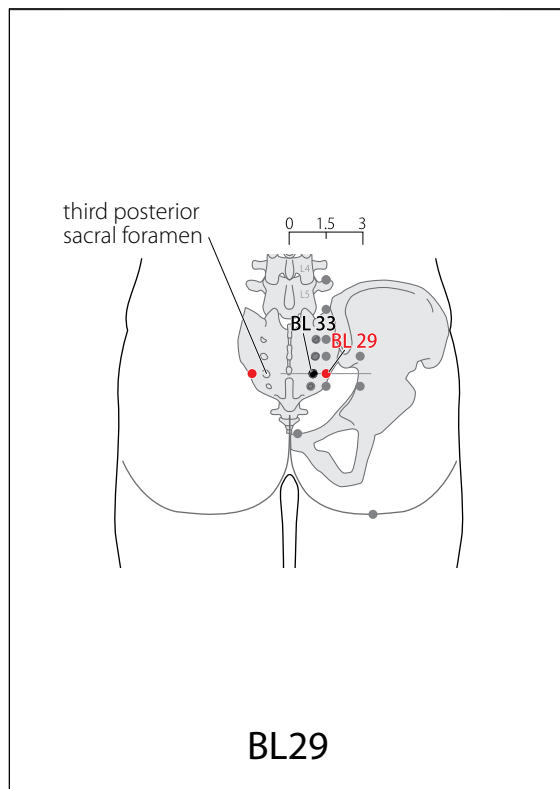
Note: At the same level as BL32.



### BL29: Zhonglushu 中膺俞(俞)

In the sacral region, at the same level as the third posterior sacral foramen, 1.5 B-cun lateral to the median sacral crest.

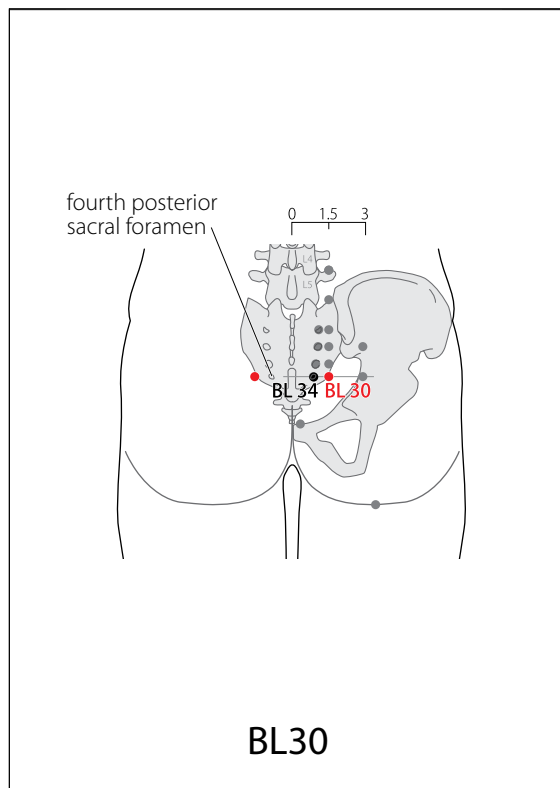
Note: At the same level as BL33.



### BL30: Baihuanshu 白環(环)俞(俞)

In the sacral region, at the same level as the fourth posterior sacral foramen, 1.5 B-cun lateral to the median sacral crest.

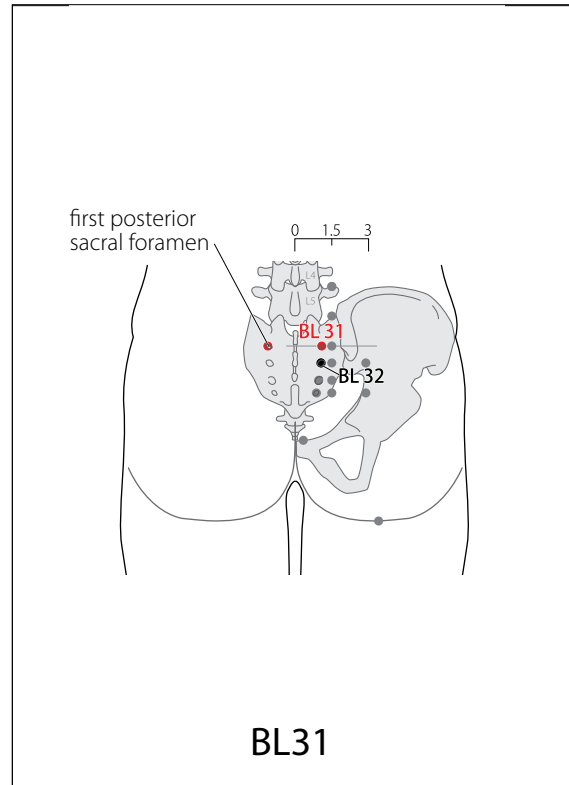
Note: 1.5 B-cun lateral to the sacral hiatus, at the same level as BL34.



**BL31: Shangliao 上髎(髎)**

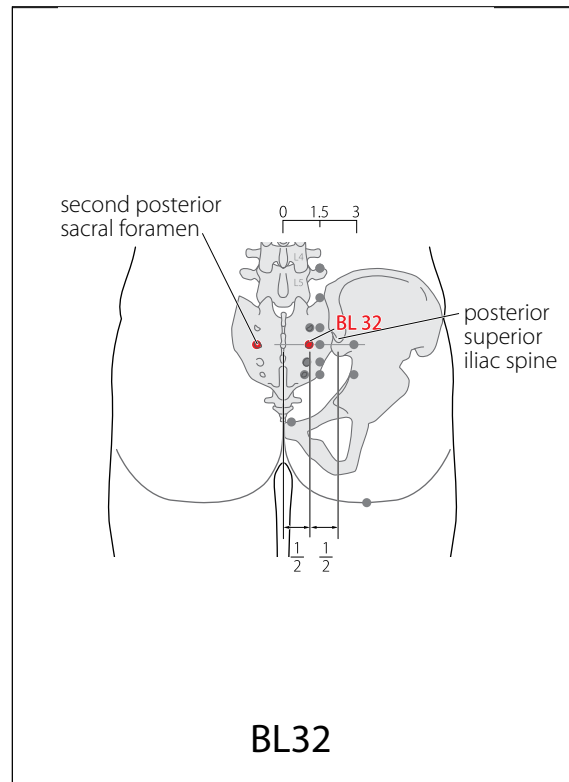
In the sacral region, in the first posterior sacral foramen.

Note: The first posterior sacral foramen is palpated in the depression, moving superiorly from BL32.

**BL32: Ciliao 次髎(髎)**

In the sacral region, in the second posterior sacral foramen.

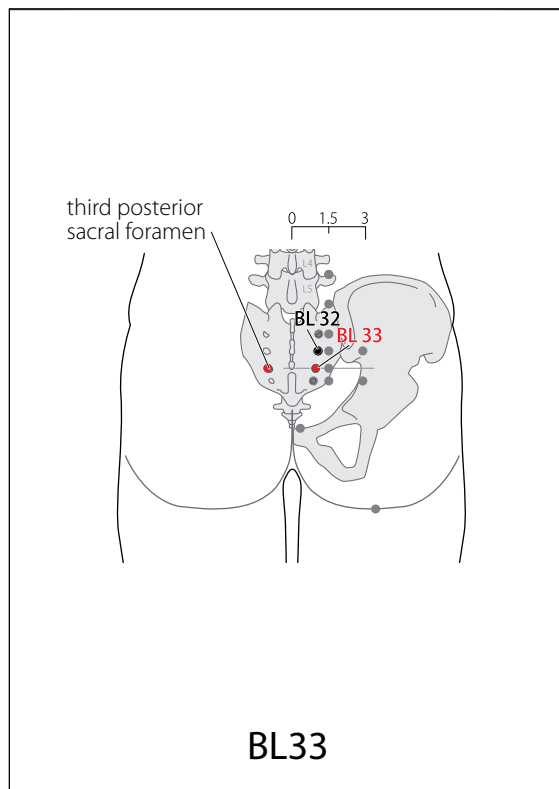
Note: The second posterior sacral foramen is located in the depression, midway between the posterior superior iliac spine and the spinous process of the second sacral vertebra.



### BL33: Zhongliao 中髎(髎)

In the sacral region, in the third posterior sacral foramen.

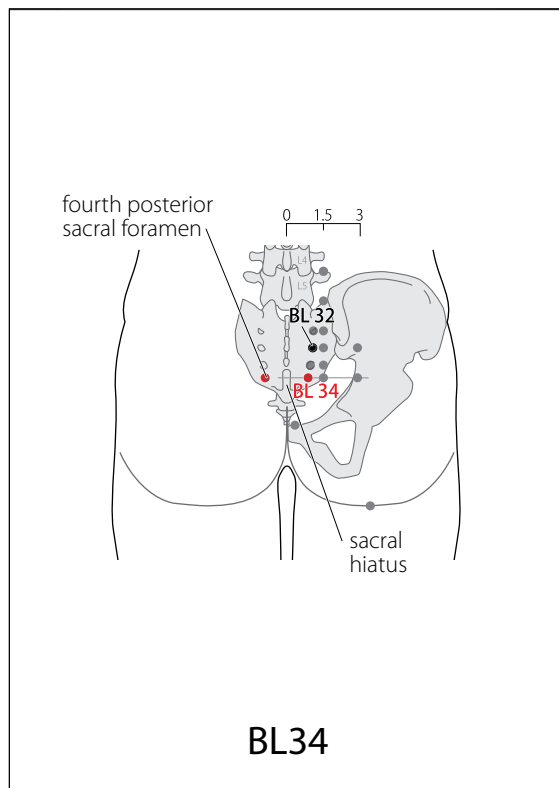
Note: The third posterior sacral foramen is located in the first depression, moving downward from BL32.



### BL34: Xialiao 下髎(髎)

In the sacral region, in the fourth posterior sacral foramen.

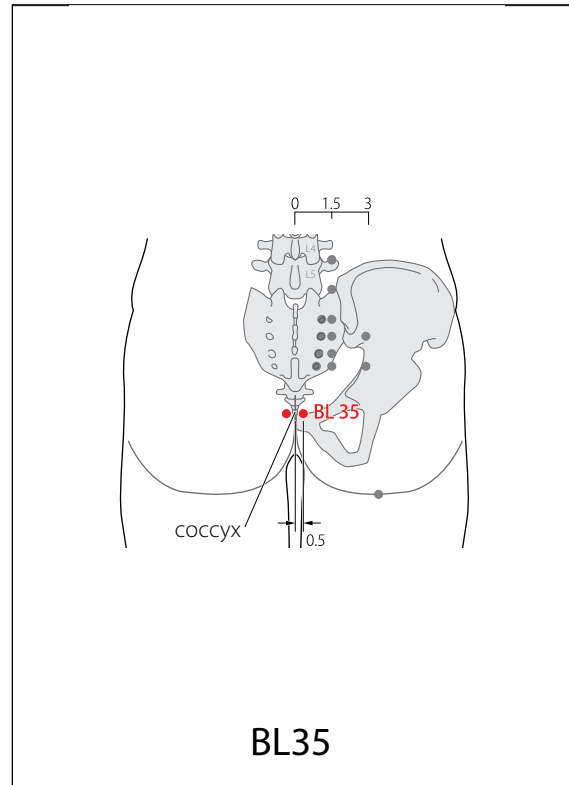
Note: The fourth posterior sacral foramen is located in the second depression, moving downward from BL32, at the same level as the sacral hiatus.



### BL35: Huiyang 會(会)陽(阳)

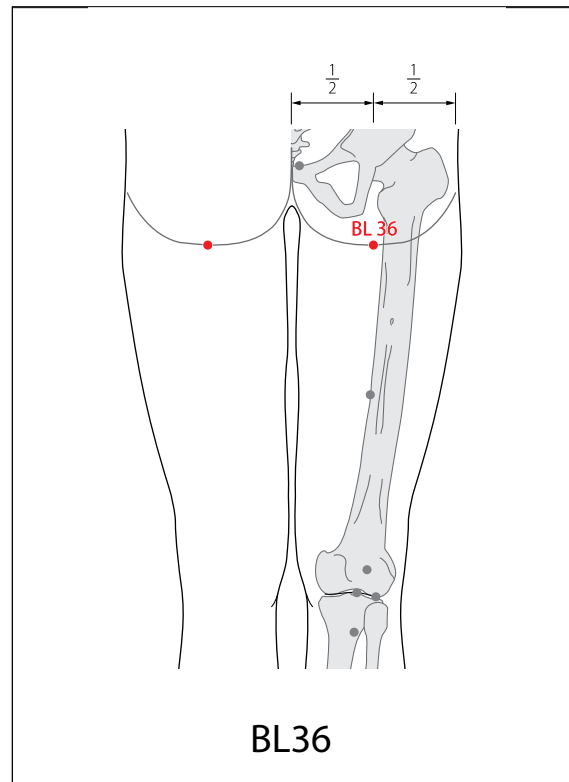
In the buttock region, 0.5 B-cun lateral to the extremity of the coccyx.

Note: The subject may be in prone position or knee-chest position. BL35 is located at the soft depression lateral to the extremity of the coccyx.



### BL36: Chengfu 承扶

In the buttock region, at the midpoint of the gluteal fold.

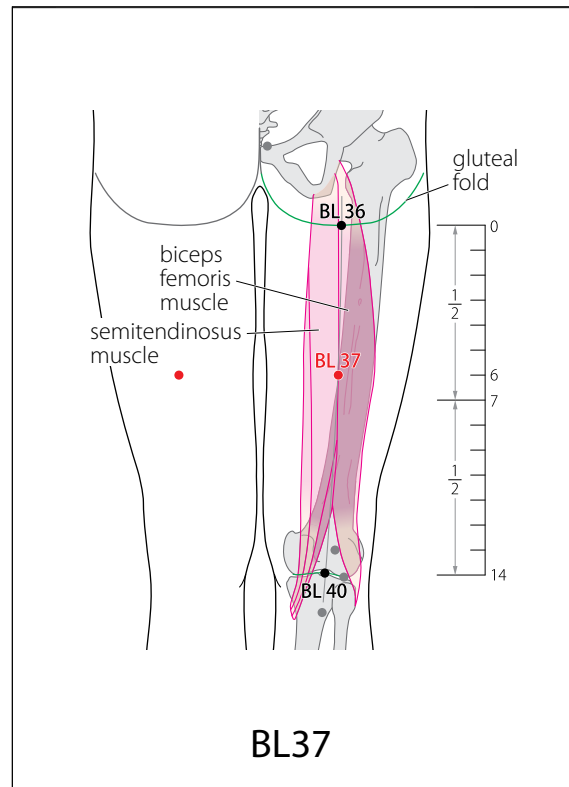


### BL37: Yinmen 殷門 (門)

On the posterior aspect of the thigh, between the biceps femoris and the semitendinosus muscles, 6 B-cun inferior to the gluteal fold.

Note 1: In the prone position, the semitendinosus and the biceps femoris muscles are more distinct when the knee is flexed against resistance. In addition, it is easier to find the two muscles with internal and external rotation of the hip.

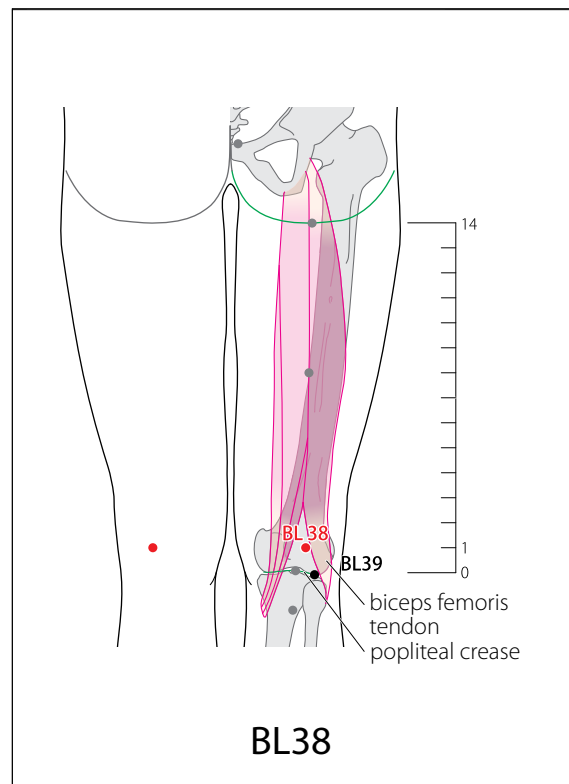
Note 2: 1 B-cun superior to the midpoint of the line connecting BL36 with BL40.



### BL38: Fuxi 浮 (浮) 郤

On the posterior aspect of the knee, just medial to the biceps femoris tendon, 1 B-cun proximal to the popliteal crease.

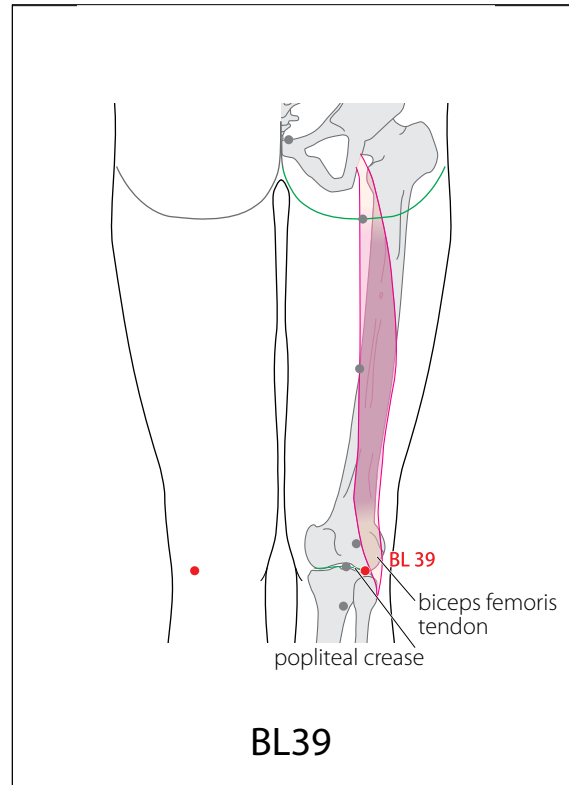
Note: With the knee in slight flexion, BL38 is located medial to the biceps femoris tendon, 1 B-cun proximal to BL39.



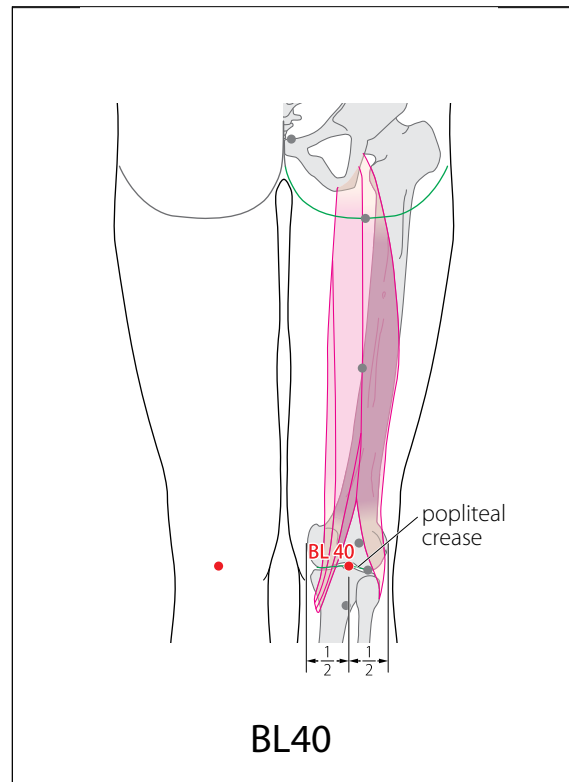
**BL39: Weiyang 委陽(阳)**

On the posterolateral aspect of the knee, just medial to the biceps femoris tendon in the popliteal crease.

Note: The biceps femoris tendon is more prominent when the knee is slightly flexed.

**BL40: Weizhong 委中**

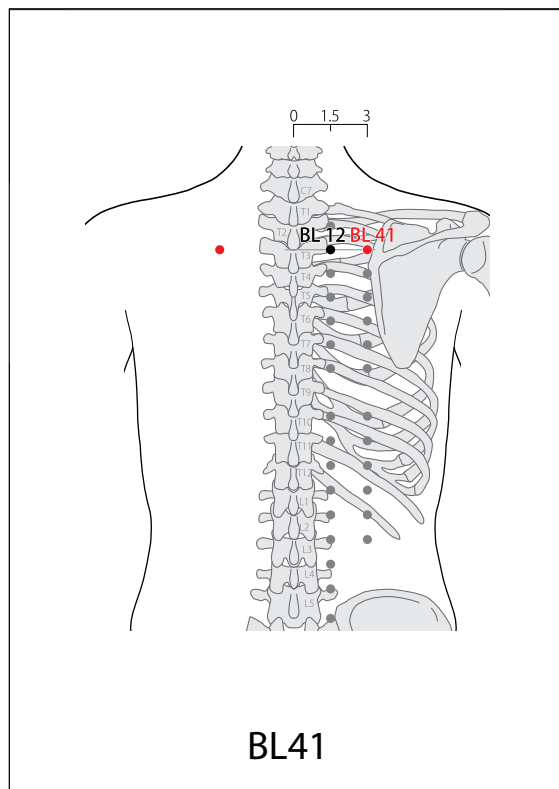
On the posterior aspect of the knee, at the midpoint of the popliteal crease.



### BL41: Fufen 附分

In the upper back region, at the same level as the inferior border of the spinous process of the second thoracic vertebra (T2), 3 B-cun lateral to the posterior median line.

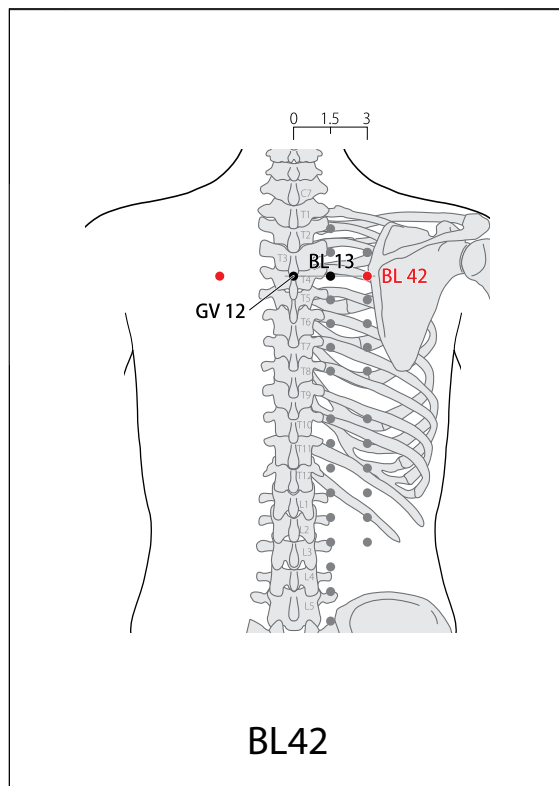
Note: BL41 and BL12 are located at the same level as the inferior border of the spinous process of the second thoracic vertebra (T2).



### BL42: Pohu 魄户

In the upper back region, at the same level as the inferior border of the spinous process of the third thoracic vertebra (T3), 3 B-cun lateral to the posterior median line.

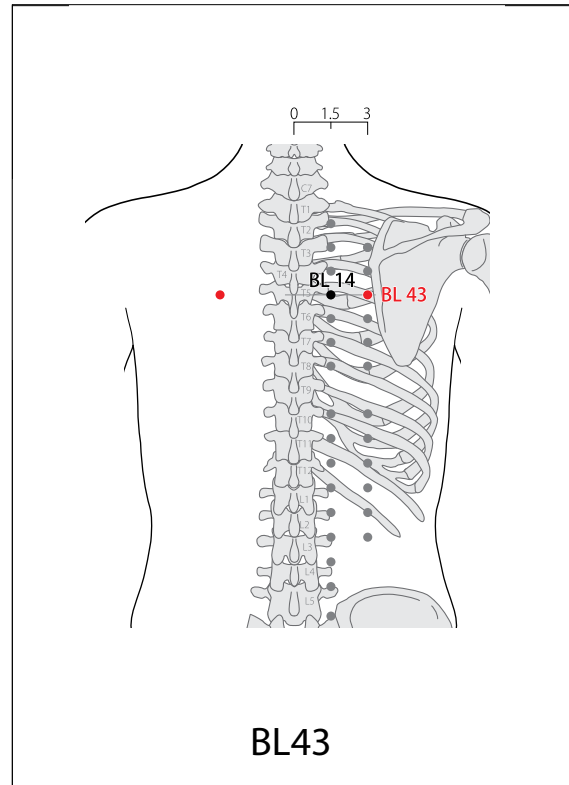
Note: BL42, BL13 and GV12 are located at the same level as the inferior border of the third thoracic vertebra (T3).



**BL43: Gaohuang 膏肓**

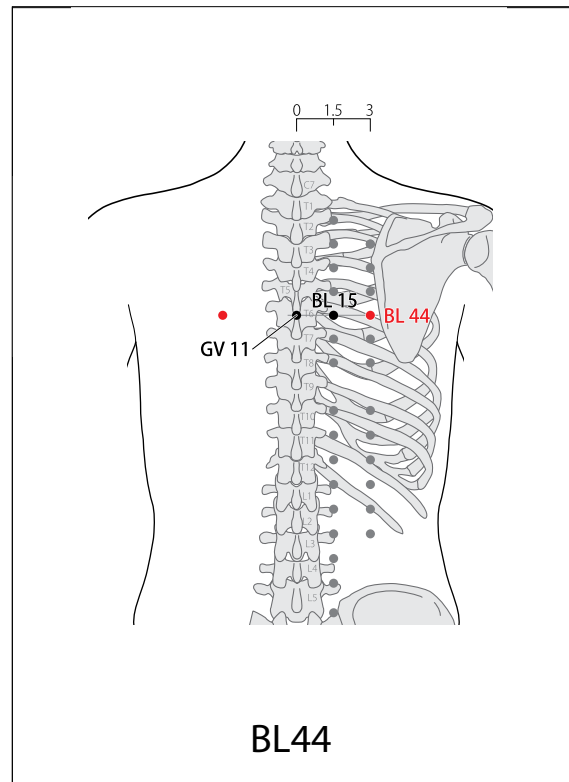
In the upper back region, at the same level as the inferior border of the spinous process of the fourth thoracic vertebra (T4), 3 B-cun lateral to the posterior median line.

Note: BL43 and BL14 are located at the same level as the inferior border of the spinous process of the fourth thoracic vertebra (T4).

**BL44: Shentang 神(神)堂**

In the upper back region, at the same level as the inferior border of the spinous process of the fifth thoracic vertebra (T5), 3 B-cun lateral to the posterior median line.

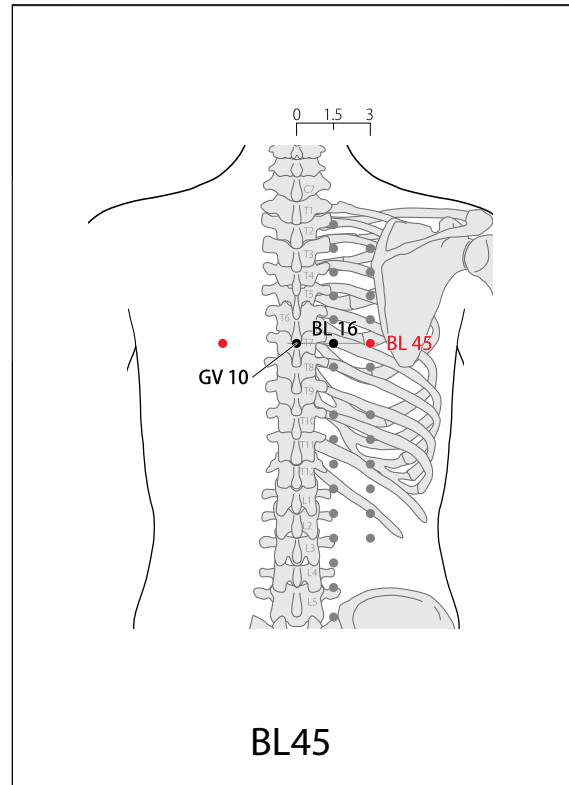
Note: BL44, BL15 and GV11 are located at the same level as the inferior border of the spinous process of the fifth thoracic vertebra (T5).



### BL45: Yixi 臆譚

In the upper back region, at the same level as the inferior border of the spinous process of the sixth thoracic vertebra (T6), 3 B-cun lateral to the posterior median line.

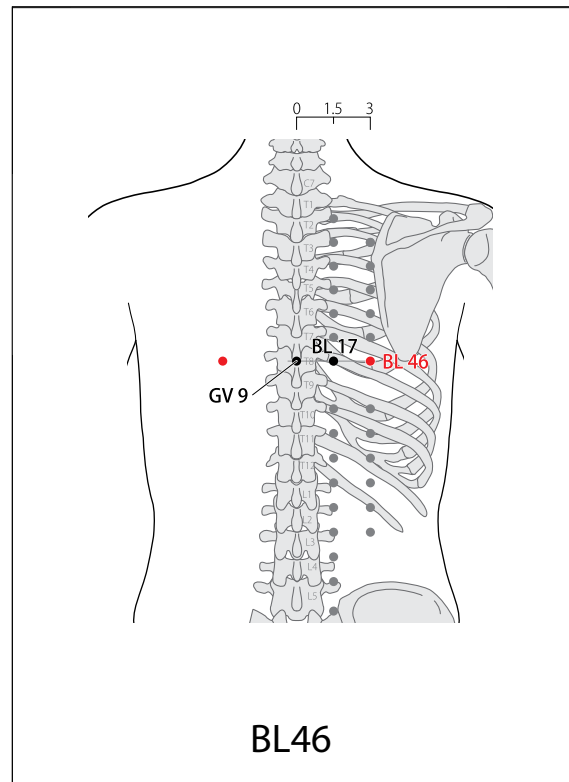
Note: BL45, BL16 and GV10 are located at the same level as the inferior border of the spinous process of the sixth thoracic vertebra (T6).



### BL46: Geguan 膈關 (关, 関)

In the upper back region, at the same level as the inferior border of the spinous process of the seventh thoracic vertebra (T7), 3 B-cun lateral to the posterior median line.

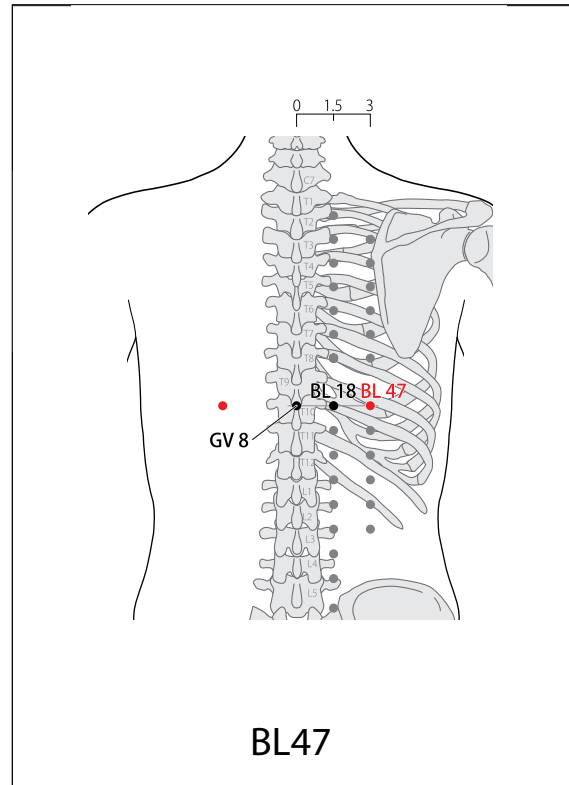
Note: BL 46, BL17 and GV9 are located at the same level as the inferior border of the spinous process of the seventh thoracic vertebra (T7).



### BL 47: Hunmen 魂門 (門)

In the upper back region, at the same level as the inferior border of the spinous process of the ninth thoracic vertebra (T9), 3 B-cun lateral to the posterior median line.

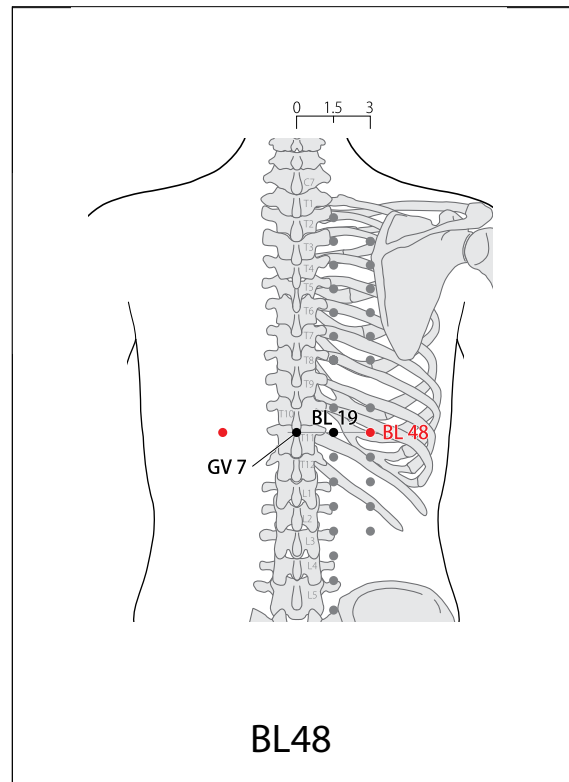
Note: BL47, BL18 and GV8 are located at the same level as the inferior border of the spinous process of the ninth thoracic vertebra (T9).



### BL 48: Yanggang 陽 (陽) 綱 (綱)

In the upper back region, at the same level as the inferior border of the spinous process of the tenth thoracic vertebra (T10), 3 B-cun lateral to the posterior median line.

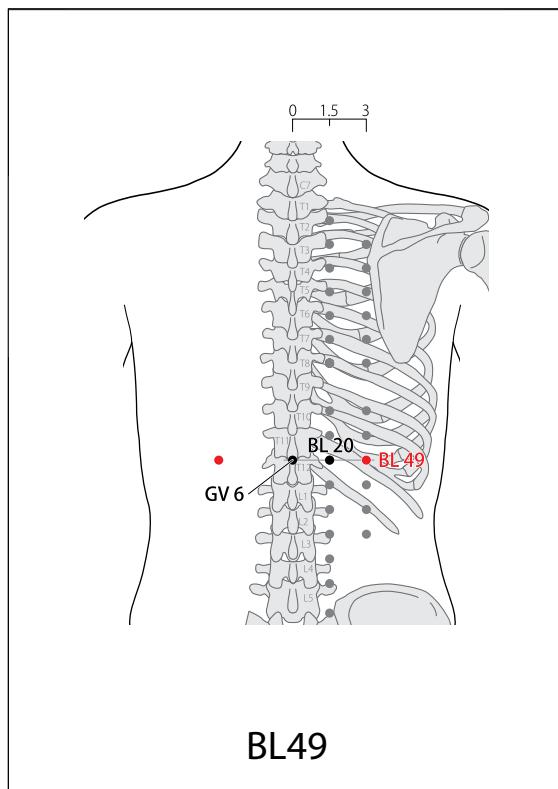
Note: BL48, BL19 and GV7 are located at the same level as the inferior border of the spinous process of the tenth thoracic vertebra (T10).



### BL 49: Yishe 意舍(舍)

In the upper back region, at the same level as the inferior border of the spinous process of the 11th thoracic vertebra (T11), 3 B-cun lateral to the posterior median line.

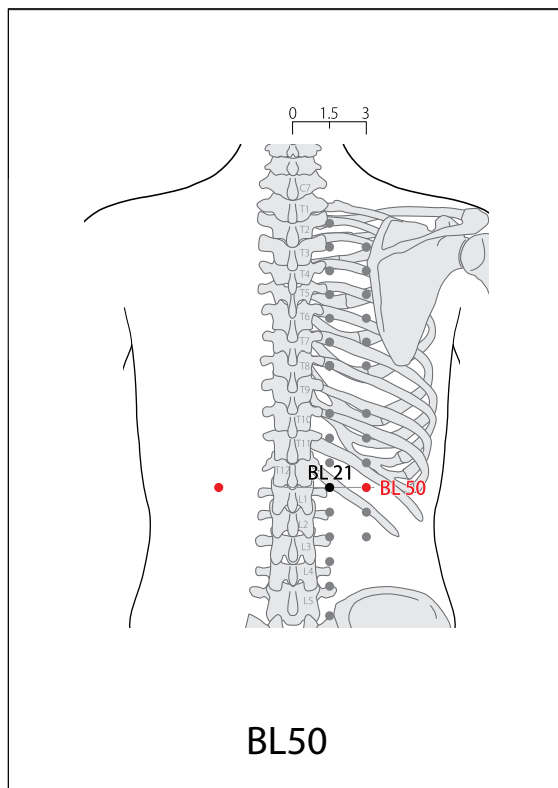
Note: BL49, BL20 and GV6 are located at the same level as the inferior border of the spinous process of the 11th thoracic vertebra (T11).



### BL 50: Weicang 胃倉(仓)

In the upper back region, at the same level as the inferior border of the spinous process of the 12th thoracic vertebra (T12), 3 B-cun lateral to the posterior median line.

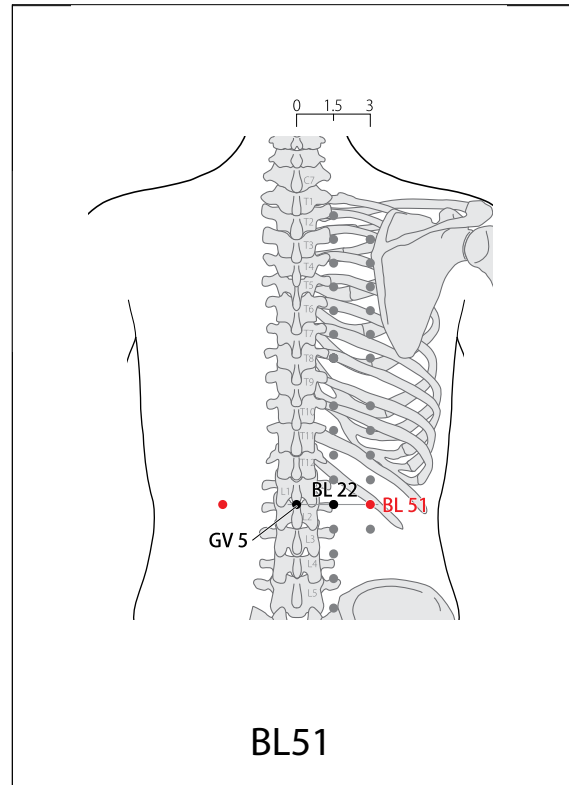
Note: BL50 and BL21 are located at the same level as the inferior border of the spinous process of the 12th thoracic vertebra (T12).



### BL51: Huangmen 育門(门)

In the lumbar region, at the same level as the inferior border of the spinous process of the first lumbar vertebra (L1), 3 B-cun lateral to the posterior median line.

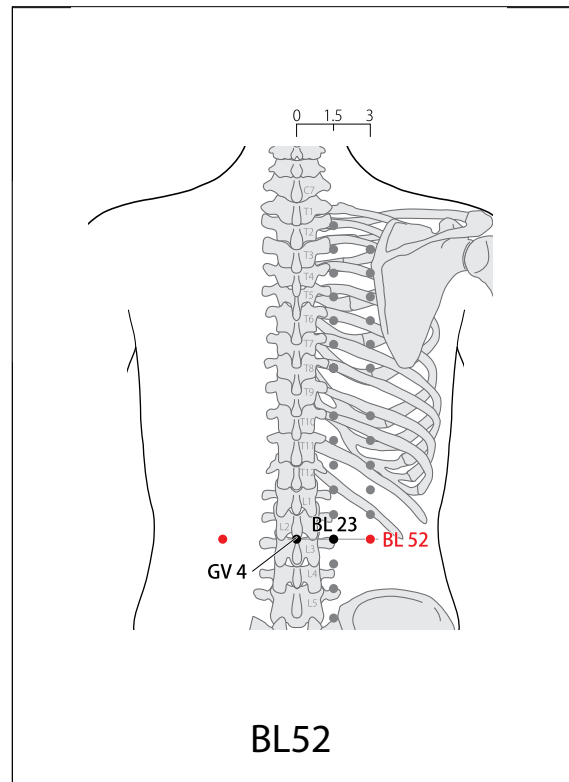
Note: BL51, BL22 and GV5 are located at the same level as the inferior border of the spinous process of the first lumbar vertebra (L1).



### BL52: Zhishi 志室

In the lumbar region, at the same level as the inferior border of the spinous process of the second lumbar vertebra (L2), 3 B-cun lateral to the posterior median line.

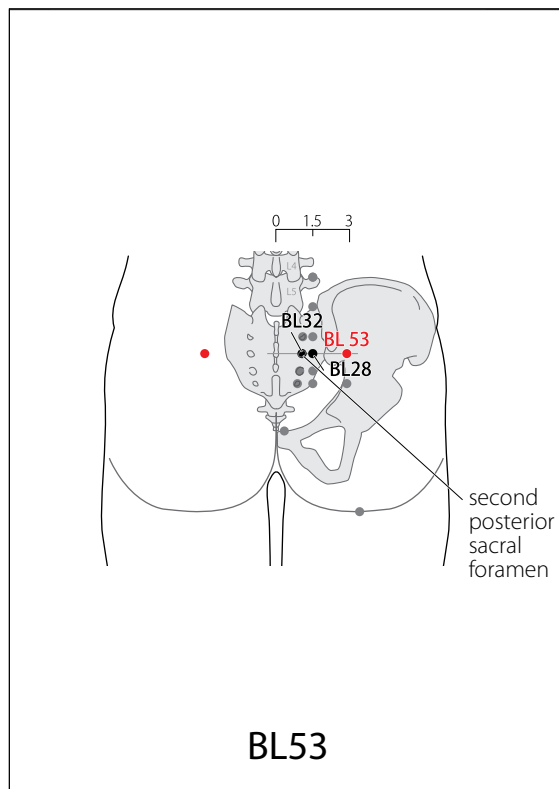
Note: BL52, BL23 and GV4 are located at the same level as the inferior border of the spinous process of the second lumbar vertebra (L2).



### BL53: Baohuang 胞(胞)育

In the buttock region, at the same level as the second posterior sacral foramen, 3 B-cun lateral to the median sacral crest.

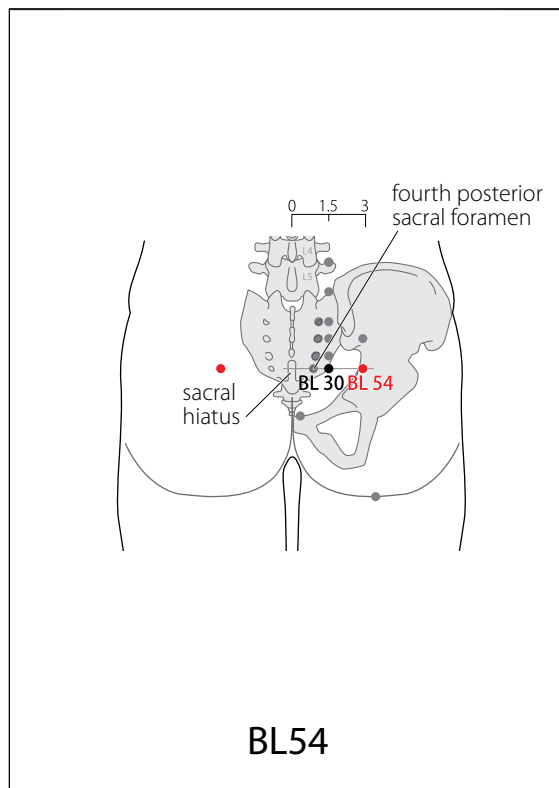
Note: BL53, BL28 and BL32 are located at the same level as the second posterior sacral foramen.



### BL54: Zhibian 秩邊(边, 辺)

In the buttock region, at the same level as the fourth posterior sacral foramen, 3 B-cun lateral to the median sacral crest.

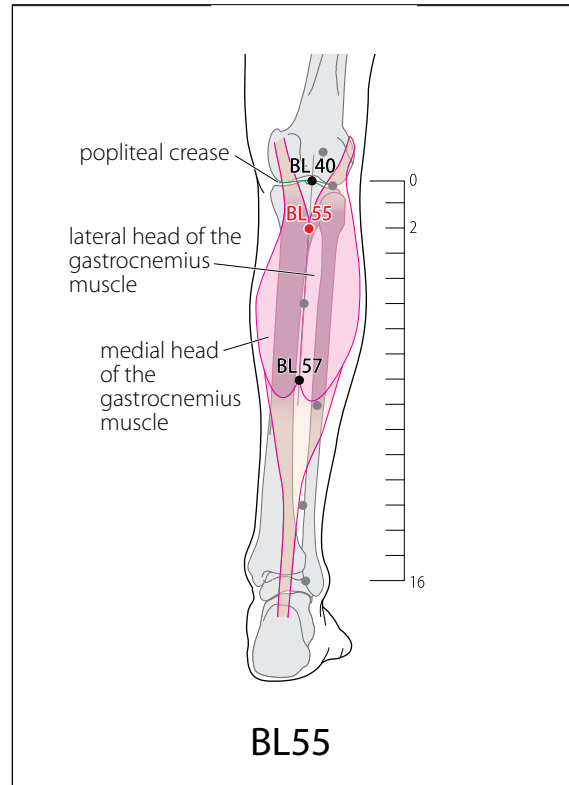
Note: 3 B-cun lateral to the sacral hiatus, at the same level as BL 30.



### BL55: Heyang 合陽(阳)

On the posterior aspect of the leg, between the lateral head and medial head of the gastrocnemius muscle, 2 B-cun distal to the popliteal crease.

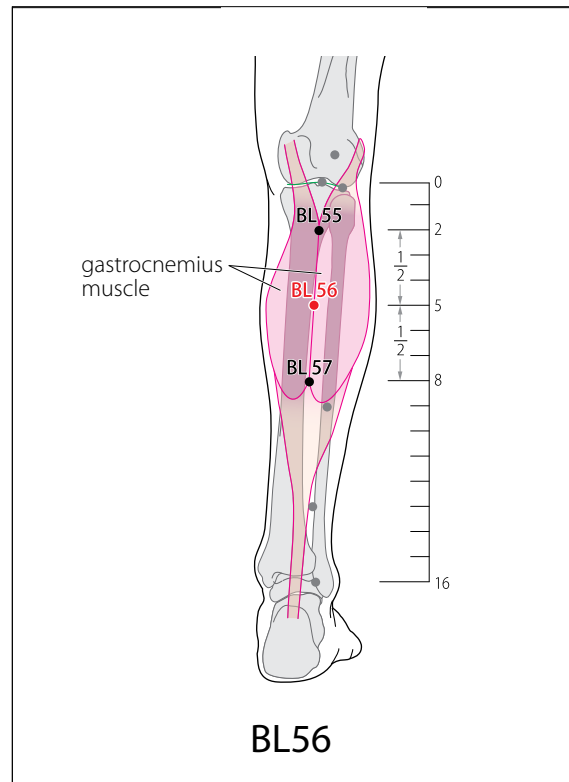
Note: 2 B-cun distal to BL40, on the line connecting BL40 with BL57.



### BL56: Chengjin 承筋

On the posterior aspect of the leg, between the two muscle bellies of the gastrocnemius muscle, 5 B-cun distal to the popliteal crease.

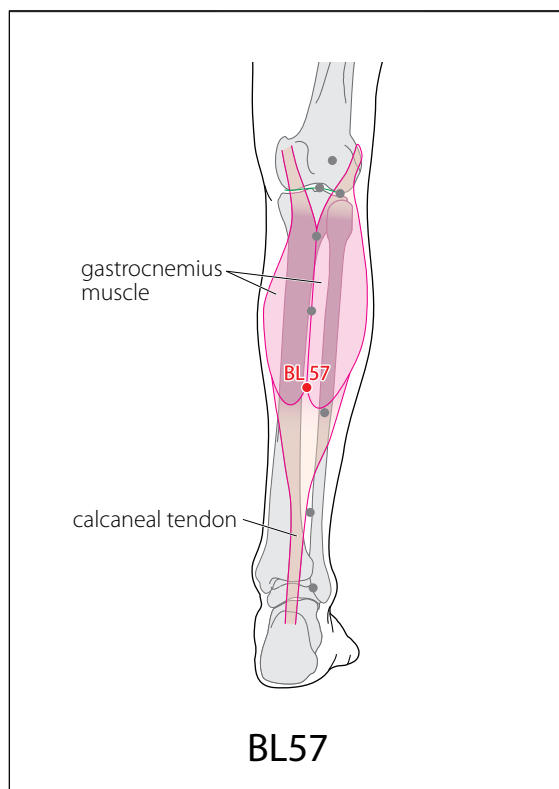
Note: Midway between BL55 and BL57.



### BL57: Chengshan 承山

On the posterior aspect of the leg, at the connecting point of the calcaneal tendon with the two muscle bellies of the gastrocnemius muscle.

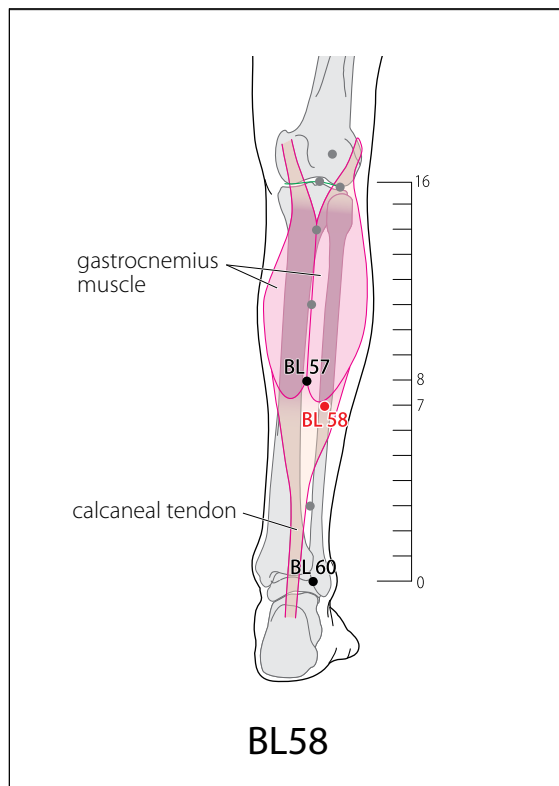
Note: With the leg stretched (plantar flexion) or the heel up, BL57 is located at the sharp angled depression inferior to the muscle belly of the gastrocnemius muscle. The two heads of the gastrocnemius muscle are separated to make a lambda shape ( $\Lambda$ ).



### BL58: Feiyang 飛(飞)揚(扬)

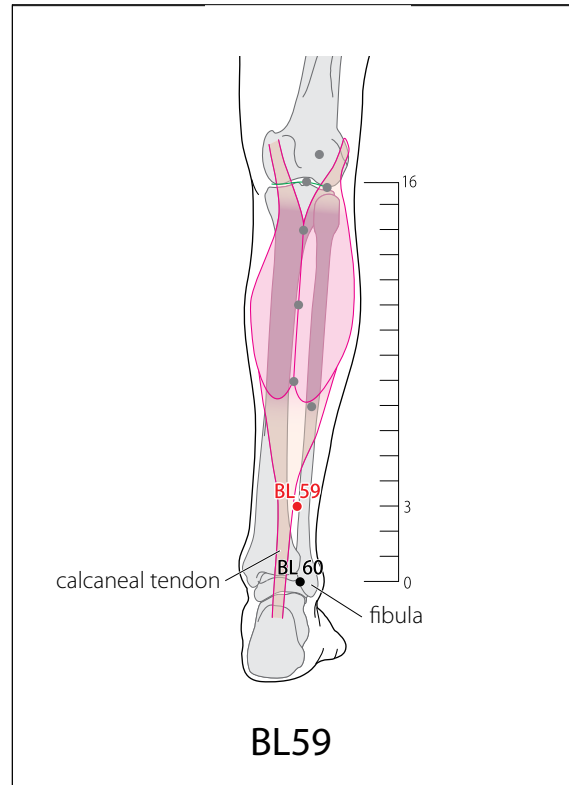
On the posterolateral aspect of the leg, between the inferior border of the lateral head of the gastrocnemius muscle and the calcaneal tendon, at the same level as 7 B-cun proximal to BL60.

Note: BL58 is located 1 B-cun lateral and distal to BL57, proximal to BL60.

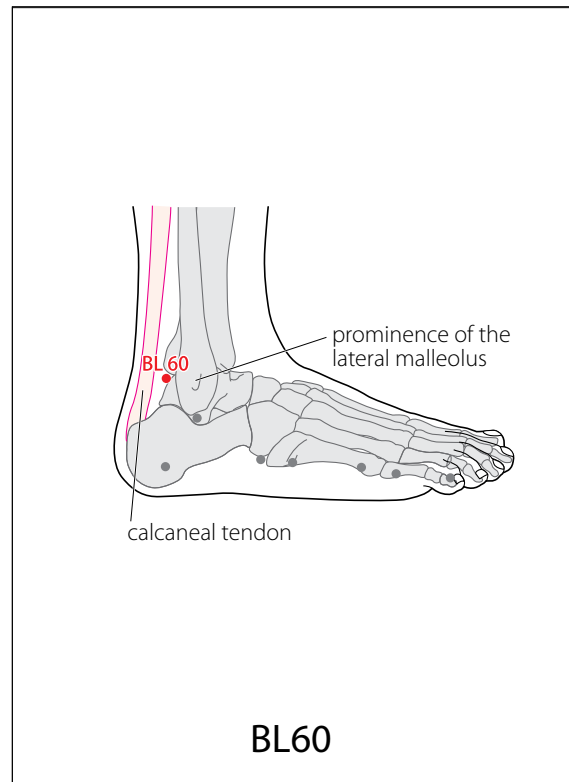


**BL59: Fuyang 跗陽(阳)**

On the posterolateral aspect of the leg, between the fibula and the calcaneal tendon, at the same level as 3 B-cun proximal to BL60.

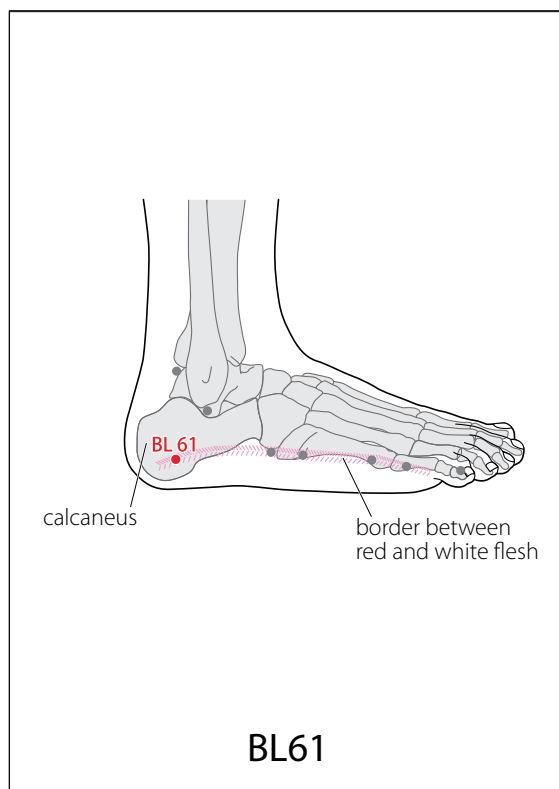
**BL60: Kunlun 崑(昆)崙(崙, 仑)**

On the posterolateral aspect of the ankle, in the depression between the prominence of the lateral malleolus and the calcaneal tendon.



# BL61: Pucan (Pushen) 僕(仆)參(参)

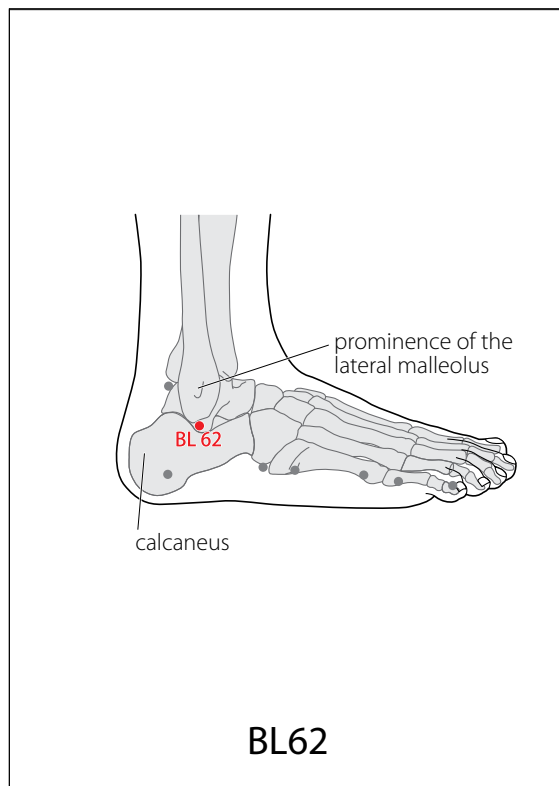
On the lateral aspect of the foot, distal to BL60, lateral to the calcaneus, at the border between the red and white flesh.



# BL62: Shenmai 申脈(脉)

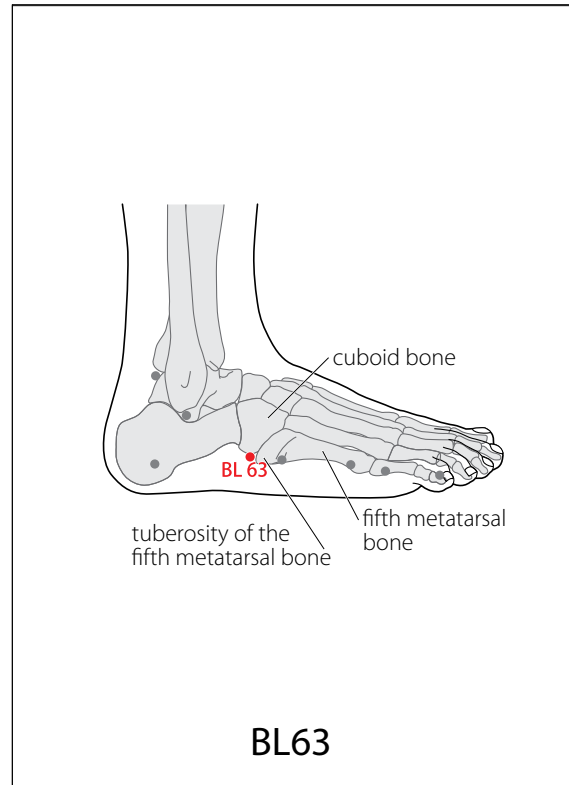
On the lateral aspect of the foot, directly inferior to the prominence of the lateral malleolus, in the depression between the inferior border of the lateral malleolus and the calcaneus.

Note: BL62 is located in the depression distal to the inferior border of the lateral malleolus. The corresponding medial acupuncture point to BL 62 is KI6.



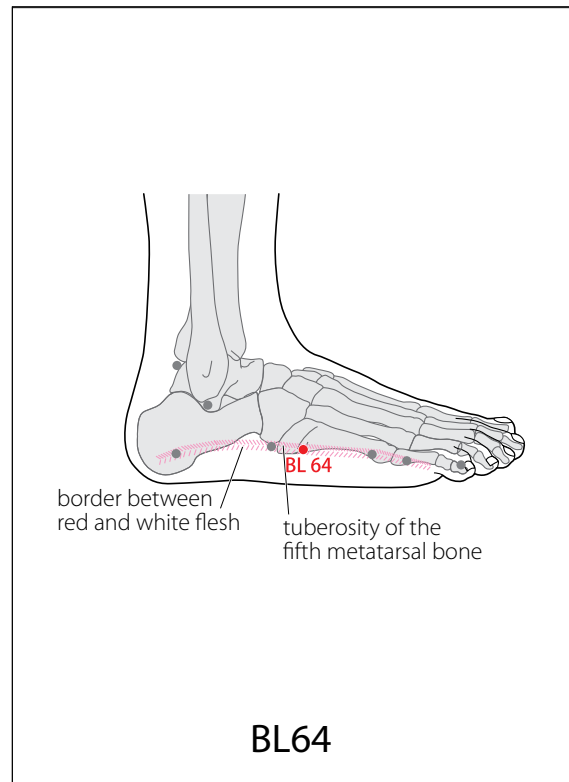
**BL63: Jinmen 金門 (门)**

On the dorsum of the foot, distal to the anterior border of the lateral malleolus, posterior to the tuberosity of the fifth metatarsal bone, in the depression inferior to the cuboid bone.

**BL64: Jinggu 京骨 (骨)**

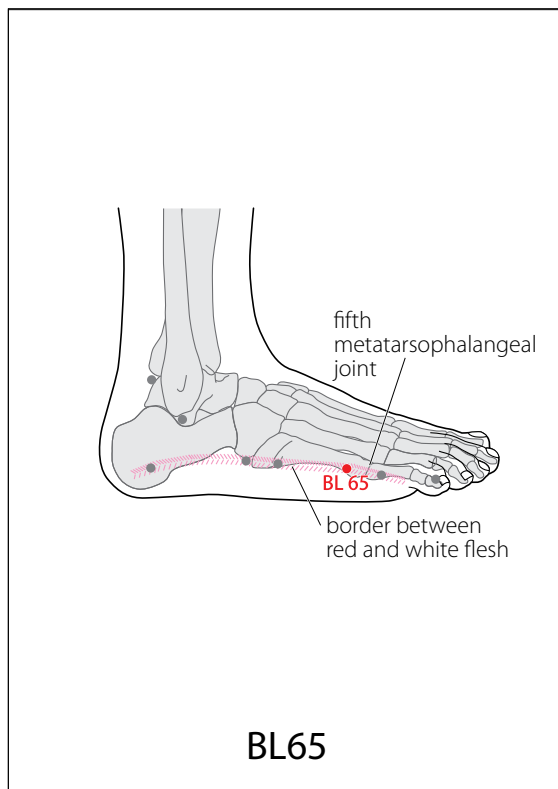
On the lateral aspect of the foot, distal to the tuberosity of the fifth metatarsal bone, at the border between the red and white flesh.

Note: The tuberosity of the fifth metatarsal bone is located approximately midway between the heel and the fifth metatarsophalangeal joint.

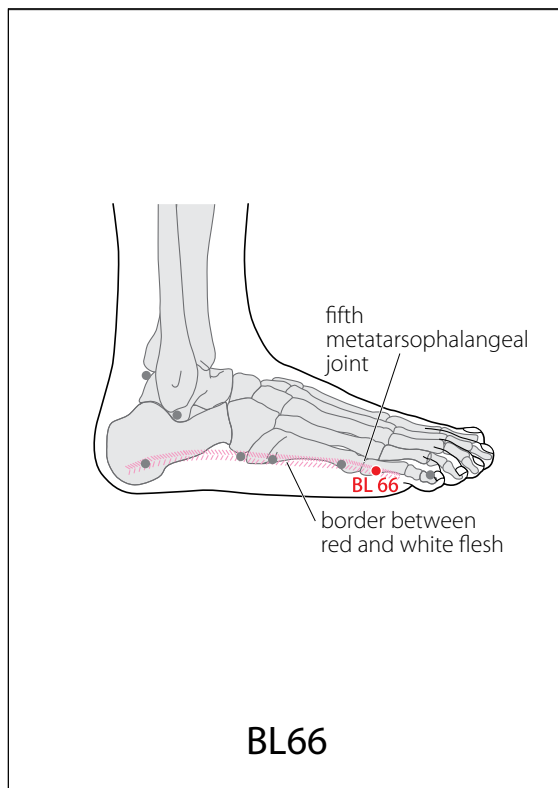


**BL65: Shugu 束骨 (骨)**

On the lateral aspect of the foot, in the depression proximal to the fifth metatarsophalangeal joint, at the border between the red and white flesh.

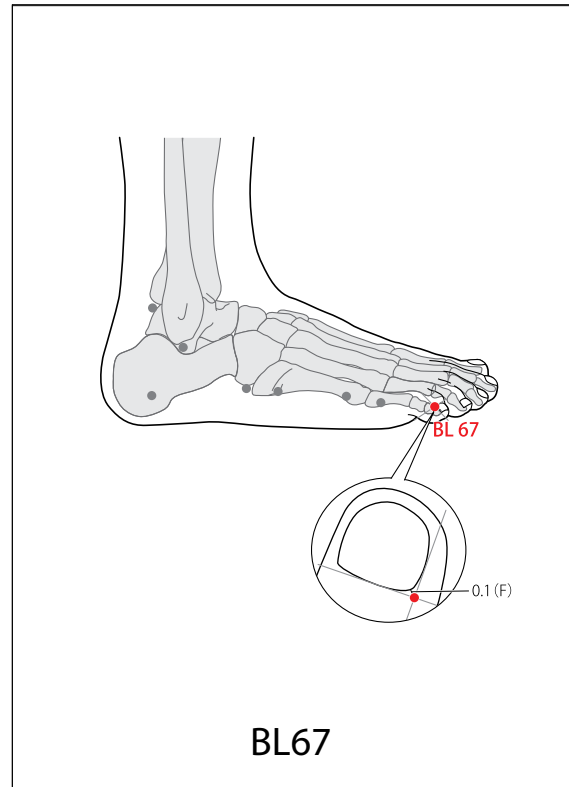
**BL66: Zutonggu 足通 (通) 谷**

On the little toe, in the depression distal and lateral to the fifth metatarsophalangeal joint, at the border between the red and white flesh.



**BL67: Zhiyin 至陰 (阴)**

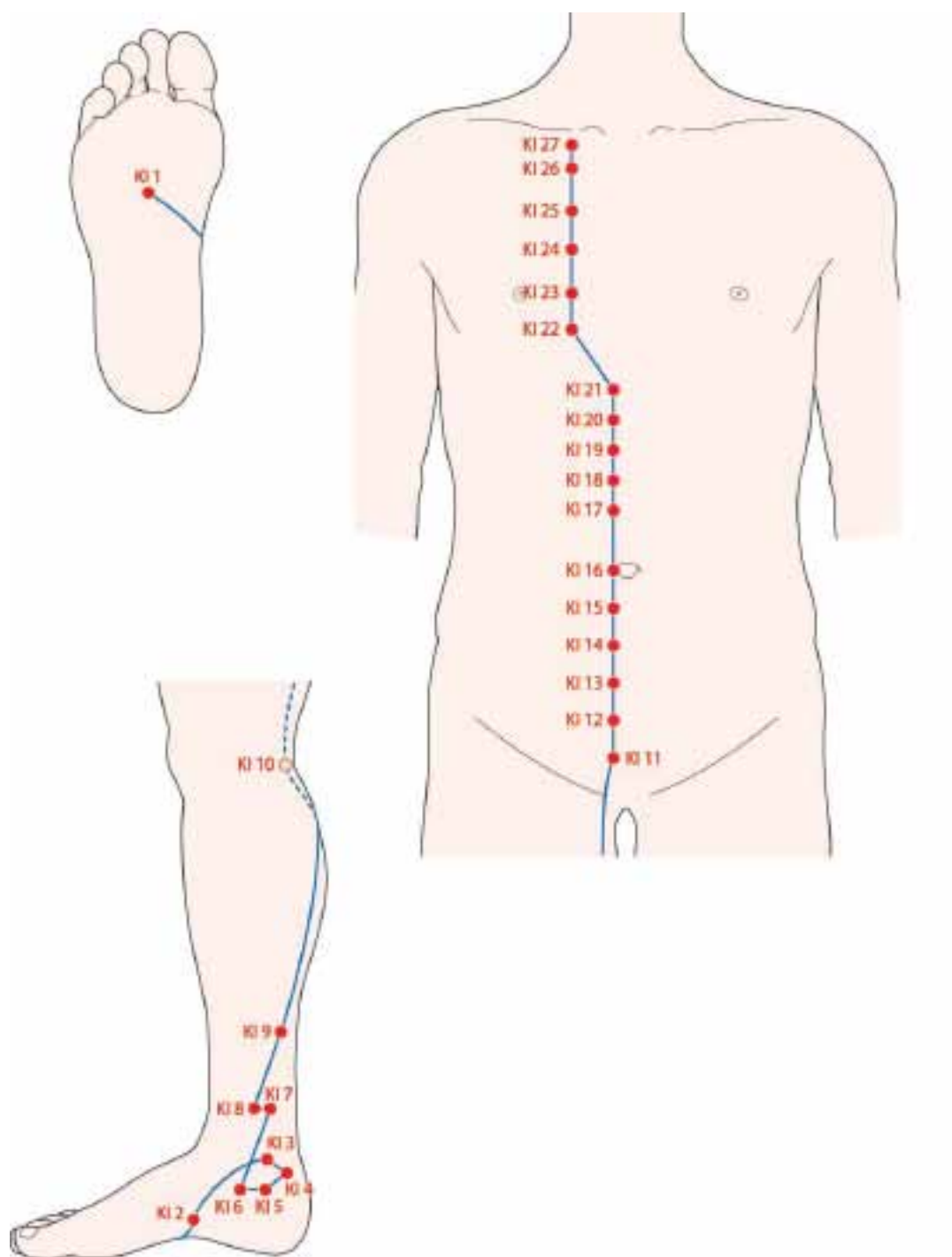
On the little toe, lateral to the distal phalanx, 0.1 F-cun proximal to the lateral corner of the toenail; at the intersection of the vertical line of the lateral side of the nail and the horizontal line of the base of the toenail.





## KIDNEY MERIDIAN

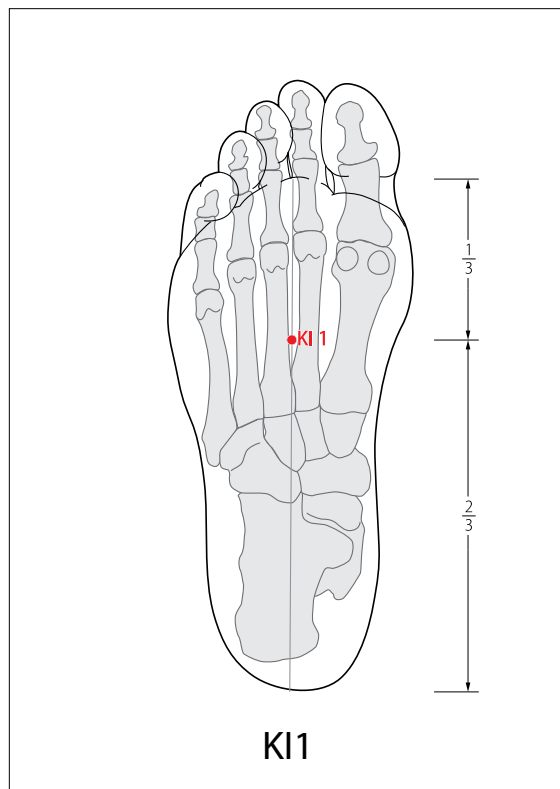
足少陰(陰)腎(腎)經(经, 経)



### KI1: Yongquan 湧(涌)泉

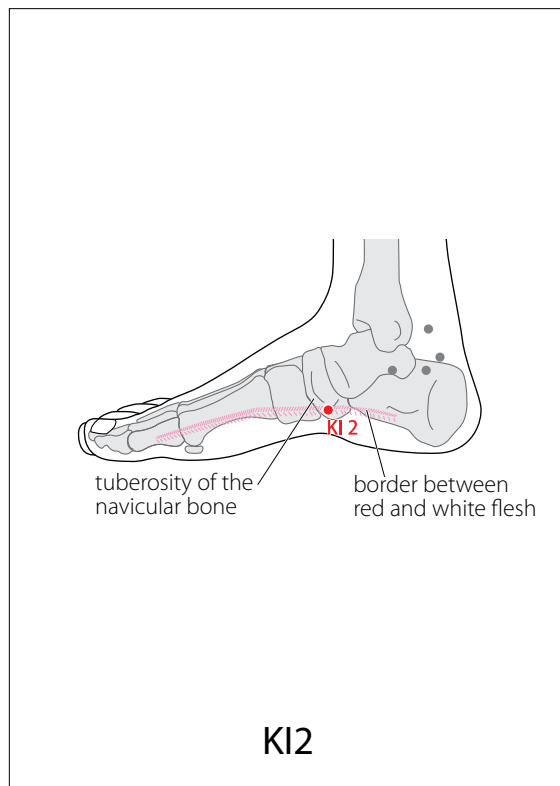
On the sole of the foot, in the deepest depression of the sole when the toes are flexed.

Note: When the toes are flexed, KI1 is located approximately in the depression at the junction of the anterior one third and the posterior two thirds of the line connecting the heel with the web margin between the bases of the second and third toes.



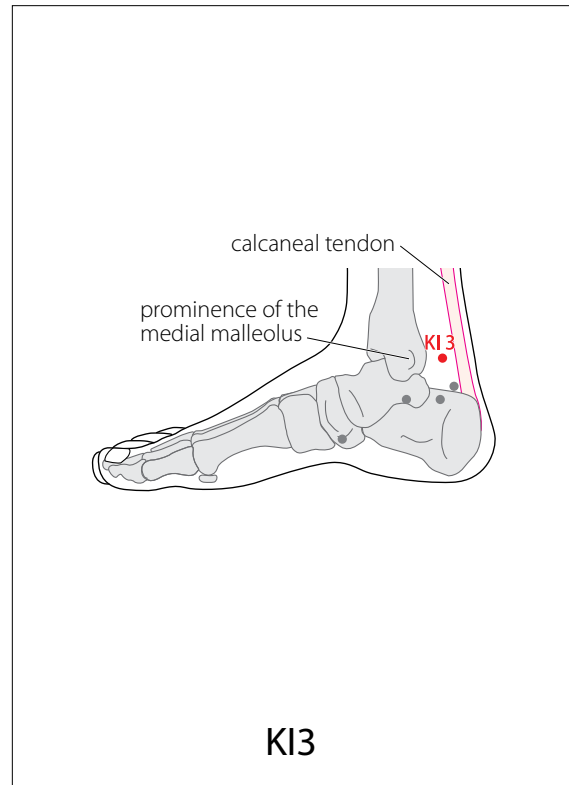
### KI2: Rangu 然谷

On the medial aspect of the foot, inferior to the tuberosity of the navicular bone, at the border between the red and white flesh.

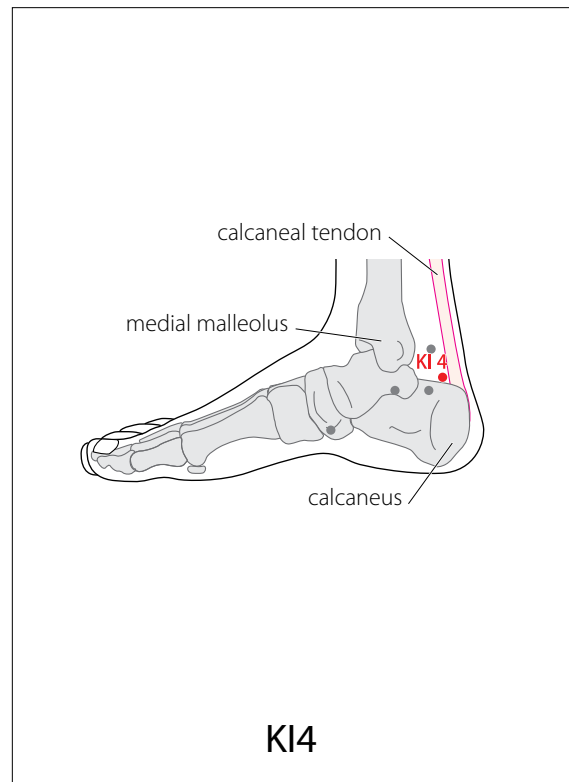


**KI3: Taixi 太谿(溪)**

On the posteromedial aspect of the ankle, in the depression between the prominence of the medial malleolus and the calcaneal tendon.

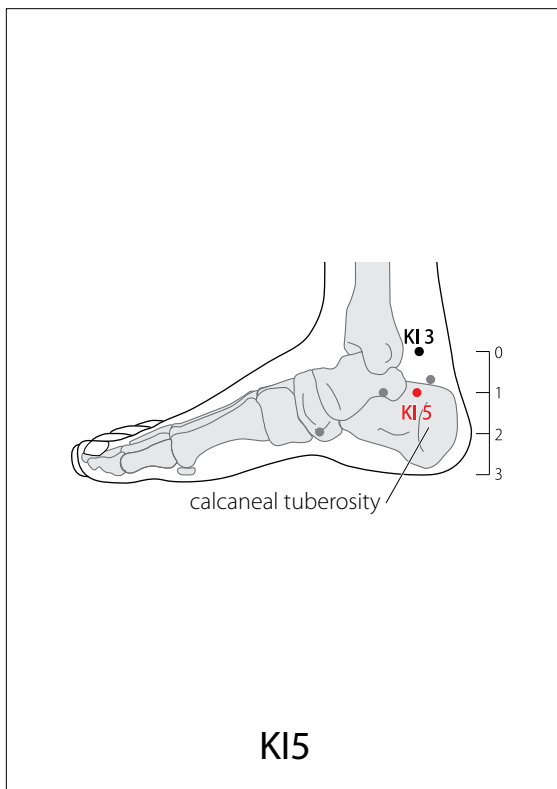
**KI4: Dazhong 大鍾(钟)**

On the medial aspect of the foot, postero-inferior to the medial malleolus, superior to the calcaneus, in the depression anterior to the medial attachment of the calcaneal tendon.



### KI5: Shuiquan 水泉

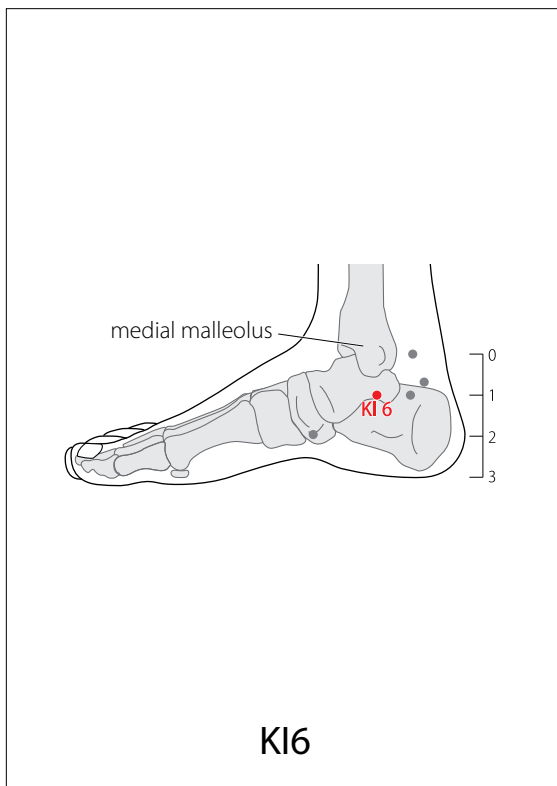
On the medial aspect of the foot, 1 B-cun inferior to KI3, in the depression anterior to the calcaneal tuberosity.



### KI6: Zhaohai 照海(海)

On the medial aspect of the foot, 1 B-cun inferior to the prominence of the medial malleolus, in the depression inferior to the medial malleolus.

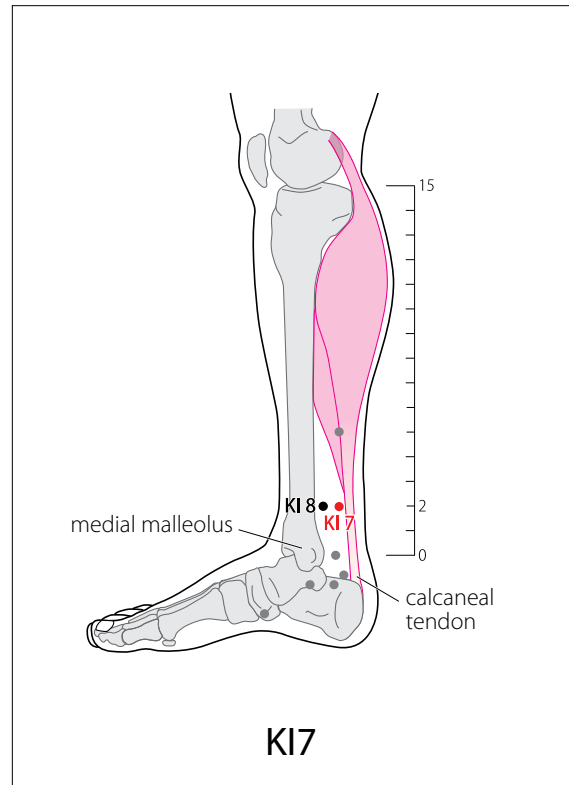
Note: The corresponding lateral point to KI6 is BL62.



### KI7: Fuliu 復(复)溜

On the posteromedial aspect of the leg, anterior to the calcaneal tendon, 2 B-cun superior to the prominence of the medial malleolus.

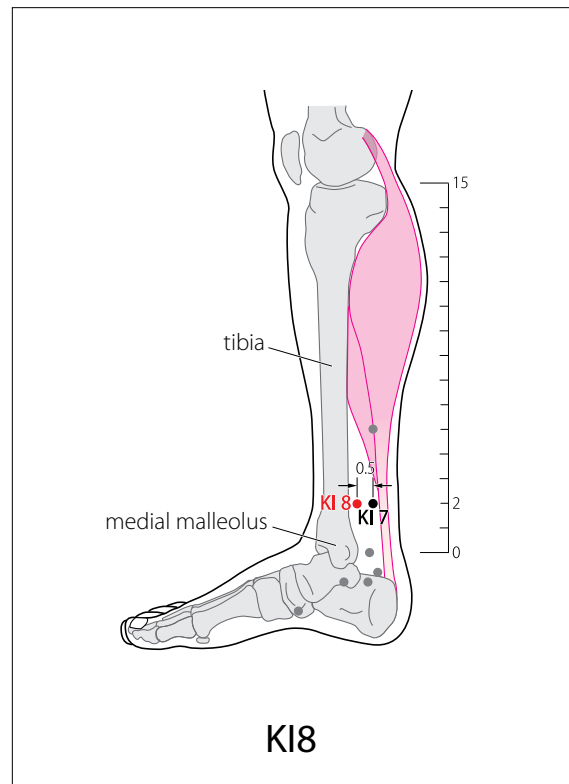
Note: At the same level and posterior to KI8.



### KI8: Jiaoxin 交信

On the medial aspect of the leg, in the depression posterior to the medial border of the tibial bone, 2 B-cun superior to the prominence of the medial malleolus.

Note: 0.5 B-cun anterior to KI7.

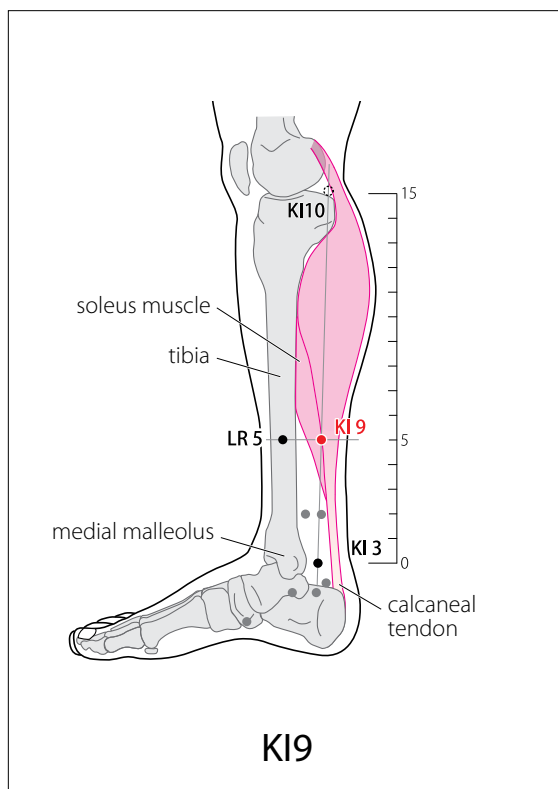


### KI9: Zhubin 築(筑)賓(宾)

On the posteromedial aspect of the leg, between the soleus muscle and the calcaneal tendon, 5 B-cun superior to the prominence of the medial malleolus.

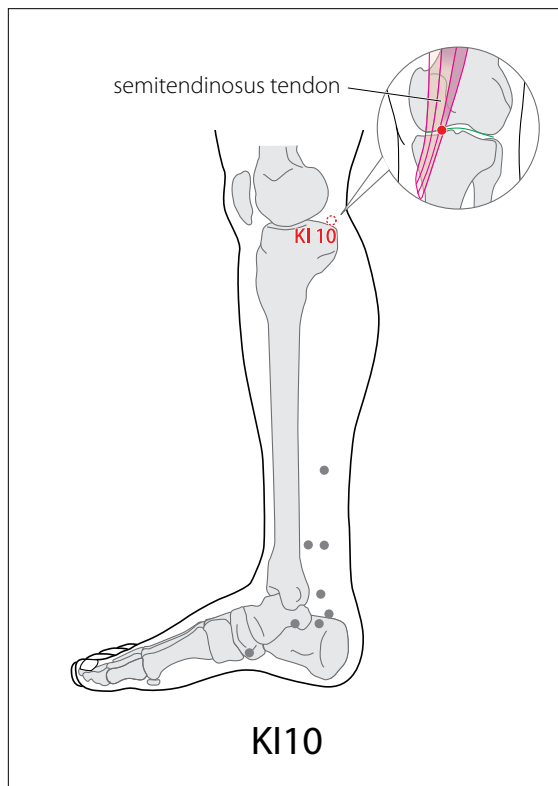
Note 1: With the knee flexed and the leg stretched (plantar flexion) against resistance, the soleus muscle can be seen more clearly along the medial border of the tibia bone.

Note 2: At the same level as LR5, on the line connecting KI3 with KI10.



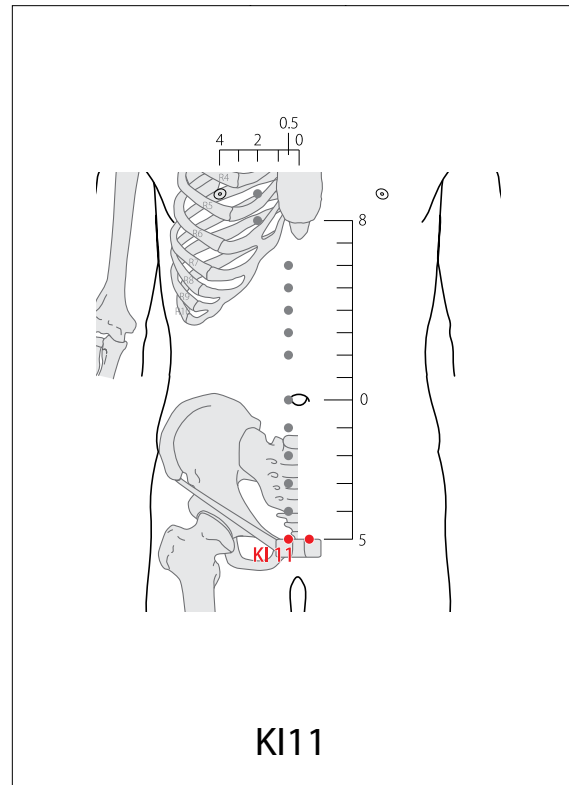
### KI10: Yingu 陰(阴)谷

On the posteromedial aspect of the knee, just lateral to the semitendinosus tendon, in the popliteal crease.

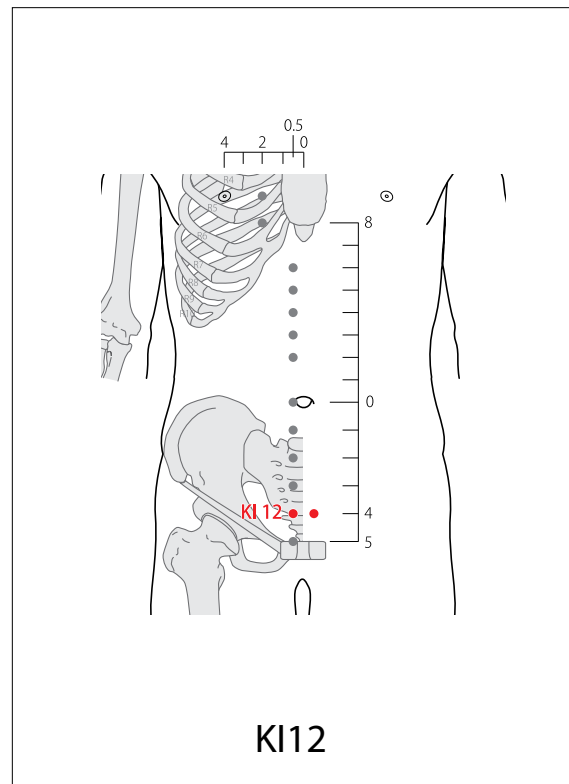


**KI11: Henggu 横骨(骨)**

On the lower abdomen, 5 B-cun inferior to the centre of the umbilicus, 0.5 B-cun lateral to the anterior median line.

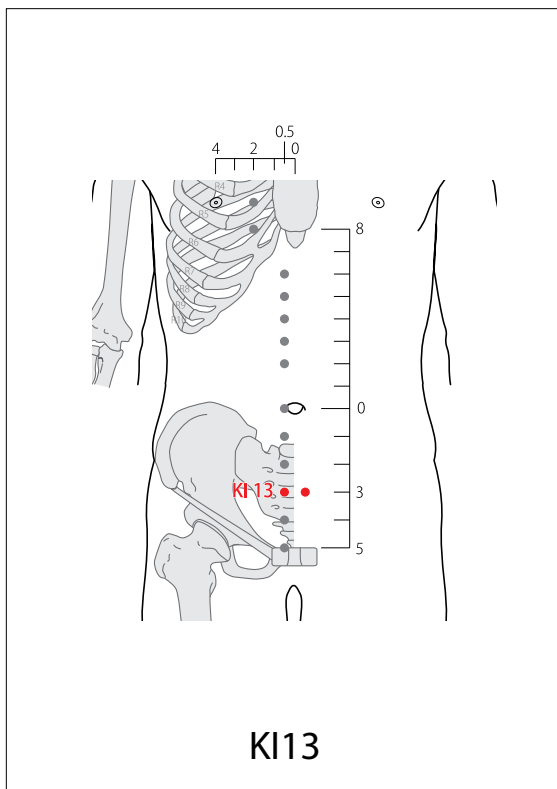
**KI12: Dahe 大赫**

On the lower abdomen, 4 B-cun inferior to the centre of the umbilicus, 0.5 B-cun lateral to the anterior median line.



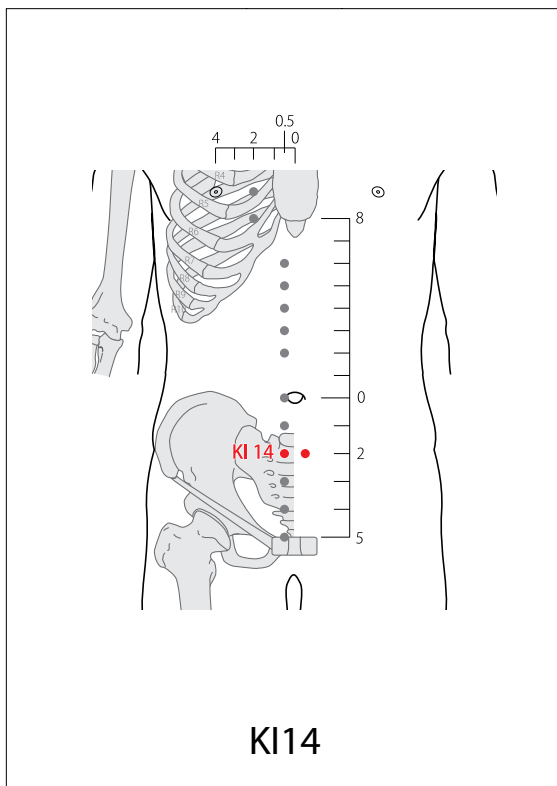
### KI13: Qixue 氣(气, 氣)穴

On the lower abdomen, 3 B-cun inferior to the centre of the umbilicus, 0.5 B-cun lateral to the anterior median line.



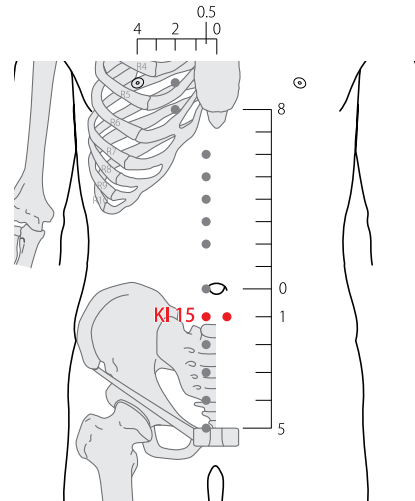
### KI14: Siman 四滿(满, 満)

On the lower abdomen, 2 B-cun inferior to the centre of the umbilicus, 0.5 B-cun lateral to the anterior median line.

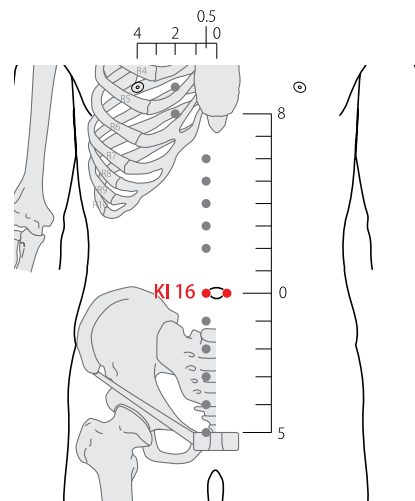


**KI15: Zhongzhu 中注**

On the lower abdomen, 1 B-cun inferior to umbilicus, 0.5 B-cun lateral to the anterior median line.

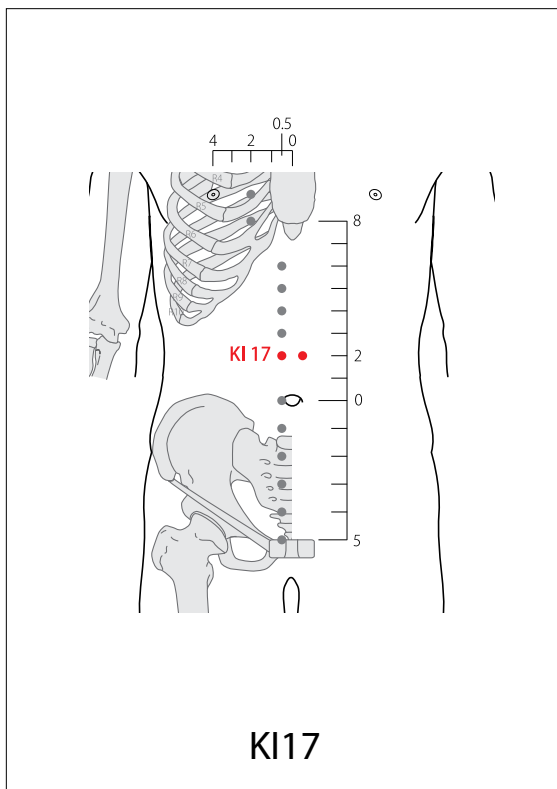
**KI15****KI16: Huangshu 育俞 (俞)**

On the upper abdomen, 0.5 B-cun lateral to the centre of the umbilicus.

**KI16**

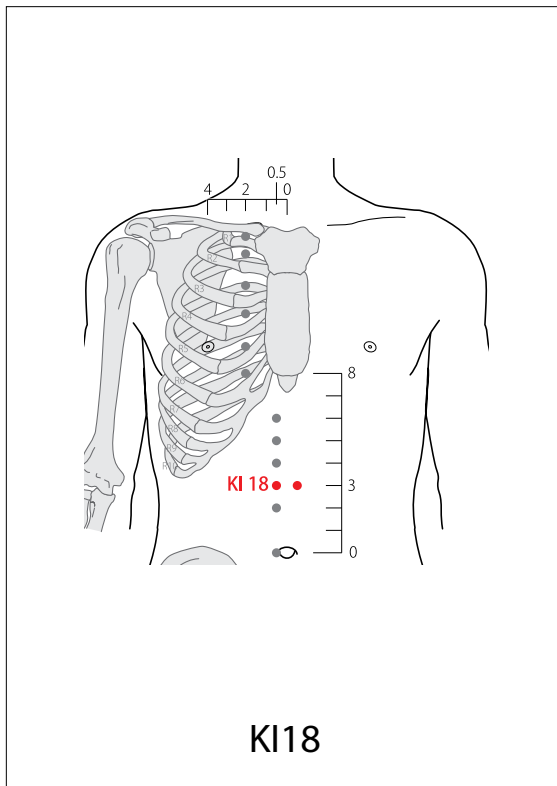
### KI17: Shangqu 商曲

On the upper abdomen, 2 B-cun superior to the centre of the umbilicus, 0.5 B-cun lateral to the anterior median line.



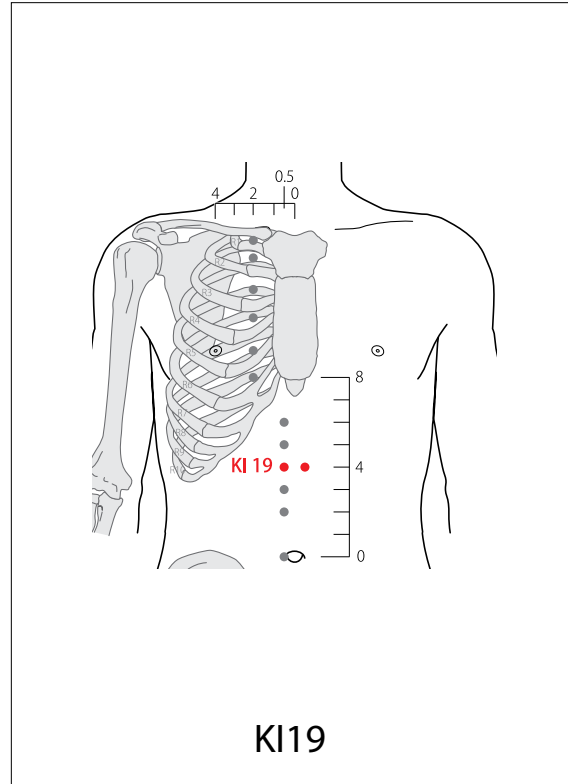
### KI18: Shiguan 石關 (关, 関)

On the upper abdomen, 3 B-cun superior to the centre of the umbilicus, 0.5 B-cun lateral to the anterior median line.

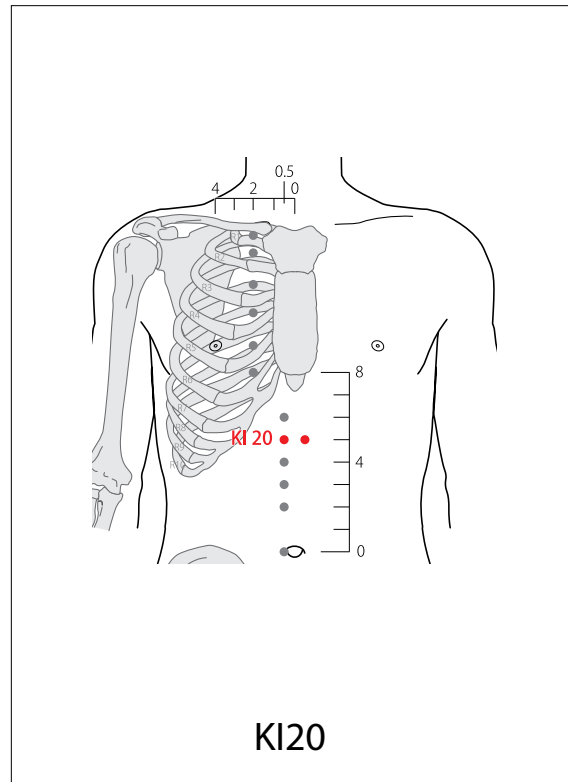


**KI19: Yindu 陰(阴)都(都)**

On the upper abdomen, 4 B-cun superior to the centre of the umbilicus, 0.5 B-cun lateral to the anterior median line.

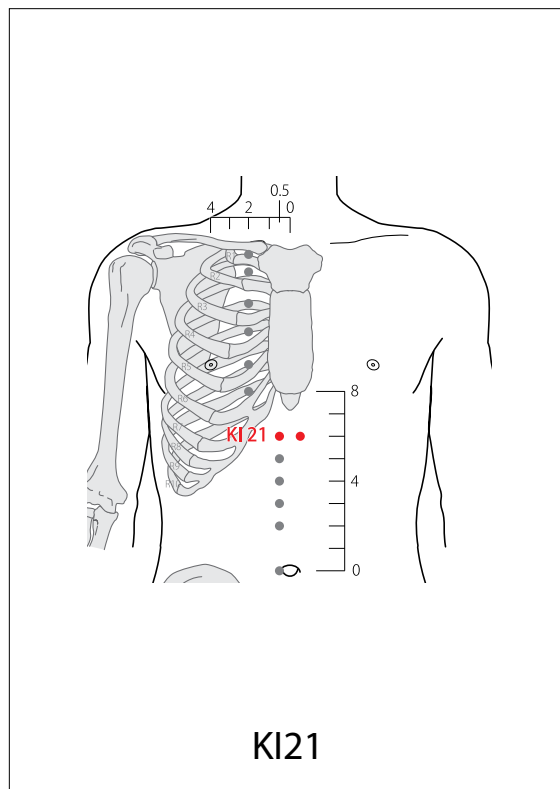
**KI20: Futonggu 腹通(通)谷**

On the upper abdomen, 5 B-cun superior to the centre of the umbilicus, 0.5 B-cun lateral to the anterior median line.



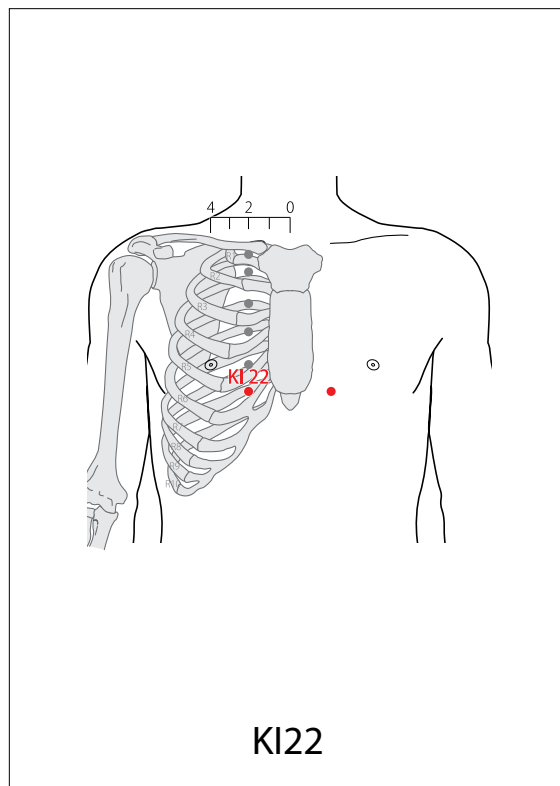
### KI21: Youmen 幽門 (門)

On the upper abdomen, 6 B-cun superior to the centre of the umbilicus, 0.5 B-cun lateral to the anterior median line.



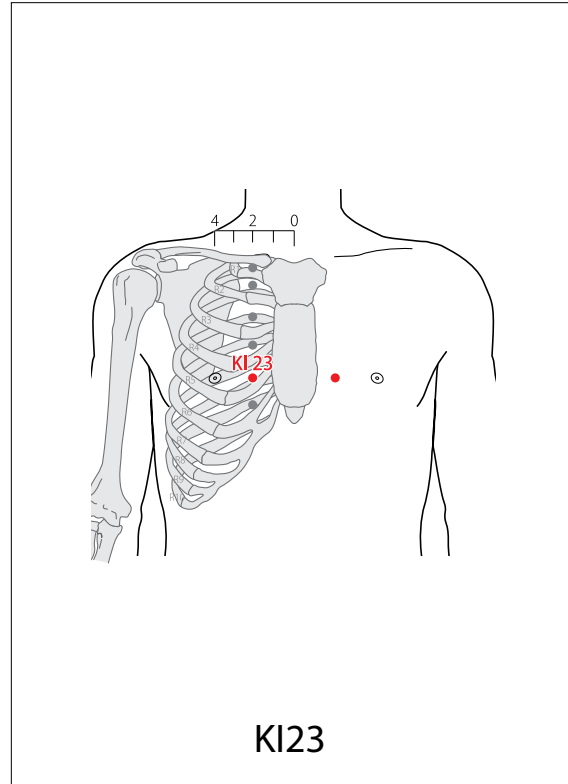
### KI22: Bulang 步 (步) 廊

In the anterior thoracic region, in the fifth intercostal space, 2 B-cun lateral to the anterior median line.

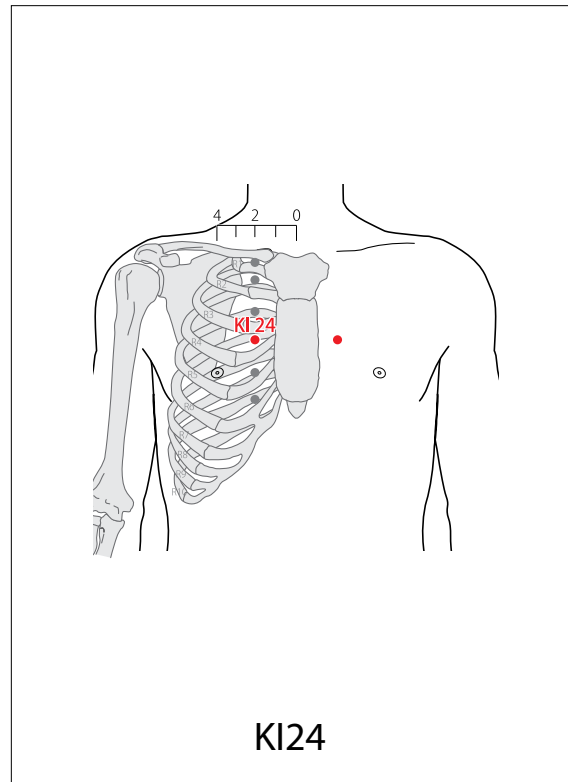


**KI23: Shenfeng 神(神)封**

In the anterior thoracic region, in the fourth intercostal space, 2 B-cun lateral to the anterior median line.

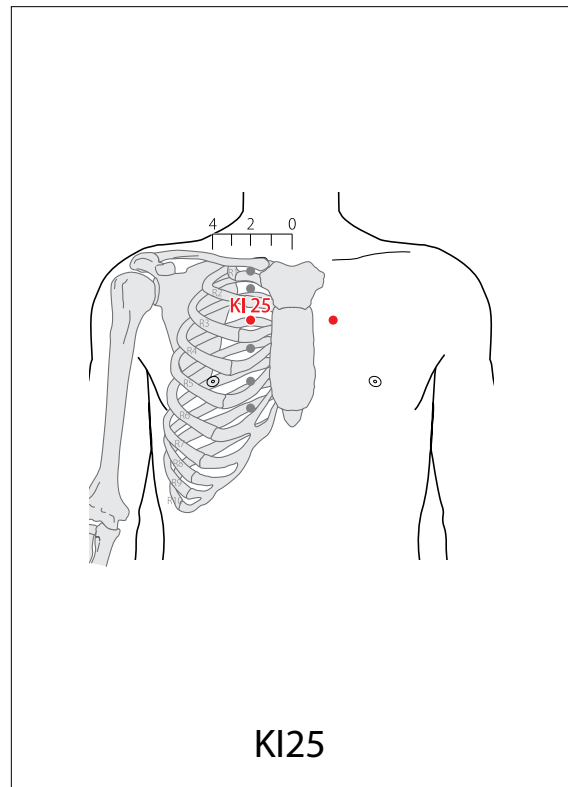
**KI24: Lingxu 靈(灵, 靈)墟(墟)**

In the anterior thoracic region, in the third intercostal space, 2 B-cun lateral to the anterior median line.

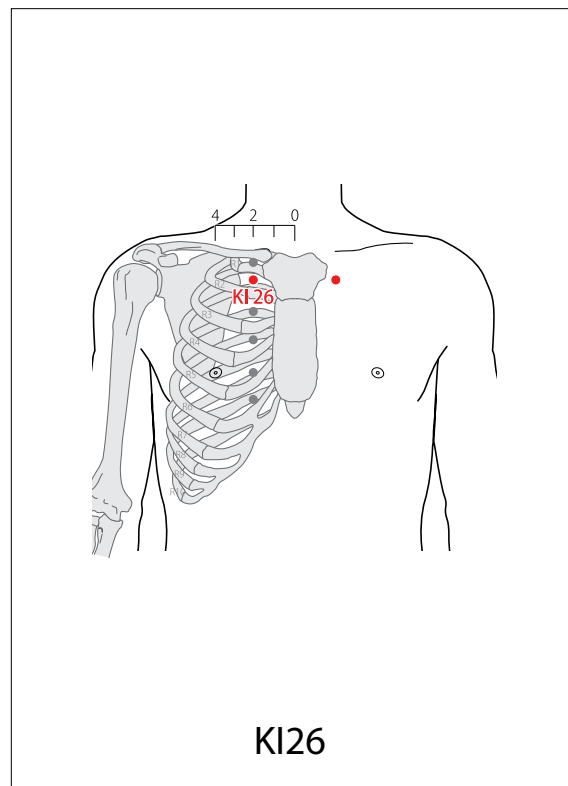


**KI25: Shencang 神(神)藏(藏)**

In the anterior thoracic region, in the second intercostal space, 2 B-cun lateral to the anterior median line.

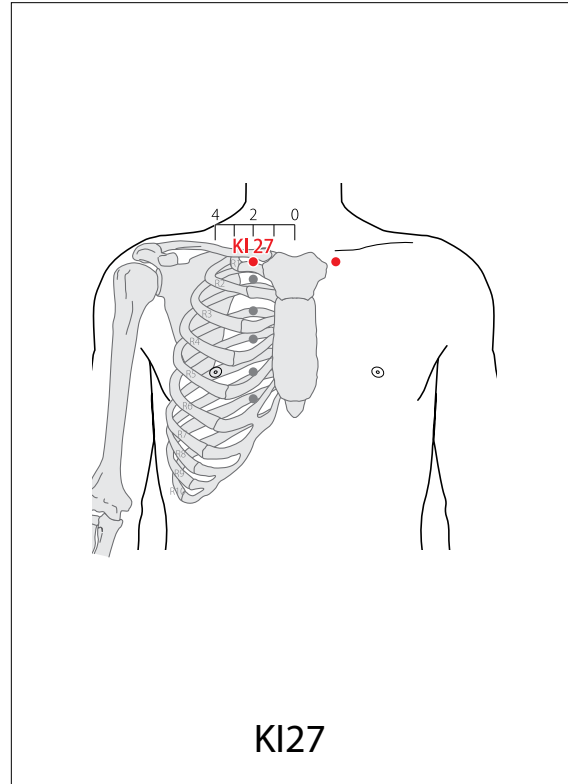
**KI26: Yuzhong 臑中**

In the anterior thoracic region, in the first intercostal space, 2 B-cun lateral to the anterior median line.



**KI27: Shufu 俞(俞)府**

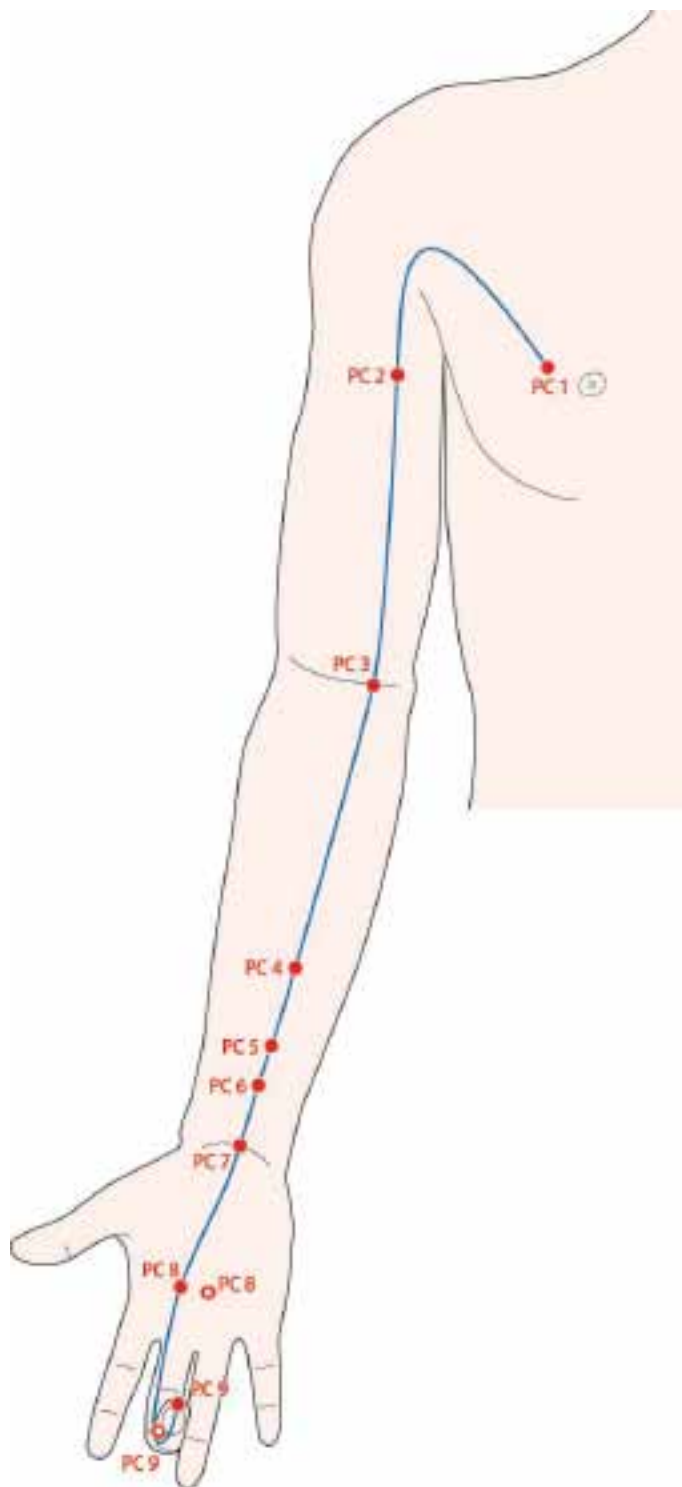
In the anterior thoracic region, just inferior to the clavicle, 2 B-cun lateral to the anterior median line.





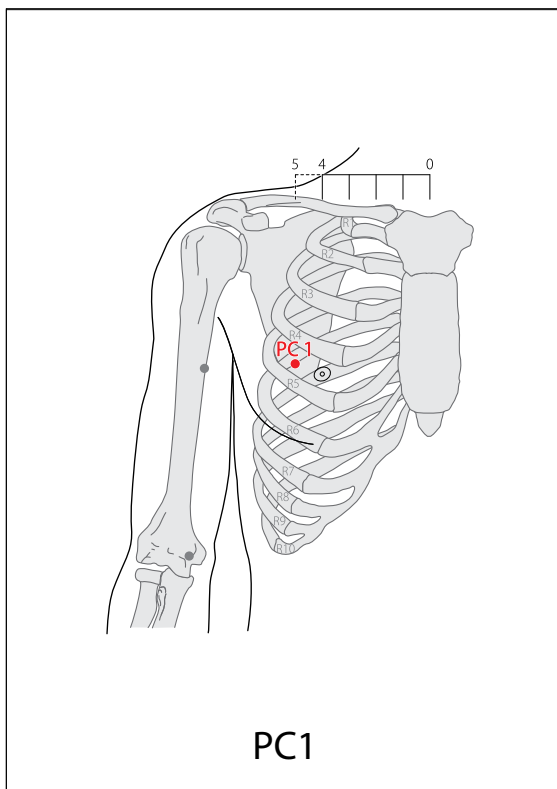
# PERICARDIUM MERIDIAN

手厥陰(阴)心包(包)經(经, 經)



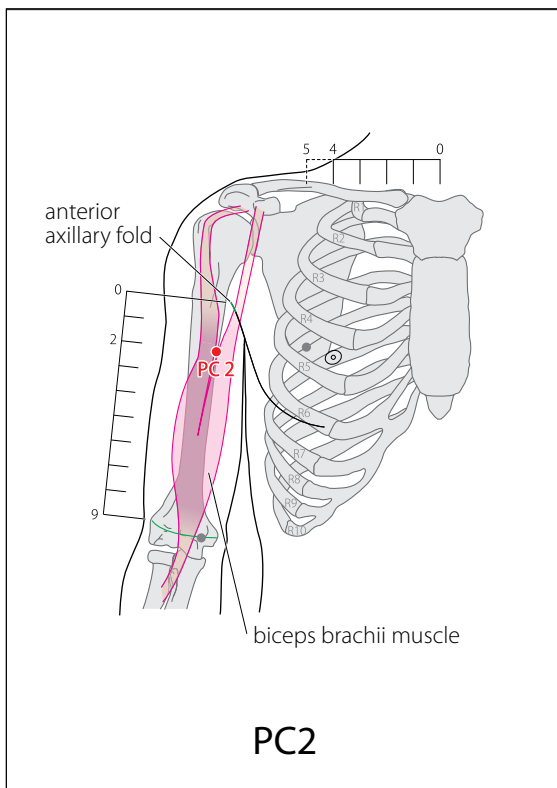
### PC1: Tianchi 天池

In the anterior thoracic region, in the fourth intercostal space, 5 B-cun lateral to the anterior median line.



### PC2: Tianquan 天泉

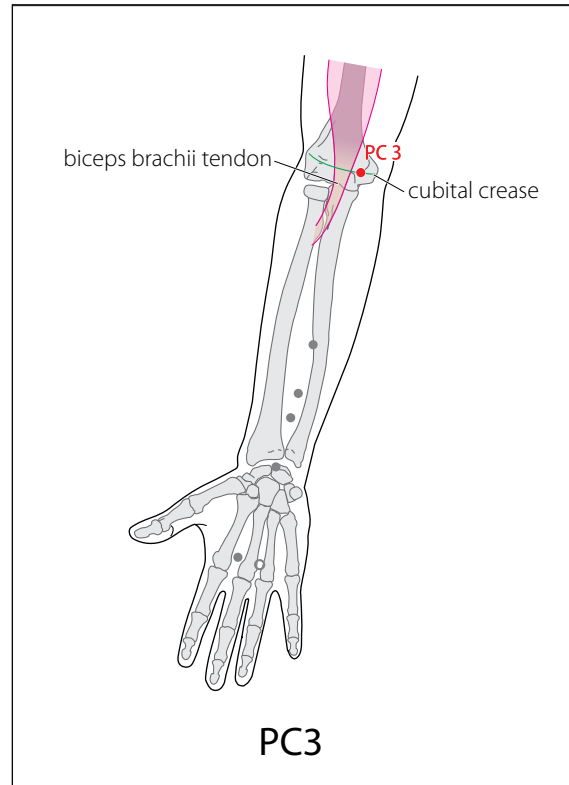
On the anterior aspect of the arm, between the long head and short head of the biceps brachii muscle, 2 B-cun distal to the anterior axillary fold.



### PC3: Quze 曲澤 (泽, 沢)

On the anterior aspect of the elbow, at the cubital crease, in the depression medial to the biceps brachii tendon.

Note: When the elbow is flexed at 45 degrees, PC3 is located medial to the biceps brachii tendon.

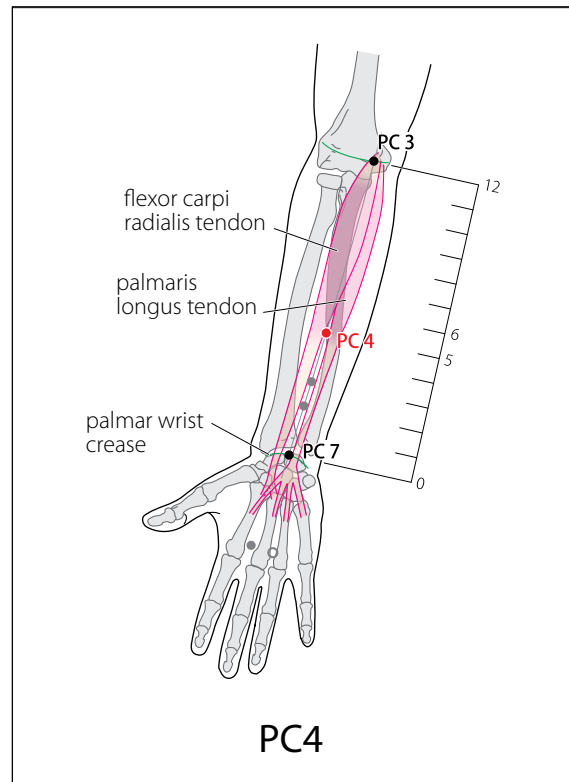


### PC4: Ximen 郄門 (门)

On the anterior aspect of the forearm, between the tendons of the palmaris longus and the flexor carpi radialis, 5 B-cun proximal to the palmar wrist crease.

Note 1: With the fist clenched, the wrist supinated, and the elbow slightly flexed, the two tendons become more prominent. PC4 is located 1 B-cun distal to the midpoint of the line connecting PC3 with PC7.

Note 2: If the palmaris longus tendon is not present, PC4 is medial to the flexor carpi radialis tendon.

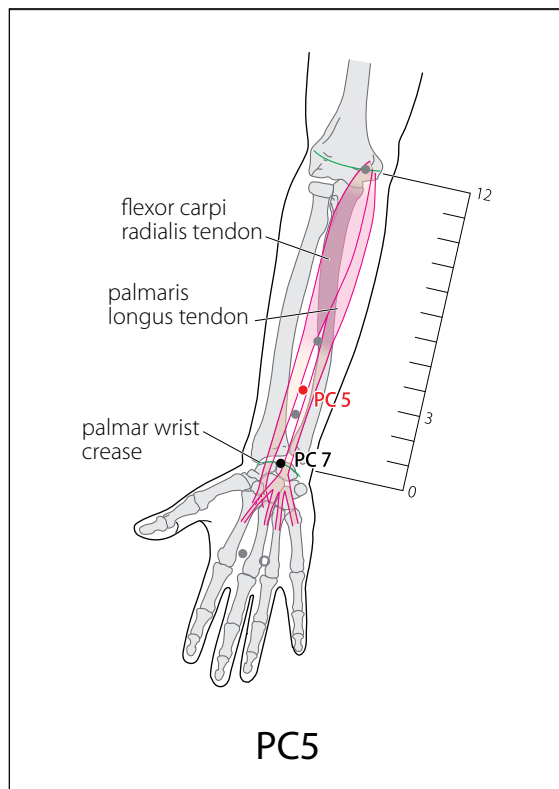


### PC5: Jianshi 間(间)使

On the anterior aspect of the forearm, between the tendons of the palmaris longus and the flexor carpi radialis, 3 B-cun proximal to the palmar wrist crease.

Note 1: With the fist clenched, the wrist supinated and the elbow slightly flexed, the two tendons become more prominent. PC5 is located 3 B-cun proximal to PC7.

Note 2: If the palmaris longus tendon is not present, PC5 is medial to the flexor carpi radialis tendon.

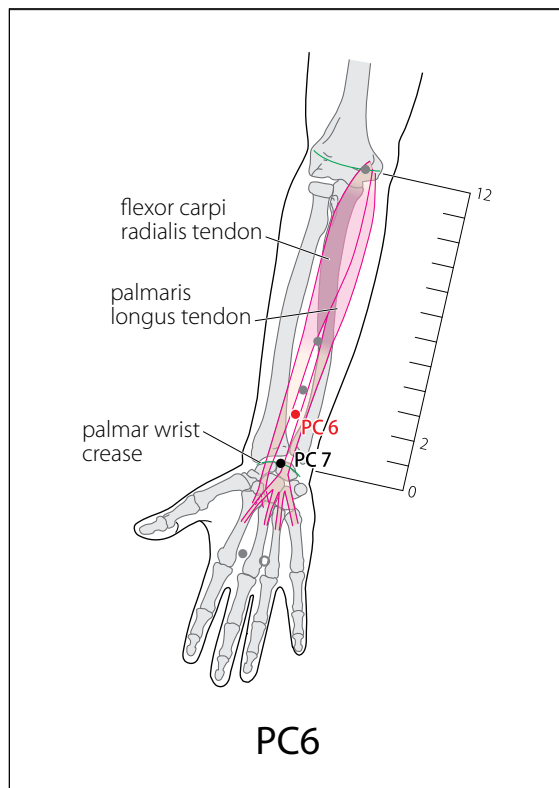


### PC6: Neiguan 内關(关, 関)

On the anterior aspect of the forearm, between the tendons of the palmaris longus and the flexor carpi radialis, 2 B-cun proximal to the palmar wrist crease.

Note 1: With the fist clenched, the wrist supinated and the elbow slightly flexed, the two tendons become more prominent. PC6 is located 2 B-cun proximal to PC7. The posterial point corresponding to PC6 is TE5.

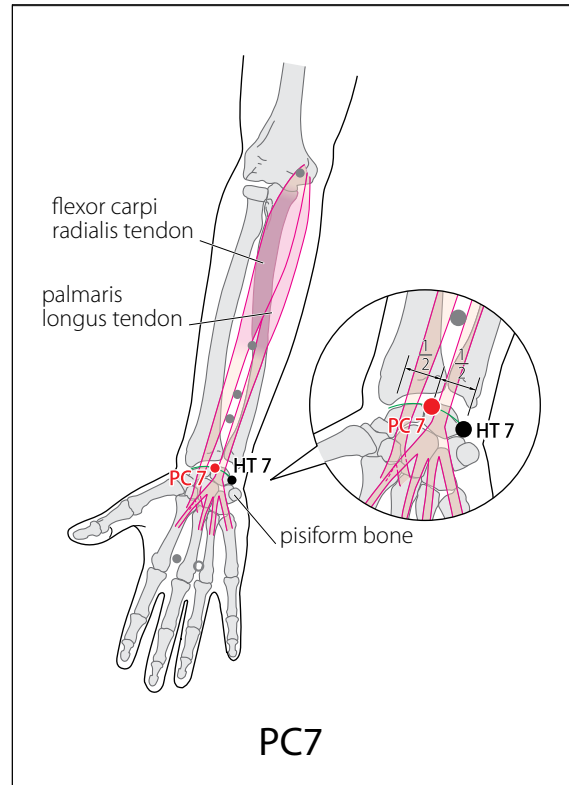
Note 2: If the palmaris longus tendon is not present, PC6 is medial to the flexor carpi radialis tendon.



### PC7: Daling 大陵

On the anterior aspect of the wrist, between the tendons of palmaris longus and the flexor carpi radialis, on the palmar wrist crease.

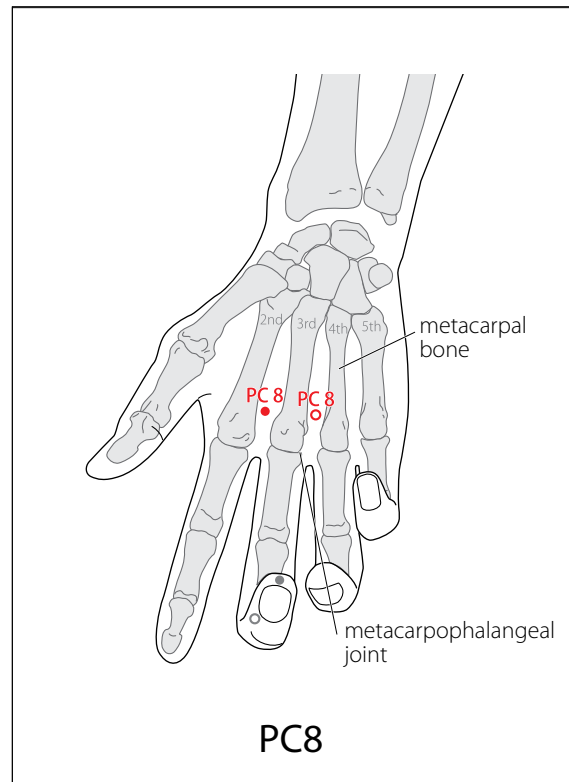
Note: With the fist clenched, the wrist slightly flexed, the two tendons become more prominent. PC7 is located at the midpoint of the palmar wrist crease, between the tendons of palmaris longus and the flexor carpi radialis, at the same level as HT7, at the proximal extremity of the pisiform bone.



### PC8: Laogong 勞(勞, 勞)宮(宮)

On the palm of the hand, in the depression between the second and third metacarpal bones, proximal to the metacarpophalangeal joints.

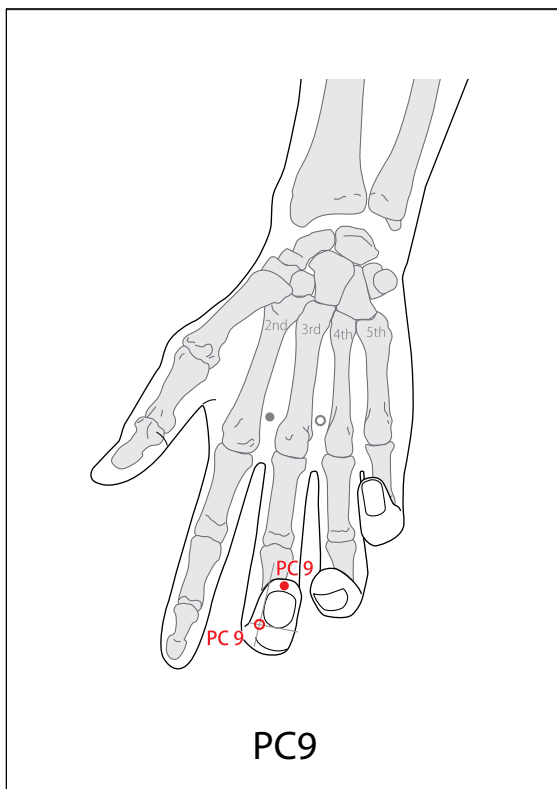
Remarks: Alternative location for PC8 - On the palm of the hand, in the depression, between the third and fourth metacarpal bones, proximal to the metacarpophalangeal joints.



### PC9: Zhongchong 中衝 (冲)

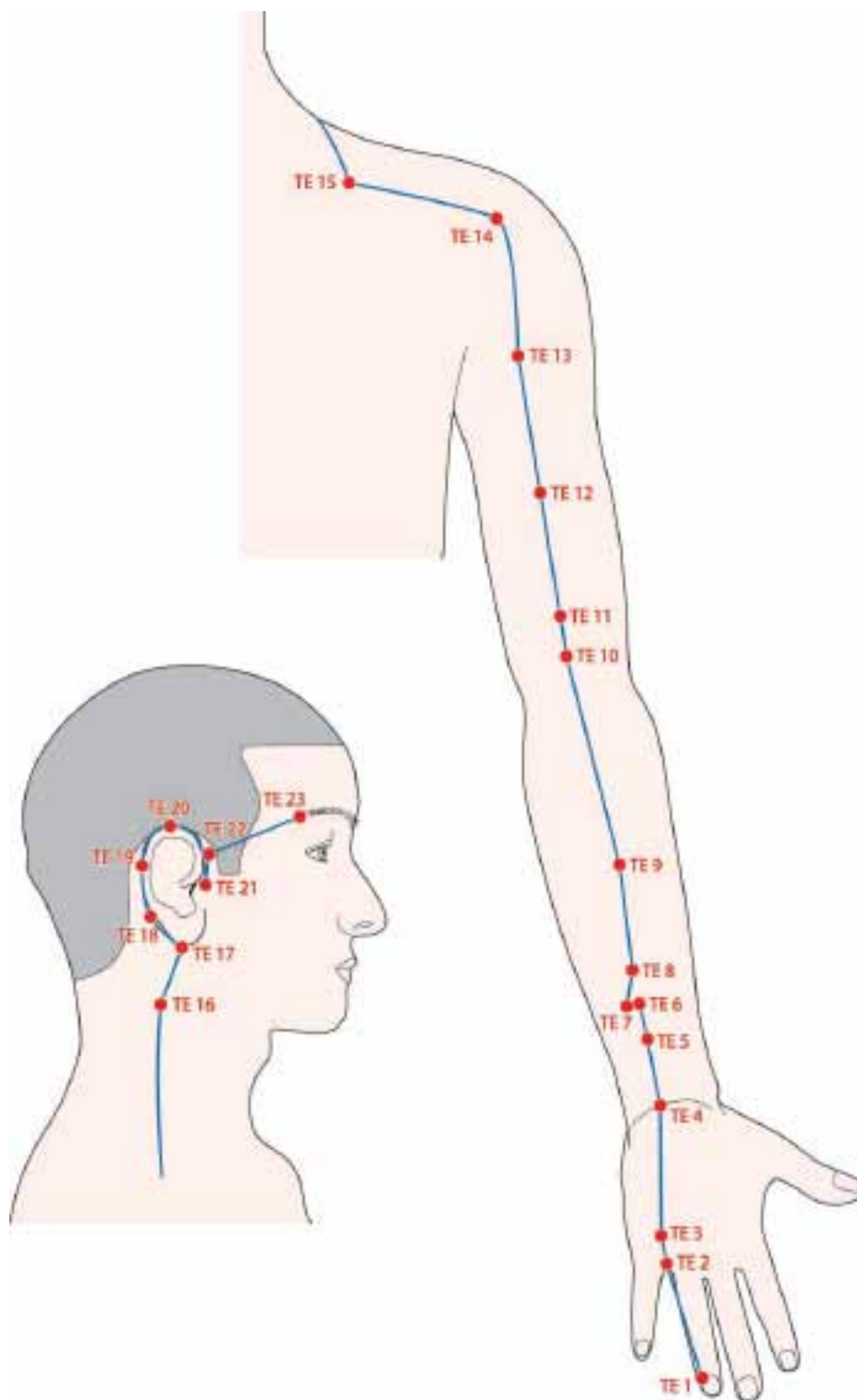
On the middle finger, at the centre of the tip of the middle finger.

Remarks: Alternative location for PC9 -  
On the middle finger, 0.1 F-cun proximal to the radial corner of the middle fingernail, at the intersection of the vertical line of the radial side of the nail and the horizontal line of the base of the fingernail.



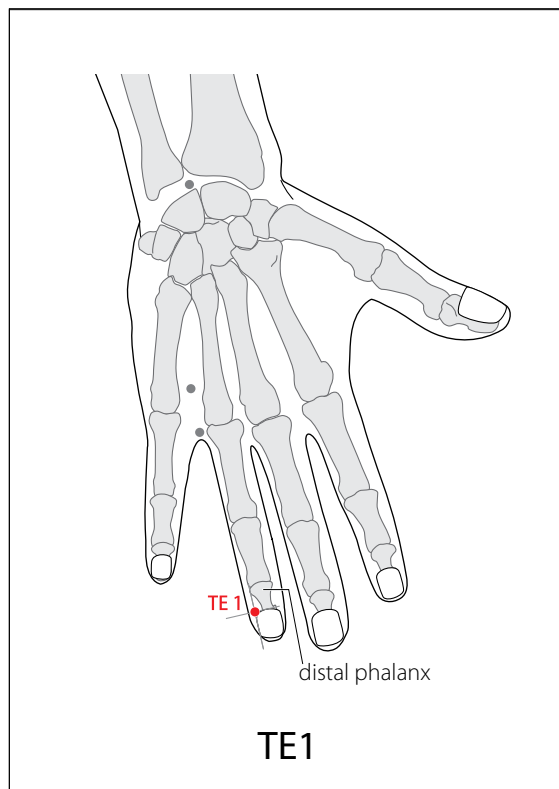
## TRIPLE ENERGIZER MERIDIAN

手少陽(阳)三焦經(经, 經)



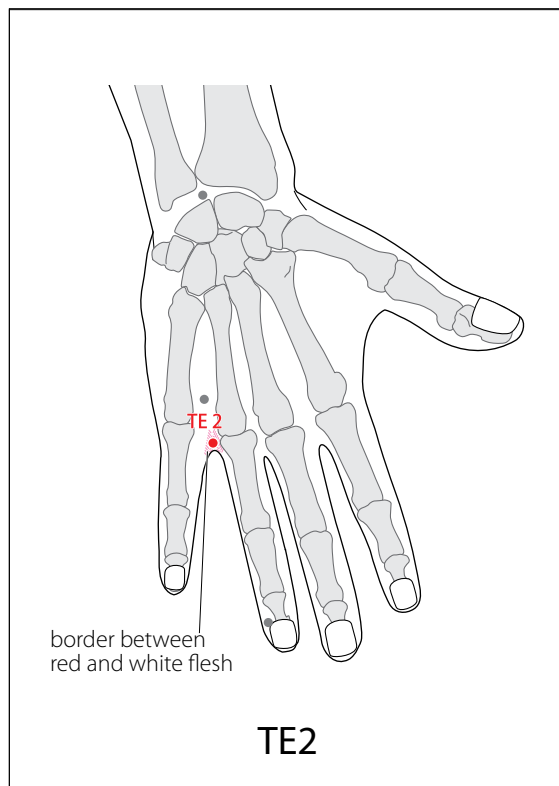
### TE1: Guanchong 關(关, 関)衝(冲)

On the ring finger, ulnar to the distal phalanx, 0.1 F-cun proximal to the ulnar corner of the fingernail, at the intersection of the vertical line of the ulnar side of the nail and the horizontal line of the base of the fingernail.



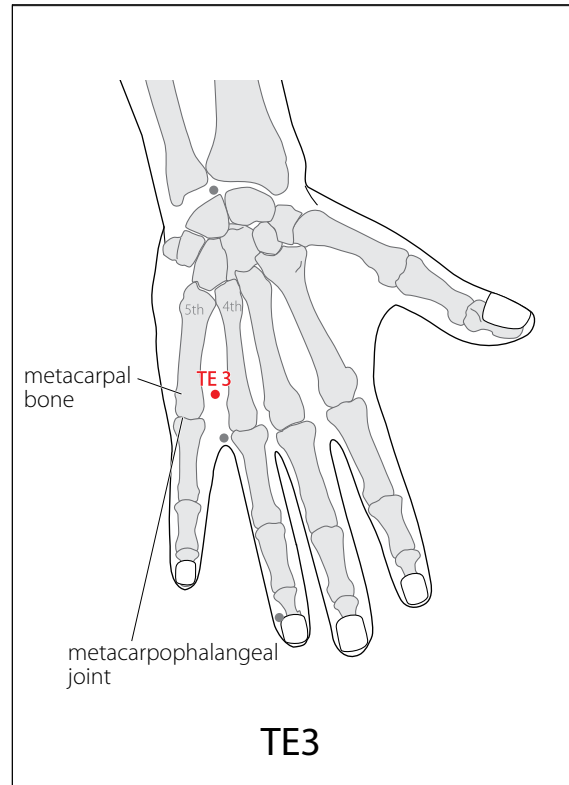
### TE2: Yemen 液門(门)

On the dorsum of the hand, in the depression superior to the web margin between the ring and little fingers, at the border between the red and white flesh.



### TE3: Zhongzhu 中渚 (渚)

On the dorsum of the hand, between the fourth and fifth metacarpal bones, in the depression proximal to the fourth metacarpophalangeal joint.

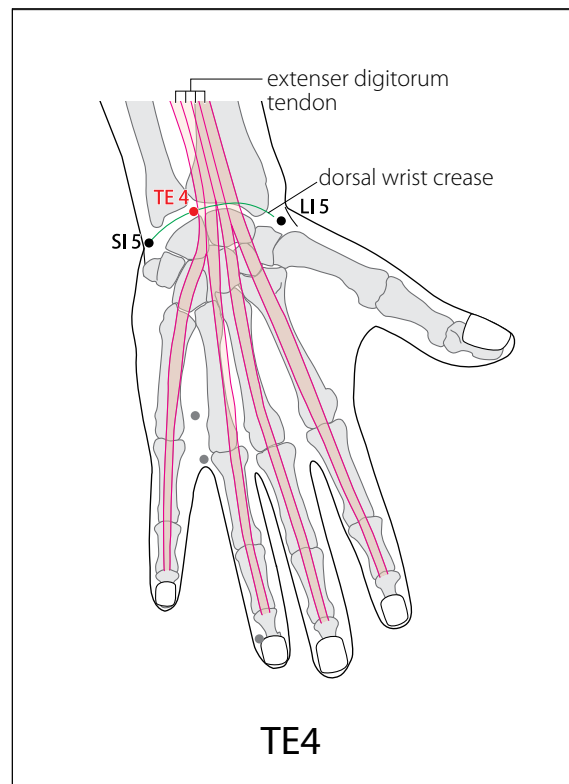


### TE4: Yangchi 陽 (阳) 池

On the posterior aspect of the wrist, in the depression ulnar to the extensor digitorum tendon, on the dorsal wrist crease.

Note 1: TE4 can be palpated when moving proximally along the gap between the fifth and fourth metacarpal bones, at the same level as LI5 and SI5.

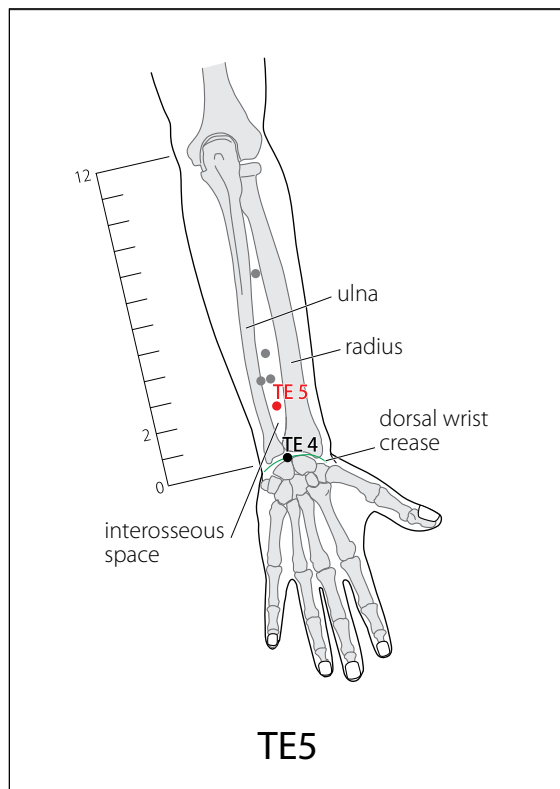
Note 2: When the wrist is extended against resistance, the extensor digitorum tendon can be palpated more easily.



### TE5: Waiguan 外關 (关, 関)

On the posterior aspect of the forearm, midpoint of the interosseous space between the radius and the ulna, 2 B-cun proximal to the dorsal wrist crease.

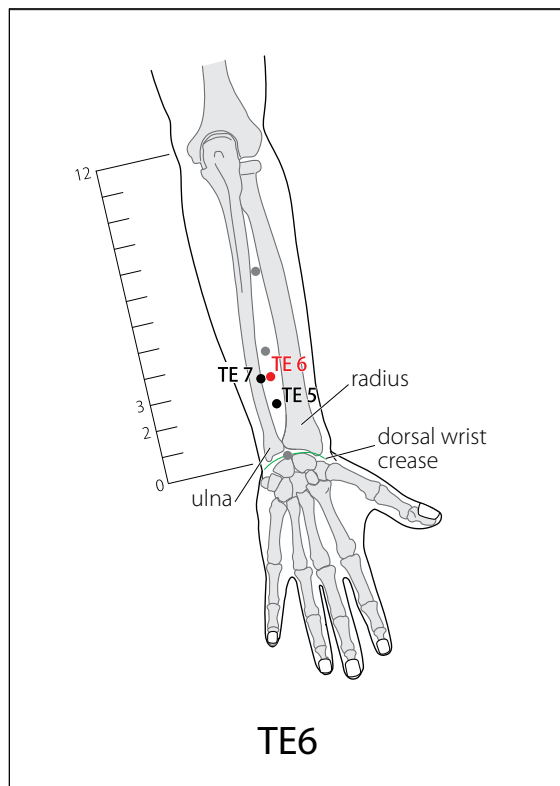
Note: 2 B-cun proximal to TE4, in the depression between the radius and the ulna. The anterior point corresponding to TE5 is PC6.



### TE6: Zhigou 支溝 (沟)

On the posterior aspect of the forearm, midpoint of the interosseous space between the radius and the ulna, 3 B-cun proximal to the dorsal wrist crease.

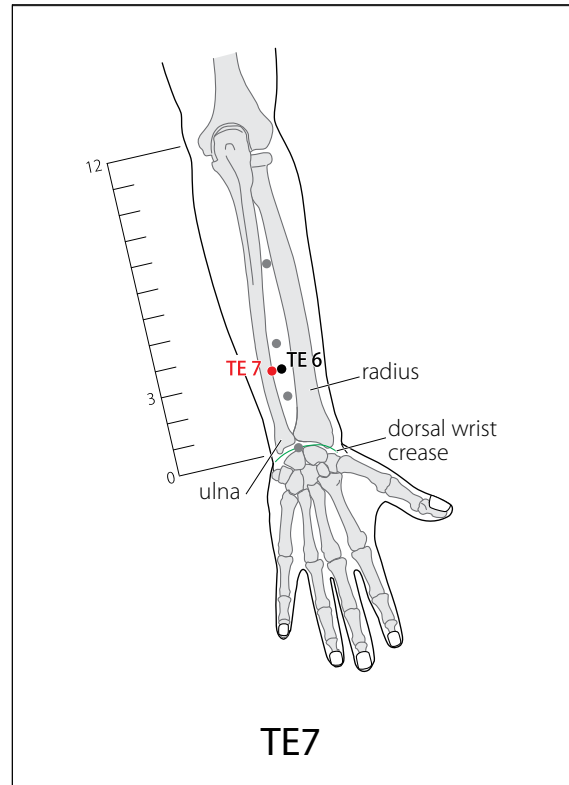
Note: 1 B-cun proximal to TE5, between the radius and the ulna, at the same level as TE7.



### TE7: Huizong 會(会)宗

On the posterior aspect of the forearm, just radial to the ulna, 3 B-cun proximal to the dorsal wrist crease.

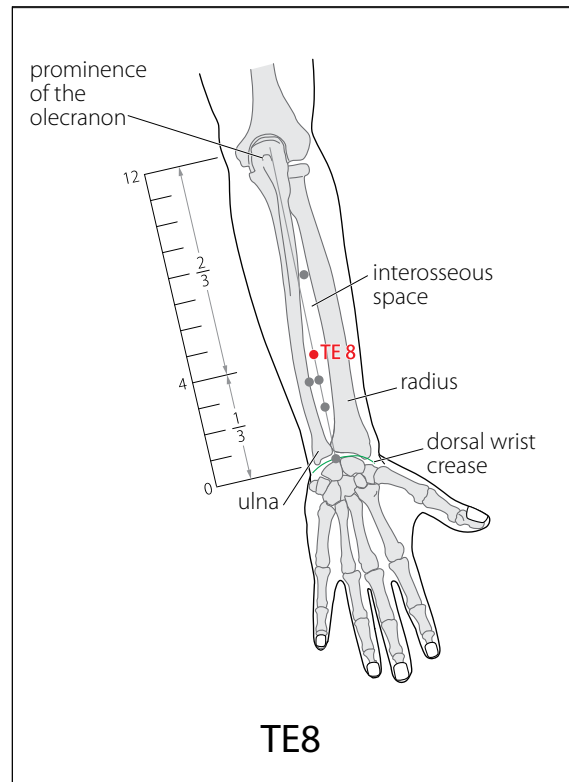
Note: TE7 is ulnar to TE6.



### TE8: Sanyangluo 三陽(阳)絡(络)

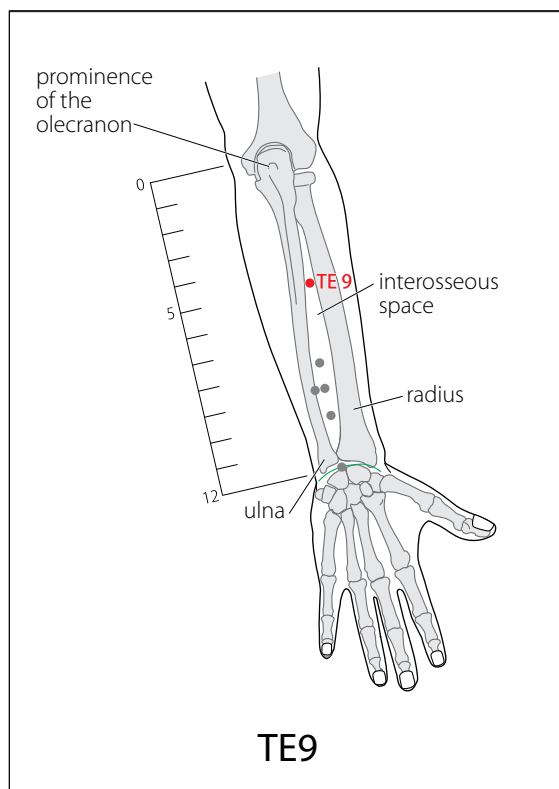
On the posterior aspect of the forearm, midpoint of the interosseous space between the radius and the ulna, 4 B-cun proximal to the dorsal wrist crease.

Note: At the junction of the upper two thirds and lower one third of the line connecting TE4 with the tip of the elbow.



## TE9: Sidu 四瀆 (渎)

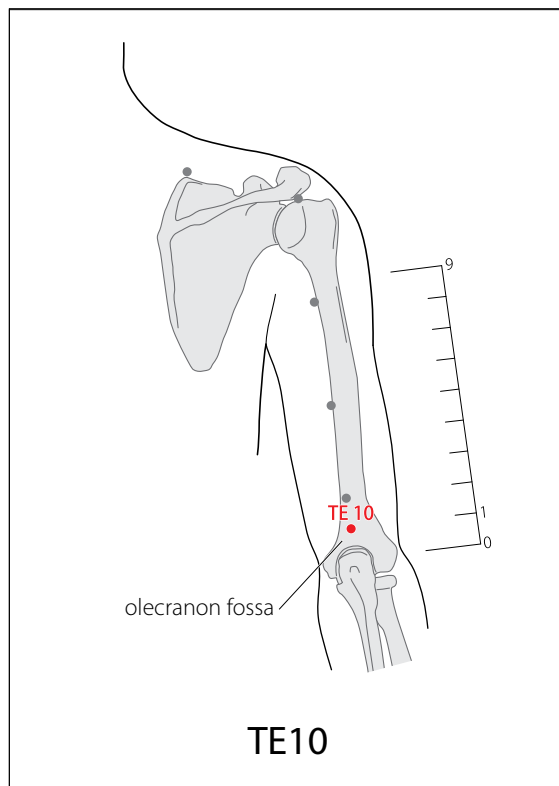
On the posterior aspect of the forearm, midpoint of the interosseous space between the radius and the ulna, 5 B-cun distal to the prominence of the olecranon.



## TE10: Tianjing 天井

On the posterior aspect of the elbow, in the depression 1 B-cun proximal to the prominence of the olecranon.

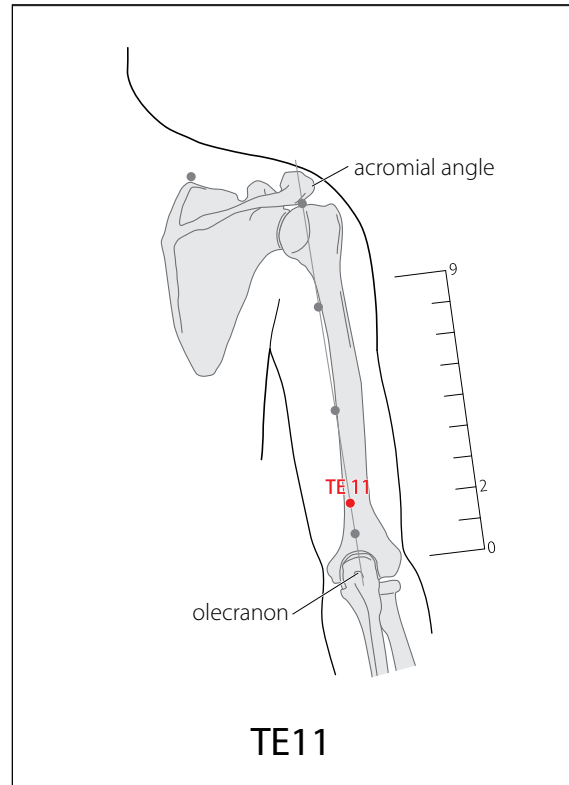
Note: When the elbow is flexed, TE10 is located in the olecranon fossa.



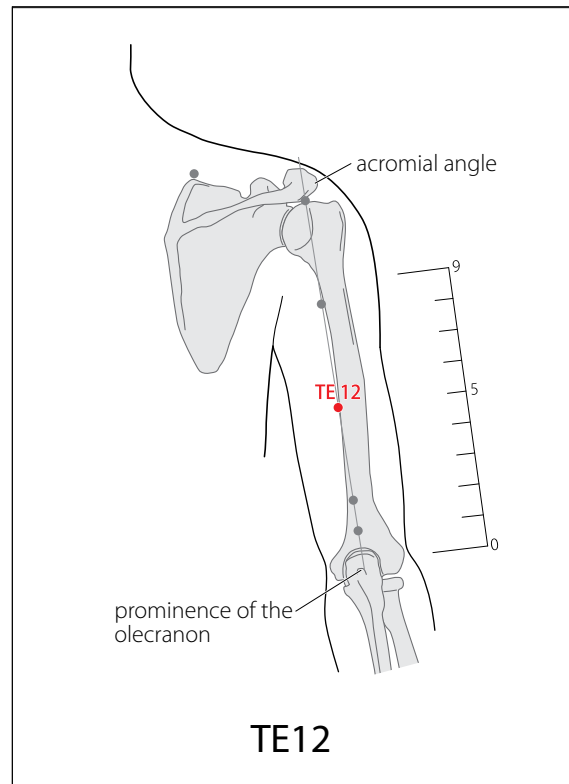
**TE11: Qinglengyuan 清(清)冷(令)淵(渊)**

On the posterior aspect of the arm, on the line connecting the prominence of olecranon with the acromial angle, 2 B-cun proximal to the prominence of the olecranon.

Note: With the elbow extended, 2 B-cun superior to the prominence of the olecranon.

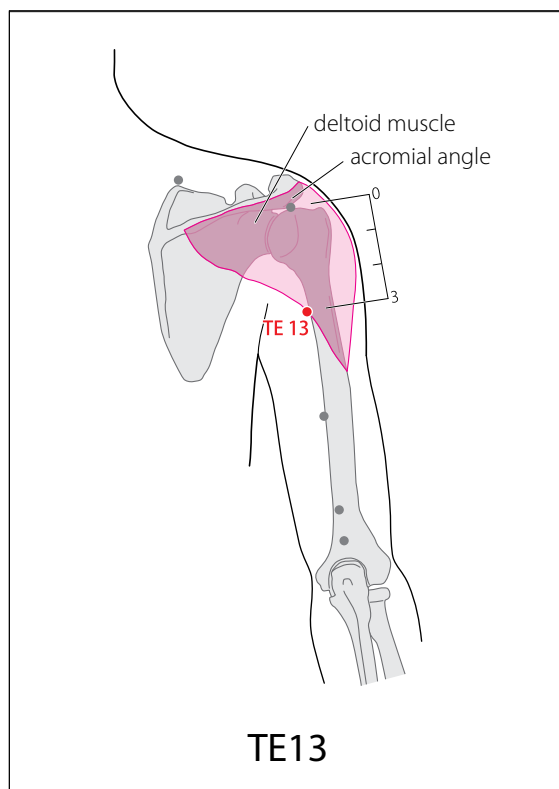
**TE12: Xiaoluo 消瀾(冻)**

On the posterior aspect of the arm, on the line connecting the prominence of the olecranon with the acromial angle, 5 B-cun proximal to the prominence of the olecranon.



## TE13: Naohui 臑會(会)

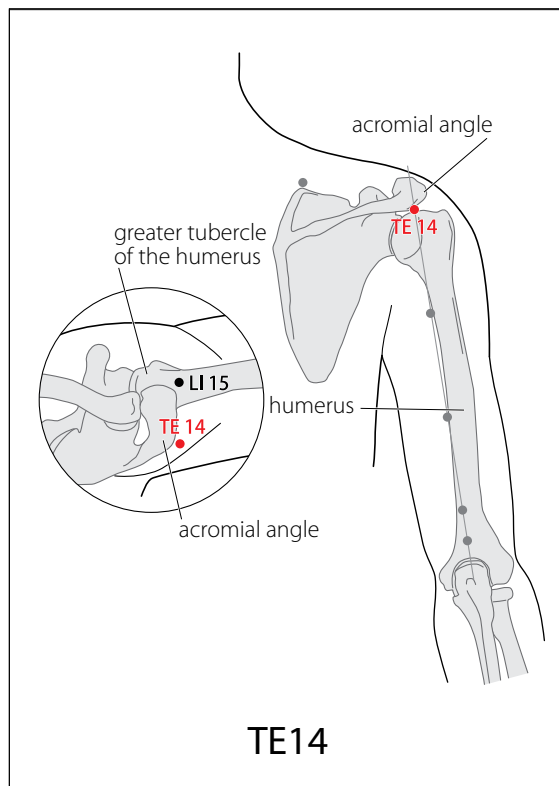
On the posterior aspect of the arm, postero-inferior to the border of the deltoid muscle, 3 B-cun inferior to the acromial angle.



## TE14: Jianliao 肩髃(髃)

On the shoulder girdle, in the depression between the acromial angle and the greater tubercle of the humerus.

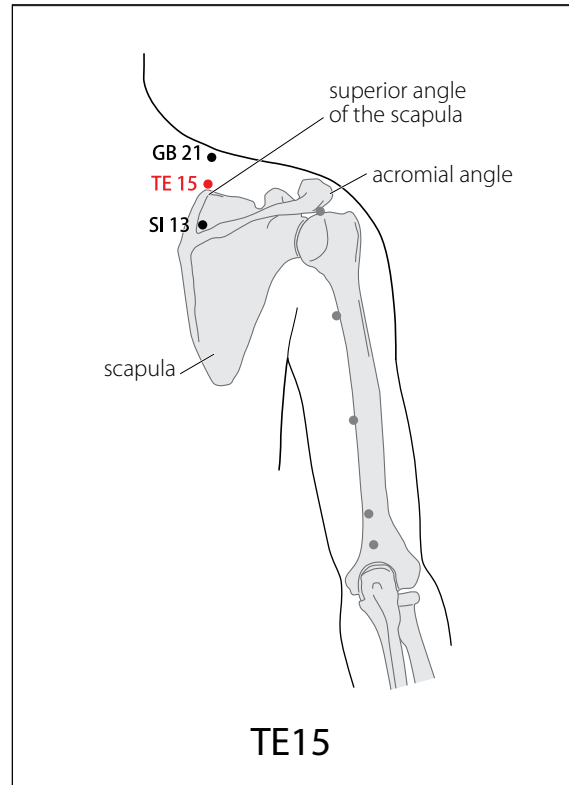
Note: When the elbow is flexed and the arm is abducted, two depressions appear respectively anterior and posterior to the acromion. LI15 is located in the anterior one, deeper than the posterior one, in which TE14 is located.



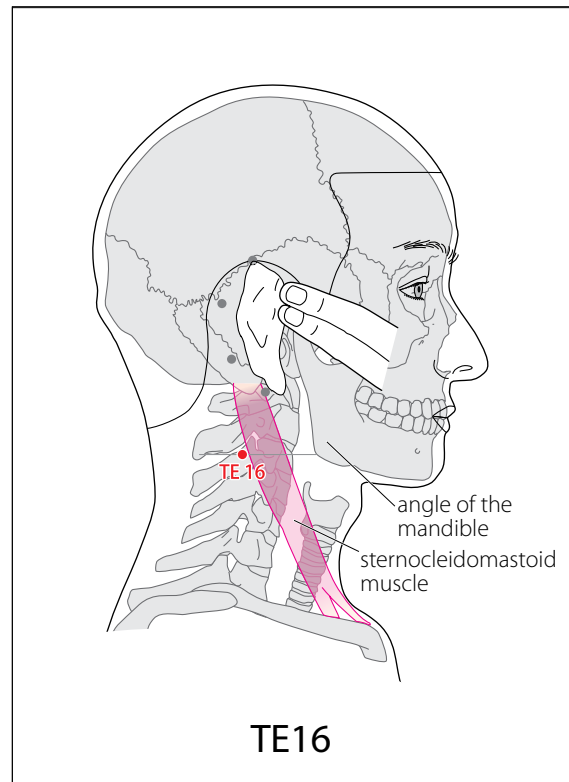
**TE15: Tianliao 天髎(髎)**

In the scapular region, in the depression superior to the superior angle of the scapula.

Note: With the upper limb hanging by the side of trunk in a seated position, TE15 is located midway between GB21 and SI13.

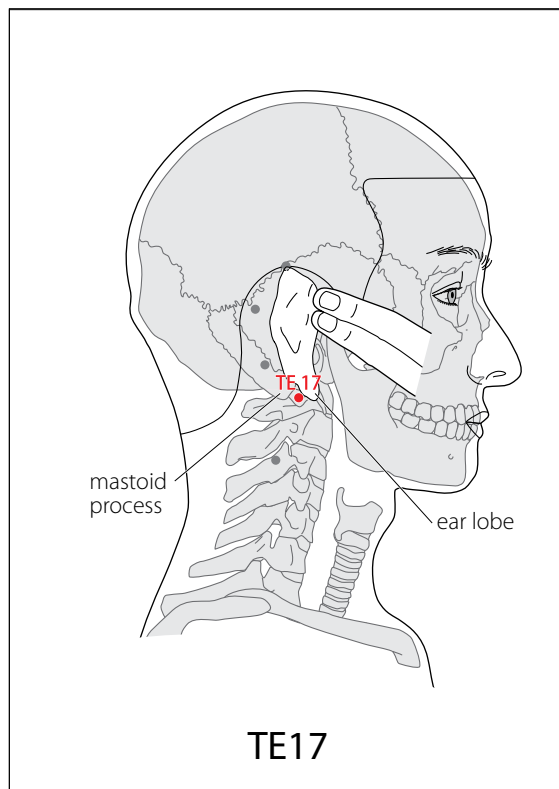
**TE16: Tianyou 天牖**

In the anterior region of the neck, at the same level as the angle of the mandible, in the depression posterior to the sternocleidomastoid muscle.



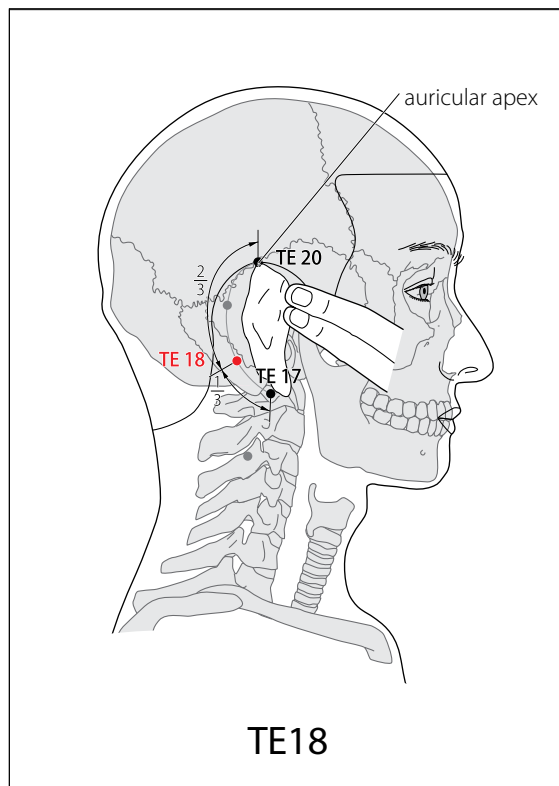
### TE17: Yifeng 翳風 (风)

In the anterior region of the neck, posterior to the ear lobe, in the depression anterior to the inferior end of the mastoid process.



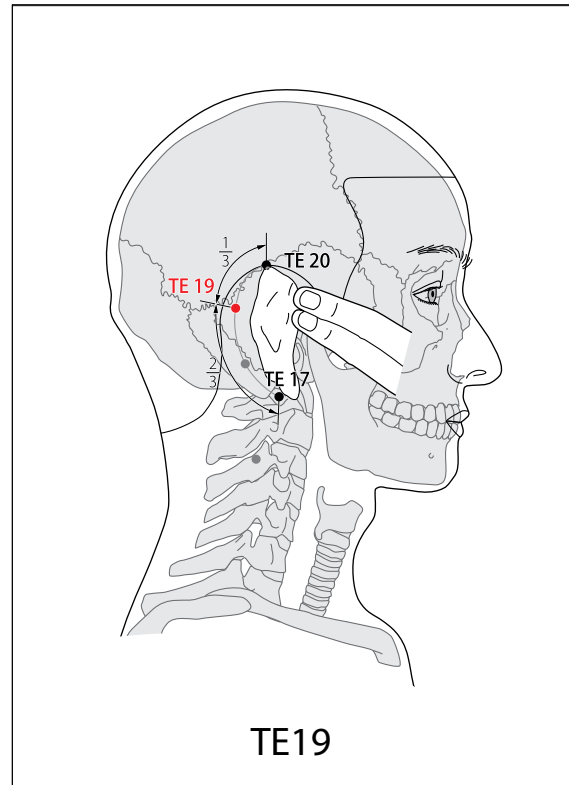
### TE18: Chimai (Qimai) 瘕脈 (脉)

On the head, at the centre of the mastoid process, at the junction of the upper two thirds and lower one third of the curved line from TE17 to TE20.



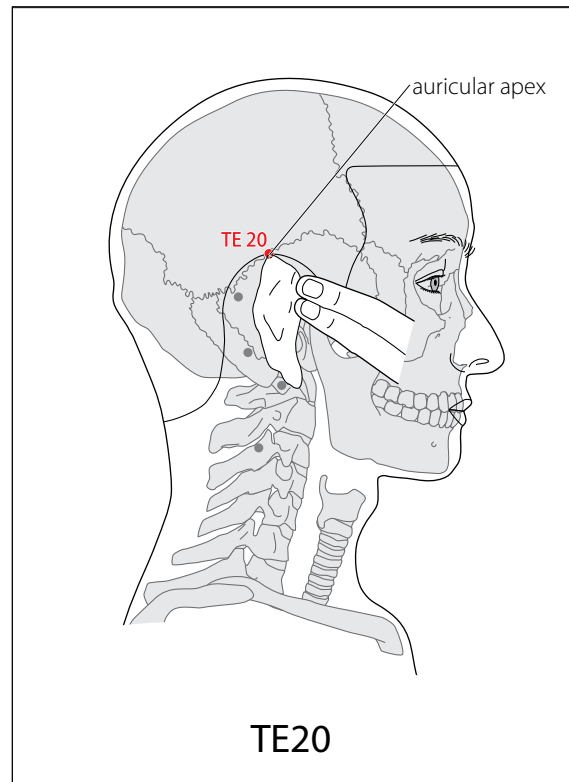
**TE19: Luxi 顙(頤)息**

On the head, at the junction of the upper one third and lower two thirds of the curved line from TE17 to TE20.

**TE20: Jiaosun 角孫(孫)**

On the head, just superior to the auricular apex.

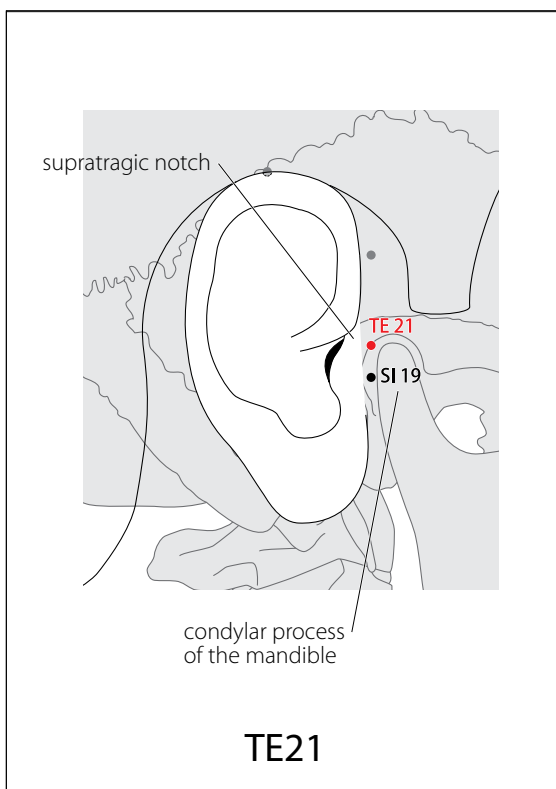
Note: With the auricle folded forward and pressed against the head, the point is located where the auricular apex touches the head.



## TE21: Ermen 耳門(門)

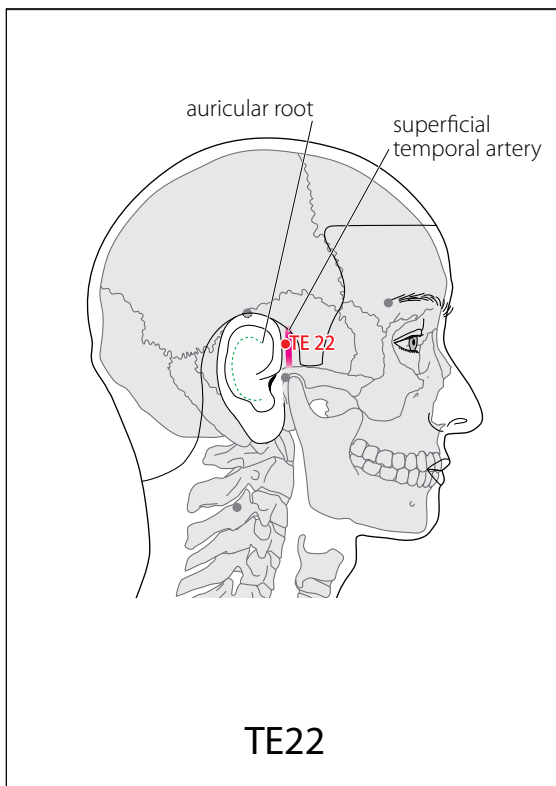
On the face, in the depression between the supratragic notch and the condylar process of the mandible.

Note: When the mouth is slightly opened, TE21 is located in the depression anterior to the supratragic notch, directly superior to SI19.



## TE22: Erheliao 耳和髎(髎)

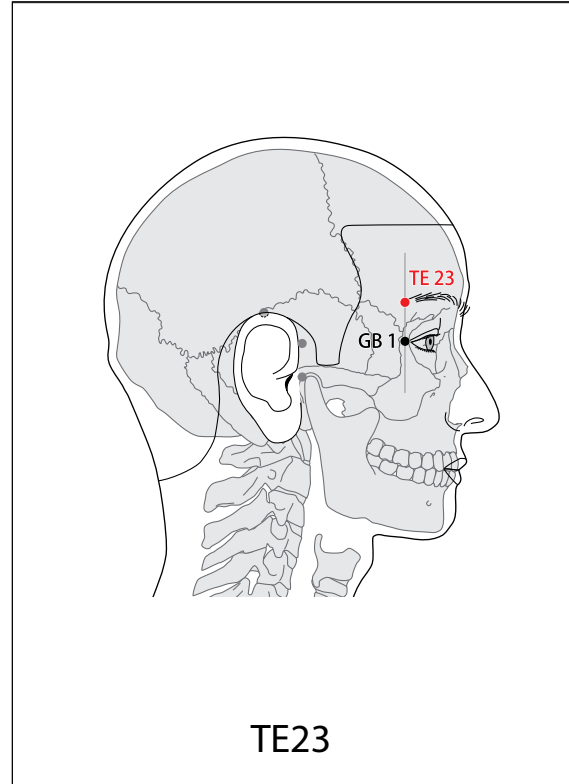
On the head, posterior to the temple hair-line, anterior to the auricular root, posterior to the superficial temporal artery.



**TE23: Sizhukong 絲(丝)竹空**

On the head, in the depression at the lateral end of the eyebrow.

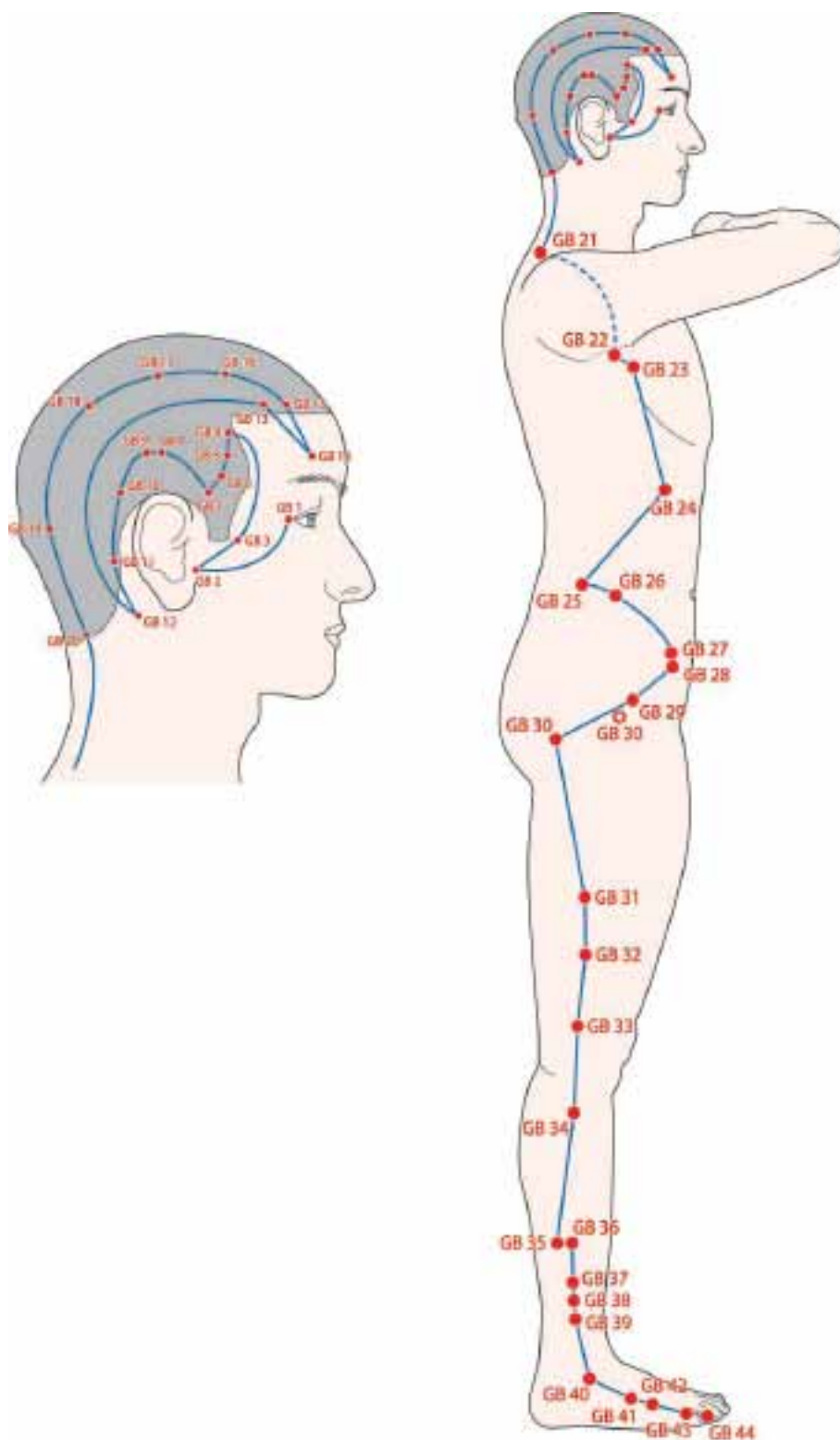
Note: TE23 is superior to GB1.





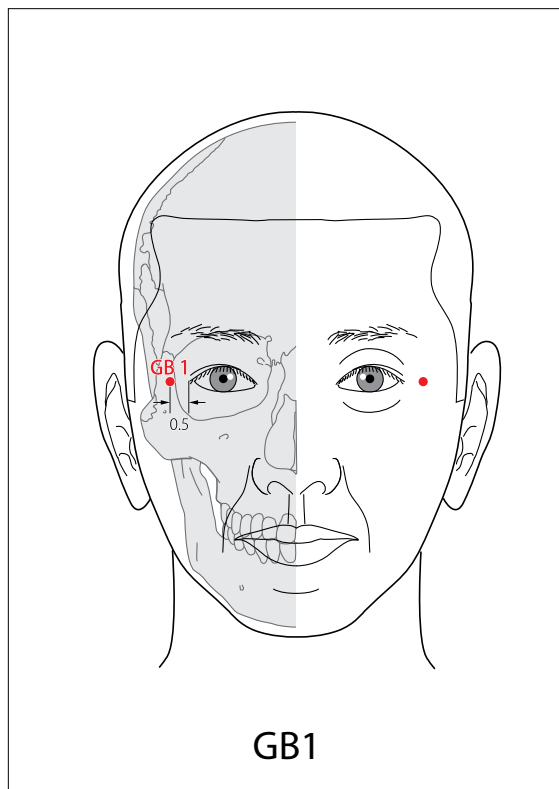
# GALLBLADDER MERIDIAN

## 足少陽(阳)膽(胆)經(经, 經)



### GB1: Tongziliao 瞳子髎(髎)

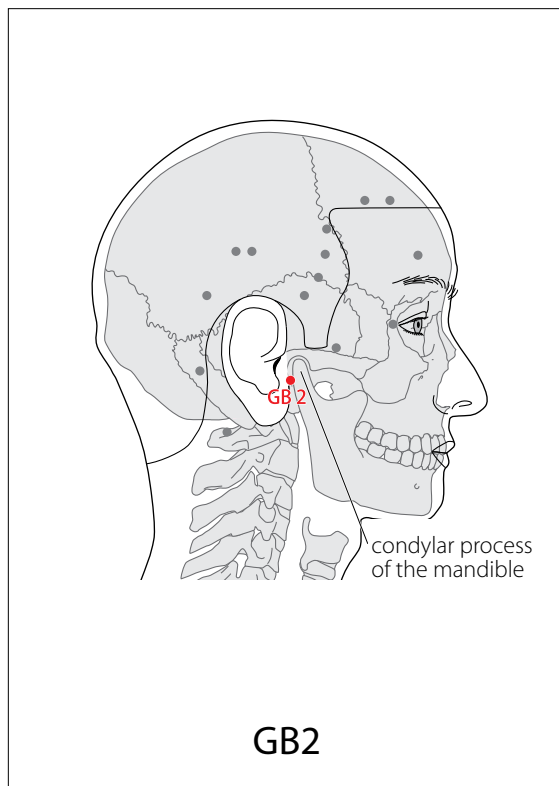
On the head, in the depression, 0.5 B-cun lateral to the outer canthus of the eye.



### GB2: Tinghui 聽(听, 聽)會(会)

On the face, in the depression between the intertragic notch and the condylar process of the mandible.

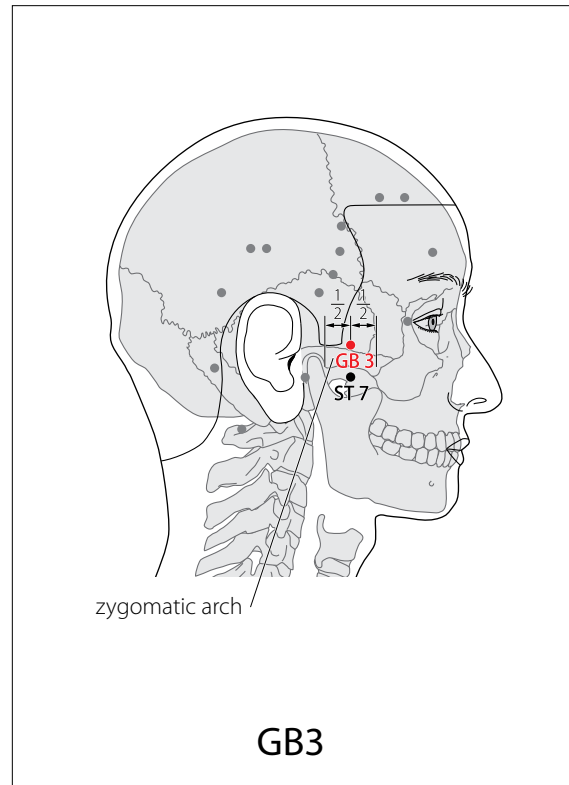
Note: When the mouth is opened, GB2 is located in the depression anterior to the intertragic notch.



### GB3: Shangguan 上關(关, 関)

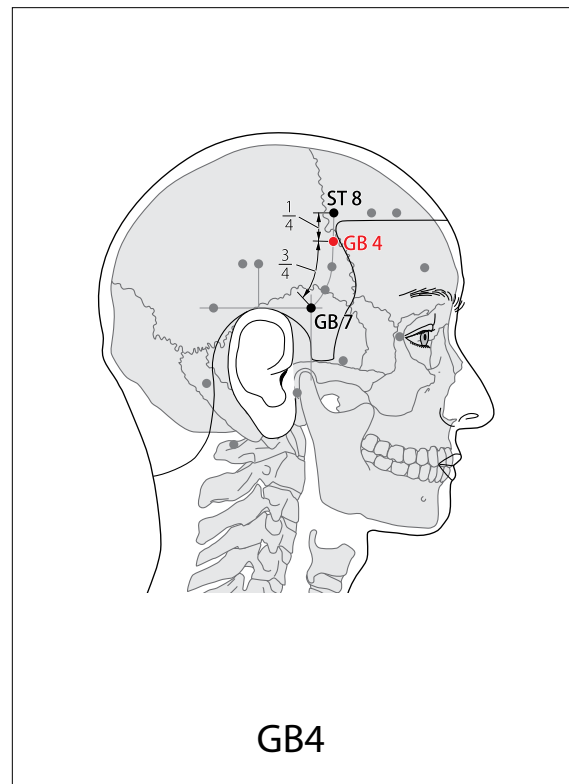
On the head, in the depression superior to the midpoint of the zygomatic arch

Note: In the depression superior to the zygomatic arch, superior to ST7.



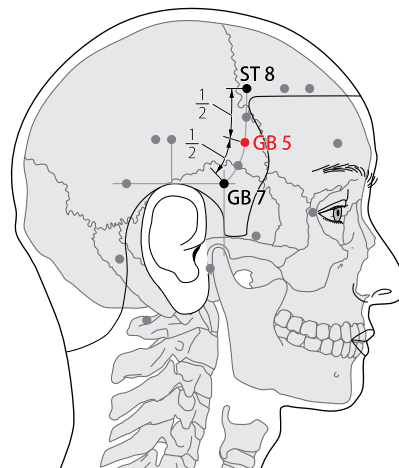
### GB4: Hanyan 頤(頤)厭(厌)

On the head, at the junction of the upper one fourth and lower three fourths of the curved line from ST8 to GB7.



### GB5: Xuanlu 懸(悬)顛(颠)

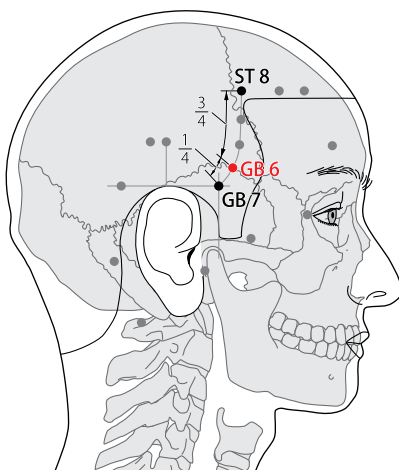
On the head, at the midpoint of the curved line from ST8 to GB7.



GB5

### GB6: Xuanli 懸(悬)釐(厘)

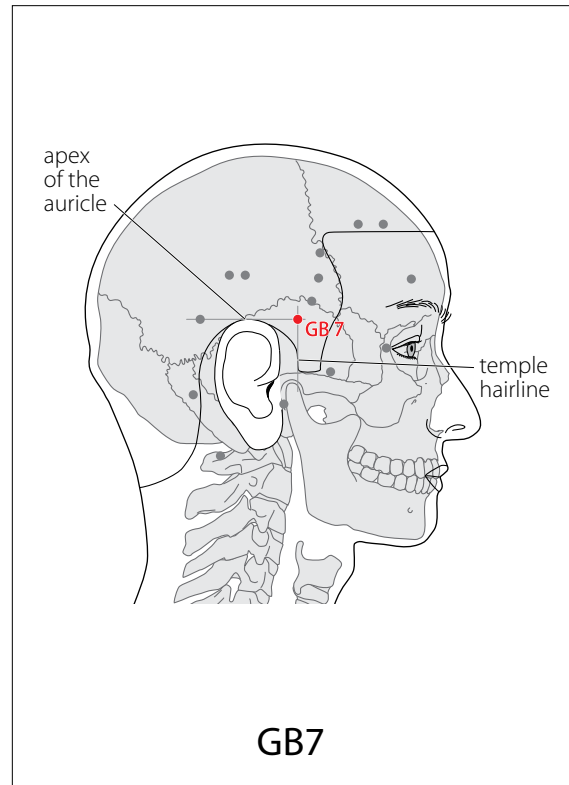
On the head, at the junction of the upper three fourths and lower one fourth of the curved line from ST8 to GB7.



GB6

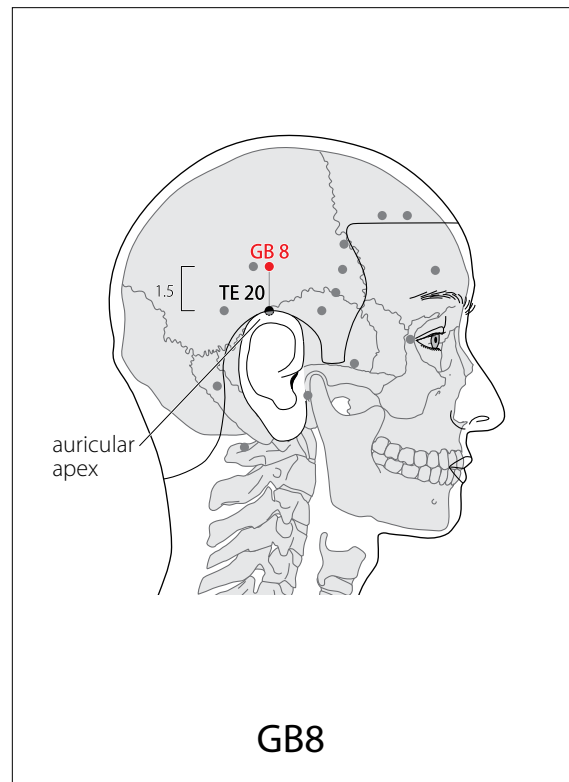
**GB7: Qubin 曲鬢 (鬢)**

On the head, at the junction of the vertical line of the posterior border of the temple hairline and the horizontal line of the apex of the auricle.

**GB8: Shuaigu 率谷**

On the head, directly superior to the auricular apex, 1.5 B-cun superior to the temporal hairline.

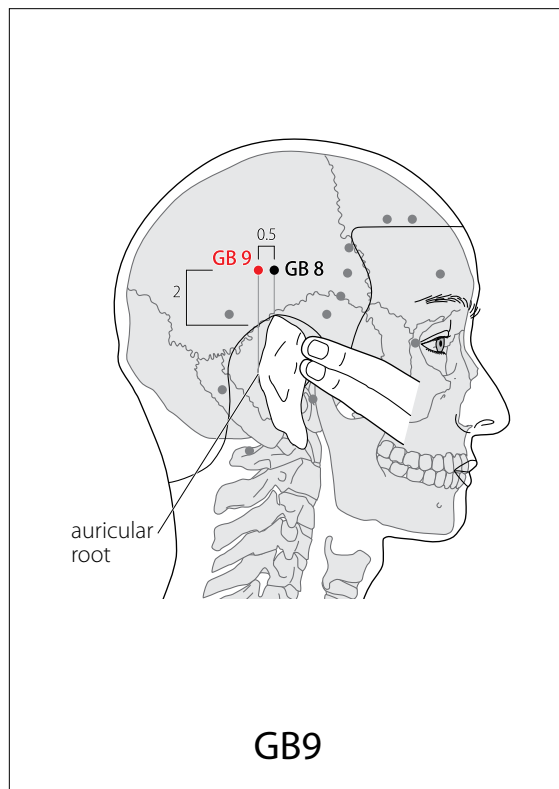
Note: Superior to TE20, 1.5 B-cun within the hairline, it is easier to palpate the point while the subject is chewing.



### GB9: Tianchong 天衝 (冲)

On the head, directly superior to the posterior border of the auricular root, 2 B-cun superior to the hairline.

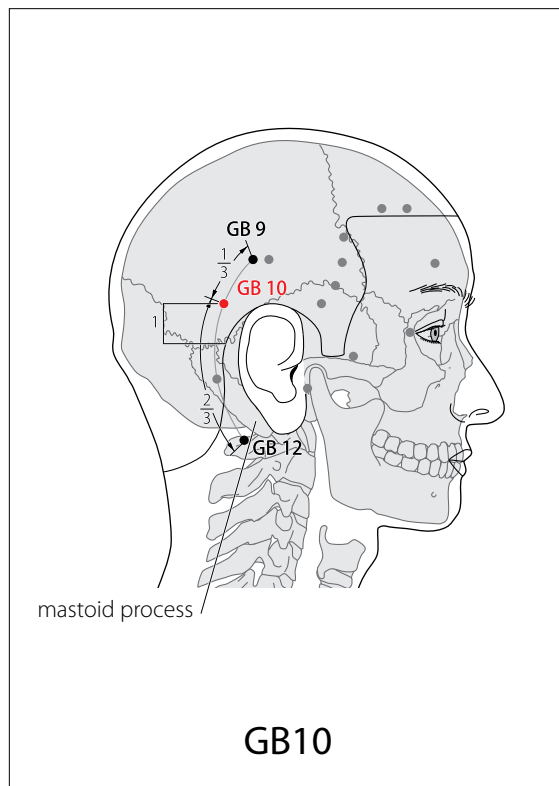
Note: GB9 is 0.5 B-cun posterior to GB8.



### GB10: Fubai 浮 (浮) 白

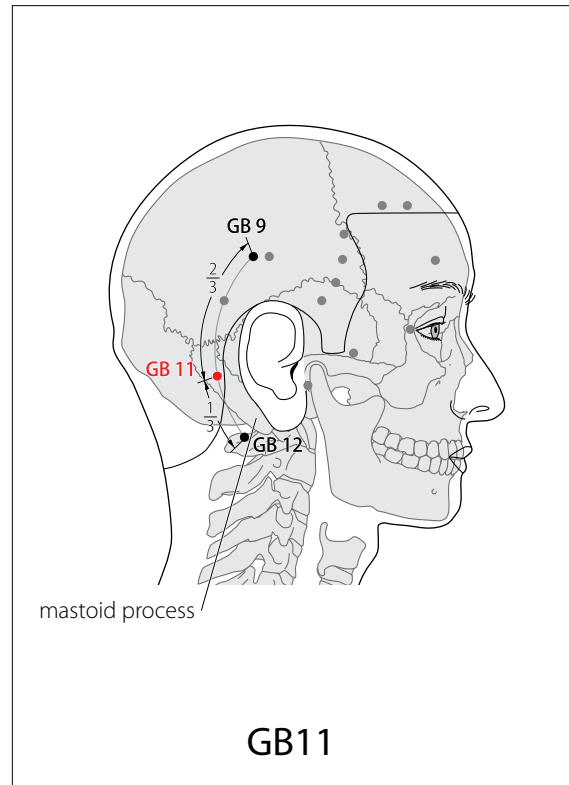
On the head, posterosuperior to the mastoid process, at the junction of the upper one third and lower two thirds of the curved line from GB9 to GB12.

Note: Posterior to the auricular apex, 1 B-cun superior to the hairline.



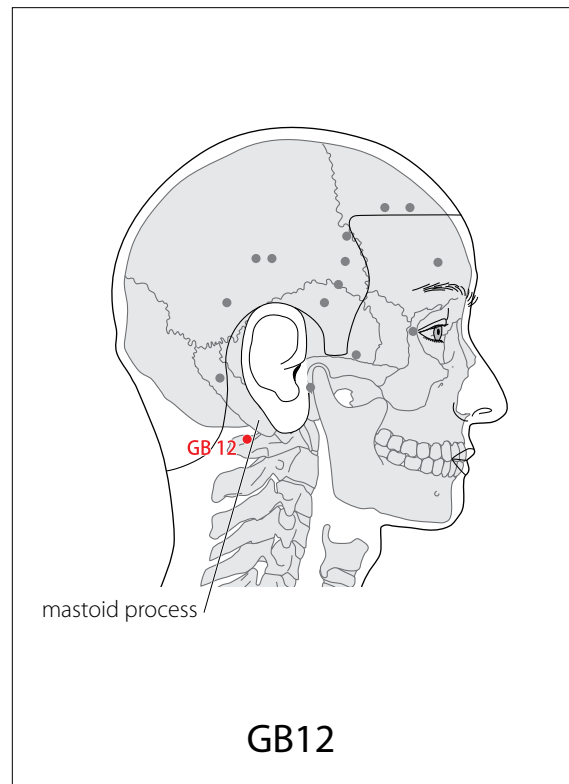
### GB11: Touqiaoyin 頭(头)竅(窍)陰(阴)

On the head, posterior and superior to the mastoid process, at the junction of the upper two thirds and lower one third of the curved line from GB 9 to GB12.



### GB12: Wangu 完骨(骨)

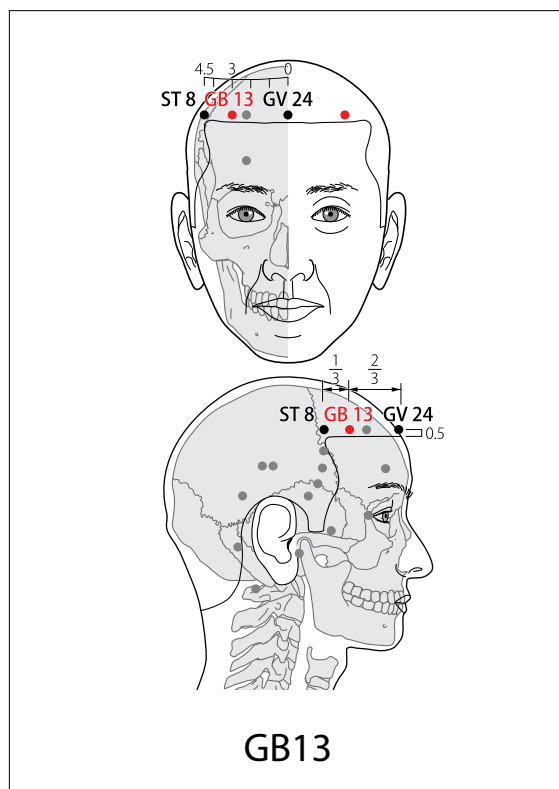
In the anterior region of the neck, in the depression posteroinferior to the mastoid process.



### GB13: Benshen 本神 (神)

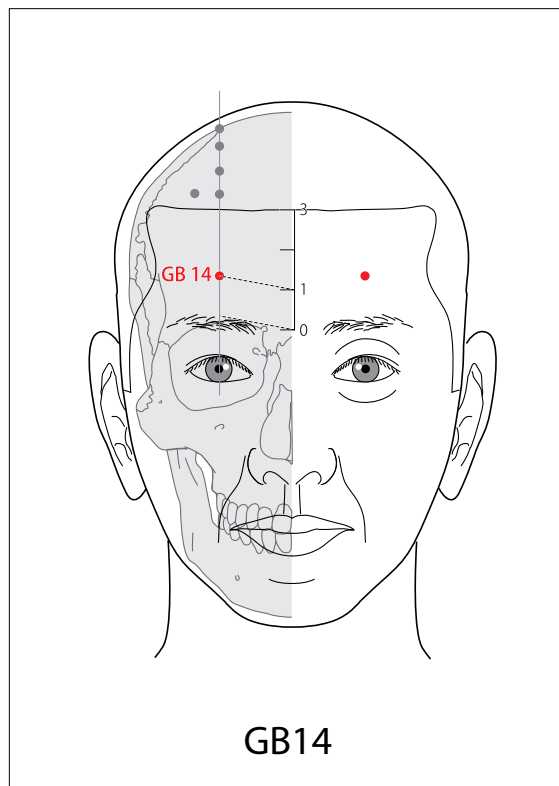
On the head, 0.5 B-cun superior to the anterior hairline, 3 B-cun lateral to the anterior median line.

Note: GB13 is at the junction of the medial two thirds and lateral one third of the curved line from GV24 to ST8.



### GB14: Yangbai 陽 (阳) 白

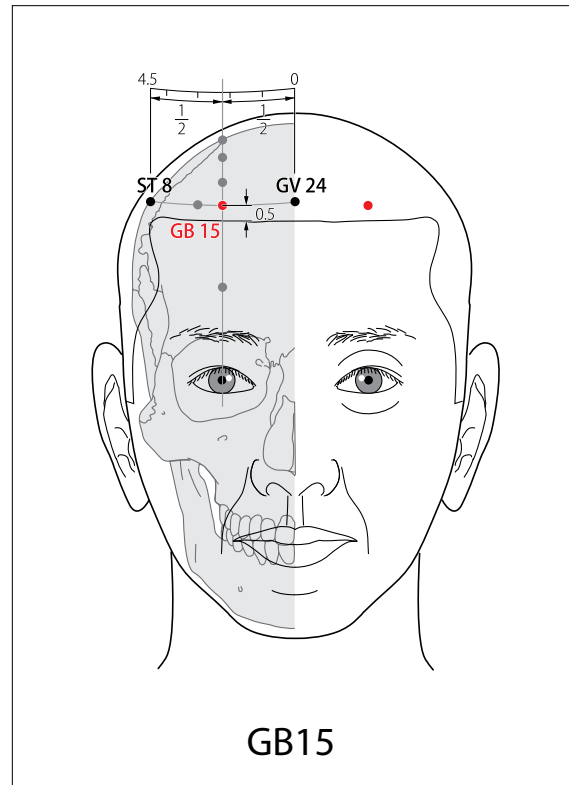
On the head, 1 B-cun superior to the eyebrow, directly superior to the centre of the pupil.



### GB15: Toulinqi 頭(头)臨(临)泣

On the head, 0.5 B-cun within the anterior hairline, directly superior to the centre of the pupil.

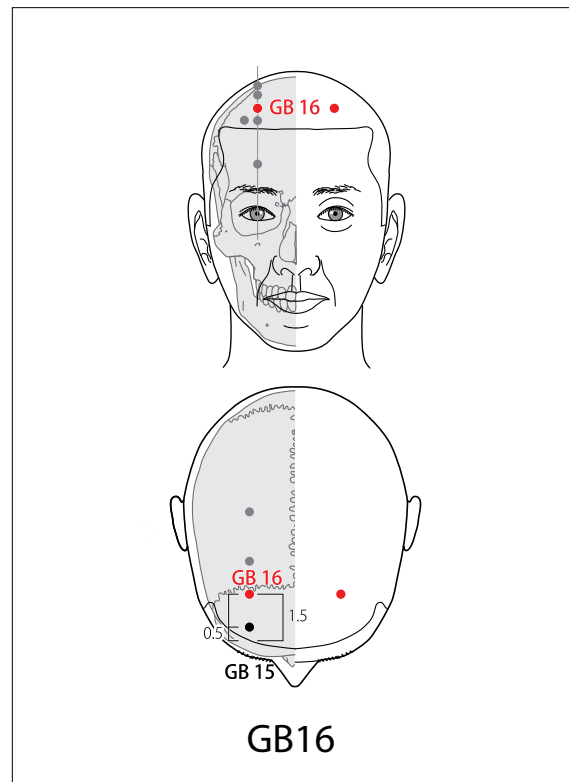
Note: When looking straight ahead, GB15 is superior to the centre of the pupil, at the midpoint of the curved line from GV24 to ST8.



### GB16: Muchuang 目窗(窓)

On the head, 1.5 B-cun within the anterior hairline, directly superior to the centre of the pupil.

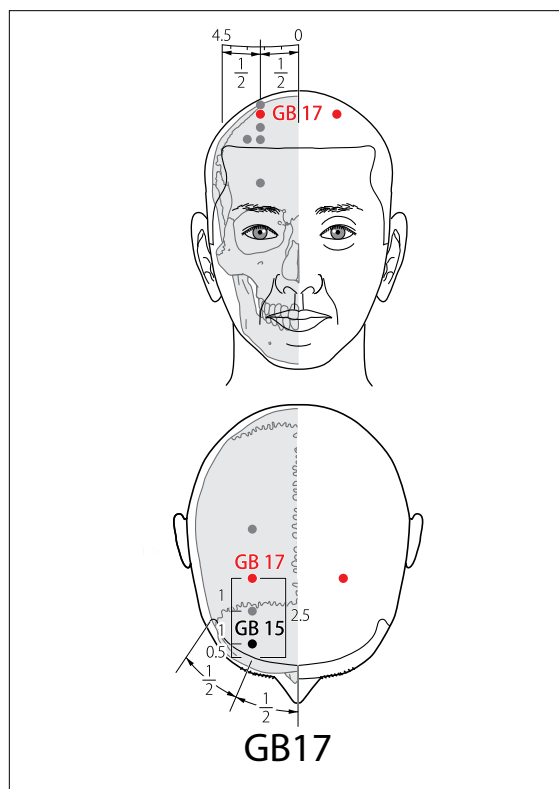
Note: GB16 is 1 B-cun superior to GB15.



### GB17: Zhengying 正營 (营, 營)

On the head, 2.5 B-cun within the anterior hairline, directly superior to the centre of the pupil.

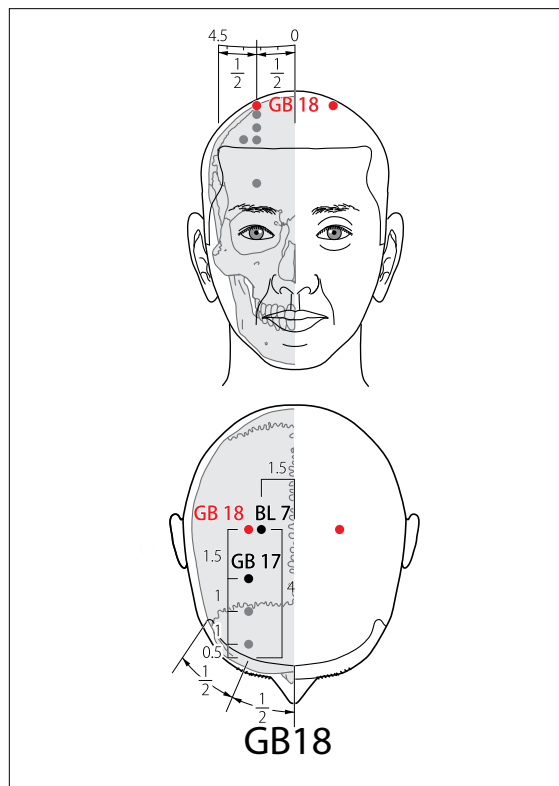
Note: GB17 is 2 B-cun superior to GB15.



### GB18: Chengling 承靈 (灵, 靈)

On the head, 4 B-cun within the anterior hairline, directly superior to the centre of the pupil.

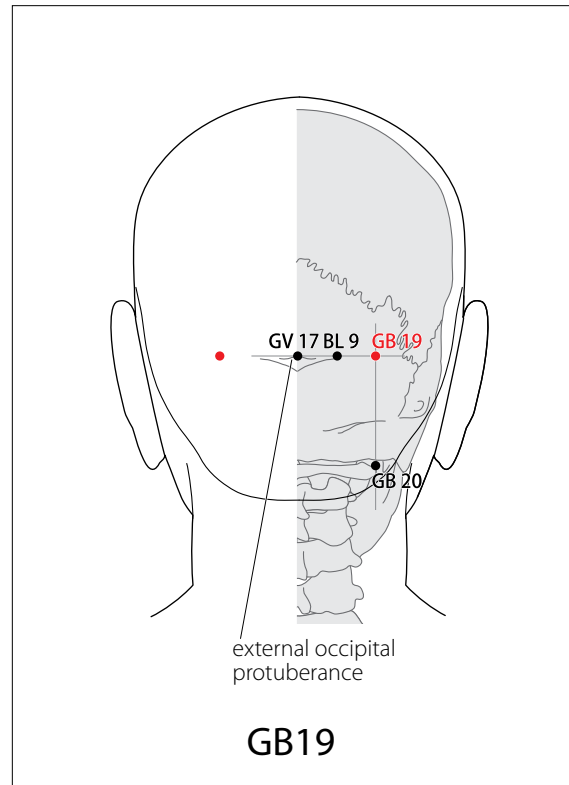
Note: GB18 is 1.5 B-cun posterior to GB17, at the same level as BL7.



### GB19: Naokong 腦(脑, 脑)空

On the head, at the same level as the superior border of the external occipital protuberance, directly superior to GB20.

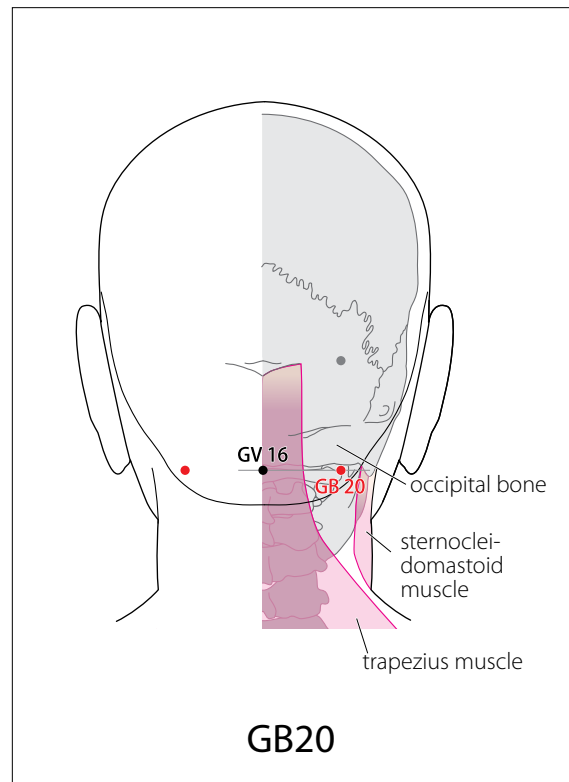
Note: GB19 is at the same level as GV17 and BL9.



### GB20: Fengchi 風(风)池

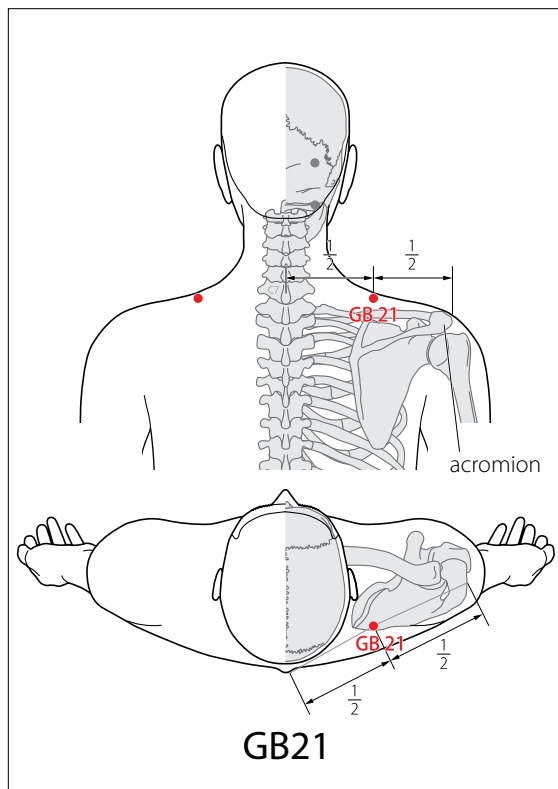
In the anterior region of the neck, inferior to the occipital bone, in the depression between the origins of sternocleidomastoid and the trapezius muscles.

Note: GB20 is at the same level as GV16.



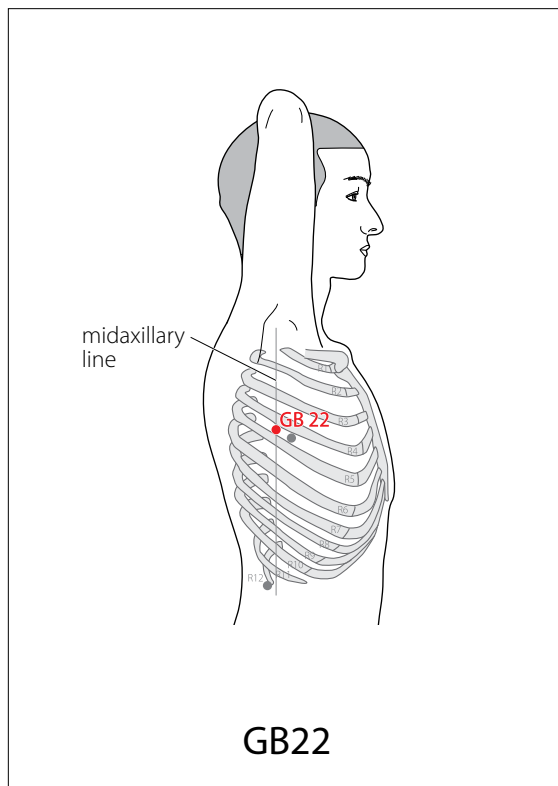
## GB21: Jianjing 肩井

In the posterior region of the neck, at the midpoint of the line connecting the spinous process of the seventh cervical vertebra (C7) with the lateral end of the acromion.



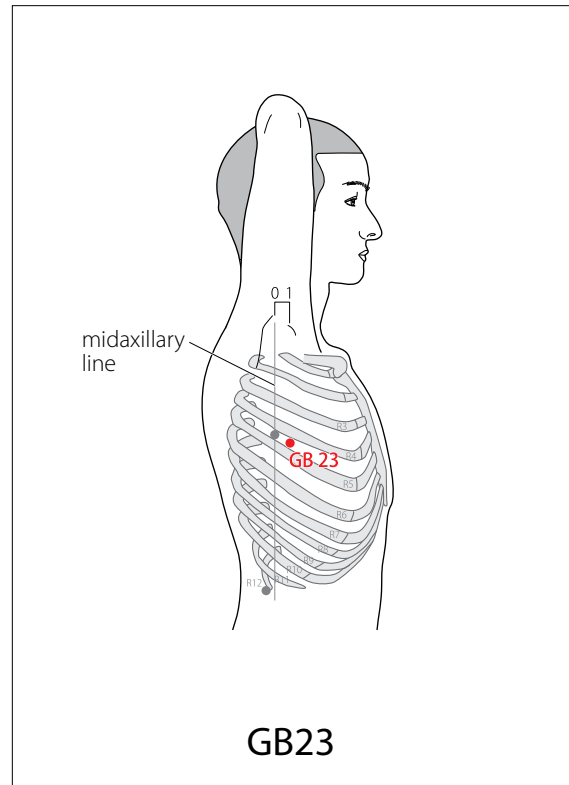
## GB22: Yuanye 淵(淵)液

In the lateral thoracic region, in the fourth intercostal space, on the midaxillary line.



### GB23: Zhejin 輒(輒)筋

In the lateral thoracic region, in the fourth intercostal space, 1 B-cun anterior to the midaxillary line.

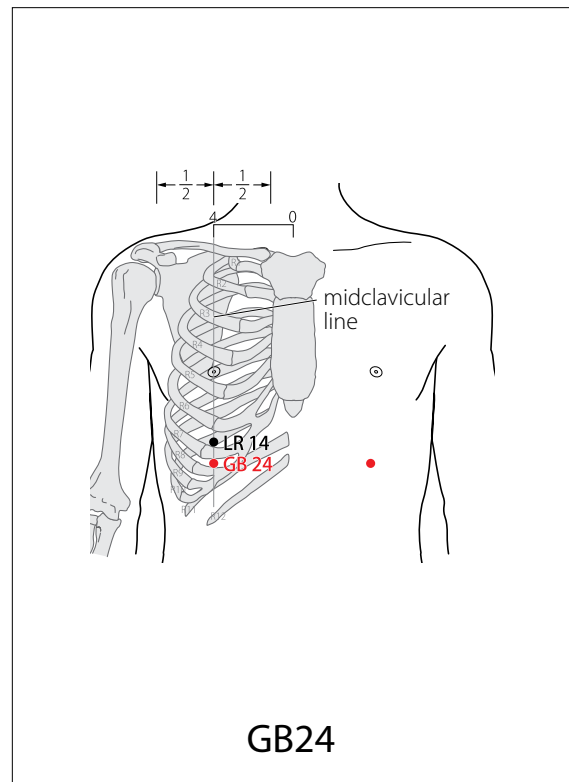


### GB24: Riyue 日月

In the anterior thoracic region, in the seventh intercostal space, 4 B-cun lateral to the anterior median line.

Note 1: GB24 is inferior to the centre of the nipple, one rib inferior to LR14.

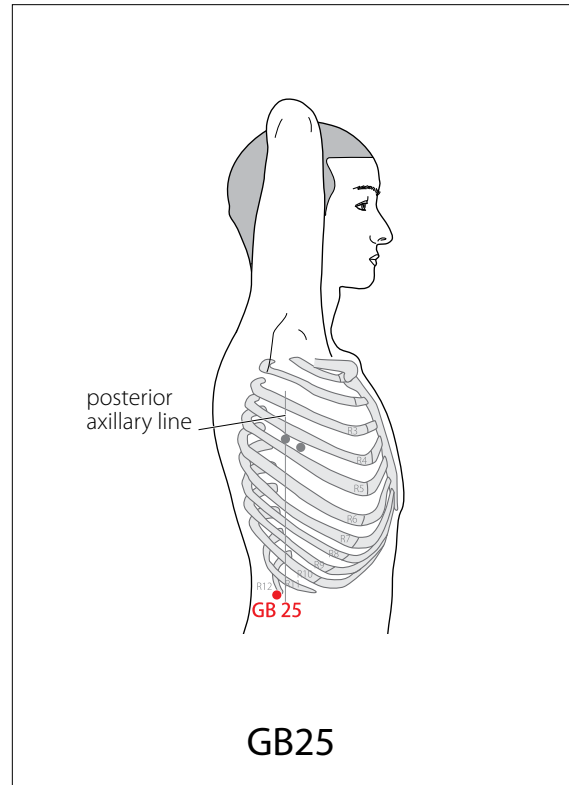
Note 2: In females, GB24 can be found at the intersection of the midclavicular line and the seventh intercostal space.



### GB25: Jingmen 京門 (门)

On the lateral abdomen, inferior to the free extremity of the 12th rib.

Note: GB25 can be located while the subject is lying on the side with the shoulder flexed. The free extremity of the 12th rib can be palpated below the inferior border of the costal arch posterior to the posterior axillary line.

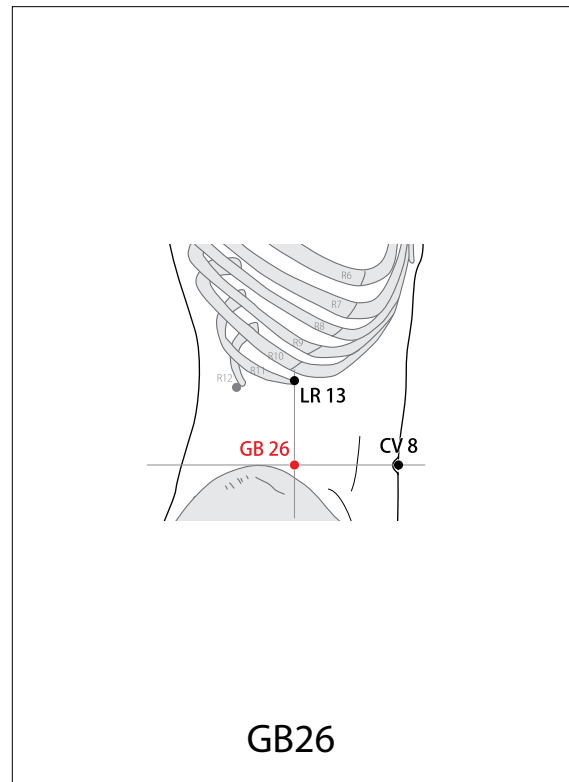


### GB26: Daimai 帶 (帶, 带) 脈 (脉)

On the lateral abdomen, inferior to the free extremity of the 11th rib, at the same level as the centre of umbilicus.

Note 1: GB26 can be located by first locating the tenth rib, then searching for the free extremity of the 11th rib that is situated immediately below the inferior border of the costal arch.

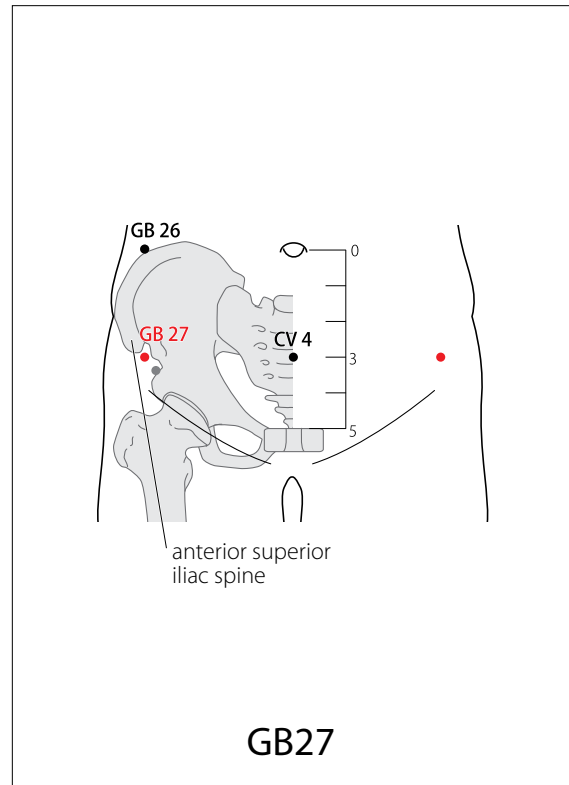
Note 2: GB26 is inferior to LR13, at the same level as CV8.



### GB27: Wushu 五樞(枢)

On the lower abdomen, 3 B-cun inferior to the centre of umbilicus, medial to the anterior superior iliac spine.

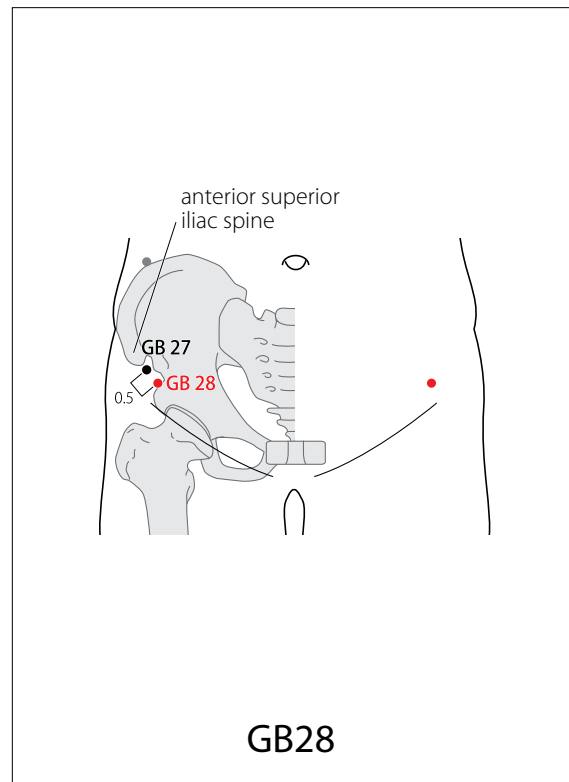
Note: GB27 is 3 B-cun inferior to GB26, at the same level as CV4.



### GB28: Weidao 維(维)道(道)

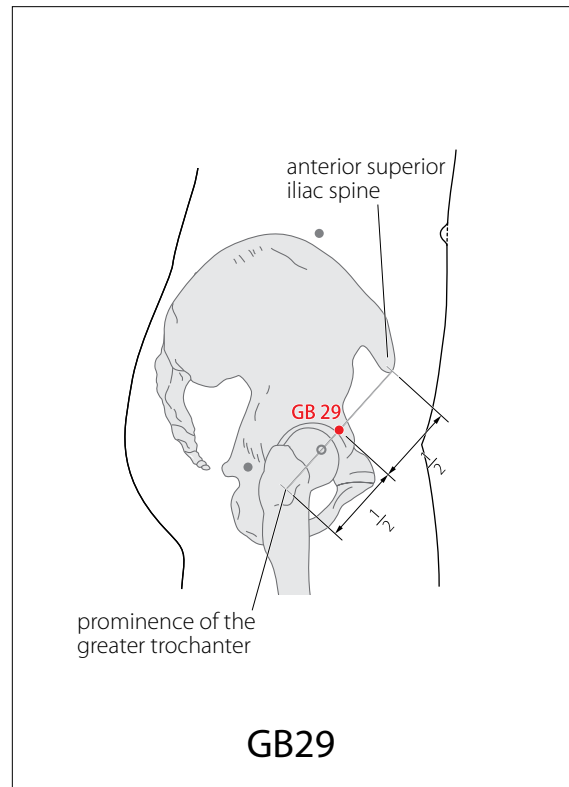
On the lower abdomen, 0.5 B-cun medioinferior to the anterior superior iliac spine.

Note: GB28 is 0.5 B-cun medioinferior to GB27.



### GB29: Juliao 居髃(髃)

In the buttock region, midpoint of the line connecting the anterior superior iliac spine and the prominence of the greater trochanter.

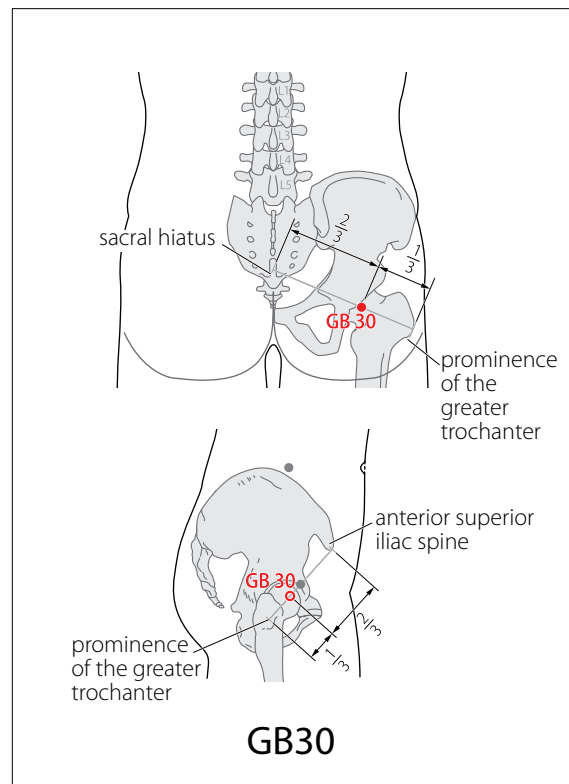


### GB30: Huantiao 環(环)跳

In the buttock region, at the junction of the lateral one third and medial two thirds of the line connecting the prominence of the greater trochanter with the sacral hiatus.

Note: GB30 is easier to locate when the subject is lying on the side with the thigh flexed.

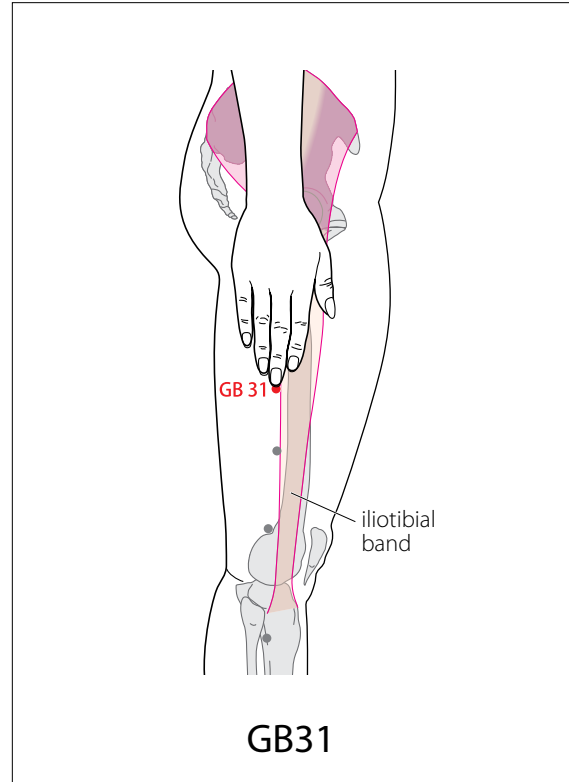
Remarks: Alternative location for GB30 - in the buttock region, at the junction of the lateral one third and medial two thirds of the distance between the prominence of the greater trochanter and the anterior superior iliac spine.



### GB31: Fengshi 風(风) 市

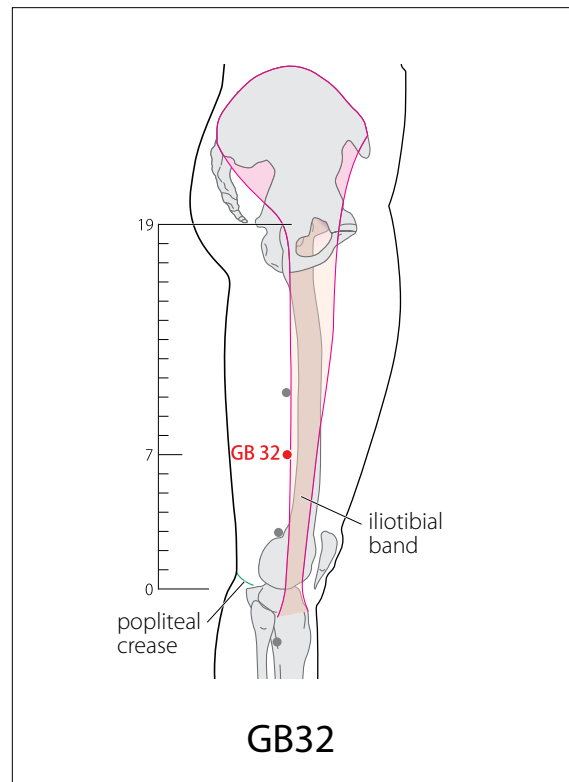
On the lateral aspect of the thigh, in the depression posterior to the iliotibial band where the tip of the middle finger rests, when standing up with the arms hanging alongside the thigh.

Note: GB31 is located by first finding the iliotibial band when the knee is slightly flexed and the hip is abducted against resistance.



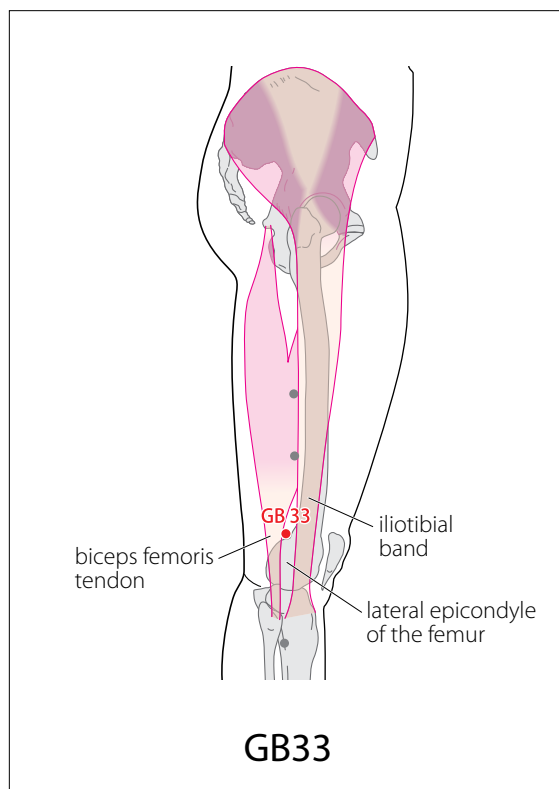
### GB32: Zhongdu 中瀆(渎)

On the lateral aspect of the thigh, posterior to the iliotibial band, 7 B-cun superior to the popliteal crease.

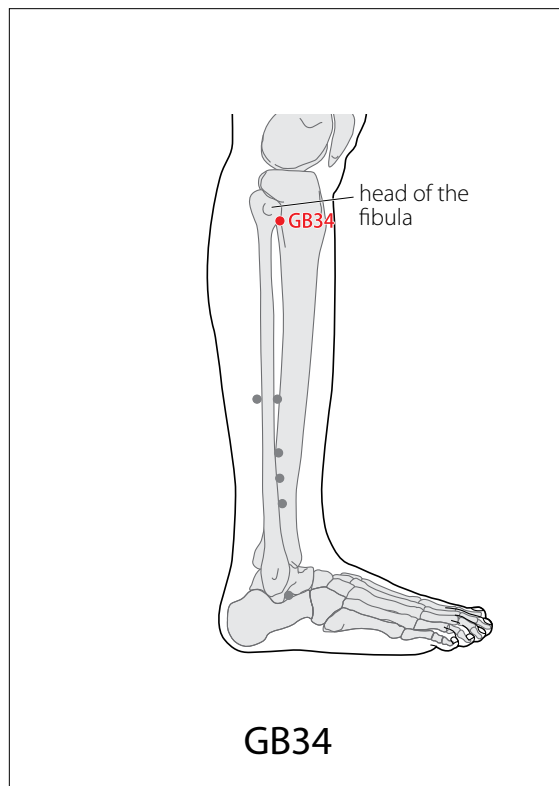


**GB33: Xiyangguan 膝陽(阳)關(关, 関)**

On the lateral aspect of the knee, in the depression between the biceps femoris tendon and the iliotibial band, posterior and proximal to the lateral epicondyle of the femur.

**GB34: Yanglingquan 陽(阳)陵泉**

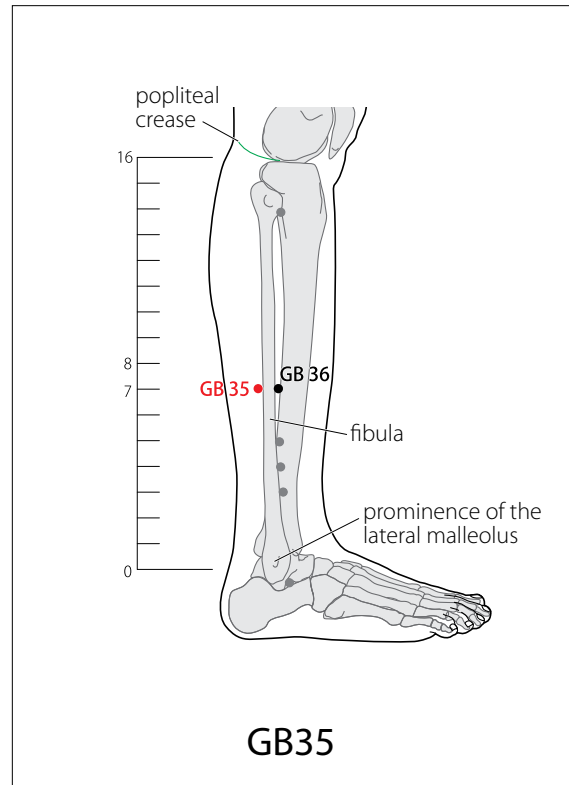
On the fibular aspect of the leg, in the depression anterior and distal to the head of the fibula.



### GB35: Yangjiao 陽(阳)交

On the fibular aspect of the leg, posterior to the fibula, 7 B-cun proximal to the prominence of the lateral malleolus.

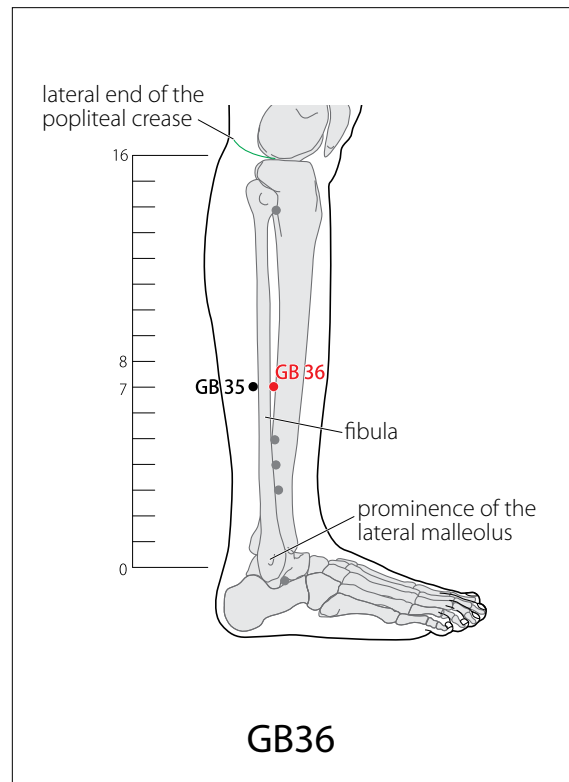
Note: GB35 is located 1 B-cun distal to the midpoint of the line connecting the prominence of the lateral malleolus and the lateral end of the popliteal crease, posterior to GB36.



### GB36: Waiqiu 外丘(邱)

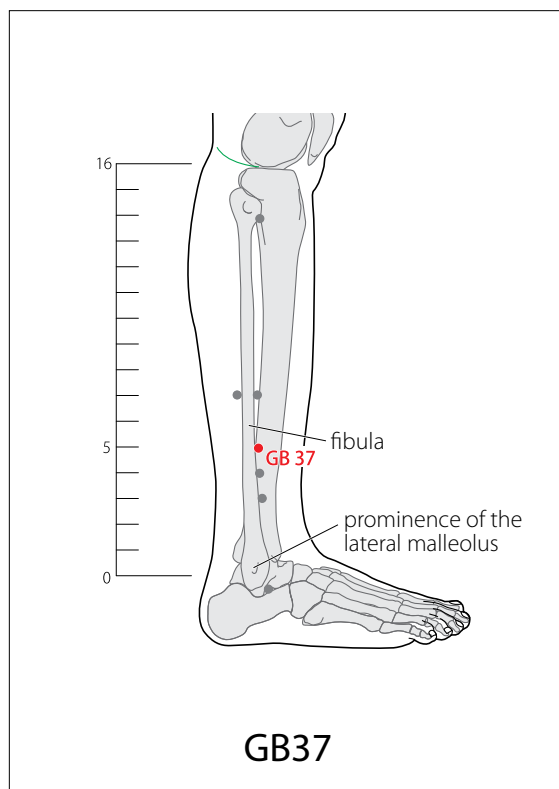
On the fibular aspect of the leg, anterior to the fibula, 7 B-cun proximal to the prominence of the lateral malleolus.

Note: GB36 is located 1 B-cun distal to the midpoint of the line connecting the prominence of the lateral malleolus and the lateral end of the popliteal crease, anterior to GB35.

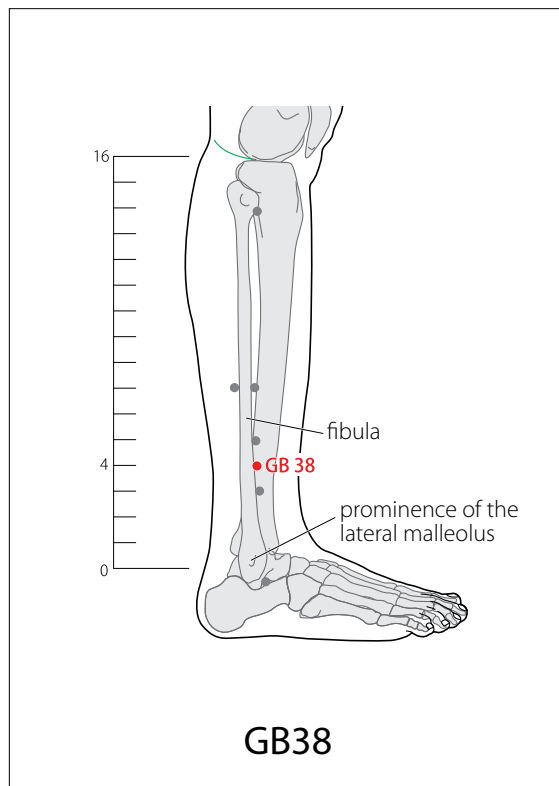


**GB37: Guangming 光明**

On the fibular aspect of the leg, anterior to the fibula, 5 B-cun proximal to the prominence of the lateral malleolus.

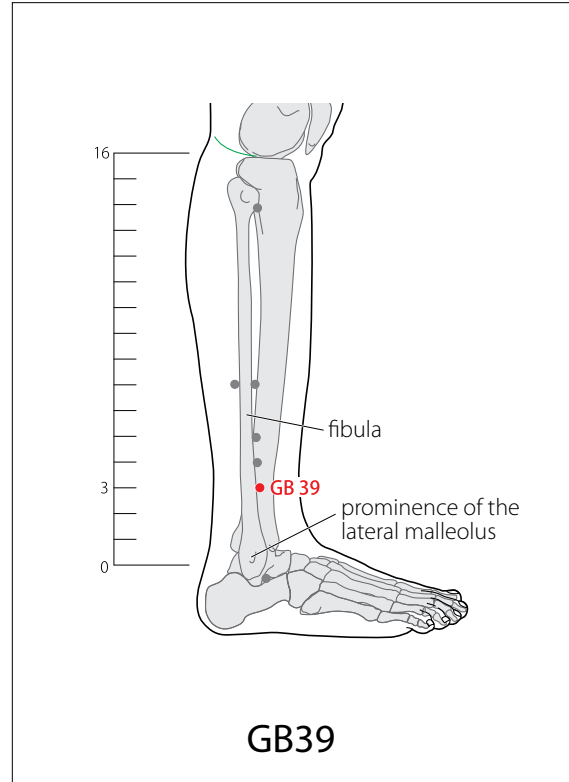
**GB38: Yangfu 陽(阳)輔(辅)**

On the fibular aspect of the leg, anterior to the fibula, 4 B-cun proximal to the prominence of the lateral malleolus.



### GB39: Xuanzhong 懸(悬)鍾(钟)

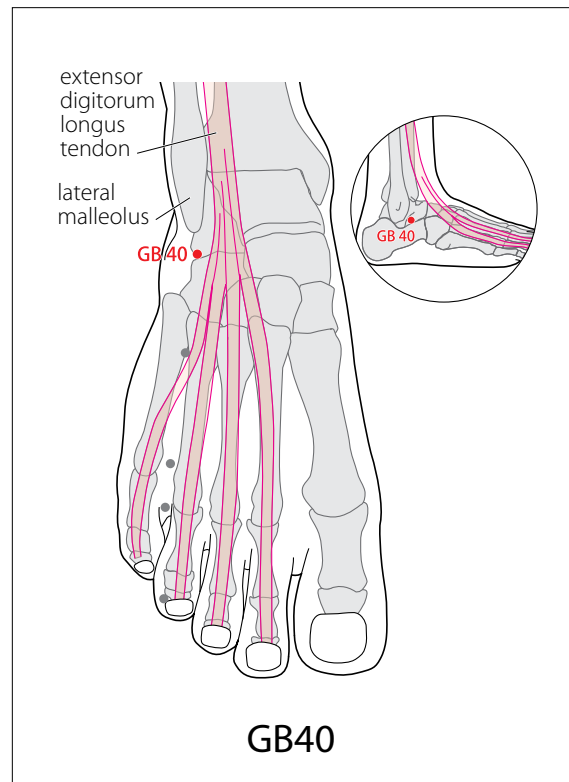
On the fibular aspect of the leg, anterior to the fibula, 3 B-cun proximal to the prominence of the lateral malleolus.



### GB40: Qiuxu 丘(坵)墟(墟)

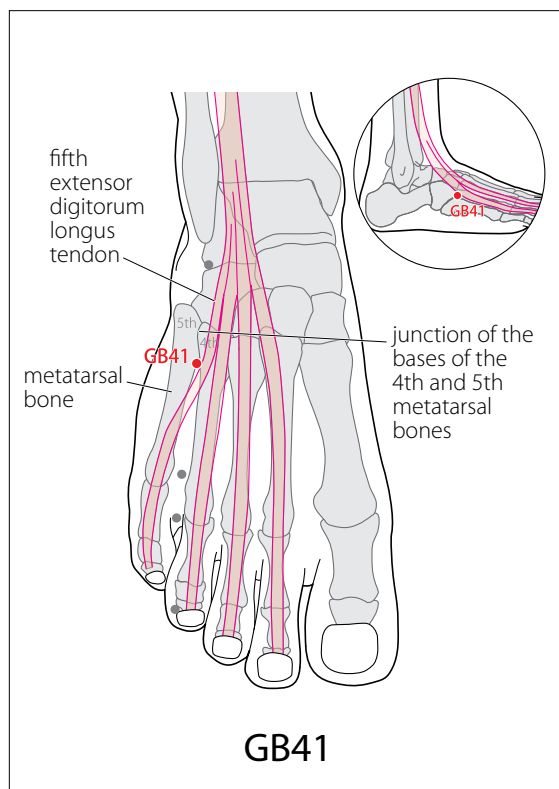
On the anterolateral aspect of the ankle, in the depression lateral to the extensor digitorum longus tendon, anterior and distal to the lateral malleolus.

Note: GB40 is easier to locate by finding the extensor digitorum longus tendon when the second to fifth toes are extended against resistance.



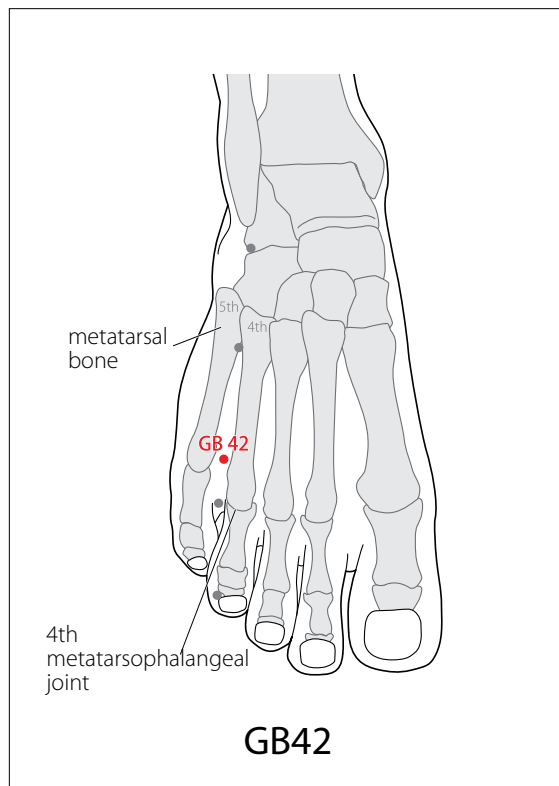
### GB41: Zulinqi 足臨(临)泣

On the dorsum of the foot, distal to the junction of the bases of the fourth and fifth metatarsal bones, in the depression lateral to the fifth extensor digitorum longus tendon.



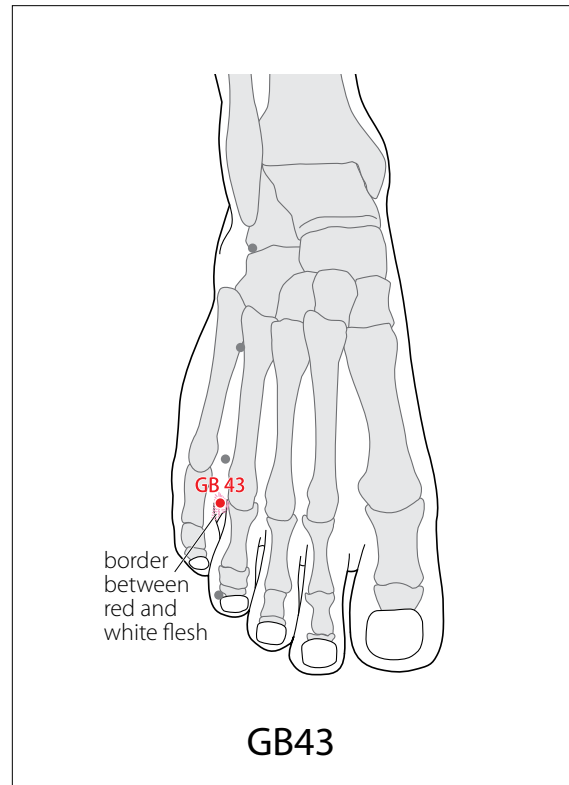
### GB42: Diwuhui 地五會(会)

On the dorsum of the foot, between the fourth and fifth metatarsal bones, in the depression proximal to the fourth metatarsophalangeal joint.

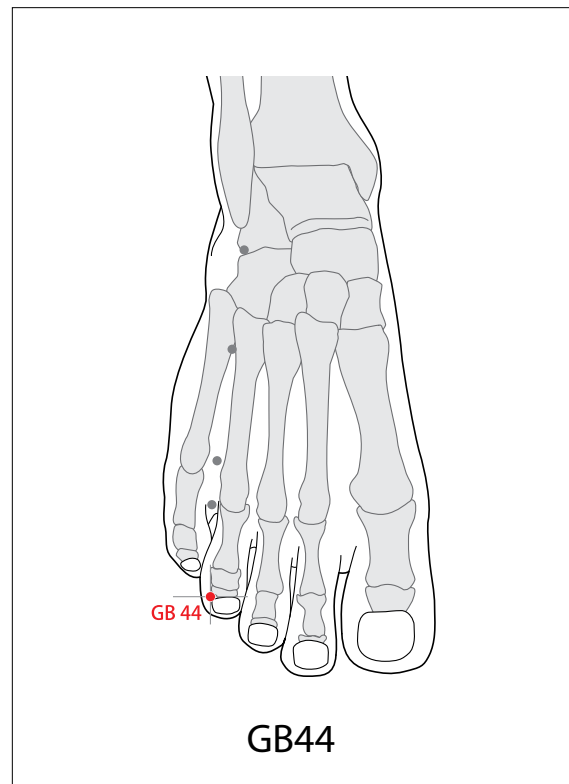


**GB43: Xiashi 俠(俠)谿(溪)**

On the dorsum of the foot, between the fourth and fifth toes, proximal to the web margin, at the border between the red and white flesh.

**GB44: Zuqiaoyin 足竅(窍)陰(阴)**

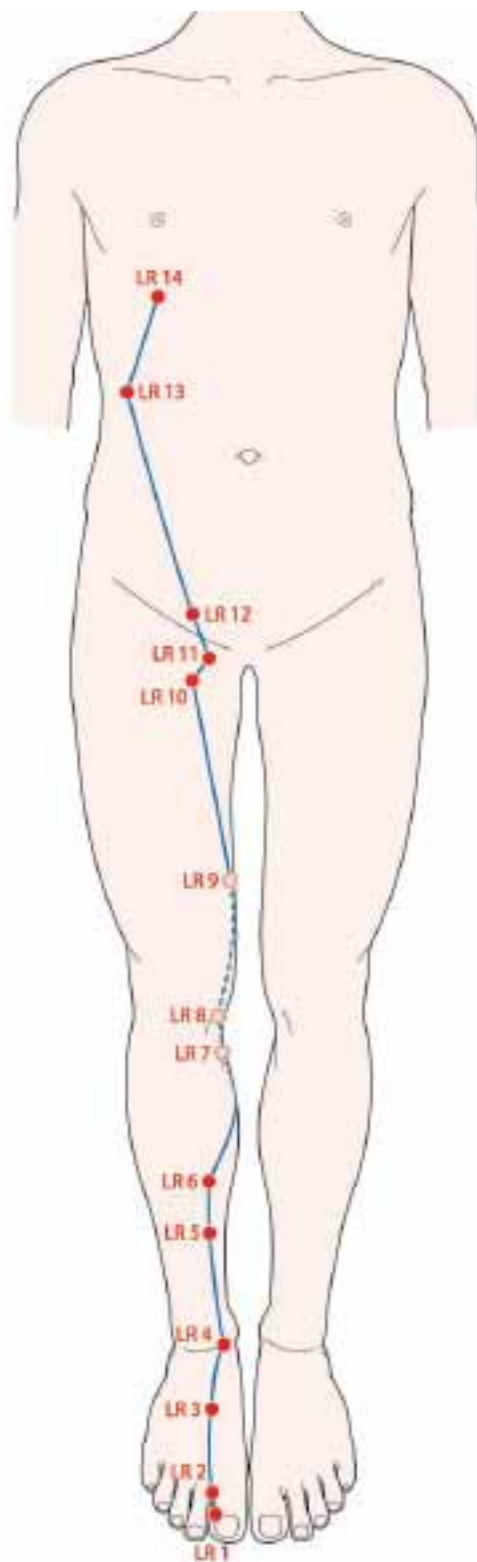
On the fourth toe, lateral to the distal phalanx, 0.1 F-cun proximal to the lateral corner of the toenail, at the intersection of the vertical line of the lateral side of the nail and the horizontal line of the base of the fourth toenail.





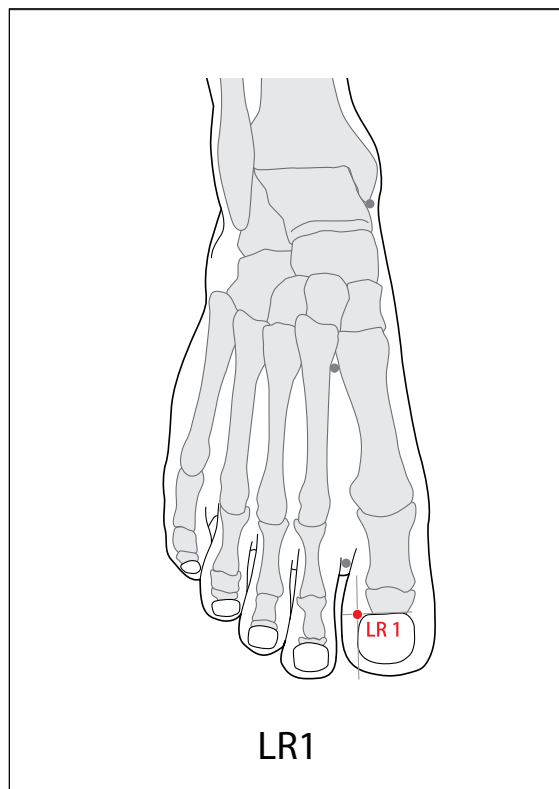
## LIVER MERIDIAN

足厥陰(阴)肝經(经, 經)

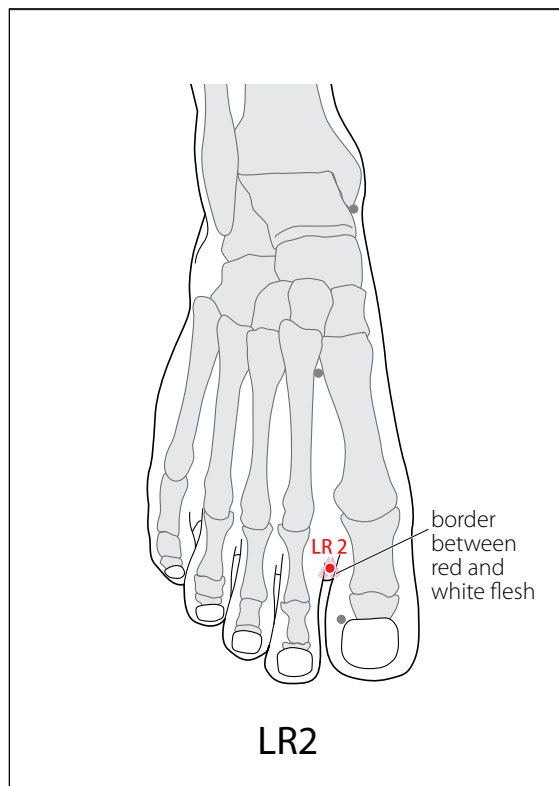


**LR1: Dadun 大敦**

On the great toe, lateral to the distal phalanx, 0.1 F-cun proximal to the lateral corner of the toenail, at the intersection of the vertical line of the lateral side of the nail and the horizontal line of the base of the toenail.

**LR2: Xingjian 行间 (间)**

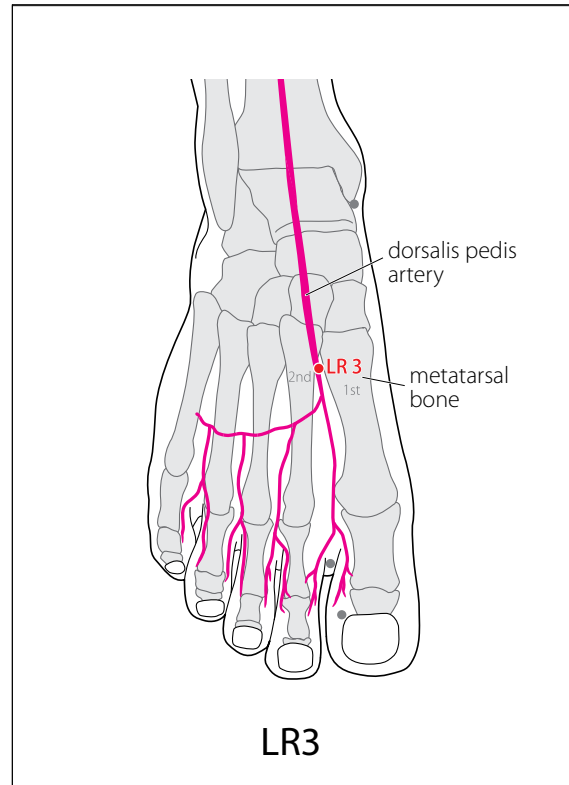
On the dorsum of the foot, between the first and second toes, proximal to the web margin, at the border between the red and white flesh.



**LR3: Taichong 太衝 (冲)**

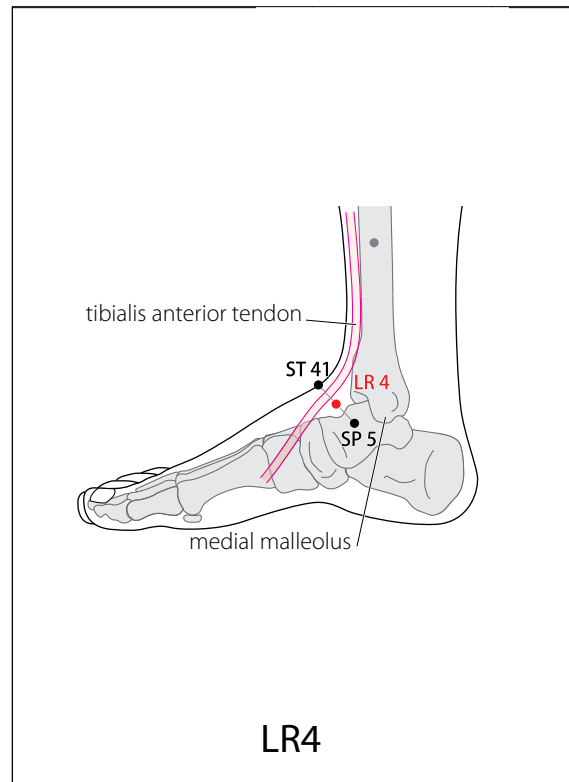
On the dorsum of the foot, between the first and second metatarsal bones, in the depression distal to the junction of the bases of the two bones, over the dorsalis pedis artery.

Note: LR3 can be felt in the depression when moving proximally from LR2 in the gap between the first and second metatarsal bones towards the base of two metatarsal bones.

**LR4: Zhongfeng 中封**

On the anteromedial aspect of the ankle, in the depression medial to the tibialis anterior tendon, anterior to the medial malleolus.

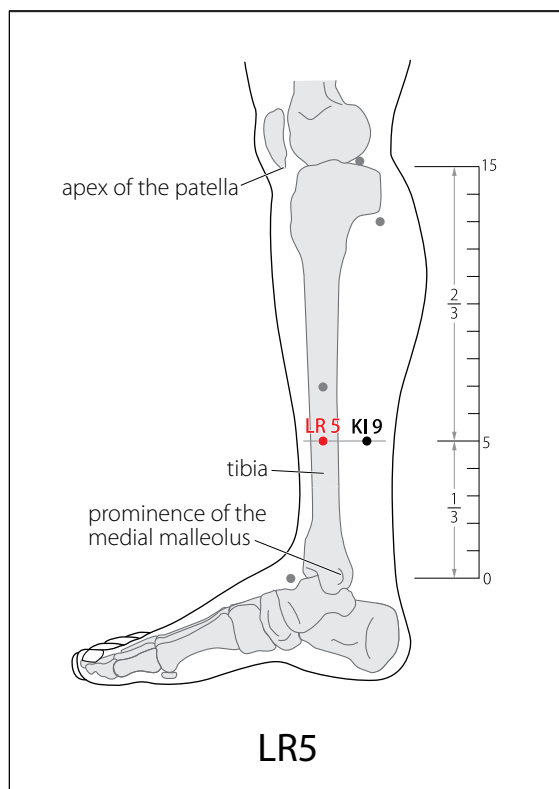
Note: LR4 is located midway between SP5 and ST41.



### LR5: Ligou 蠡沟(沟)

On the anteromedial aspect of the leg, at the centre of the medial border (surface) of the tibia, 5 B-cun proximal to the prominence of the medial malleolus.

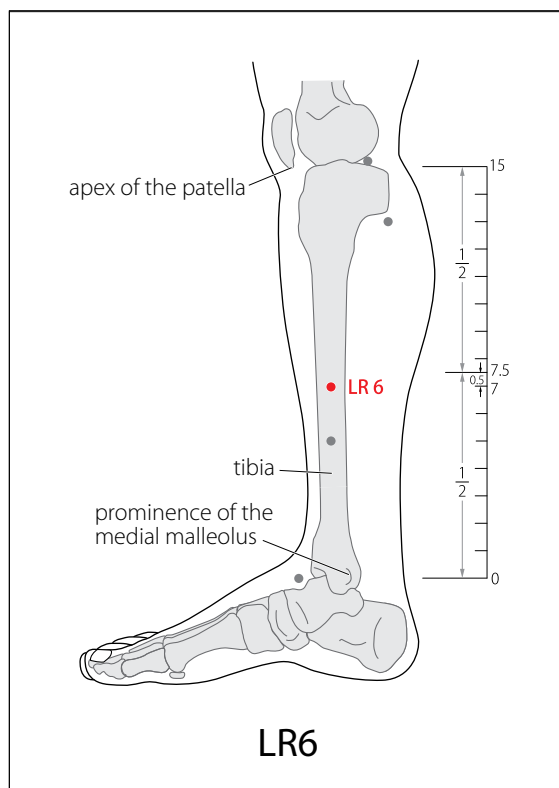
Note: LR5 is located at the same level as the upper two thirds and lower one third of the line connecting the apex of the patella with the prominence of the medial malleolus, at the centre of the medial border (surface) of the tibia, at the same level as KI9.



### LR6: Zhongdu 中都(都)

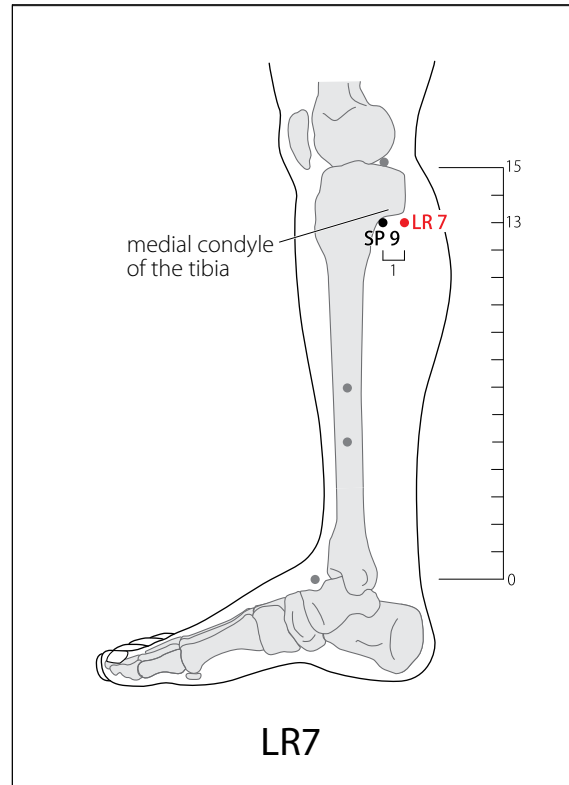
On the anteromedial aspect of the leg, at the centre of the medial border (surface) of the tibia, 7 B-cun proximal to the prominence of the medial malleolus.

Note: LR6 is located at 0.5 B-cun inferior to the midpoint of the line connecting the apex of the patella with the prominence of the medial malleolus, at the centre of the medial border (surface) of the tibia.



### LR7: Xiguan 膝關 (关, 関)

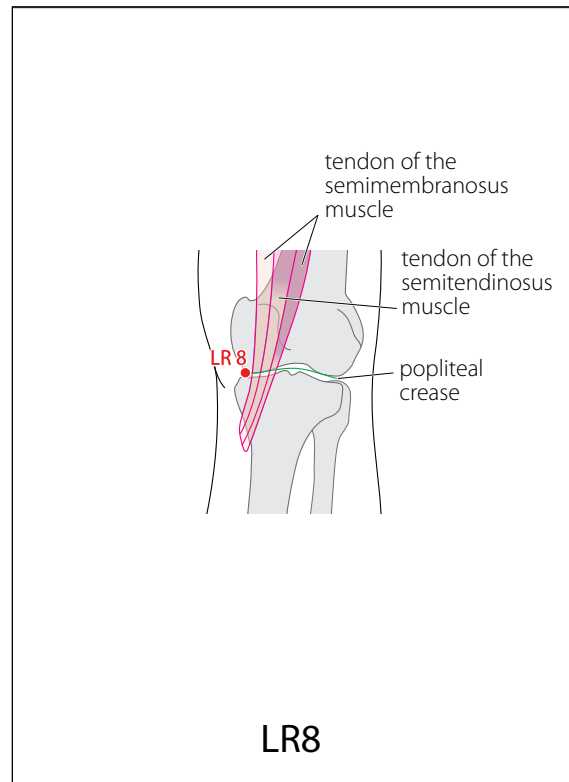
On the tibial aspect of the leg, inferior to the medial condyle of the tibia, 1 B-cun posterior to SP9.



### LR8: Ququan 曲泉

On the medial aspect of the knee, in the depression medial to the tendons of the semitendinosus and the semimembranosus muscles, at the medial end of the popliteal crease.

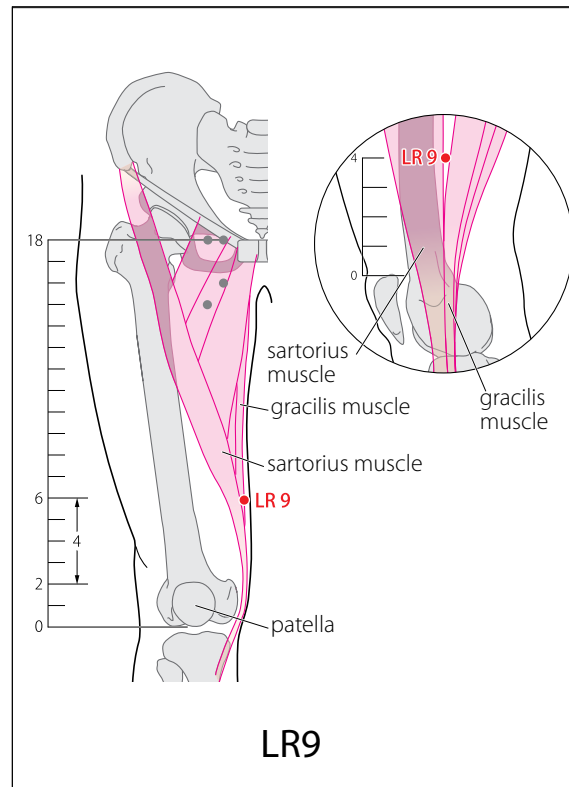
Note: With the knee flexed, LR8 is located in the depression medial to the most prominent tendon on the medial end of the popliteal crease.



### LR9: Yinbao 陰(阴)包(包)

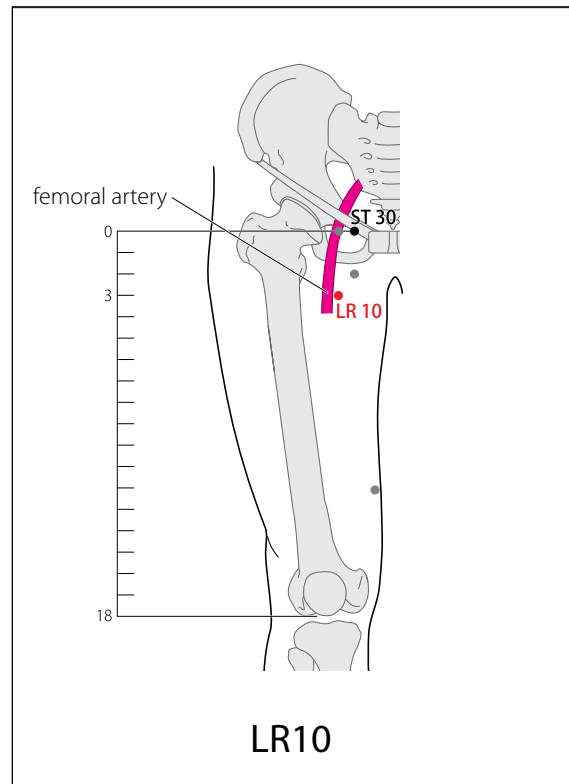
On the medial aspect of the thigh, between the gracilis and the sartorius muscles, 4 B-cun proximal to the base of the patella.

Note: With the hip slightly flexed and abducted and with the muscle under tension, the sartorius muscle becomes more distinct. LR 9 is located posterior to the sartorius muscle.



### LR10: Zuwuli 足五里

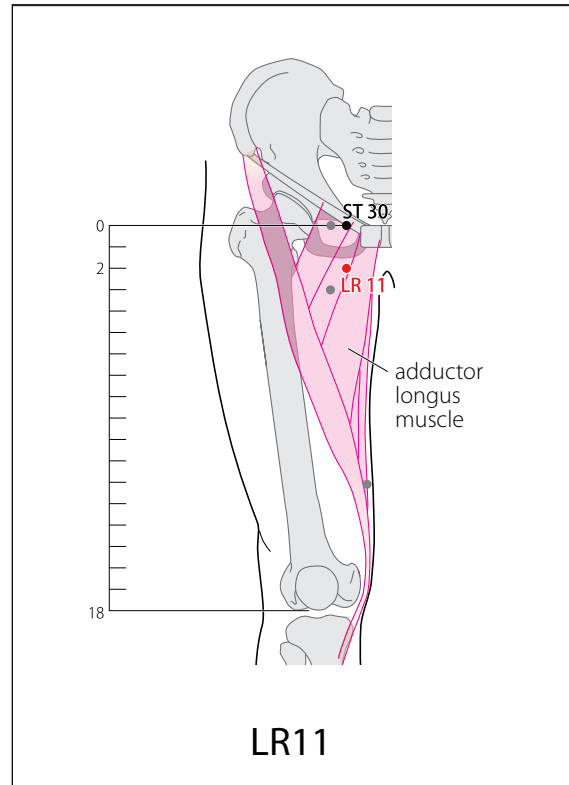
On the medial aspect of the thigh, 3 B-cun distal to ST30, over the artery.



### LR11: Yinlian 陰(阴)廉

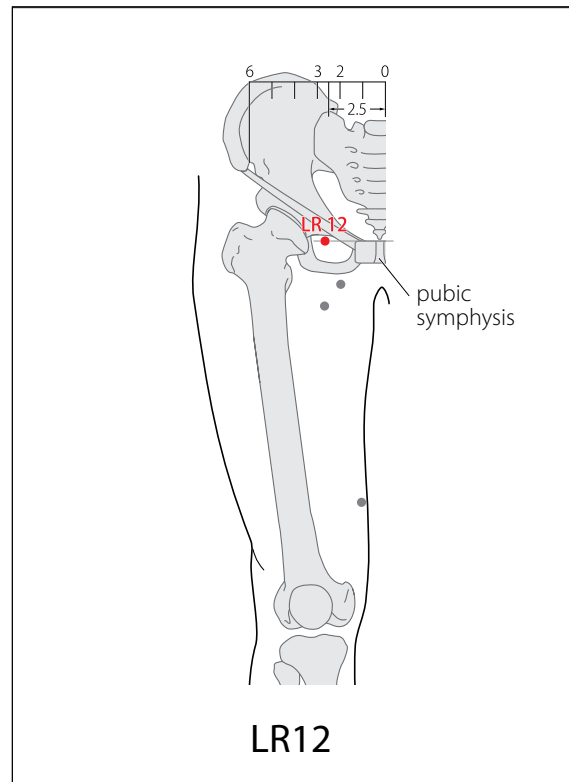
On the medial aspect of the thigh, 2 B-cun distal to ST30.

Note: LR11 is located lateral to the adductor longus muscle. When the thigh is adducted against resistance with the hip slightly flexed and abducted, the knee flexed, the adductor longus muscle becomes more distinct.



### LR12: Jimai 急脈(脉)

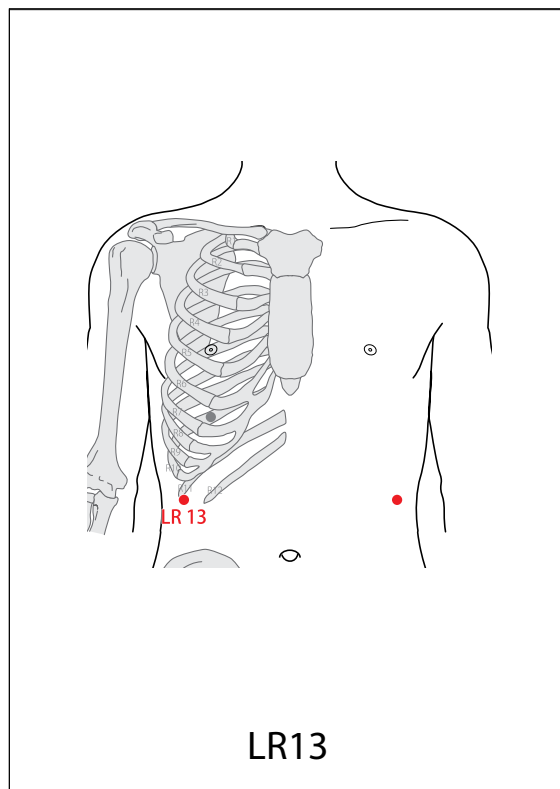
In the groin region, at the same level as the superior border of the pubic symphysis, and 2.5 B-cun lateral to the anterior median line.



### LR13: Zhangmen 章門 (门)

On the lateral abdomen, inferior to the free extremity of the 11th rib.

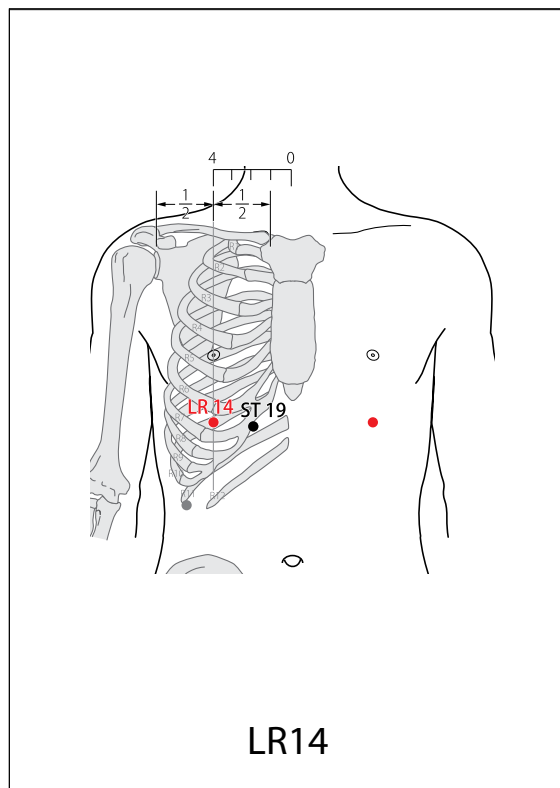
Note: LR13 can be located while the subject is lying on the side with the shoulder flexed. The free extremity of the 11th rib can be palpated below the inferior border of the costal arch.



### LR14: Qimen 期門 (门)

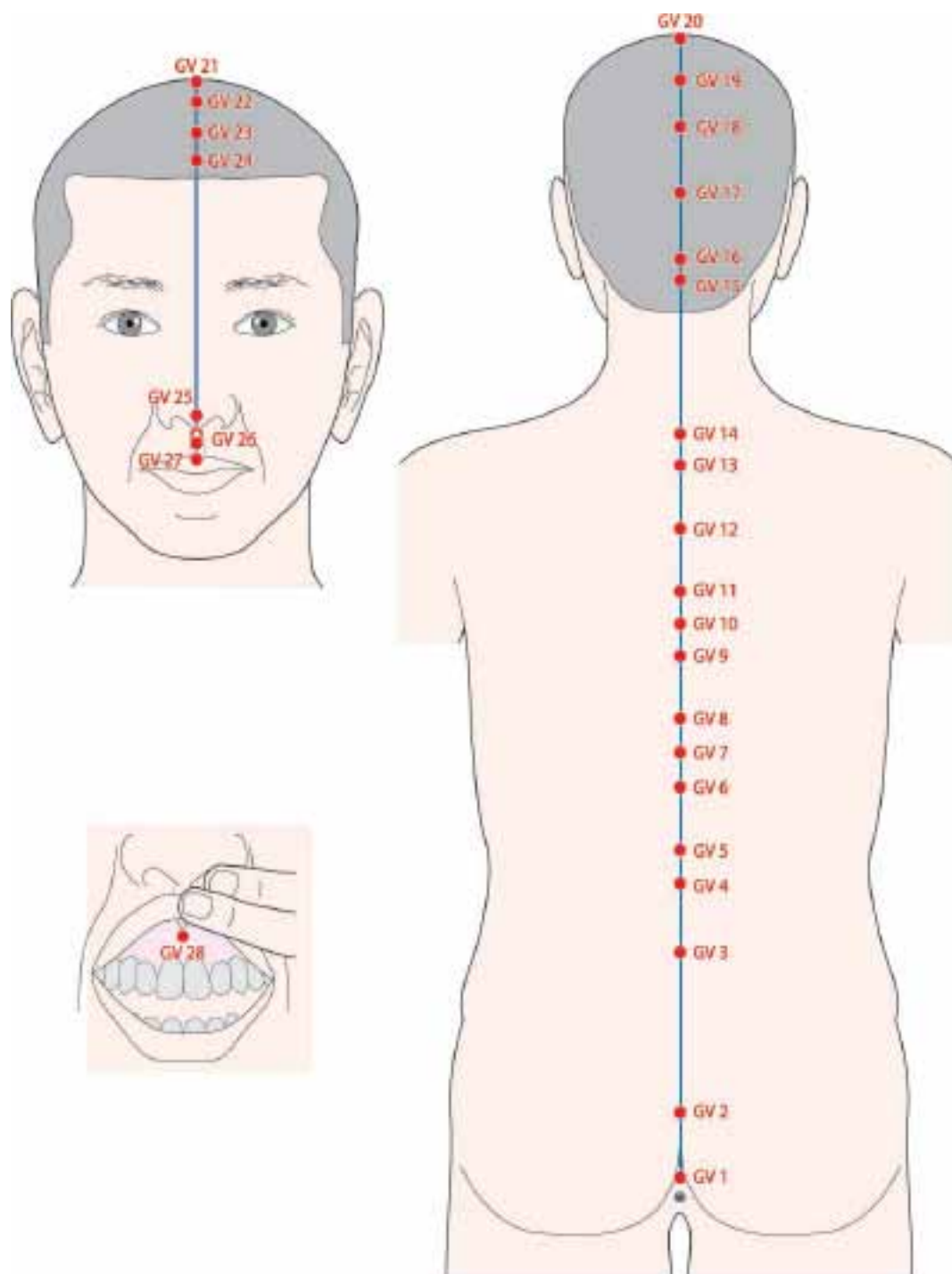
In the anterior thoracic region, in the sixth intercostal space, 4 B-cun lateral to the anterior median line.

Note: LR14 is inferior to the centre of the nipple, 2 B-cun lateral to ST19. In females, LR14 is located at the intersection of the midclavicular line and the sixth intercostal space.



# GOVERNOR VESSEL

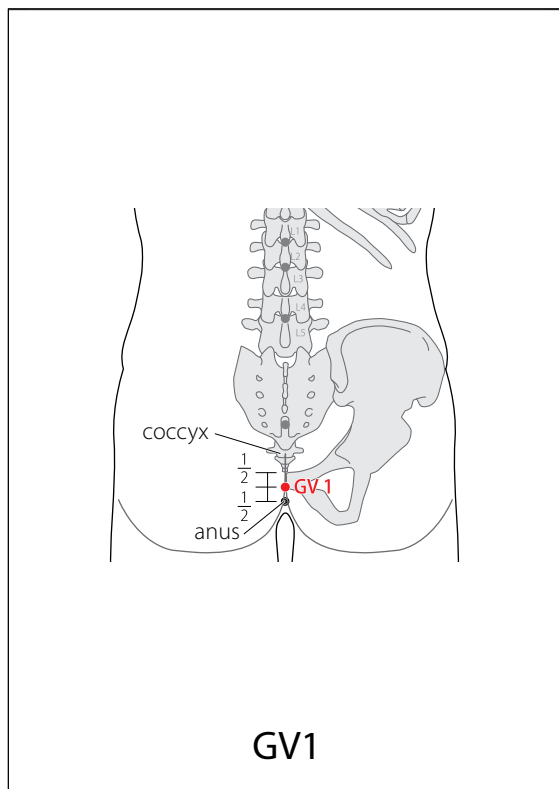
督脈(脉)



### GV1: Changqiang 長(长)強

In the perineal region, inferior to the coccyx, midway between the tip of the coccyx and the anus.

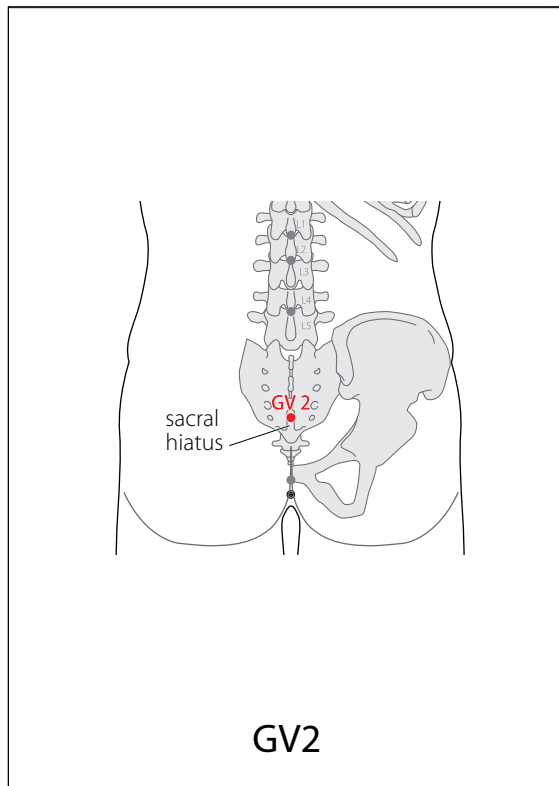
Note: The subject may be in prone position or knee-chest position.



### GV2: Yaoshu 腰俞(俞)

In the sacral region, at the sacral hiatus, on the posterior median line.

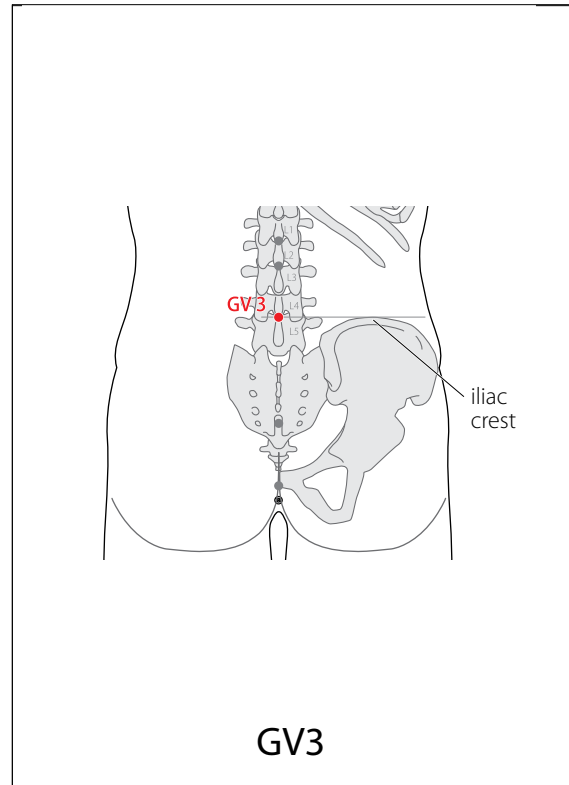
Note: The sacral hiatus is a small depression immediately above the anal cleft.



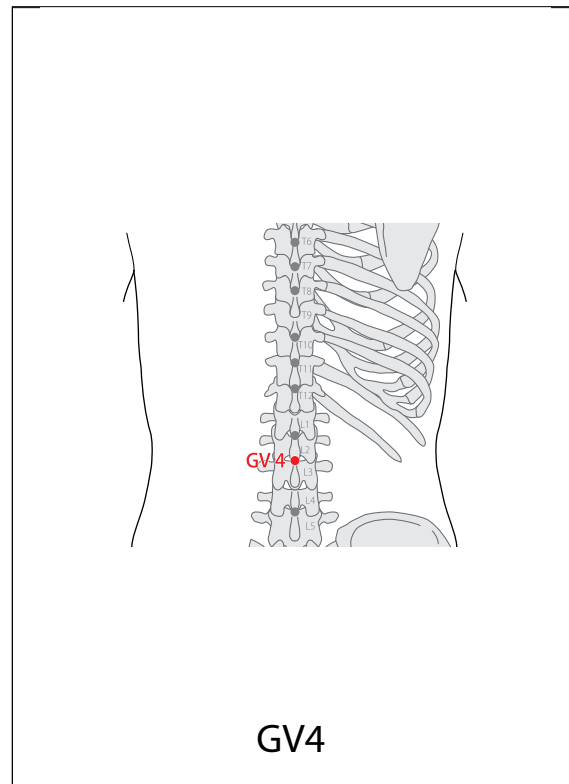
**GV3: Yaoyangguan 腰陽(阳)關(关, 関)**

In the lumbar region, in the depression inferior to the spinous process of the fourth lumbar vertebra (L4), on the posterior median line.

Note: GV3 can be located by first palpating the highest points of the iliac crests and the spinous process of the fourth lumbar vertebra (L4) can then be found at the midpoint of the highest points of both iliac crests.

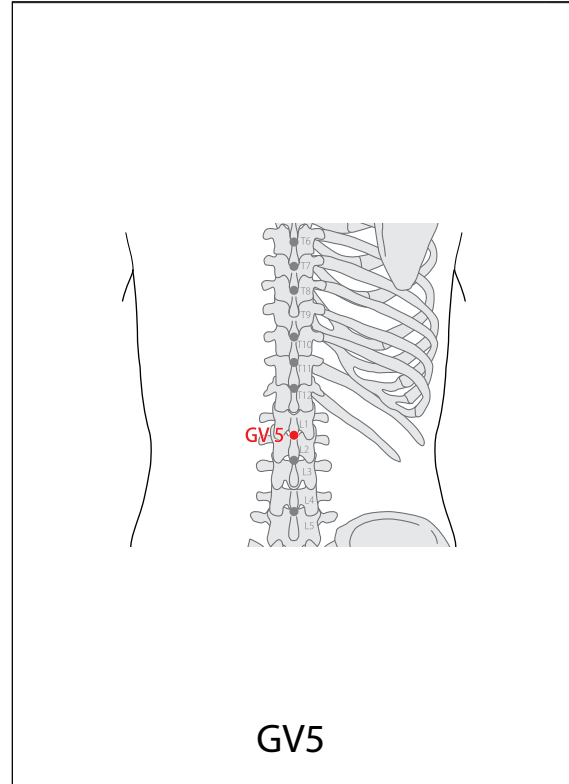
**GV4: Mingmen 命門(门)**

In the lumbar region, in the depression inferior to the spinous process of the second lumbar vertebra (L2), on the posterior median line.



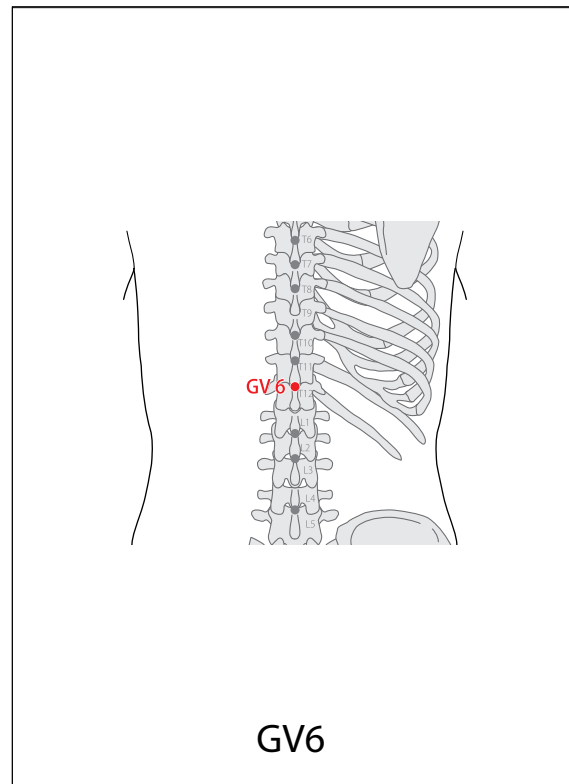
### GV5: Xuanshu 懸(悬)樞(枢)

In the lumbar region, in the depression inferior to the spinous process of the first lumbar vertebra (L1), on the posterior median line.



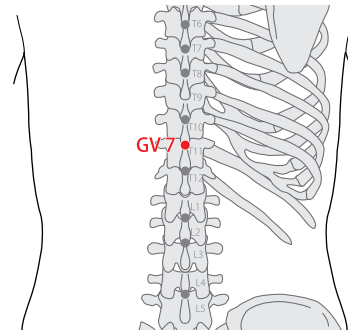
### GV6: Jizhong 脊中

In the upper back region, in the depression inferior to the spinous process of the 11th thoracic vertebra (T11), on the posterior median line.

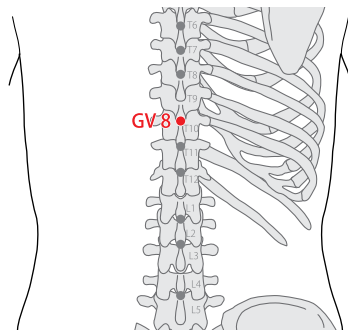


**GV7: Zhongshu 中樞 (枢)**

In the upper back region, in the depression inferior to the spinous process of the tenth thoracic vertebra (T10), on the posterior median line.

**GV7****GV8: Jinsuo 筋縮 (缩)**

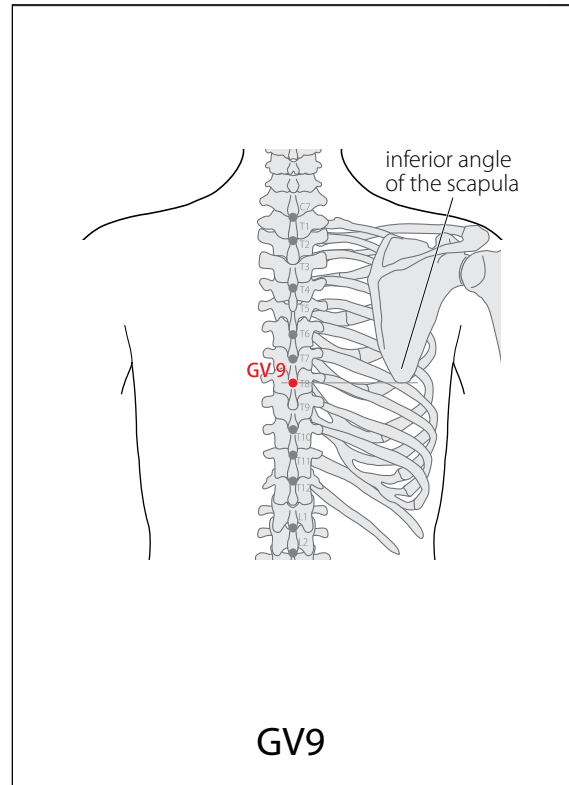
In the upper back region, in the depression inferior to the spinous process of the ninth thoracic vertebra (T9), on the posterior median line.

**GV8**

### GV9: Zhiyang 至陽(阳)

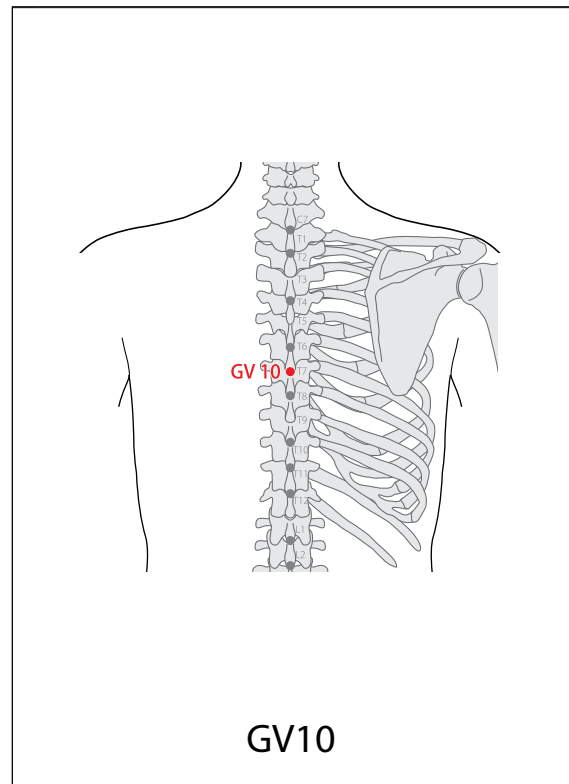
In the upper back region, in the depression inferior to the spinous process of the seventh thoracic vertebra (T7), on the posterior median line.

Note: The depression inferior to the spinous process of the seventh thoracic vertebra (T7) which is at the intersection of two imaginary lines: the posterior midline and the horizontal line of the inferior border of the inferior angle of the scapula.



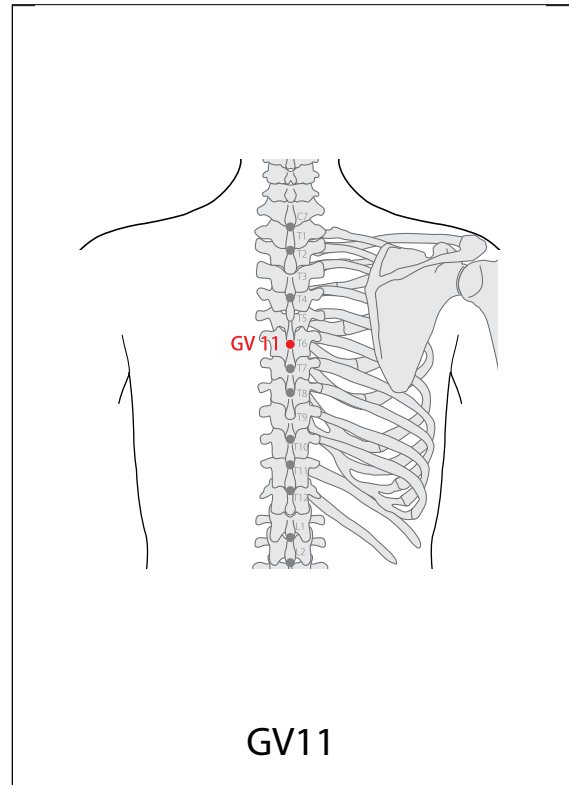
### GV10: Lingtai 靈(灵, 靈)臺(台)

In the upper back region, in the depression inferior to the spinous process of the sixth thoracic vertebra (T6), on the posterior median line.



## GV11: Shendao 神(神)道(道)

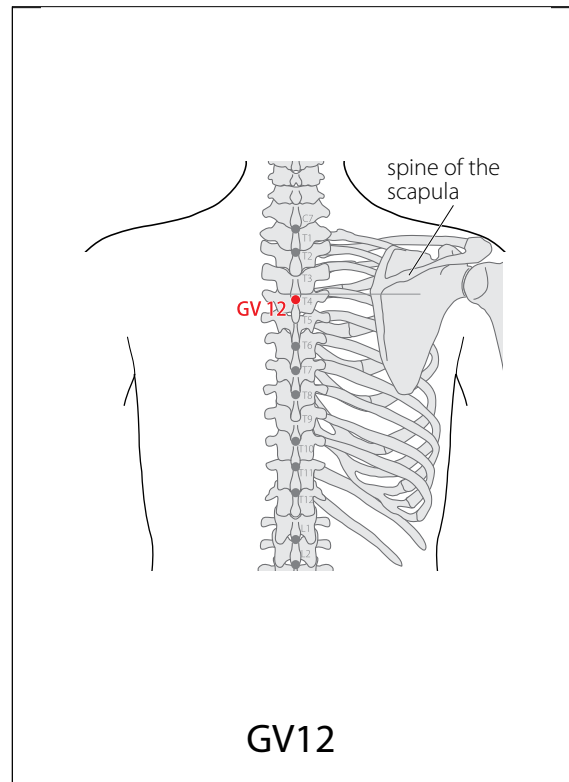
In the upper back region, in the depression inferior to the spinous process of the fifth thoracic vertebra (T5), on the posterior median line.



## GV12: Shenzhu 身柱

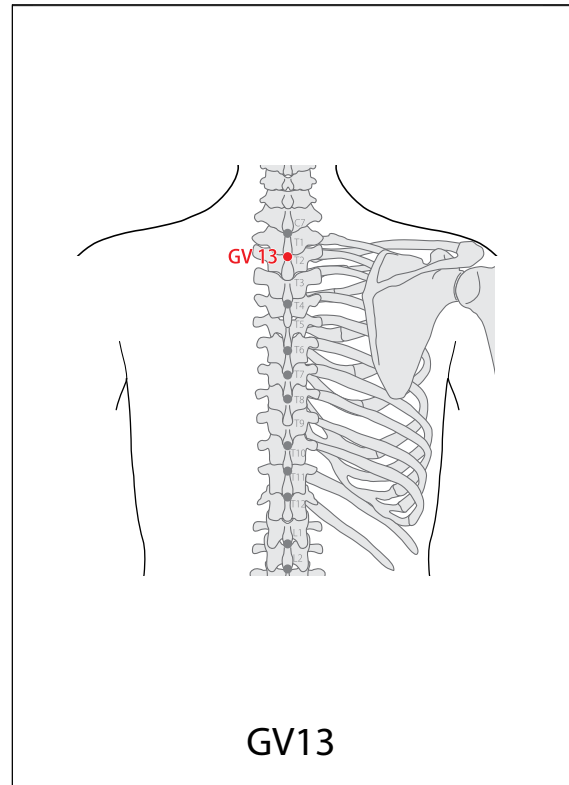
In the upper back region, in the depression inferior to the spinous process of the third thoracic vertebra (T3), on the posterior median line.

Note: The depression inferior to the spinous process of the third thoracic vertebra (T3) which is at the intersection of two imaginary lines: the posterior median line and the horizontal line of the medial end of the spine of the scapula.



### GV13: Taodao 陶道 (道)

In the upper back region, in the depression inferior to the spinous process of the first thoracic vertebra (T1), on the posterior median line.

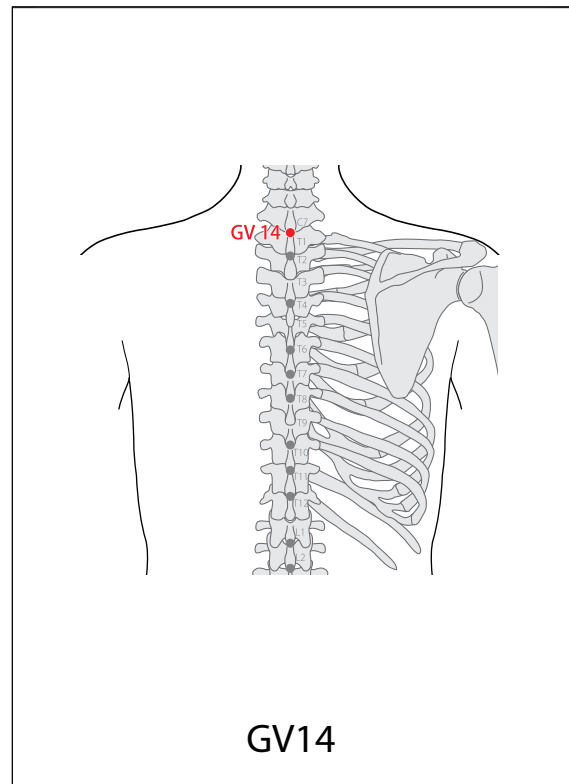


### GV14: Dazhui 大椎

In the posterior region of the neck, in the depression inferior to the spinous process of the seventh cervical vertebra (C7), on the posterior median line.

Note 1: When the head is in a neutral position while the subject is seated, the most prominent site on the posterior aspect of the neck is the spinous process of the seventh cervical vertebra (C7). Forward flexion of the neck may facilitate palpation of the C7 spinous process.

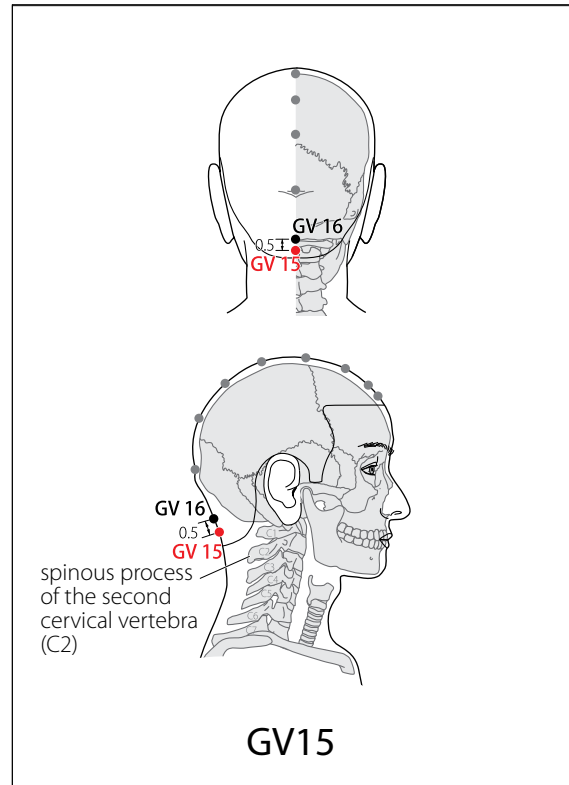
Note 2: Slight rotation of C7 can be palpated by rotating the head with the neck slightly flexed.



### GV15: Yamen 瘖(哑)門(门)

In the posterior region of the neck, in the depression superior to the spinous process of the second cervical vertebra (C2), on the posterior median line.

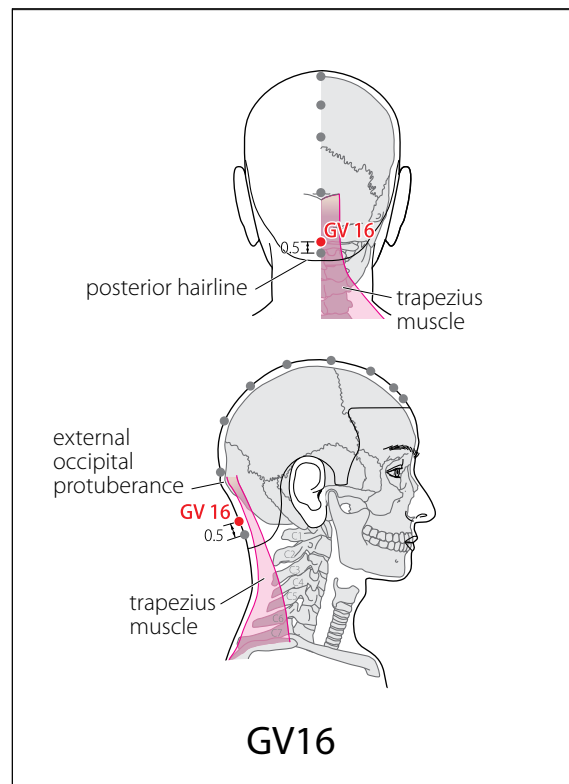
Note: After locating GV16, GV15 is located 0.5 B-cun inferior to GV16.



### GV16: Fengfu 風(风)府

In the posterior region of the neck, directly inferior to the external occipital protuberance, in the depression between the trapezius muscles.

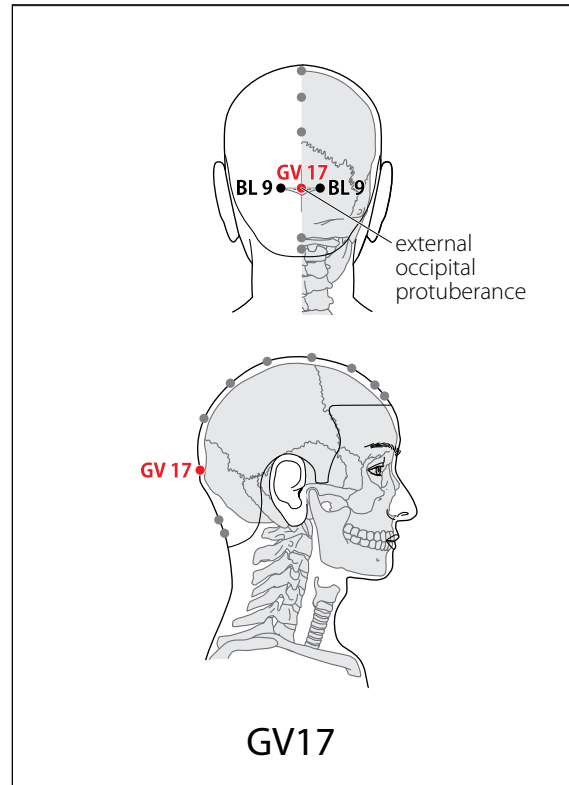
Note: With the head slightly extended in the seated position, loosen the trapezius muscle, then move superiorly from the midpoint of the posterior hairline to the occipital bone, GV16 will be found.



### GV17: Naohu 腦(腦)戶

On the head, in the depression superior to the external occipital protuberance.

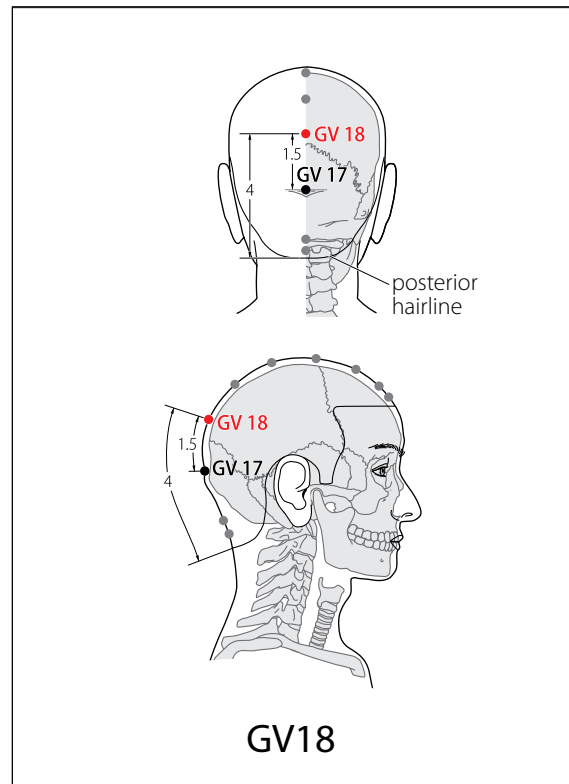
Note: GV17 is located in the depression at the intersection of two imaginary lines: the vertical line of the posterior median line and the horizontal line of the superior border of the external occipital protuberance, at the same level as BL9.



### GV18: Qiangjian 強間(間)

On the head, 4 B-cun superior to the posterior hairline, on the posterior median line.

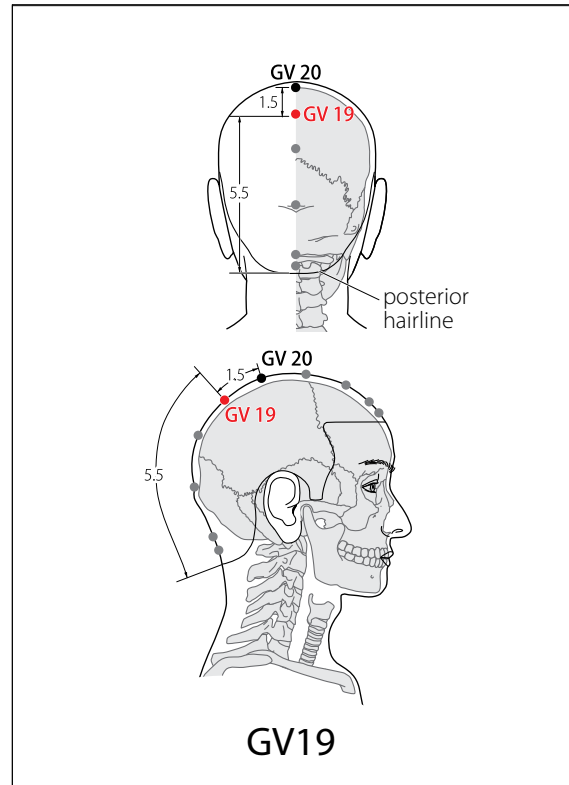
Note: GV18 is located in the depression 1.5 B-cun superior to GV17.



### GV19: Houding 後(后)頂(頂)

On the head, 5.5 B-cun superior to the posterior hairline, on the posterior median line.

Note: GV19 is located 1.5 B-cun posterior to GV20.

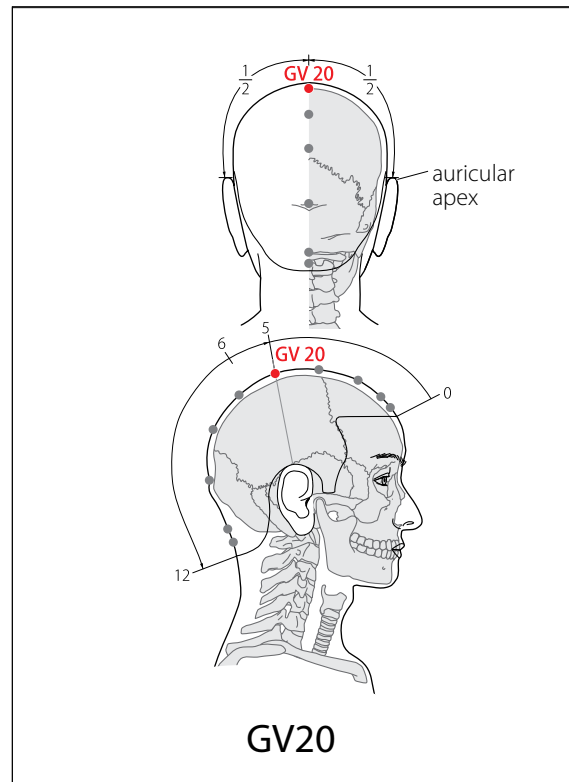


### GV20: Baihui 百會(會)

On the head, 5 B-cun superior to the anterior hairline, on the anterior median line.

Note 1: GV20 is located in the depression 1 B-cun anterior to the midpoint of the line from the anterior hairline to the posterior hairline.

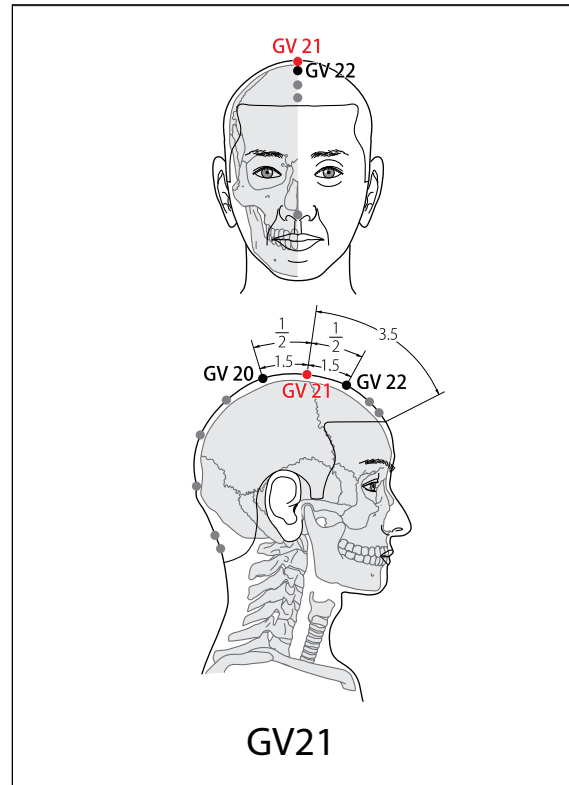
Note 2: When the ears are folded, GV20 is located at the midpoint of the connecting line between the auricular apices.



## GV21: Qianding 前頂(頂)

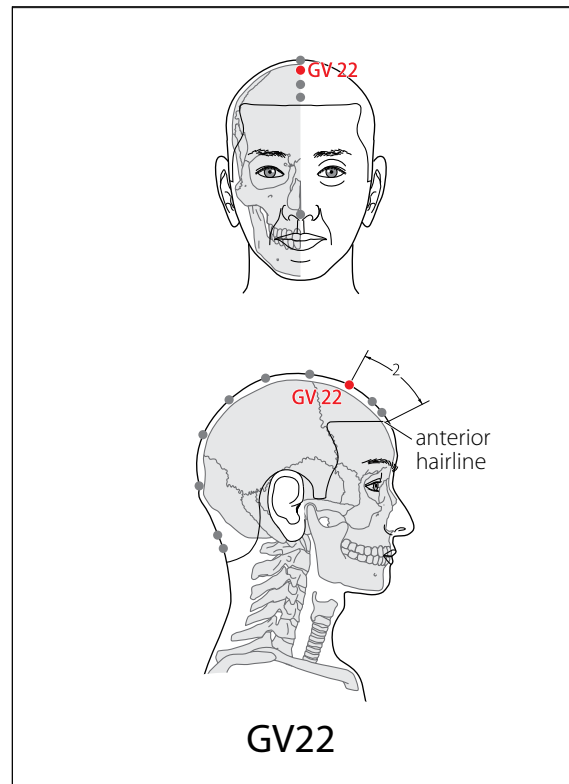
On the head, 3.5 B-cun superior to the anterior hairline, on the anterior median line.

Note: GV21 is located at the midpoint of the line connecting GV20 and GV22.



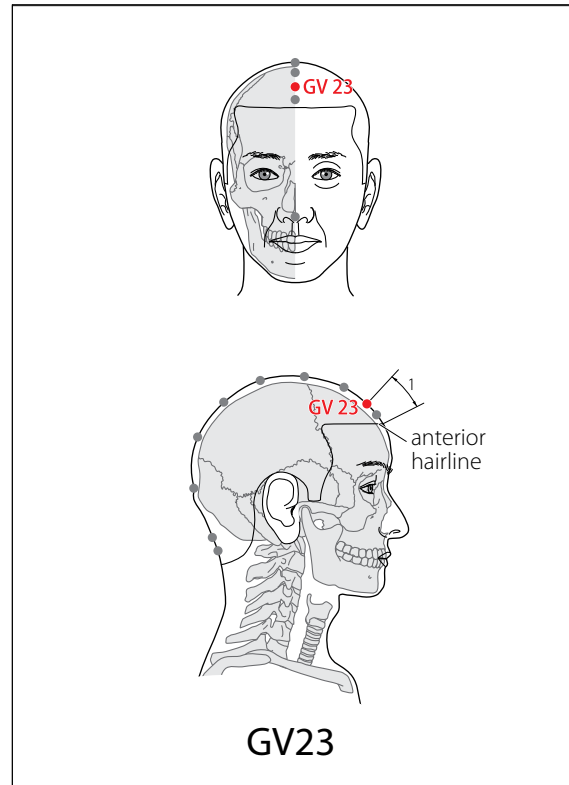
## GV22: Xinhui 顙(囟)會(会)

On the head, 2 B-cun superior to the anterior hairline, on the anterior median line.



### GV23: Shangxing 上星

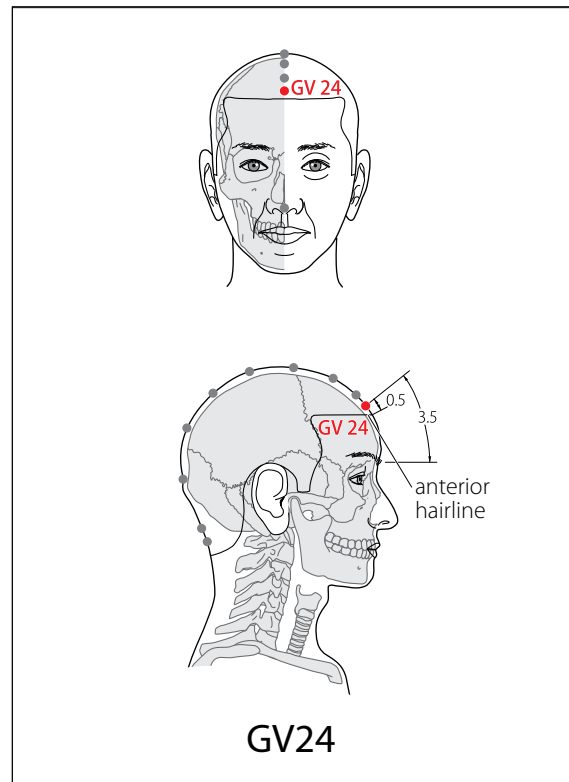
On the head, 1 B-cun superior to the anterior hairline, on the anterior median line.



### GV24: Shenting 神(神)庭

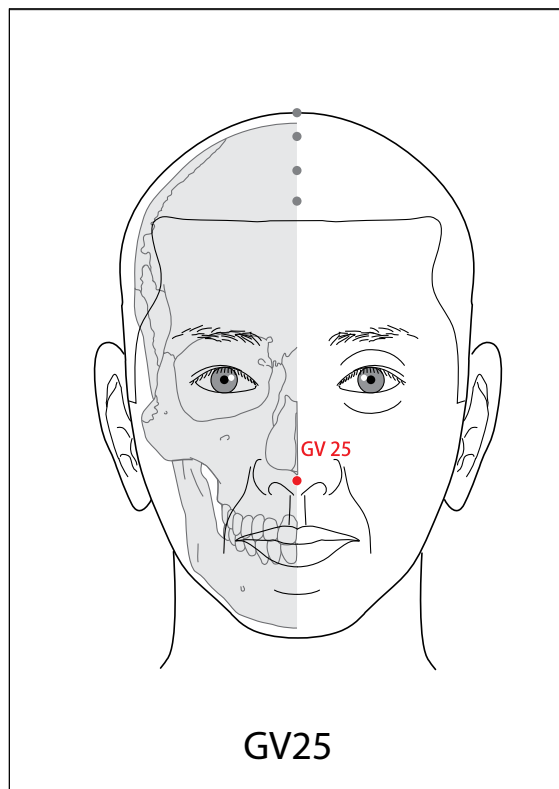
On the head, 0.5 B-cun superior to the anterior hairline, on the anterior median line.

Note: When the anterior hairline is unclear or changed, GV 24 is located 3.5 B-cun superior to the midpoint between the medial ends of the eyebrows.



# GV25: Suliao 素膠 (膠)

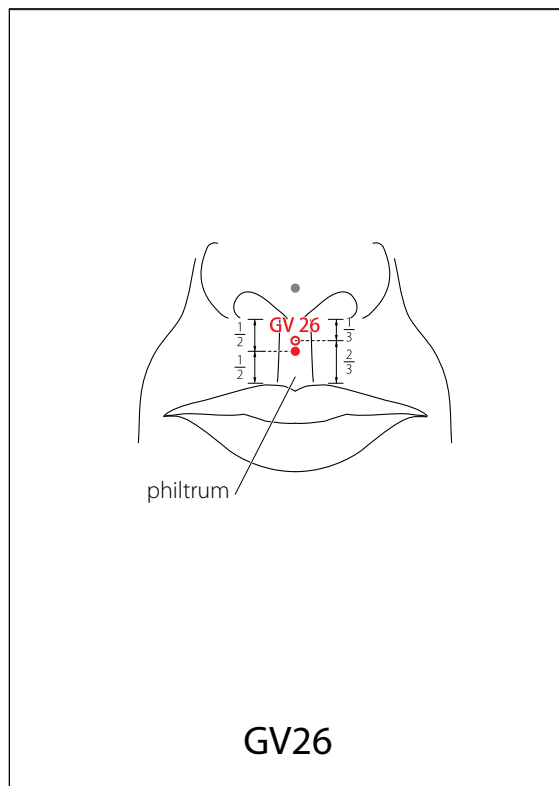
On the face, at the tip of the nose.



# GV26: Shuigou 水溝 (沟)

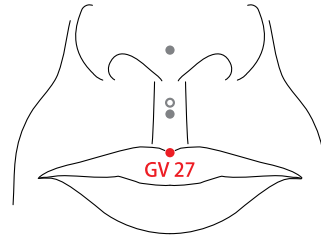
On the face, at the midpoint of the philtrum midline.

Remarks: Alternative location for GV26 -  
At the junction of the upper one third and lower two thirds of the philtrum midline.



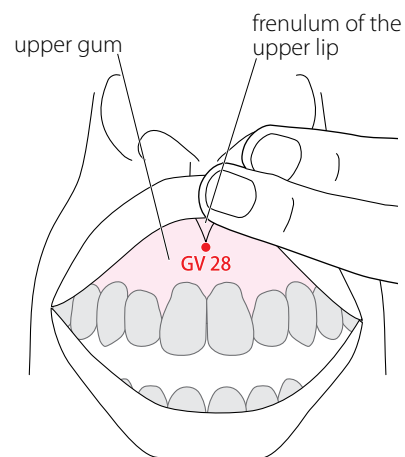
**GV27: Duiduan 兌(兑)端**

On the face, at the midpoint of the tubercle of the upper lip.

**GV27****GV28: Yinjiao 𪔐(𪔐)交**

On the face, at the junction of the frenulum of the upper lip with the upper gum.

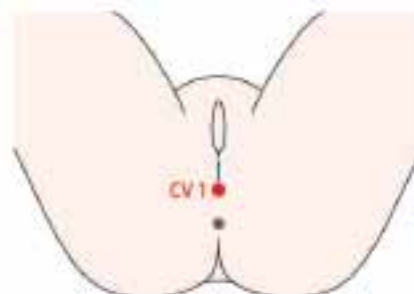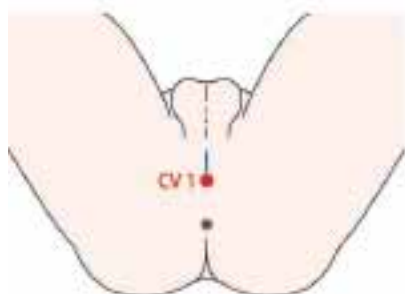
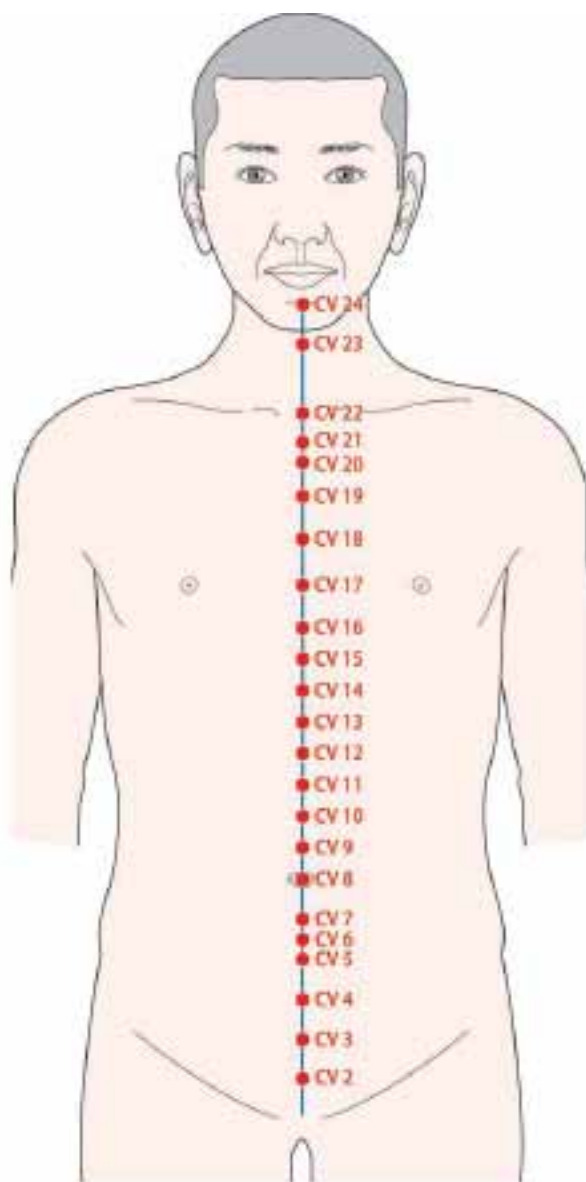
Note: With the head extended in the seated posture and the upper lip lifted, GV28 is located at the junction of the frenulum of the upper lip with the upper gum.

**GV28**



# CONCEPTION VESSEL

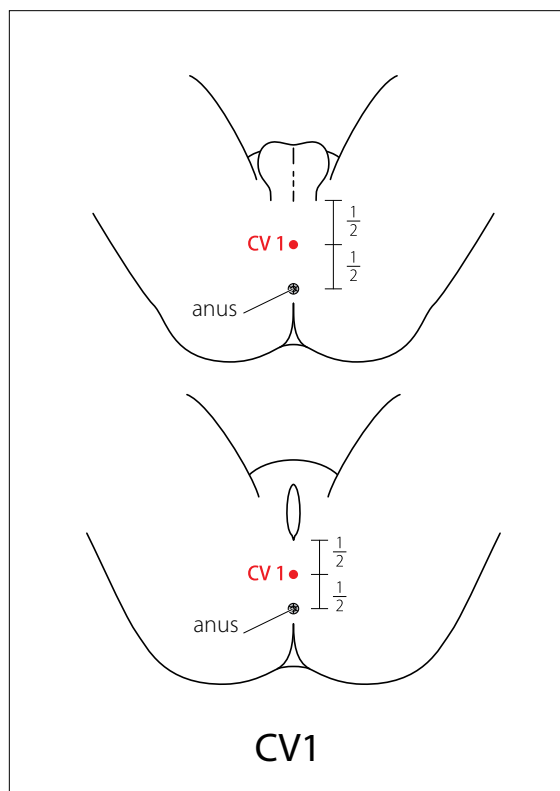
任脈(脉)



### CV1: Huiyin 會(会)陰(阴)

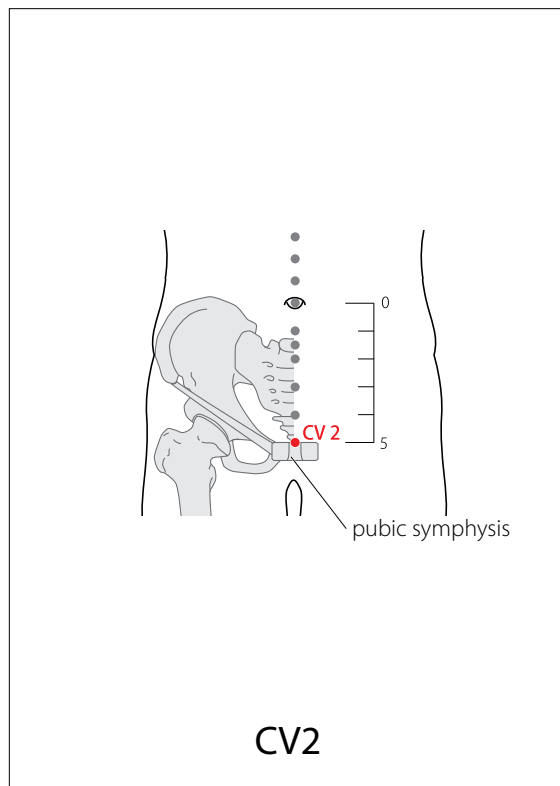
In the perineal region, at the midpoint of the line connecting the anus with the posterior border of the scrotum in males and the posterior commissure of labium majoris in females.

Note: CV1 is located midway between the anus and the genital organ, with the subject lying on the side or in knee-chest position.



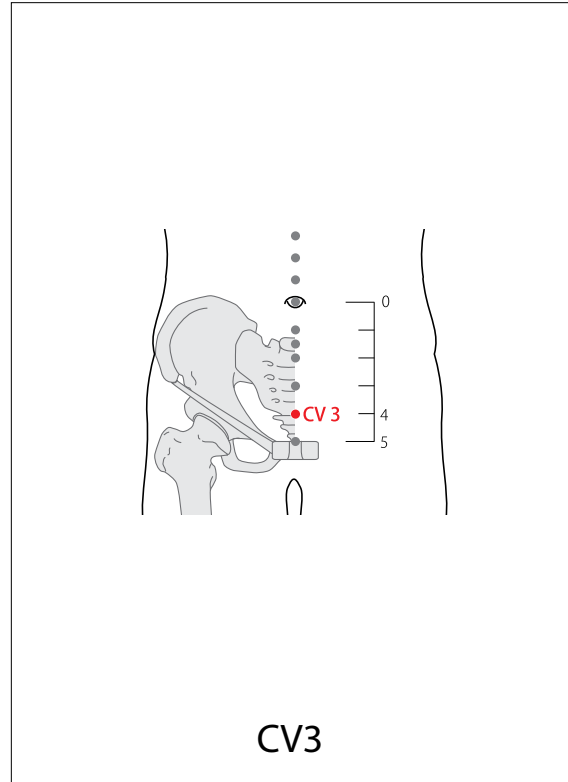
### CV2: Qugu 曲骨(骨)

On the lower abdomen, superior to the pubic symphysis, on the anterior median line.

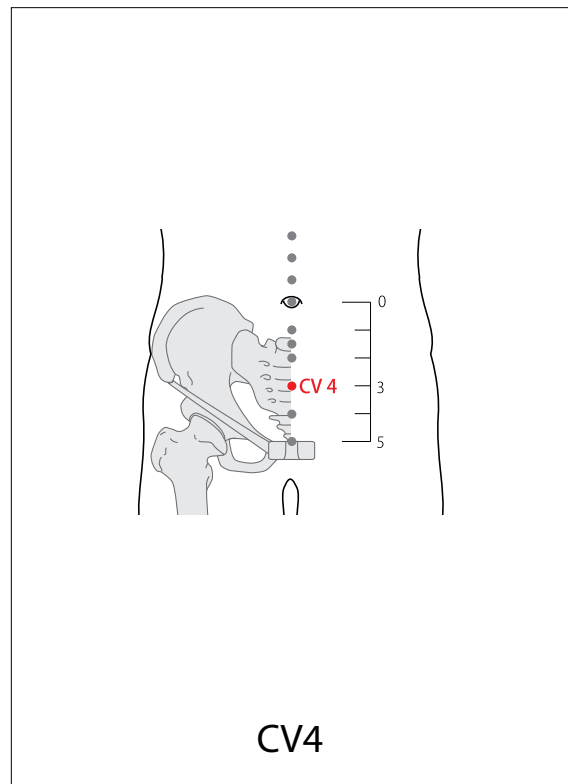


**CV3: Zhongji 中極(极)**

On the lower abdomen, 4 B-cun inferior to the centre of the umbilicus, on the anterior median line.

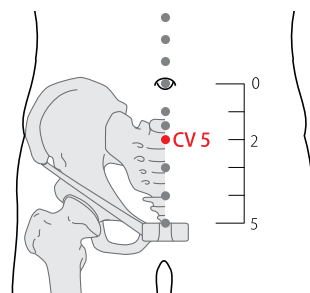
**CV4: Guanyuan 關(关, 関)元**

On the lower abdomen, 3 B-cun inferior to the centre of the umbilicus, on the anterior median line.



### CV5: Shimen 石門(門)

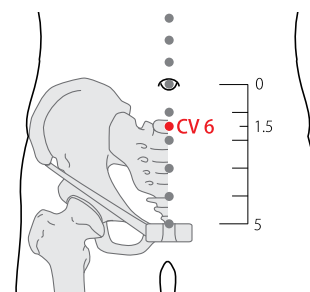
On the lower abdomen, 2 B-cun inferior to the centre of the umbilicus, on the anterior median line.



CV5

### CV6: Qihai 氣(气, 氣)海(海)

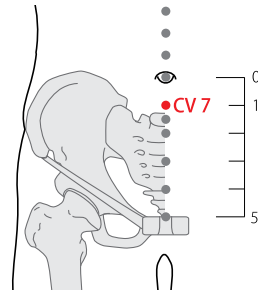
On the lower abdomen, 1.5 B-cun inferior to the centre of the umbilicus, on the anterior median line.



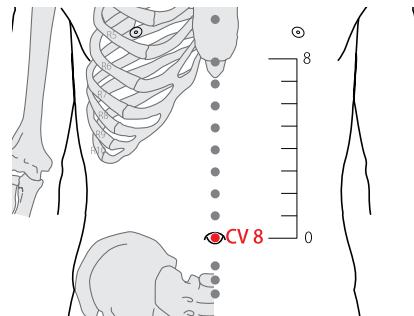
CV6

**CV7: Yinjiao 陰(阴)交**

On the lower abdomen, 1 B-cun inferior to the centre of the umbilicus, on the anterior median line.

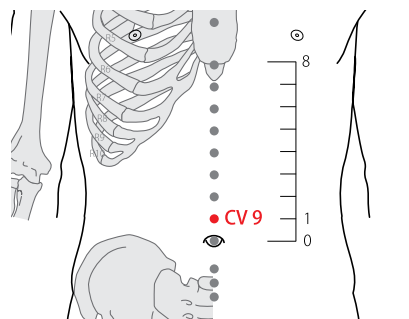
**CV7****CV8: Shenque 神(神)闕(阙)**

On the upper abdomen, in the centre of the umbilicus.

**CV8**

### CV9: Shuifen 水分

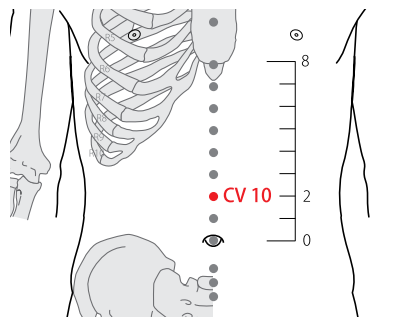
On the upper abdomen, 1 B-cun superior to the centre of the umbilicus, on the anterior median line.



CV9

### CV10: Xiawan 下脘

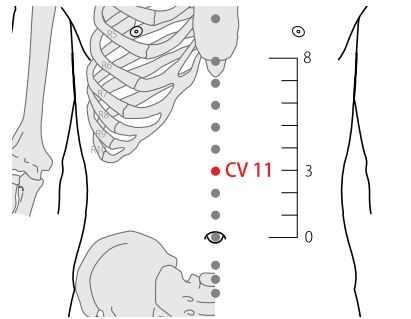
On the upper abdomen, 2 B-cun superior to the centre of the umbilicus, on the anterior median line.



CV10

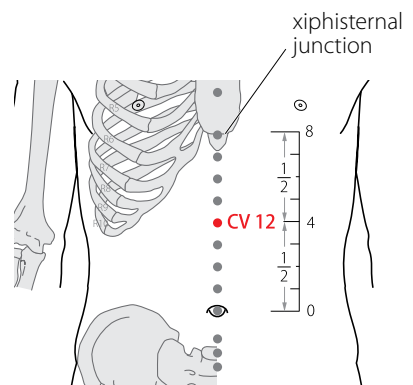
**CV11: Jianli 建里**

On the upper abdomen, 3 B-cun superior to the centre of the umbilicus, on the anterior median line.

**CV11****CV12: Zhongwan 中脘**

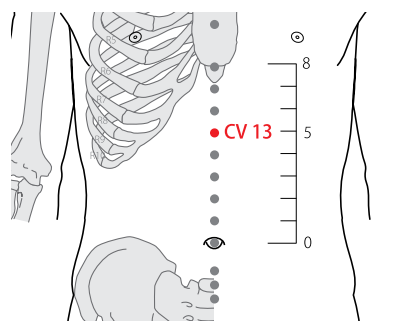
On the upper abdomen, 4 B-cun superior to the centre of the umbilicus, on the anterior median line.

Note: CV12 is located at the midpoint of the line connecting the xiphisternal junction and the centre of umbilicus.

**CV12**

### CV13: Shangwan 上脘

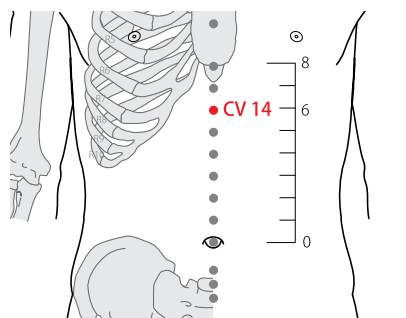
On the upper abdomen, 5 B-cun superior to the centre of the umbilicus, on the anterior median line.



CV13

### CV14: Juque 巨闕 (阙)

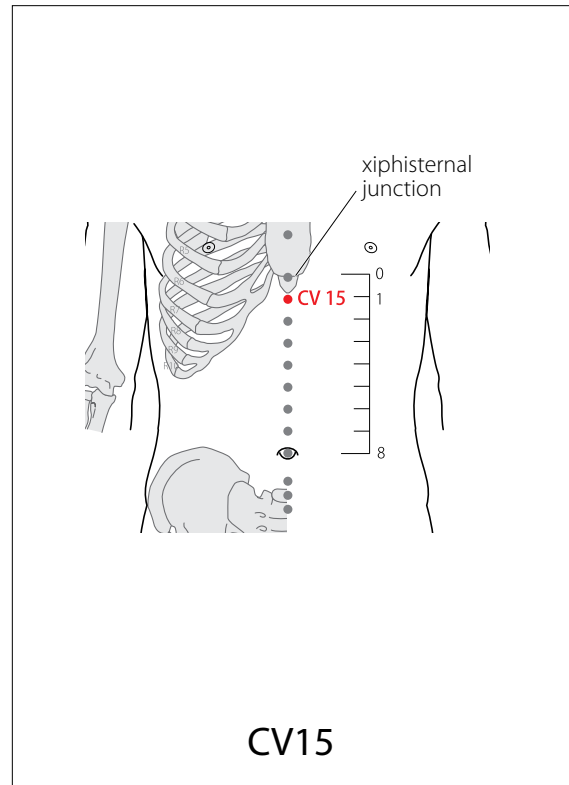
On the upper abdomen, 6 B-cun superior to the centre of the umbilicus, on the anterior median line.



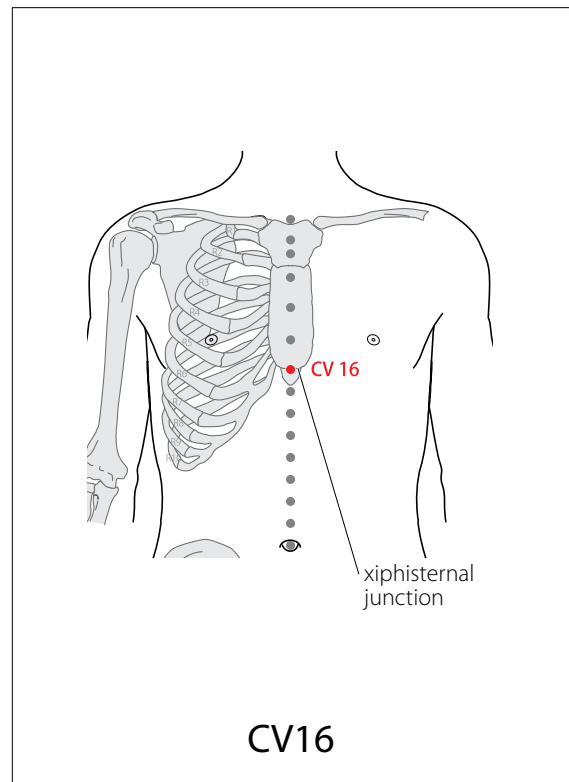
CV14

**CV15: Jiuwei 鳩(鳩)尾**

On the upper abdomen, 1 B-cun inferior to the xiphisternal junction, on the anterior median line.

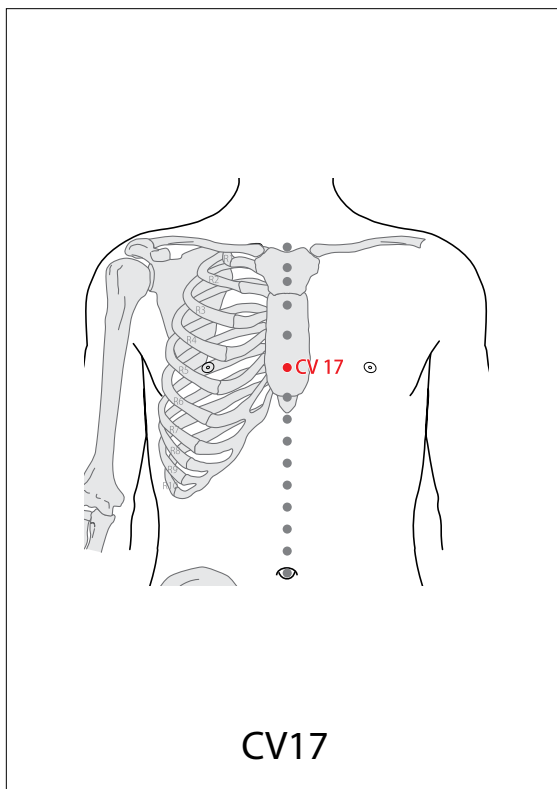
**CV16: Zhongting 中庭**

In the anterior thoracic region, at the midpoint of the xiphisternal junction, on the anterior median line.

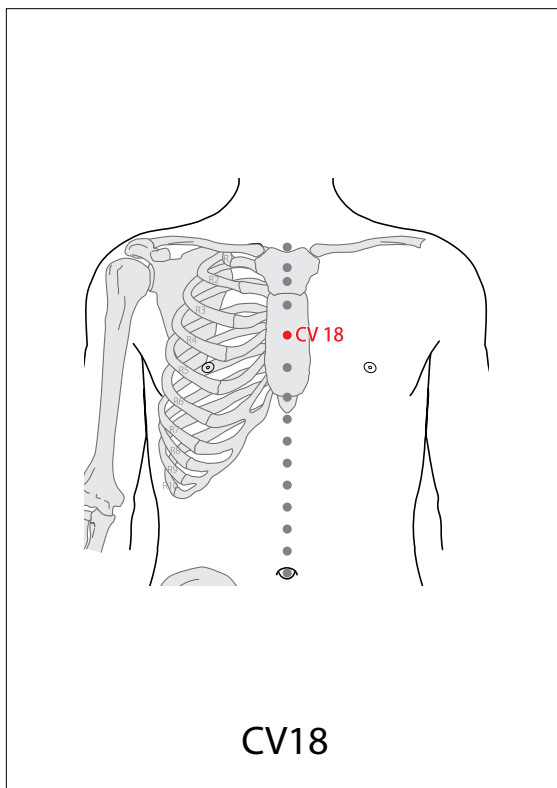


**CV17: Danzhong 膻中**

In the anterior thoracic region, at the same level as the fourth intercostal space, on the anterior median line.

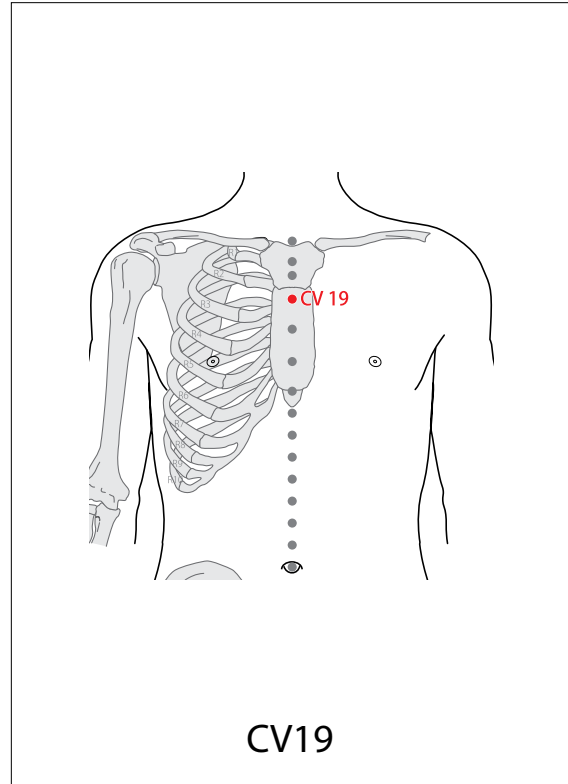
**CV18: Yutang 玉堂**

In the anterior thoracic region, at the same level as the third intercostal space, on the anterior median line.

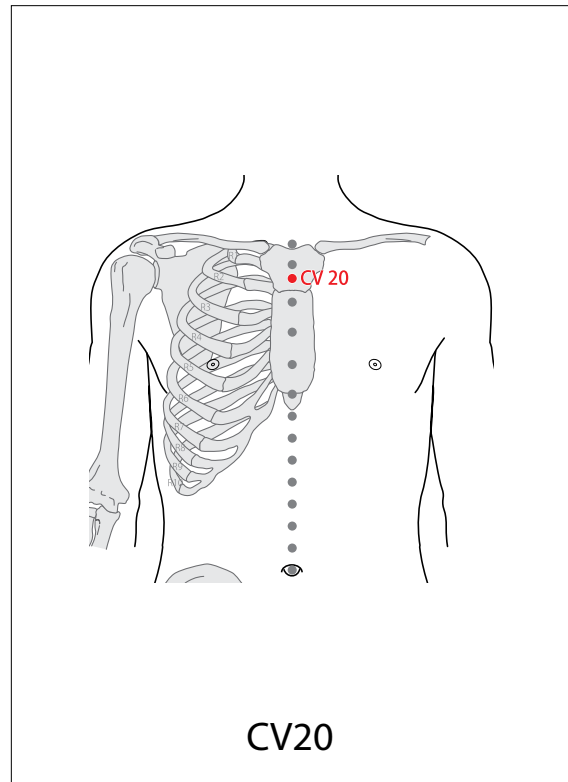


**CV19: Zigong 紫宫 (宫)**

In the anterior thoracic region, at the same level as the second intercostal space, on the anterior median line.

**CV20: Huagai 华 (华) 盖 (盖)**

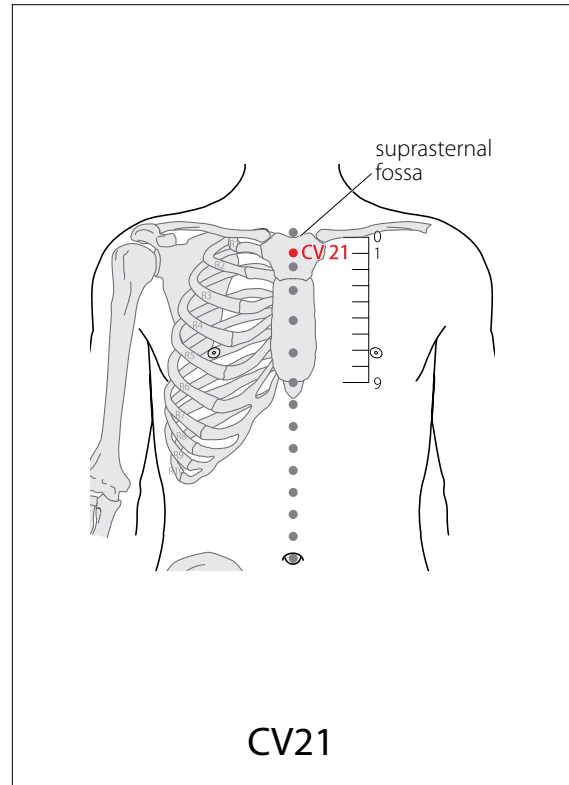
In the anterior thoracic region, at the same level as the first intercostal space, on the anterior median line.



### CV21: Xuanji 璇璣 (玑)

In the anterior thoracic region, 1 B-cun inferior to the suprasternal fossa, on the anterior median line.

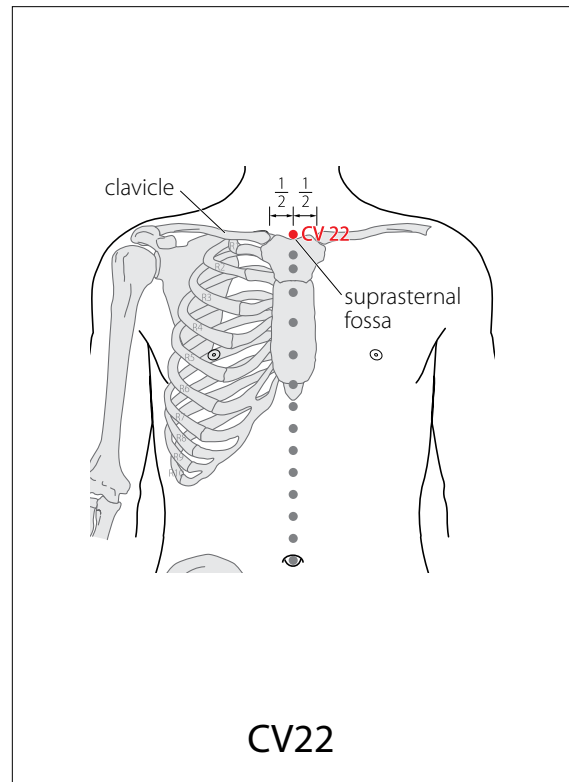
Note: CV21 is located 1 B-cun inferior to CV22.



### CV22: Tiantu 天突

In the anterior region of the neck, in the centre of the suprasternal fossa, on the anterior median line.

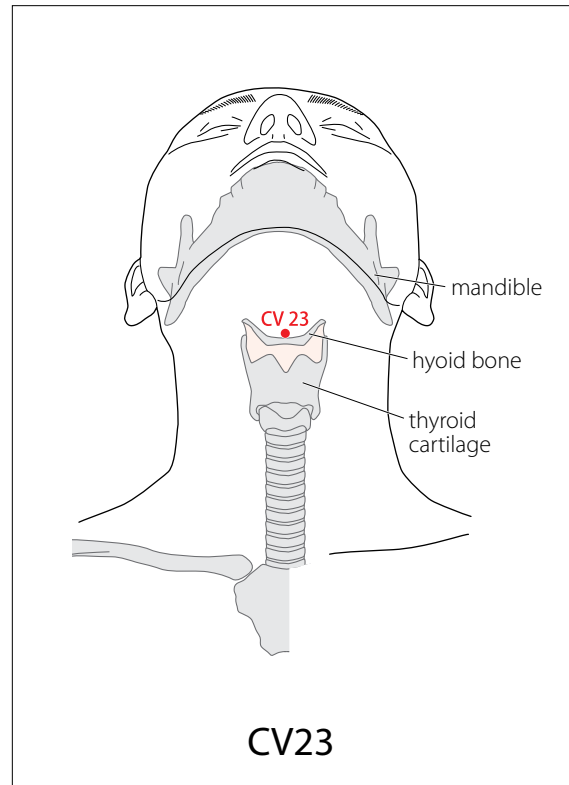
Note: CV22 is located in the depression midway between the medial ends of each clavicle.



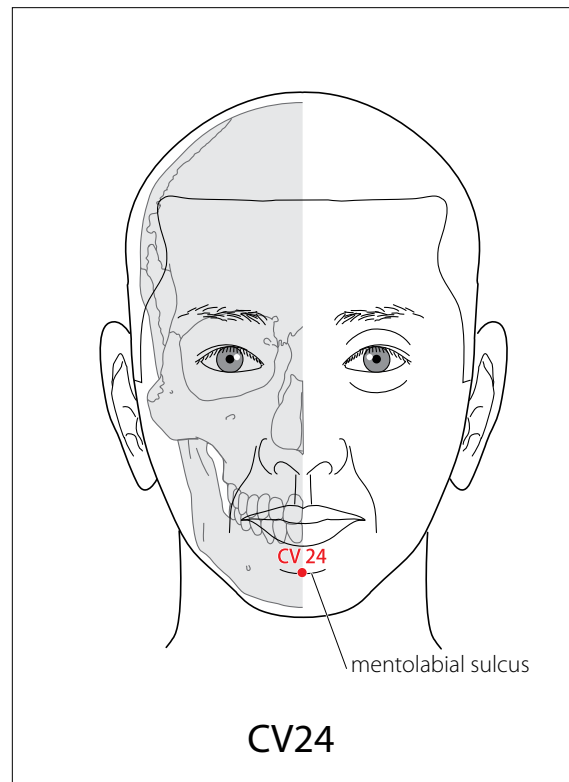
**CV23: Lianquan 廉泉**

In the anterior region of the neck, superior to superior border to thyroid cartilage, in the depression superior to the hyoid bone, on the anterior median line.

Note: With the head slightly extended, the hyoid tubercle can be palpated between the mandible and the thyroid cartilage.

**CV24: Chengjiang 承漿 (漿)**

On the face, in the depression in the centre of the mentolabial sulcus.





## REFERENCES

1. World Health Organization Regional Office for the Western Pacific, Standard Acupuncture Nomenclature, WPRO, Manila, Philippines, 1991
2. World Health Organization Regional Office for the Western Pacific, Standard Acupuncture Nomenclature, 2nd edition, WPRO, Manila, Philippines, 1993
3. World Health Organization Regional Office for the Western Pacific, WHO International Standard Terminologies on Traditional Medicine in the Western Pacific Region, WPRO, Manila, Philippines, 2007
4. 作者未详, 黄帝内经灵枢, 人民卫生出版社影印, 北京, 1956
5. 皇甫谧, 针灸甲乙经, 华夏出版社, 北京, 1996
6. 王怀隐等, 太平圣惠方, 人民卫生出版社影印, 北京, 1958
7. 王惟一, 铜人腧穴针灸图经, 华夏出版社, 北京, 1996
8. 作者未详, 循经考穴编, 群联出版社影印, 上海, 1955
9. 中华人民共和国国家标准 经穴部位 (GB 12346-90), 标准出版社, 北京, 1990
10. The National Standard of the People's Republic of China, Locations of Points, Standards Press of China, Beijing, 1990
11. State Standard of the People's Republic of China, THE LOCATION OF POINTS, Foreign Languages Press, Beijing, 1990
12. 国家中医药管理局, 经穴部位文献与解剖-中华人民共和国国家标准 经穴部位的编制说明, 中国中医药出版社, 北京, 1990
13. 中国解剖学会体质调查委员会, 中国人解剖学数值, 人民卫生出版社, 北京, 2002
14. 王德深, 中国针灸穴位通鉴, 青岛出版社, 青岛, 2004
15. (第1次) 日本经穴委员会, 标准经穴学, 医齿药出版社, 东京, 1989
16. 松元四郎平, 孔穴类聚, 绩文堂, 东京, 1927 (1998年复刻)
17. 驹井一雄, 经络经穴学, 绩文堂, 东京, 1939 (1976年复刻)
18. 本间祥白, 图解鍼灸实用经穴学, 医道の日本社, 横须贺, 1955 (1983年复刻)
19. 山下詢, 临床经络经穴图解, 医齿药出版社, 东京, 1972
20. 竹之内診佐夫 濱添圀弘, 鍼灸医学, 南山堂, 东京, 1977 (2003年复刻)
21. 森秀太郎, 解剖经穴图, 医道の日本社, 横须贺, 1984

22. 形井秀一編, 山下詢著, カラーアトラス取穴法, 医歯薬出版社, 東京, 2000
23. 崔容泰 李秀鎬, 精解鍼灸學, 杏林書院, 서울, 1974
24. 崔容泰 外, 鍼灸學(上), 集文堂, 서울, 1988
25. 安榮基, 鍼灸學叢書, 成輔社, 서울, 1991
26. 全國韓醫科大學 經穴學教室, 圖解經穴學, 正文閣, 서울, 2003
27. Deadman P, Baker K, Al-khafaji M, A Manual of Acupuncture, Journal of Chinese Medicine Publication, California, 1998
28. Drake RL, Vogl W, Mitchell AWM, Gray's Anatomy for Students, Elsevier Churchill Livingstone, 2005
29. Federative Committee on Anatomical Terminology (FCAT), International Anatomical Terminology, George Thieme Verlag, 1998
30. Hecker HU et al, Color Atlas of Acupuncture, Thieme, Stuttgart, 2001
31. ISO/IEC Directives, Part 2, Rules for the structure and drafting of International Standards, 2004
32. Lotan A, Acupoint Location Guide, Etsem, Misgav, 2000
33. Lumley J, Surface Anatomy, 3rd Edition, Elsevier Churchill Livingstone, 2006
34. Tixa S, Atlas of Palpatory Anatomy of Limbs and Trunk, Icon Learning Systems, New Jersey, 2003

# ANNEX

## —— ANNEX 1 ——

### 1ST INFORMAL CONSULTATION ON DEVELOPMENT OF INTERNATIONAL STANDARD OF ACUPUNCTURE POINT LOCATIONS, IN MANILA, PHILIPPINES, OCTOBER 2003

#### TEMPORARY ADVISERS

CHINA	Professor Wang Xuetai Professor Huang Longxiang
JAPAN	Dr Yukio KUROSU Professor Tadashi YANO
REPUBLIC OF KOREA	Professor Kang Sung-keel Professor Kim Yong-suk

#### OBSERVER

JAPAN	Professor Kiichiro TSUTANI
-------	----------------------------

#### RESPONSIBLE OFFICERS

Dr Choi Seung-hoon  
Regional Adviser in Traditional Medicine  
WHO Western Pacific Regional Office

Dr Chen Ken  
WR/South Pacific  
WHO Western Pacific Regional Office

**Deliberation**

- Identified the willingness of developing WHO standard of acupuncture point locations
- Discussed country efforts made on standardization of acupuncture point locations
- Discussed the classical documents
- Discussed the standard measurements
- Discussed description of standard point locations

---

———— ANNEX 2 ————

2ND INFORMAL CONSULTATION ON DEVELOPMENT OF  
INTERNATIONAL STANDARD OF ACUPUNCTURE POINT LOCATIONS,  
IN BEIJING, CHINA, MARCH 2004

TEMPORARY ADVISERS

CHINA	Professor Wang Xuetai Professor Li Ding Professor Huang Longxiang
JAPAN	Professor Shuichi KATAI Dr Kenji KOBAYASHI Dr Hisatsuku URAYAMA
REPUBLIC OF KOREA	Professor Kang Sung-keel Professor Kim Yong-suk Professor Lee Hye-jung

OBSERVERS

CHINA	Professor Jin Zhigao
JAPAN	Professor Shoji SHINOHARA

RESPONSIBLE OFFICER

Dr Choi Seung-hoon  
Regional Adviser in Traditional Medicine  
WHO Western Pacific Regional Office

**Deliberation**

- Confirmed the principles and methods for locating acupuncture points
  1. the body landmarks and surface remarks for locating acupuncture points
  2. the proportional measurements
  3. the methods for describing standard point locations

———— ANNEX 3 ————

3RD INFORMAL CONSULTATION ON DEVELOPMENT OF  
INTERNATIONAL STANDARD OF ACUPUNCTURE POINT LOCATIONS,  
IN KYOTO, JAPAN, OCTOBER 2004

TEMPORARY ADVISERS

CHINA	Professor Wang Xuetai Professor Huang Longxiang Mrs Situ Wen
JAPAN	Professor Shuichi KATAI Dr Kenji KOBAYASHI Dr Hisatsuku URAYAMA
REPUBLIC OF KOREA	Professor Kang Sung-keel Professor Kim Yong-suk Professor Lee Hye-jung
UNITED KINGDOM	Professor Nigel Wiseman

OBSERVERS

JAPAN	Professor Shoji SHINOHARA Professor Shunji SAKAGUCHI Professor Yasuhiro KAWAHARA
REPUBLIC OF KOREA	Professor Yim Yun-kyoung

RESPONSIBLE OFFICER

Dr Choi Seung-hoon  
Regional Adviser in Traditional Medicine  
WHO Western Pacific Regional Office

**Deliberation**

- Identified 92 acupuncture points which have different locations among the Member States
- Started to review 92 controversial points

---

———— ANNEX 4 ————

1ST TASK FORCE TEAM MEETING ON DEVELOPMENT OF  
INTERNATIONAL STANDARD OF ACUPUNCTURE POINT LOCATIONS,  
IN BEIJING, CHINA, FEBRUARY 2005

TEMPORARY ADVISERS

CHINA	Professor Huang Longxiang
JAPAN	Professor Shuichi KATAI
REPUBLIC OF KOREA	Professor Kim Yong-suk

OBSERVERS

CHINA	Professor Wang Xuetai Professor Jin Zhigao
-------	---

RESPONSIBLE OFFICER

Dr Choi Seung-hoon  
Regional Adviser in Traditional Medicine  
WHO Western Pacific Regional Office

**Deliberation**

- Reviewed 12 controversial points out of 269 non-controversial points affirmed in Kyoto meeting
- Confirmed 80 points out of formerly reviewed 92 controversial points
- Reviewed 18 points omitted in Kyoto meeting
- Reviewed 8 remaining controversial points

---

———— ANNEX 5 ————

4TH INFORMAL CONSULTATION ON DEVELOPMENT OF  
INTERNATIONAL STANDARD OF ACUPUNCTURE POINT LOCATIONS,  
IN DAEJEON, REPUBLIC OF KOREA, APRIL 2005

TEMPORARY ADVISERS

CHINA	Professor Wang Xuetai Professor Huang Longxiang Professor Jin Zhigao Professor Wu Zhongchao
JAPAN	Professor Shuichi KATAI Dr Kenji KOBAYASHI Professor Shoji SHINOHARA Dr Hisatsuku URAYAMA
REPUBLIC OF KOREA	Professor Kang Sung-keel Professor Kim Yong-suk Professor Lee Hye-jung Dr Koo Sung-tae

OBSERVERS

CHINA	Dr Tan Yuansheng
JAPAN	Professor Yasuhiro KAWAHARA Professor Shunji SAKAGUCHI Dr Munenori SAITOH Mr Toshimitsu KATORI
REPUBLIC OF KOREA	Professor Yim Yun-kyoung Professor Park Hi-joon Professor Lee Sang-hoon Professor Song Ho-sub

RESPONSIBLE OFFICER

Dr Choi Seung-hoon  
Regional Adviser in Traditional Medicine  
WHO Western Pacific Regional Office

---

## **Deliberation**

- Reviewed the remaining controversial points with 24 points suggested by Chinese experts
- Discussed chart, text and model

———— ANNEX 6 ————

2ND TASK FORCE TEAM MEETING ON DEVELOPMENT OF  
INTERNATIONAL STANDARD OF ACUPUNCTURE POINT LOCATIONS,  
IN BEIJING, CHINA, AUGUST 2005

TEMPORARY ADVISERS

CHINA	Professor Huang Longxiang
JAPAN	Professor Shuichi KATAI
REPUBLIC OF KOREA	Professor Kim Yong-suk

OBSERVER

CHINA	Professor Wang Xuetai
-------	-----------------------

RESPONSIBLE OFFICER

Dr Choi Seung-hoon  
Regional Adviser in Traditional Medicine  
WHO Western Pacific Regional Office

**Deliberation**

- Reviewed the expressions of 269 non-controversial points